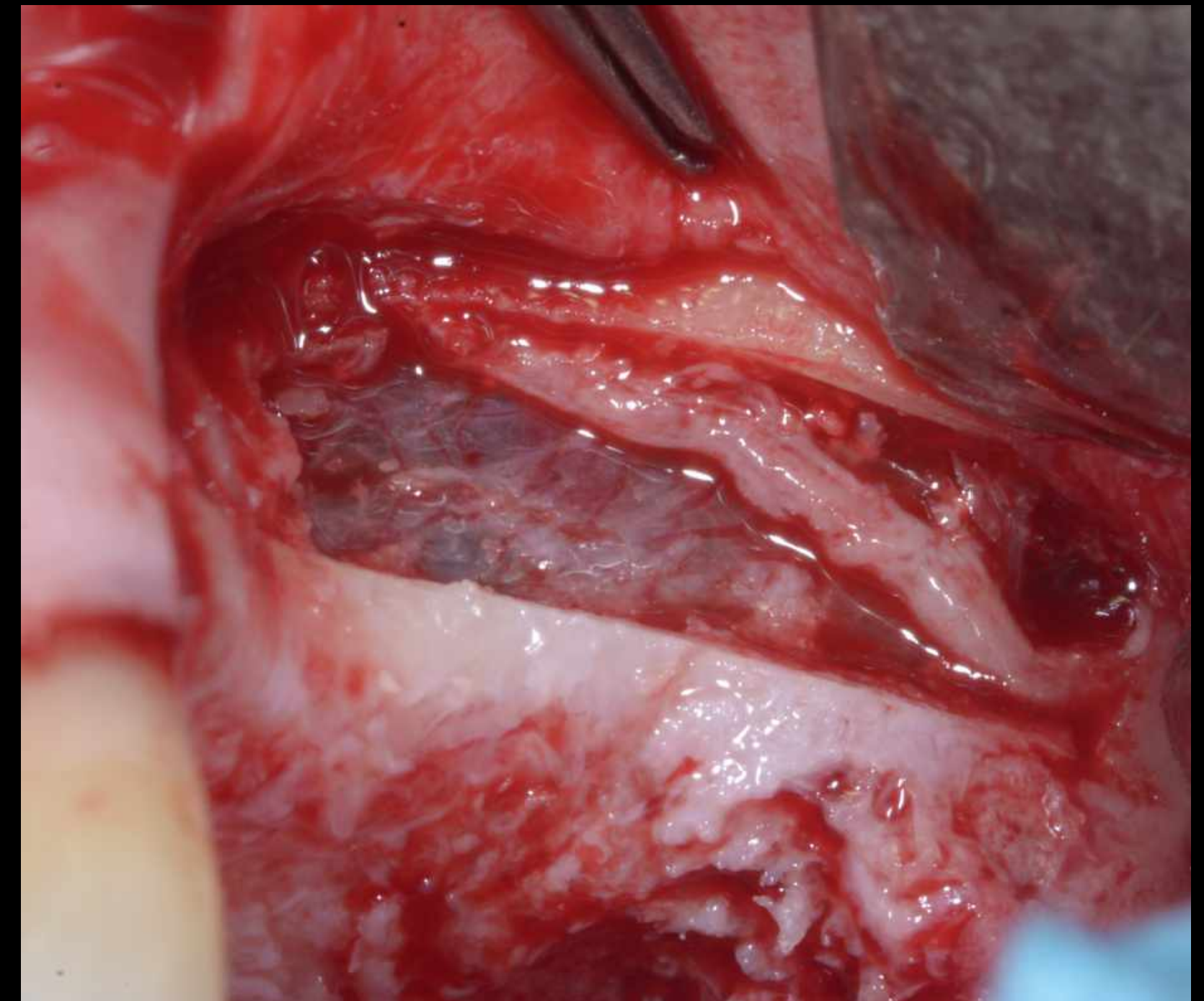
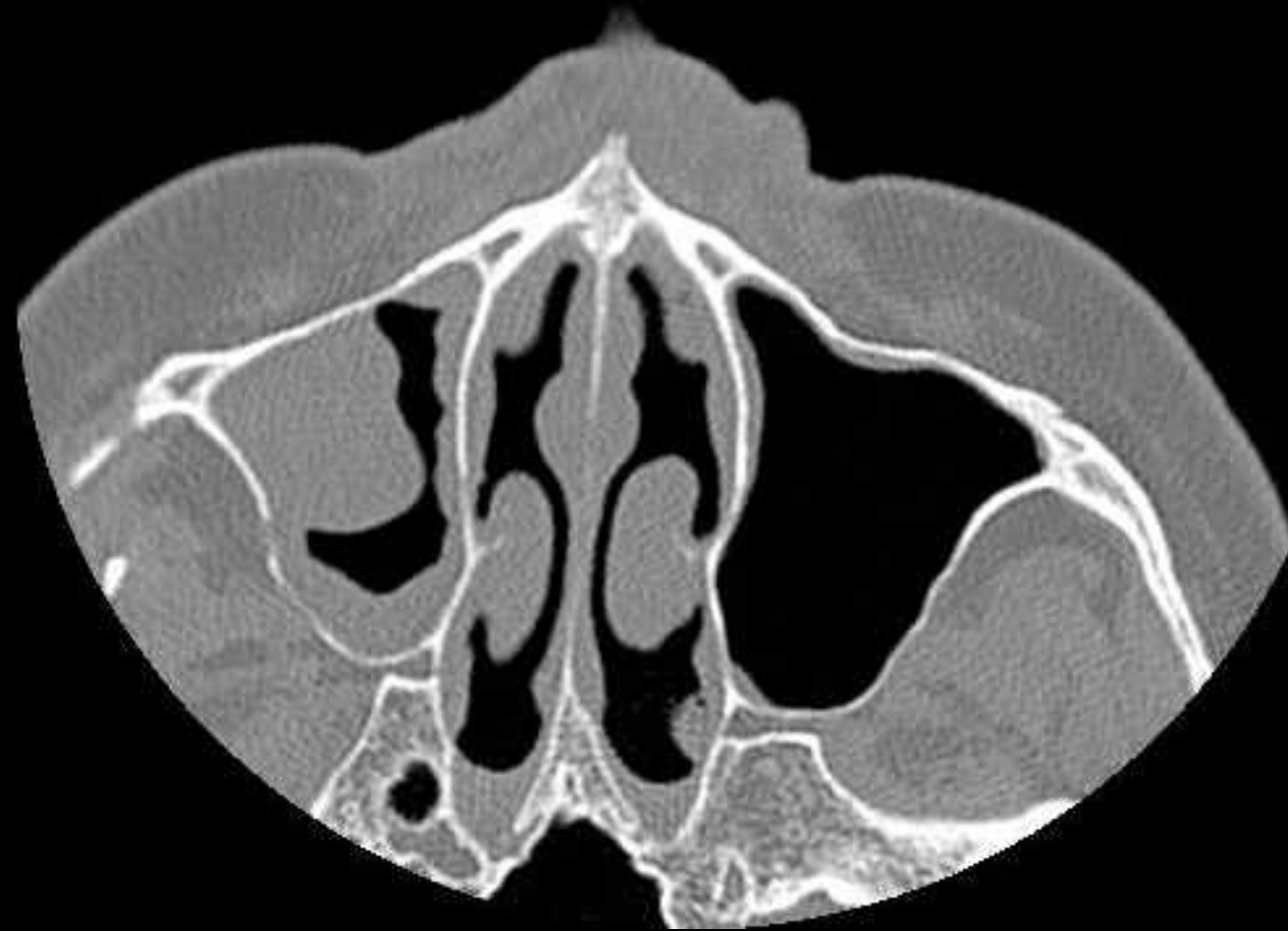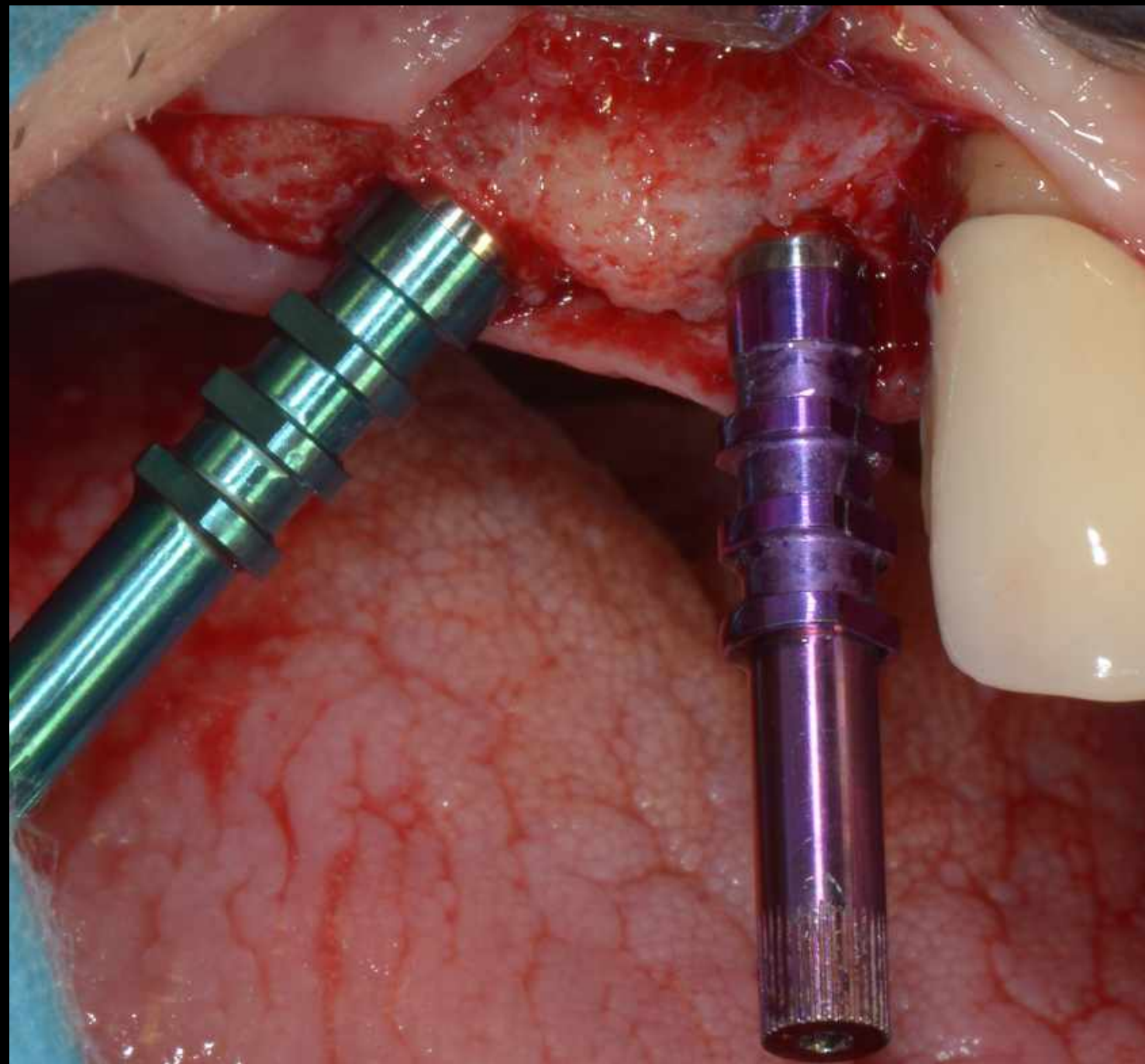
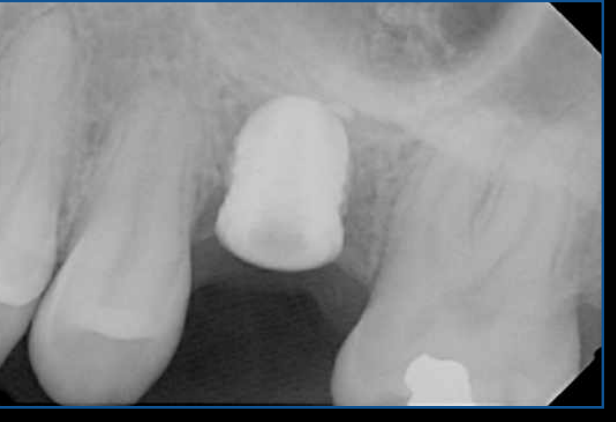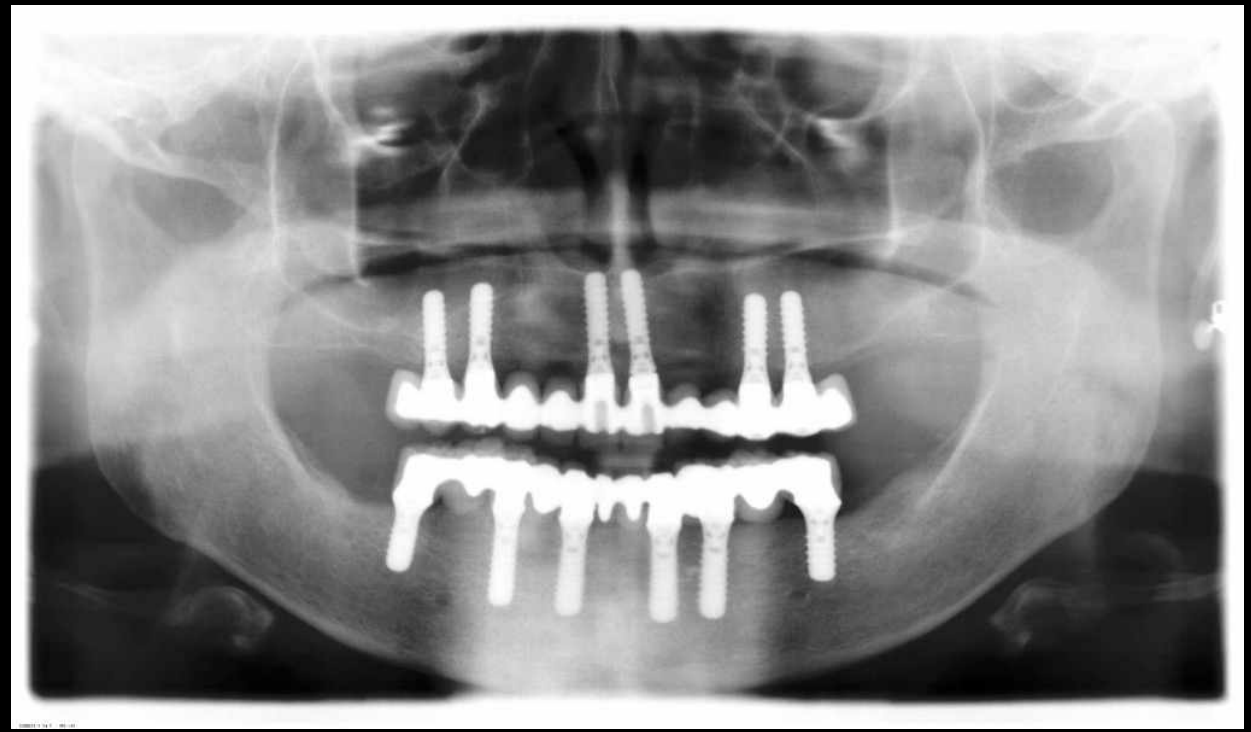


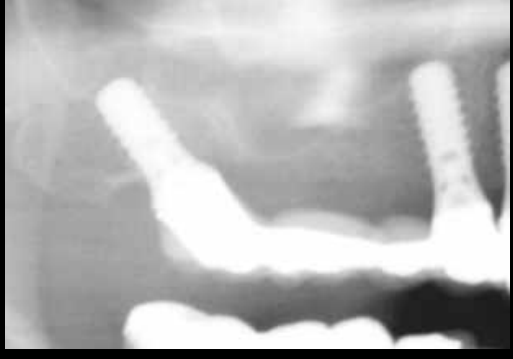
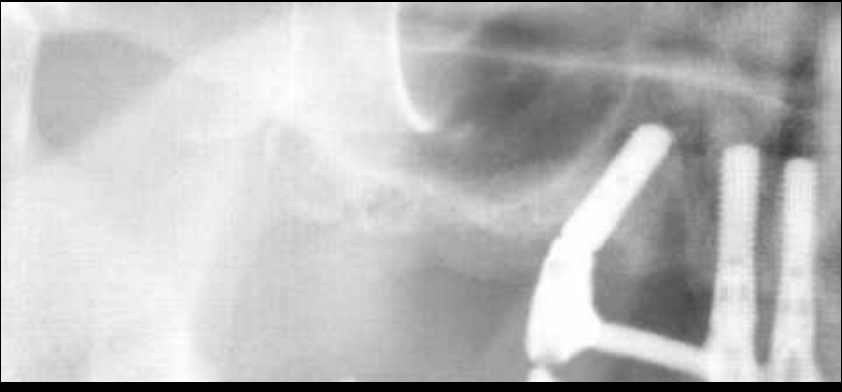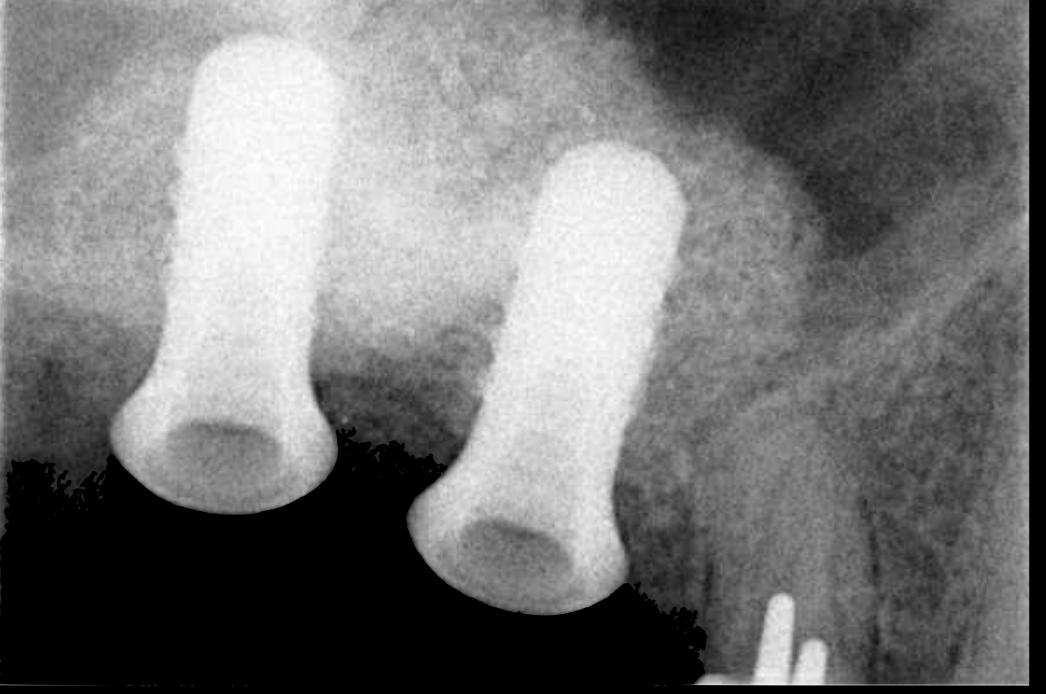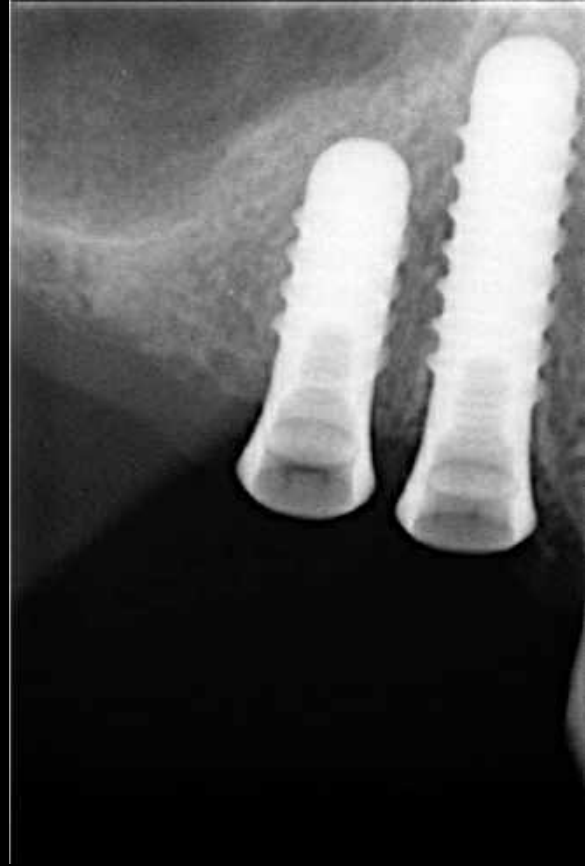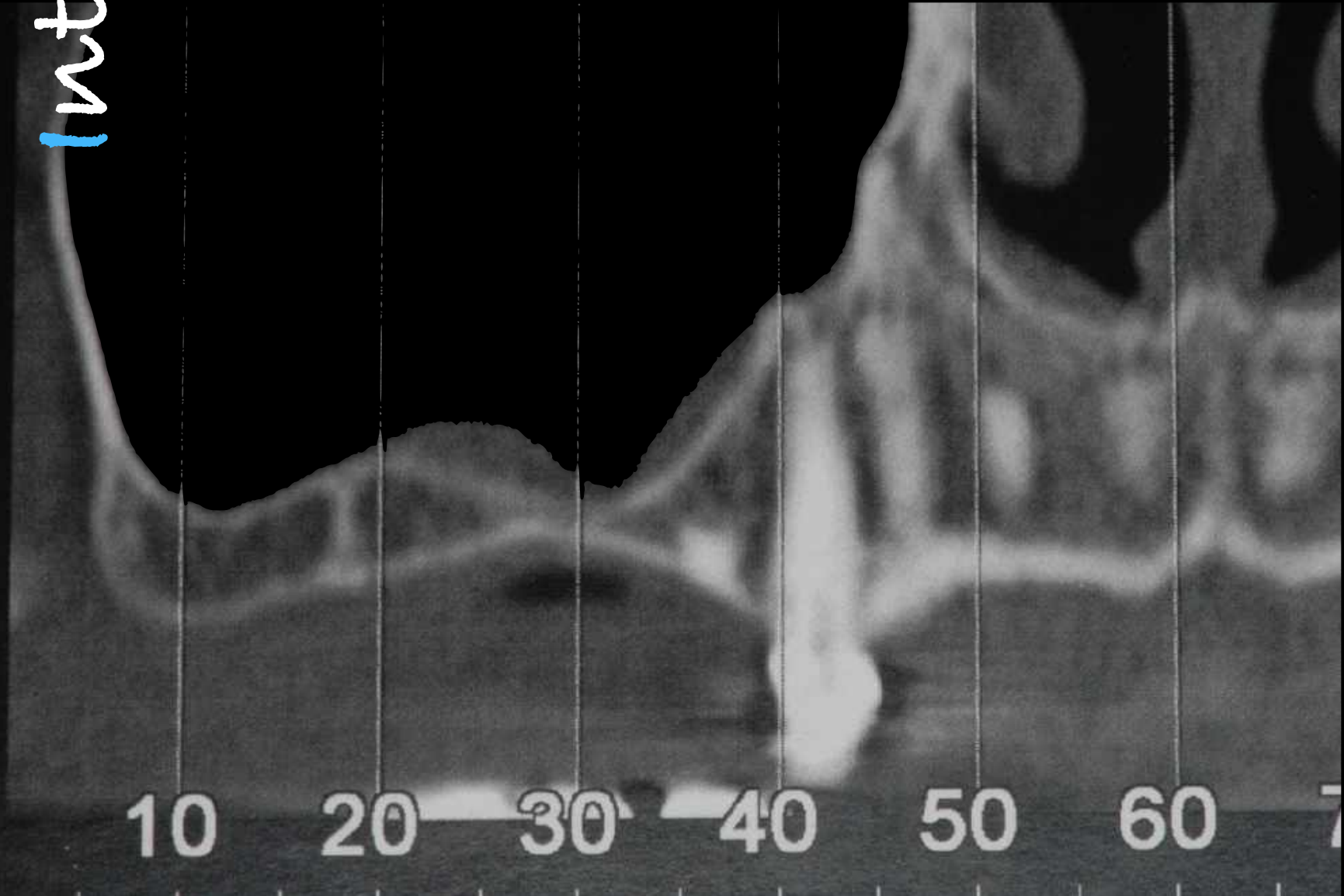


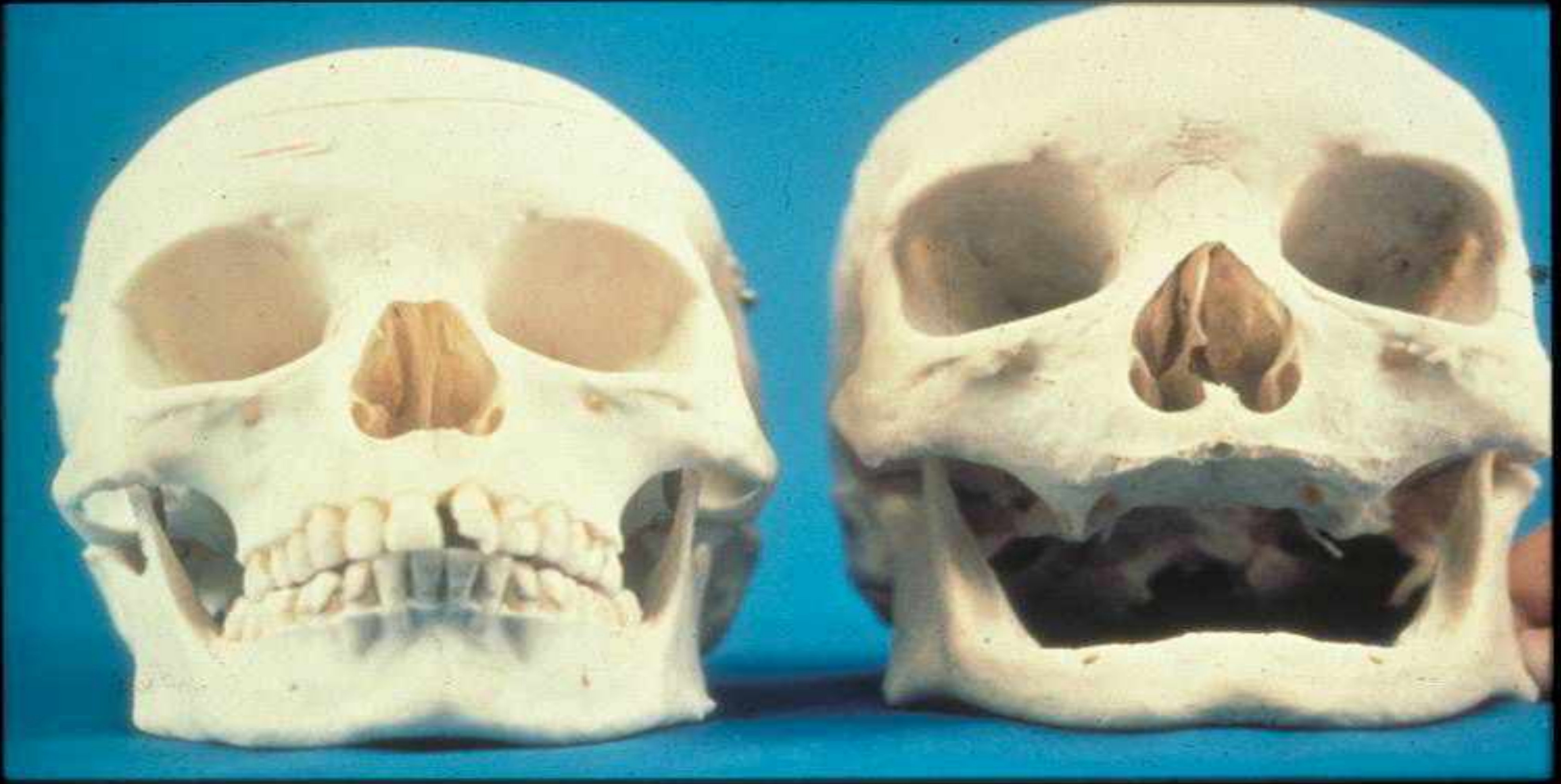Gestion des Faibles Volumes Osseux sous-Sinuséens



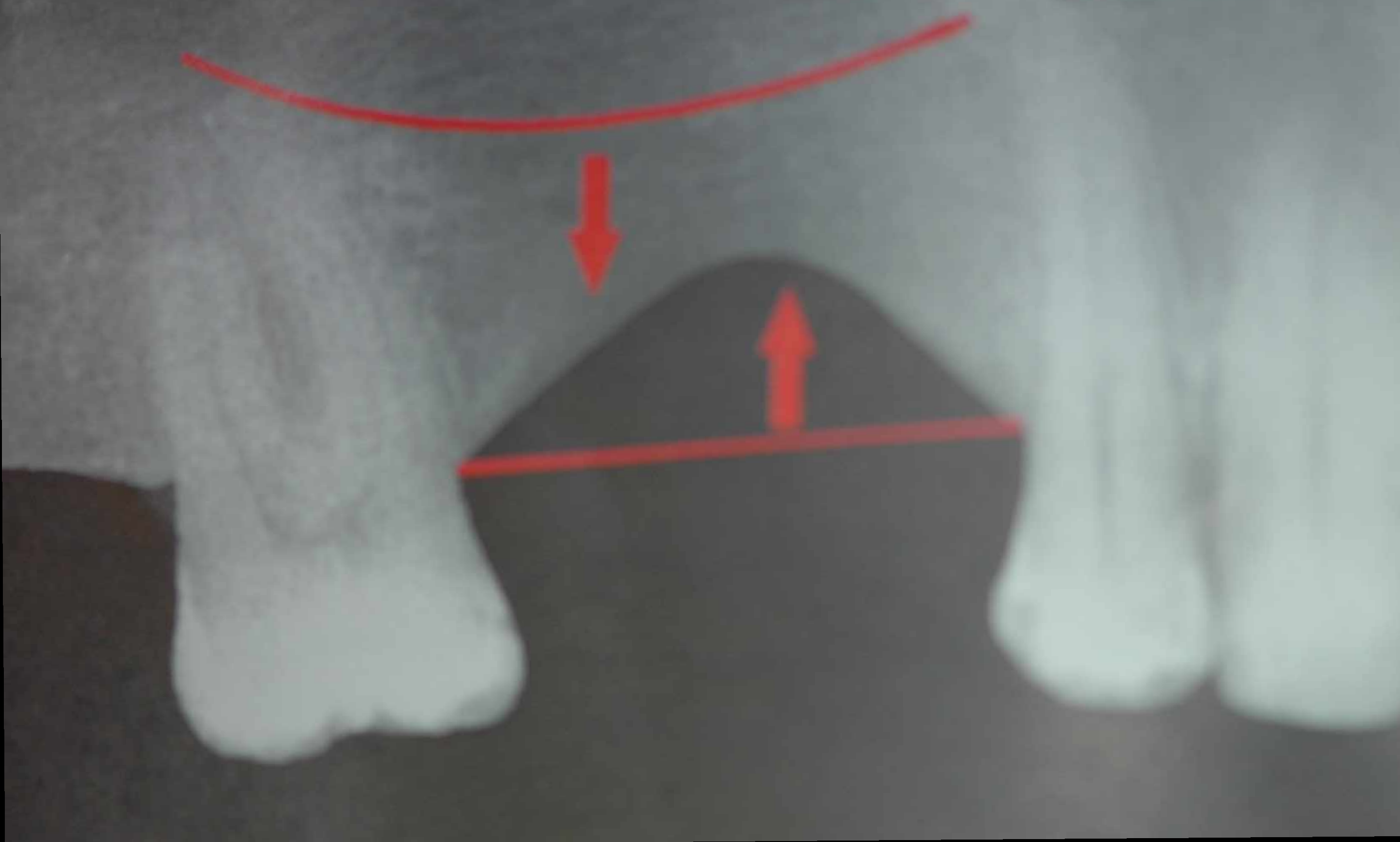
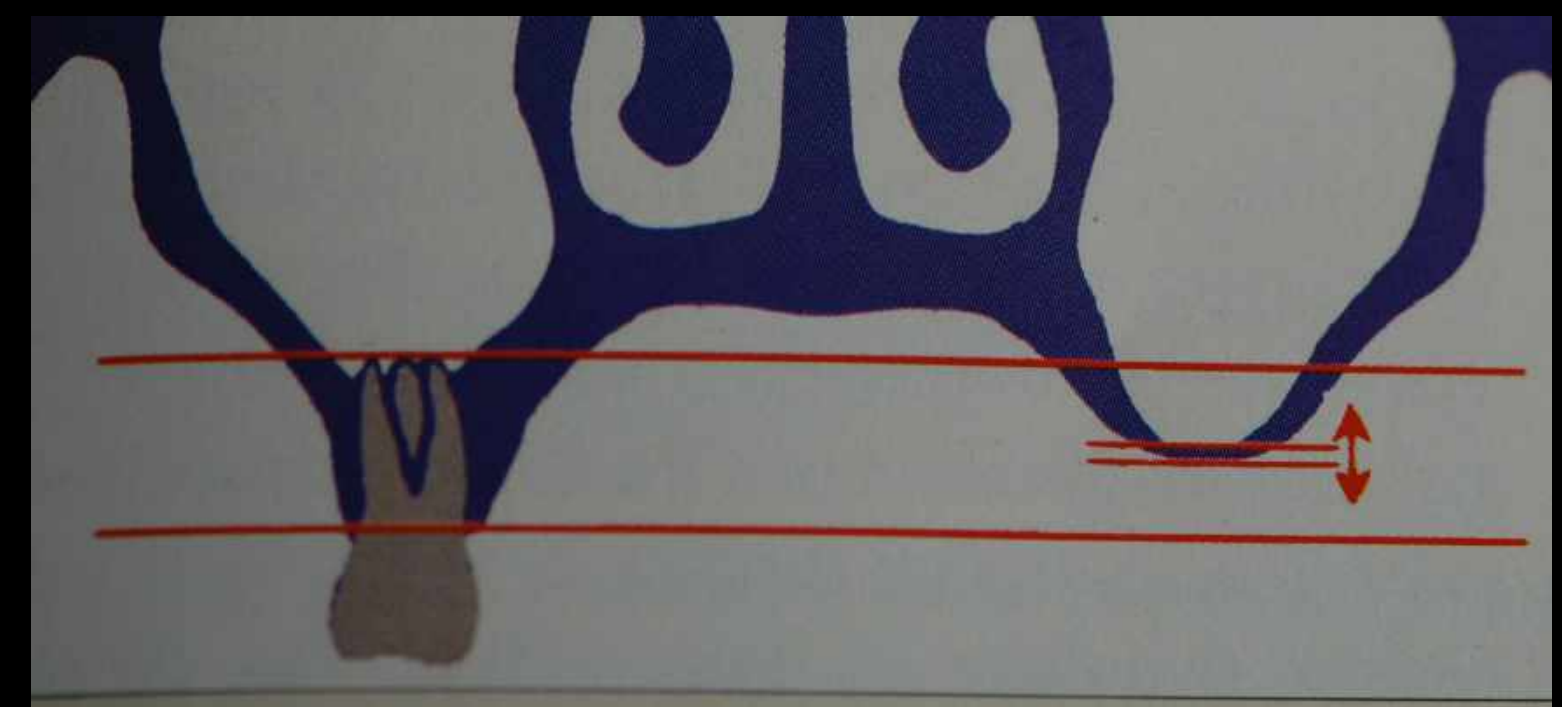


Introducción

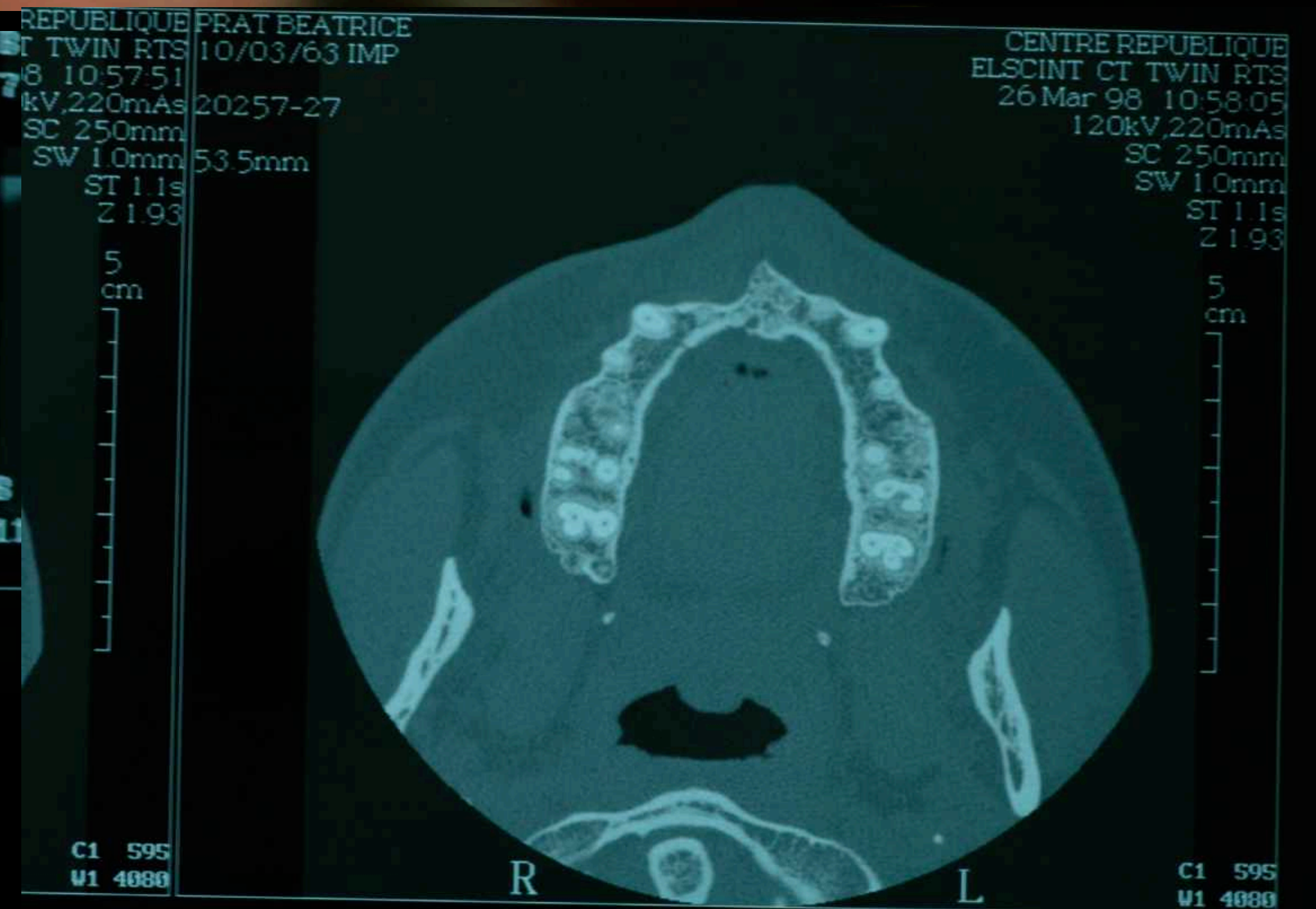
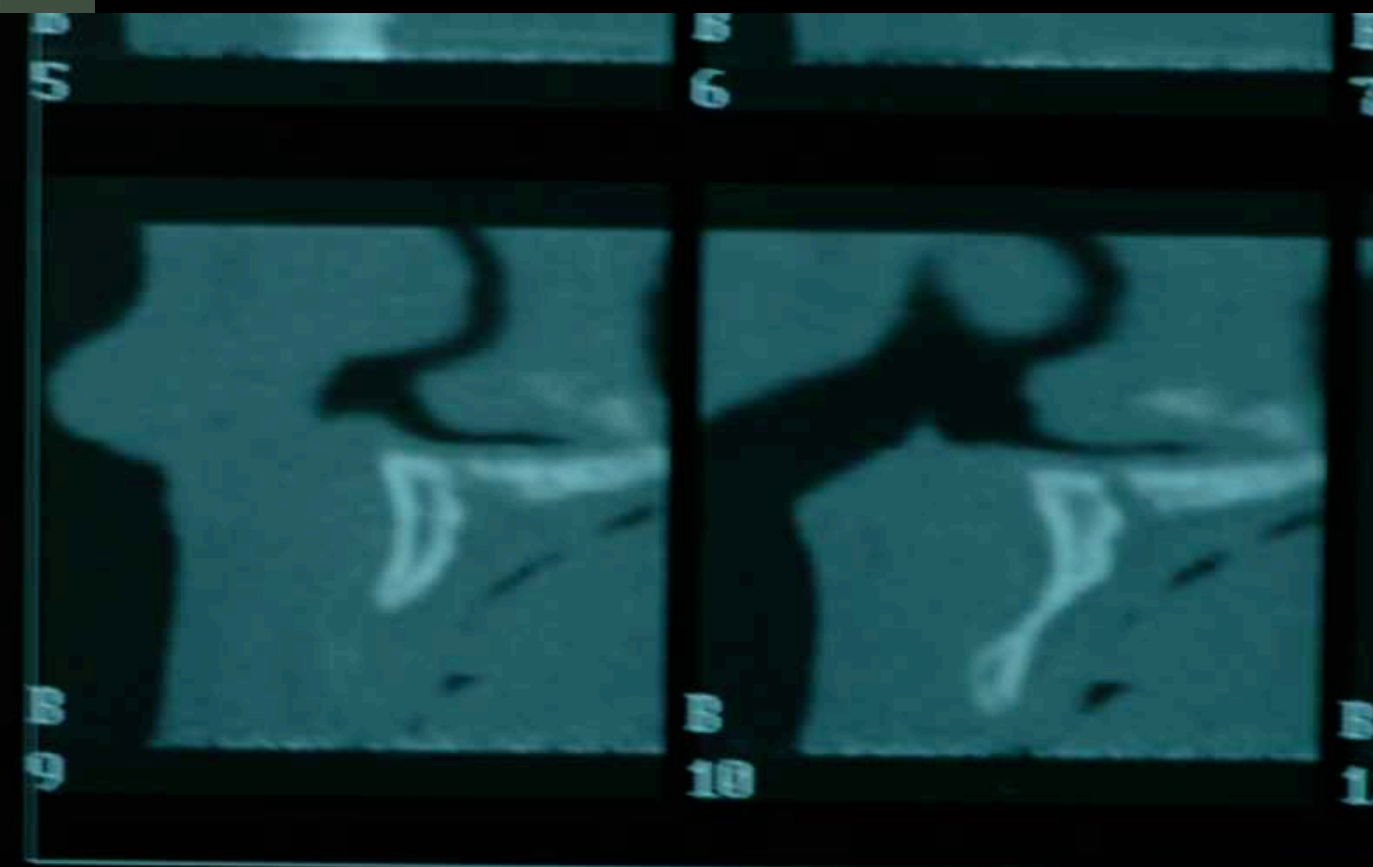
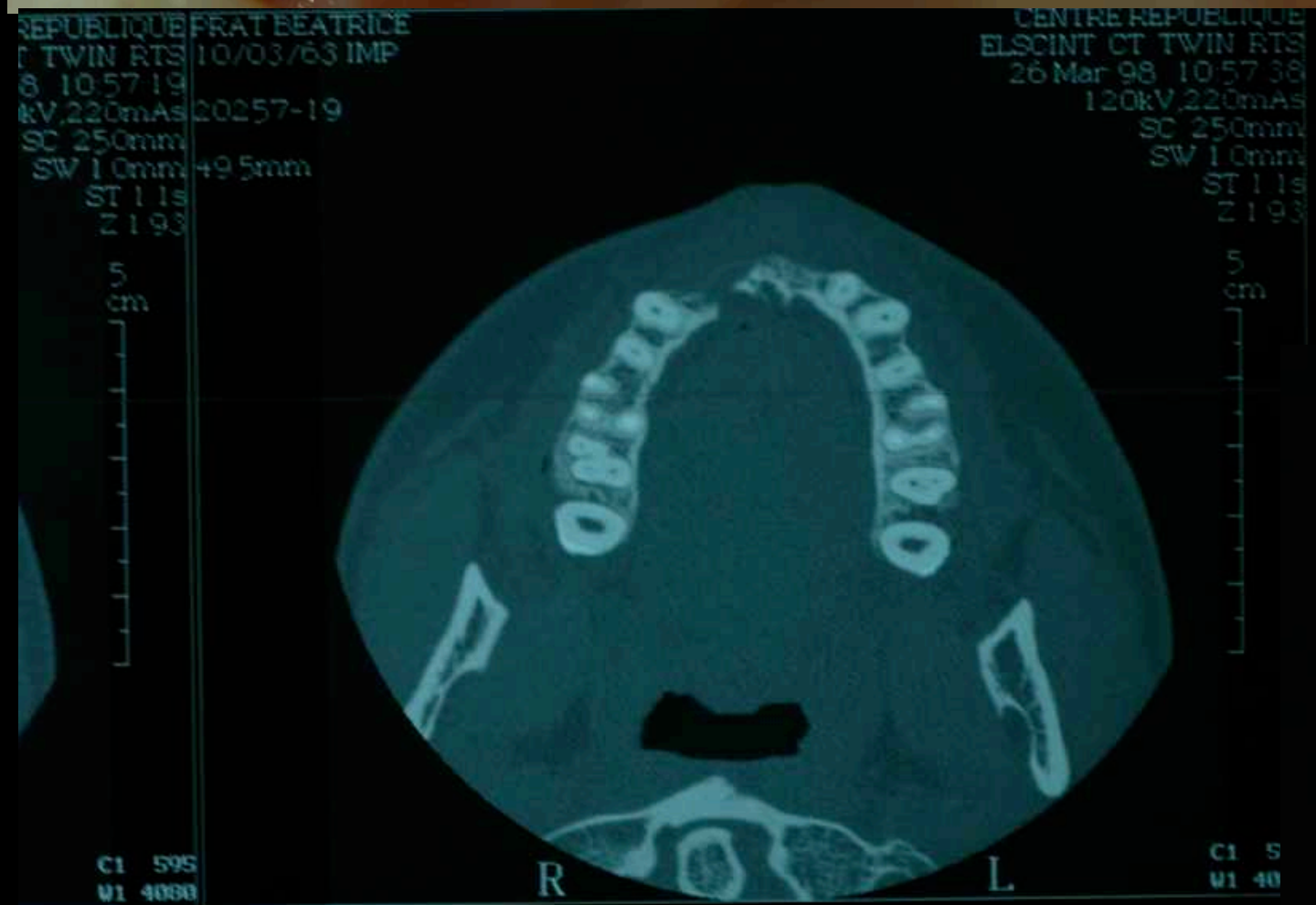
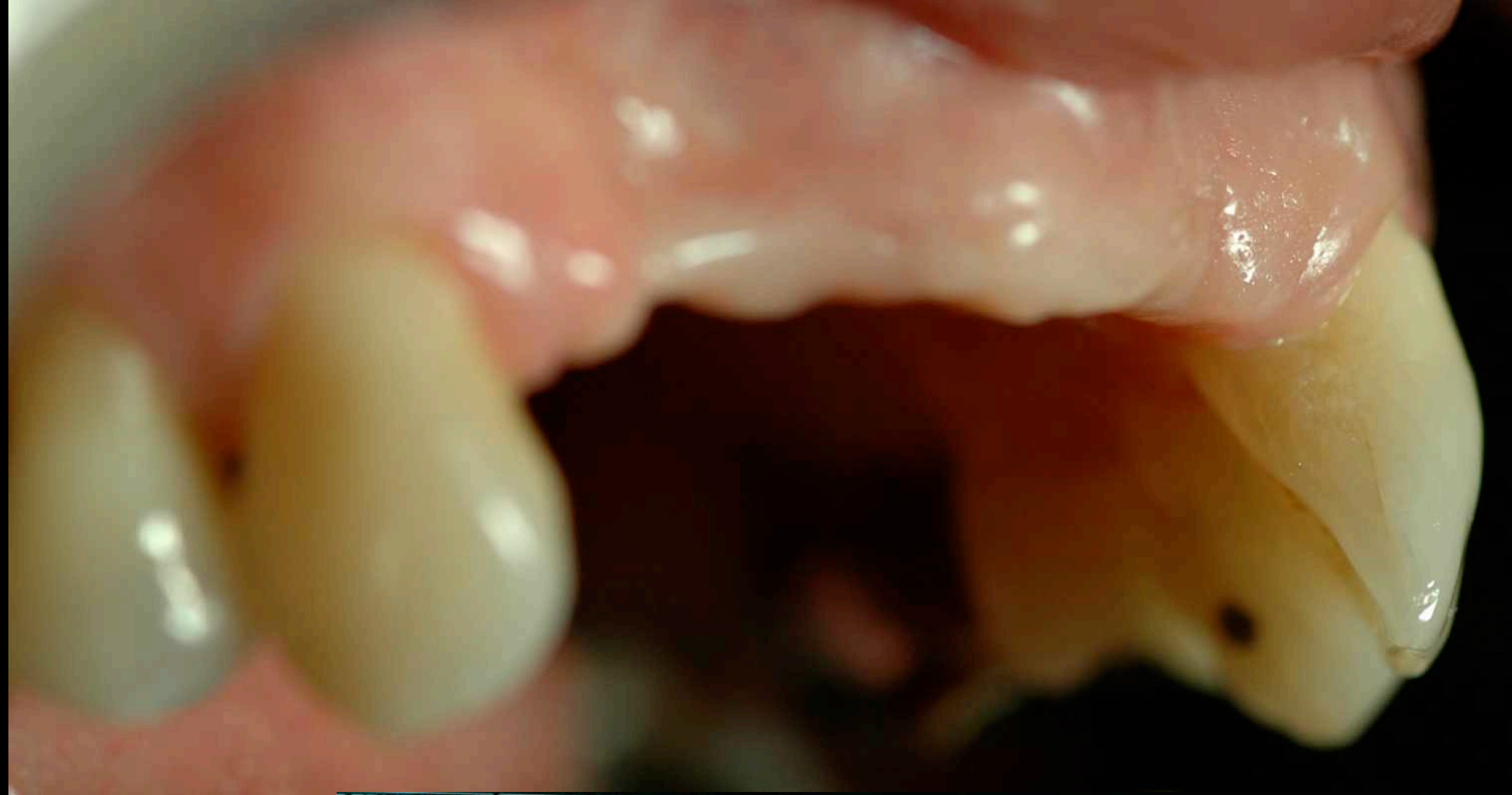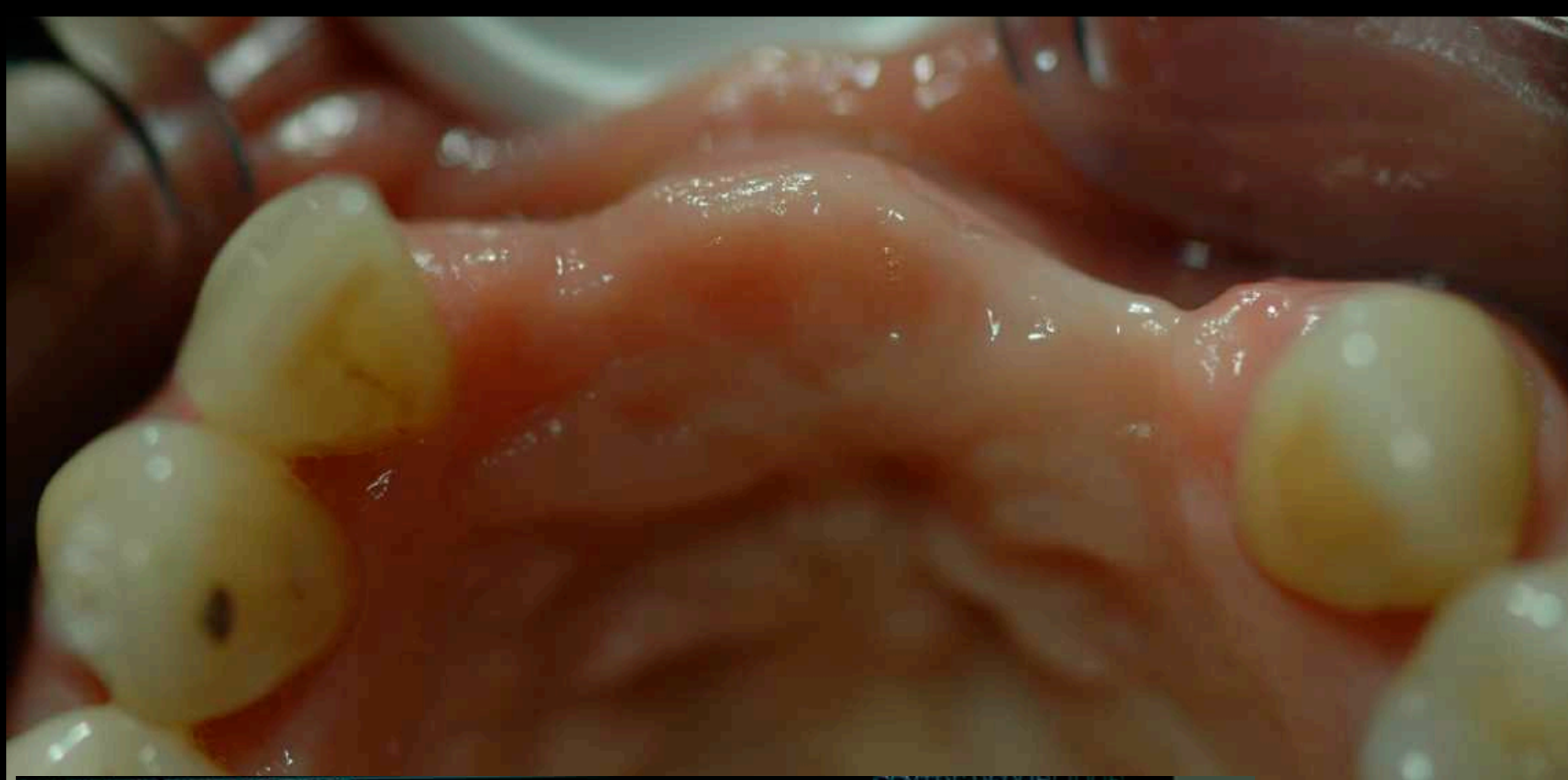


Introduction



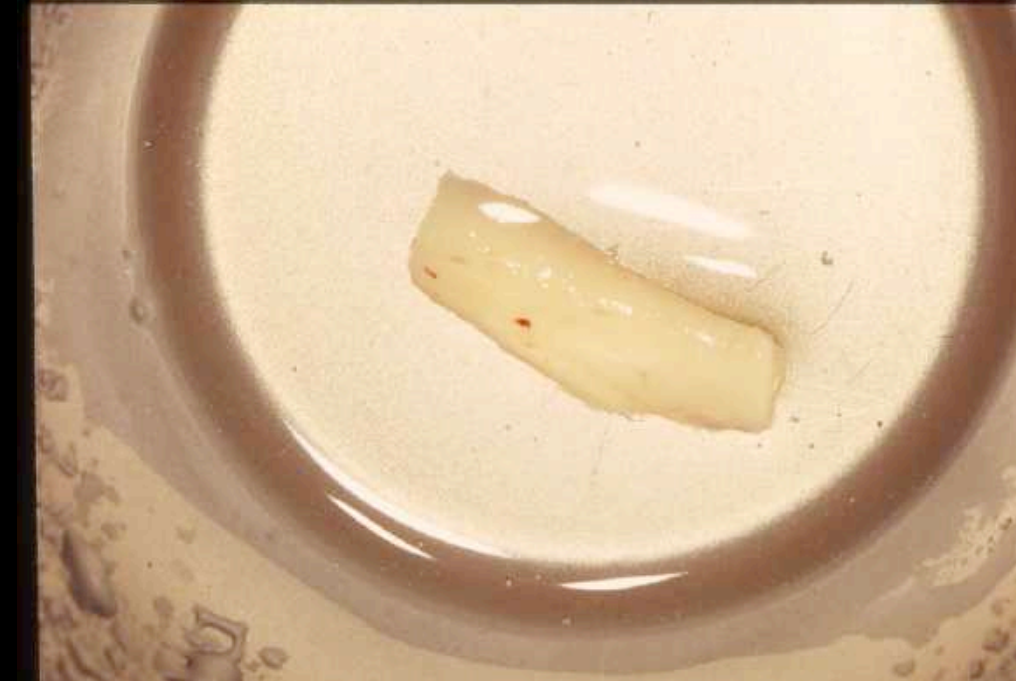
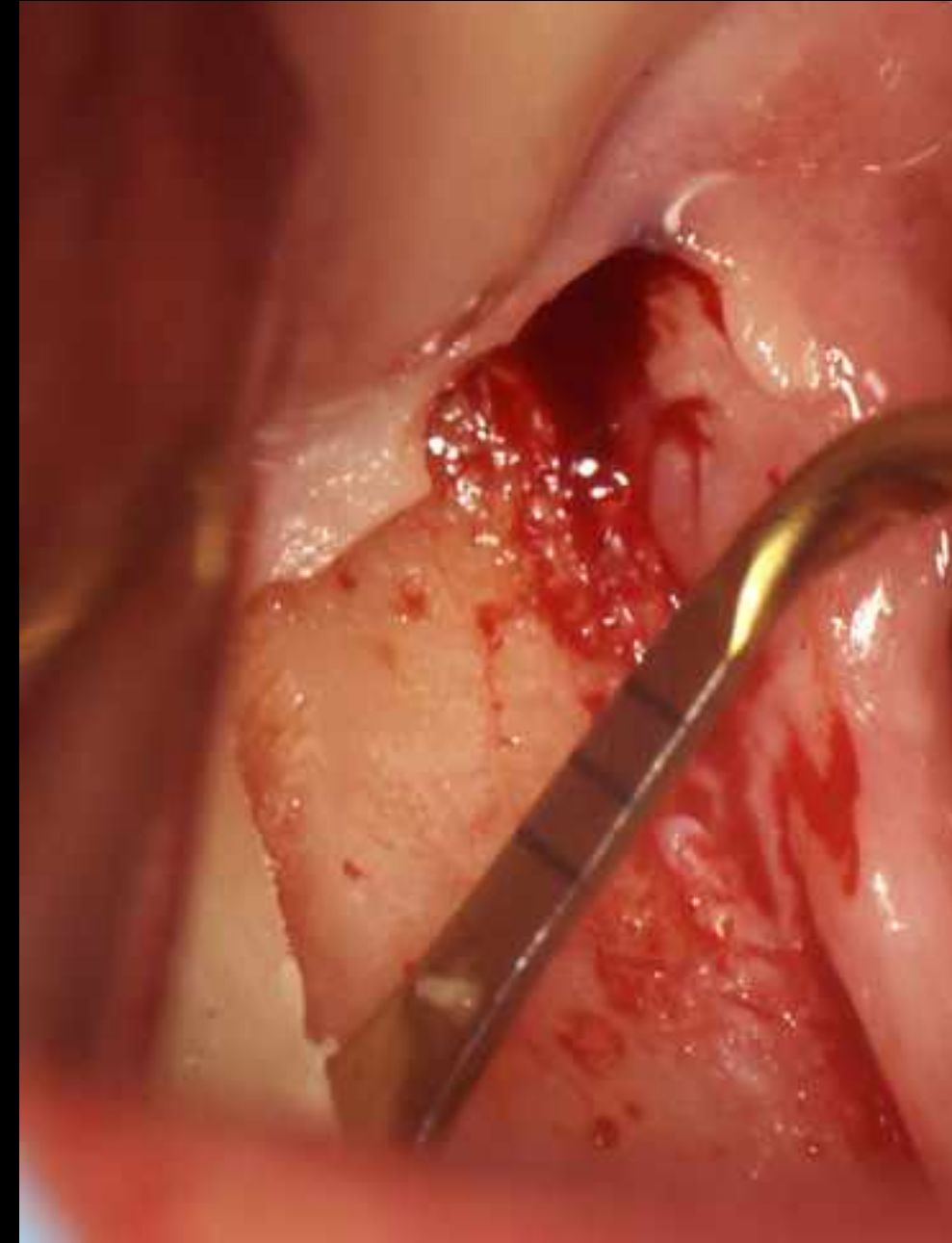Introduction





2001

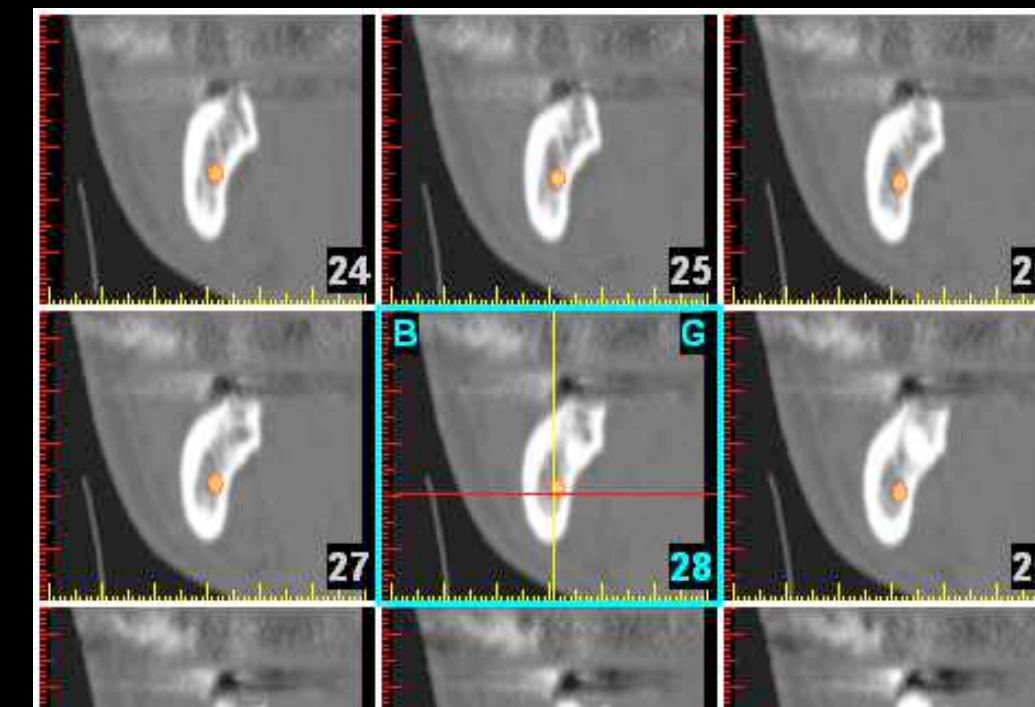
LE PRELEVEMENT RETROMOLAIRE

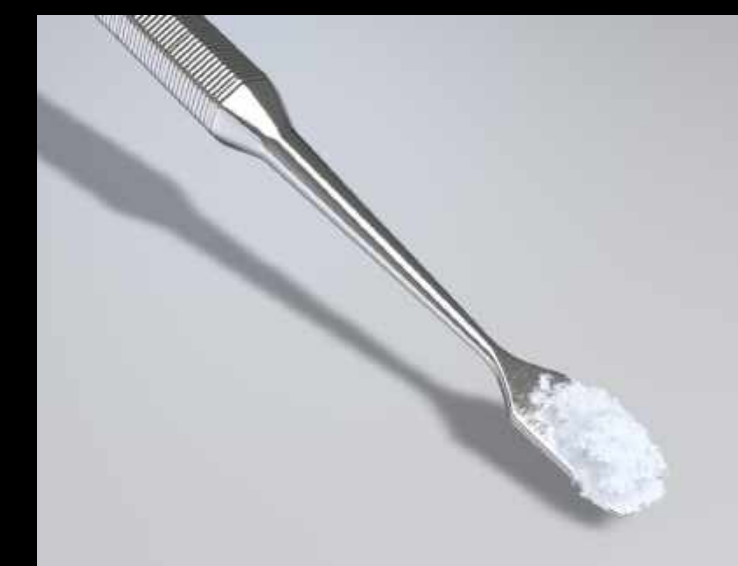
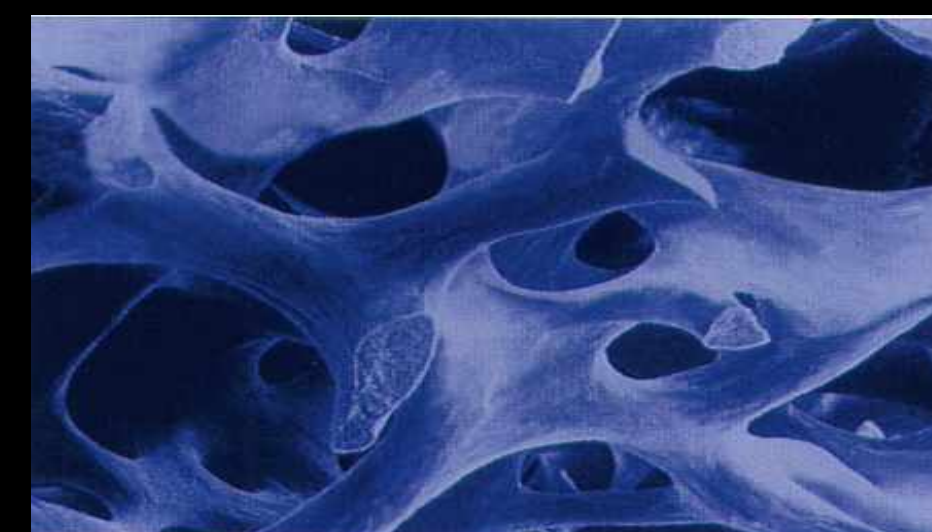
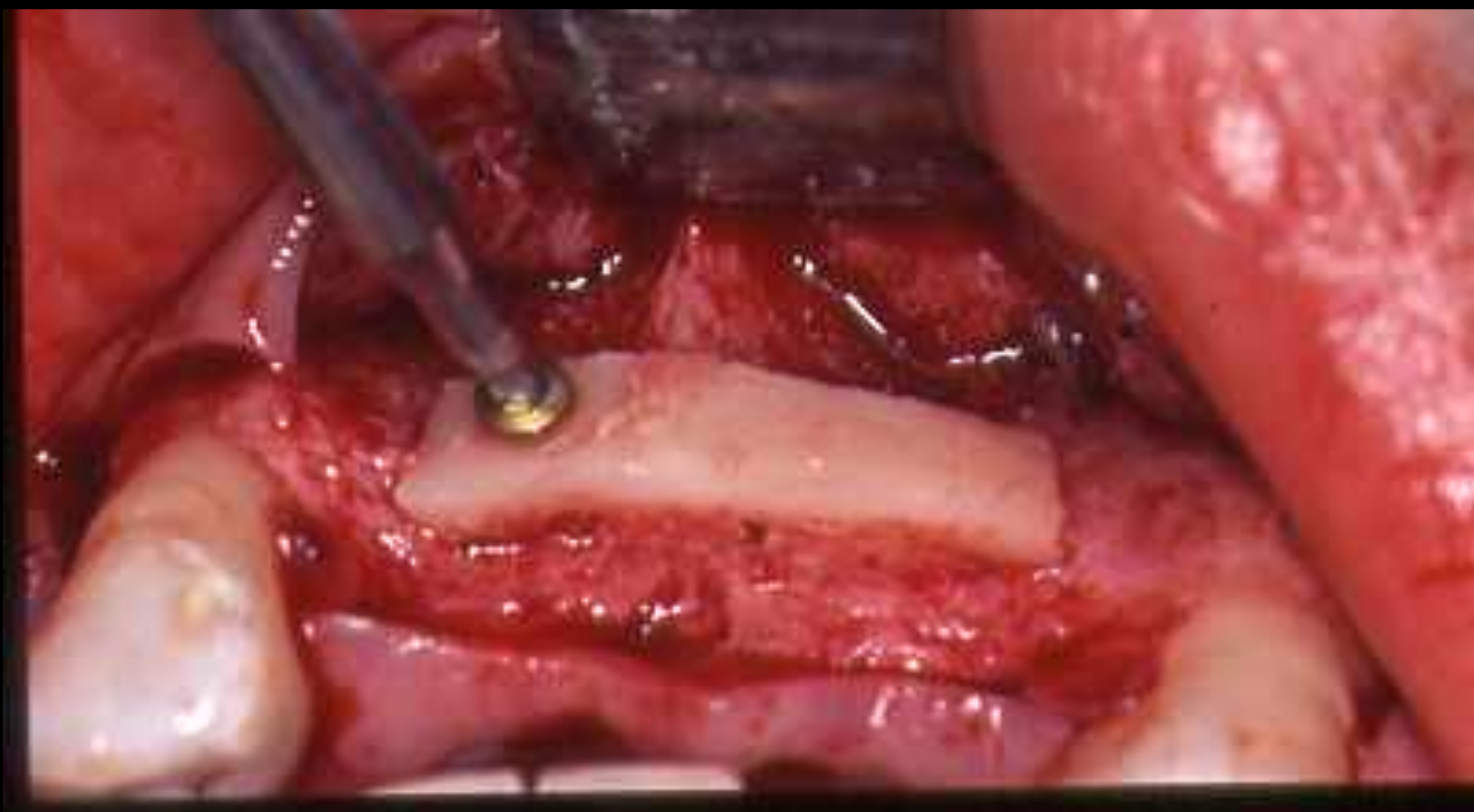

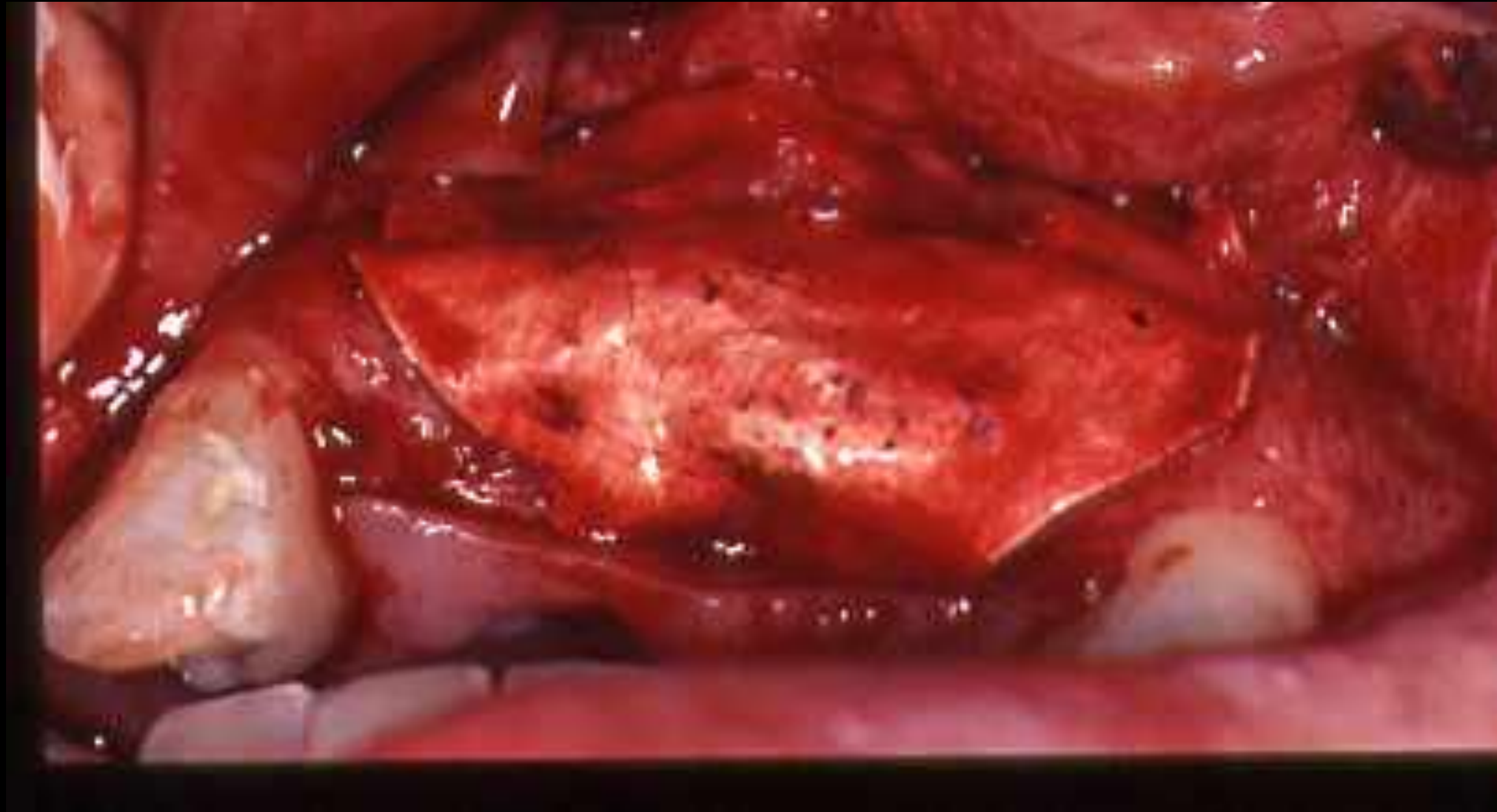
Moins de suites et de complications
bilatéral possible

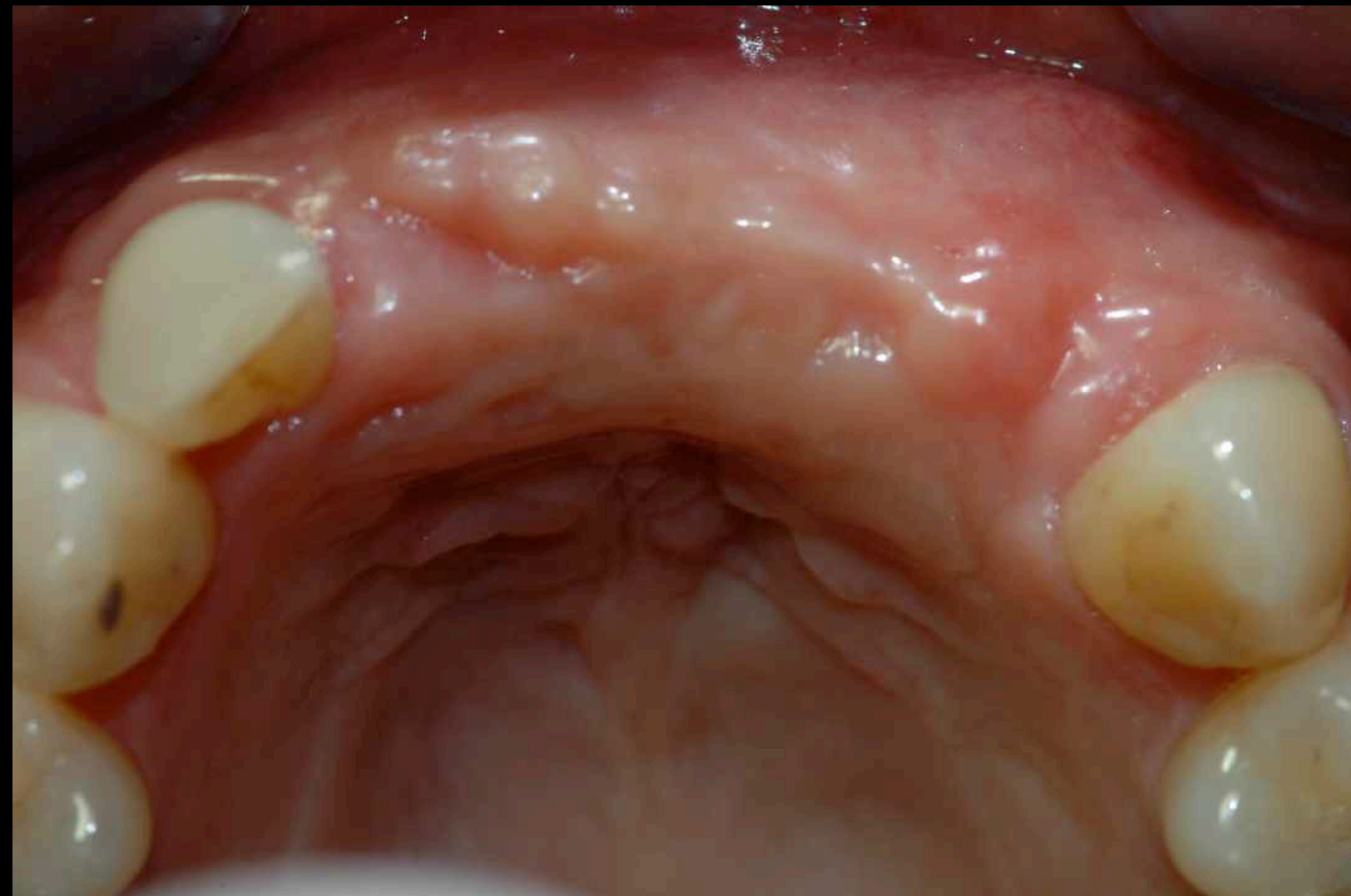
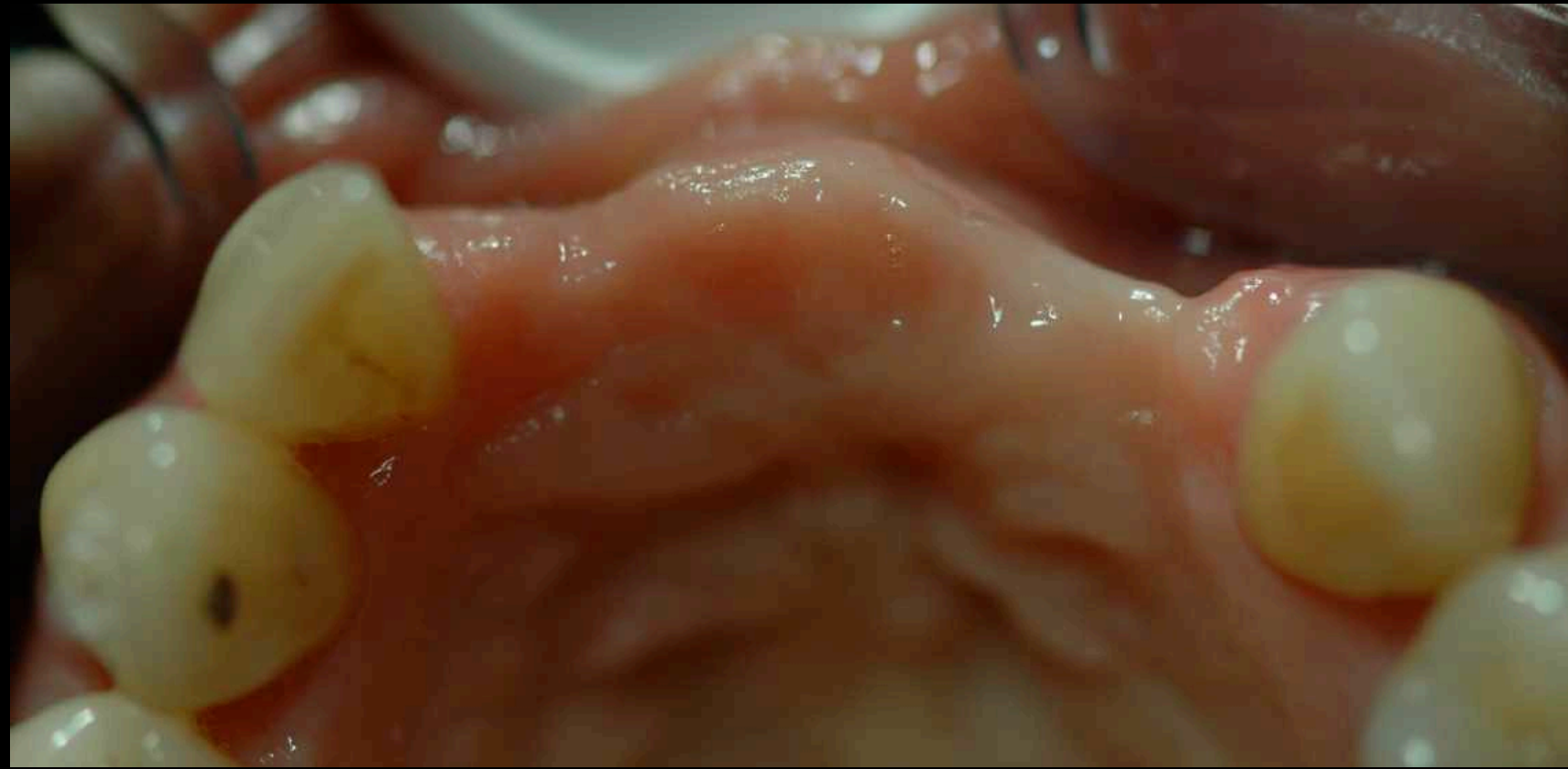
Misch CM

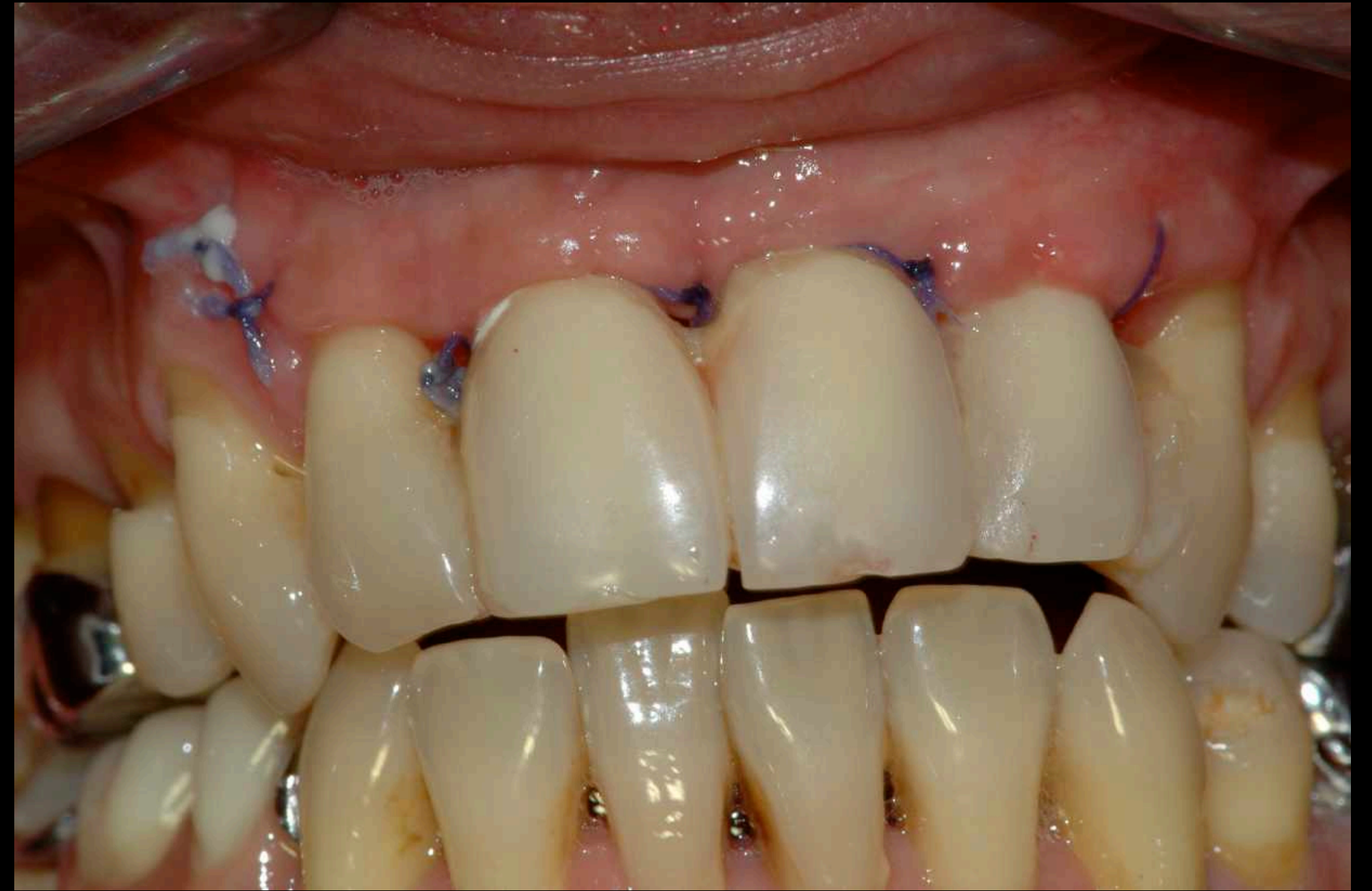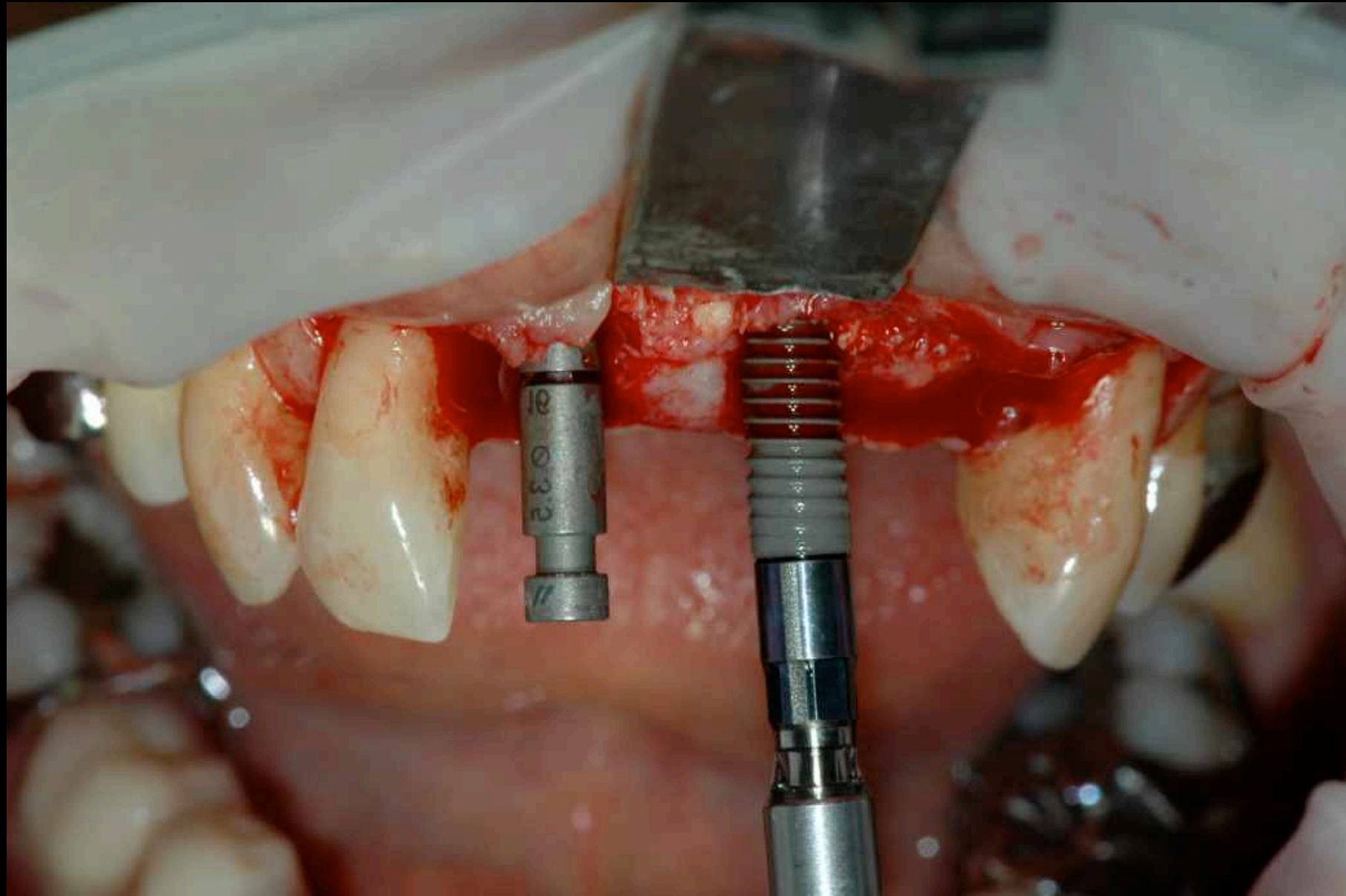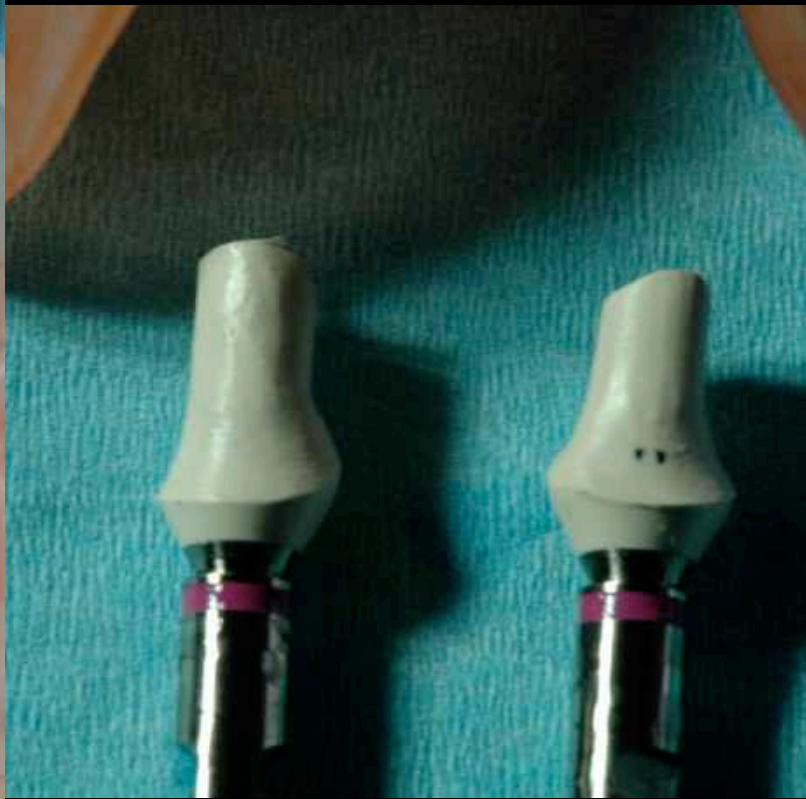
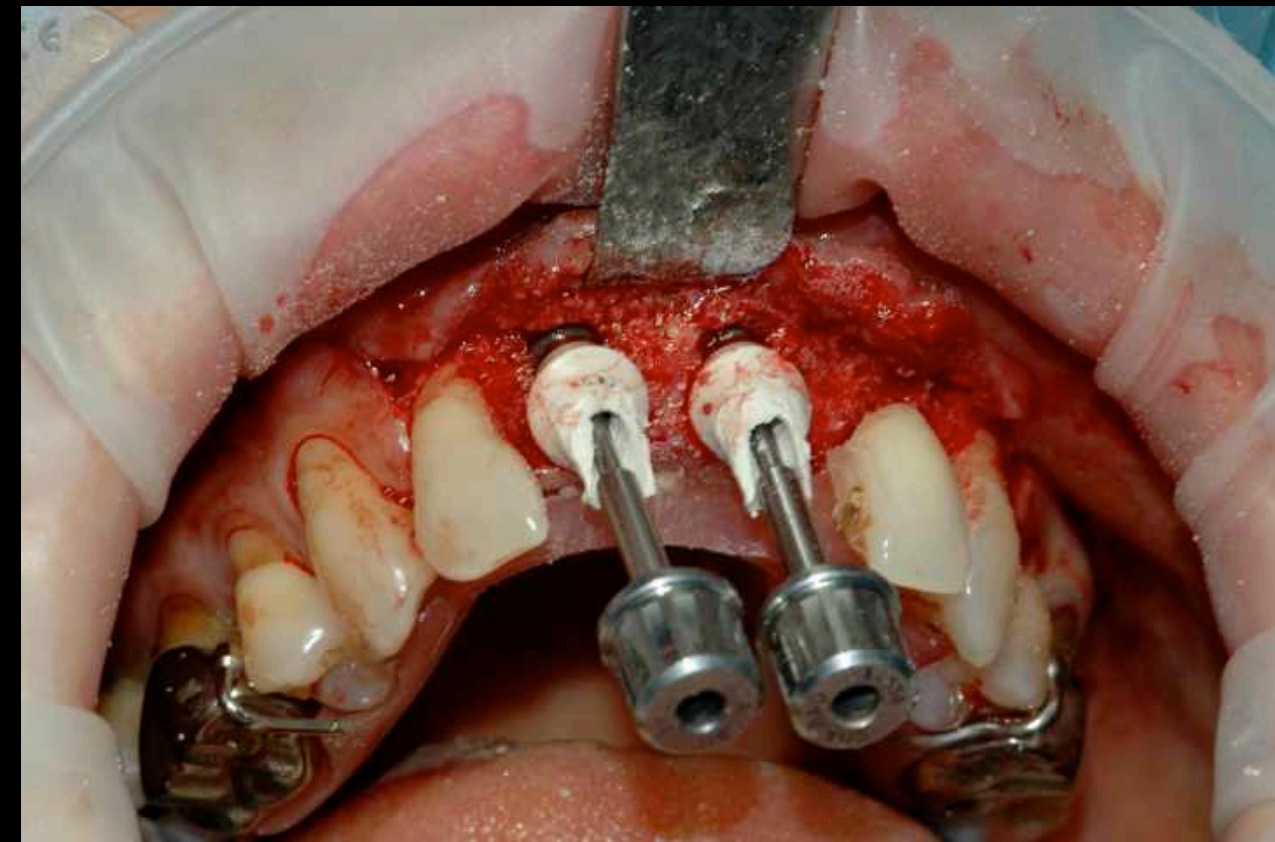
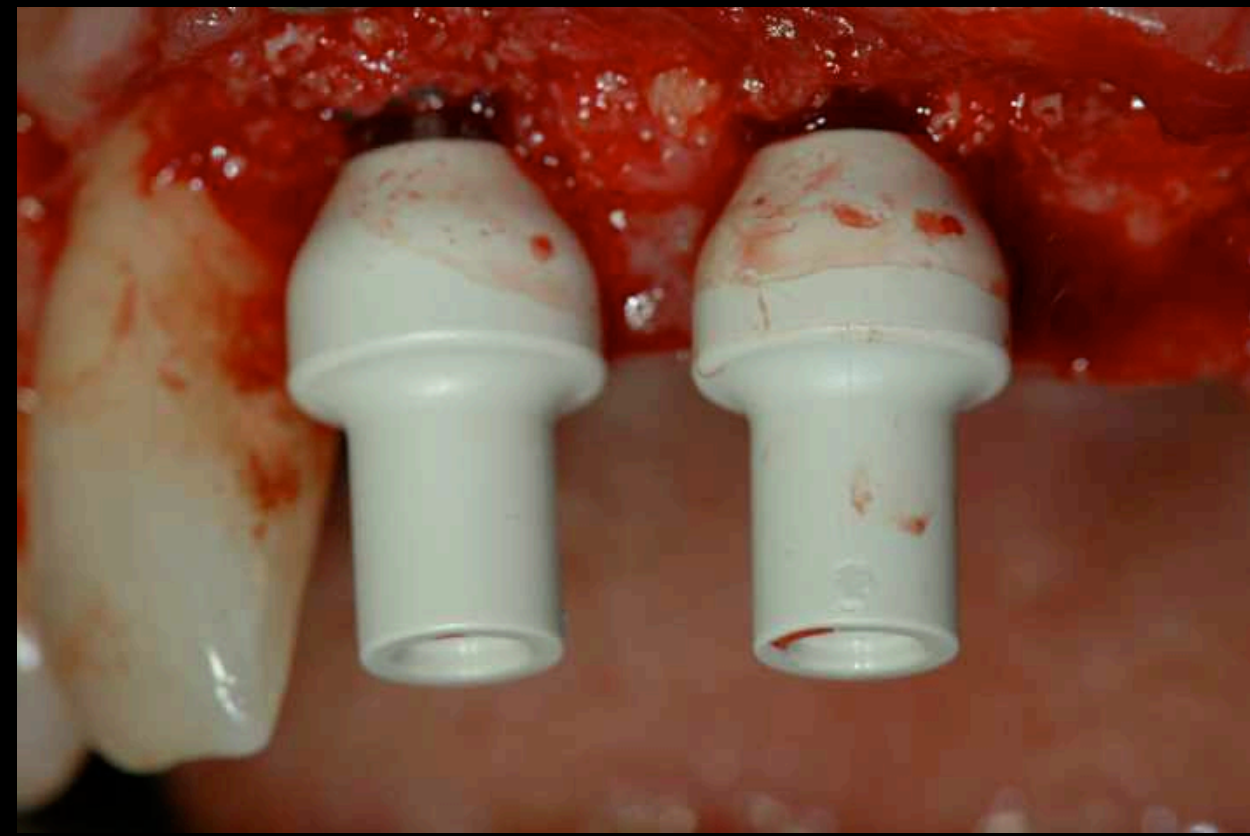
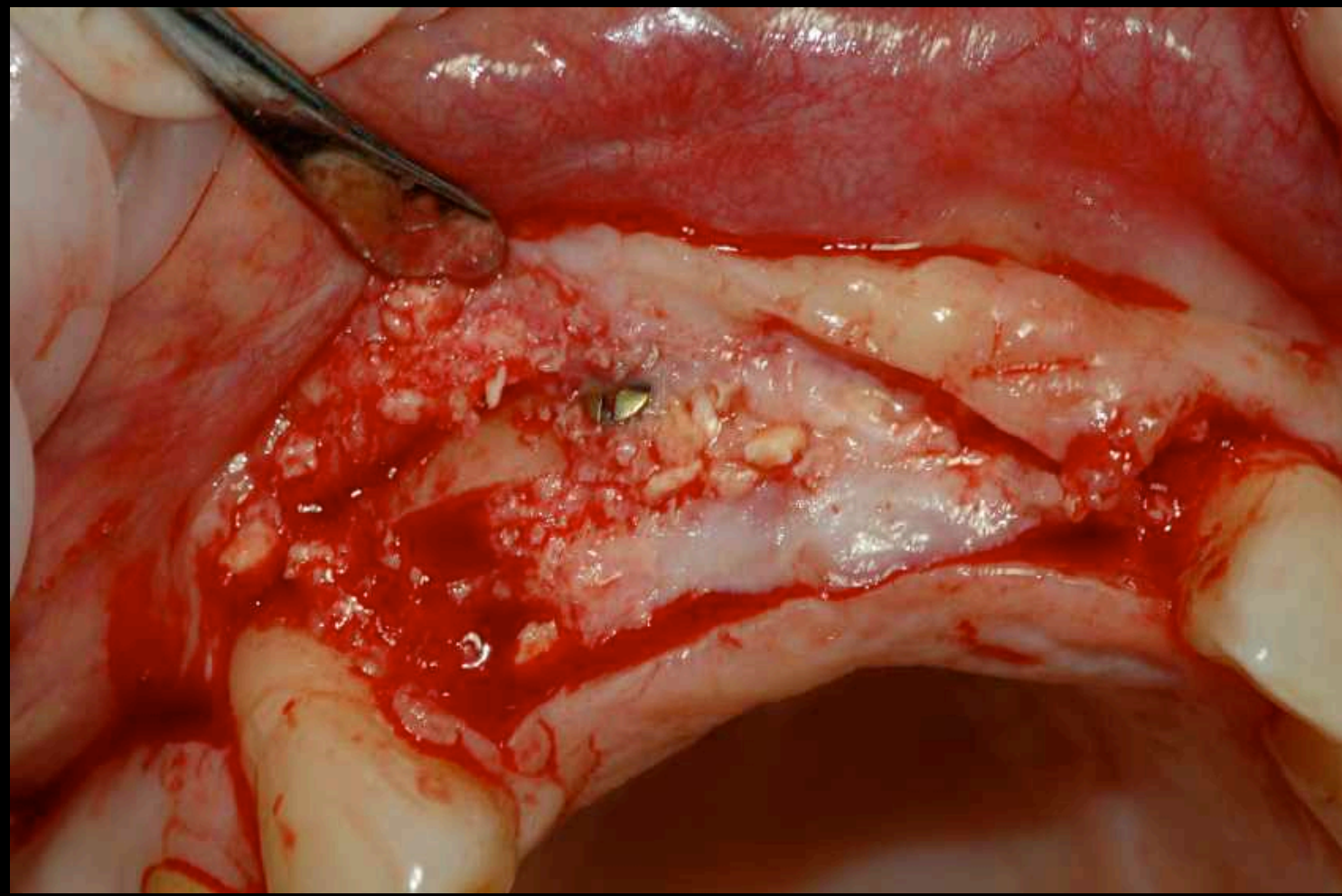
Comparison of intraoral donor sites for onlay grafting
prior to implant placement
Int J Oral Maxillofac Implants 1997;767-776

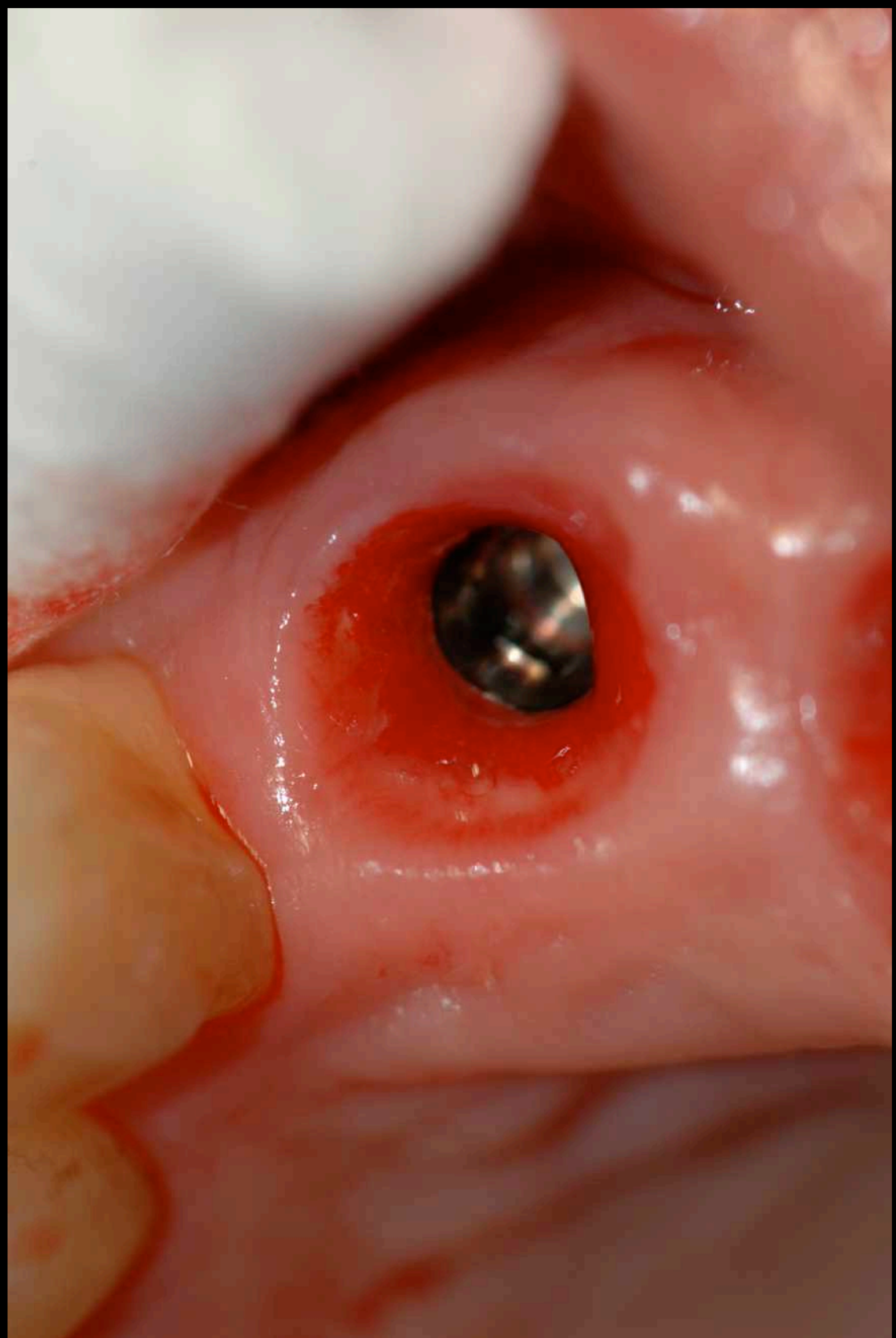
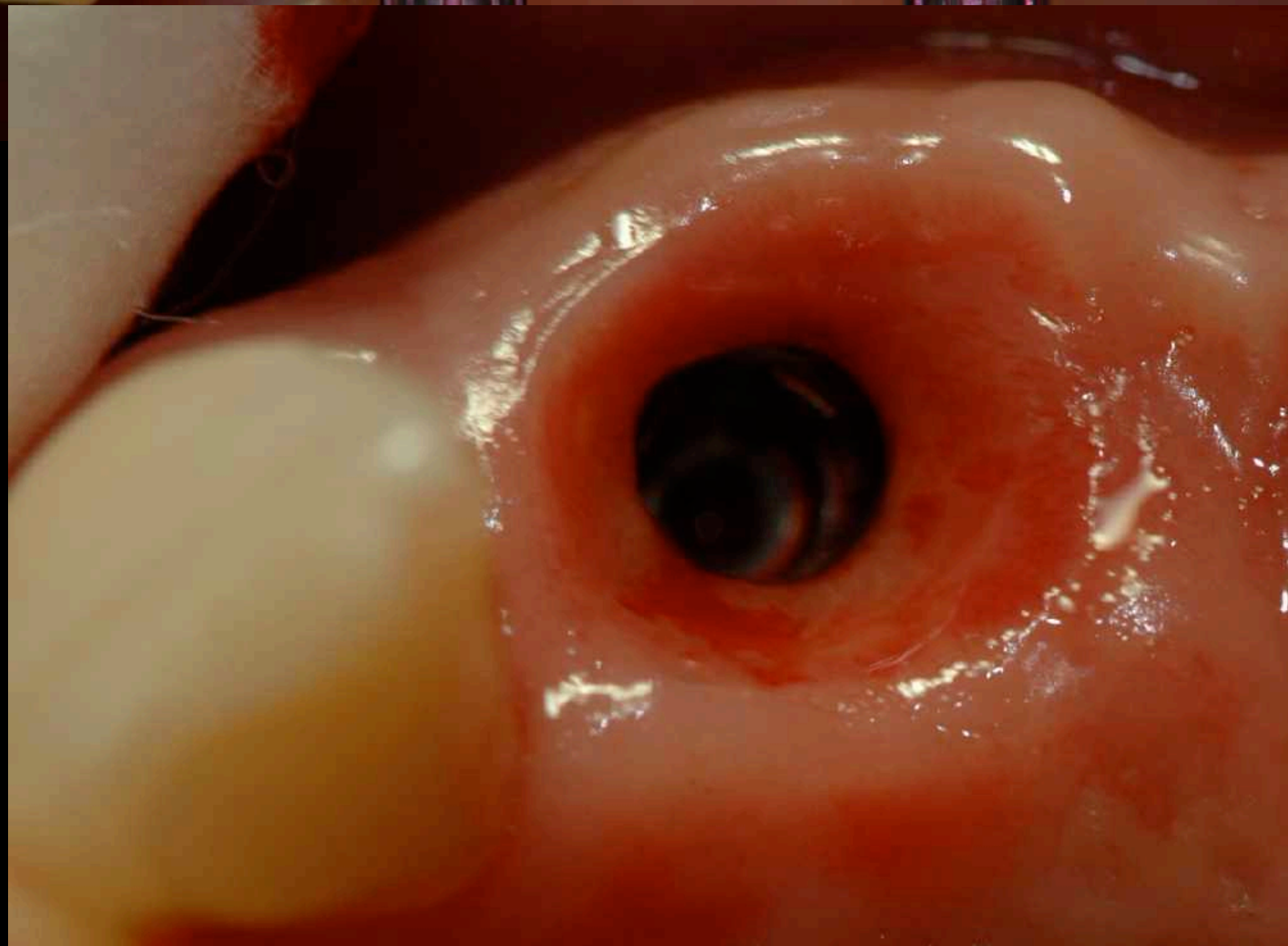
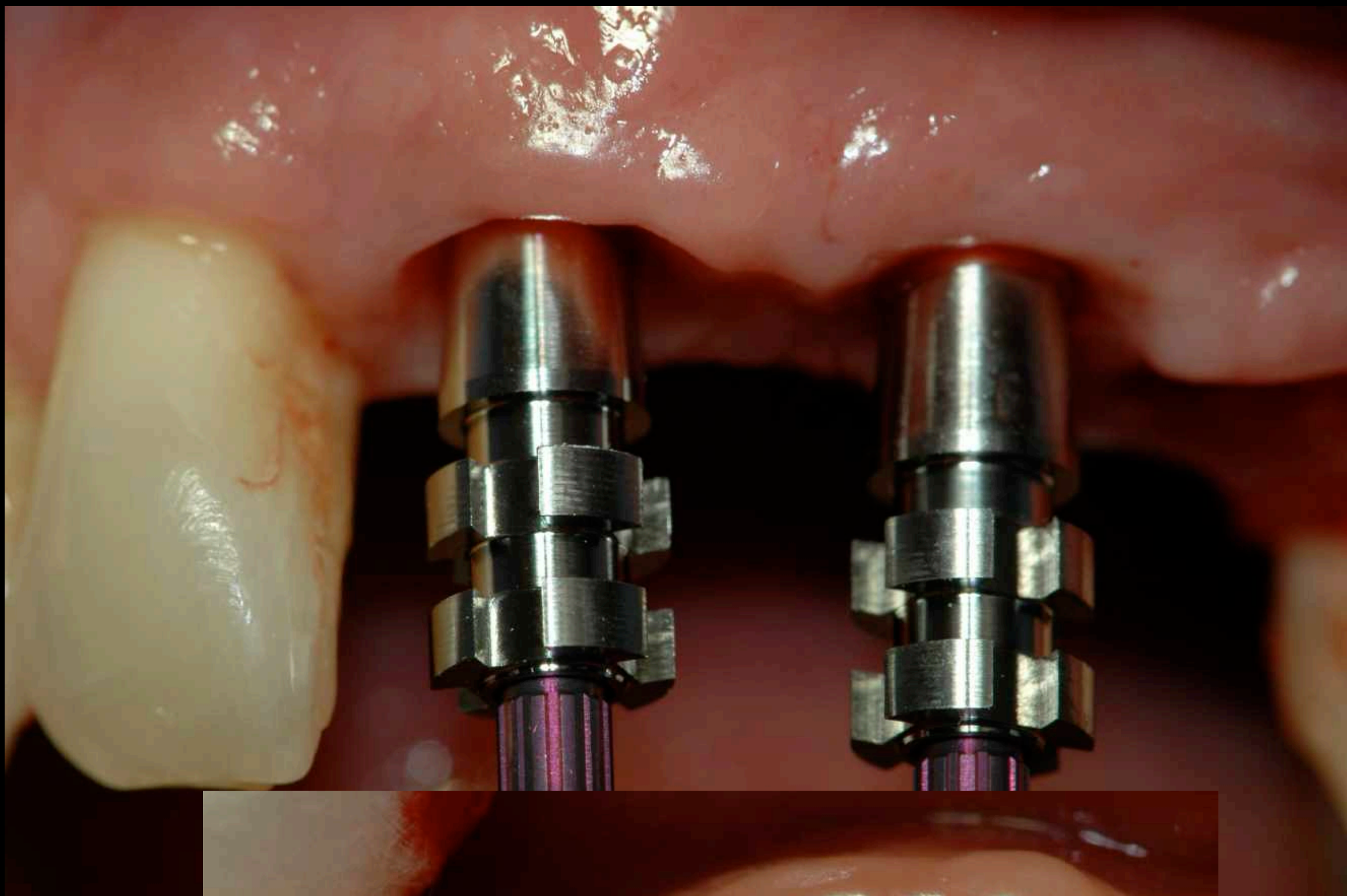


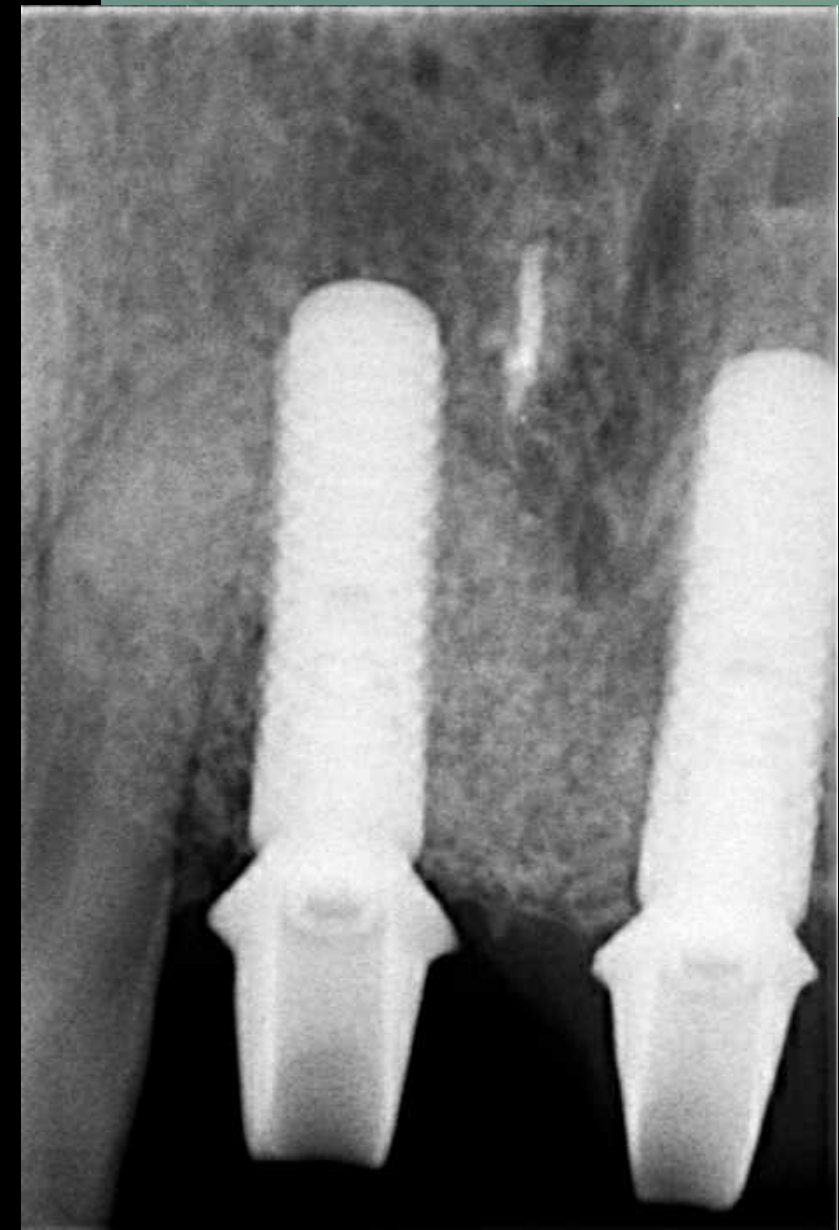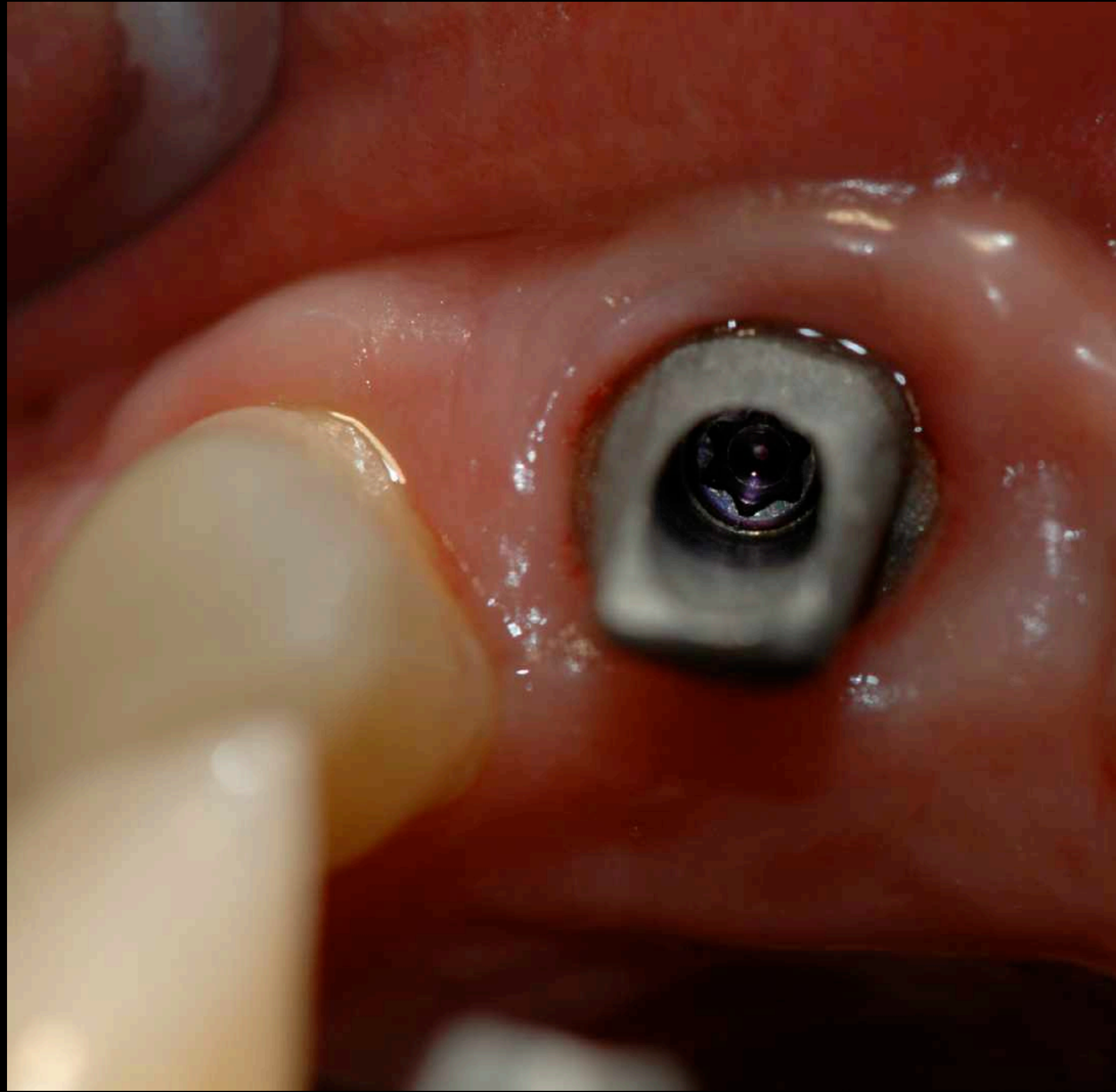

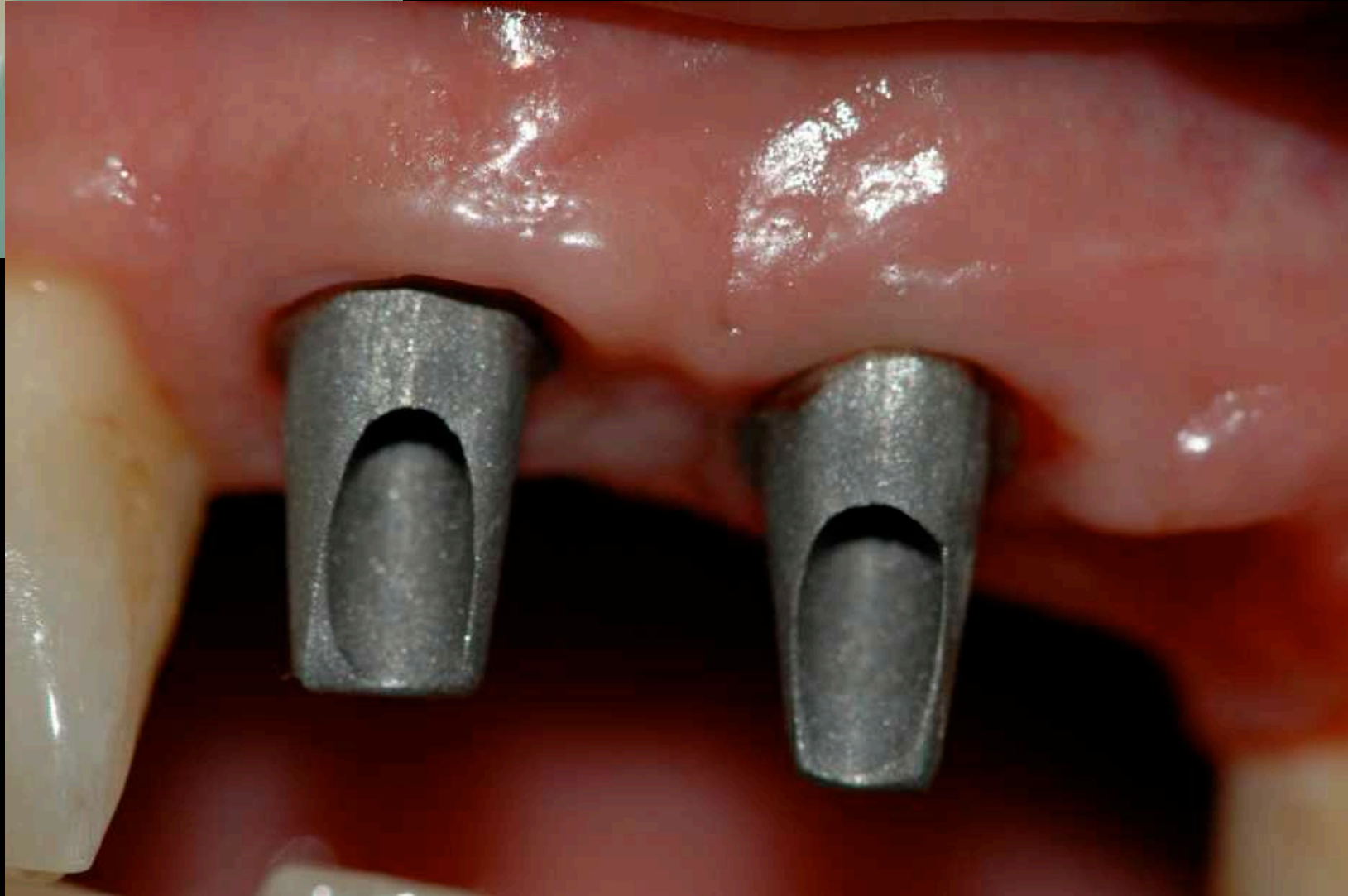
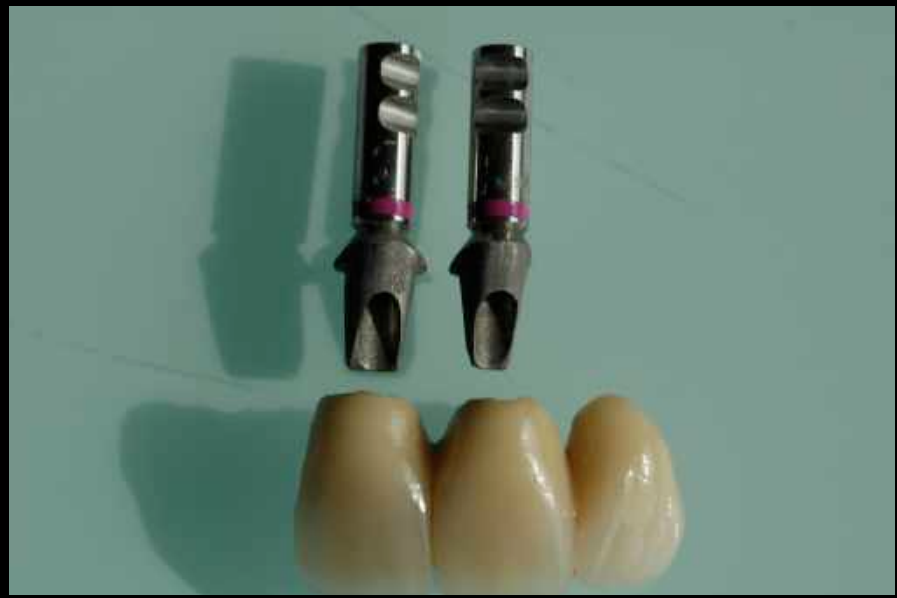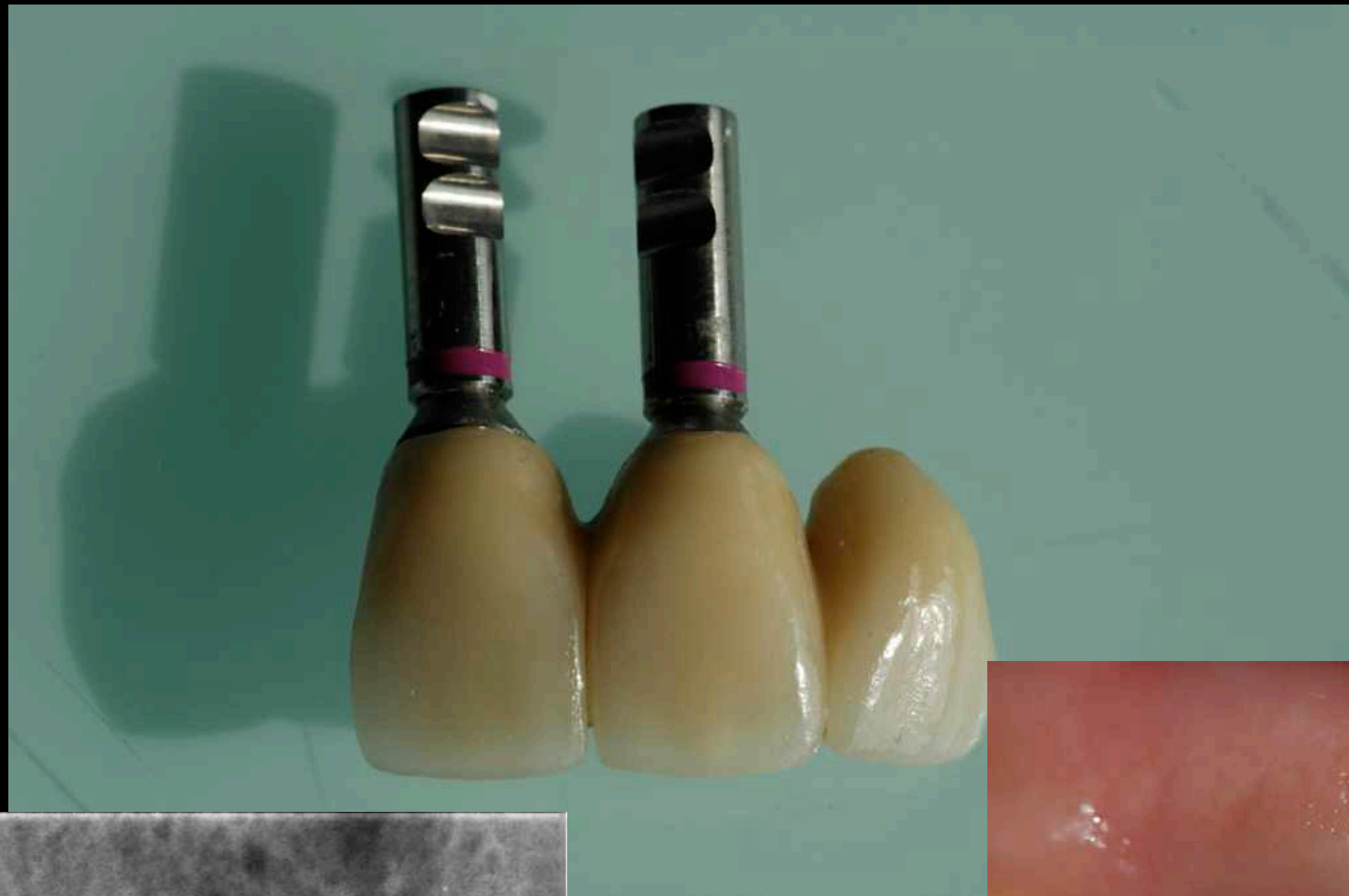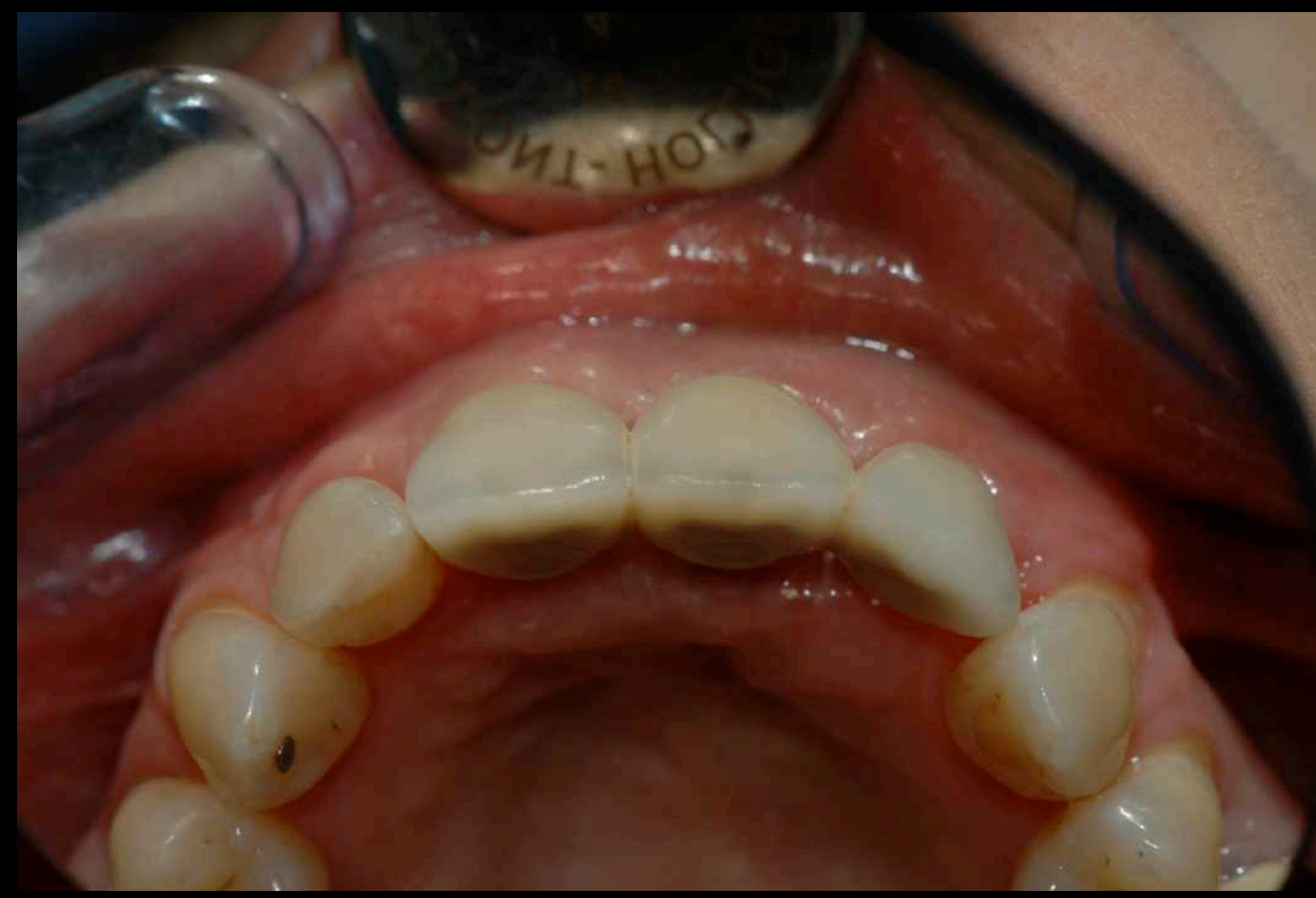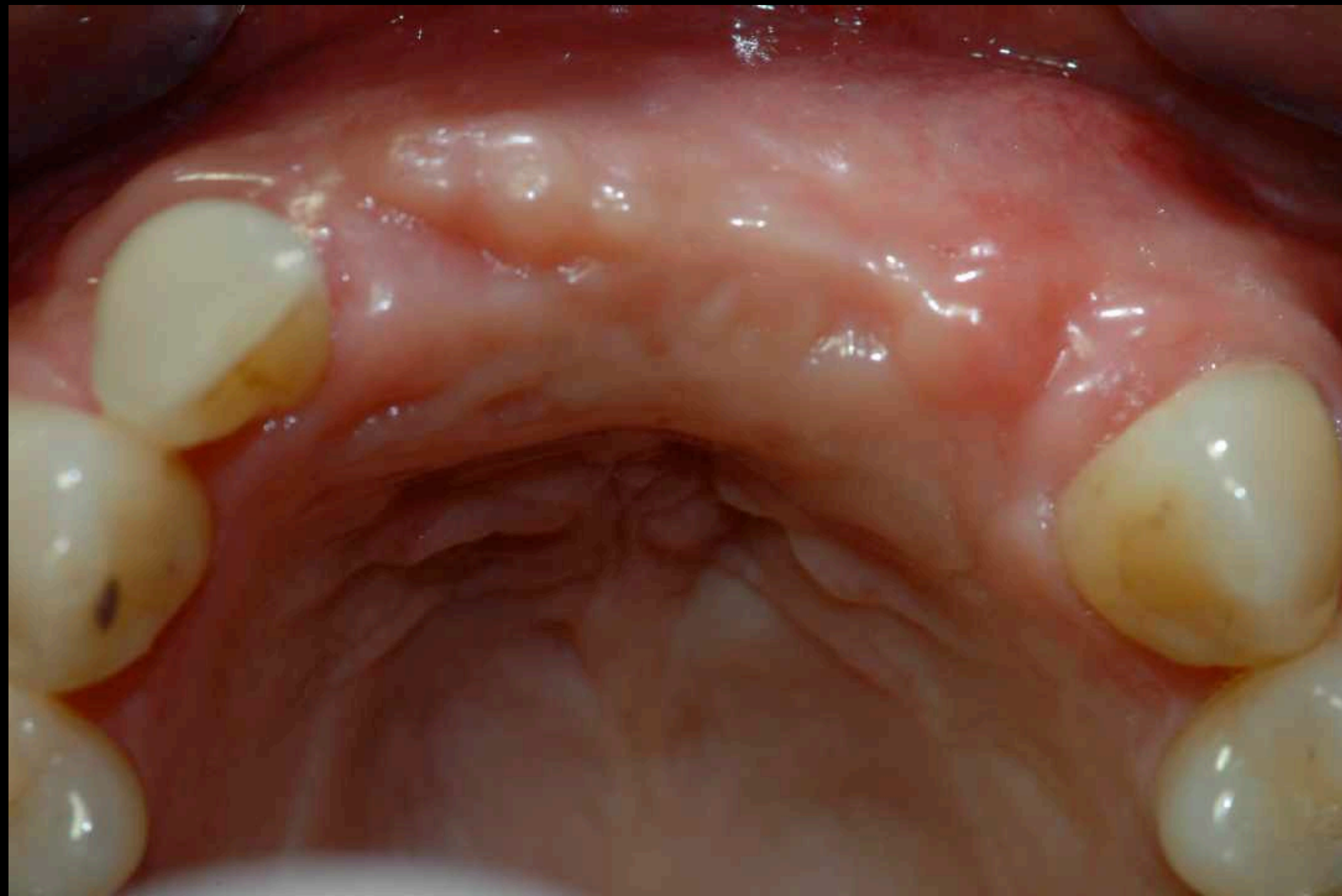
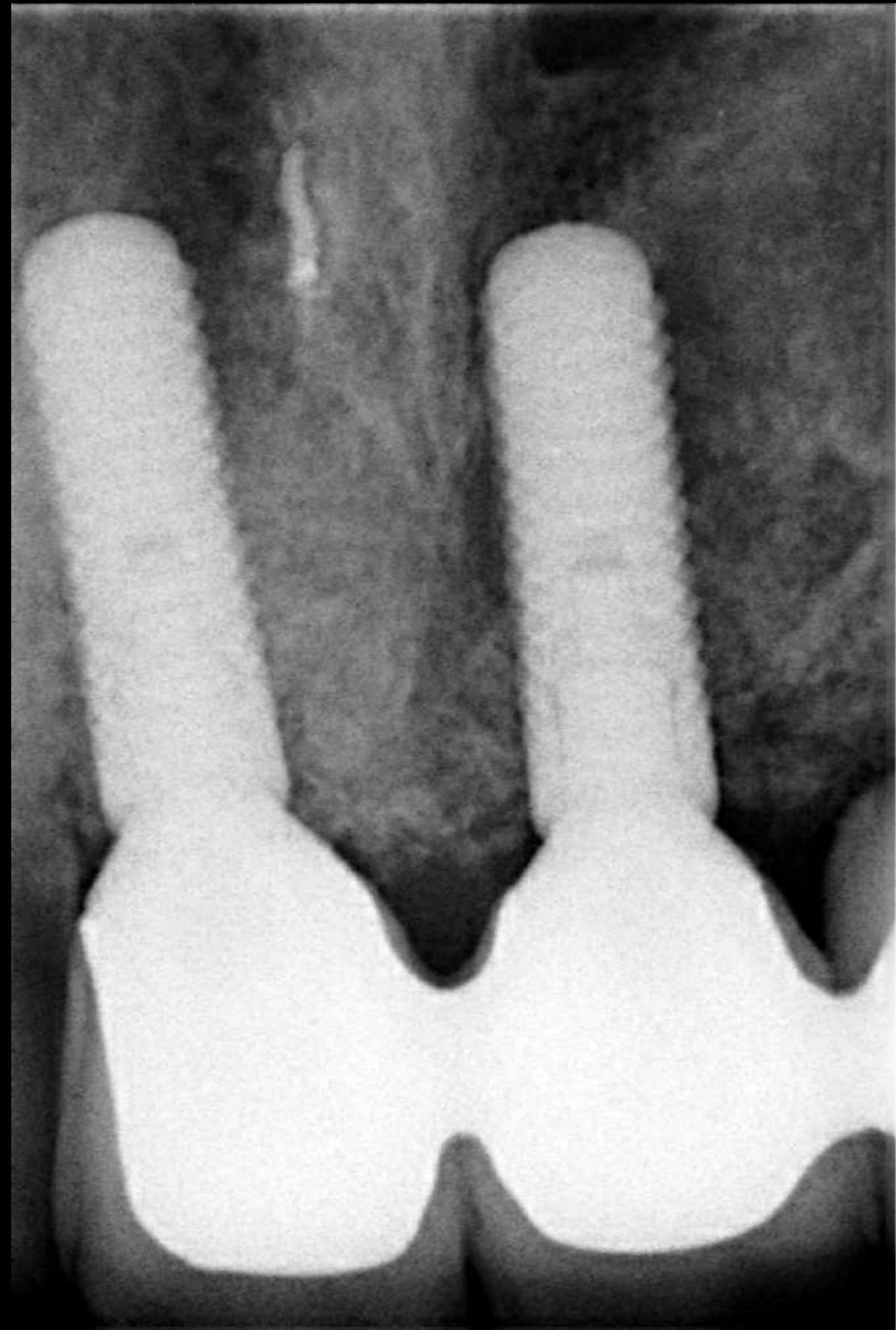
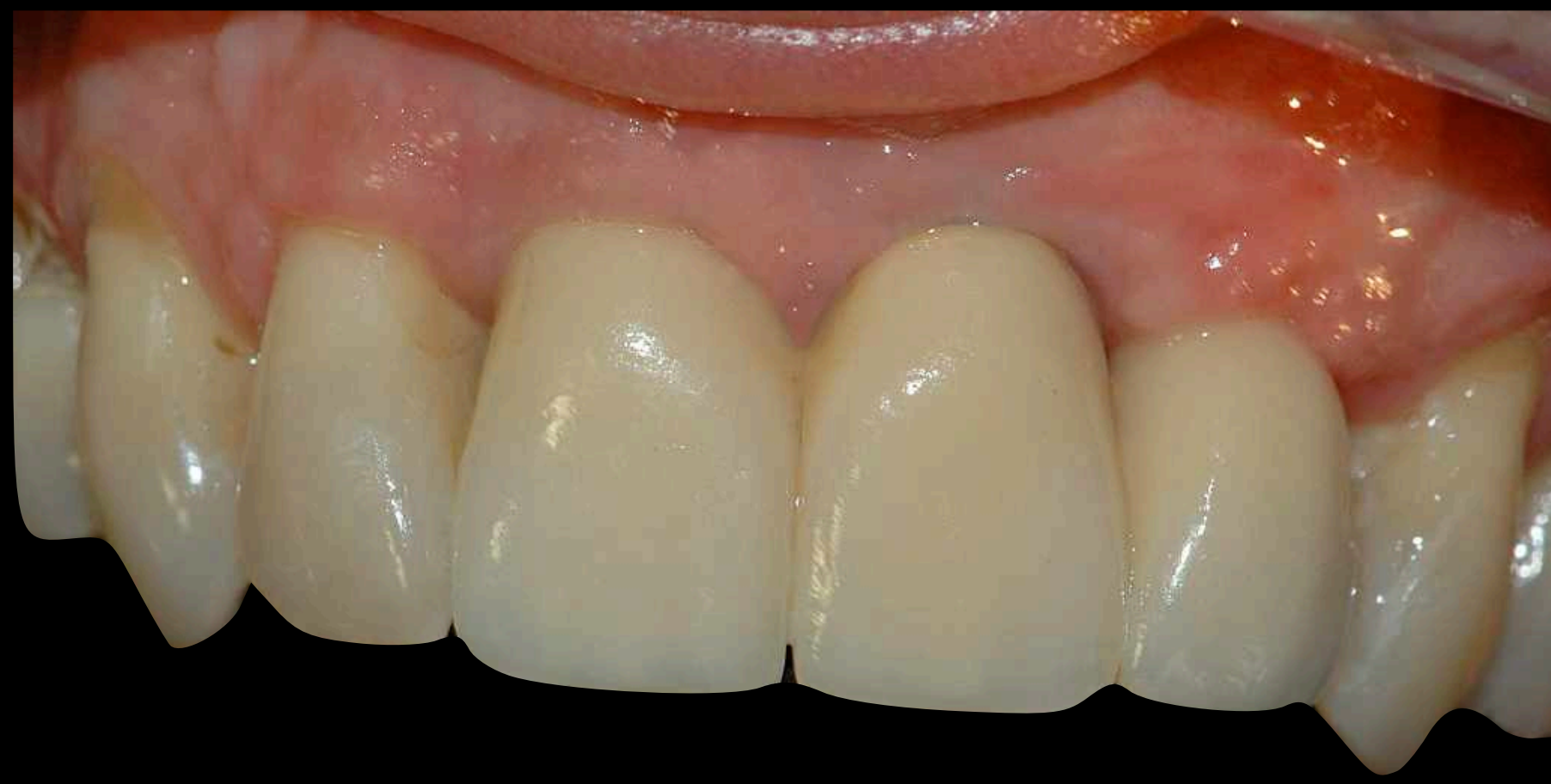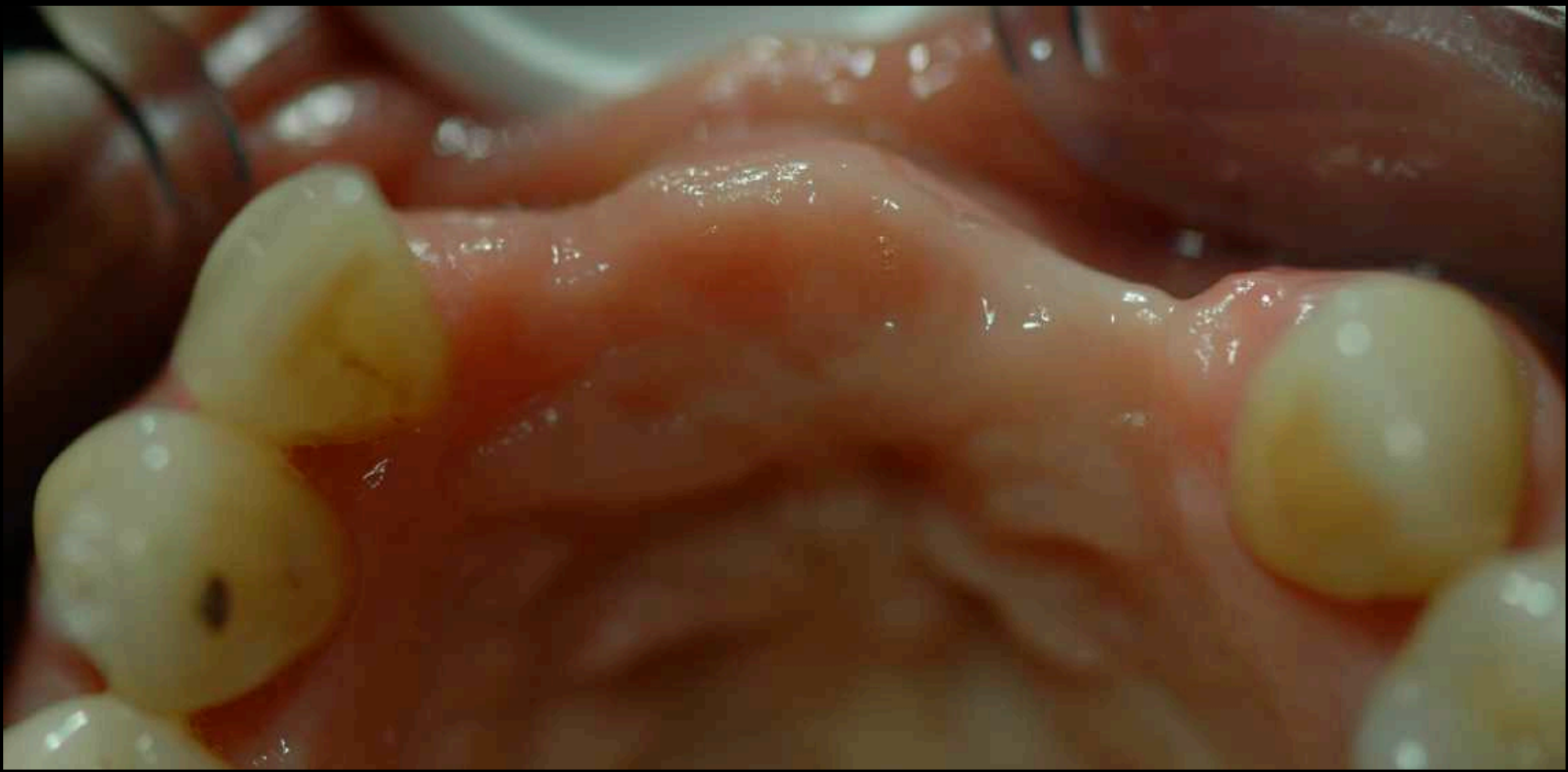


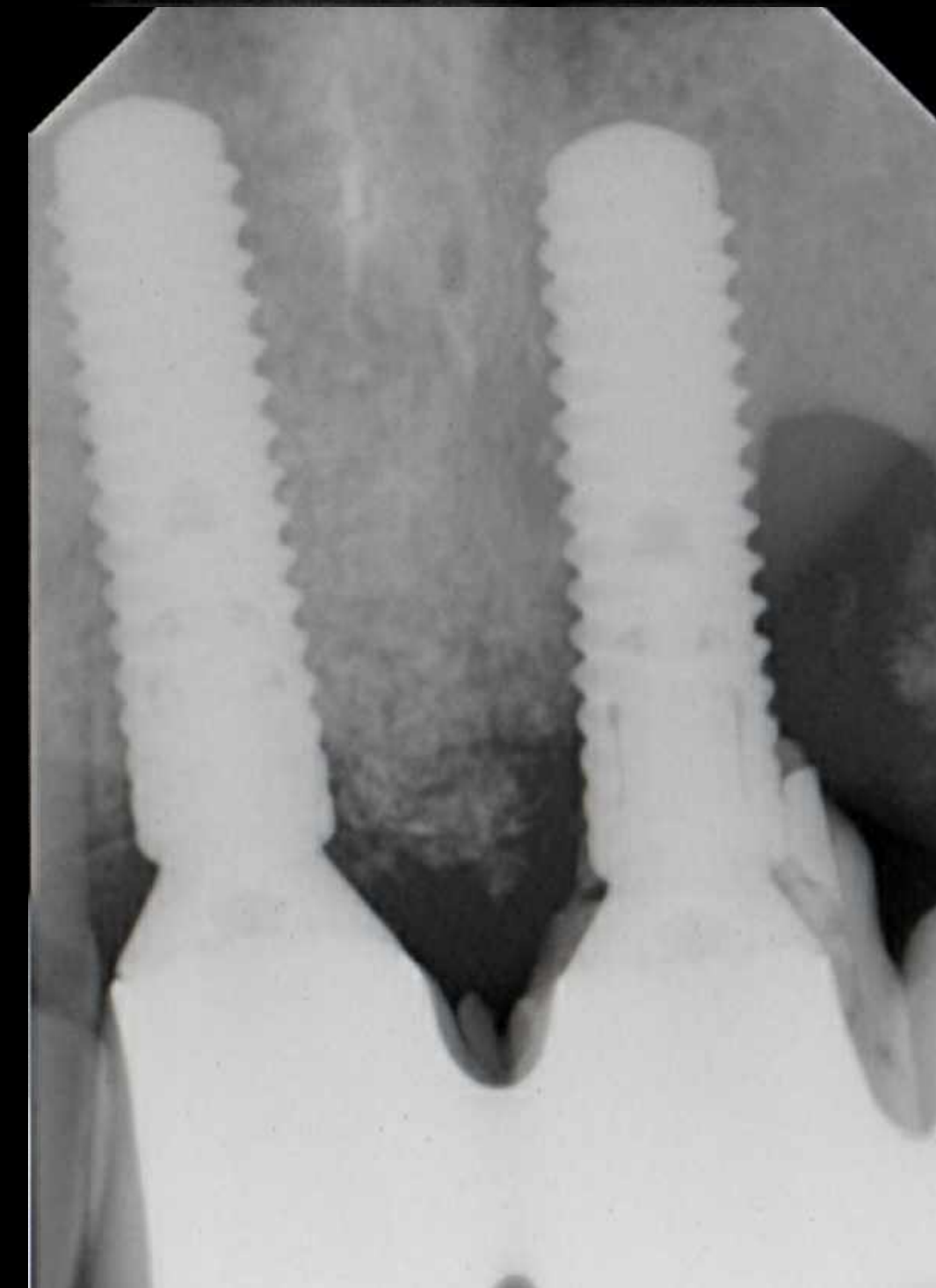
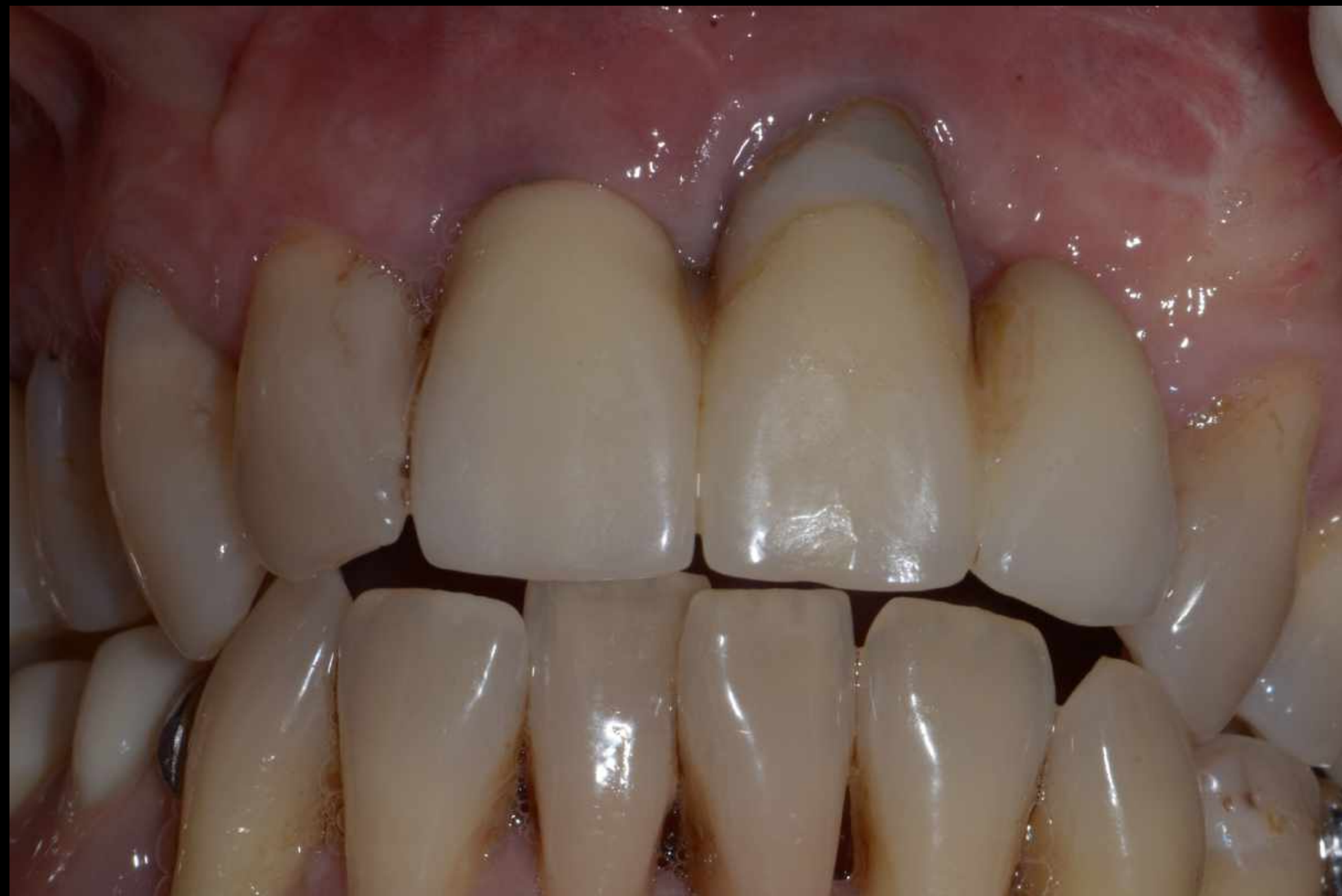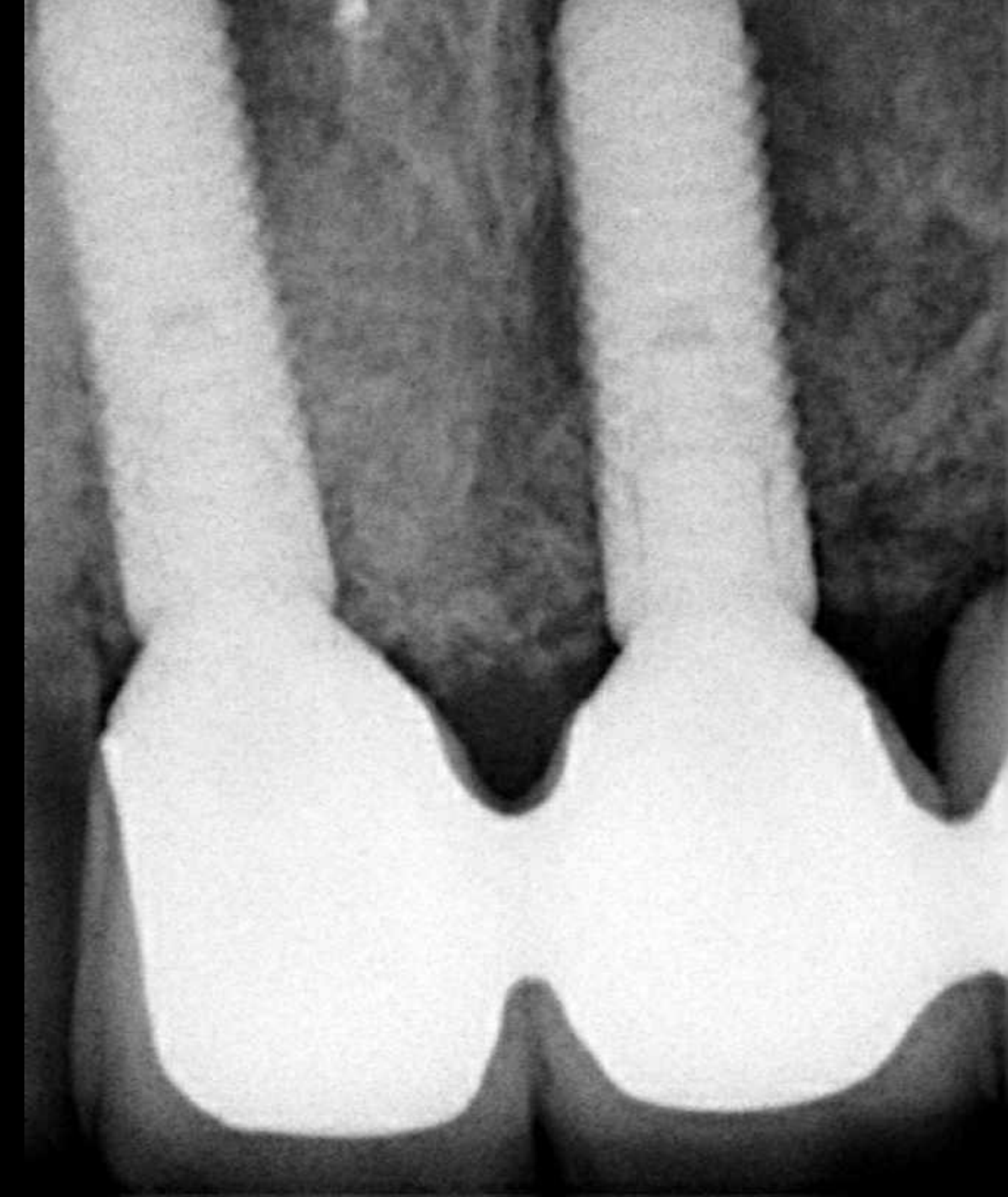






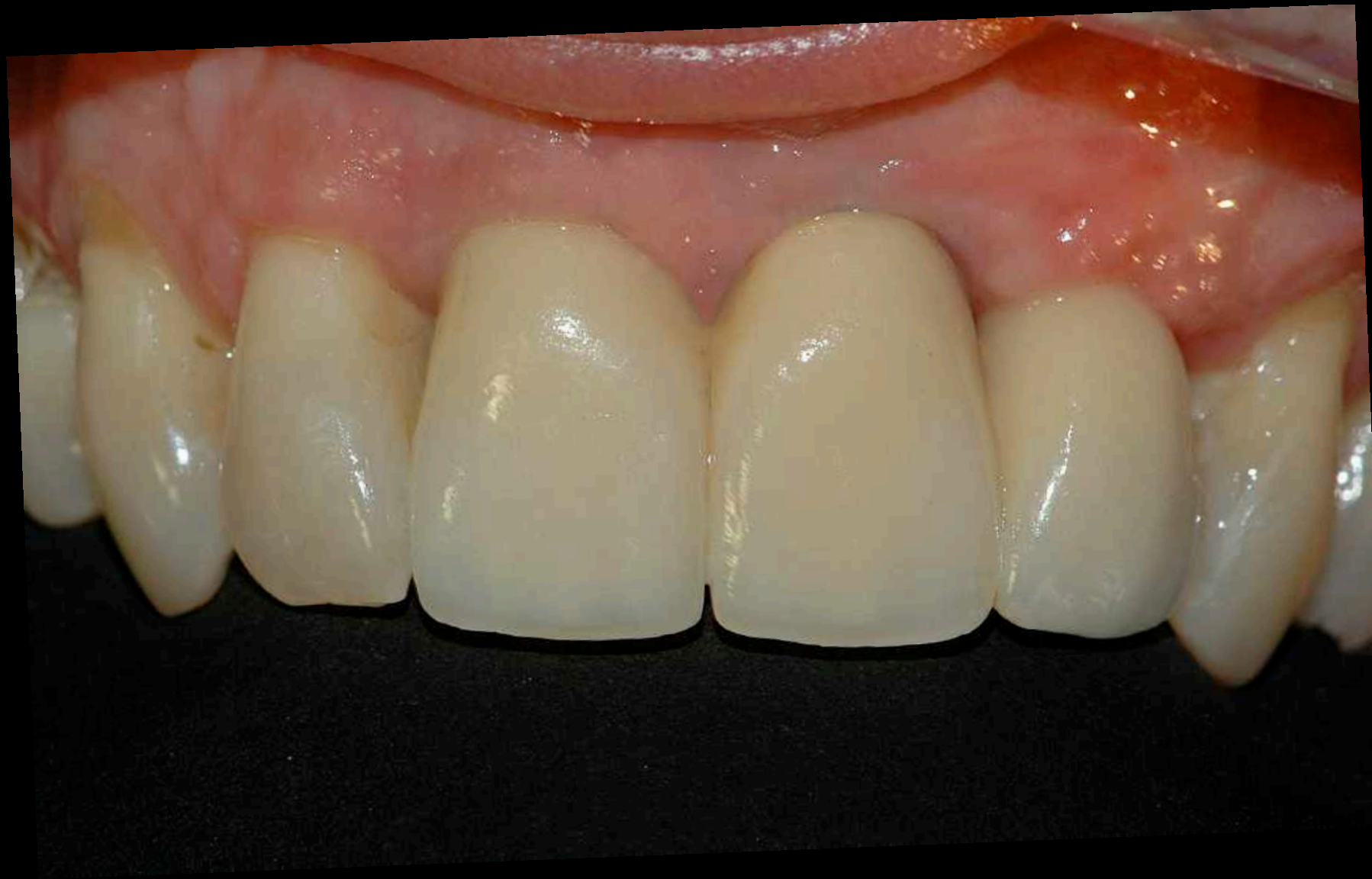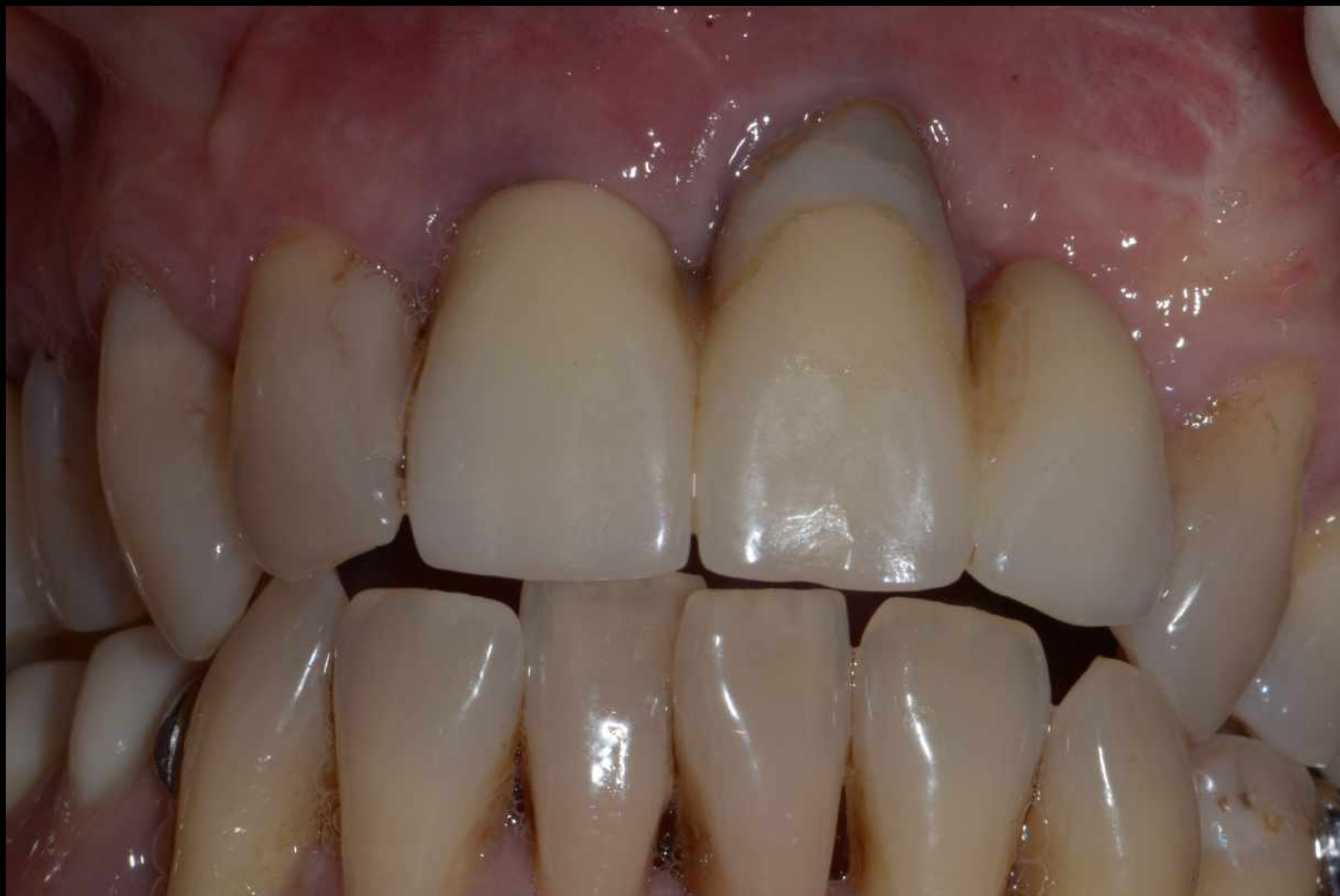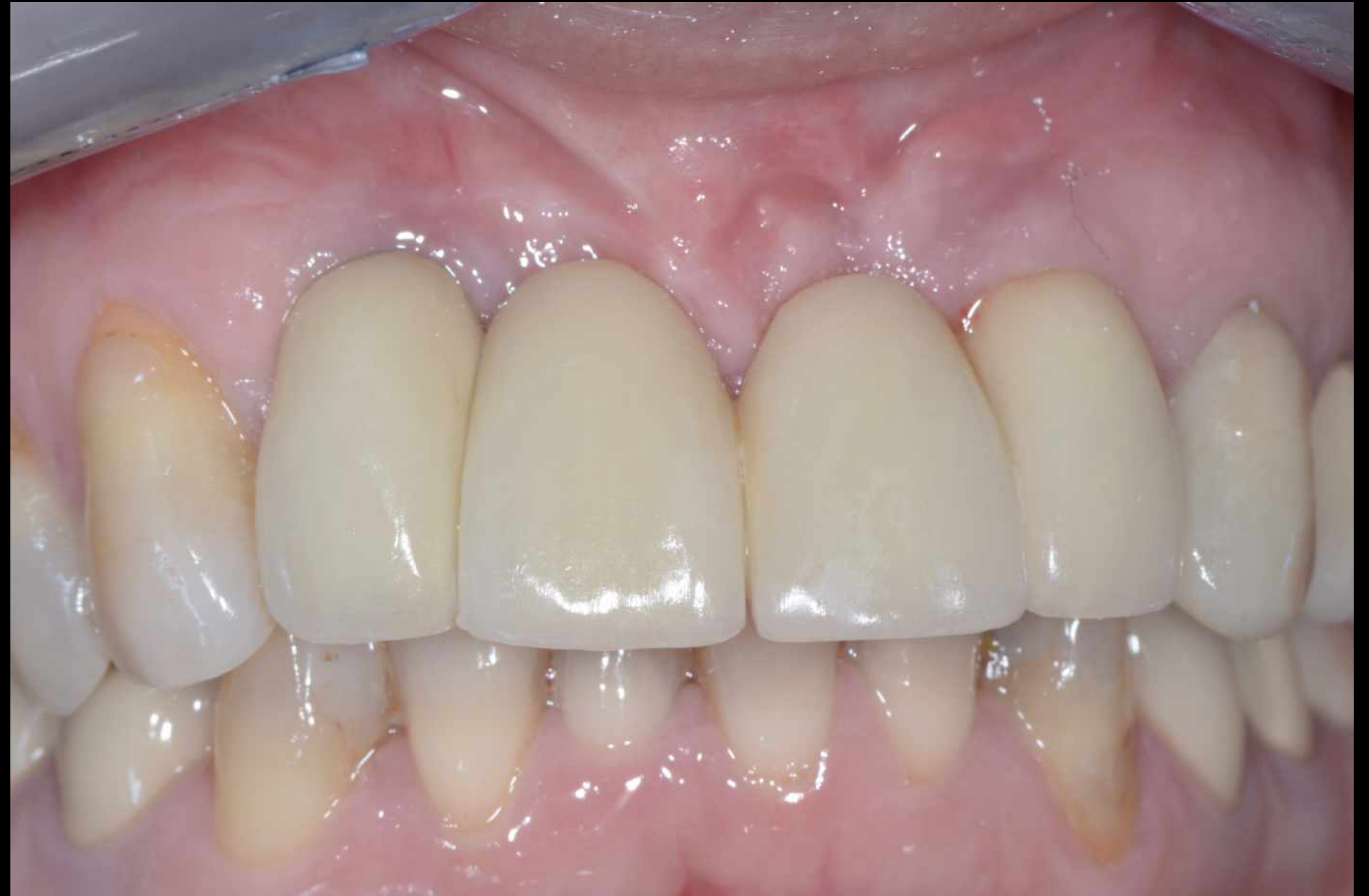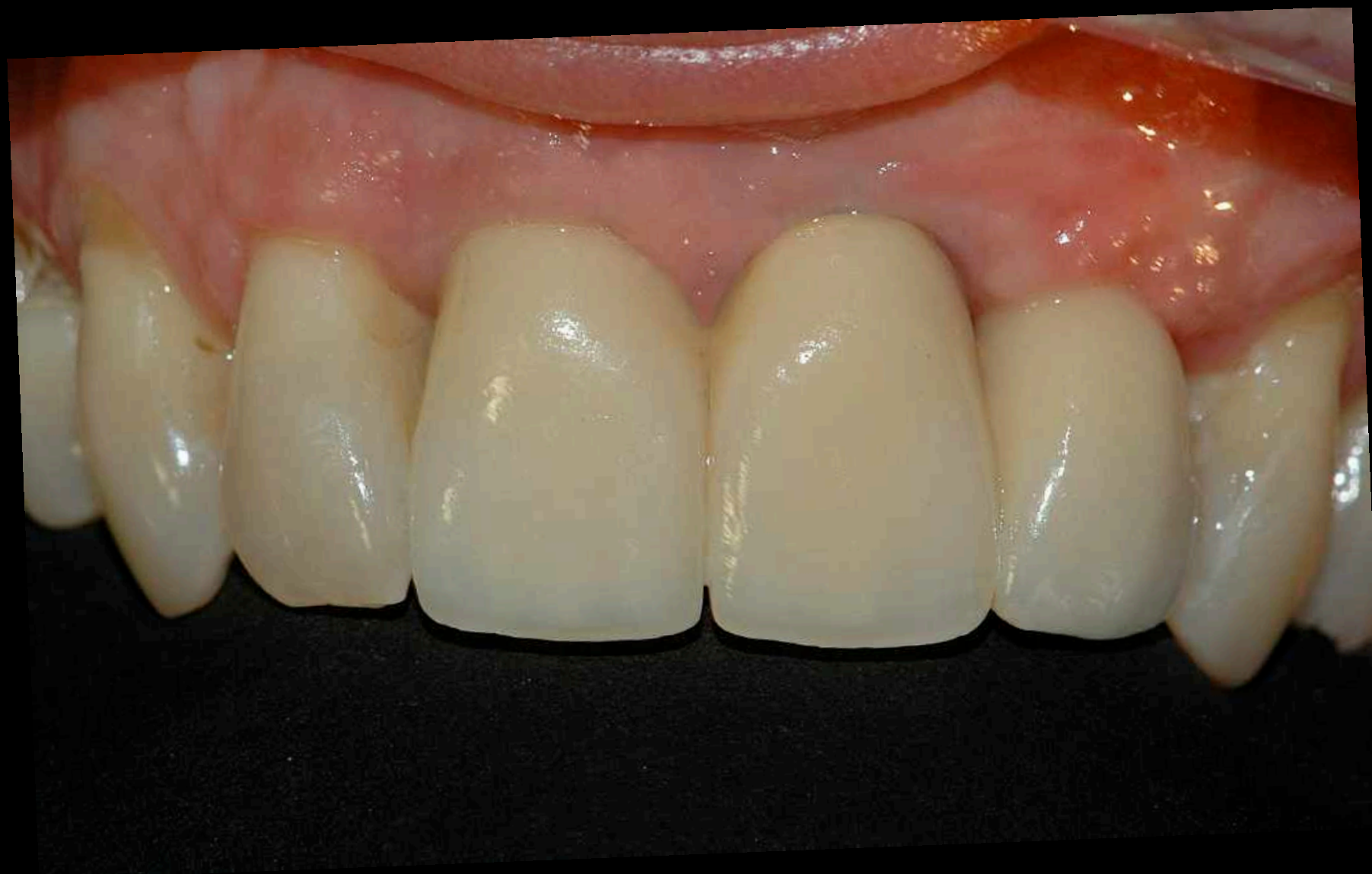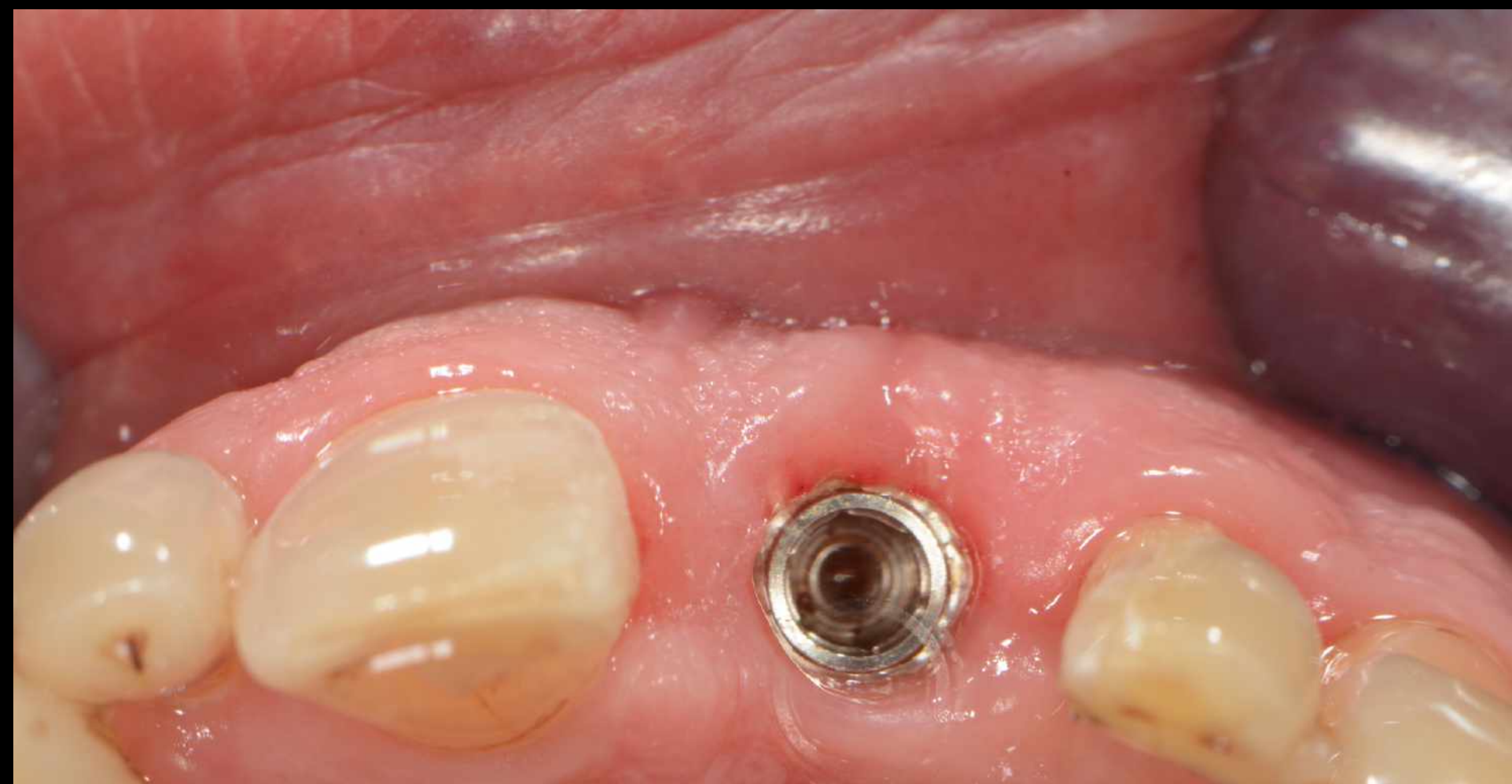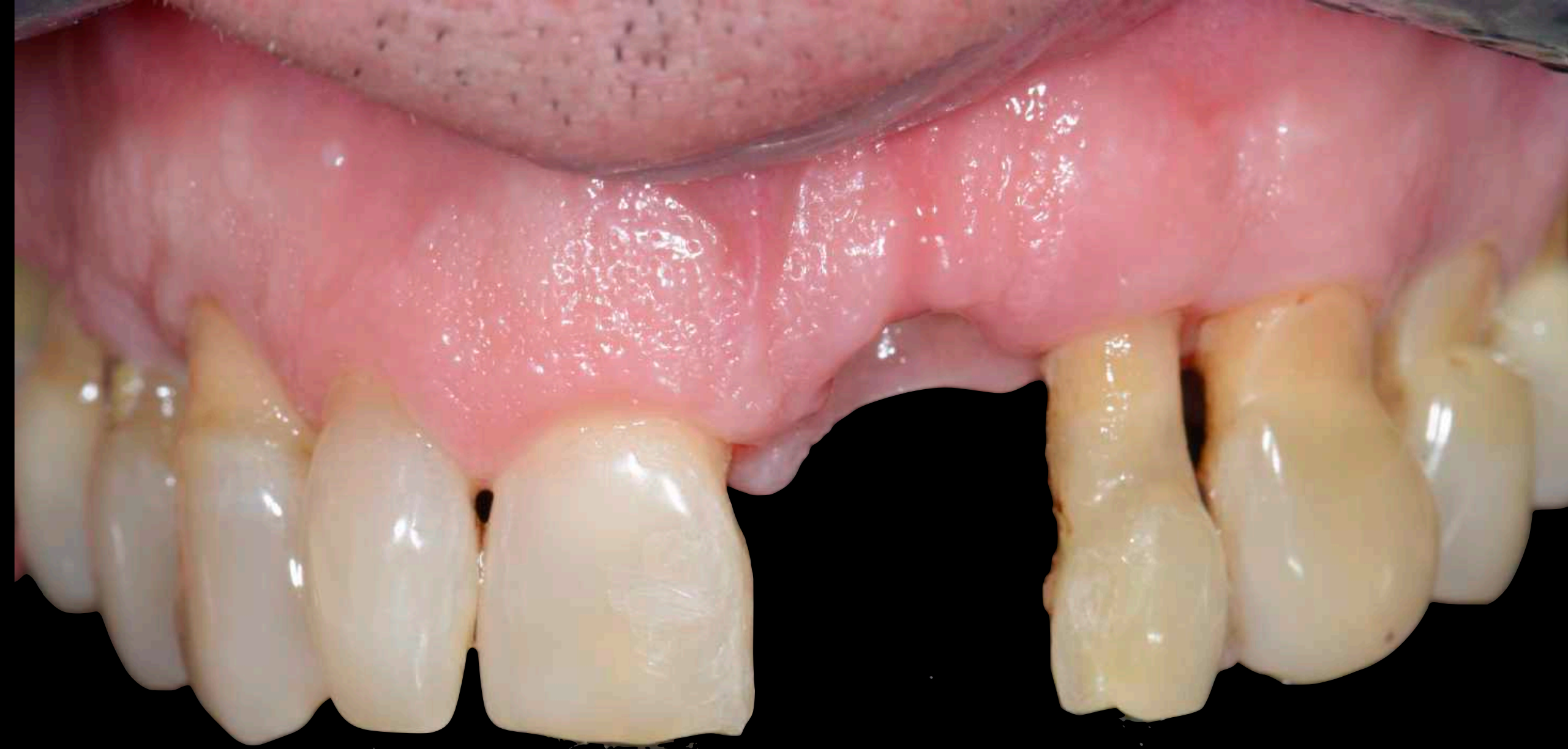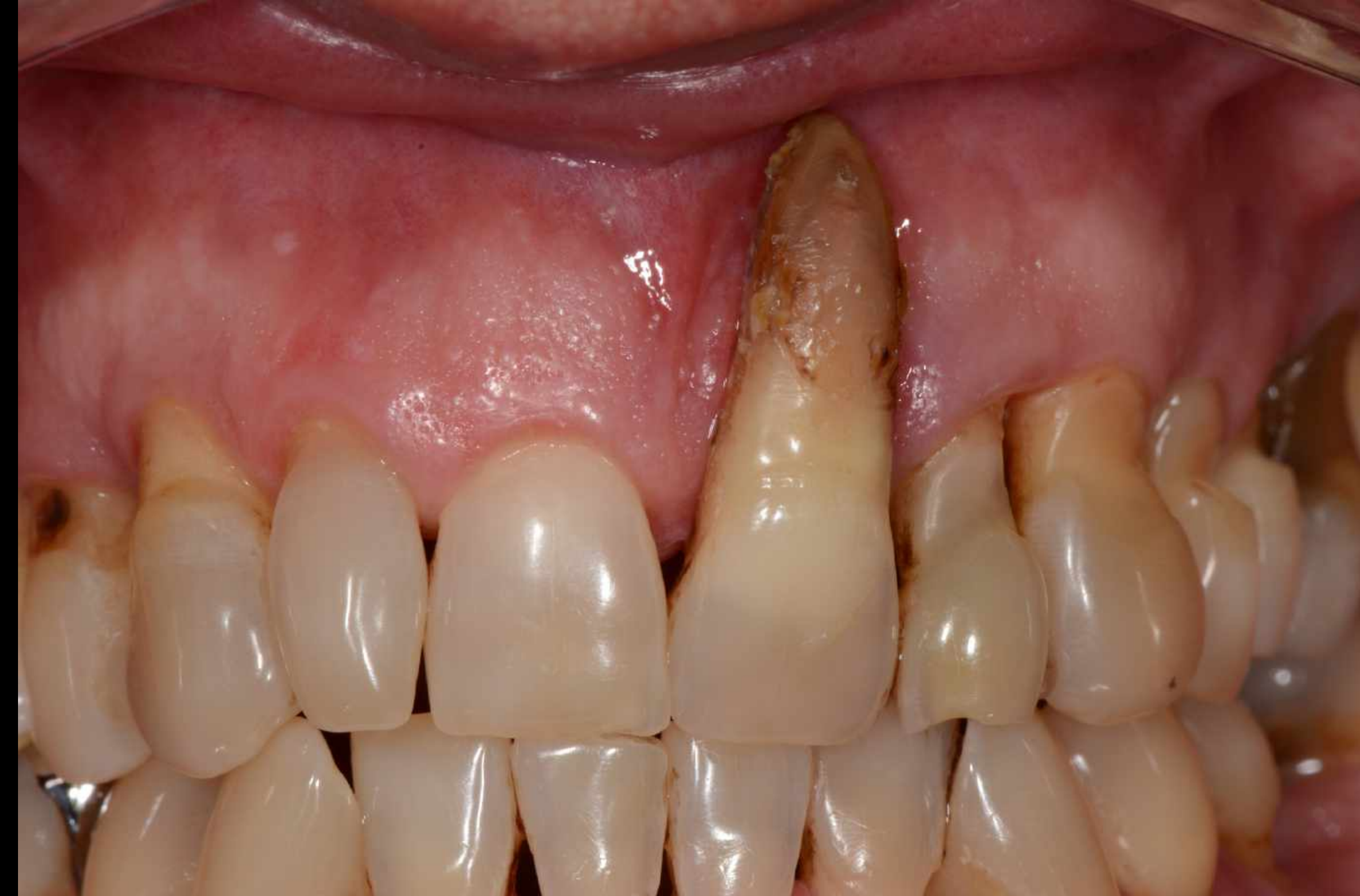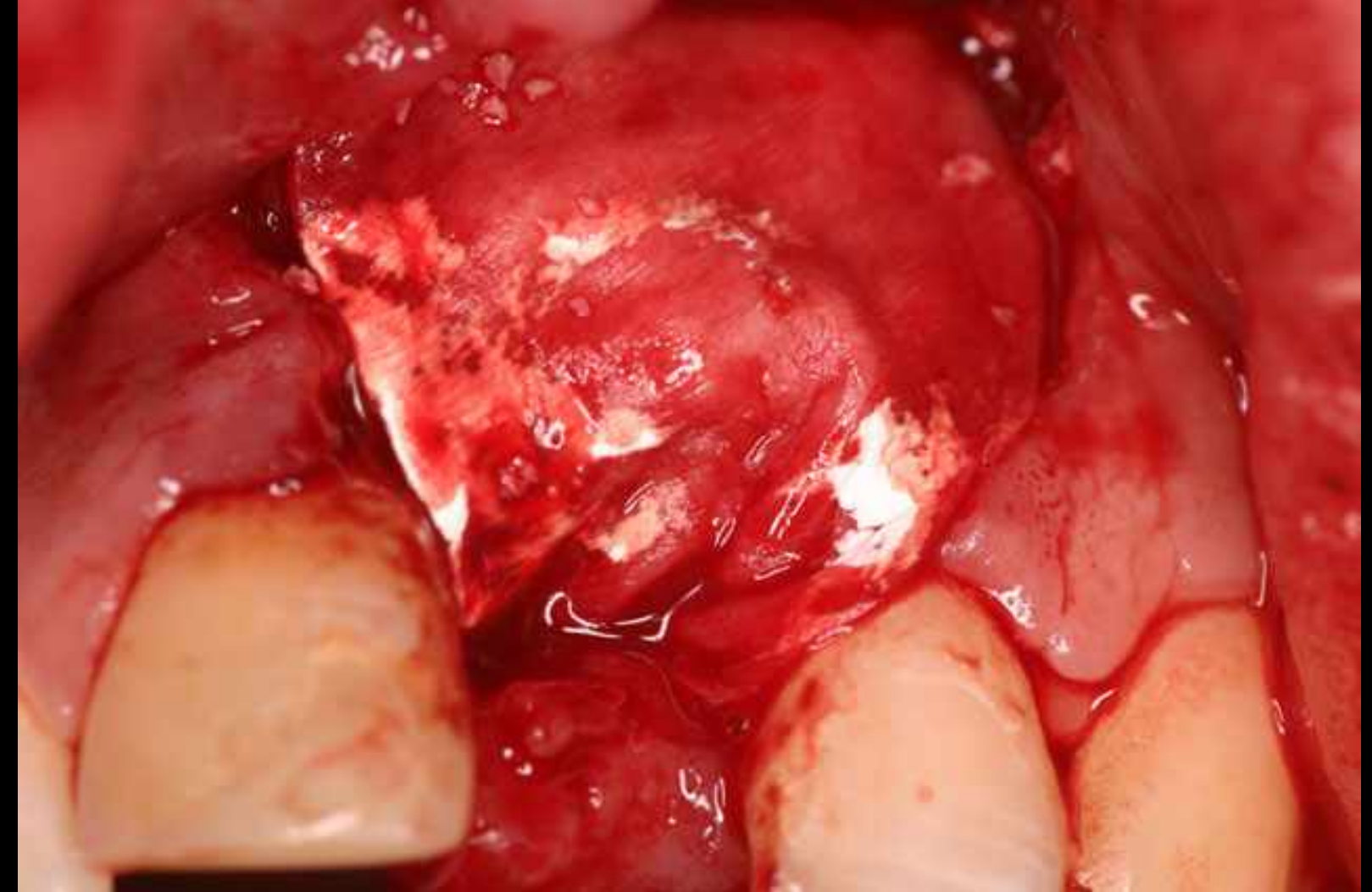
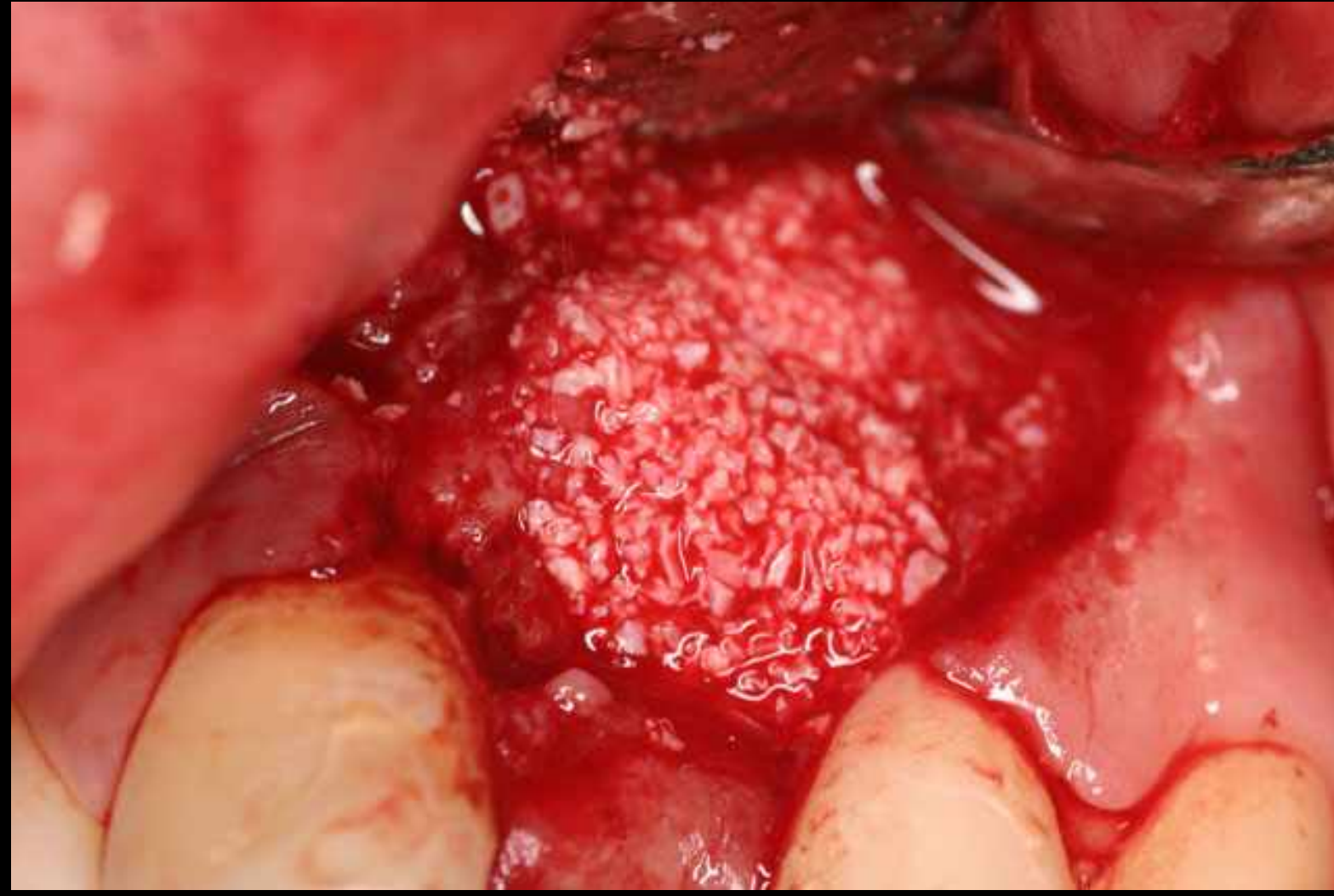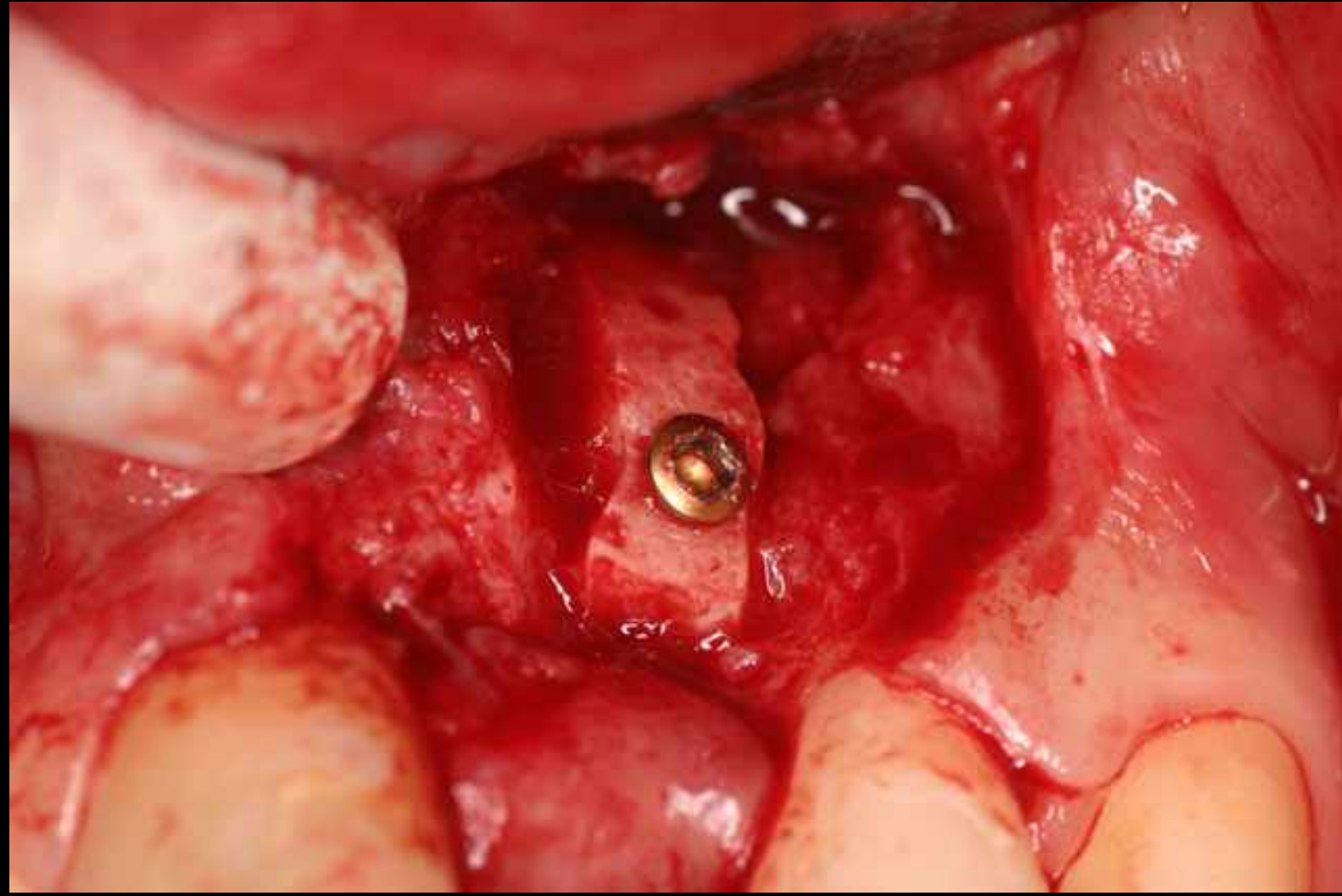




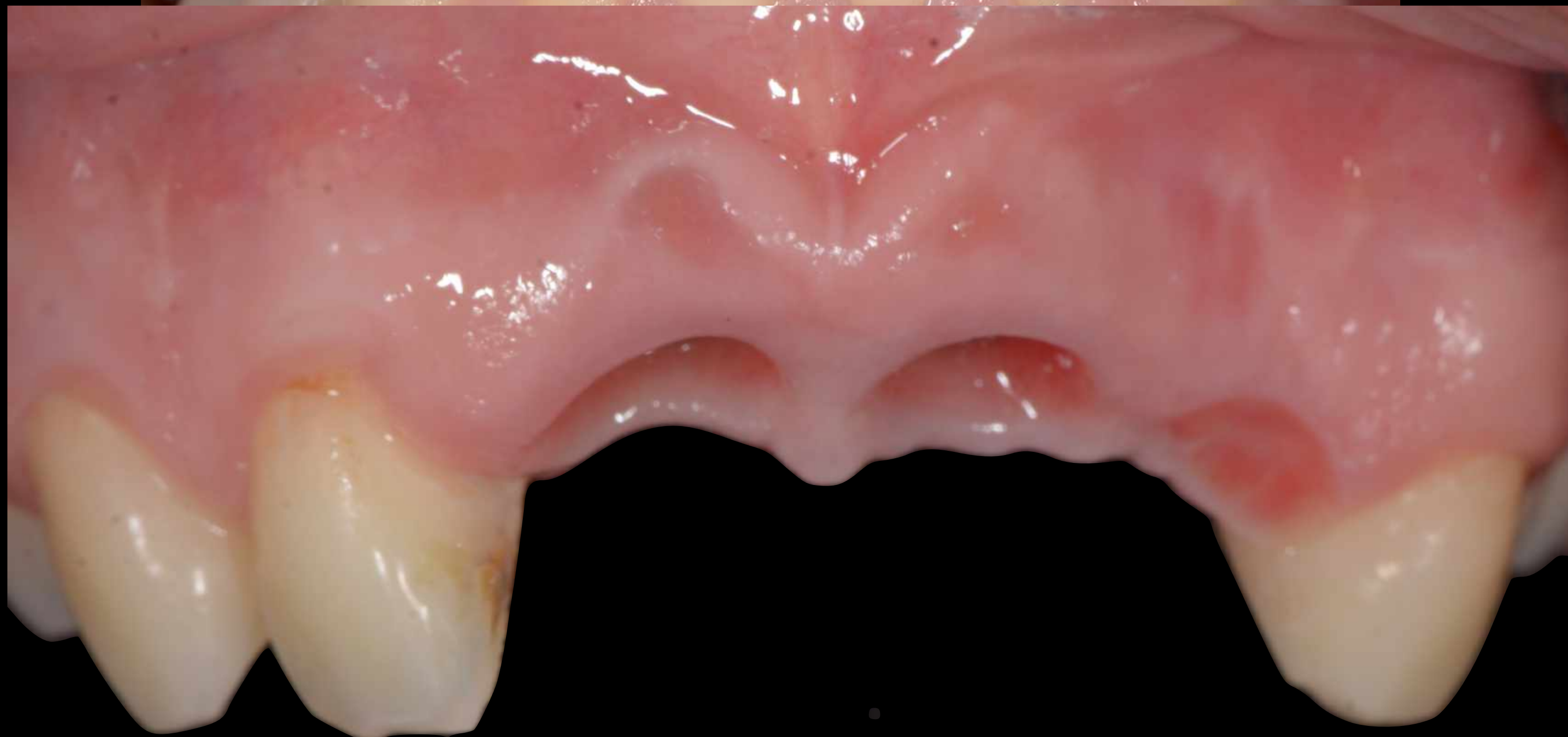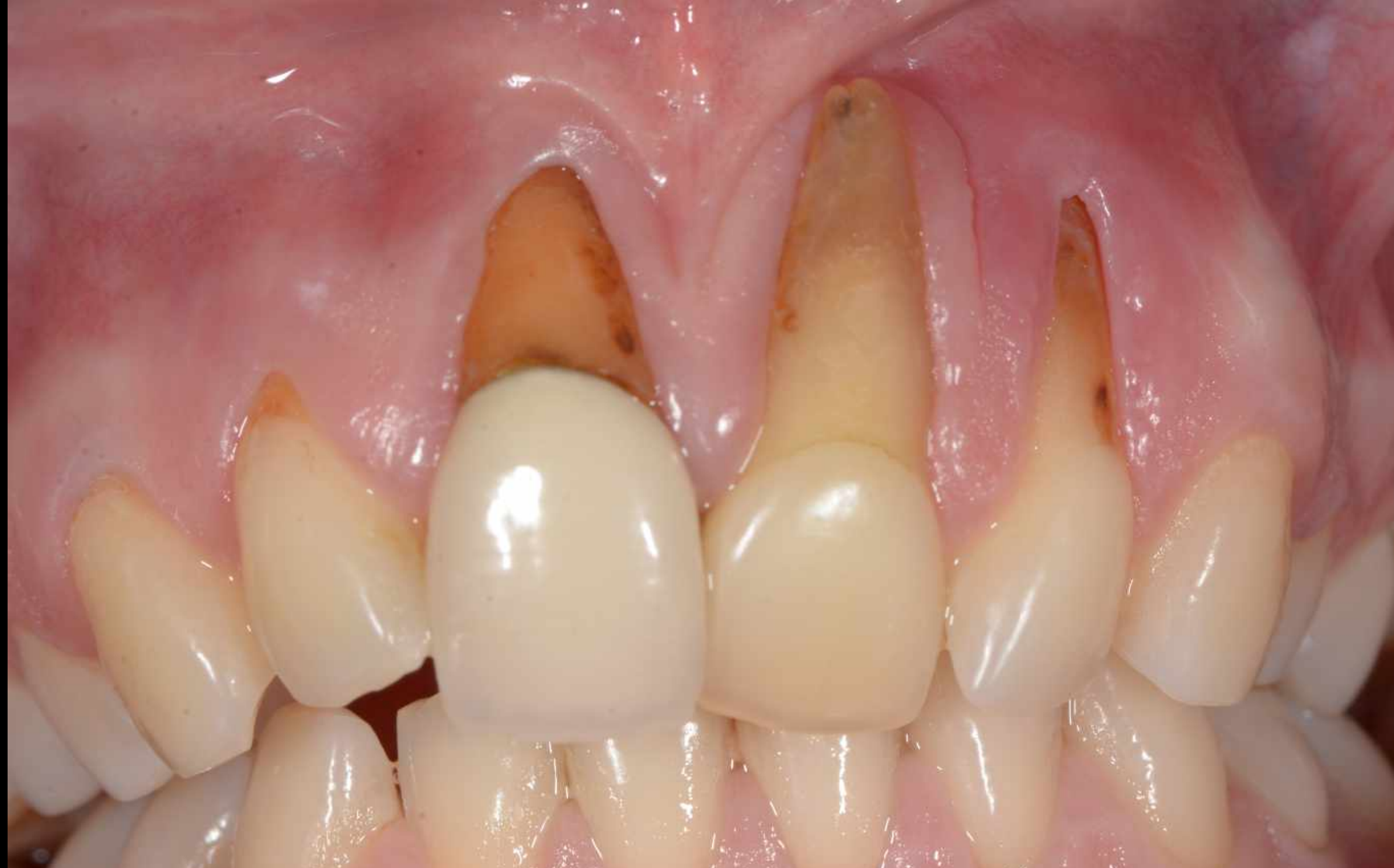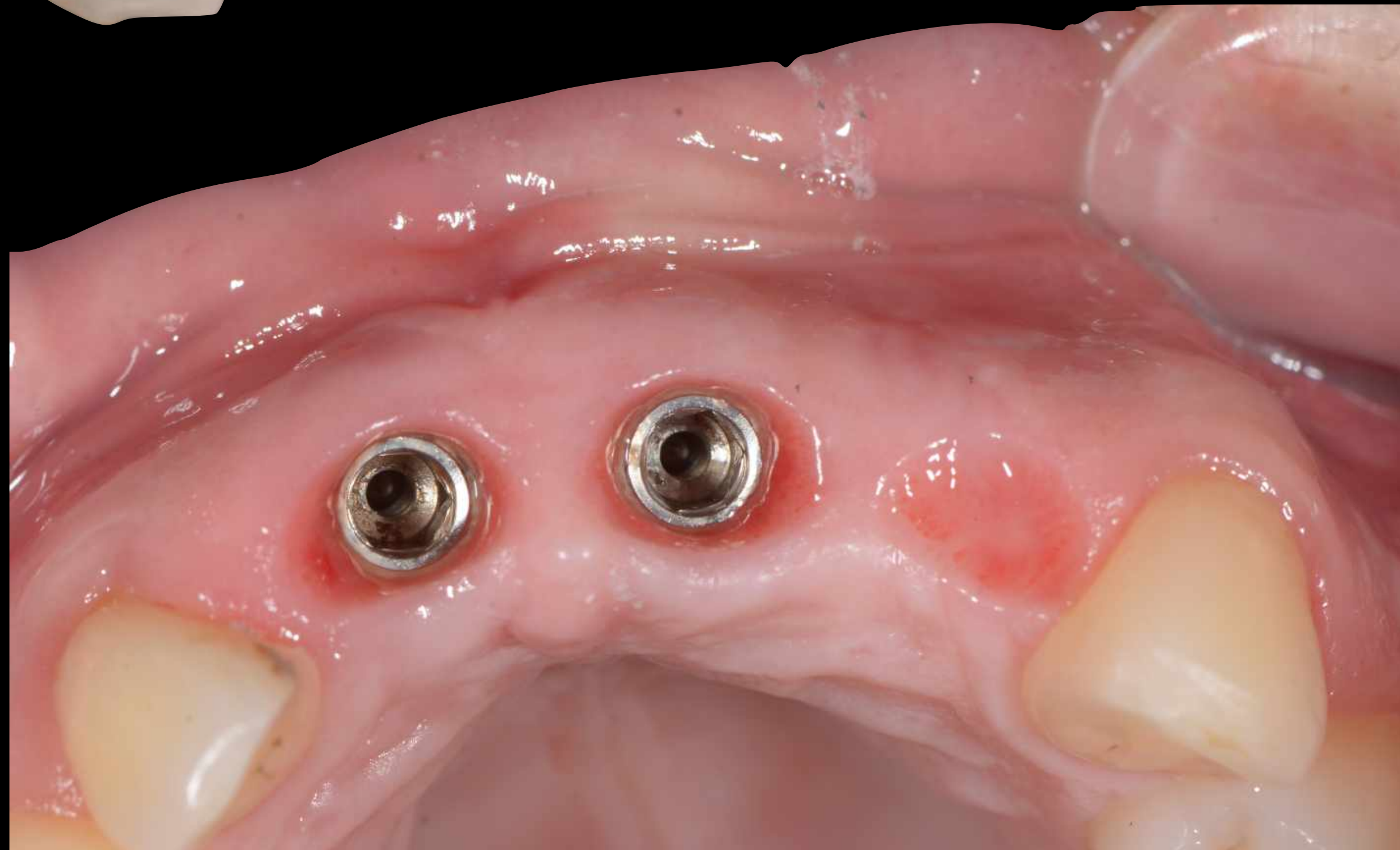


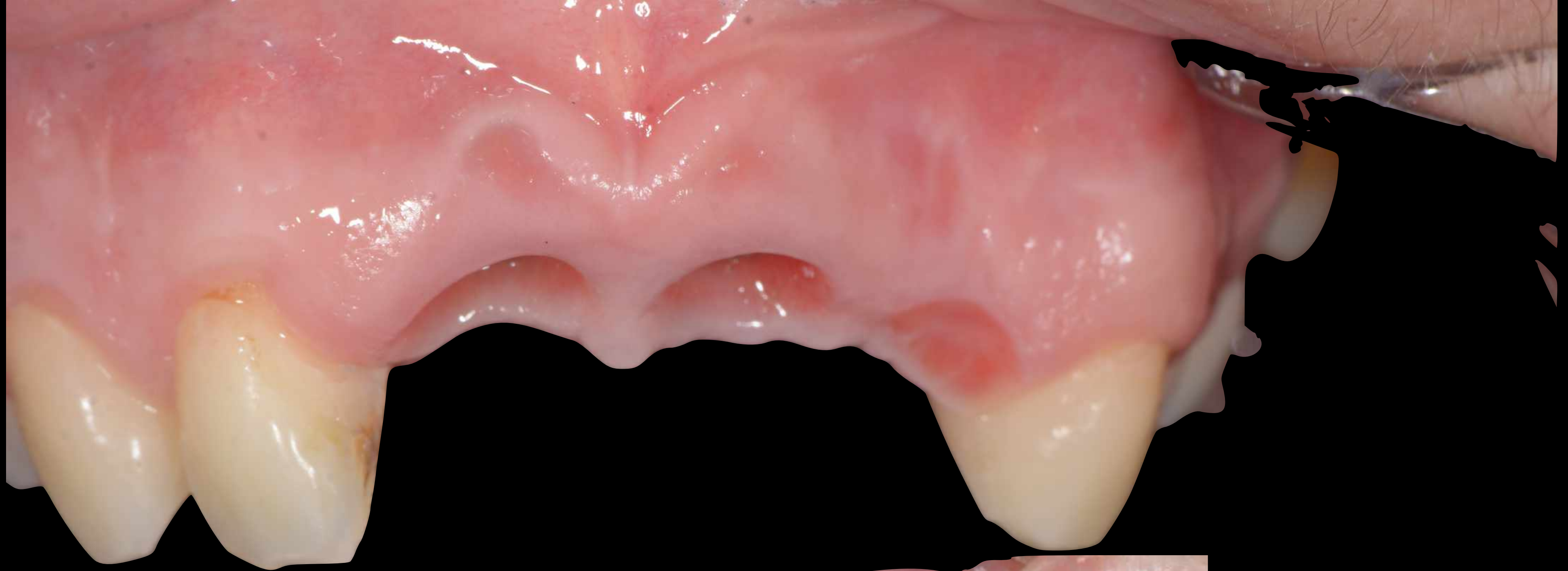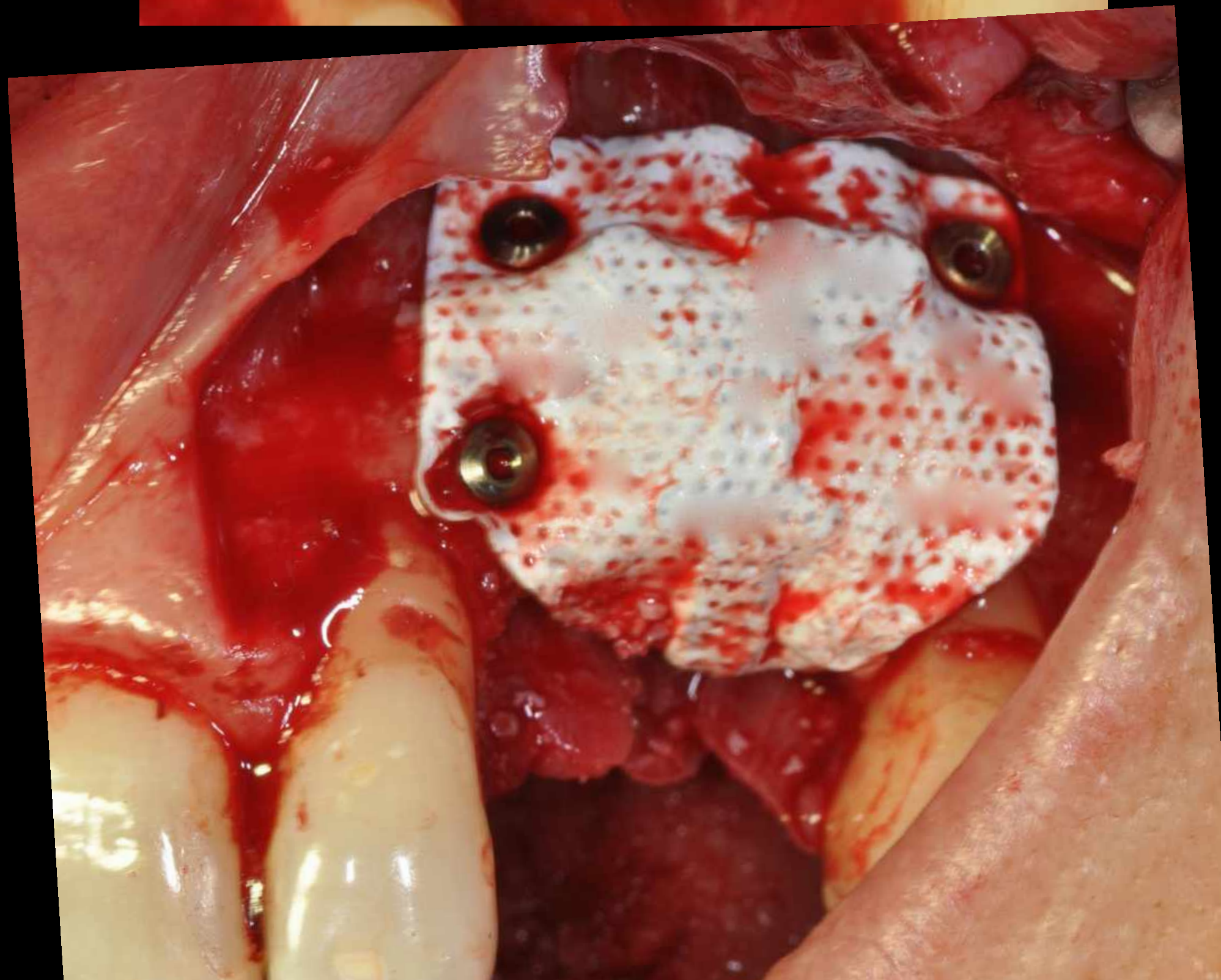


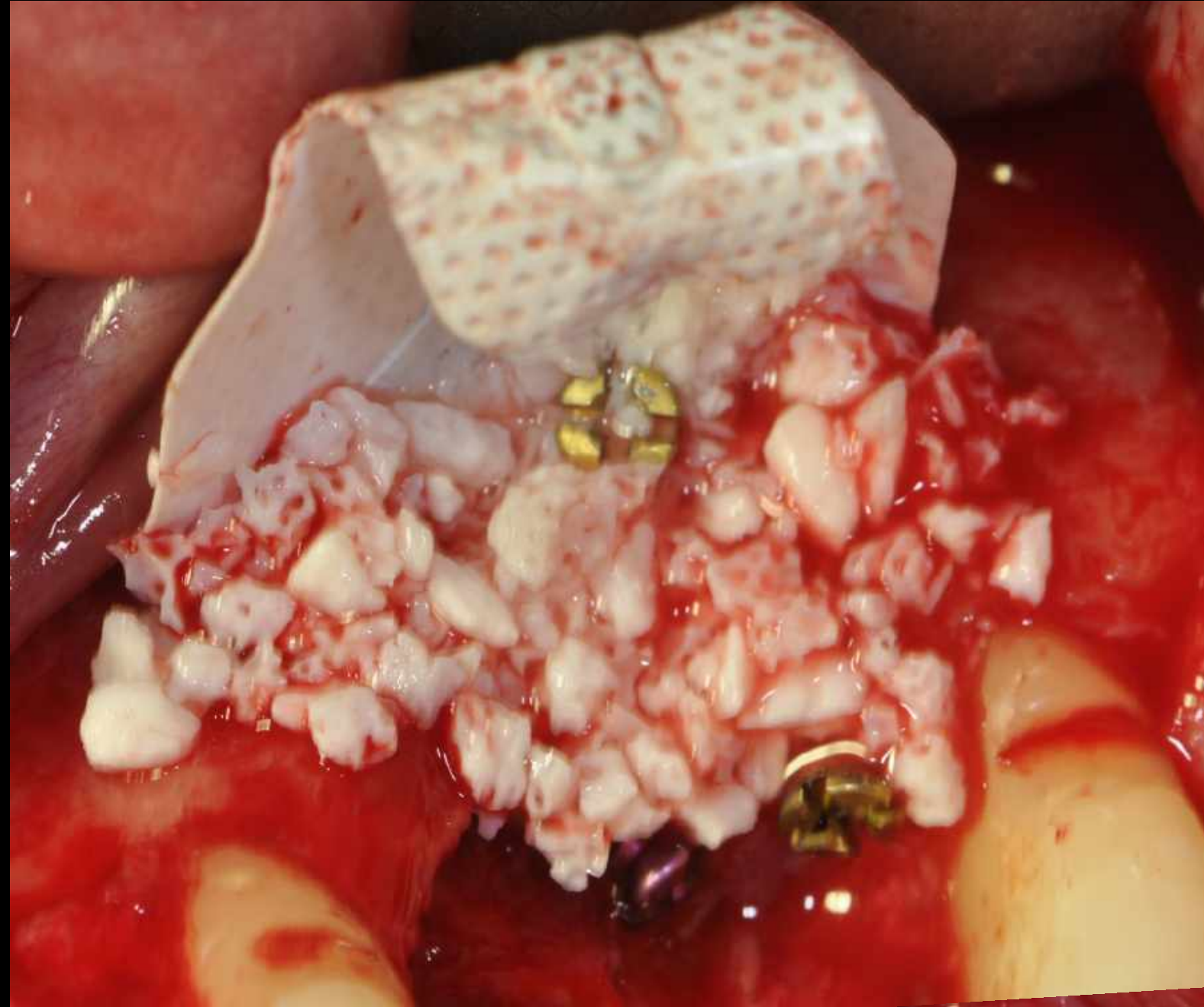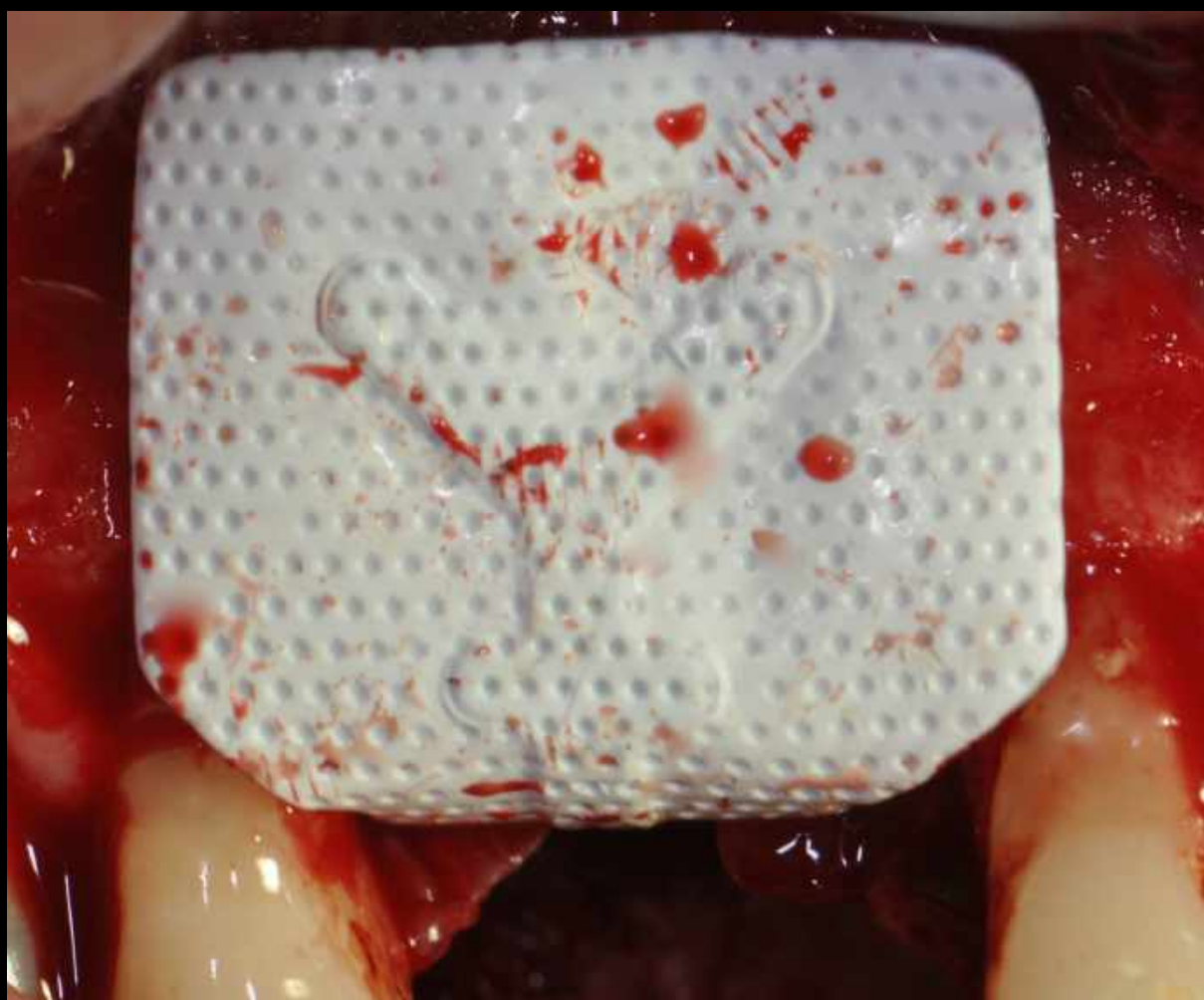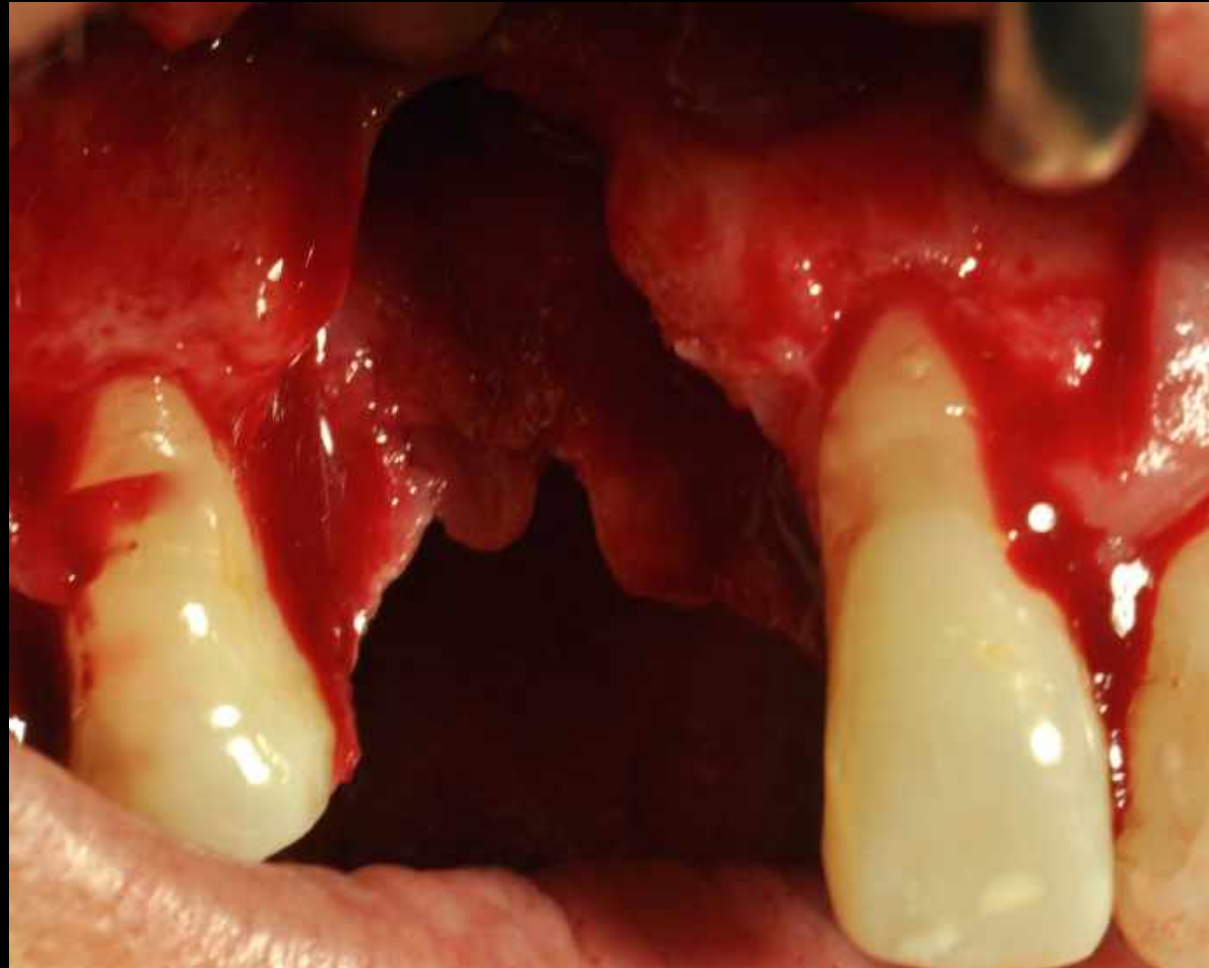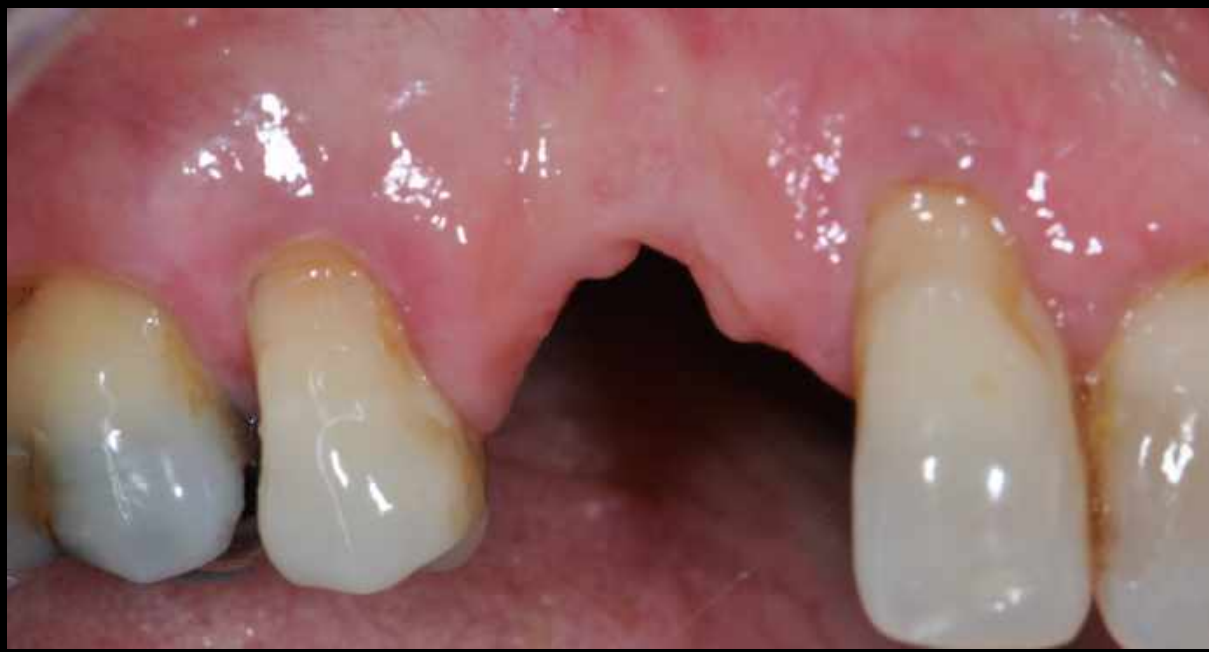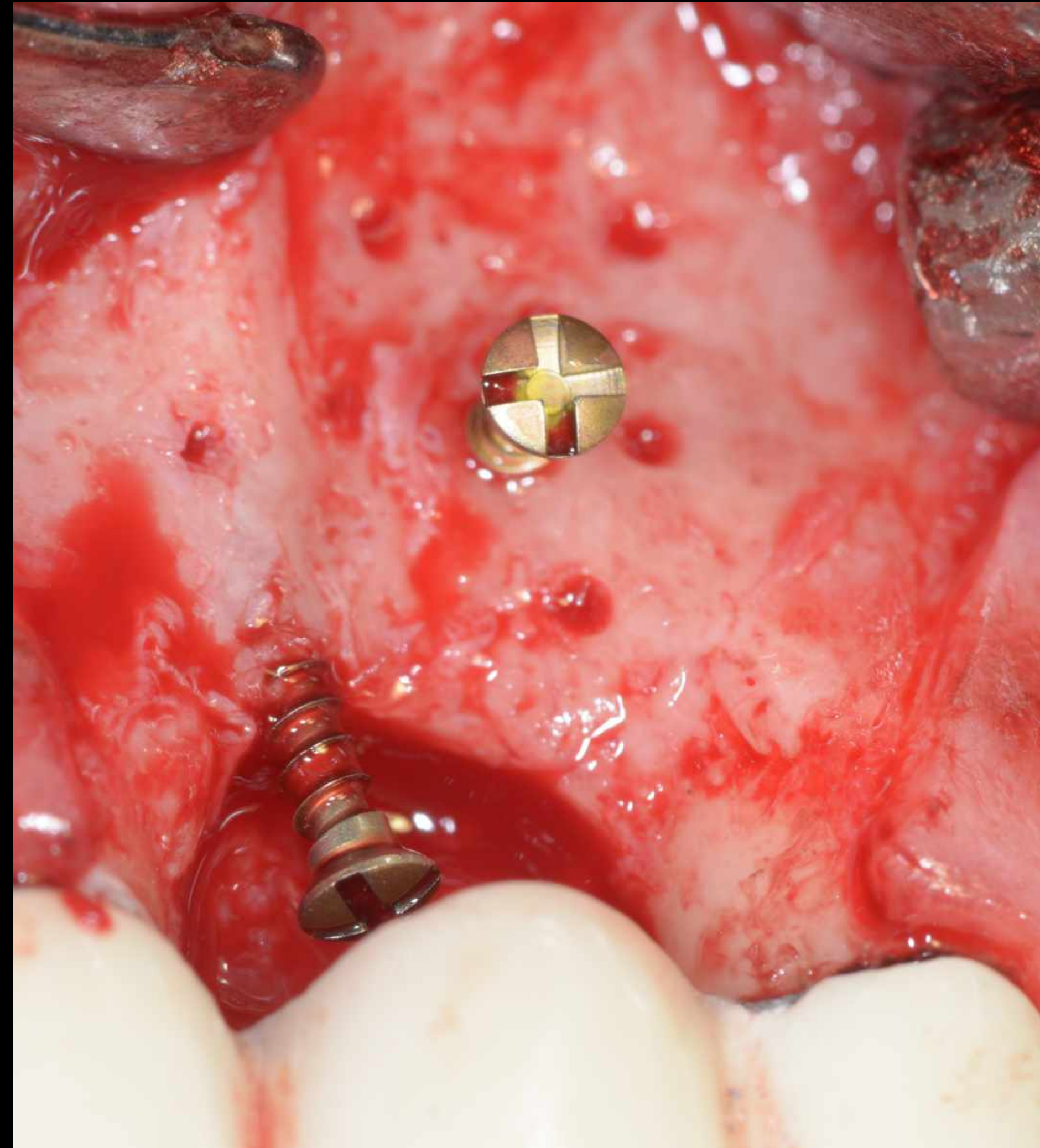
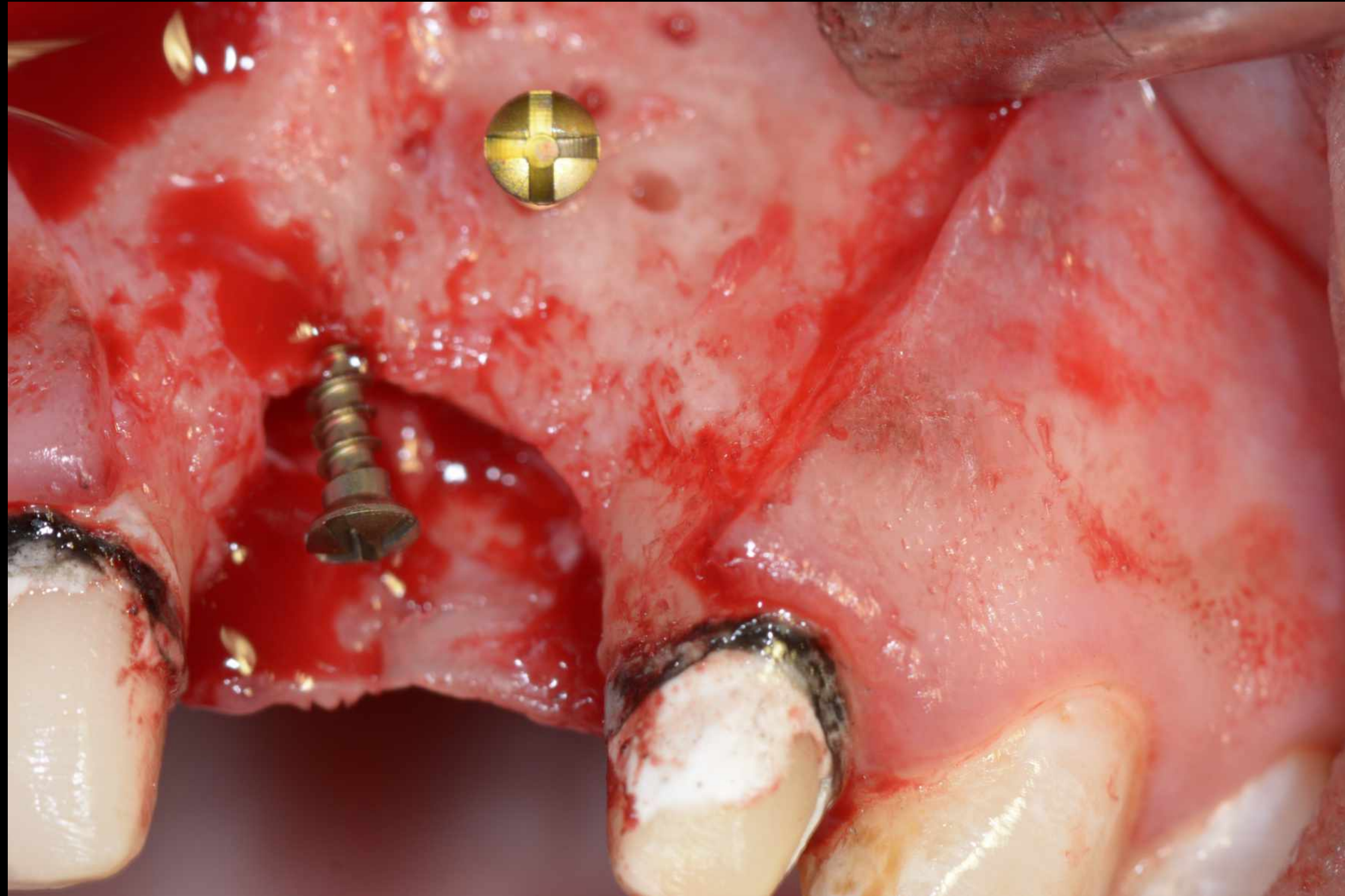




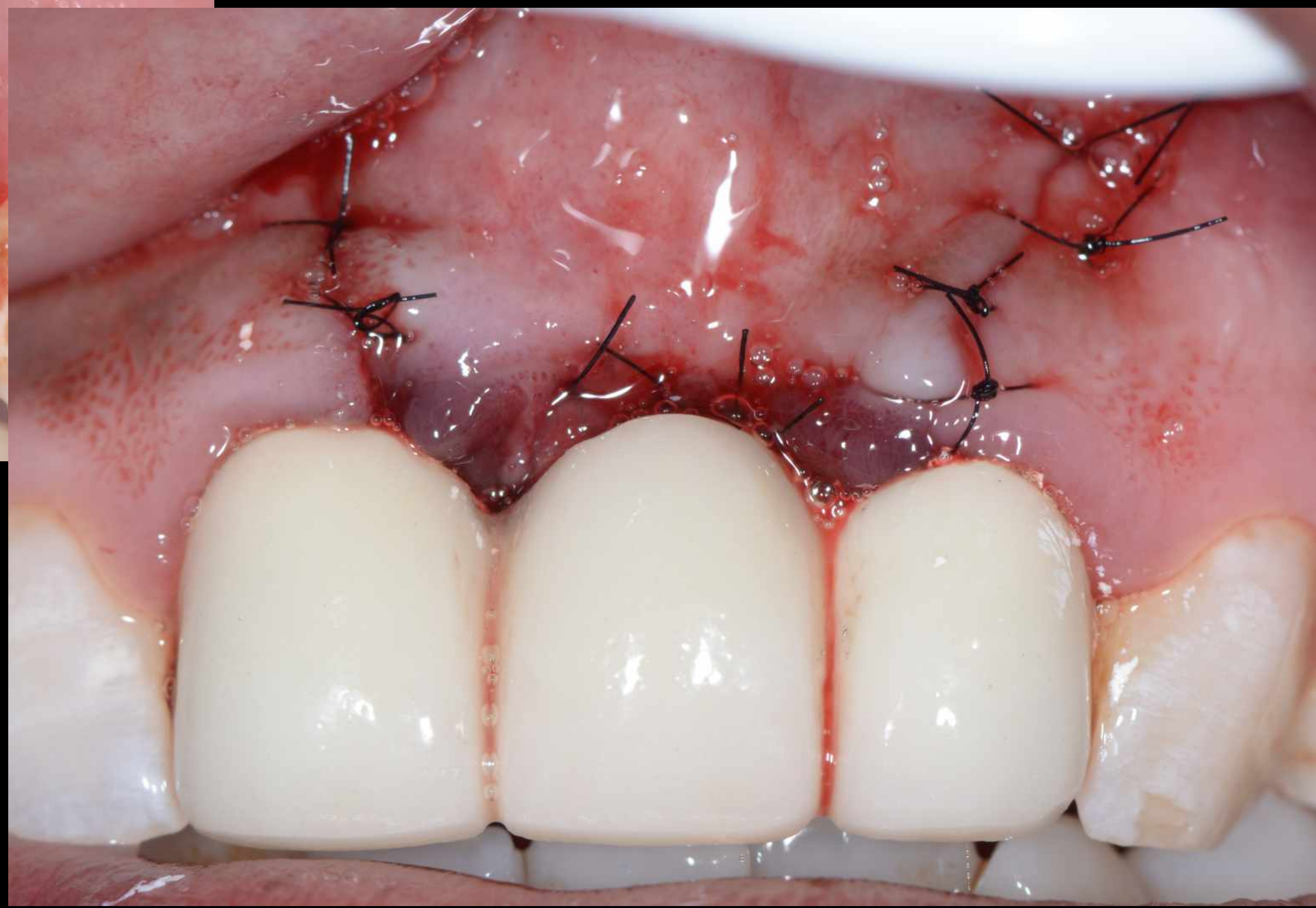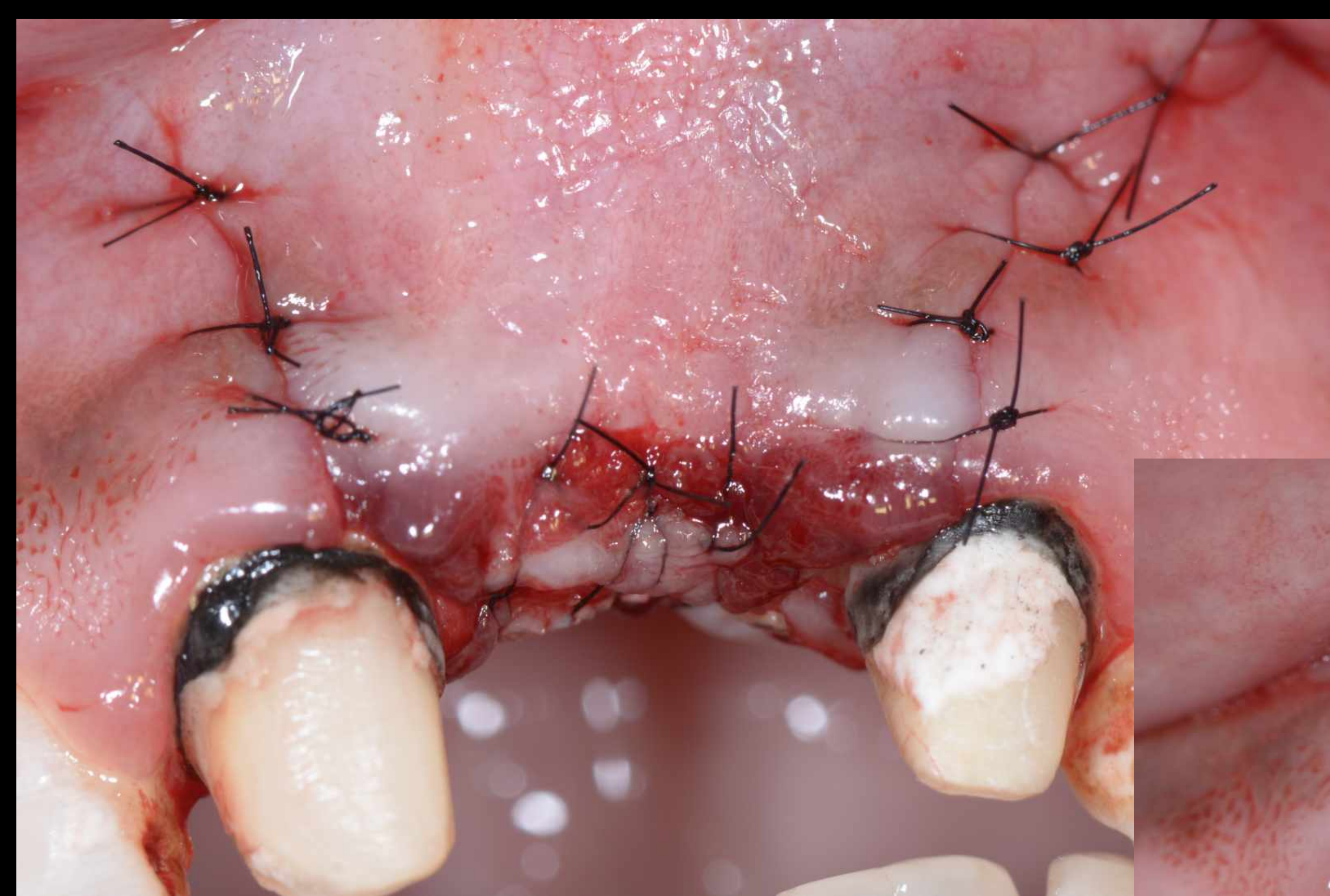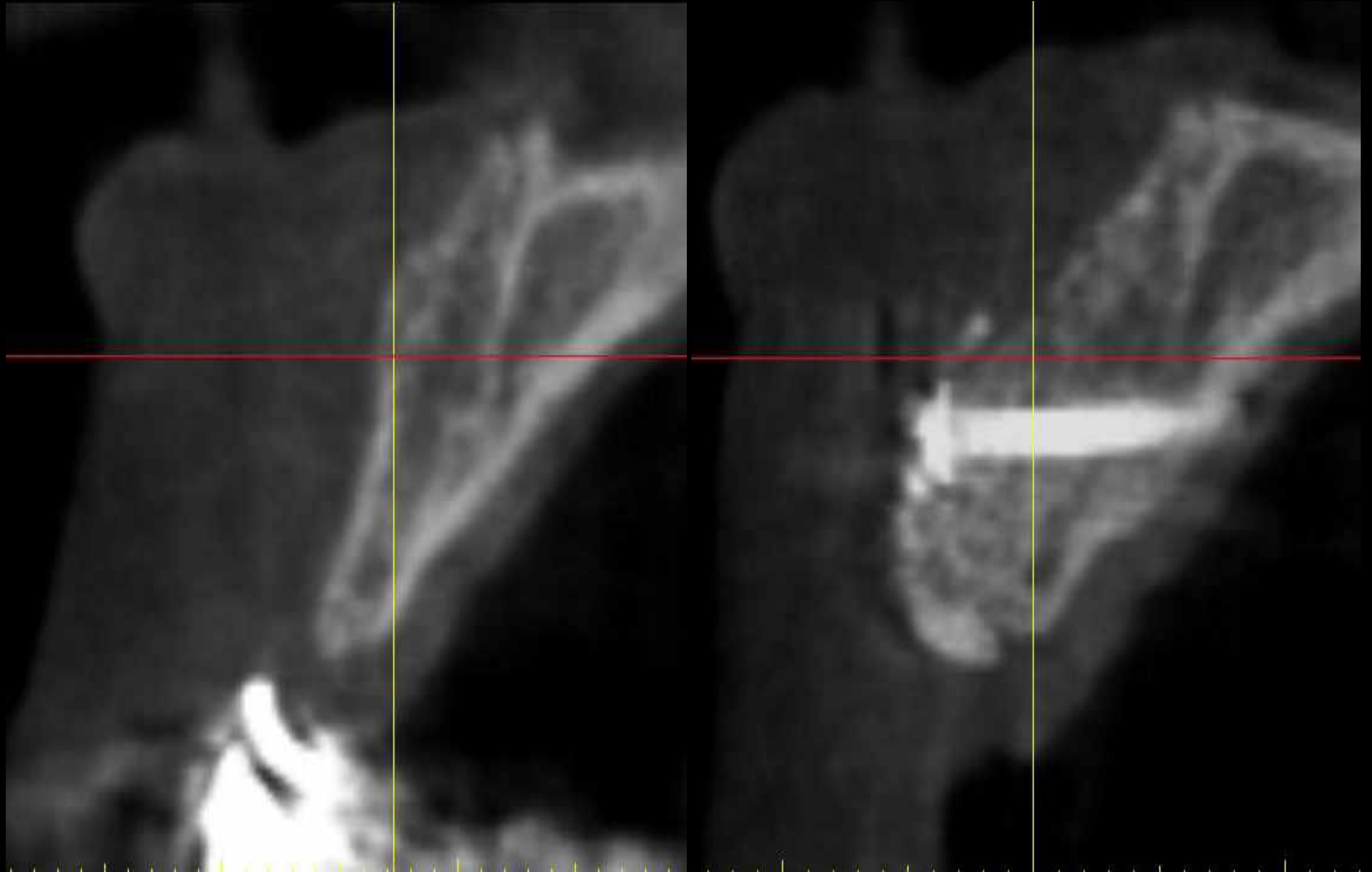


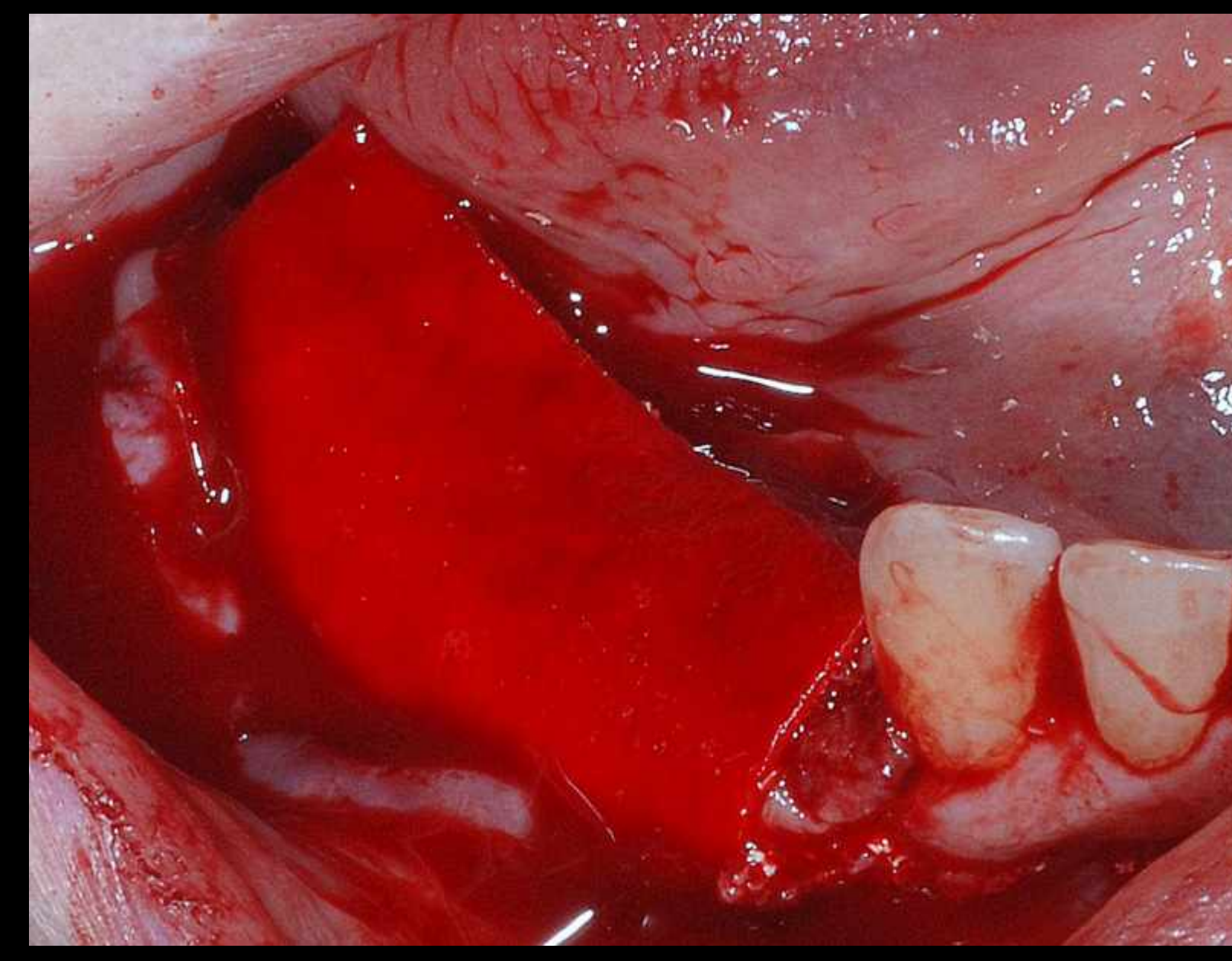
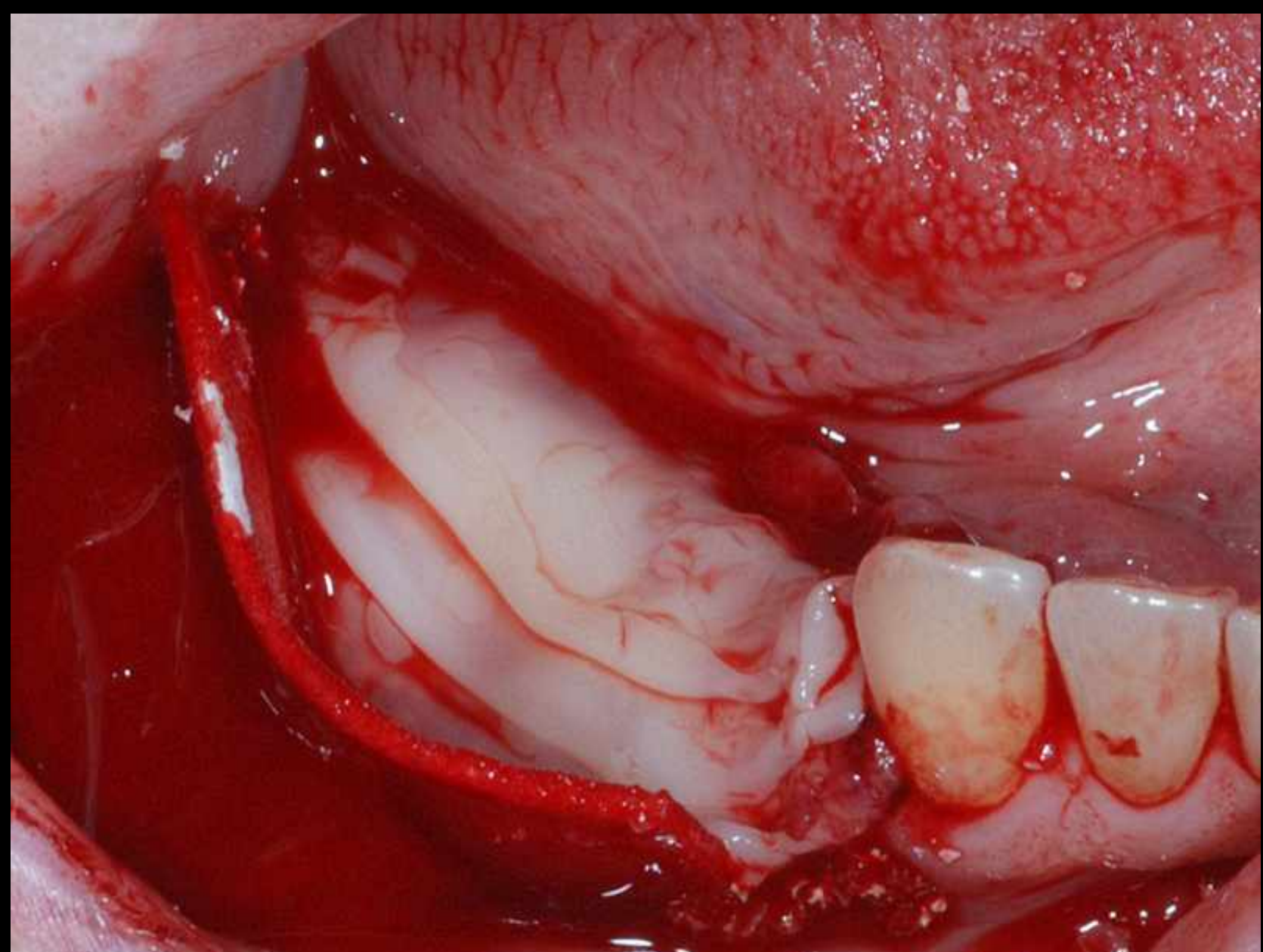
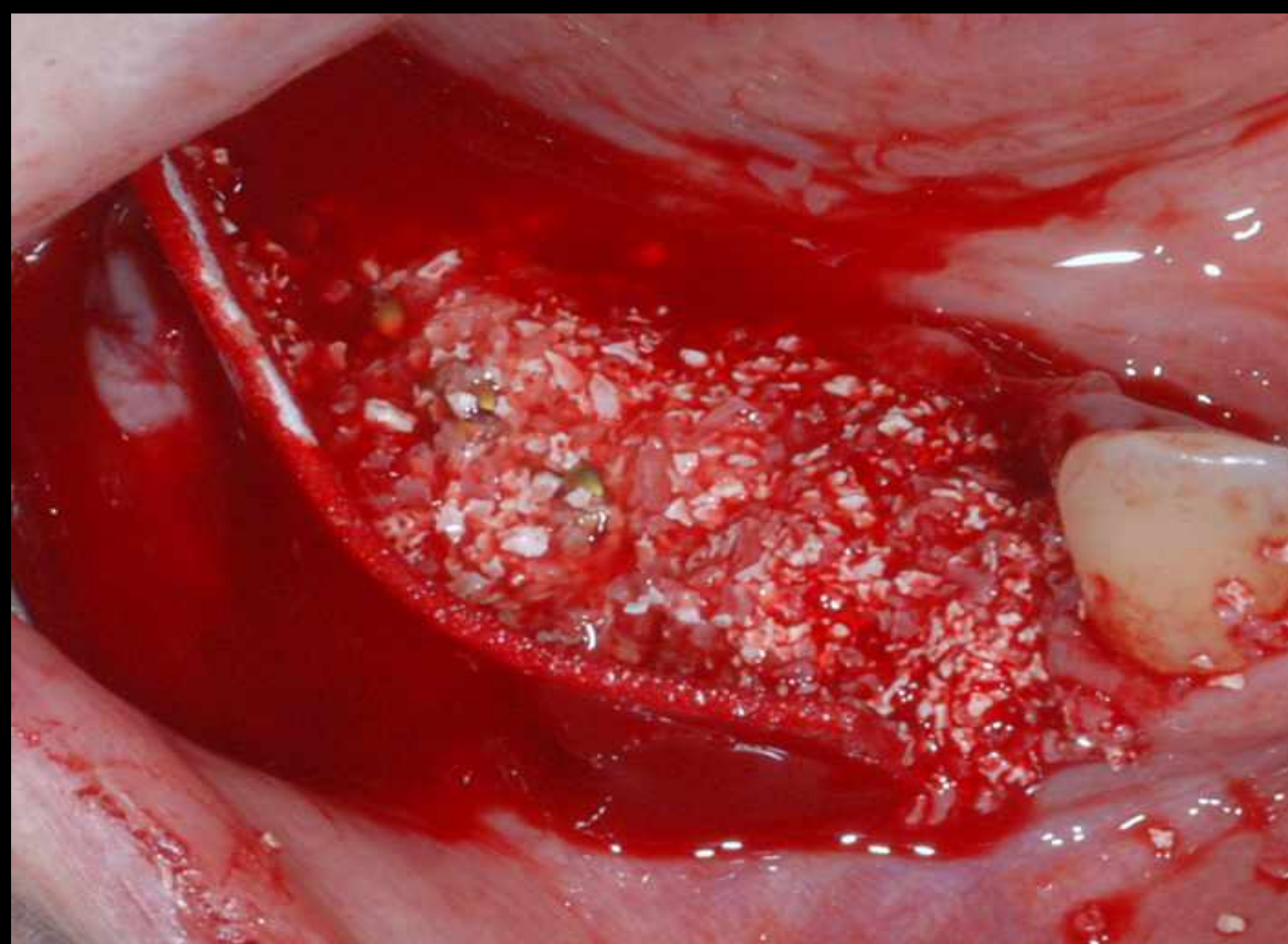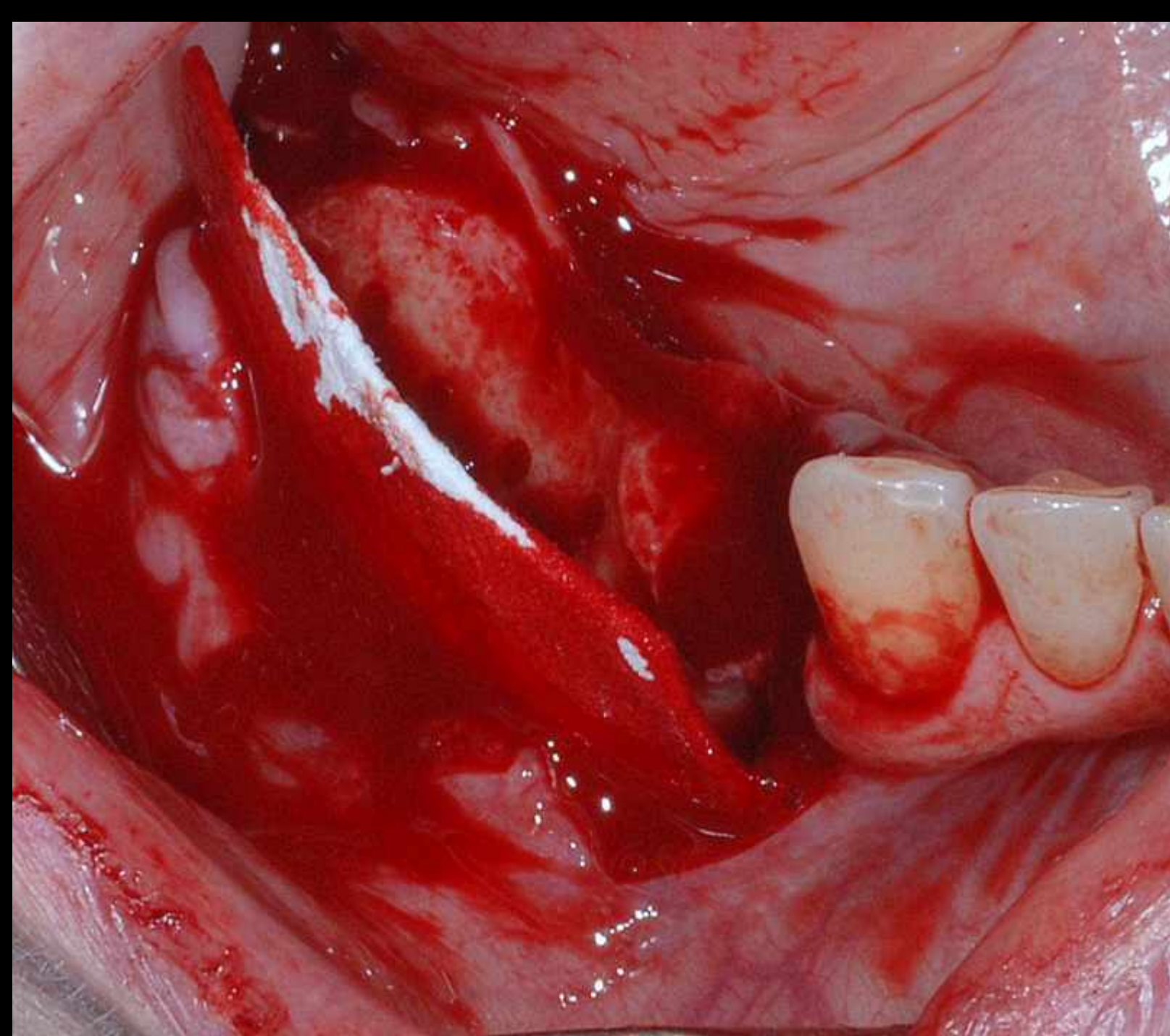
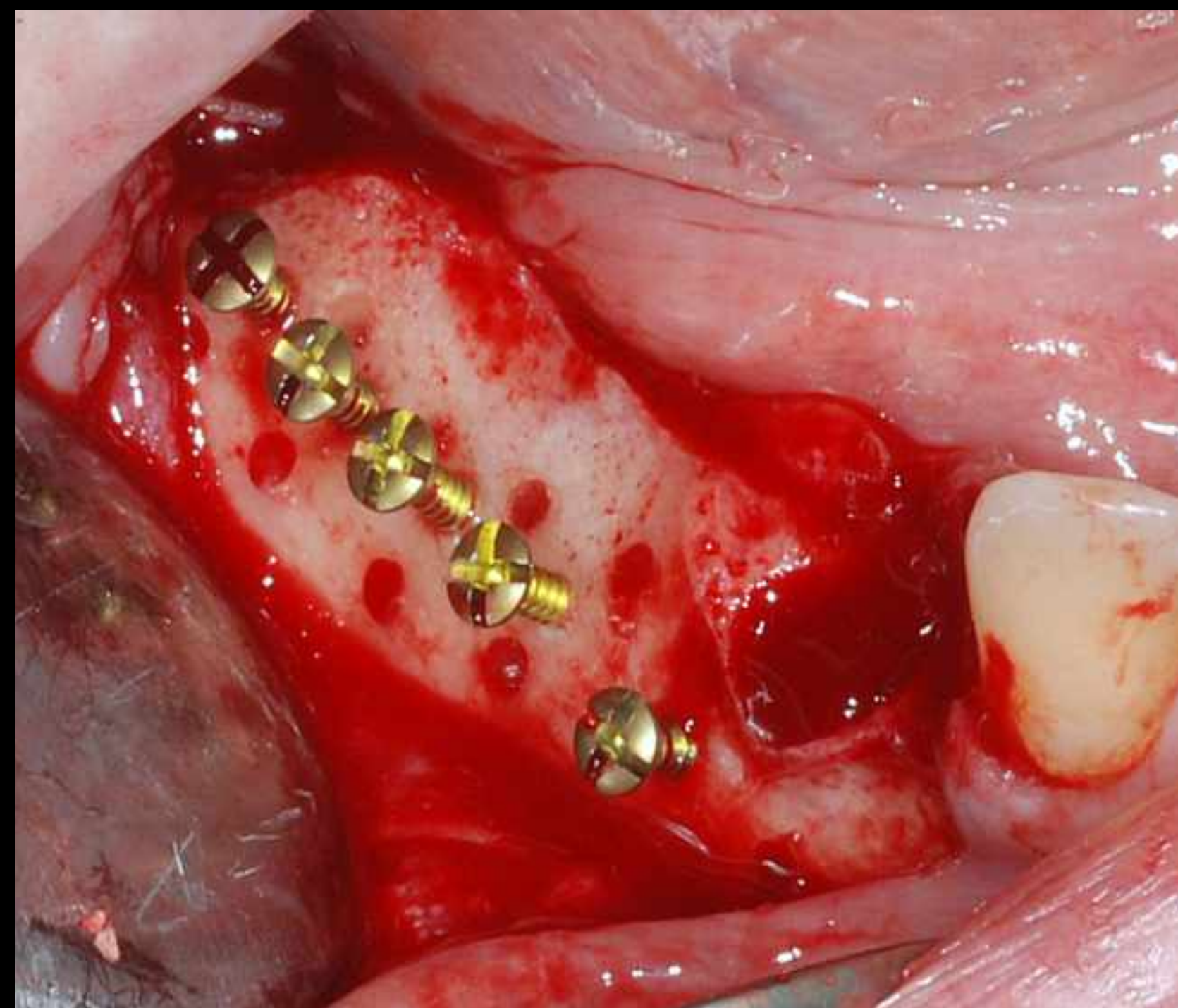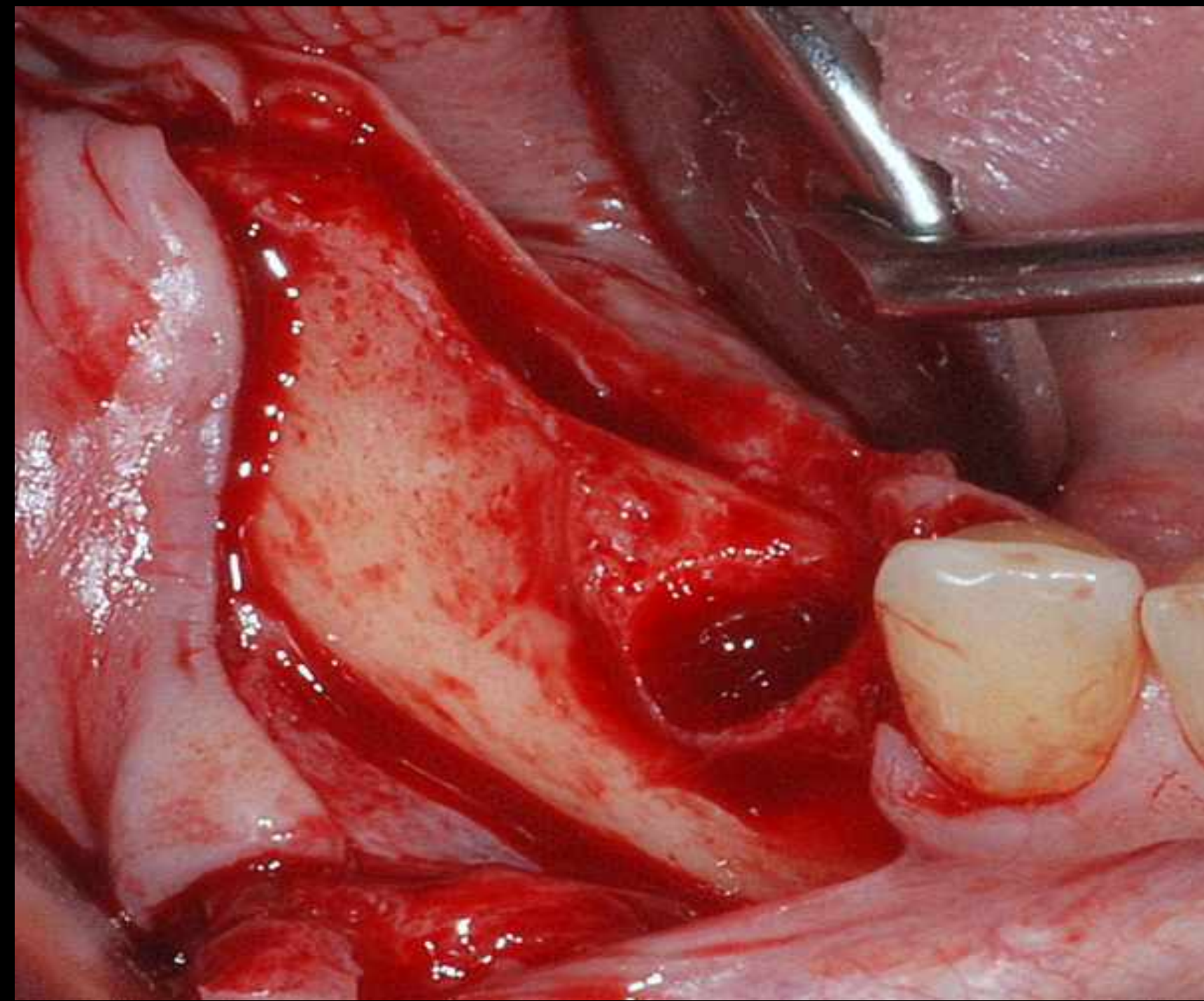




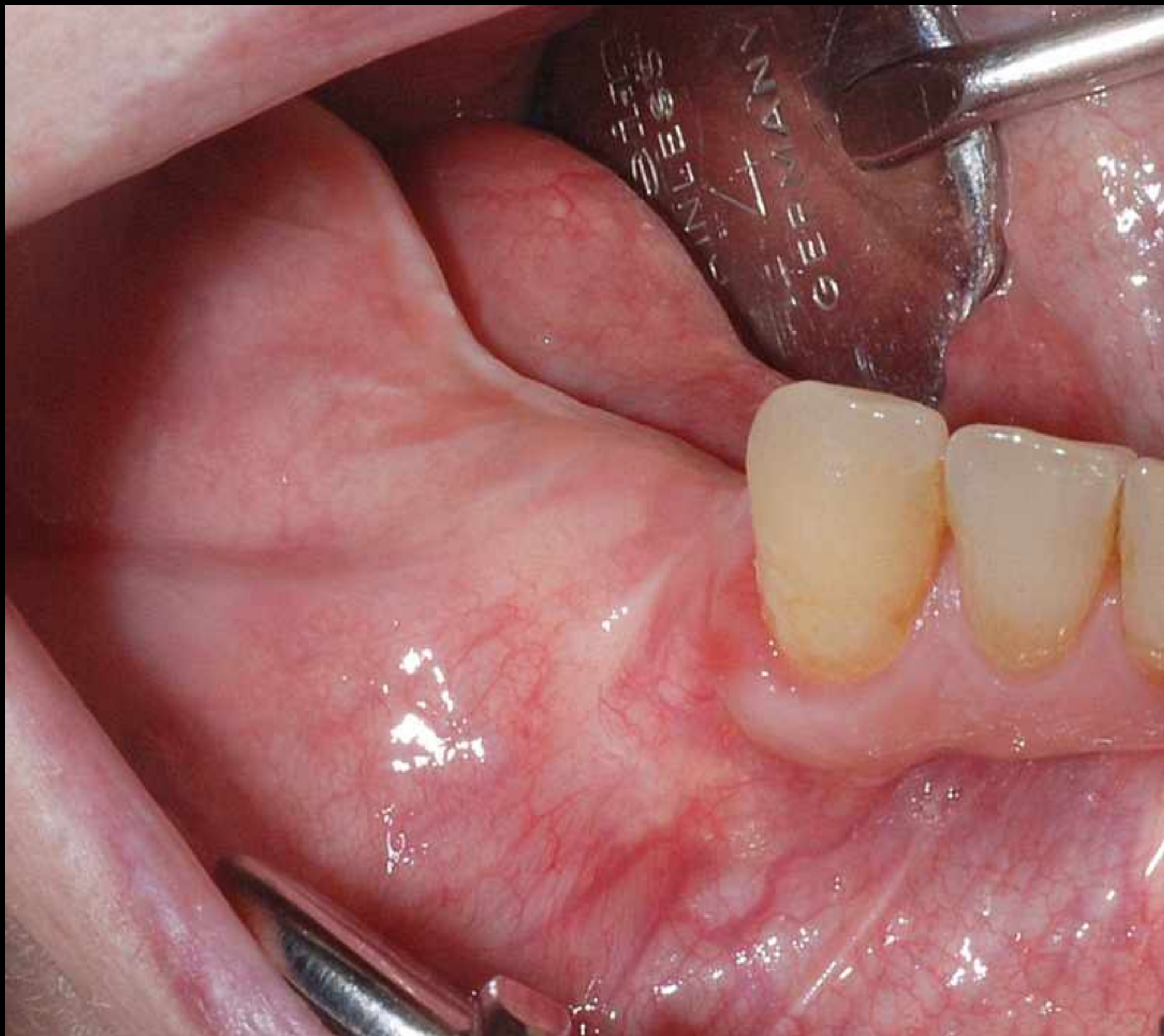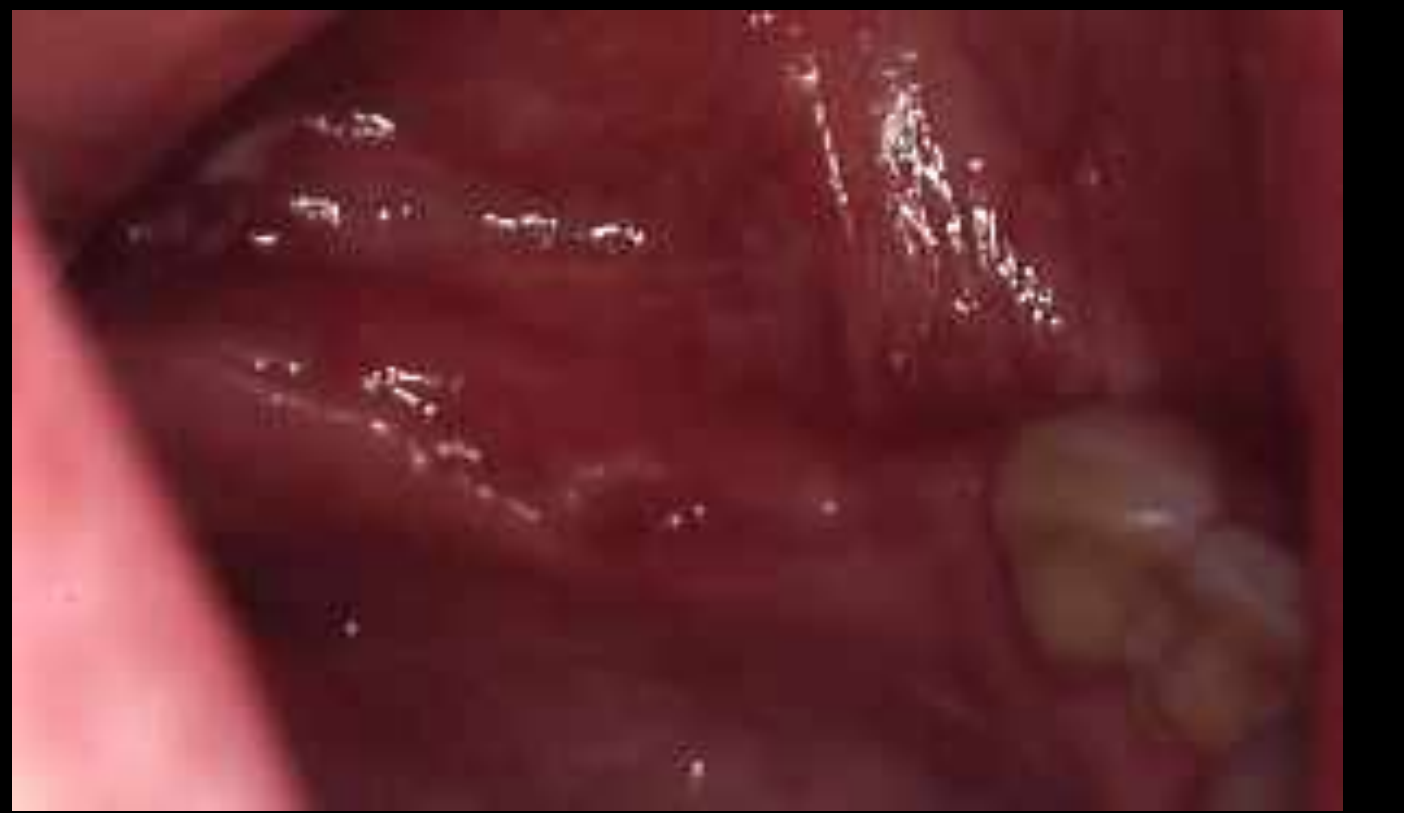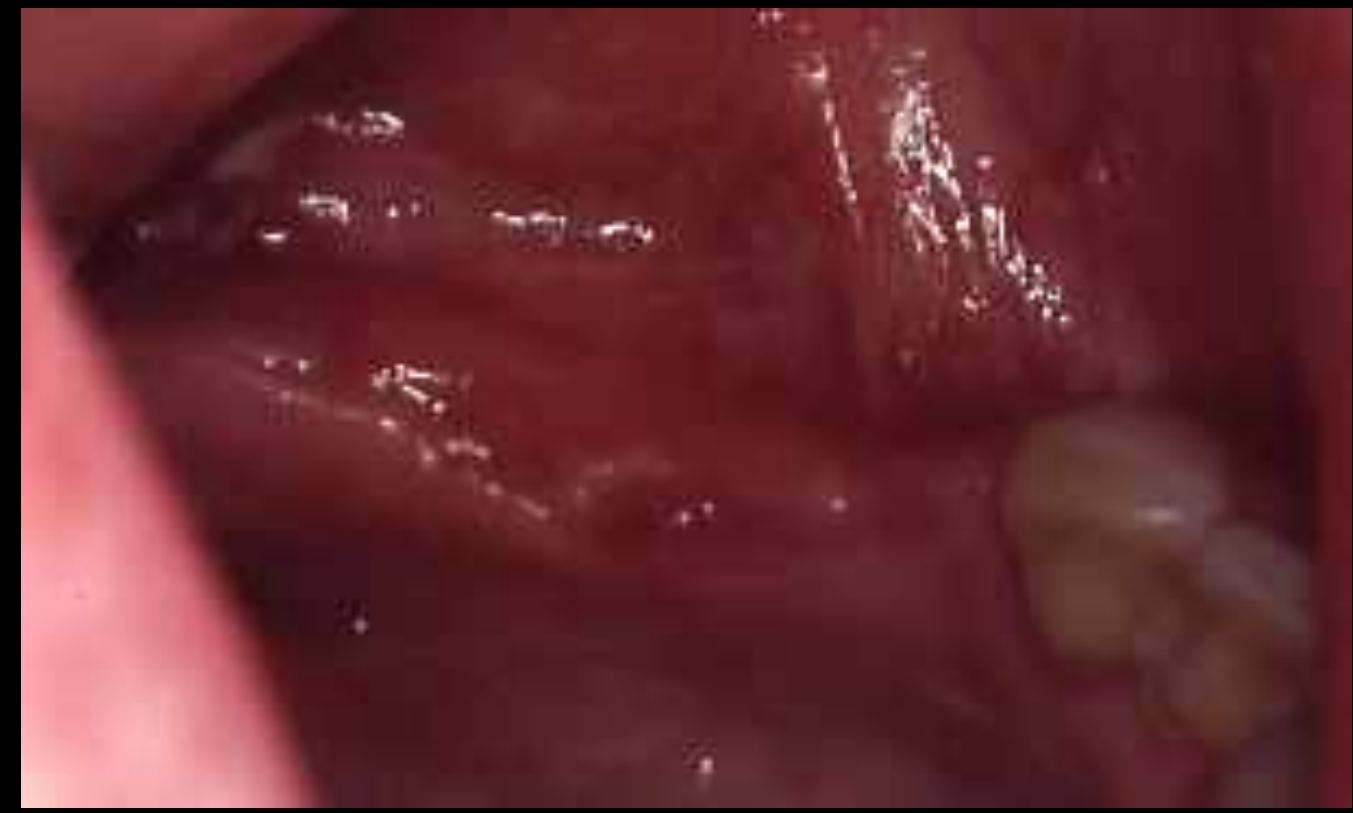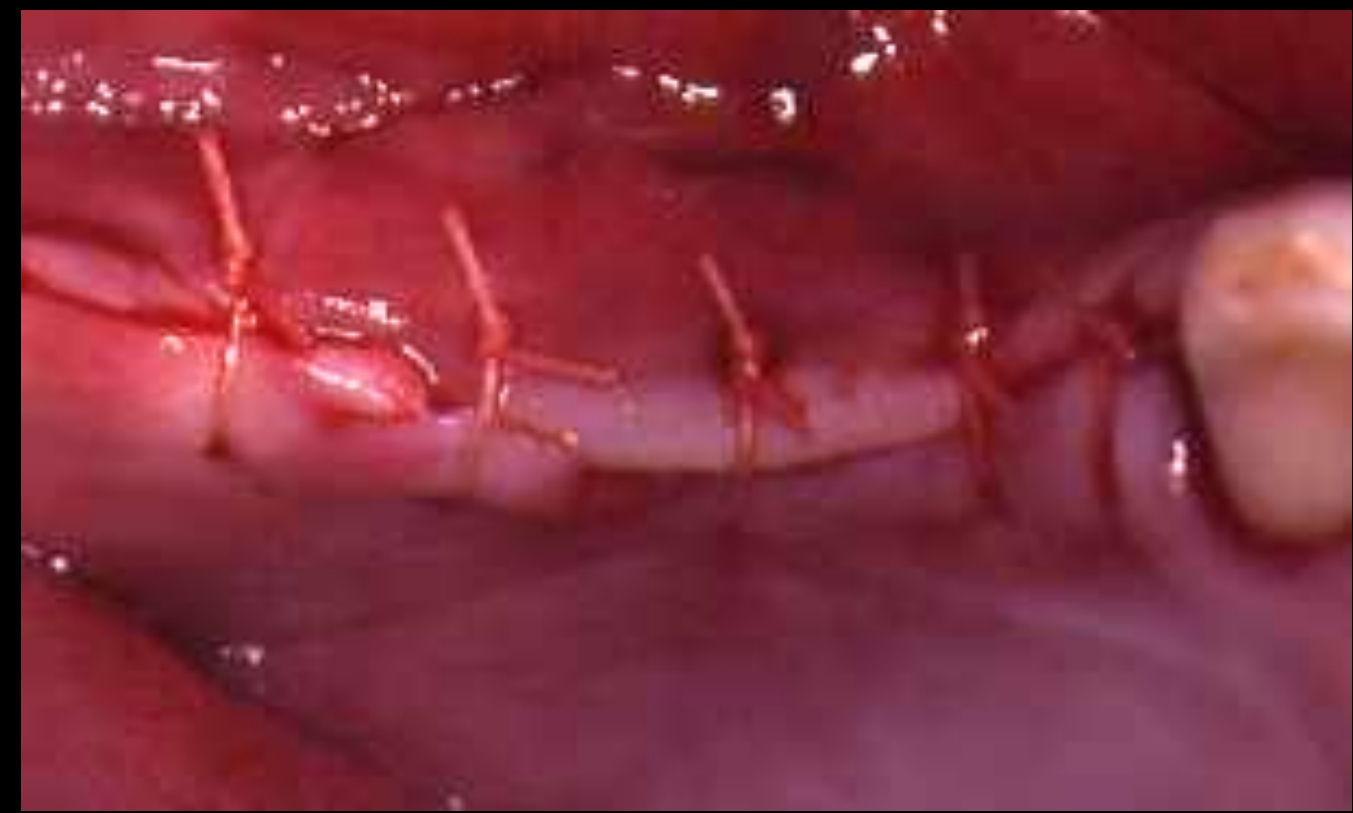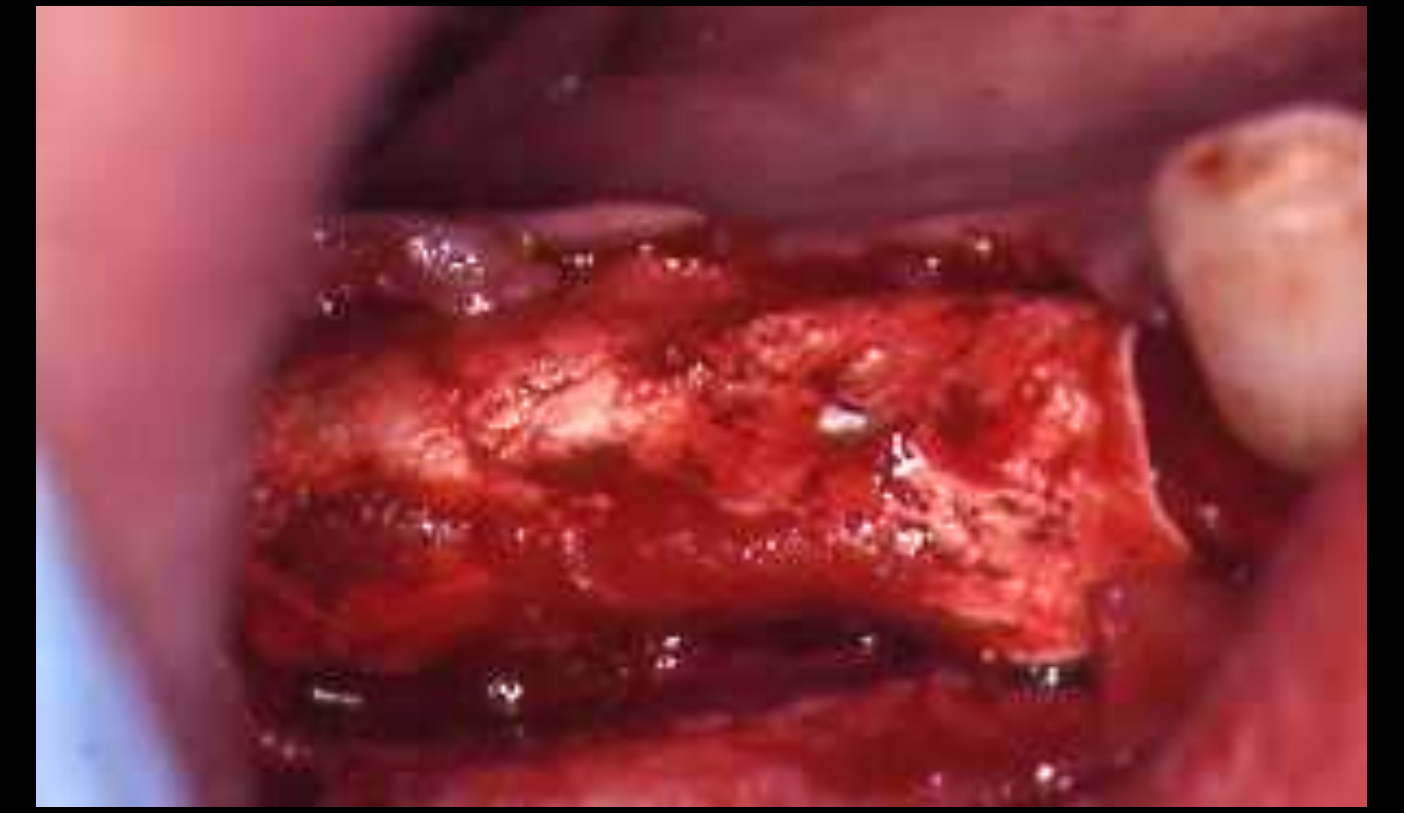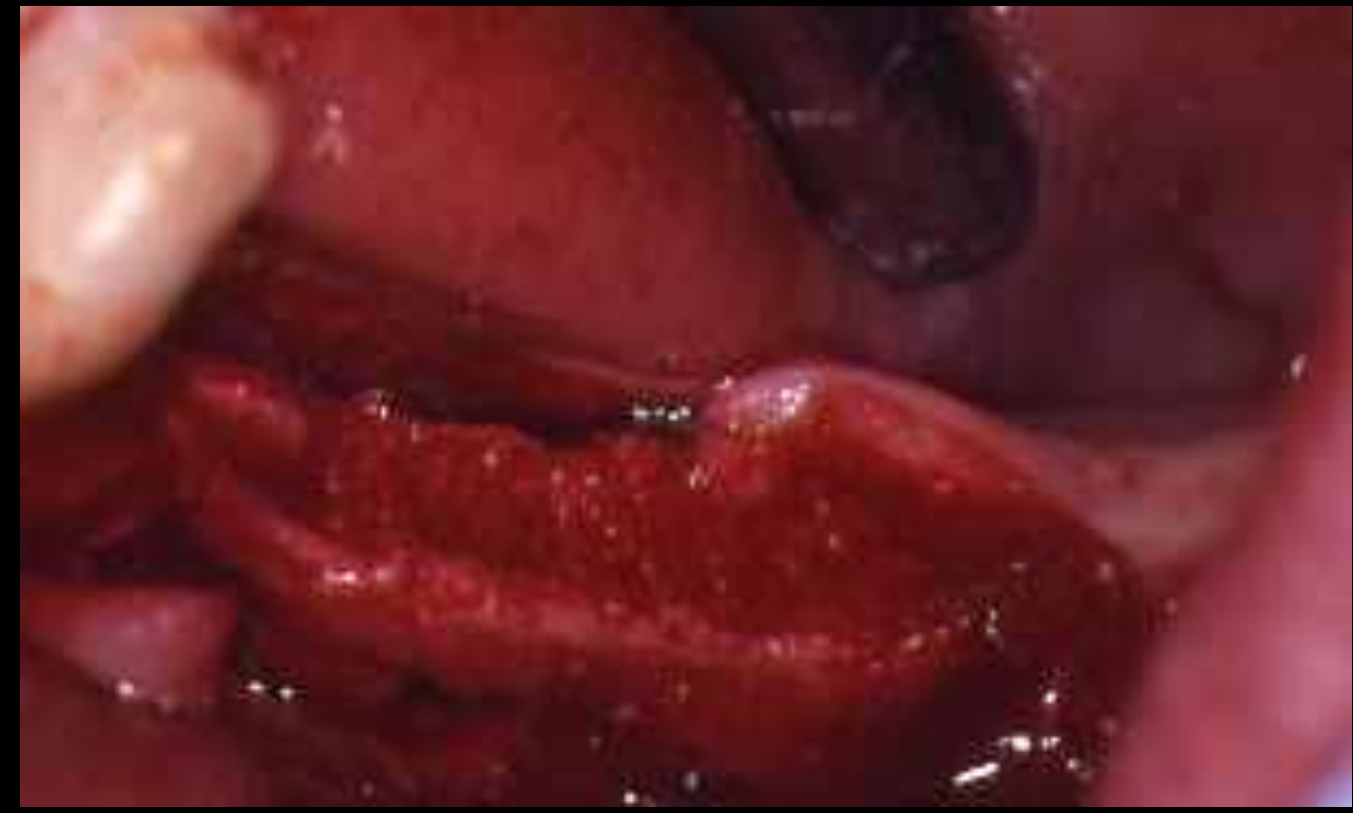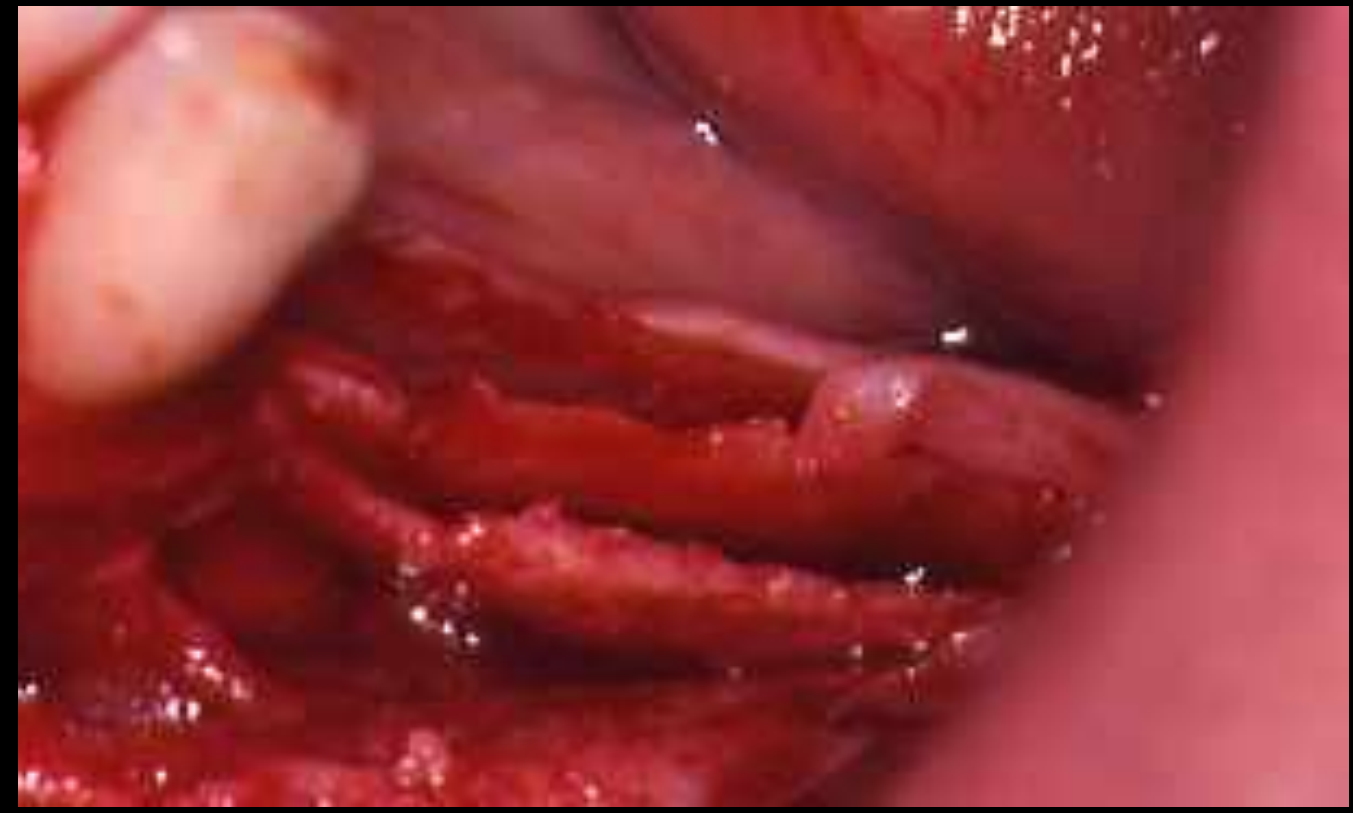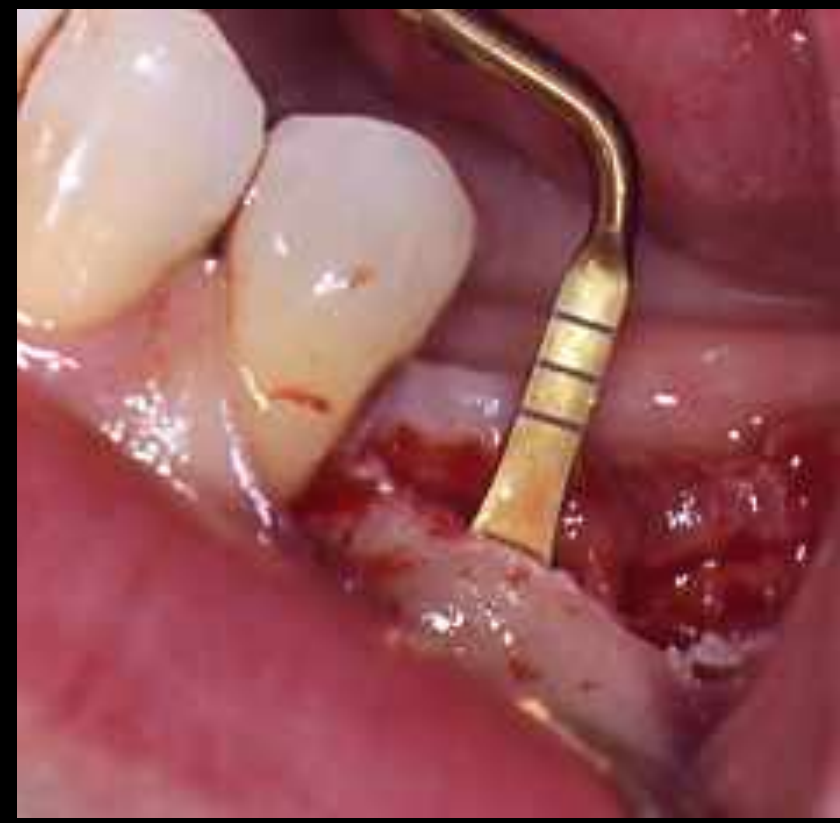


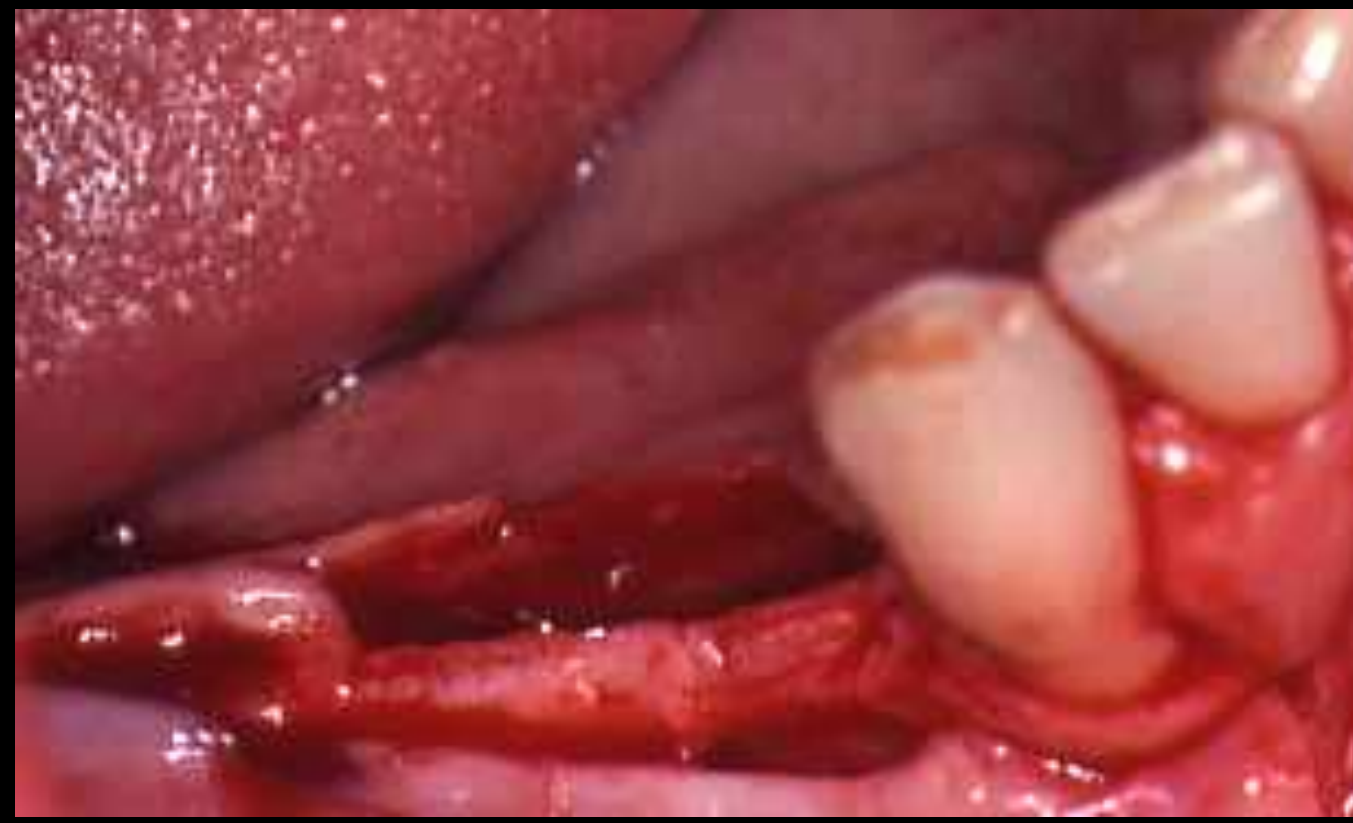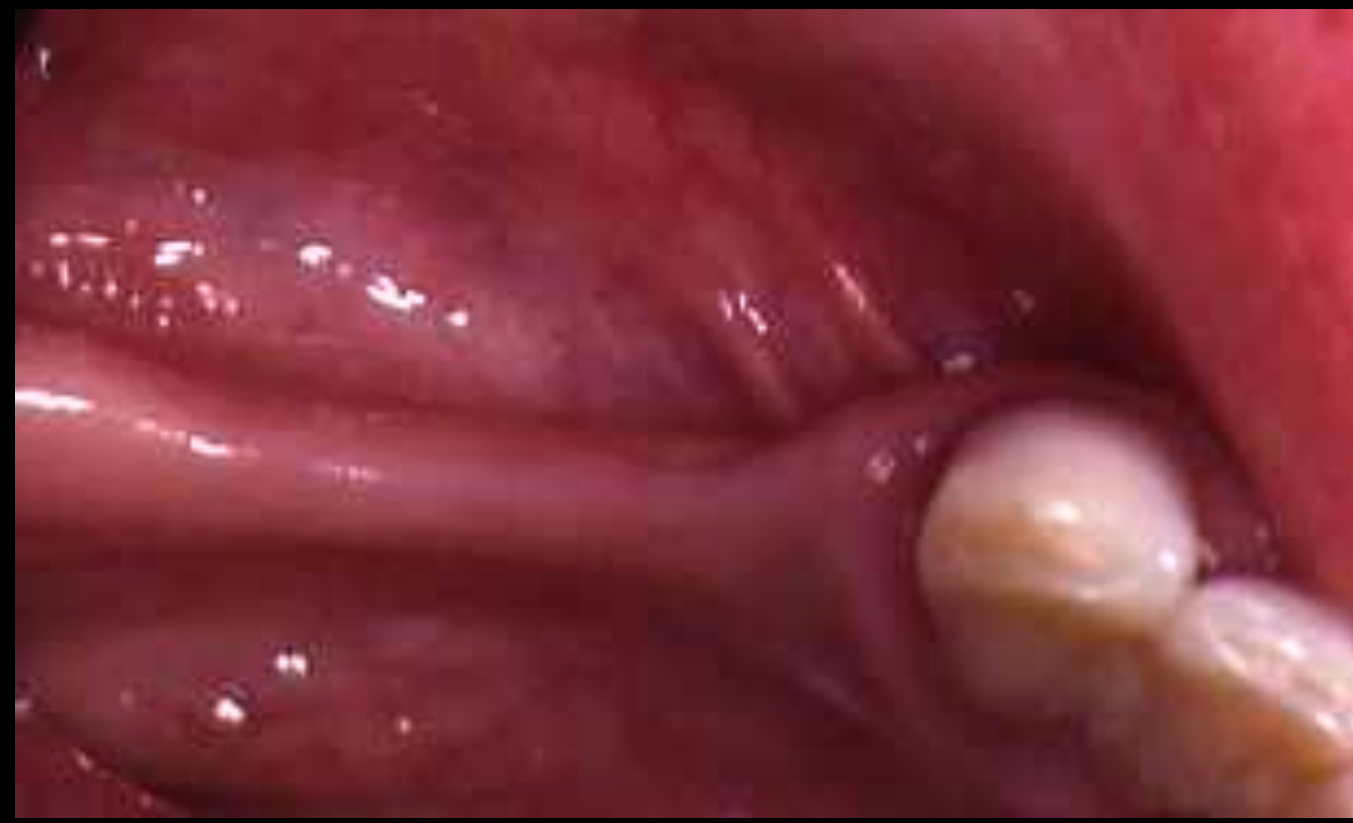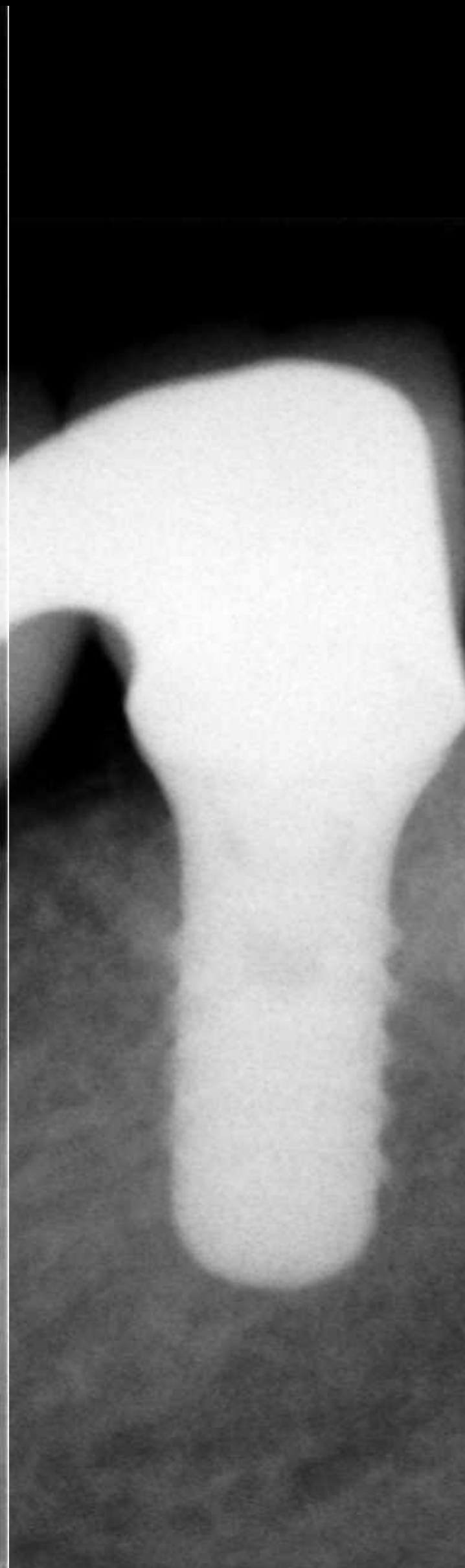














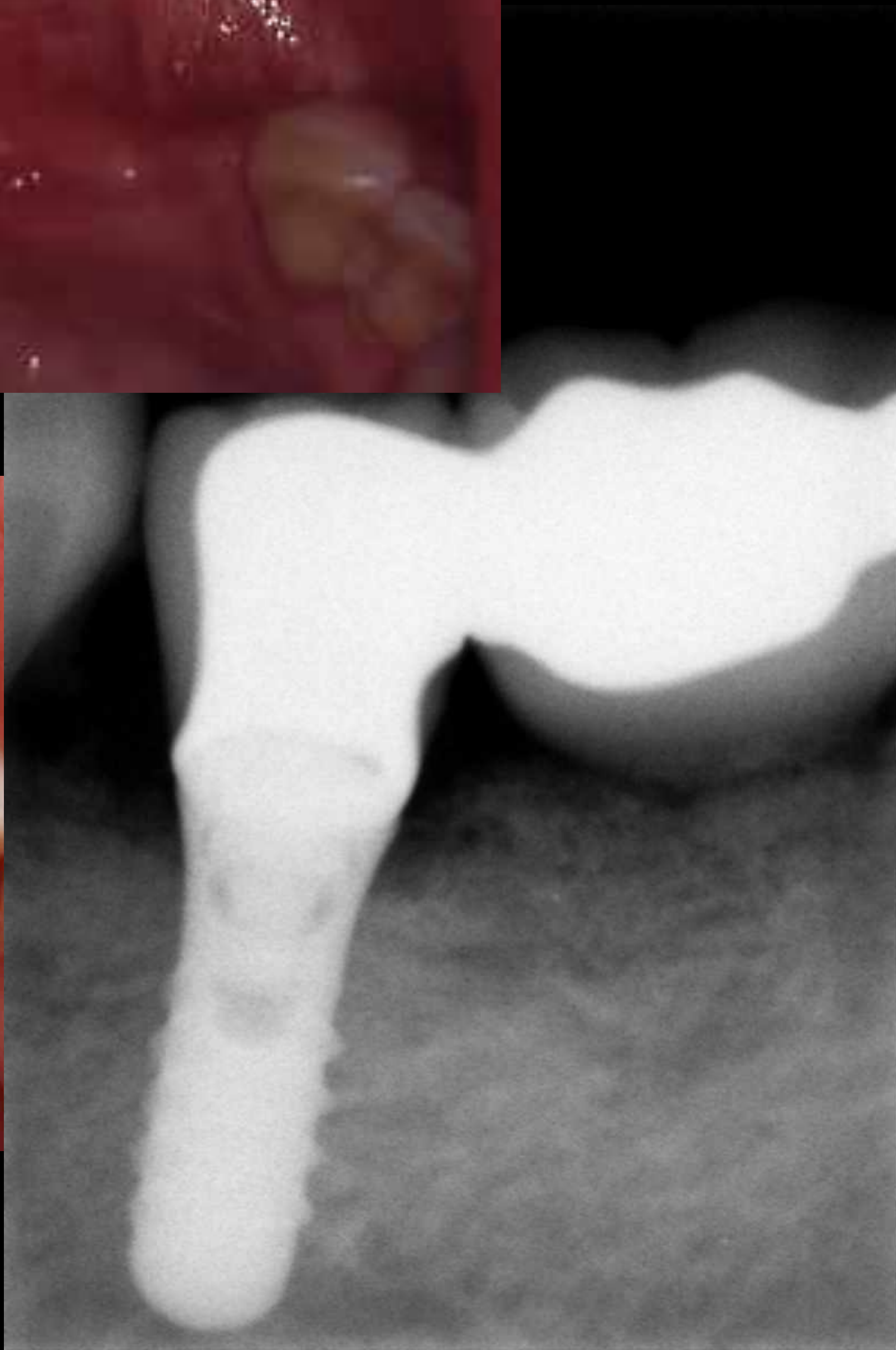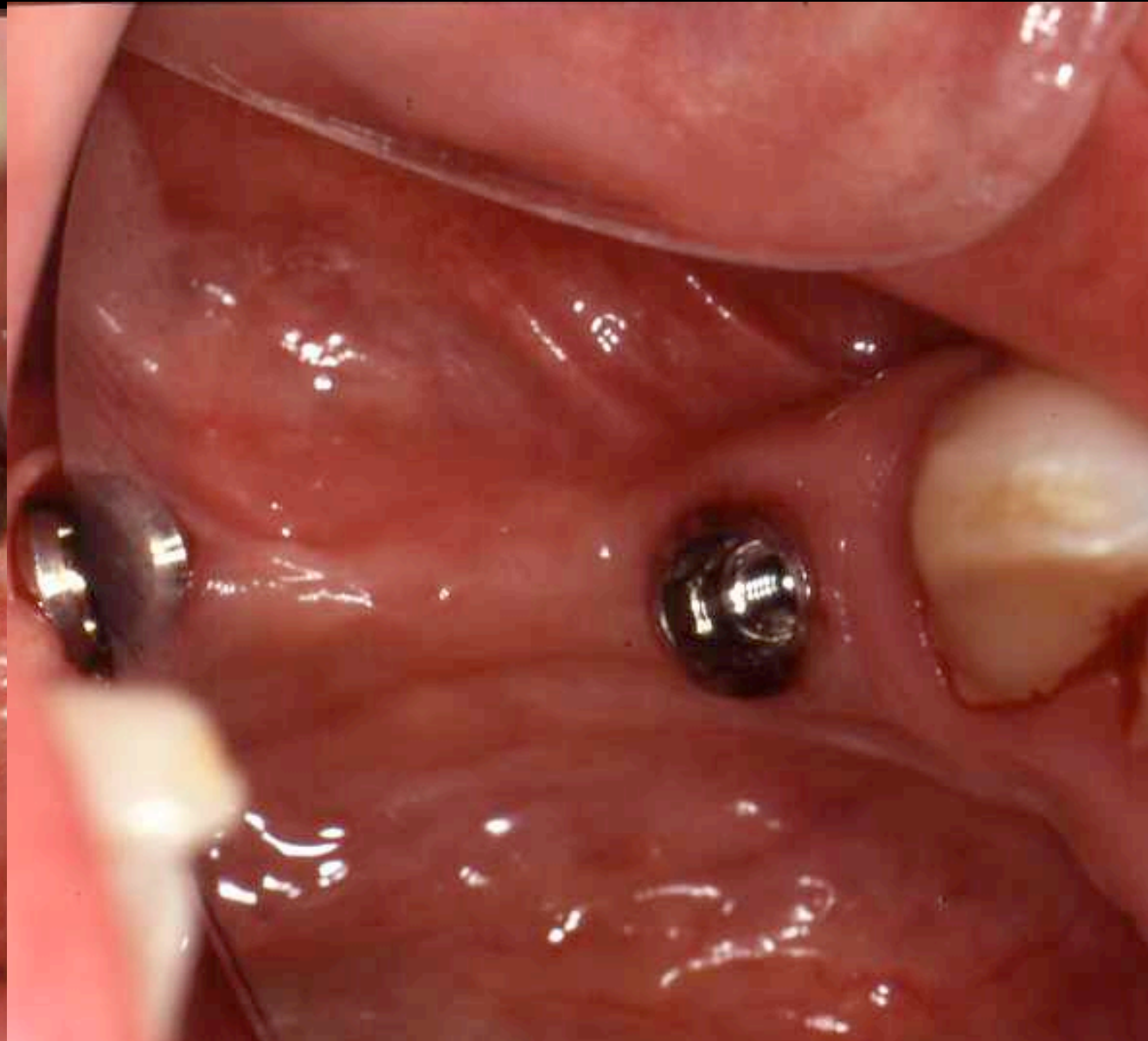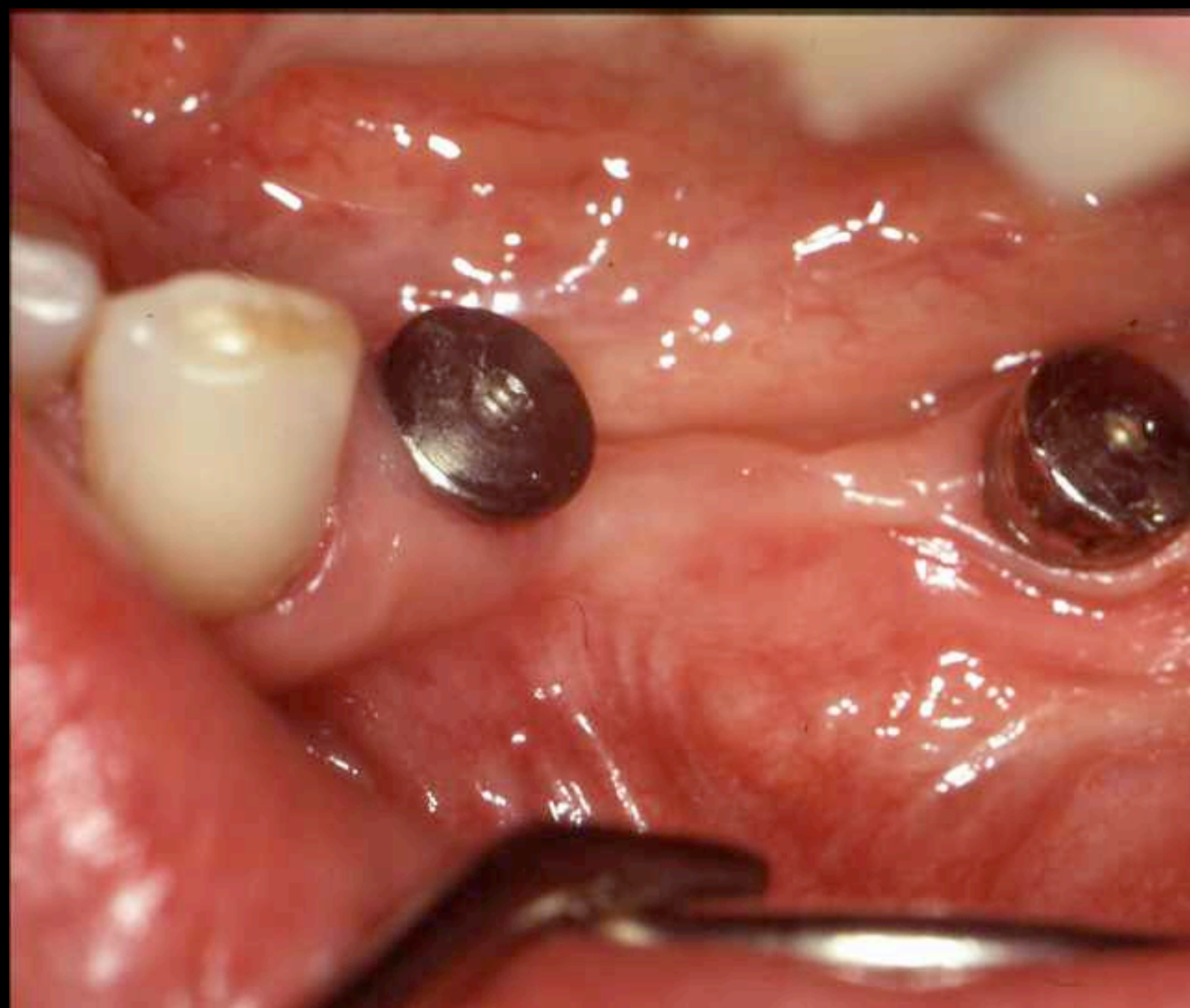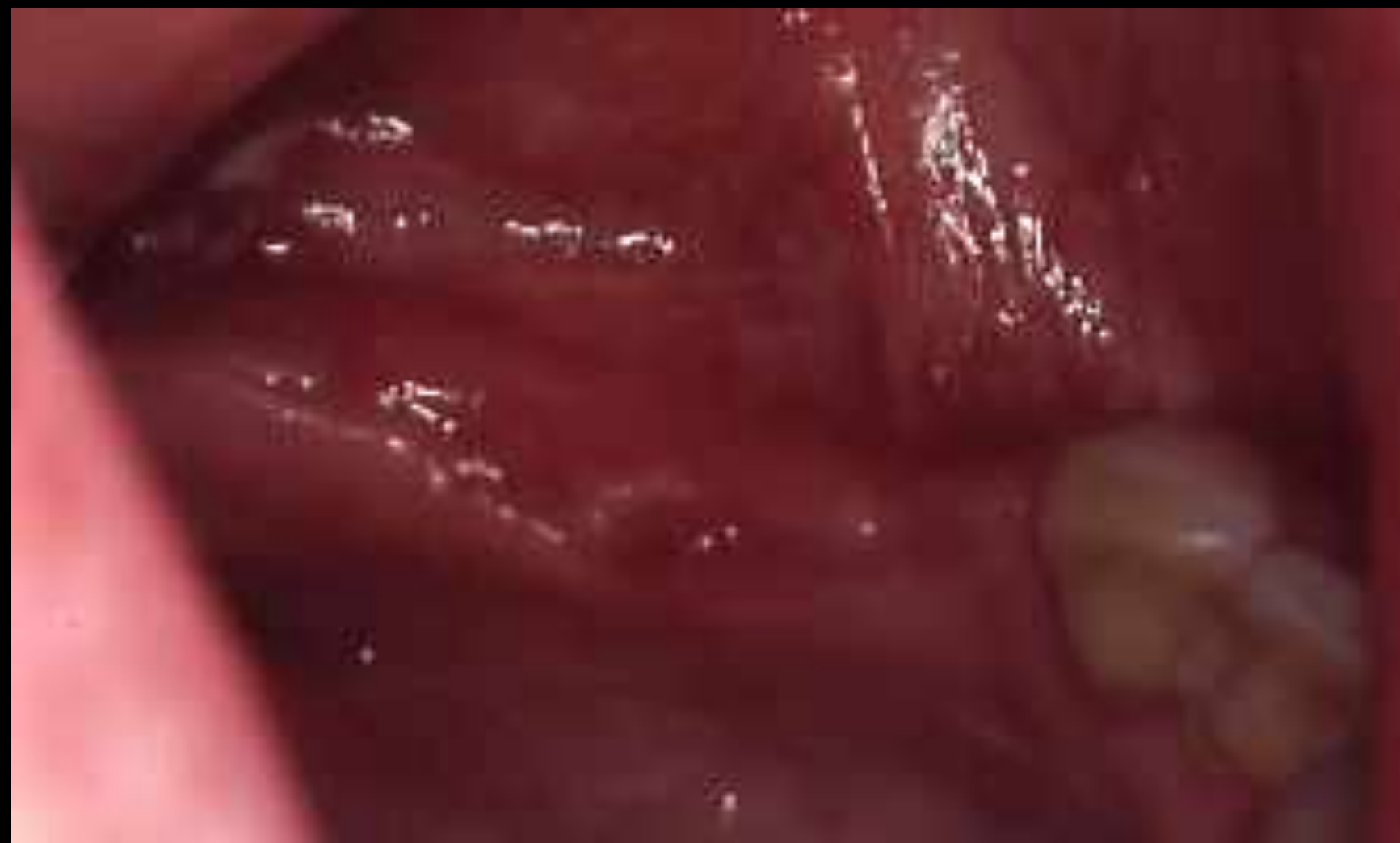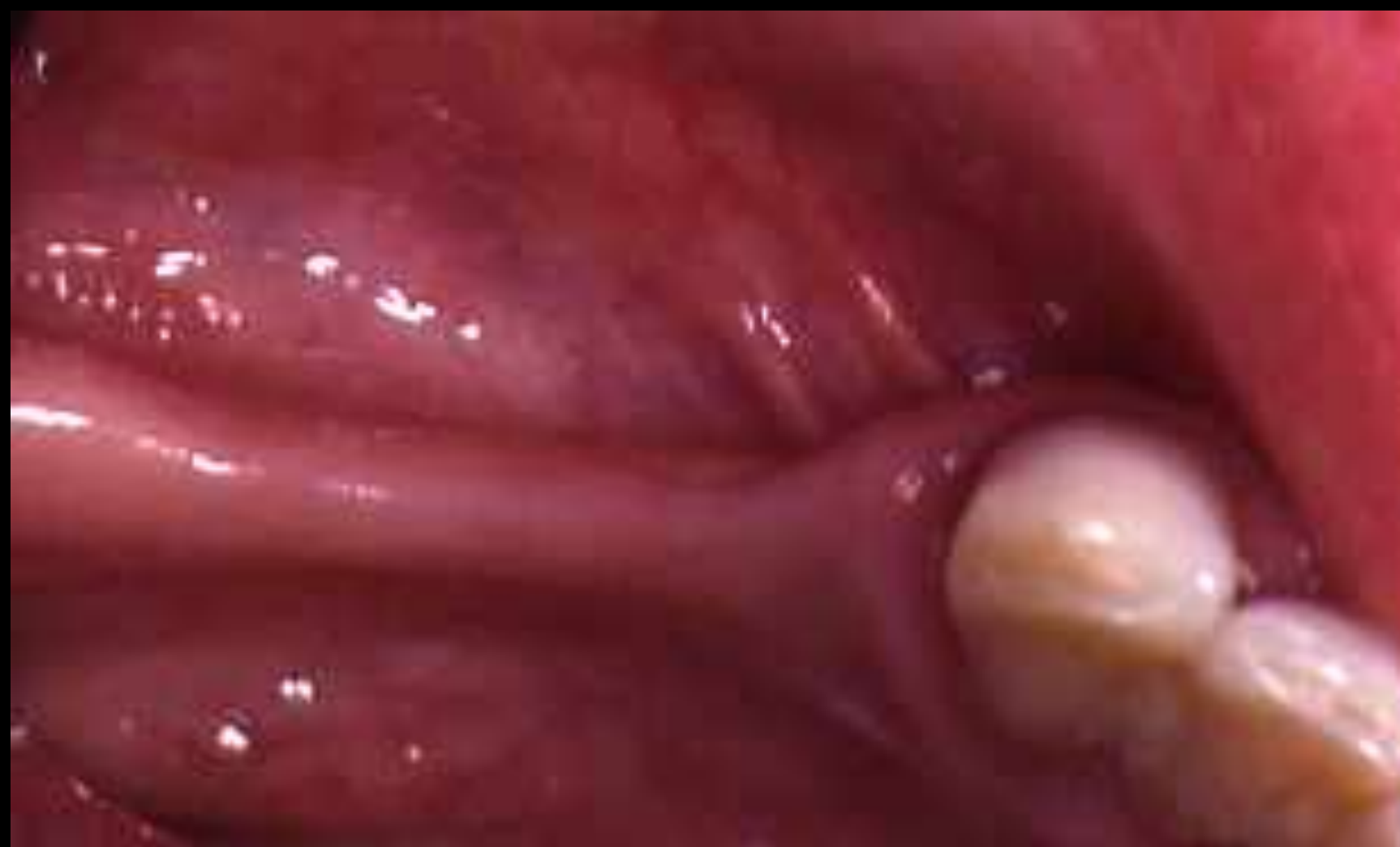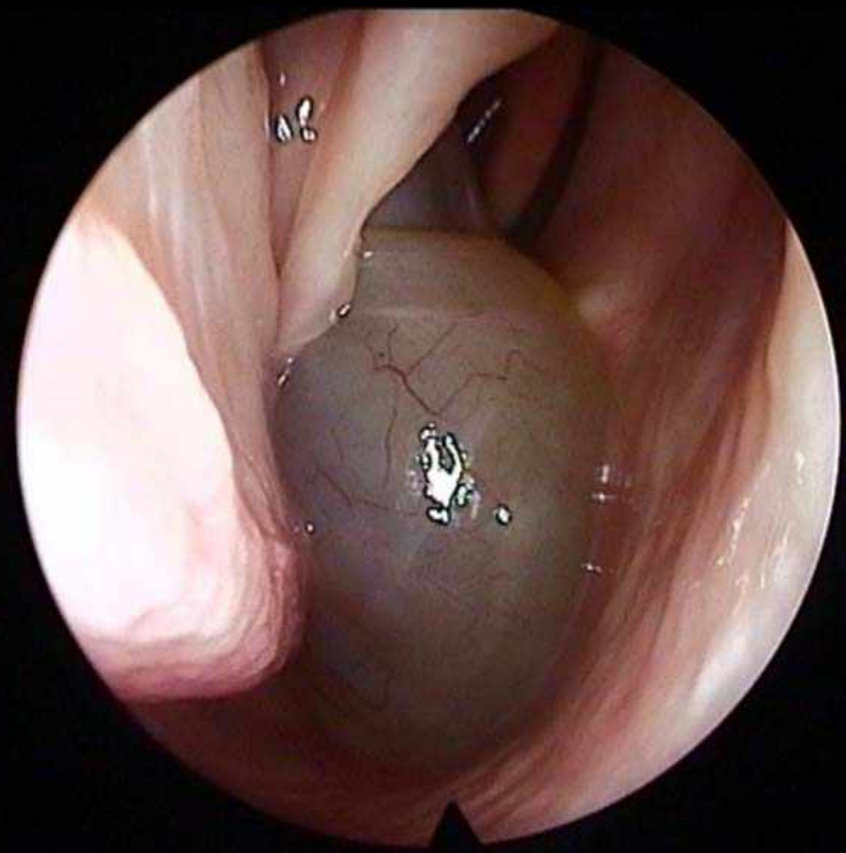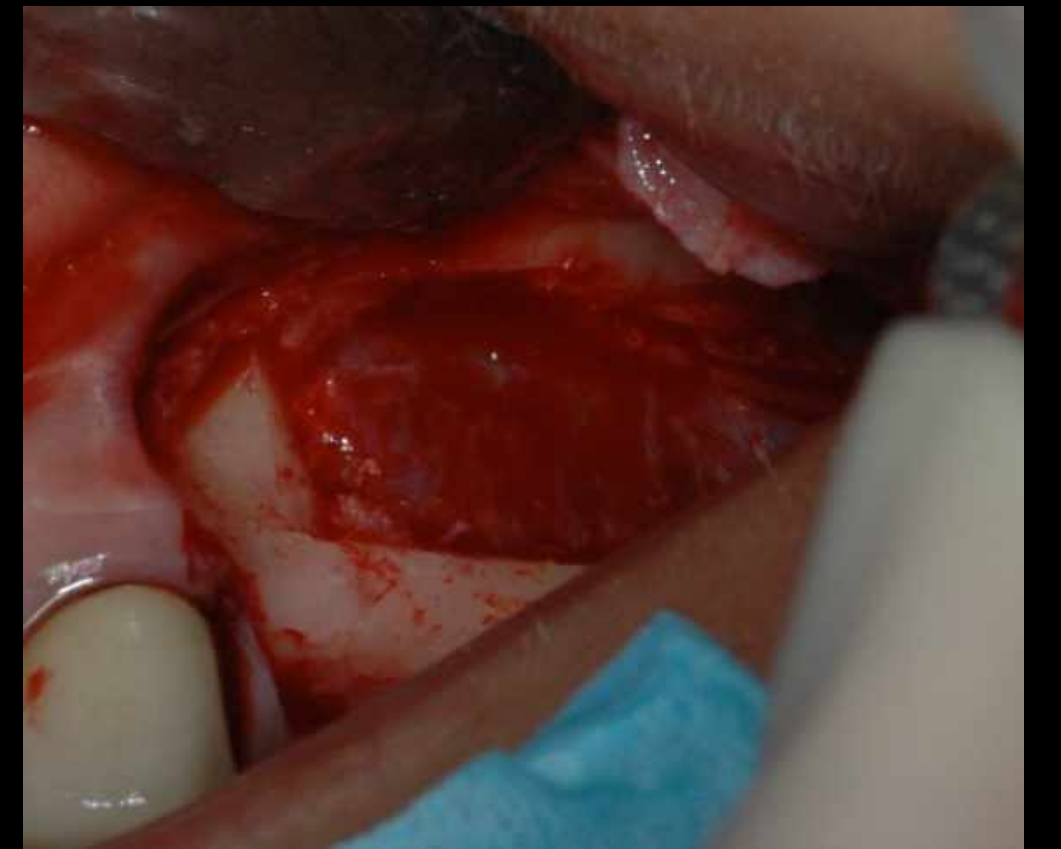Sinus maxillaire

Anatomie

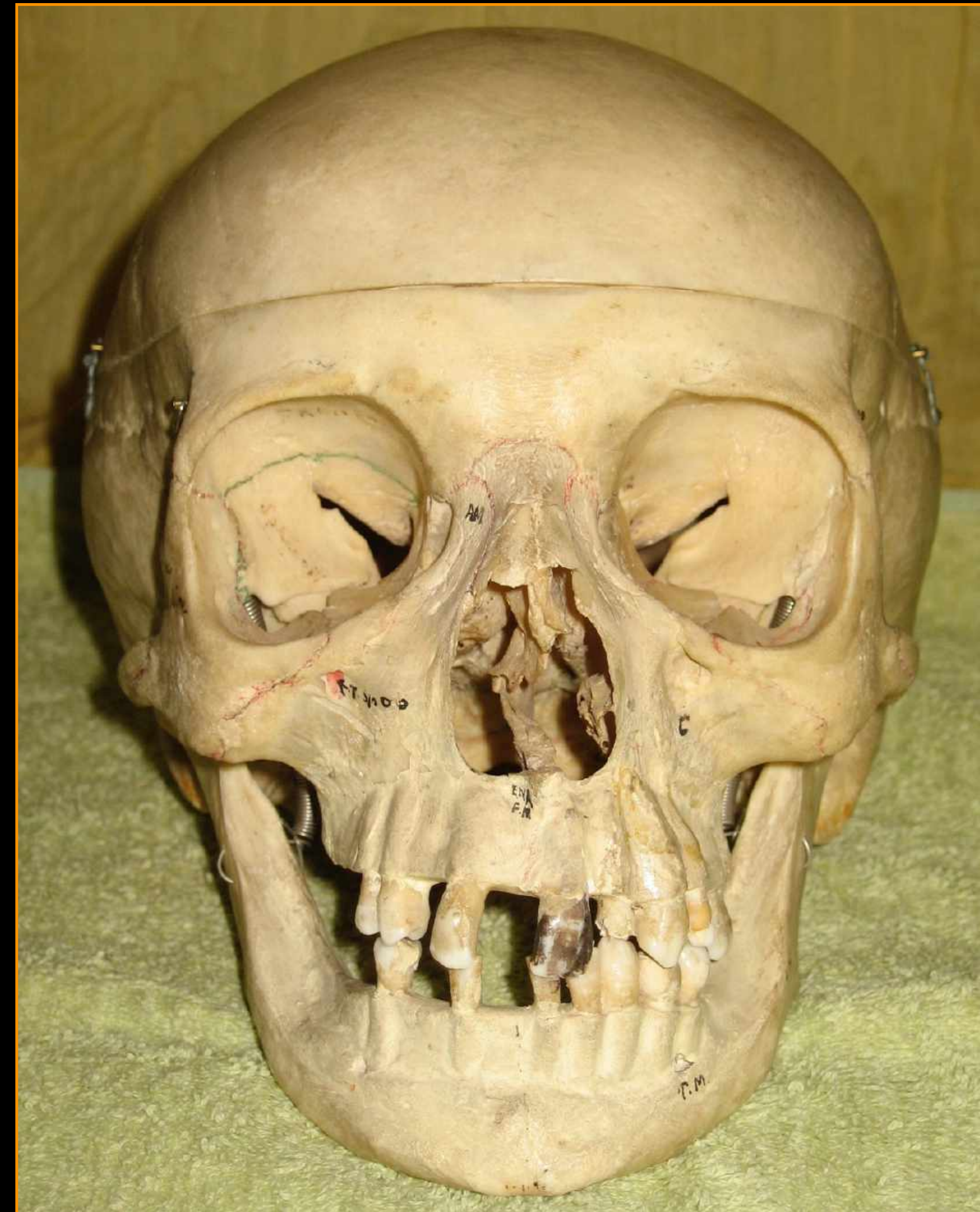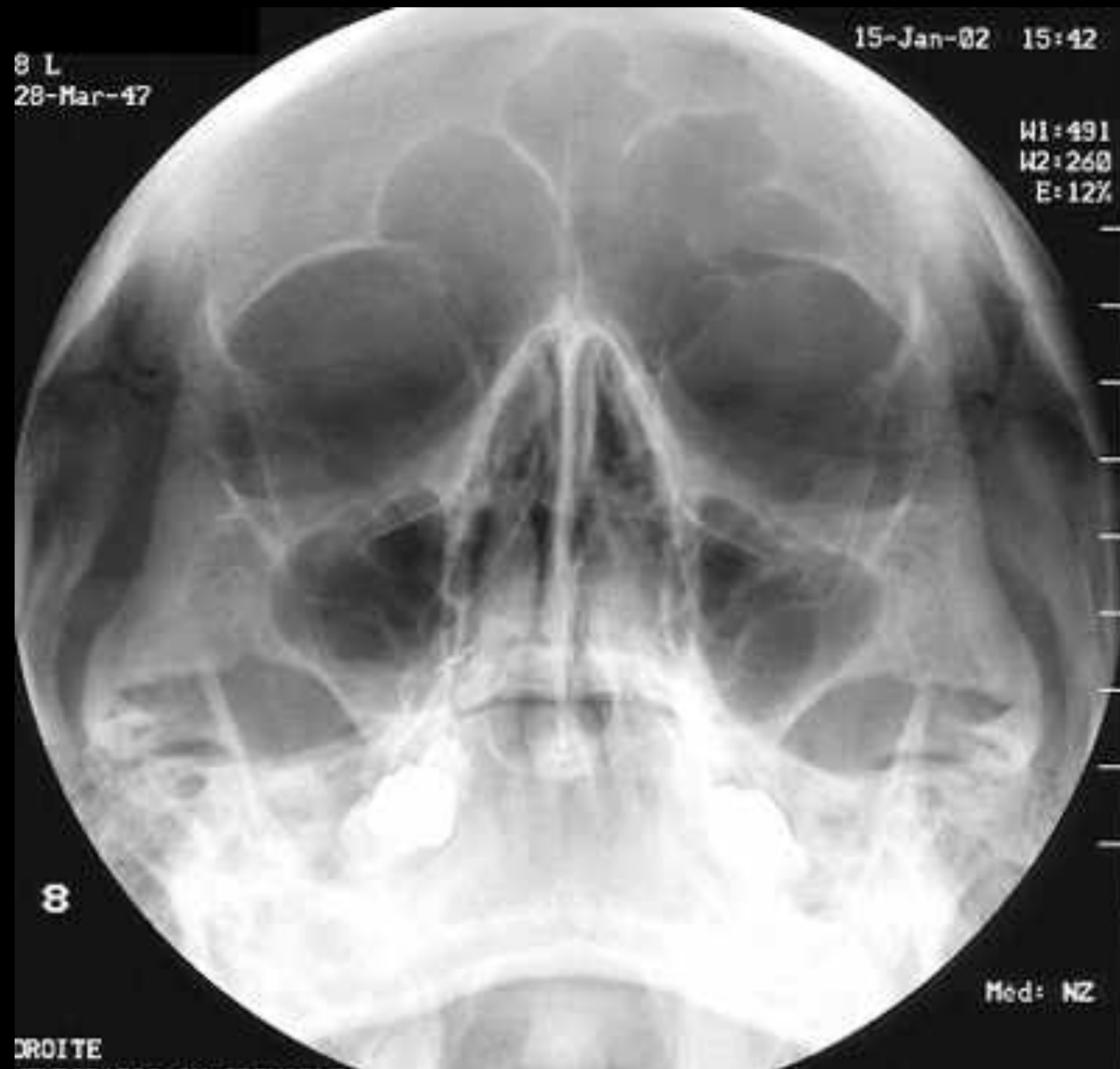Examens cliniques

Examens radiologiques

Pathologies et traitements

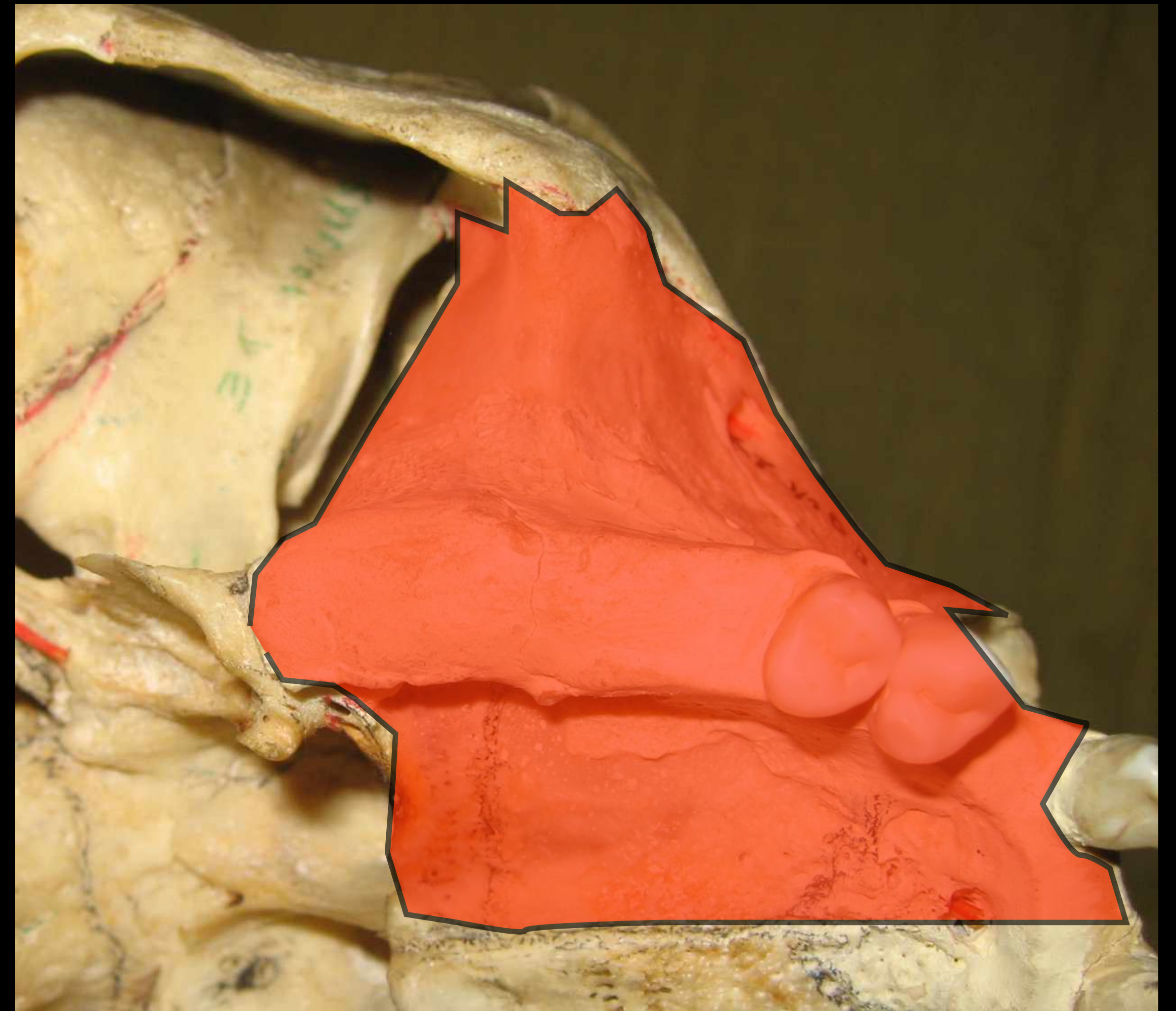
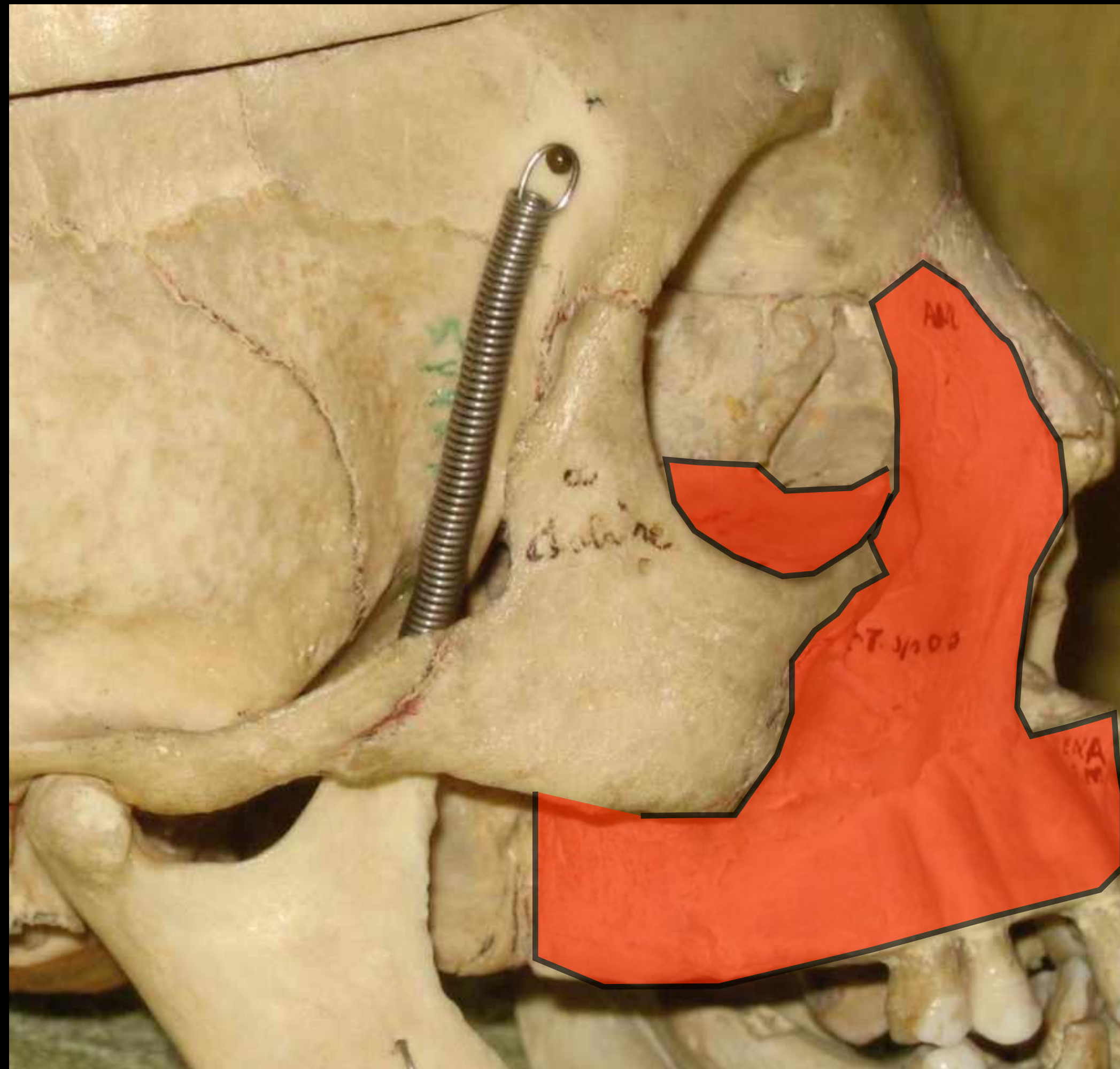


- GREFFE DU SINUS



- GREFFE DU SINUS

L'os maxillaire



GREFFE DU SINUS

Rapports anatomiques

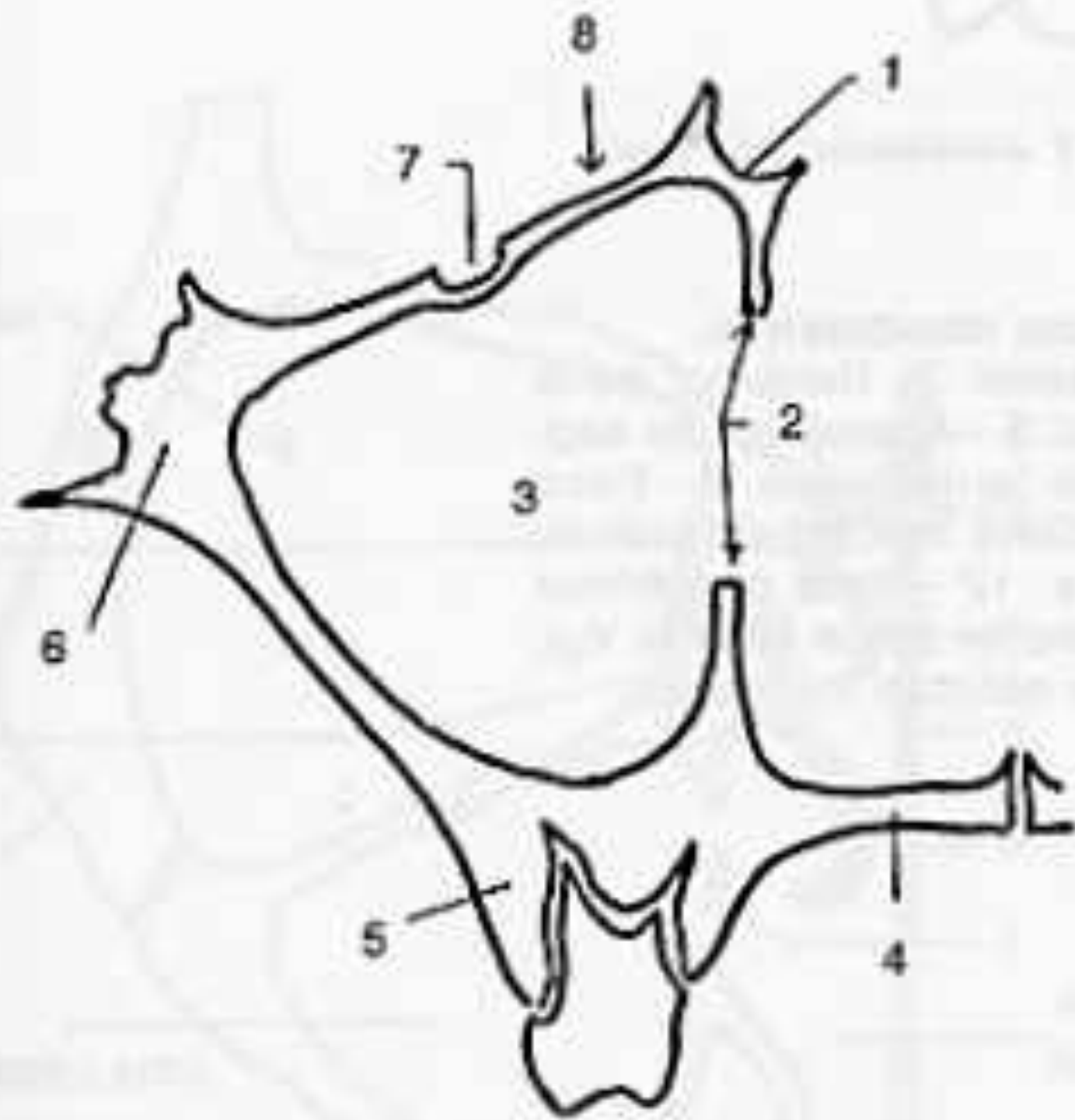
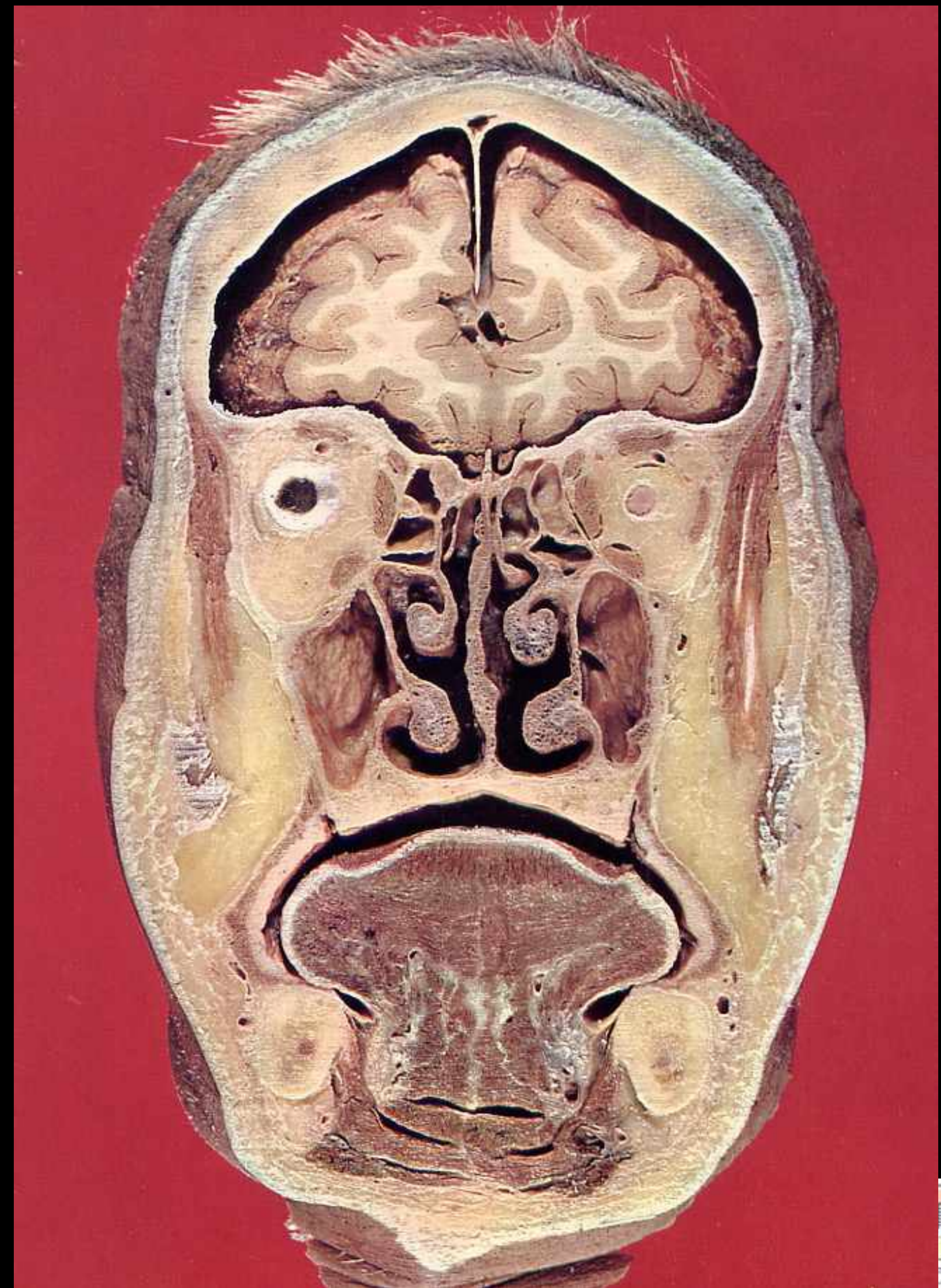


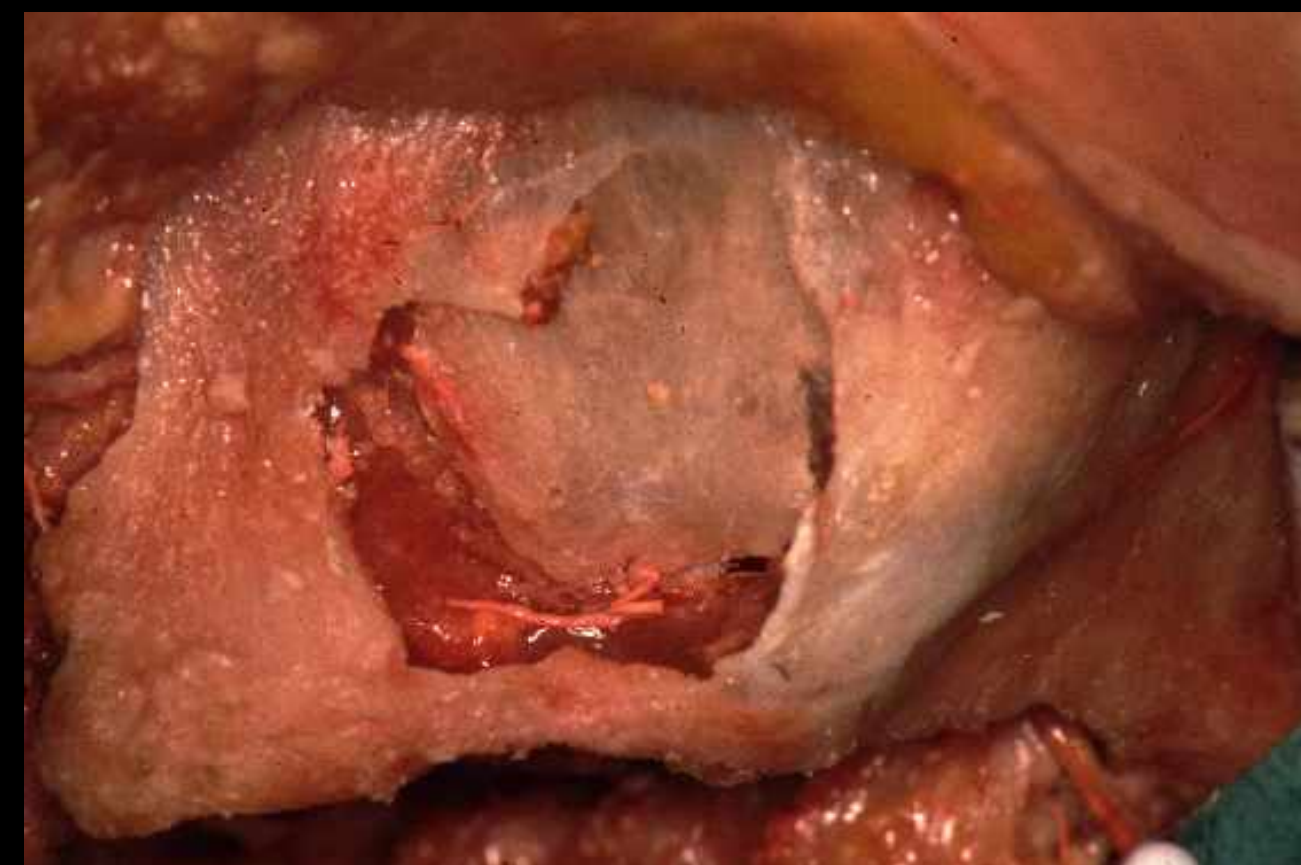
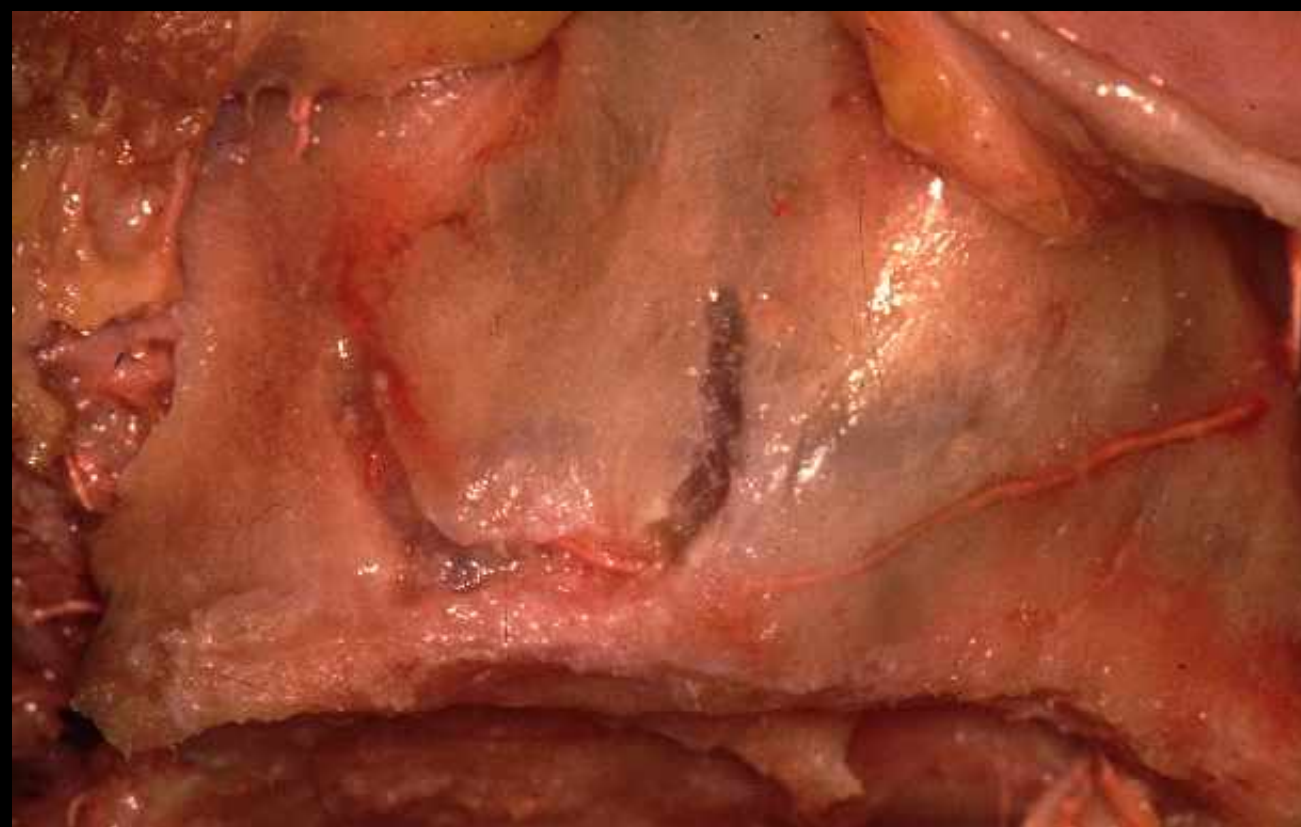
Fig. 108 — Maxillaire : coupe frontale.
1 - Cellule ethmoïdo-maxillaire. 2 - Hiatus maxillaire.
3 - Sinus maxillaire. 4 - Processus palatin. 5 - Processus alvéolaire. 6 - Processus zygomatique. 7 - Sillon infra-orbitaire. 8 - Face orbitaire (supérieure).



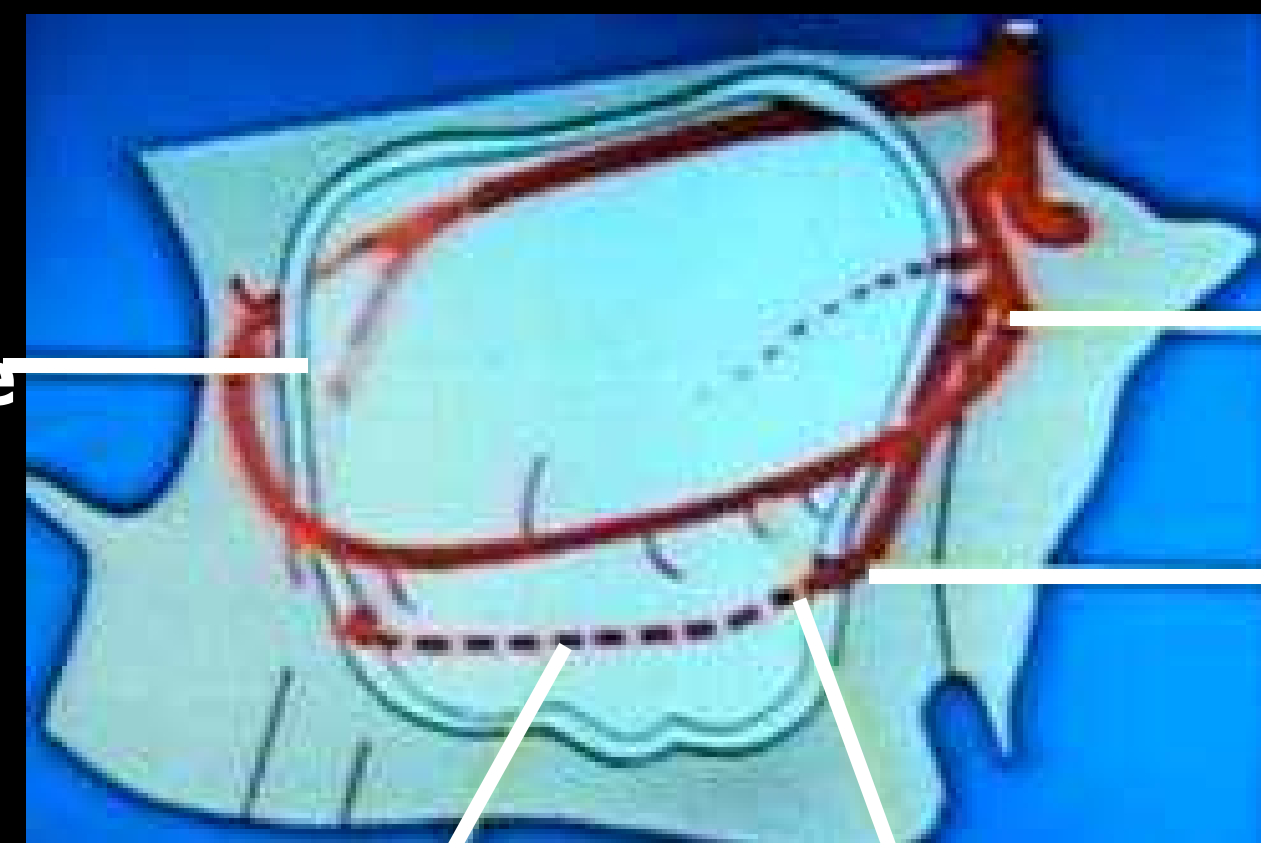
- GREFFE DU SINUS

L'os maxillaire

Anastomoses de l'artère Alvéolaire Postérieure Supérieure et des artères Infraorbitaires



Artère infraorbitaire



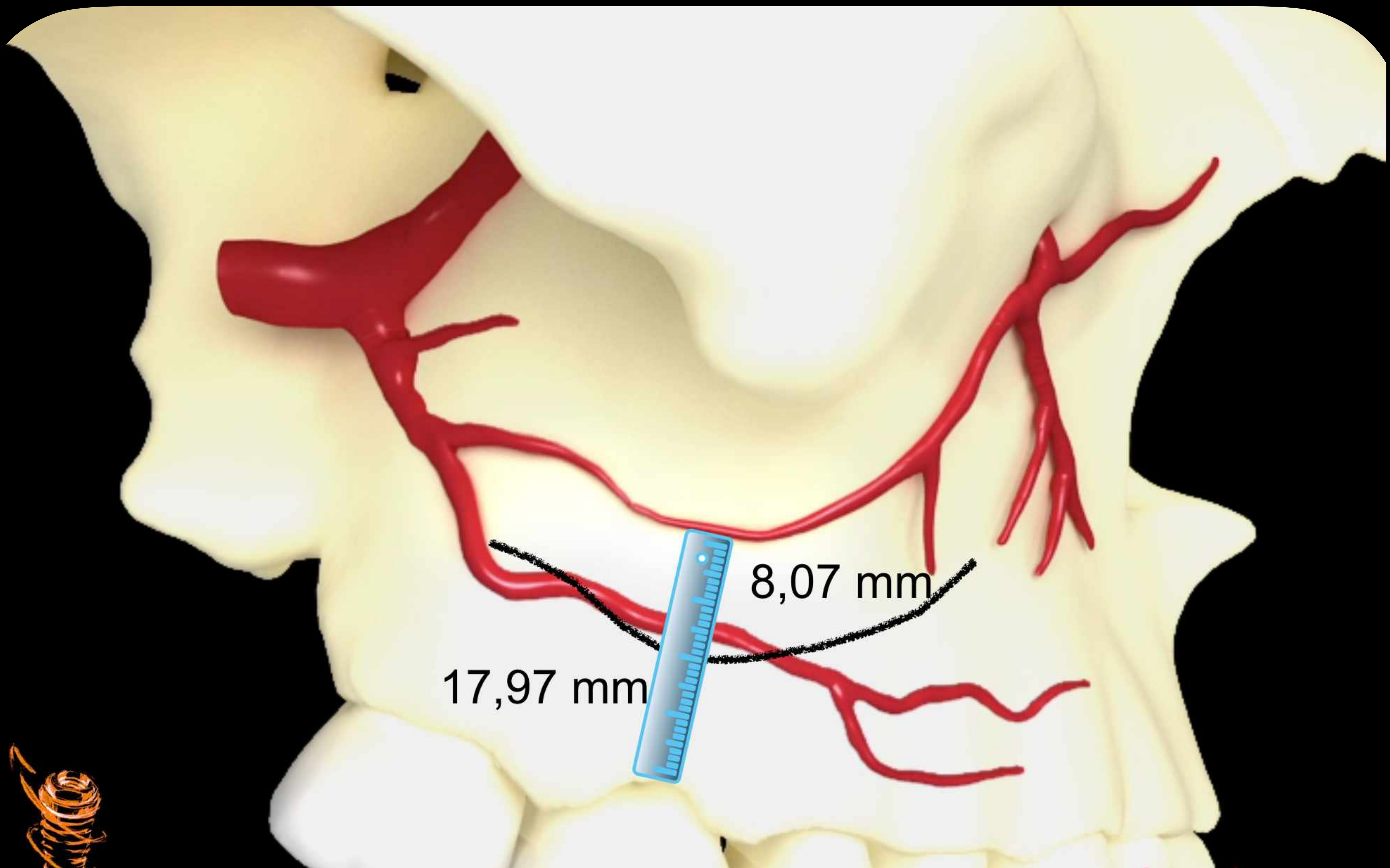
Branche supérieure De l'artère APS

Branche inférieure De l'artère APS

Trajet intraosseux

Trajet extraosseux

Anatomie Endo-sinusienne

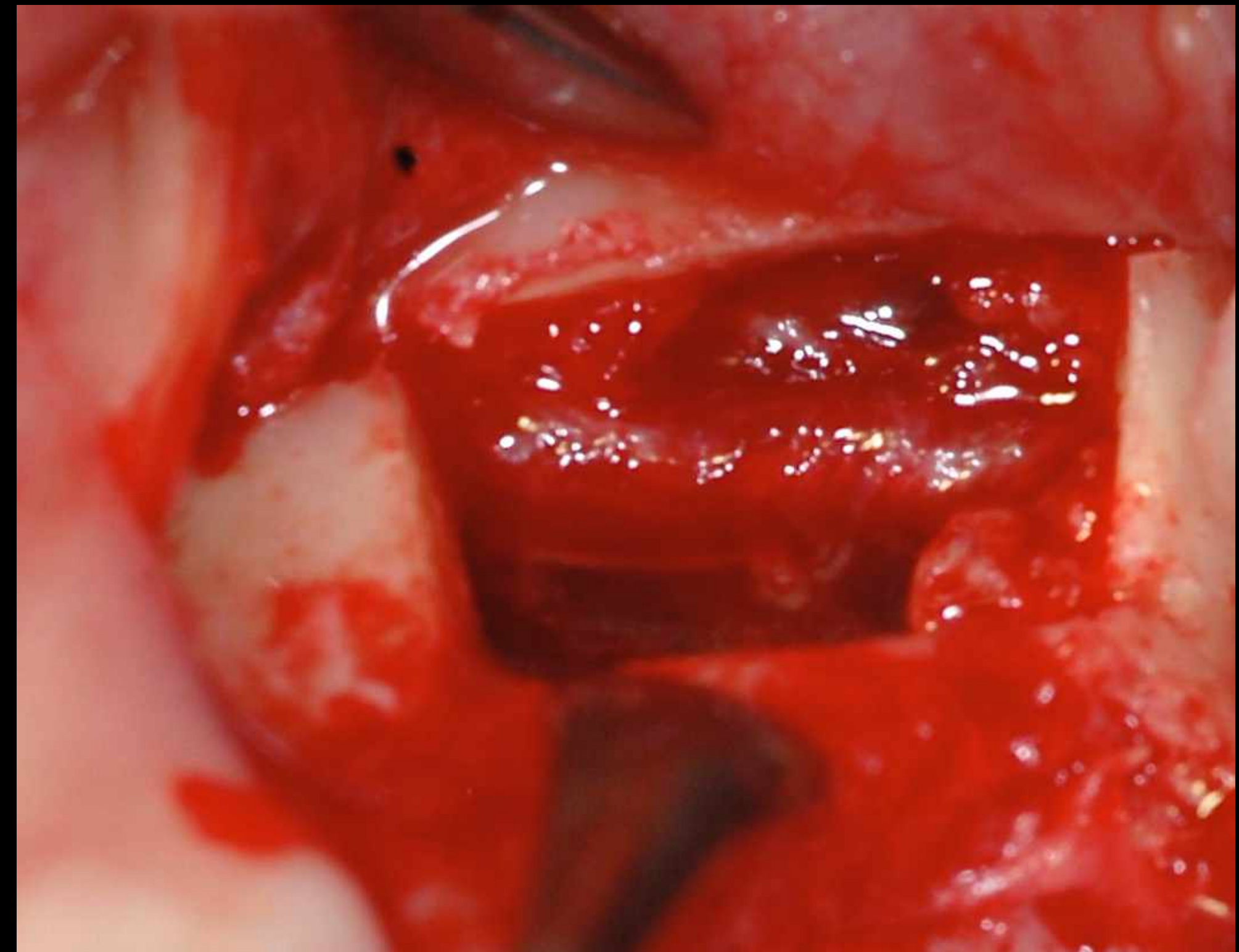
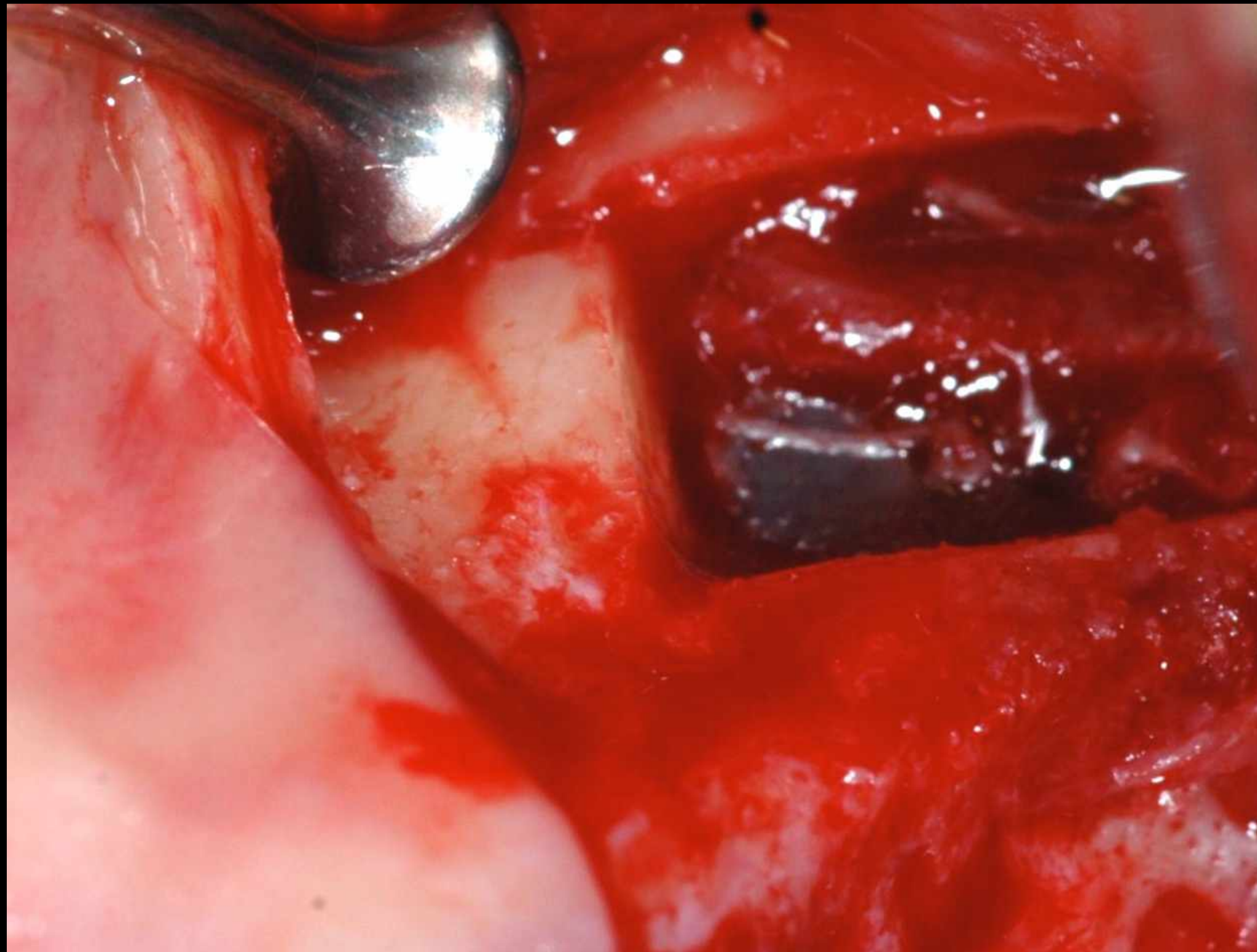


17,97 mm

8,07 mm



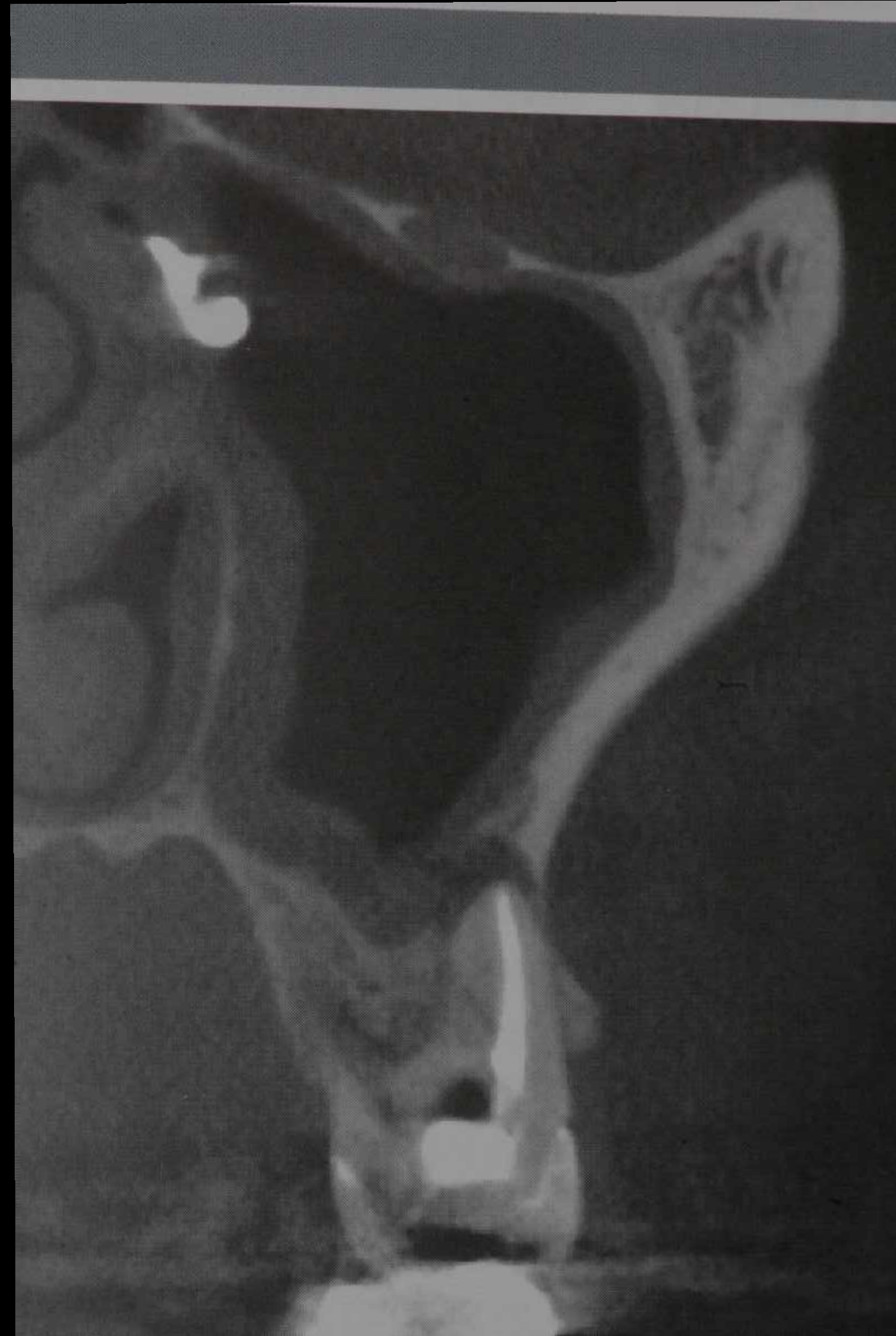Artère alvéolaire supérieure postérieure = artère antrale



Lésion : risque hémorragique
suture très difficile

Préférer pince gouge et «broyage» os + artère
si pas hémostase possible : arrêt chir + fermeture
mèches de coalgan

GREFFE DU SINUS



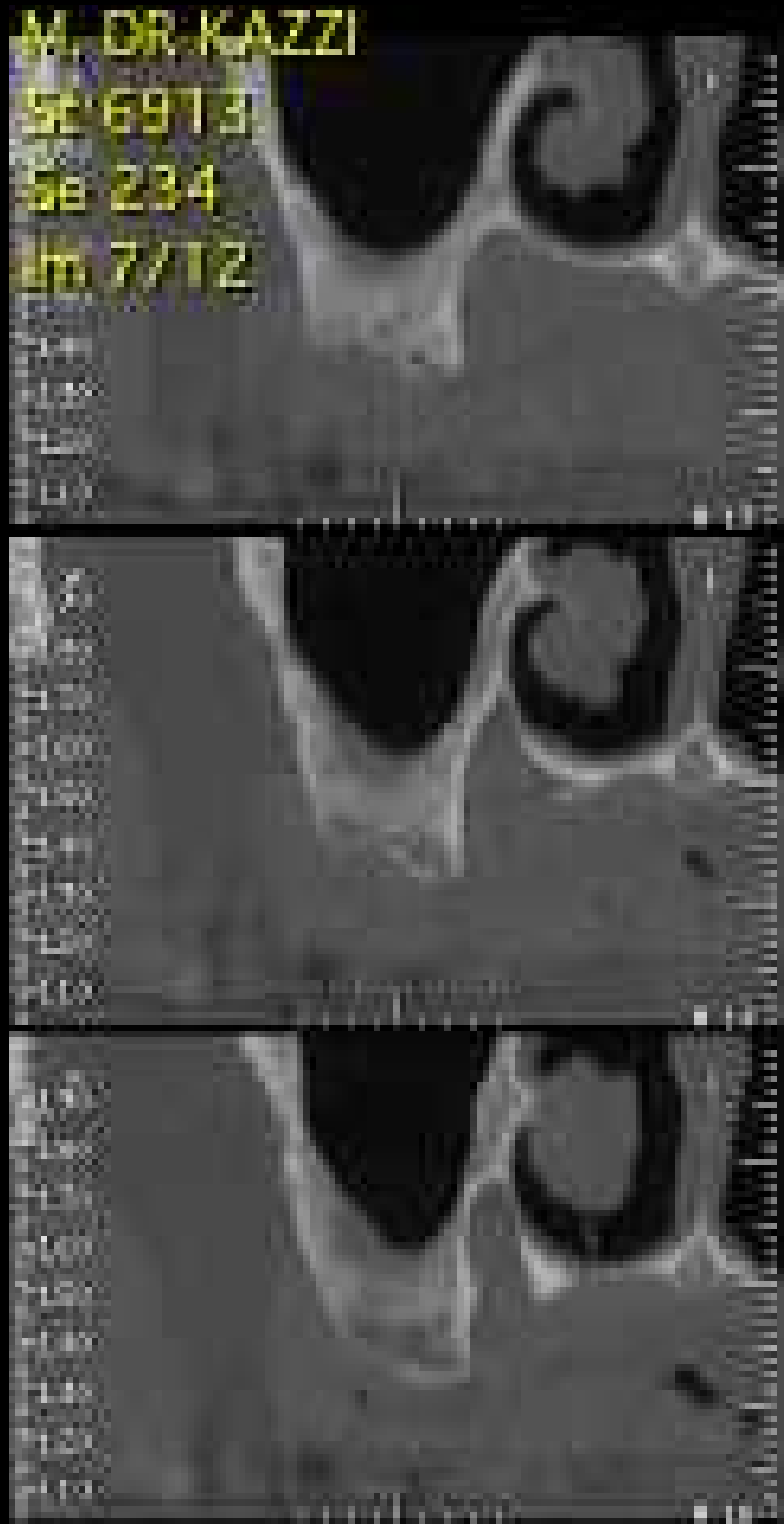
LE SINUS MAXILLAIRE

Le volume moyen est de 12 à 15cm³
Sa forme définitive est atteinte après
l'éruption des 8

Il est tapissé par la membrane de
schneider avec un **épithélium cilié** de
type respiratoire d'épaisseur 0,8mm

Les septa d'Underwood ont une
orientation frontale

GREFFE DU SINUS



Rôle dans la phonation
Rôle dans la résonance de la voix
Rôle dans l'humidification et le réchauffement de l'air inspiré
Rôle dans la fonction olfactive
Rôle dans la régulation thermique du cerveau

Garg AK

Augmentation grafting of the sinus for placement of dental implants:anatomy,physiologie,and procédures
Implant Dent 1999,36,46

Le comblement sinusien - aspect médico-légaux

Code de Santé Publique - 9 août 2004:

“La prévention, le diagnostic, le traitement des maladies congénitales ou acquises, réelles ou supposées, de la bouche, des dents, des maxillaires et des tissus attenants”

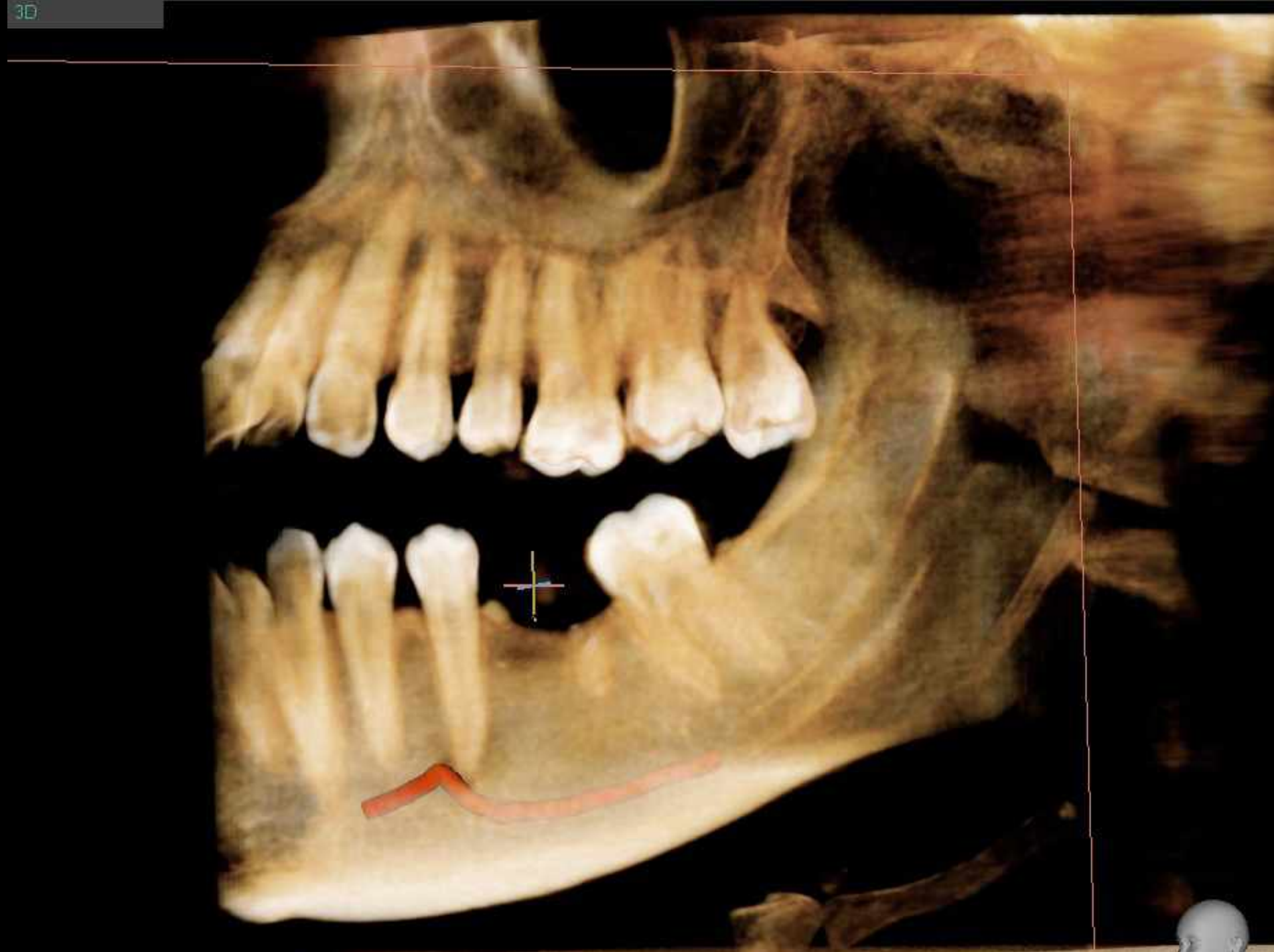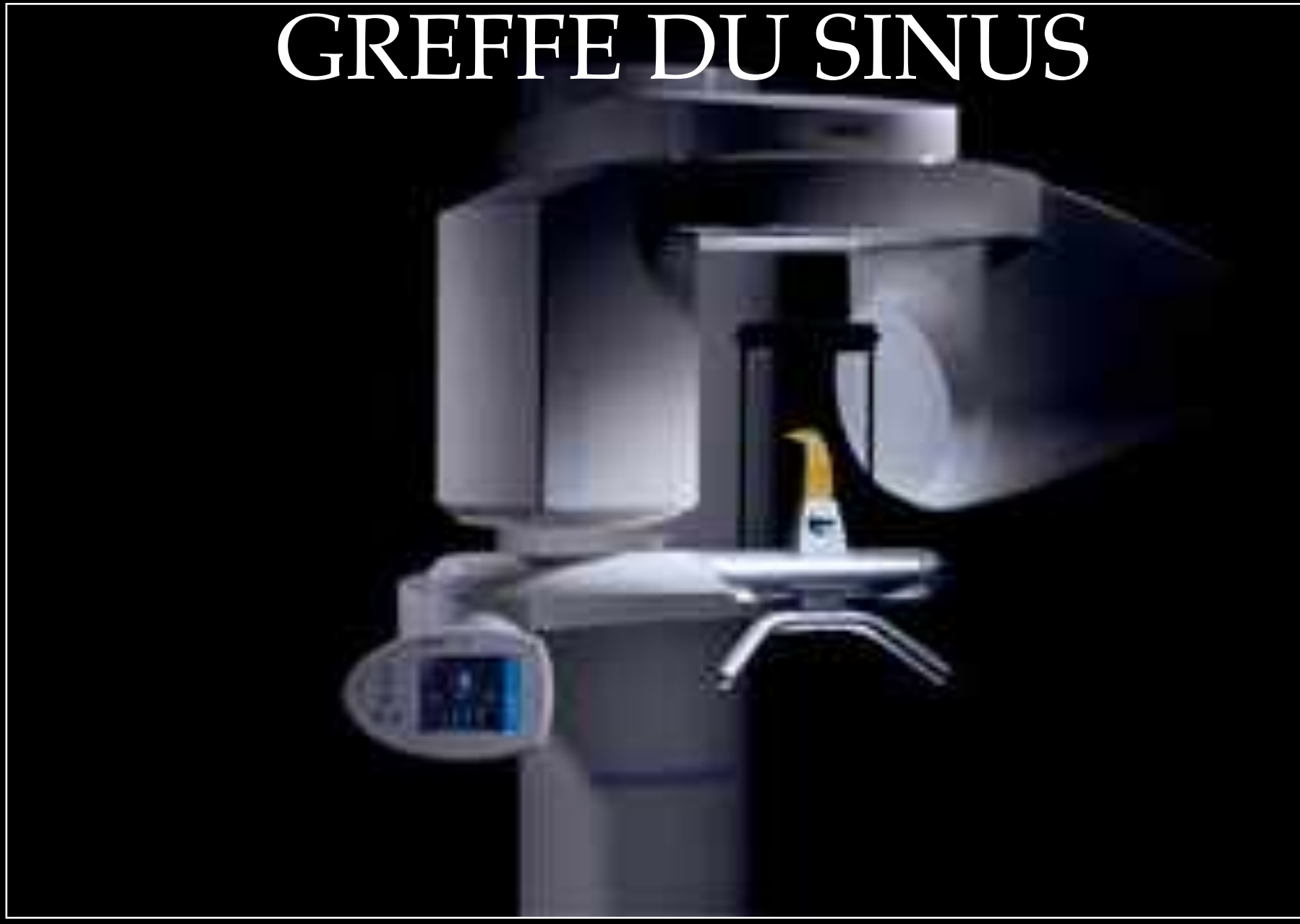“Les matériaux de comblement doivent satisfaire aux conditions de mise sur le marché”

Salle dédiée à la chirurgie

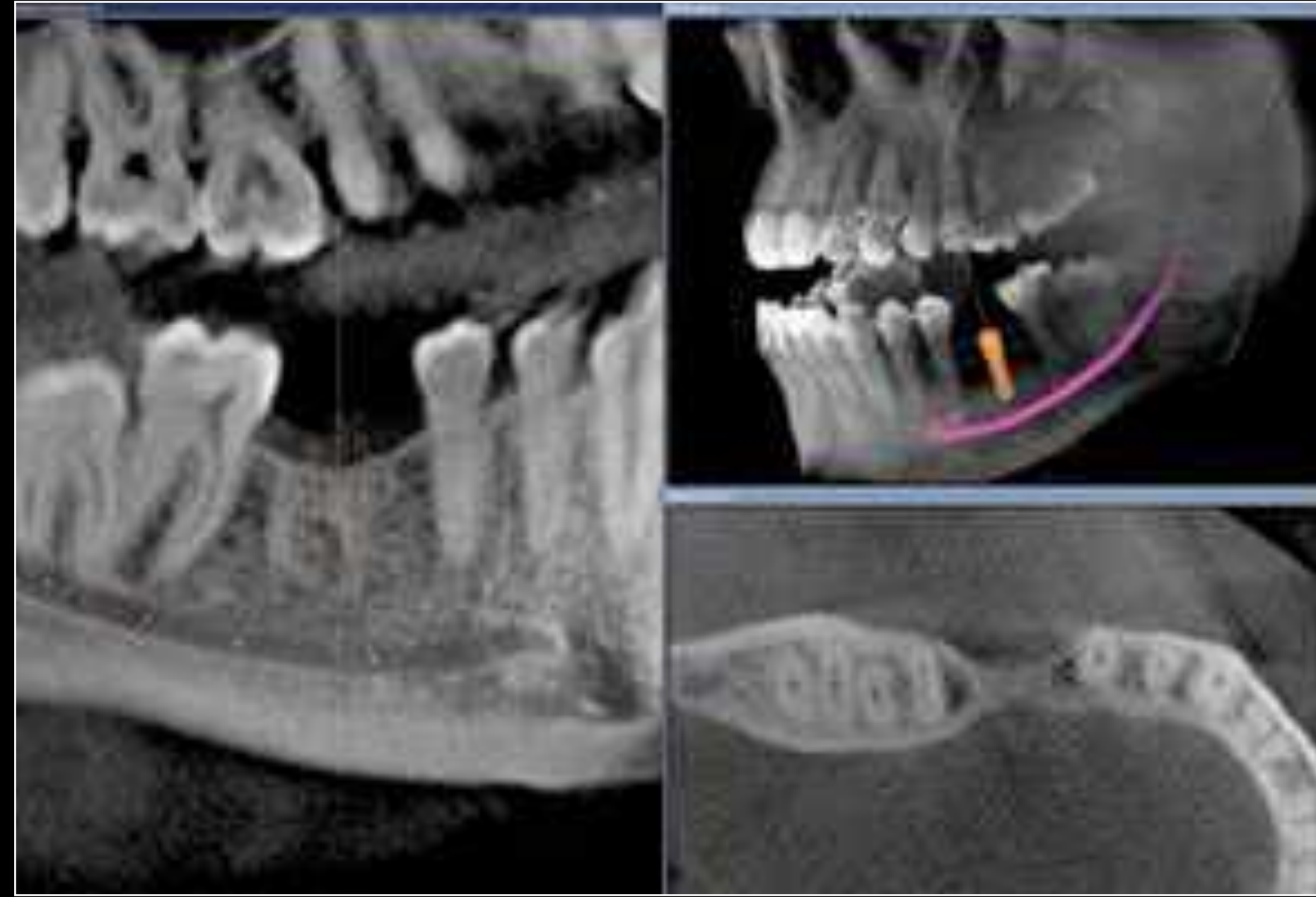
Diagnostic

Examens radiologiques

GREFFE DU SINUS



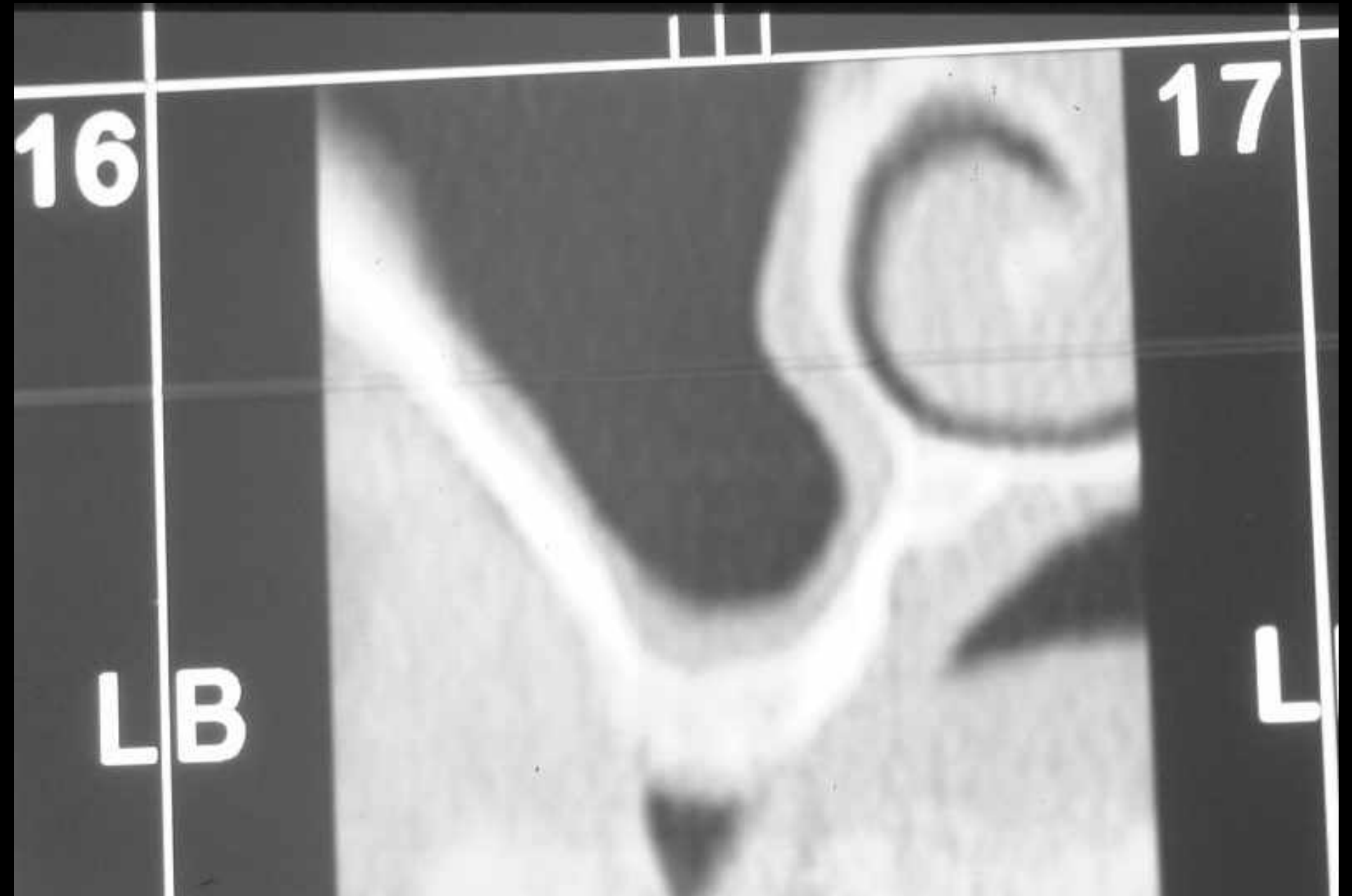
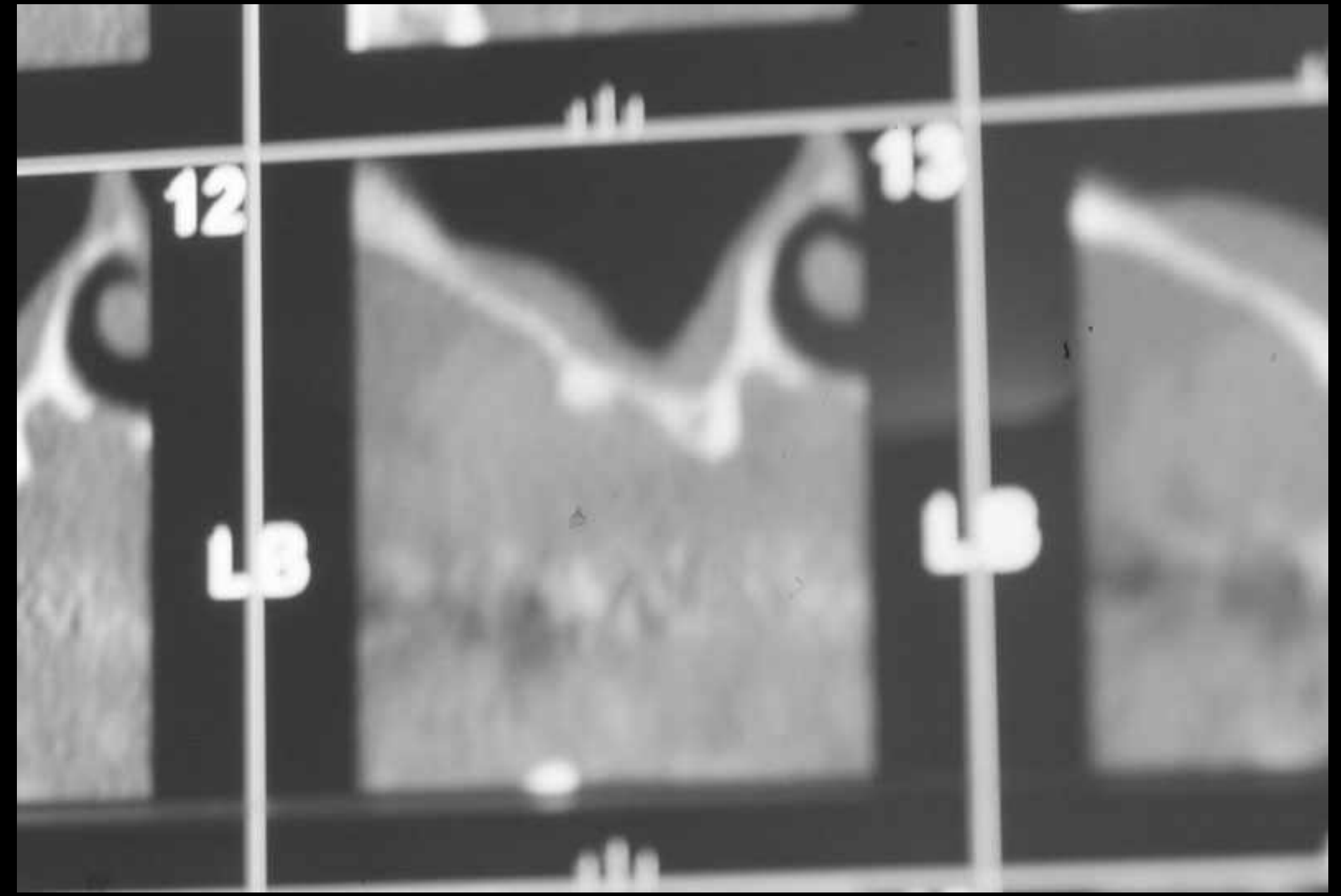
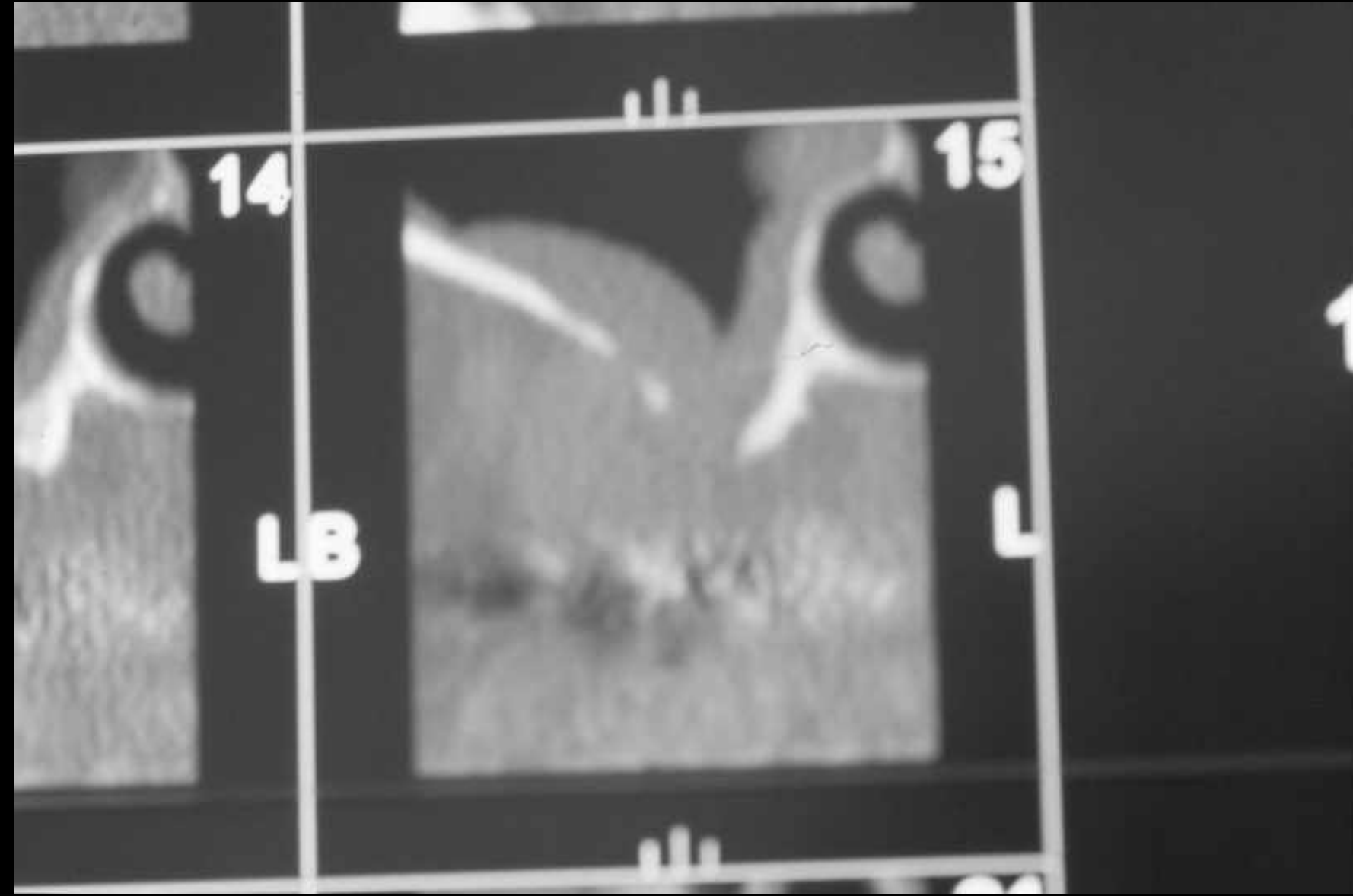Le ConeBeam



Diagnostic

Examens radiologiques

- GREFFE DU SINUS

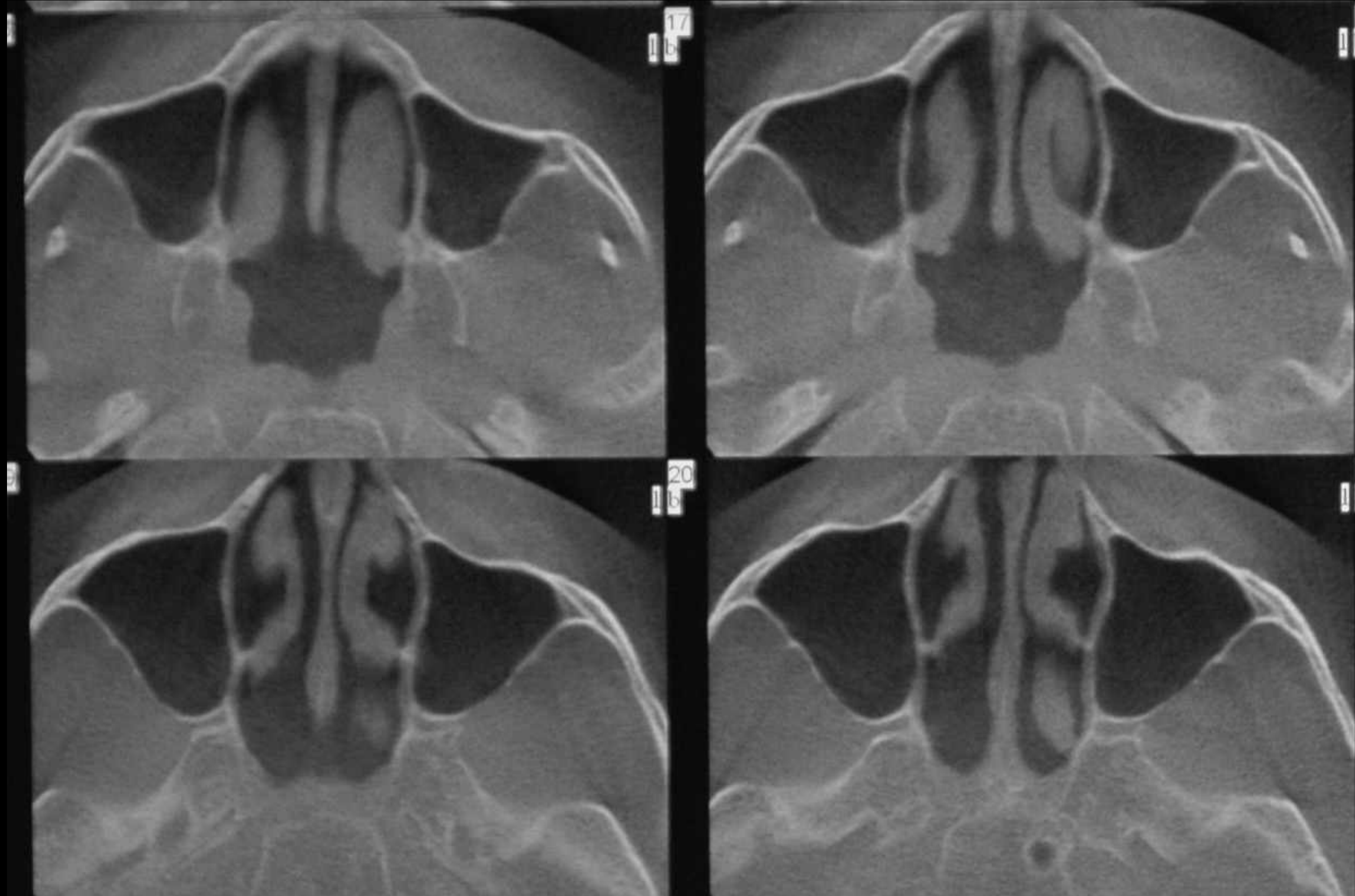


Diagnostic

Examens radiologiques

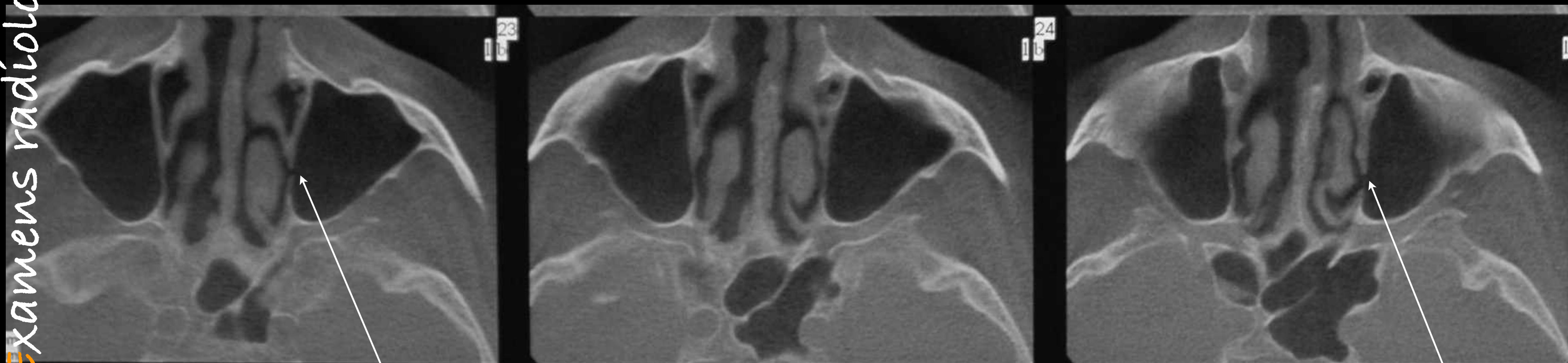GREFFE DU SINUS

Scanner coupe coronale



GREFFE DU SINUS

Scanner coupe coronale



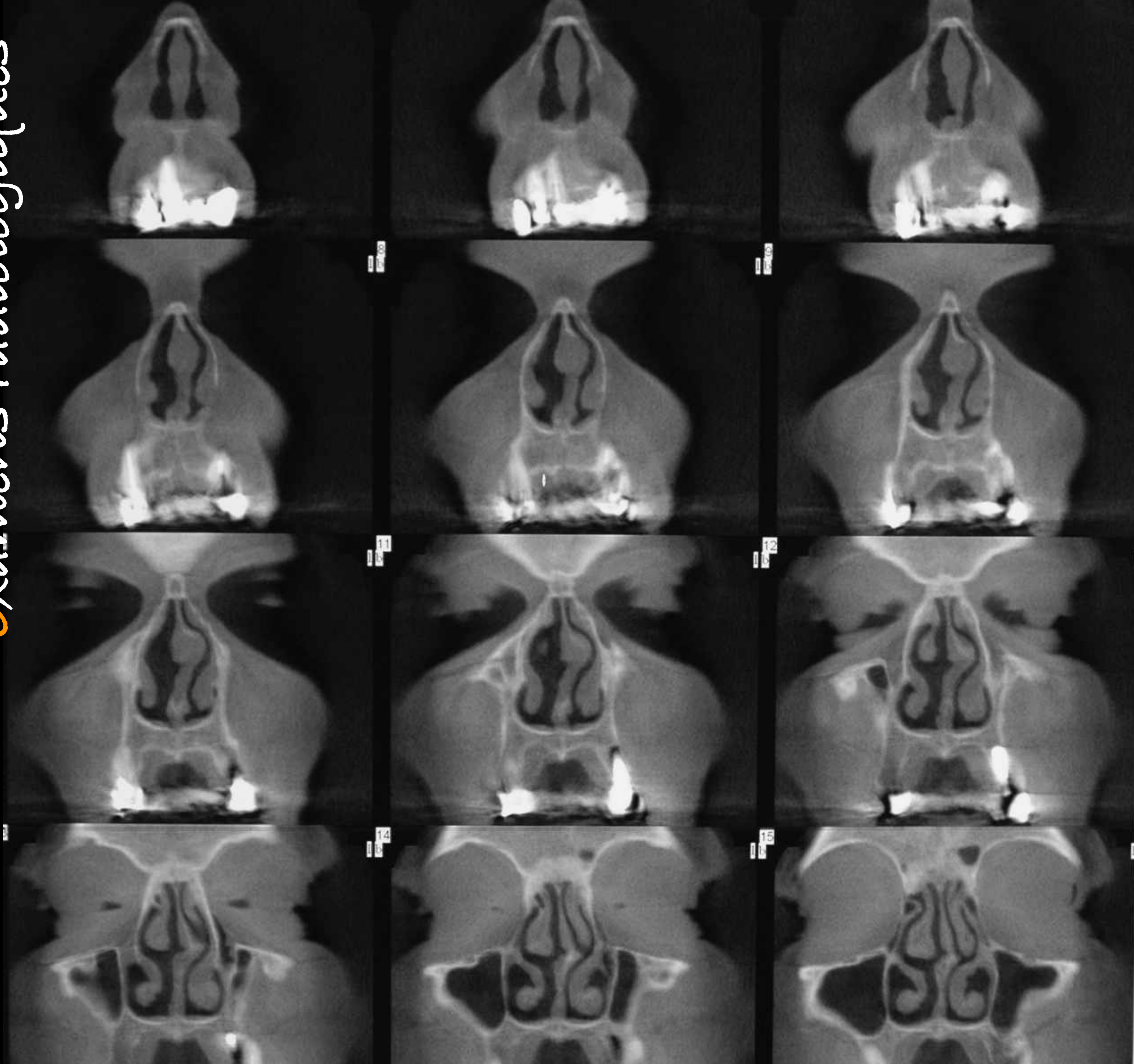
Méat moyen

Méat moyen

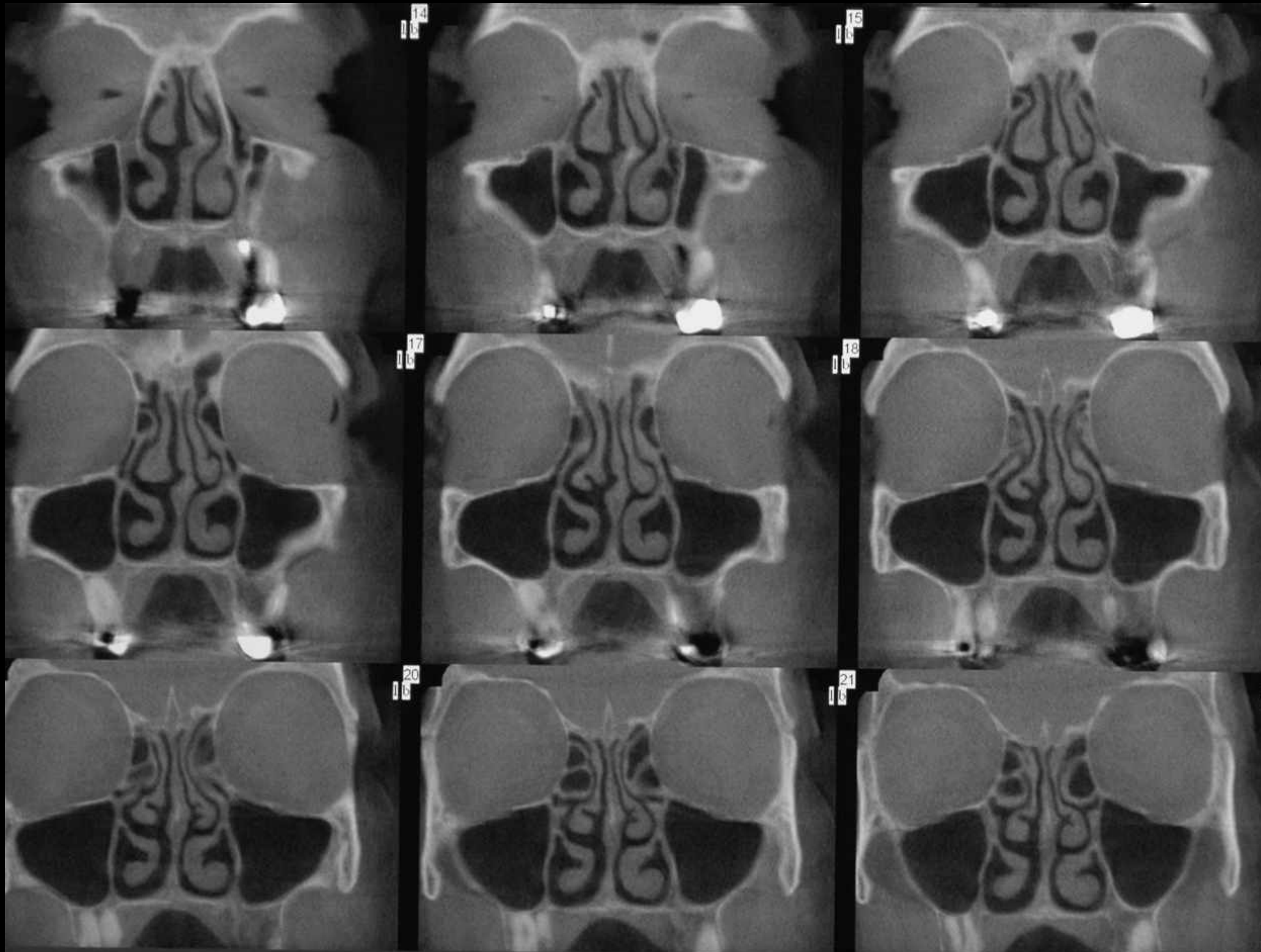
Diagnostic

Examens radiologiques

Examens radiologiques



Sinus maxillaire
Coupes frontales



Sinus maxillaire
Coupes frontales

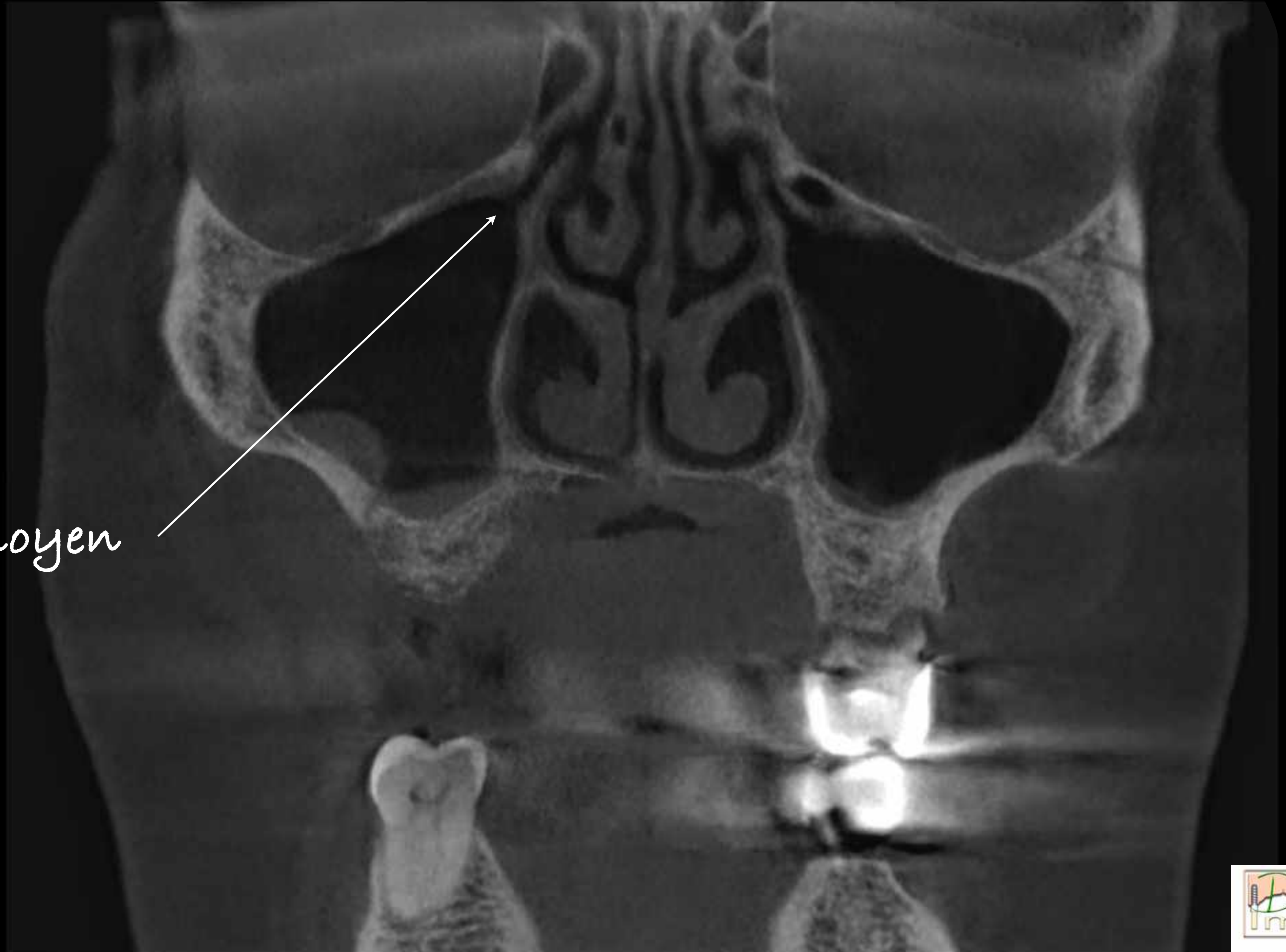
Diagnostic

Examens radiologiques

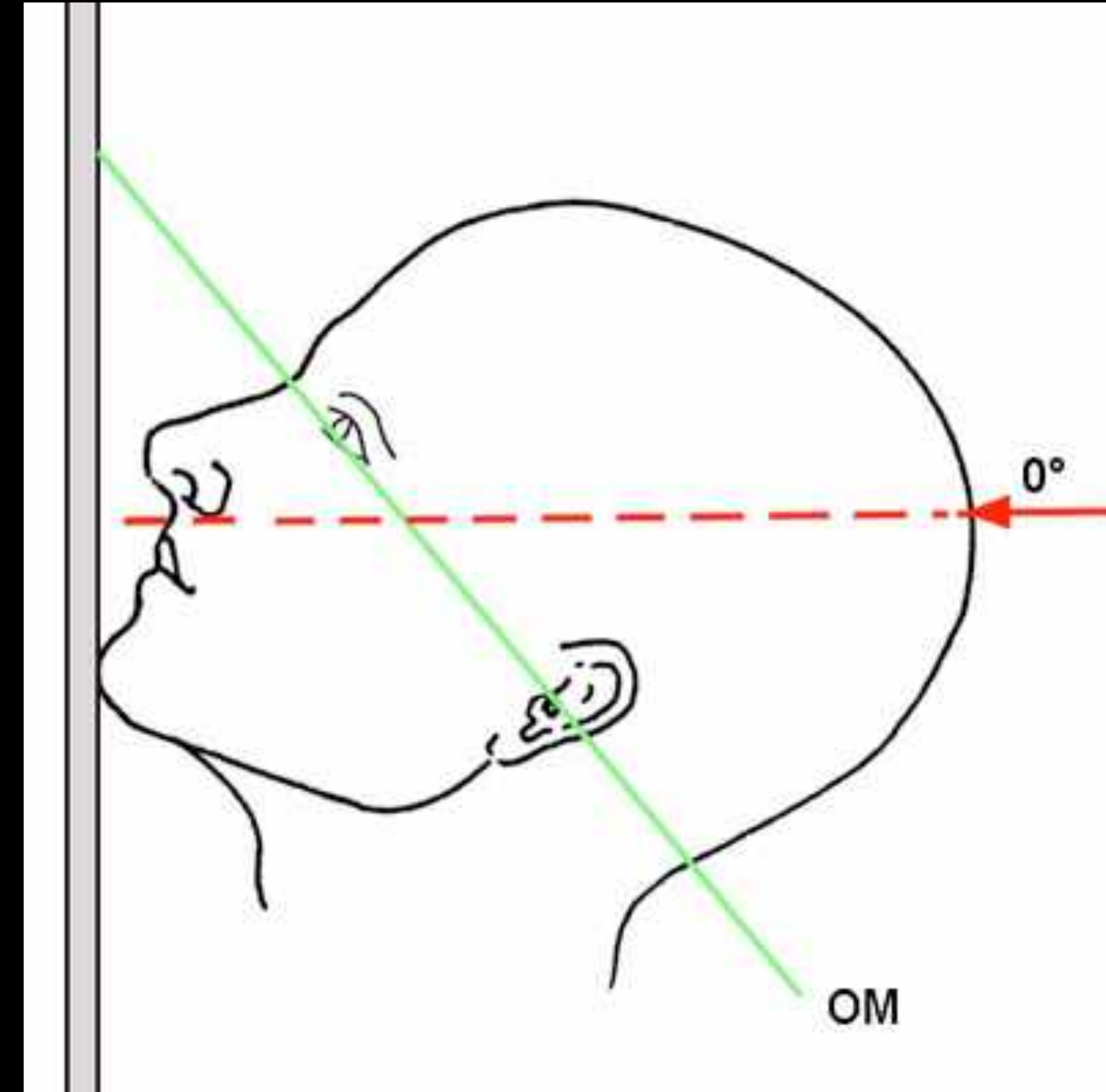
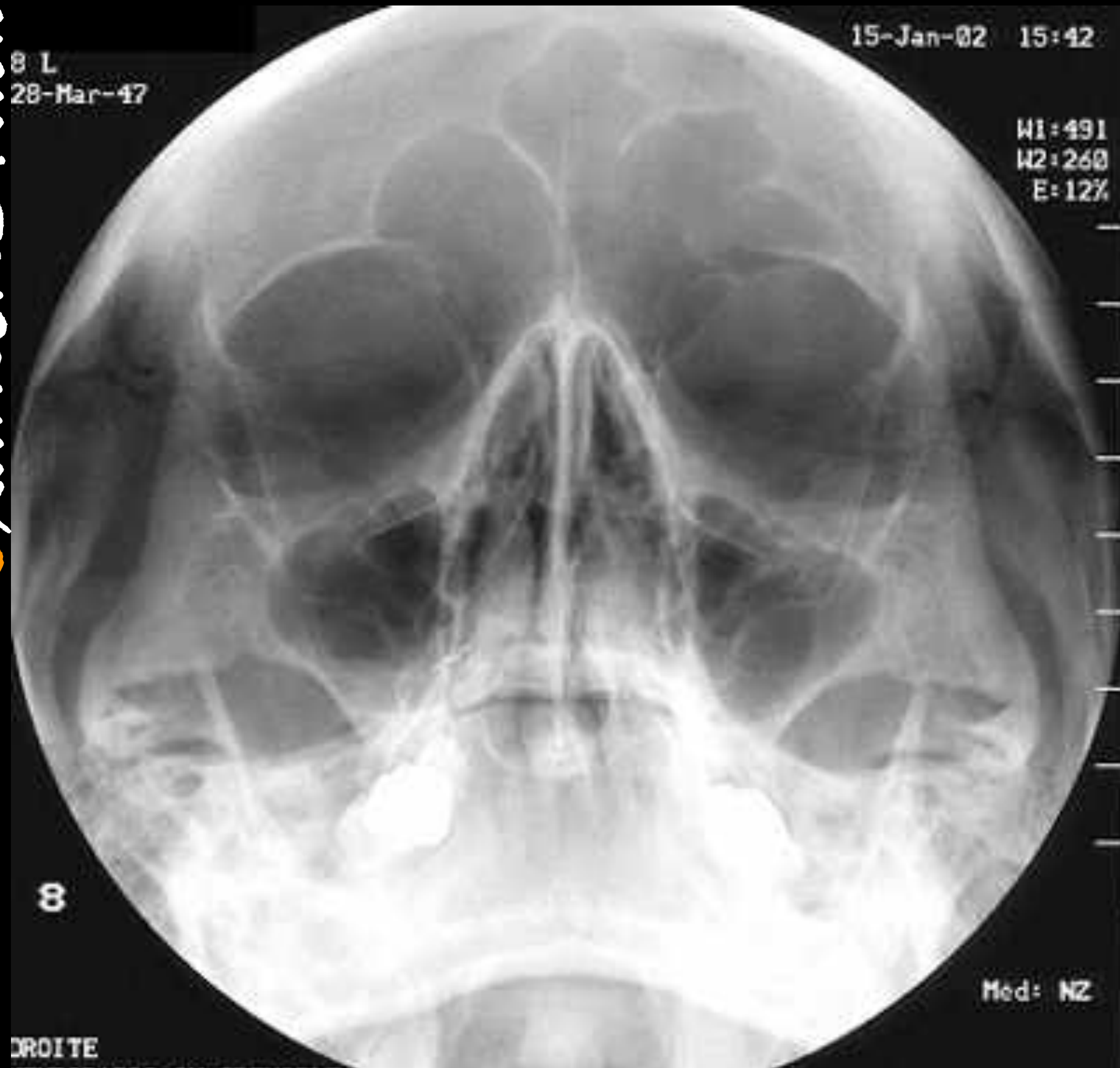GREFFE DU SINUS

Coupes frontales

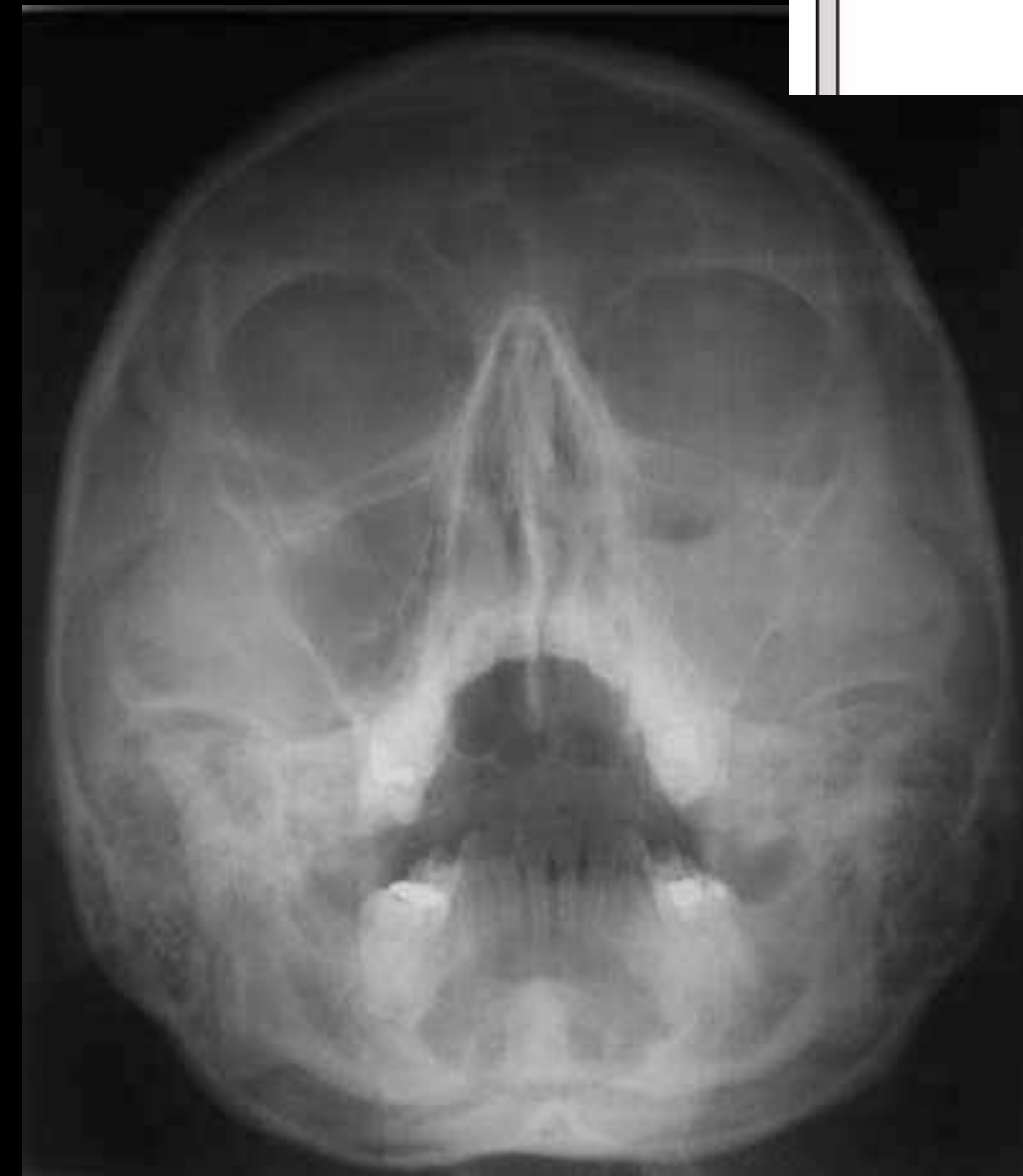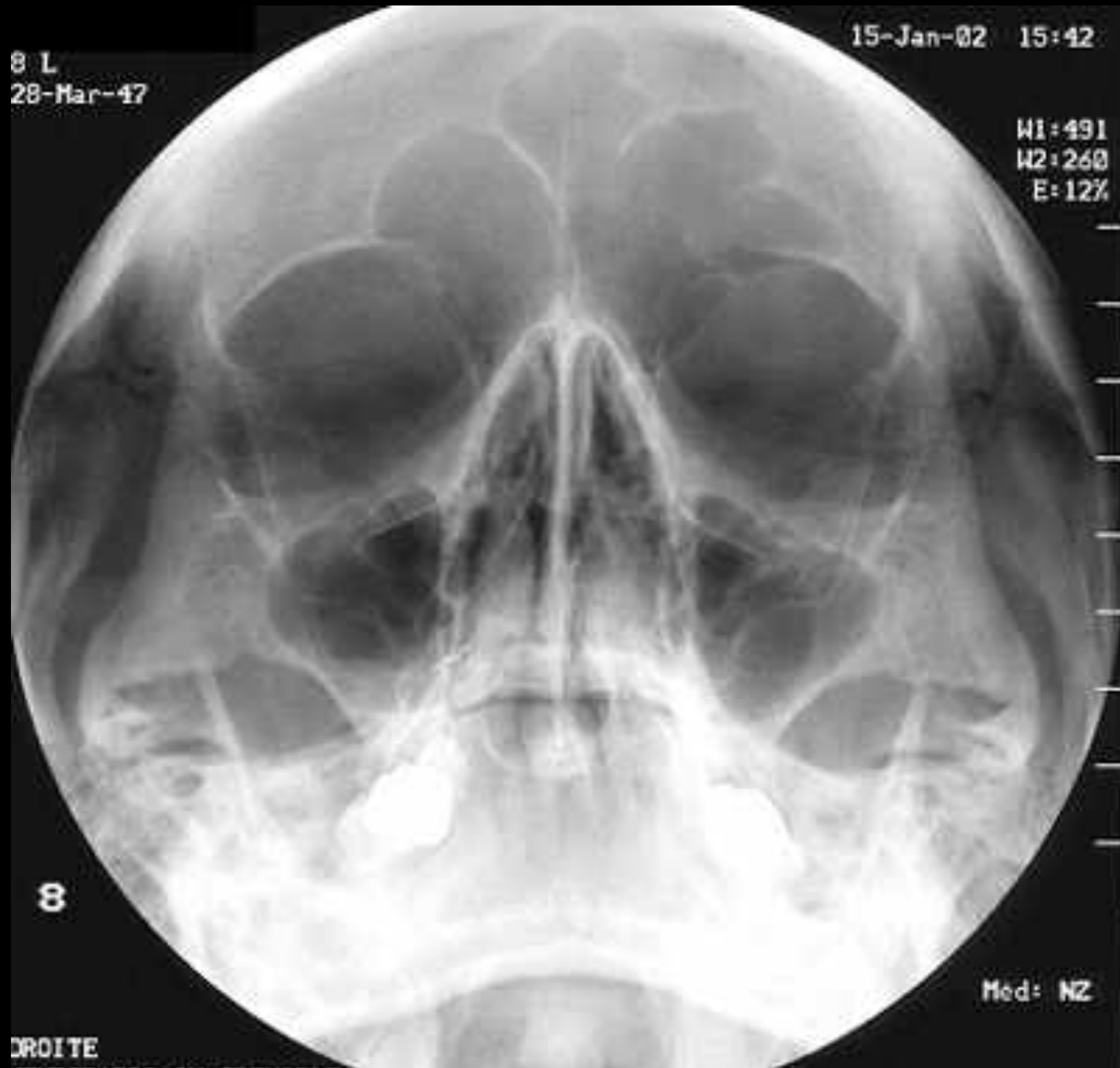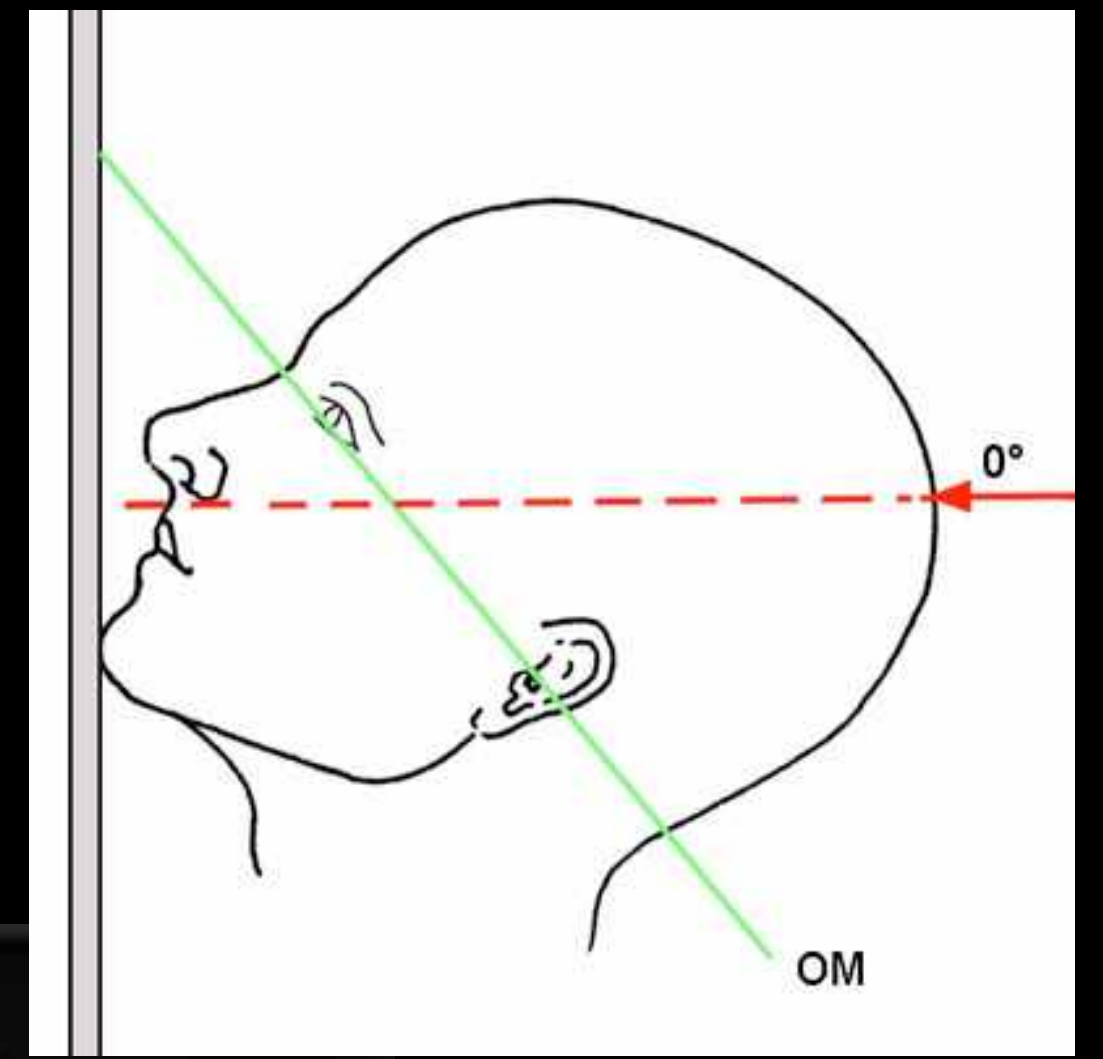
Méat moyen



Incidence de Blondeau
vérifier l'absence de niveau liquidien
ou d'opacité

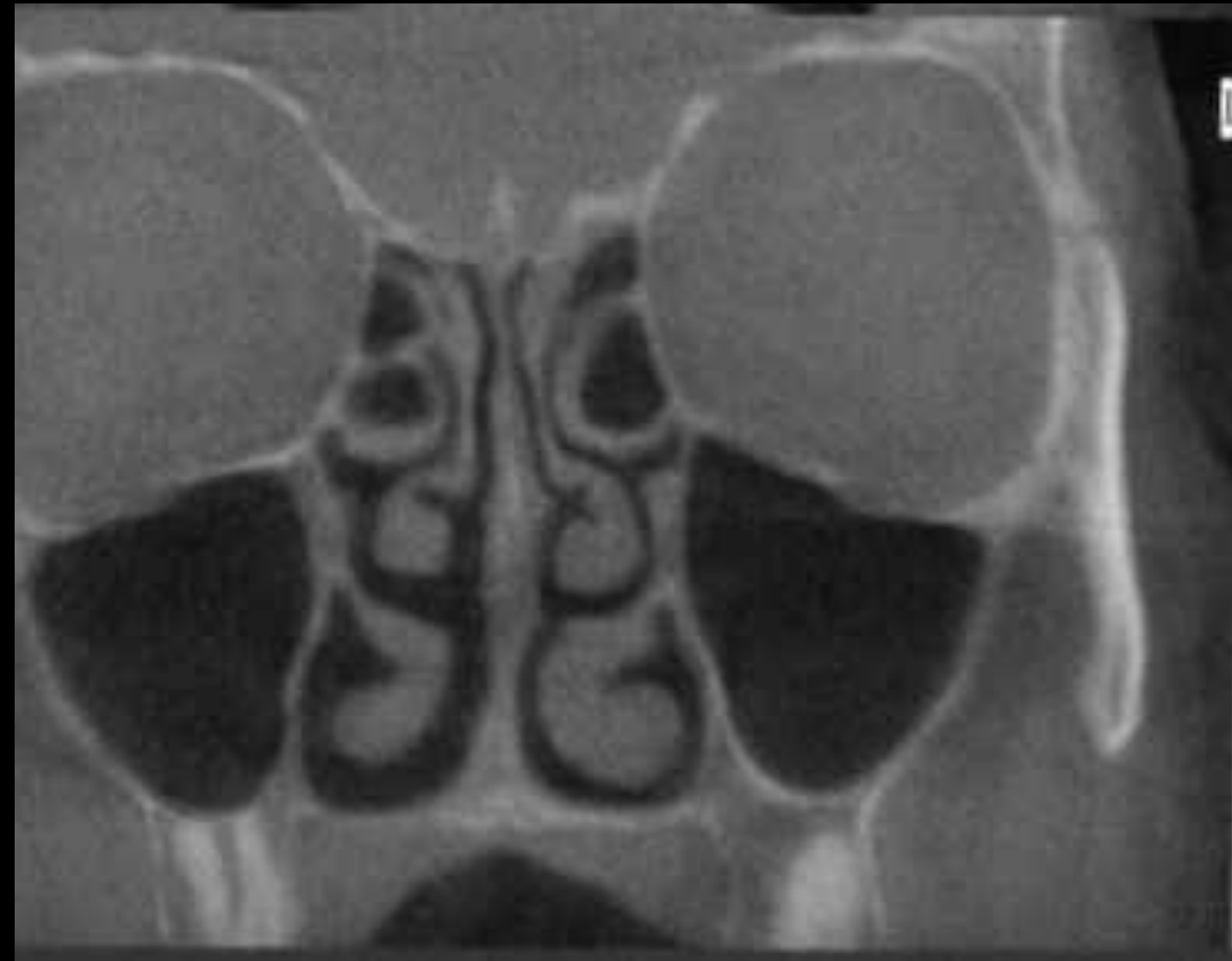
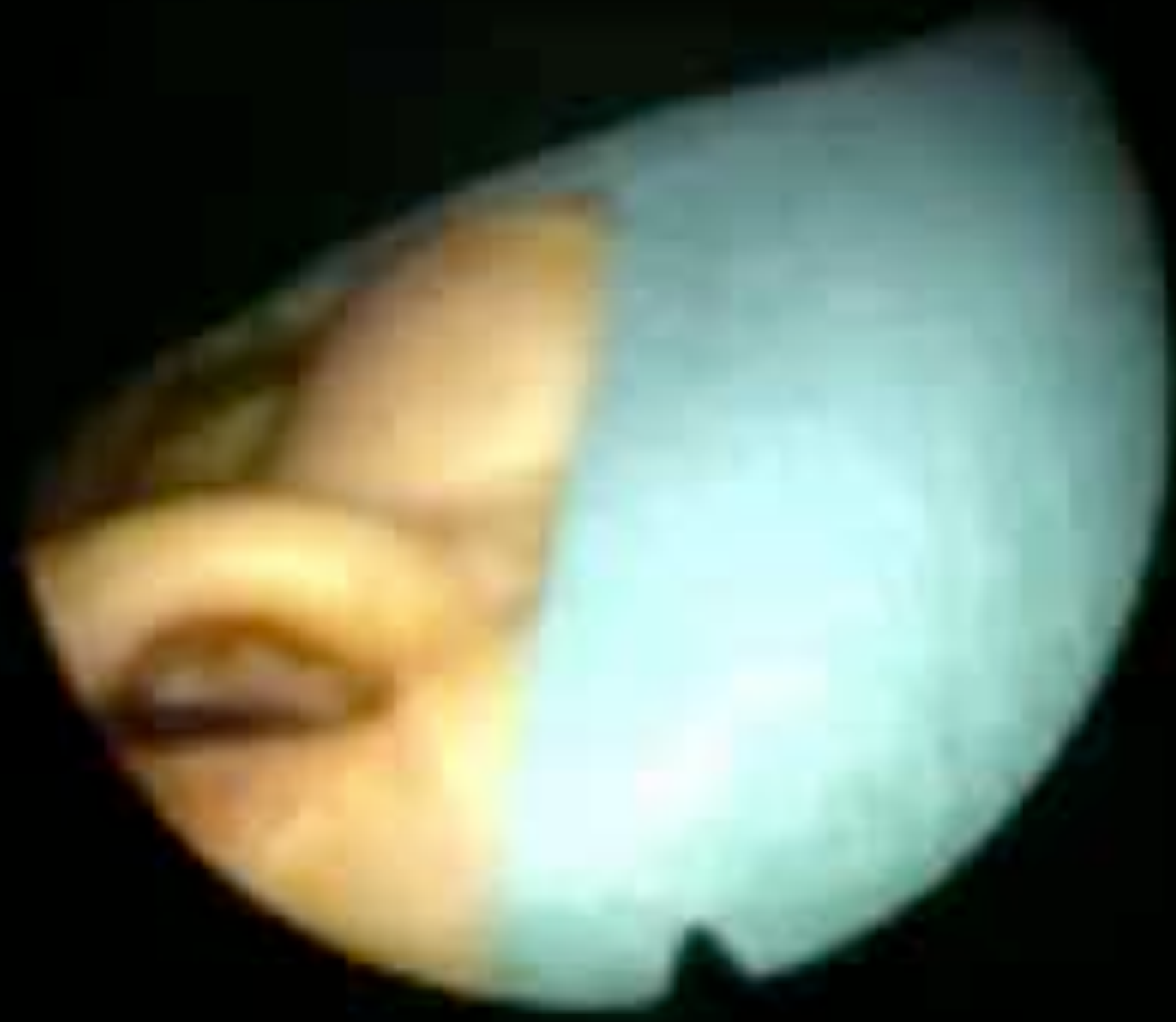

Incidence de Blondeau
vérifier l'absence de niveau liquidien
ou d'opacité



Diagnostic
Examens cliniques

GREFFE DU SINUS



Physiologie : Rhinoscopie

GREFFE DU SINUS

Recherche de dysfonction naso-sinusienne

Interrogatoire médical

ATCD de sinusite chronique

ATCD d'intervention chirurgicale / méatotomie moyenne

Rhinite allergique saisonnière

mouchage purulent uní ou bilatéral

Epístaxis

GREFFE DU SINUS

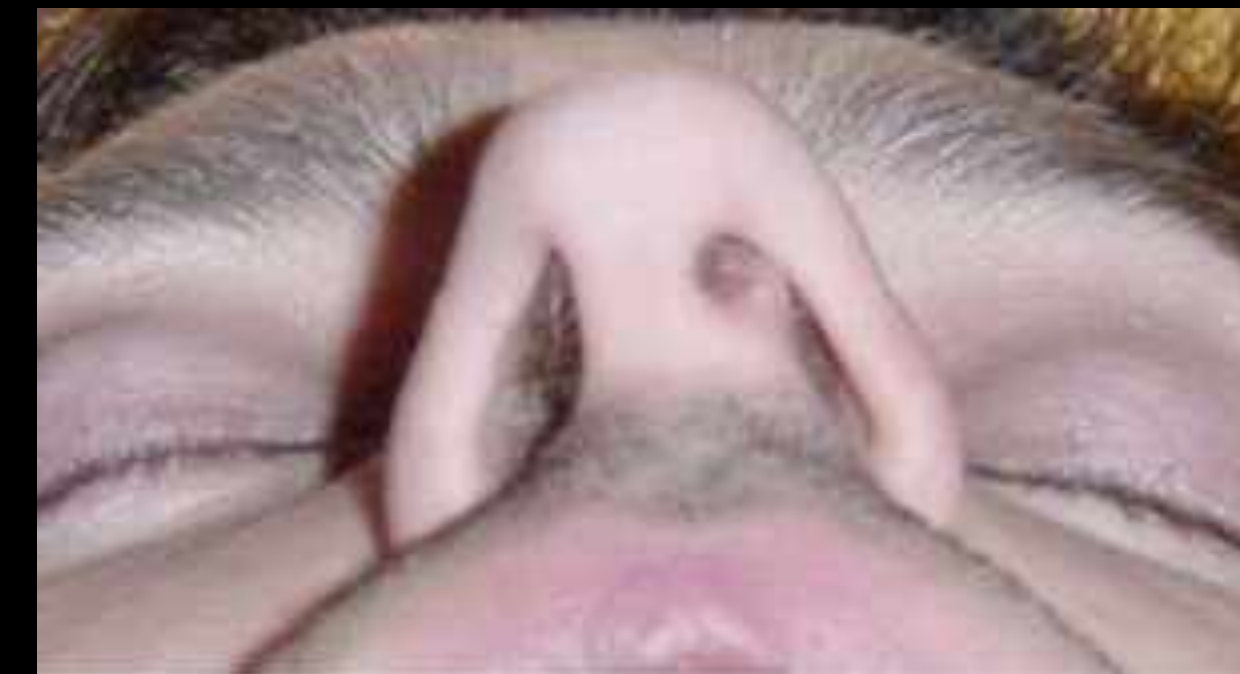Recherche de dysfonction naso-sinusienne

Tester les fonctions ventilatoires

Test du miroir de Glatzell



Déviations de la cloison nasale

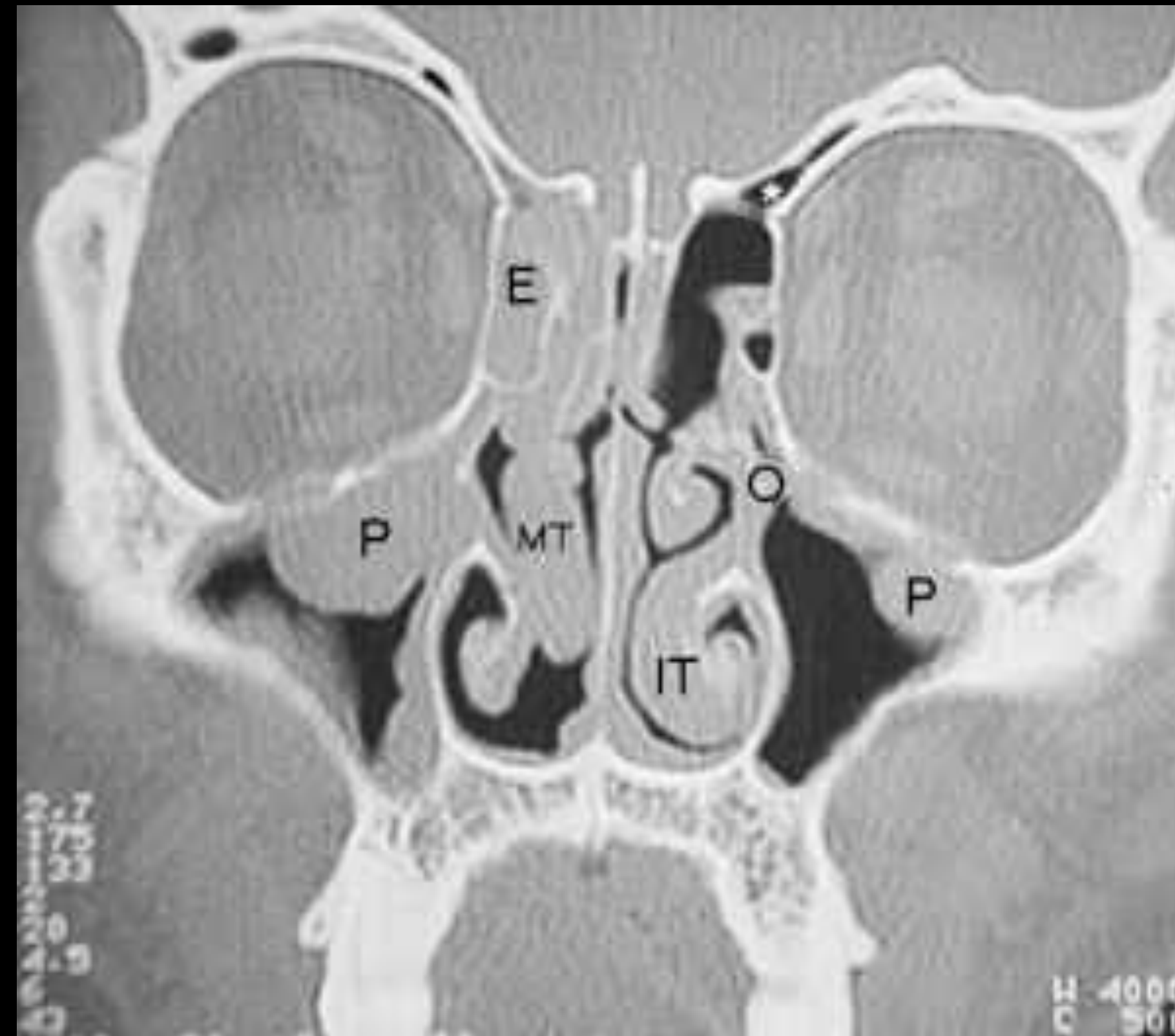

Scanner

visualiser l'état de la muqueuse sinusienne

Image en cadre

Polype intra-sinusal



Scanner

visualiser l'état de la muqueuse sinusienne

Recherche de :

Epaississement de la muqueuse sinusienne ou nasale

Polype intra-sinusal

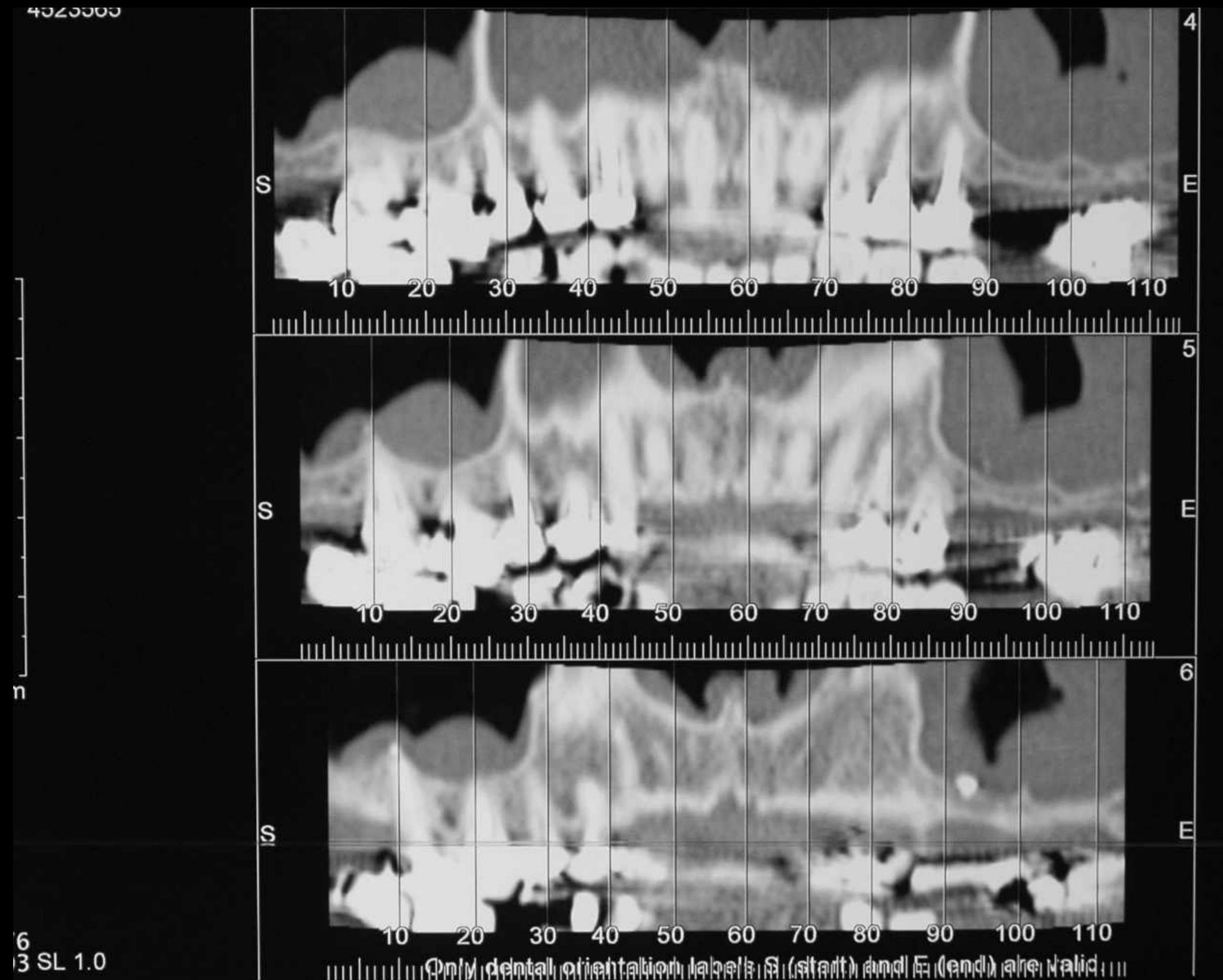
Concha bullosa

Aspergillose

forme du bas fond sinusal

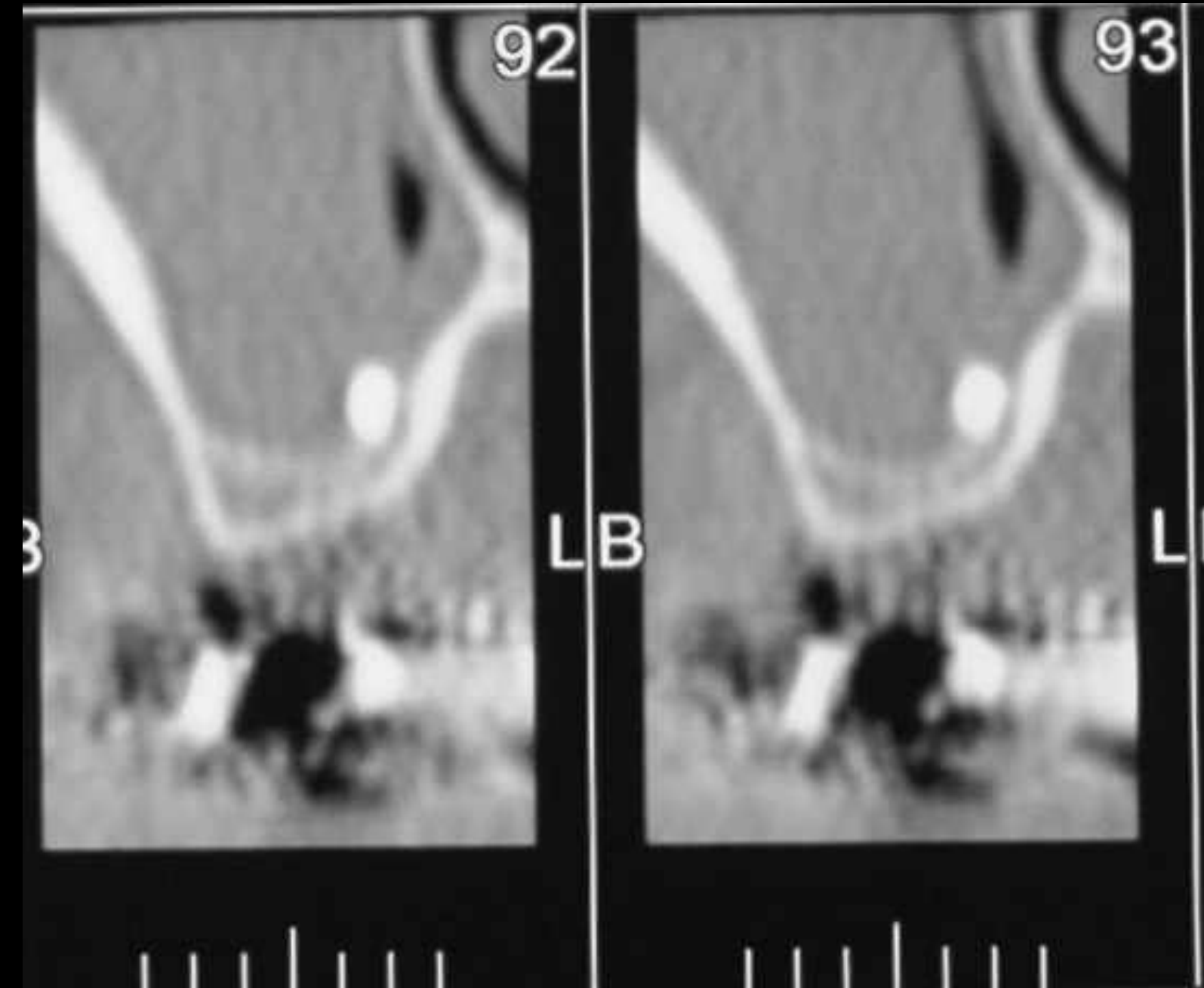
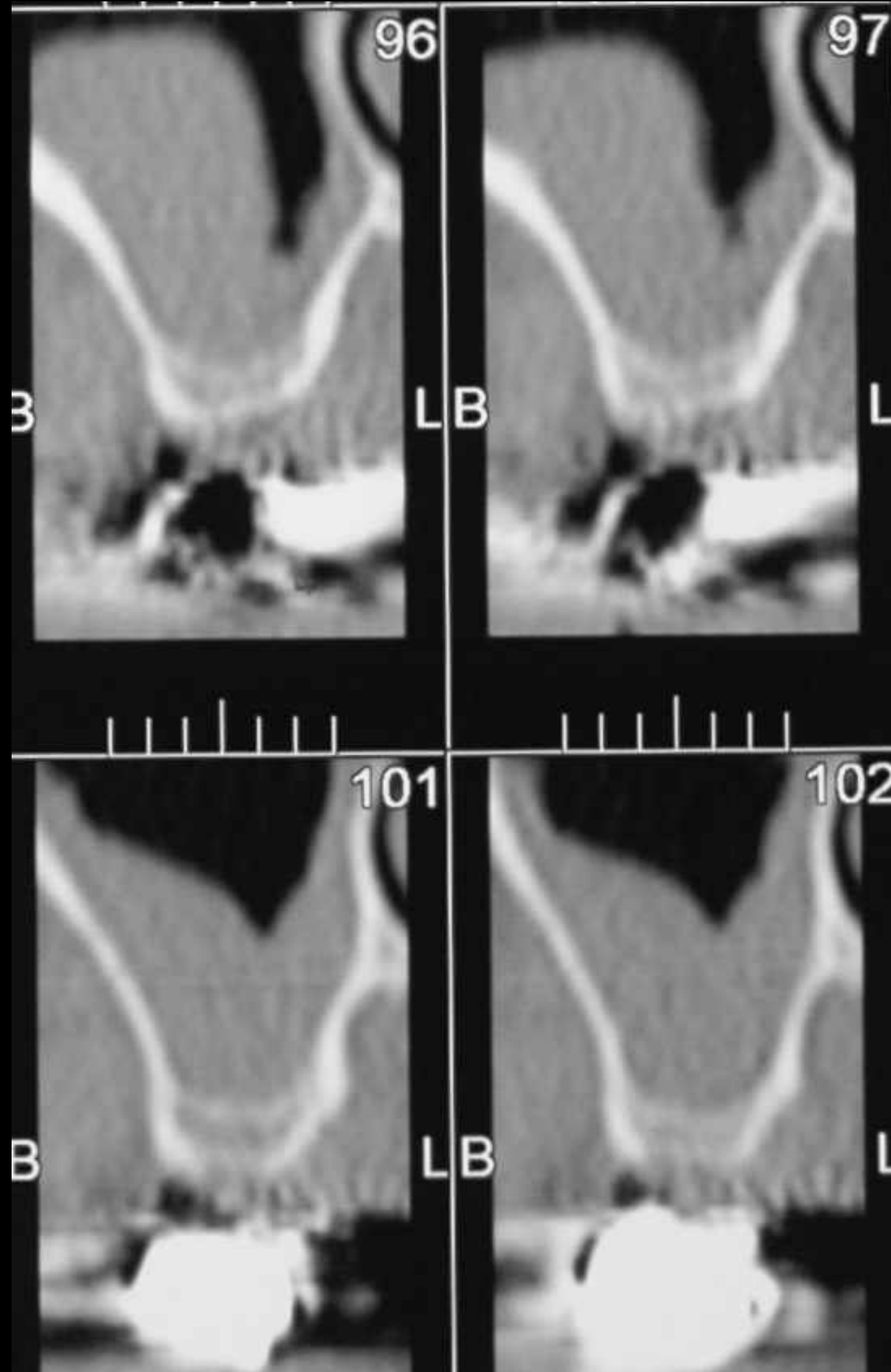
GREFFE DU SINUS

Scanner
Image en cadre

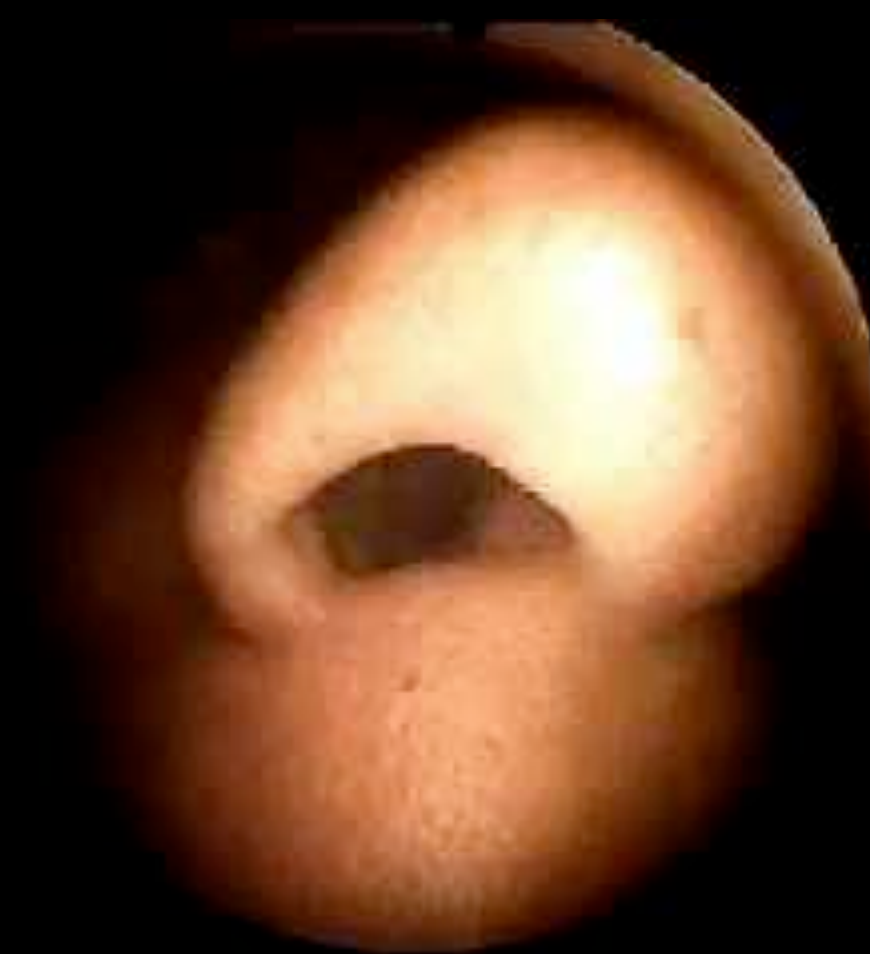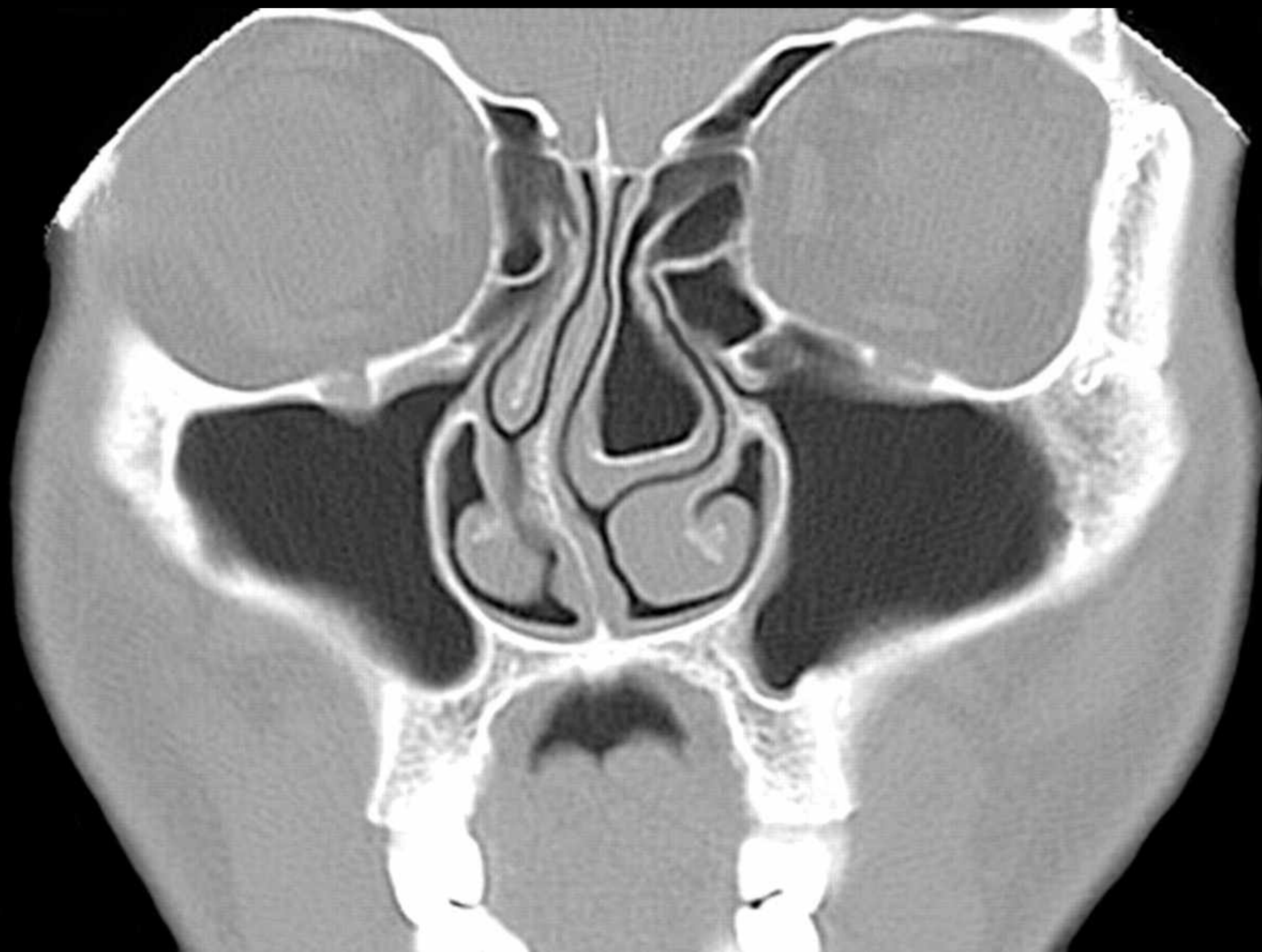


Psoriasis généralisé
Echec corticothérapie
Chirurgie différée

Scanner
Image en cadre



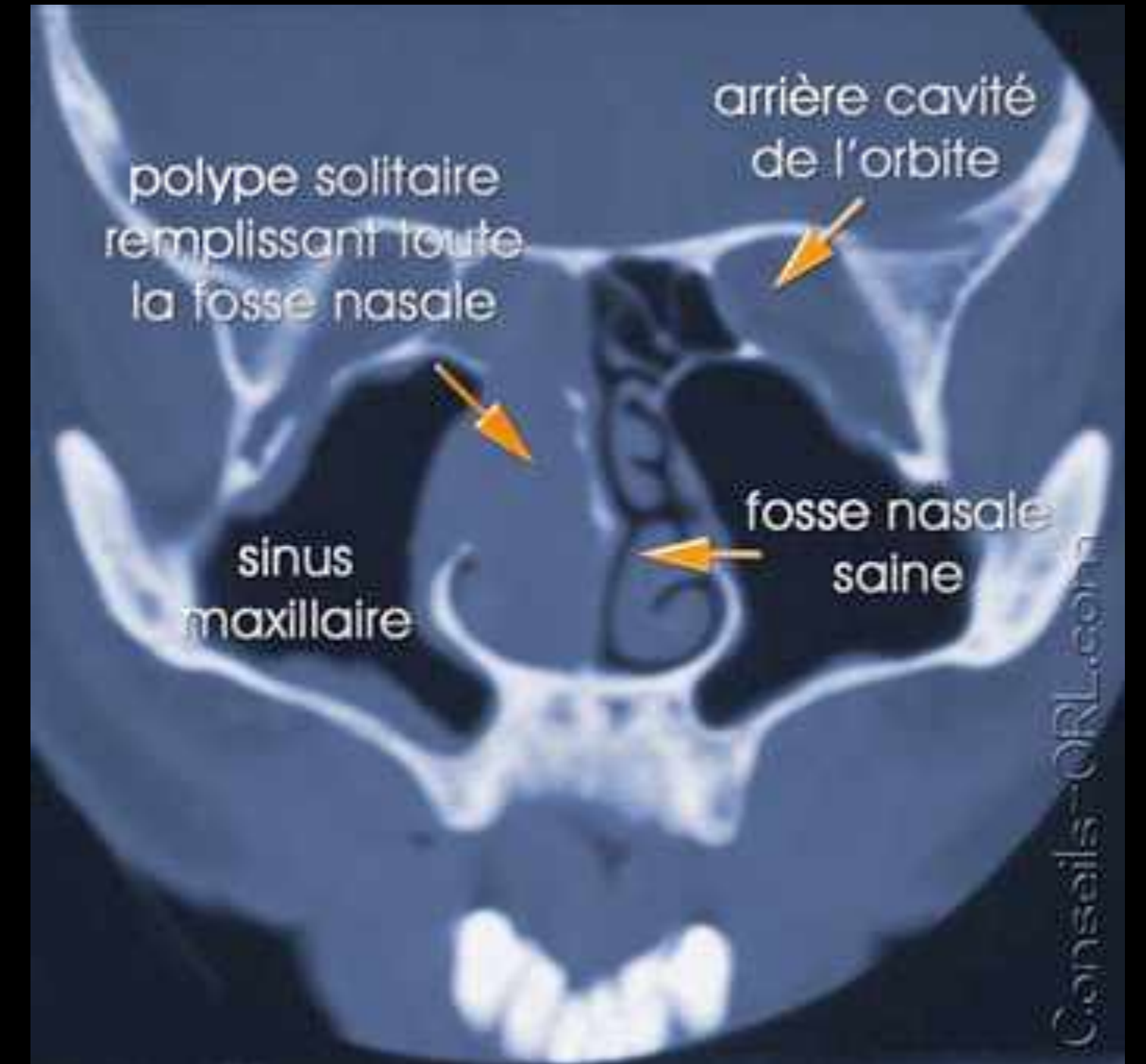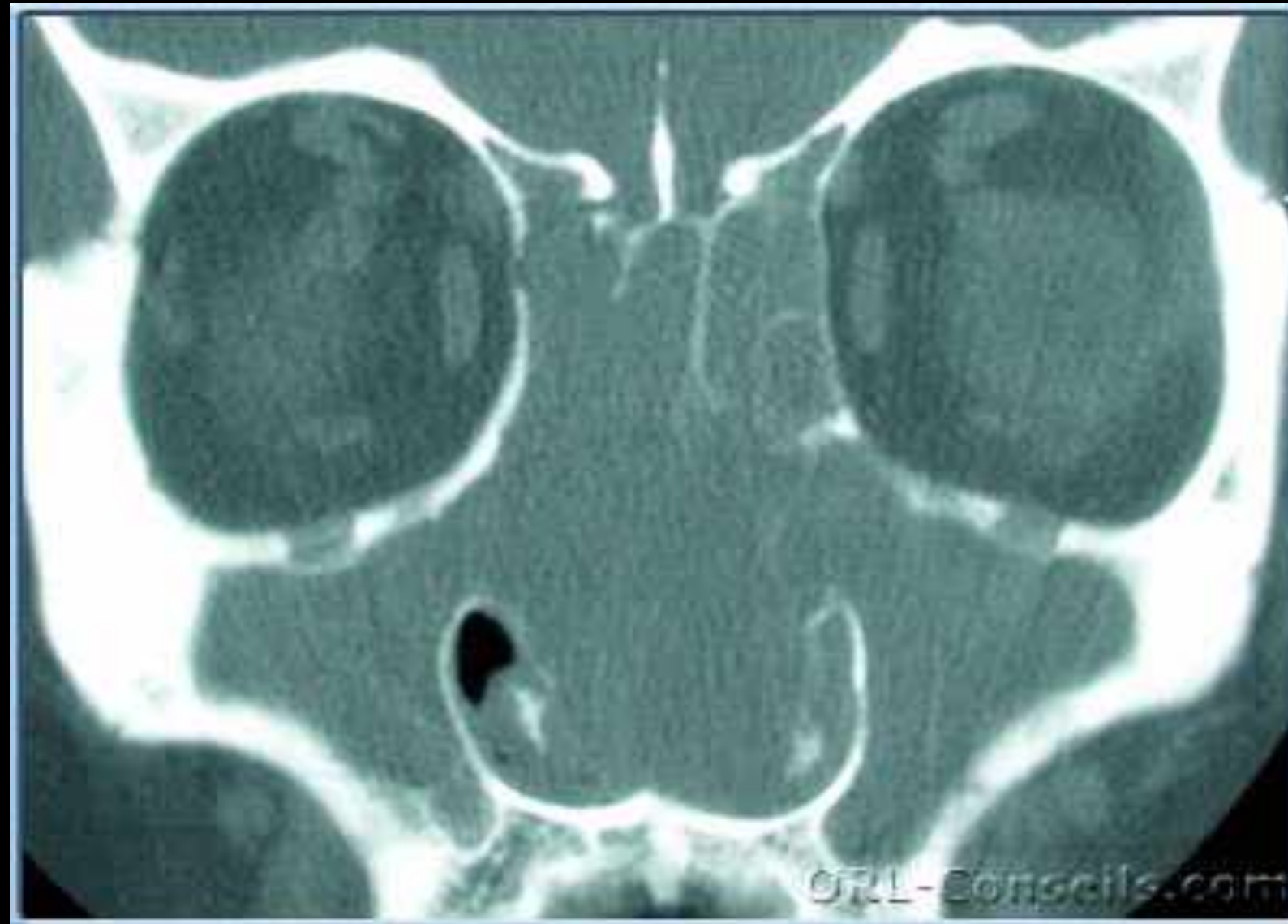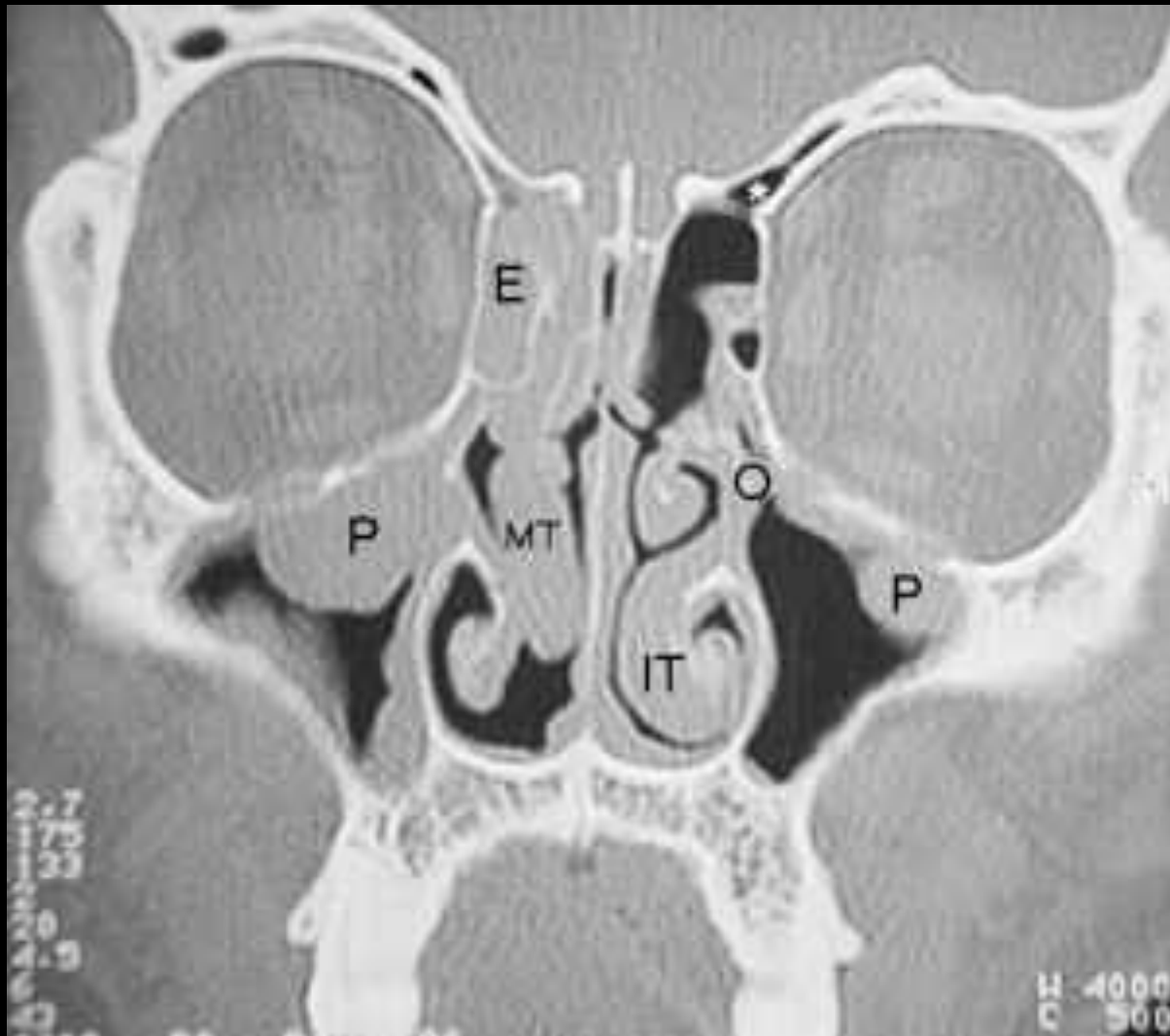
GREFFE DU SINUS



Adresser en ORL pour avis

Pathologies et Traitements

GREFFE DU SINUS



Polype isolé ou polyposse ?

GREFFE DU SINUS

Polype isolé ou polypose ?

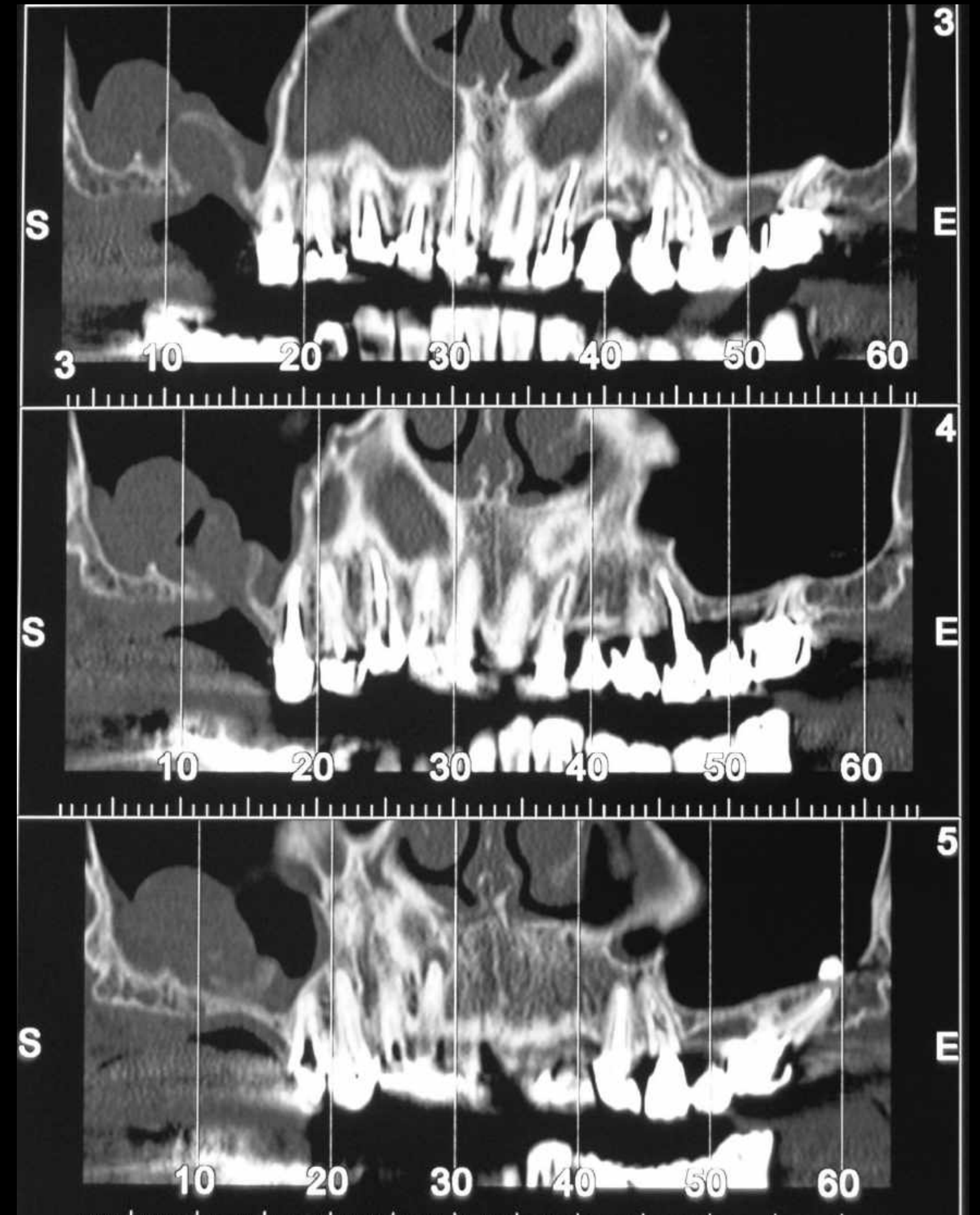
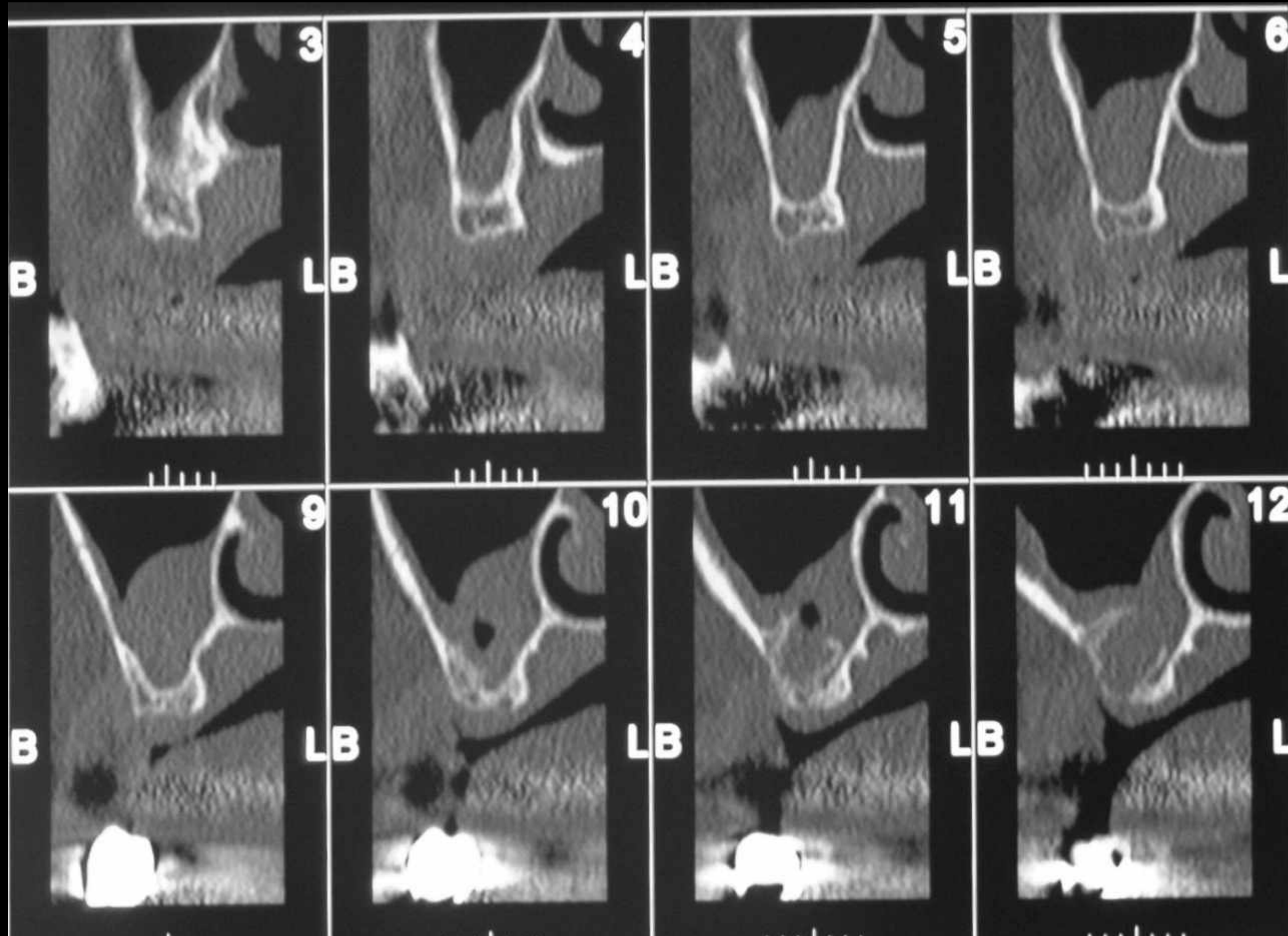
Le polype s'est développé au dépend du bas fond sinusien
moins d'1/3 du volume du sinus :

On peut intervenir !

Polype à proximité du méat moyen ou polypose :

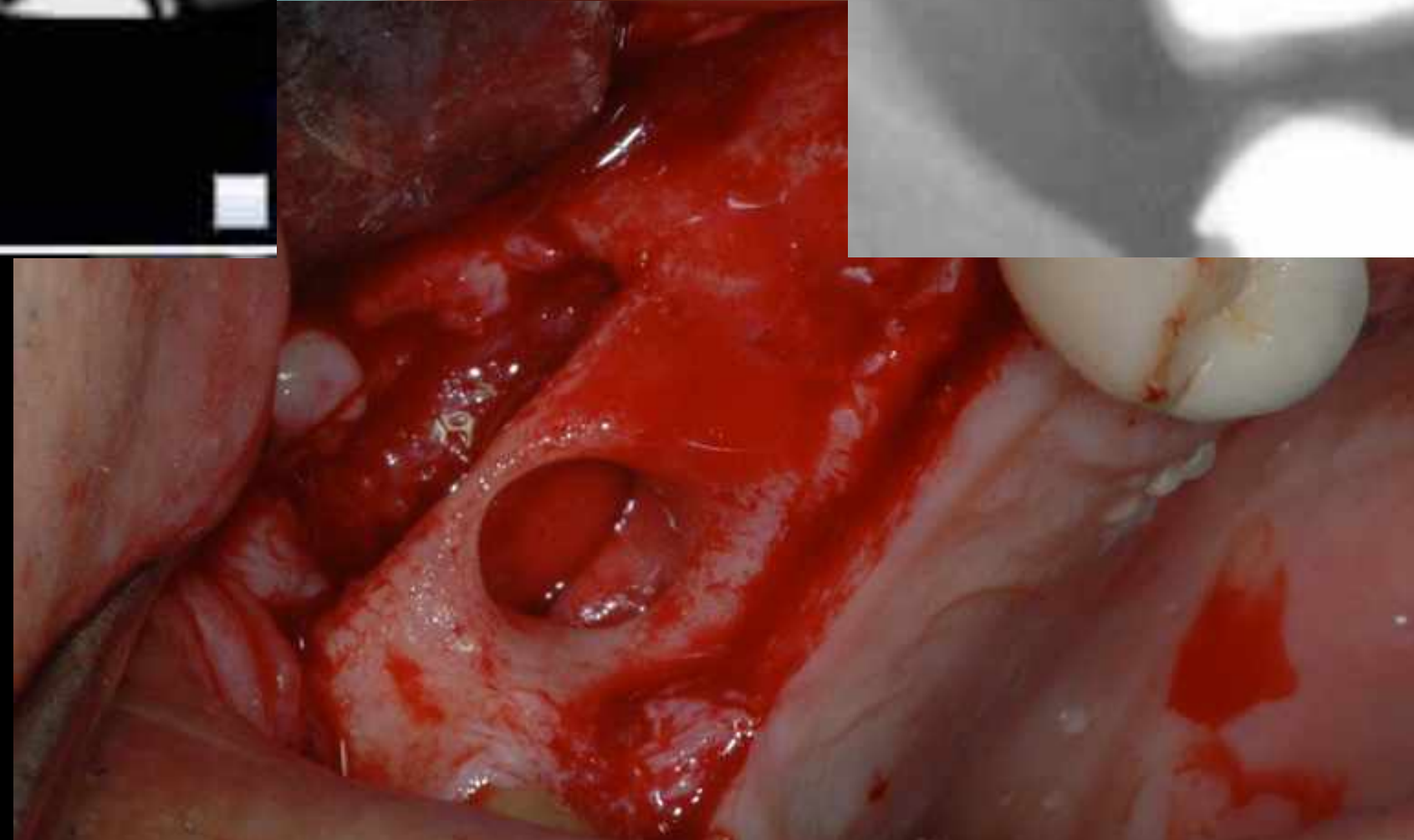
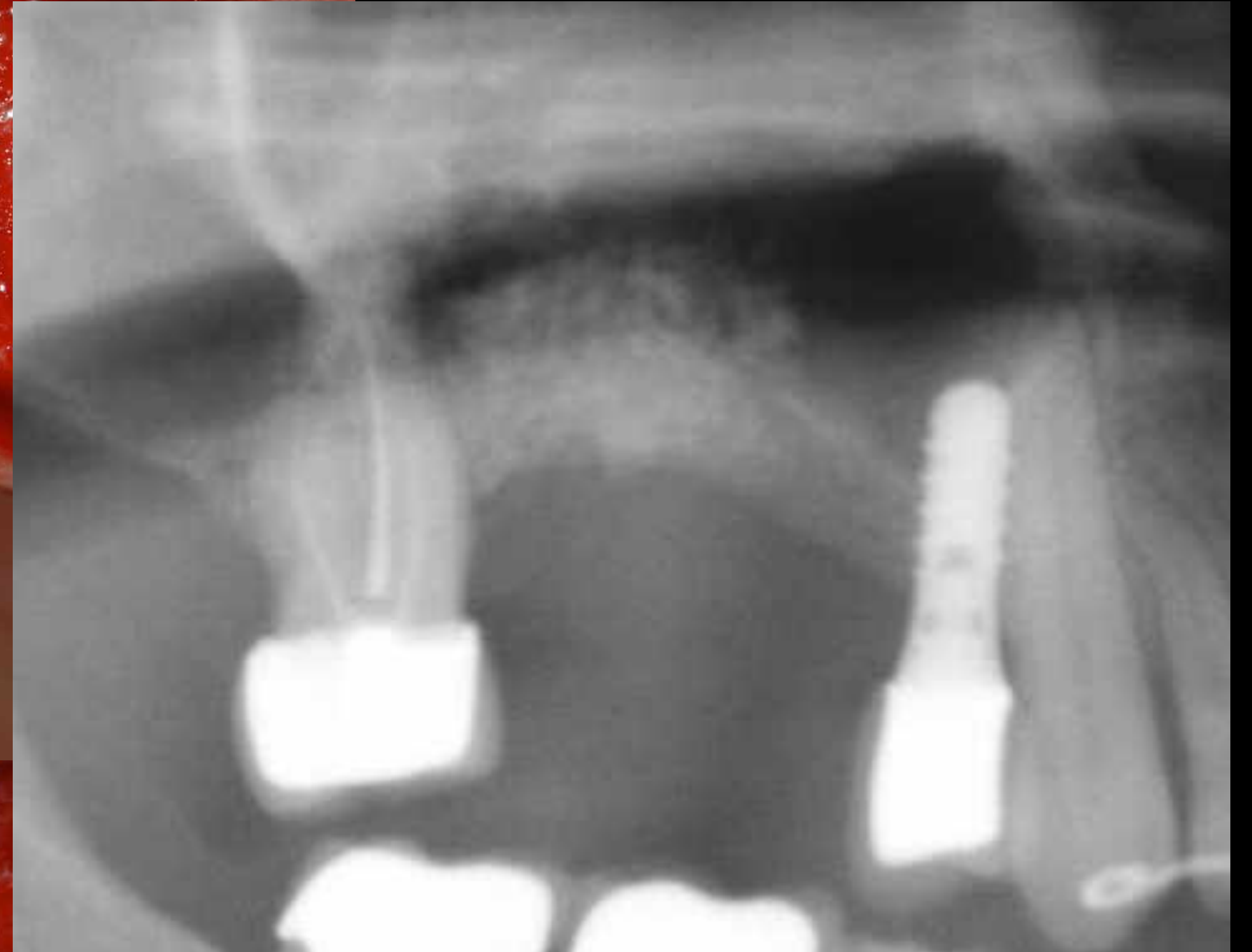
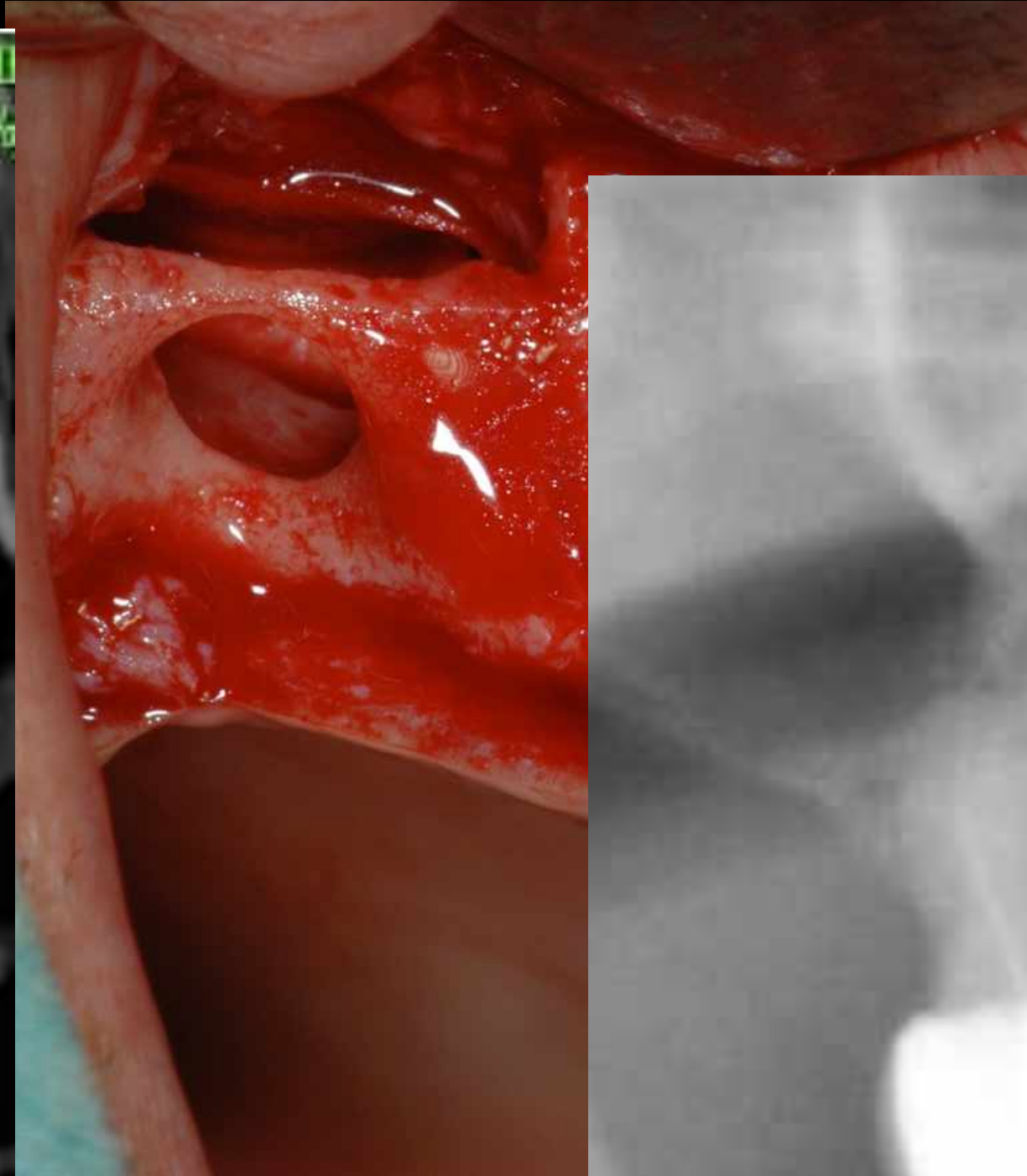
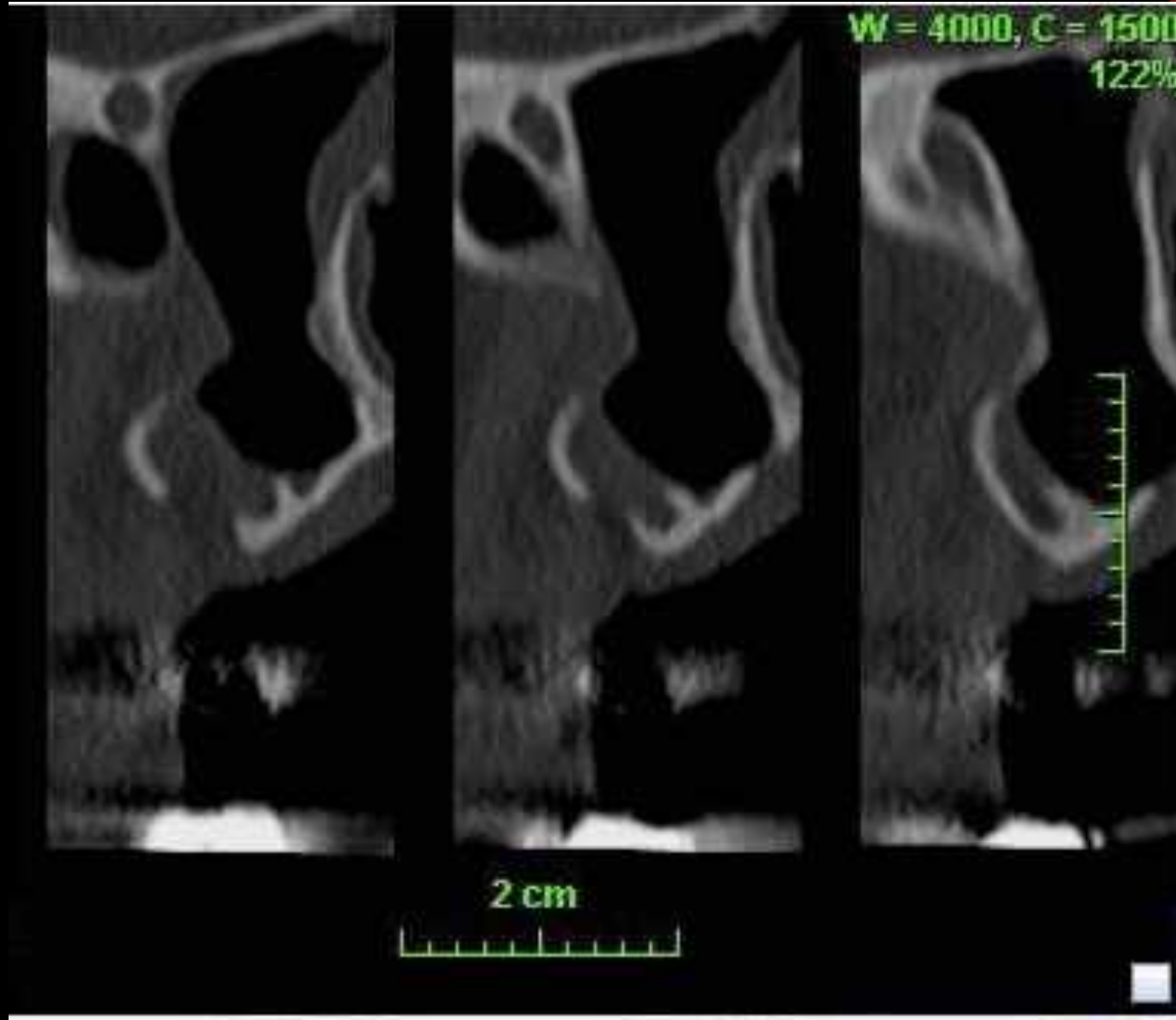
On adresse à un ORL !

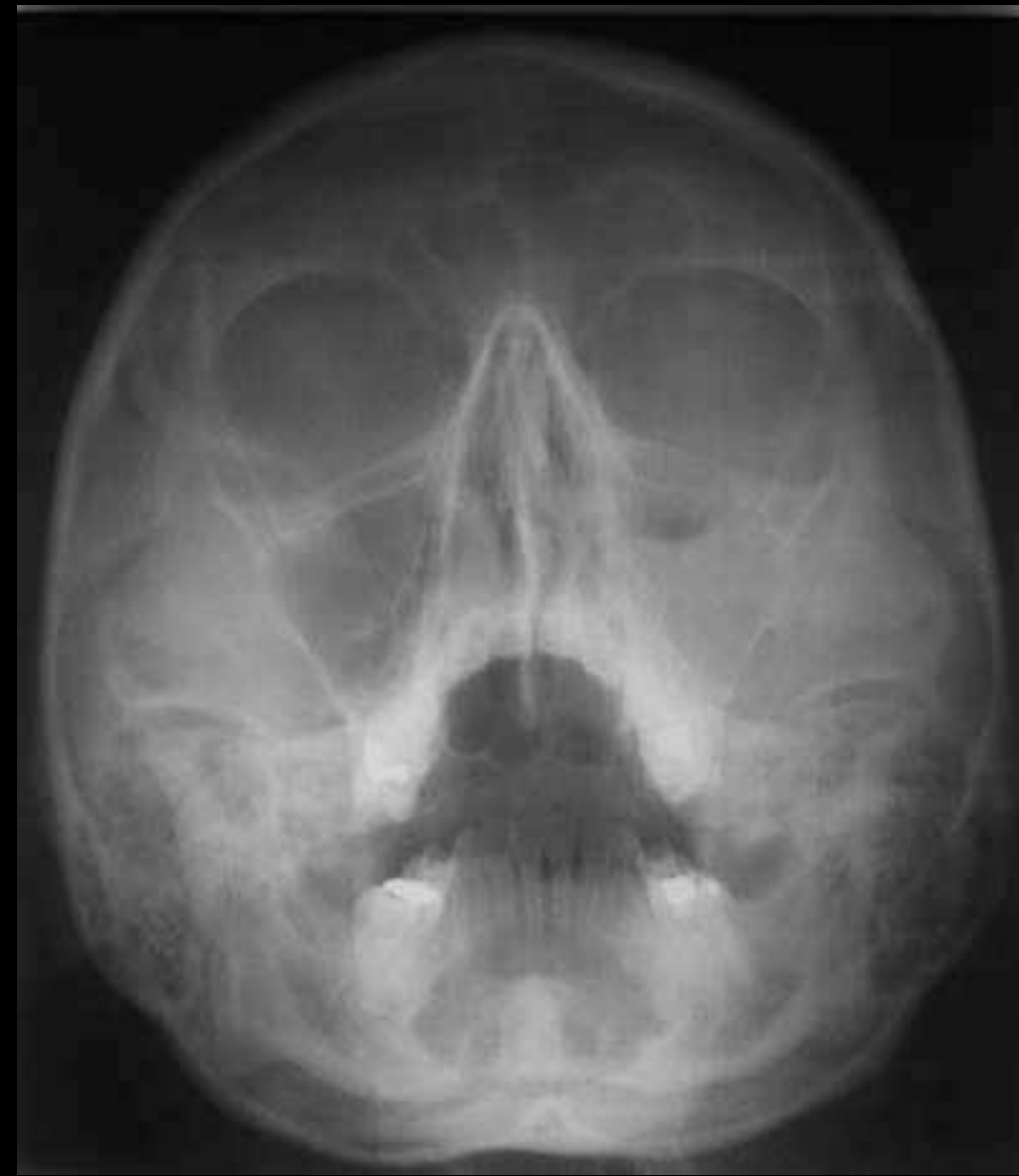
Polype isolé du bas fond sinusien



Je fais ou je ne fais pas ?

Sinus maxillaire

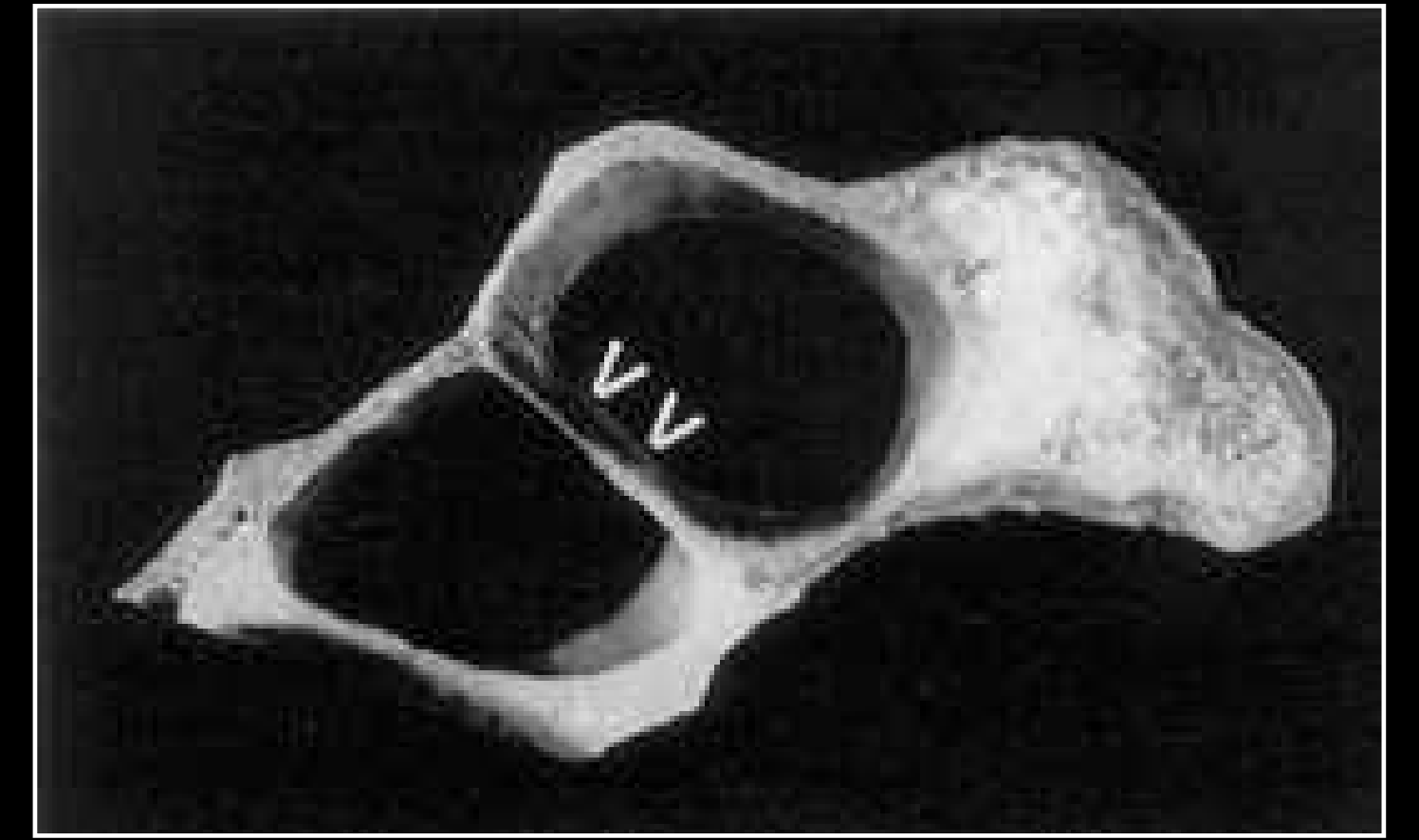
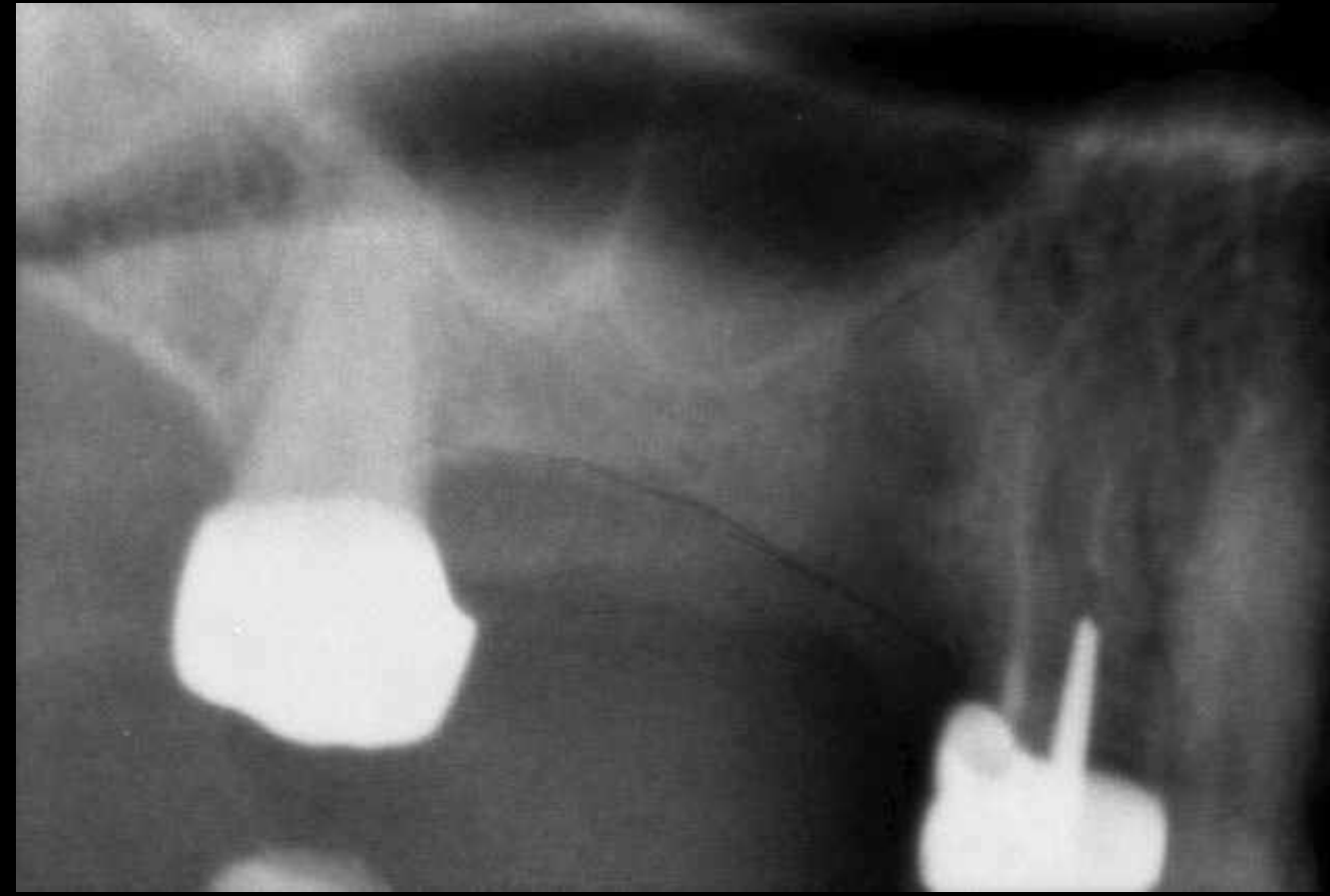





L'indication d'une expertise O.R.L s'impose

-chez les patients aux antécédents rhinosinusiens
(27% des patients)

-chez les patients présentant des images radiologiques
douteuses



On n'interviendra pas lors

-de pathologie tumorale

-de pathologie sinusienne récidivante après méatotomie

-d'anomalies osseuses du plancher

*haemophilus
influenzae + streptococcus
pneumoniae
staphylococcus
anaerobies (sinusite)*

Traitement antibiotique pré-opératoire

-Amoxicilline + Acide Clavulanique 1g 2xj pdt 8j (Augmentin)

Association Rovamycine 3x4Mui/Metronidazole 3x500mg 8j (Josacyne/Flagyl)

Association Clindamycine 2x300mg/Metronidazole 2x500mg 8j (Dalacine/Flagyl)

Quinolone Izilox 1cpr/J 7j

Anti-Inflammatoire Stéroïdien : Prednisolone 20mg 1mg/kg pdt 5j

Antalgique Niveau 2

Ultra-levure... Bain de bouche ?

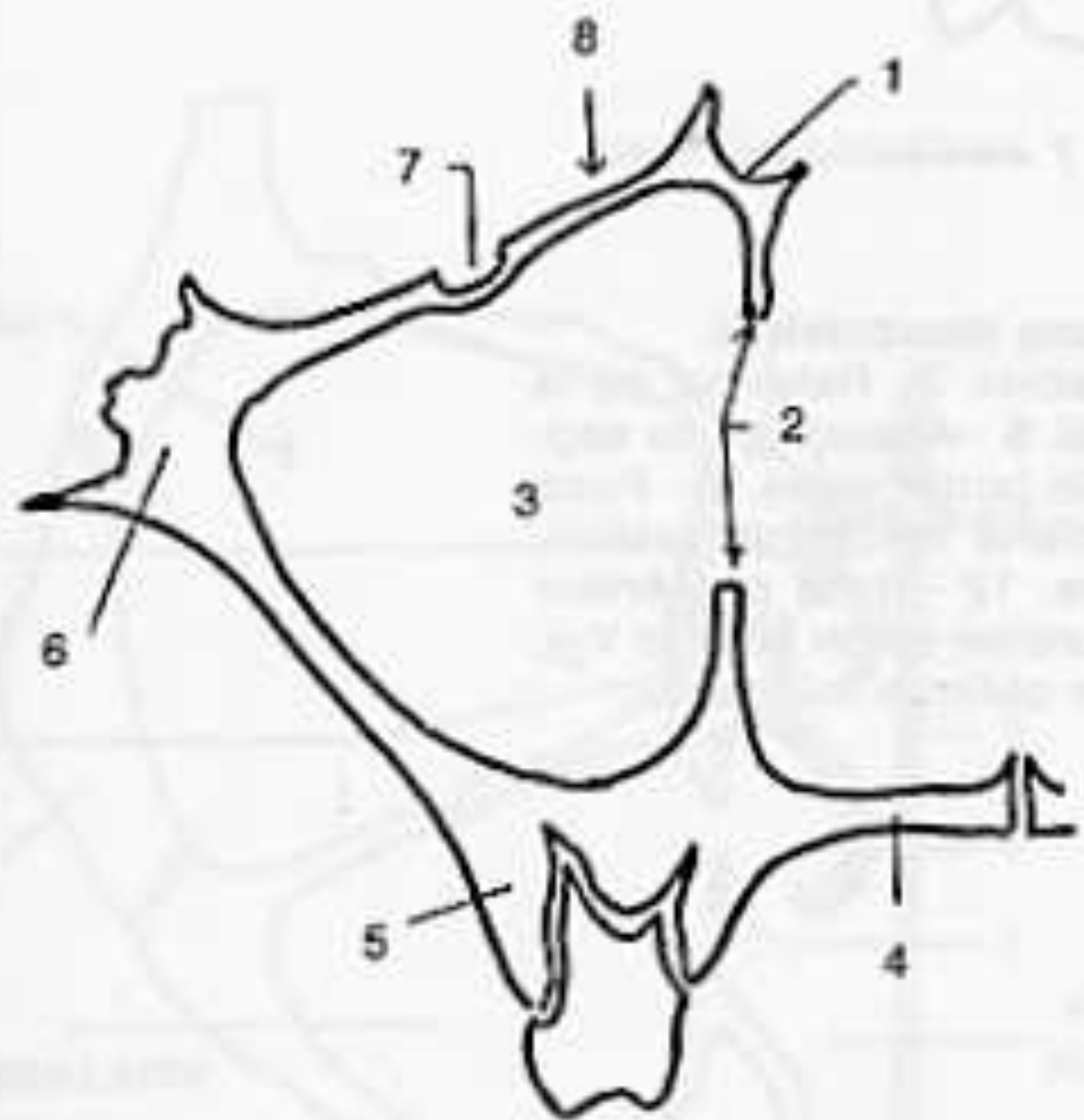
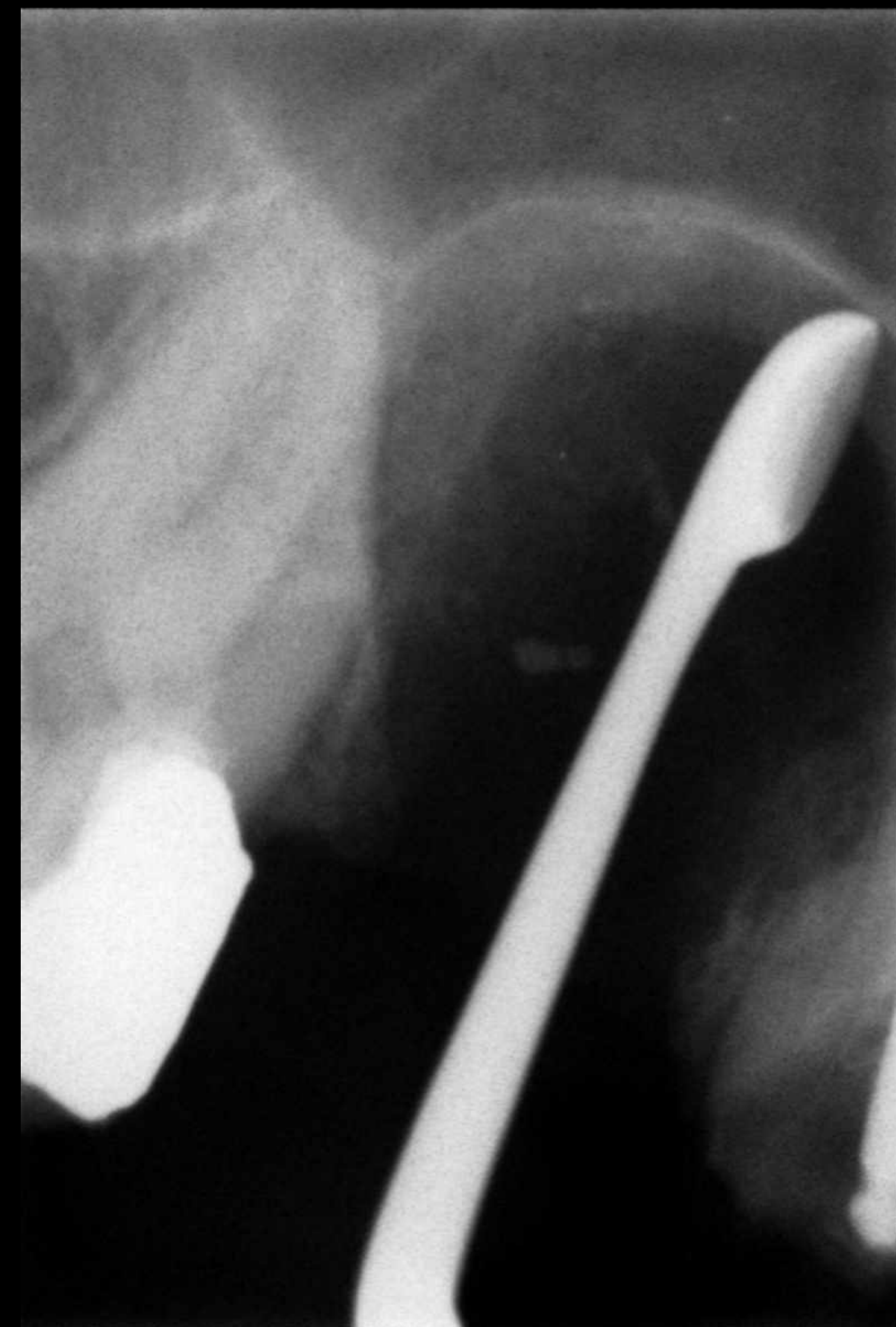
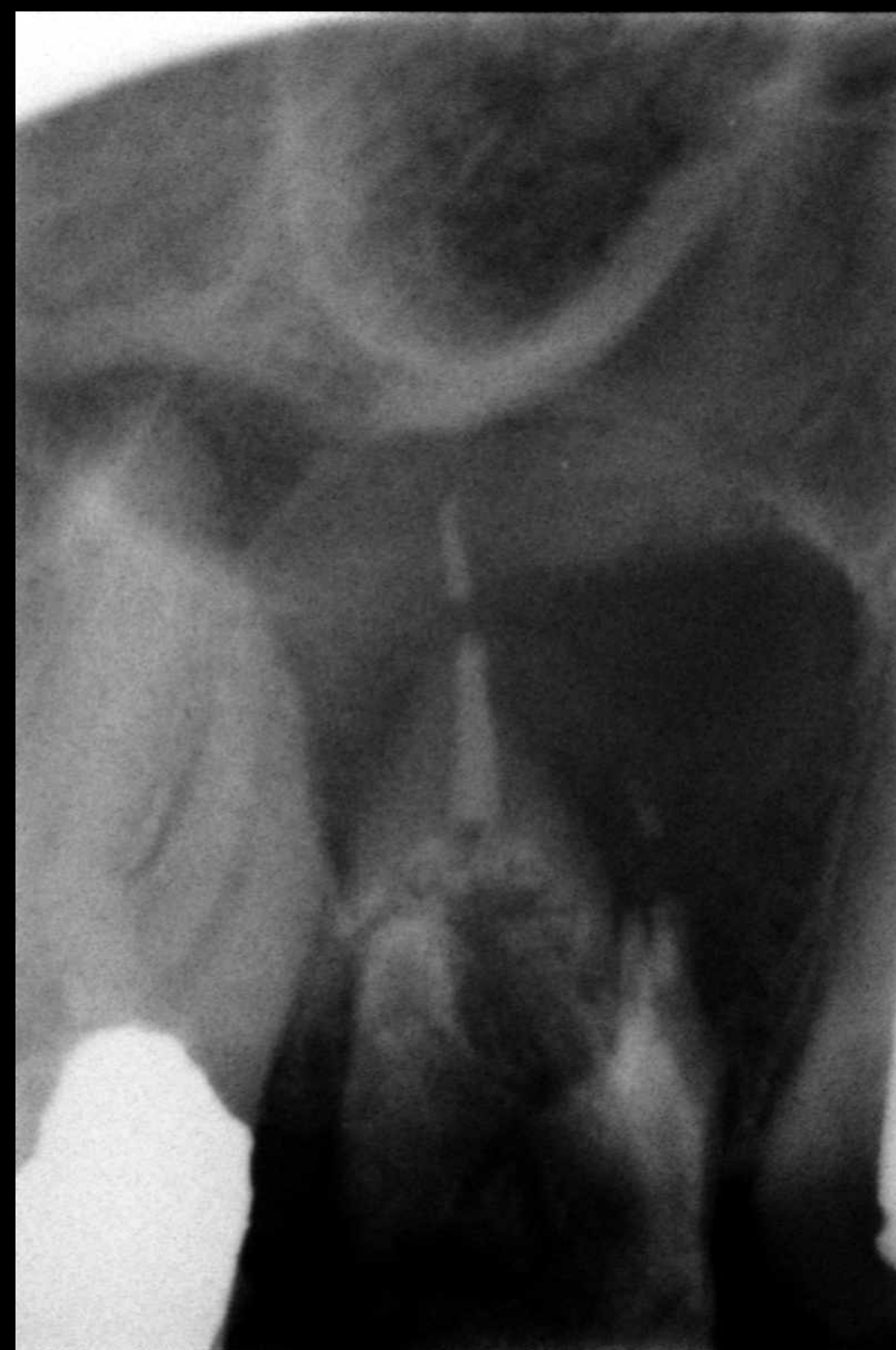
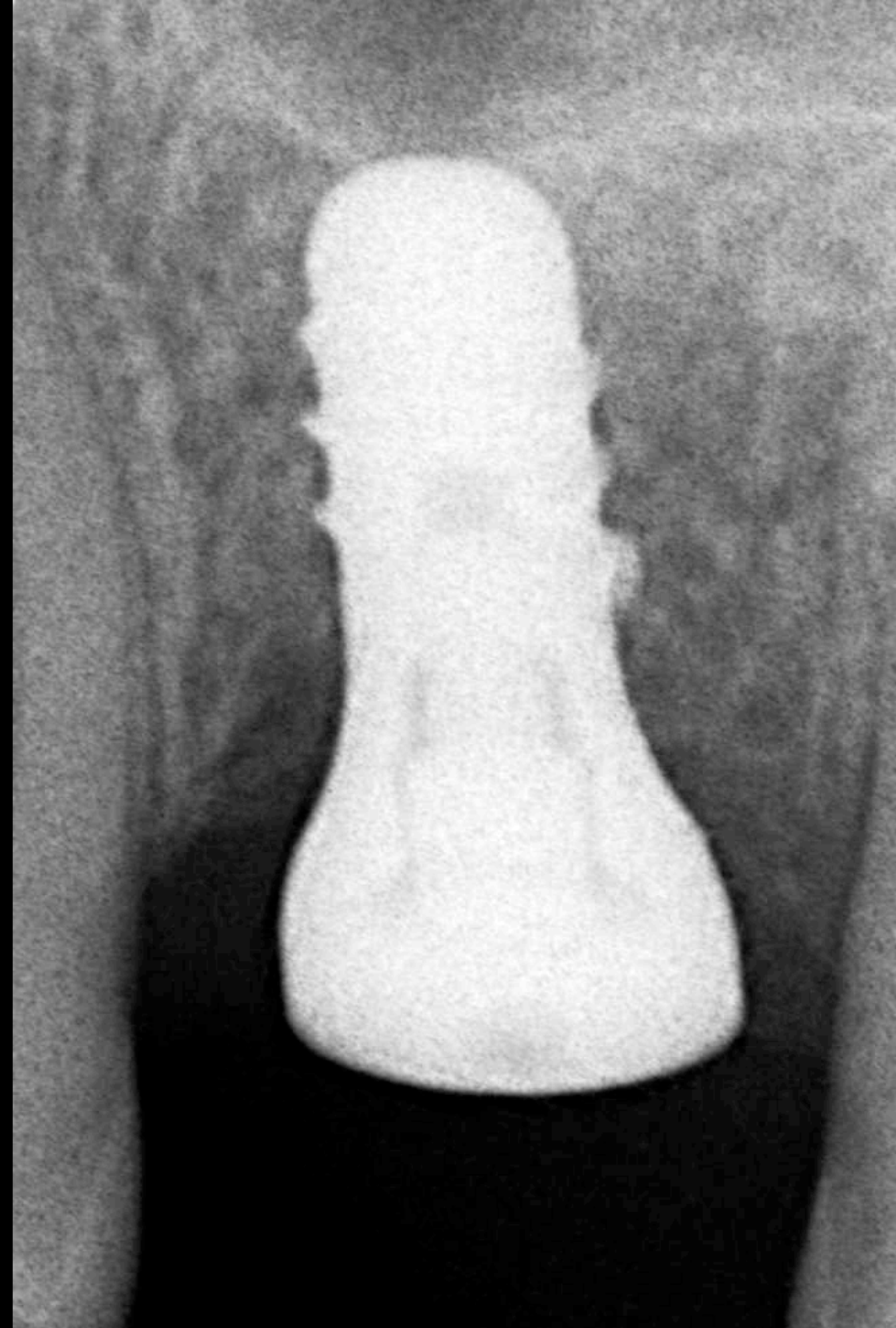
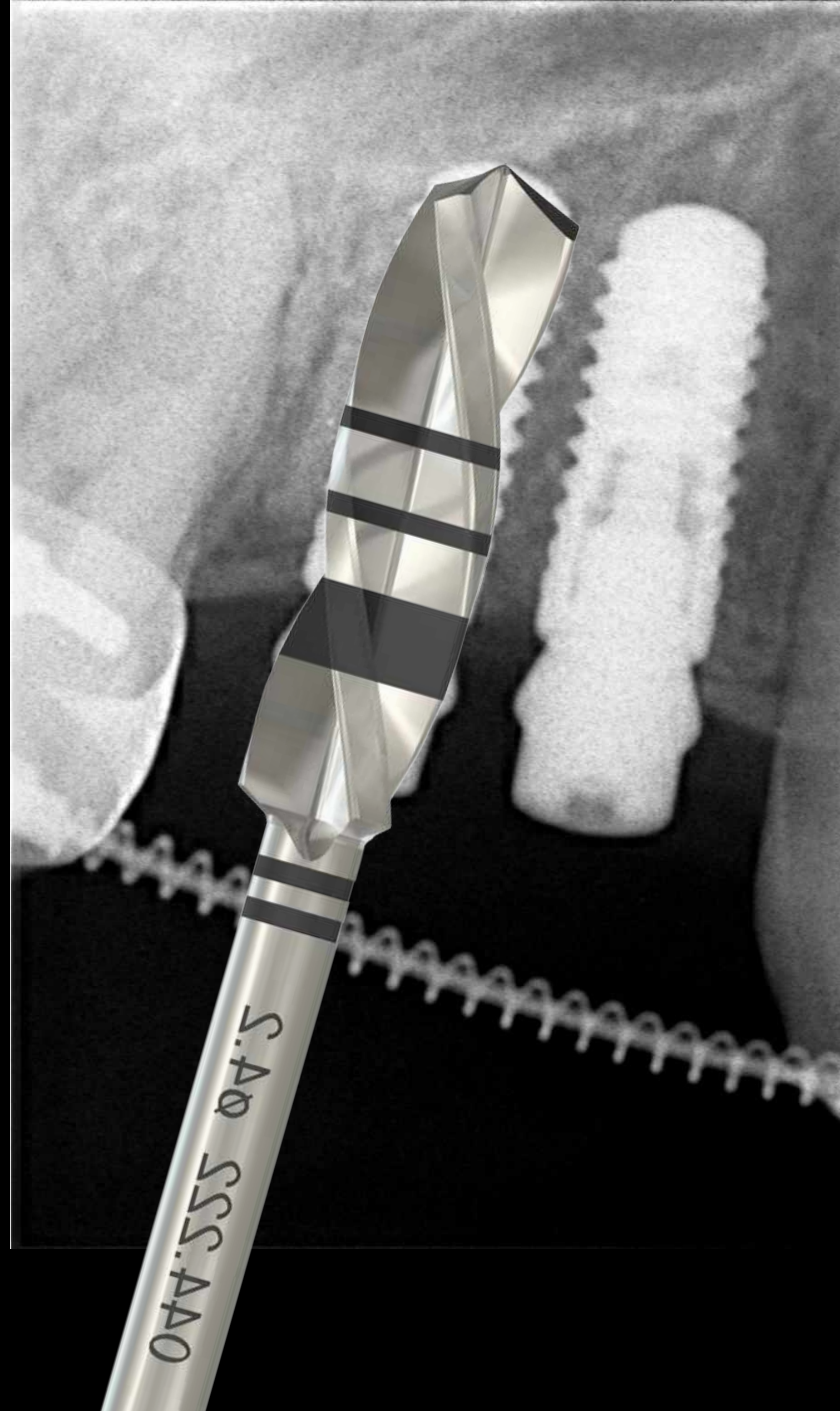
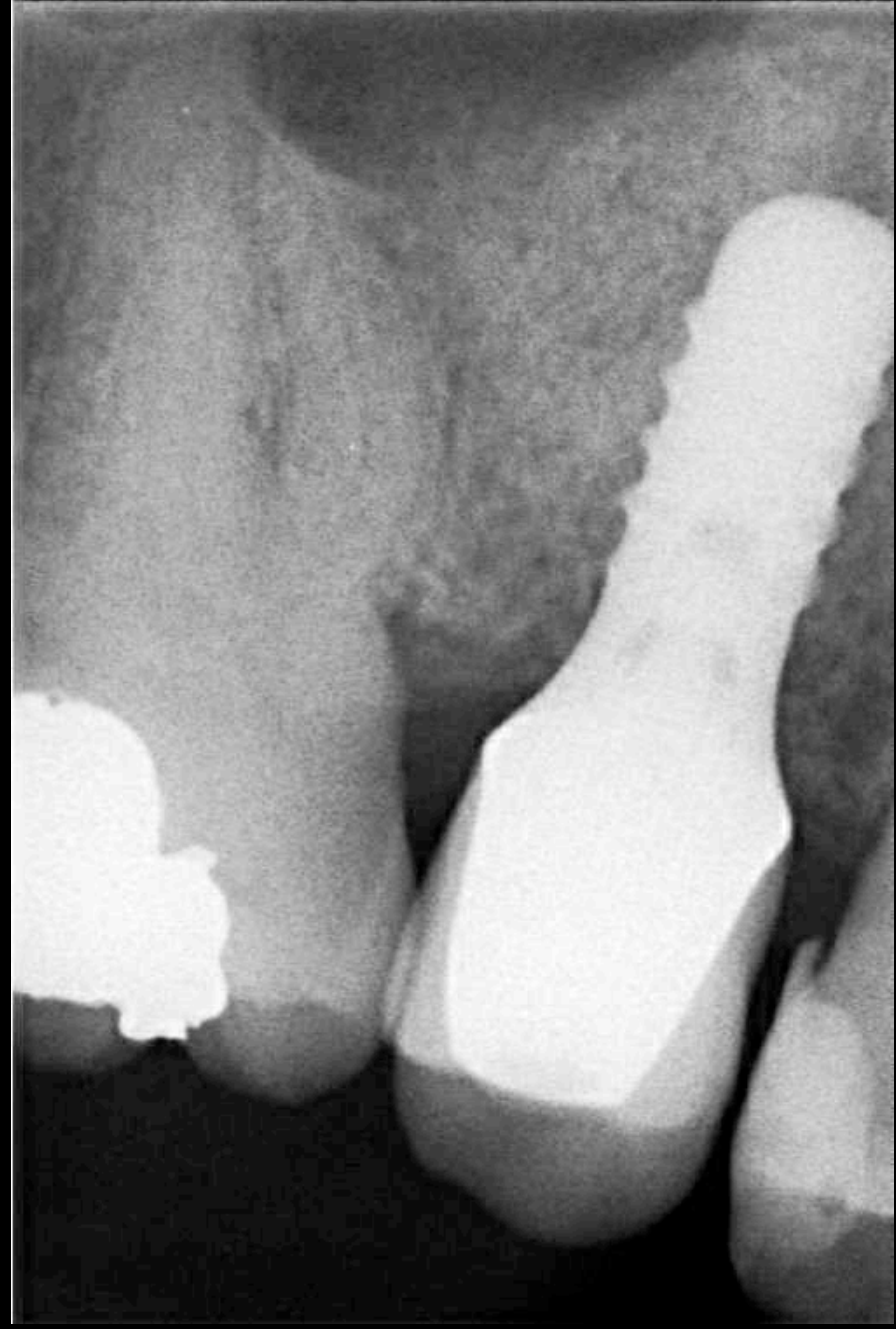
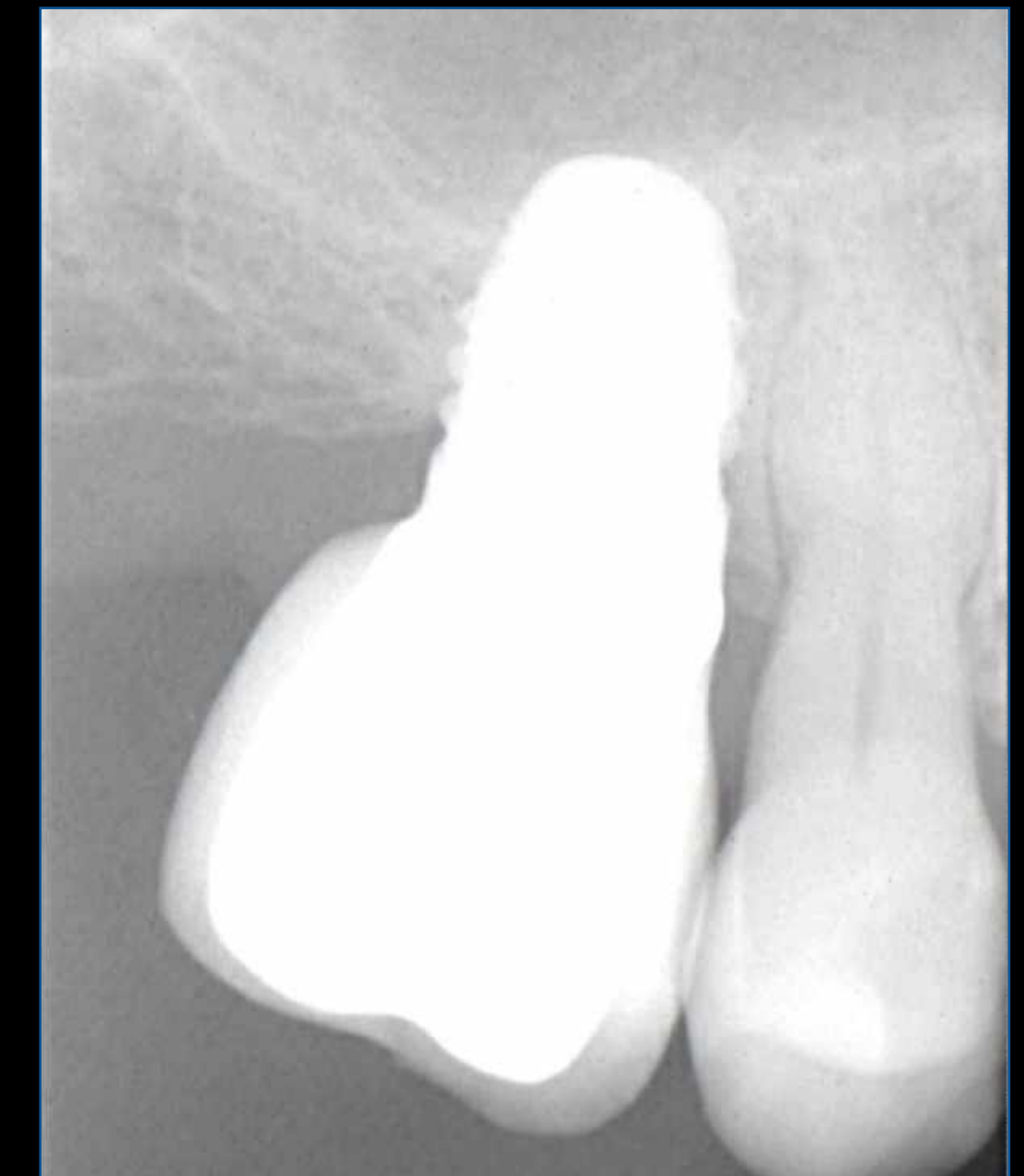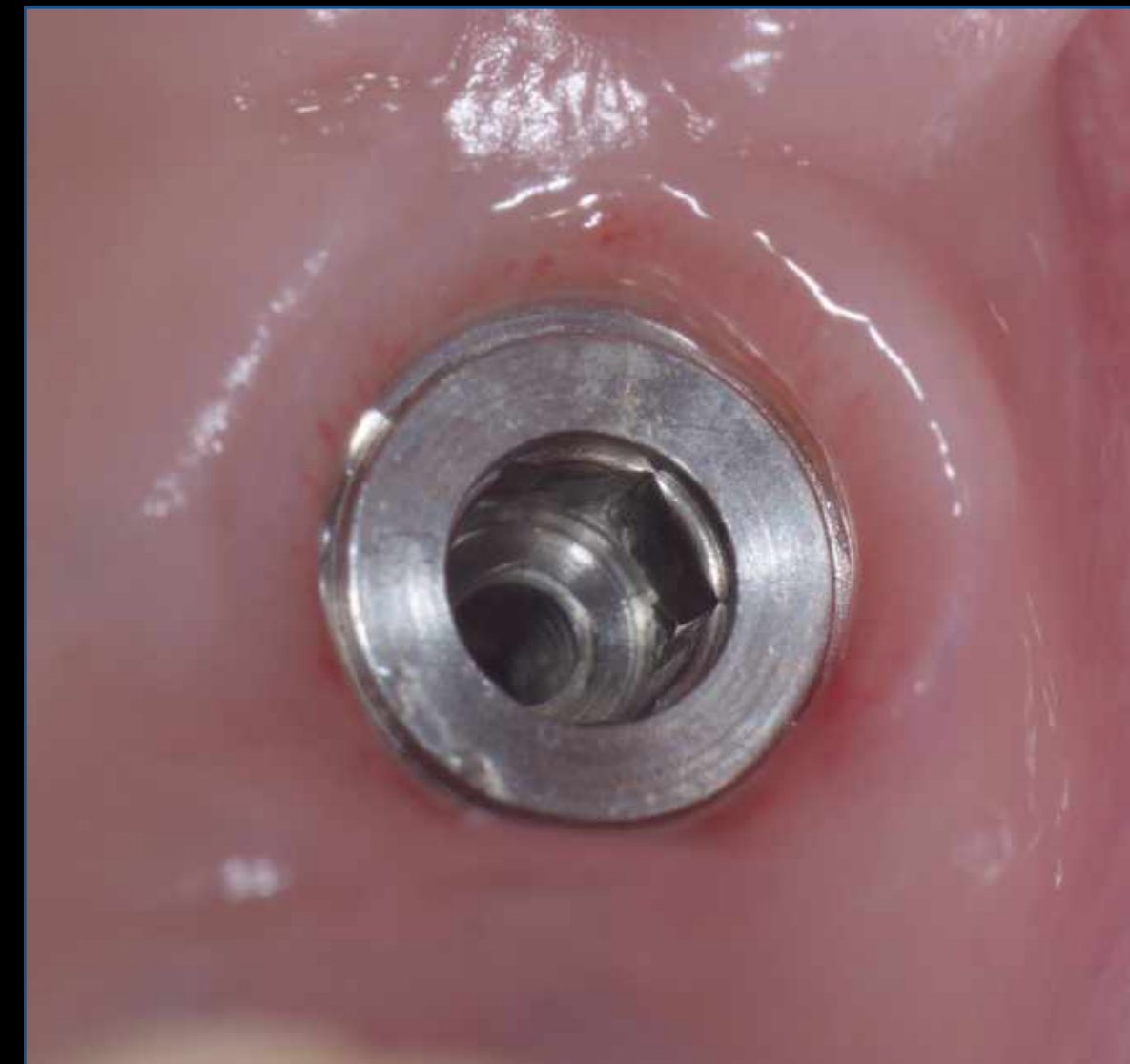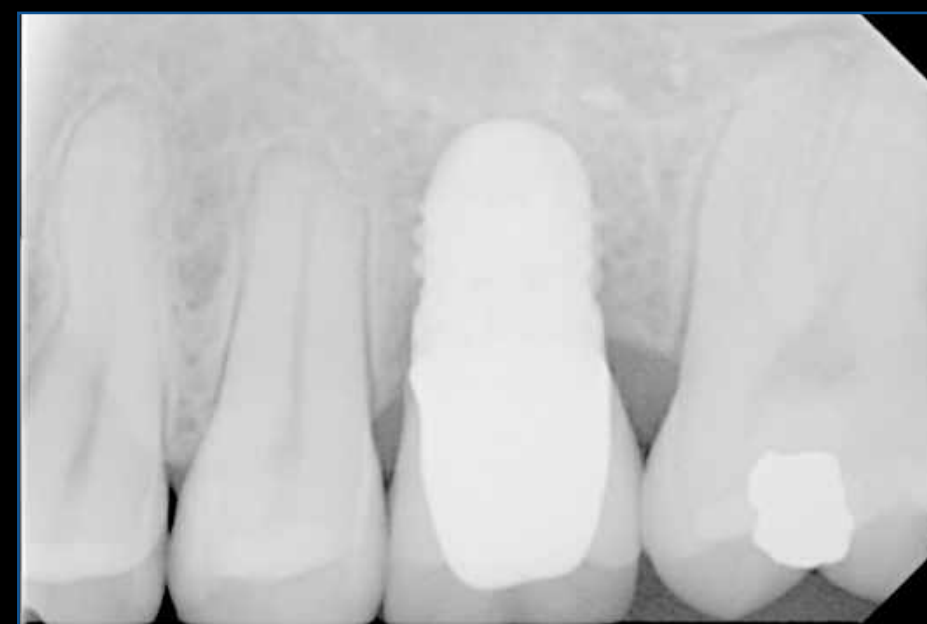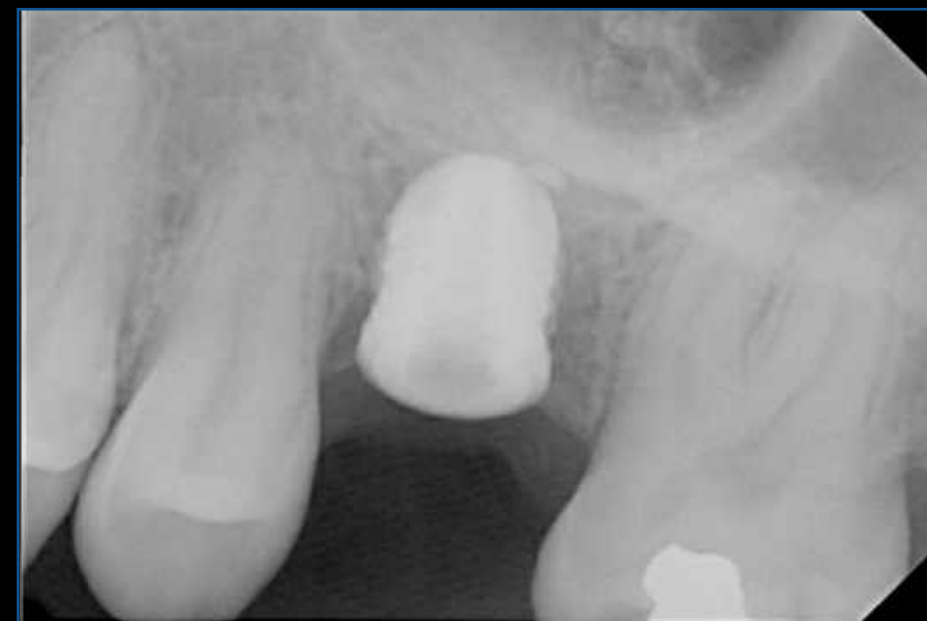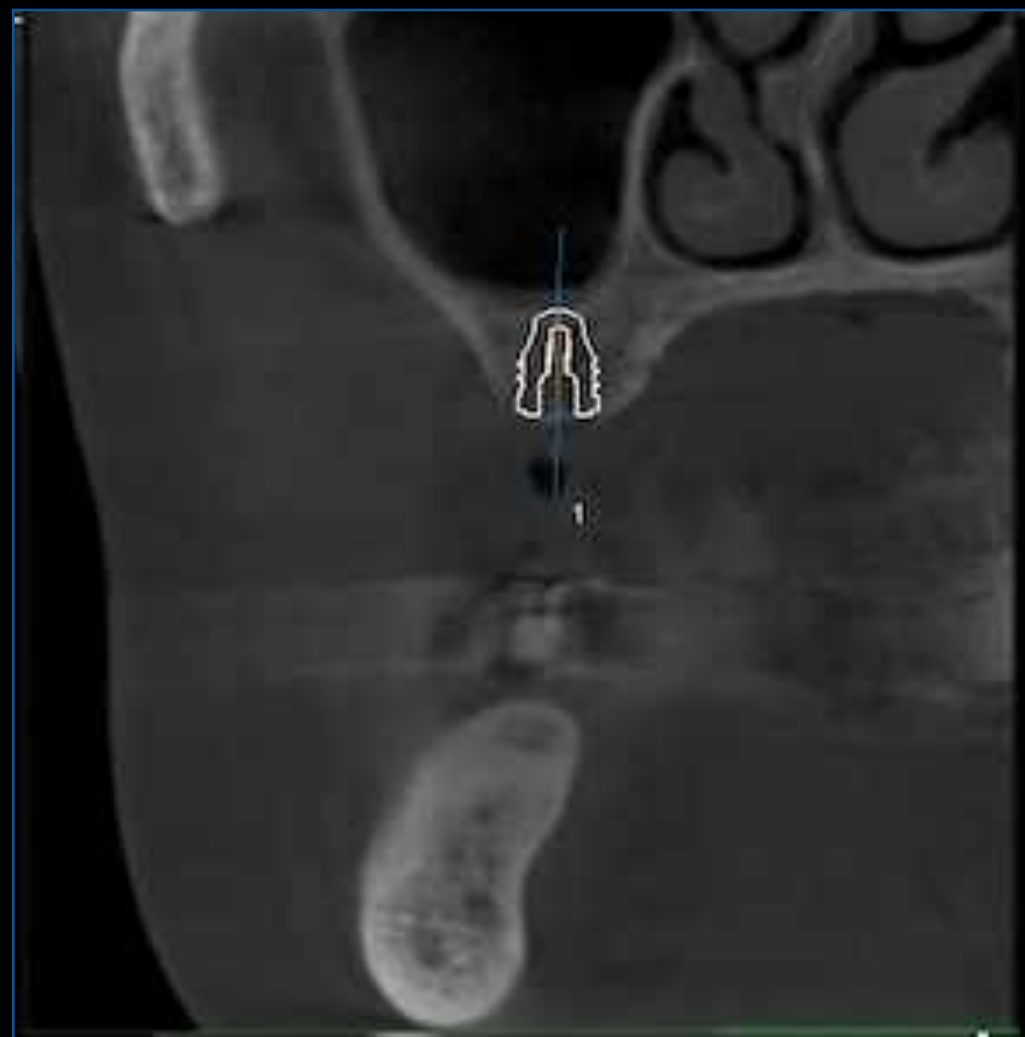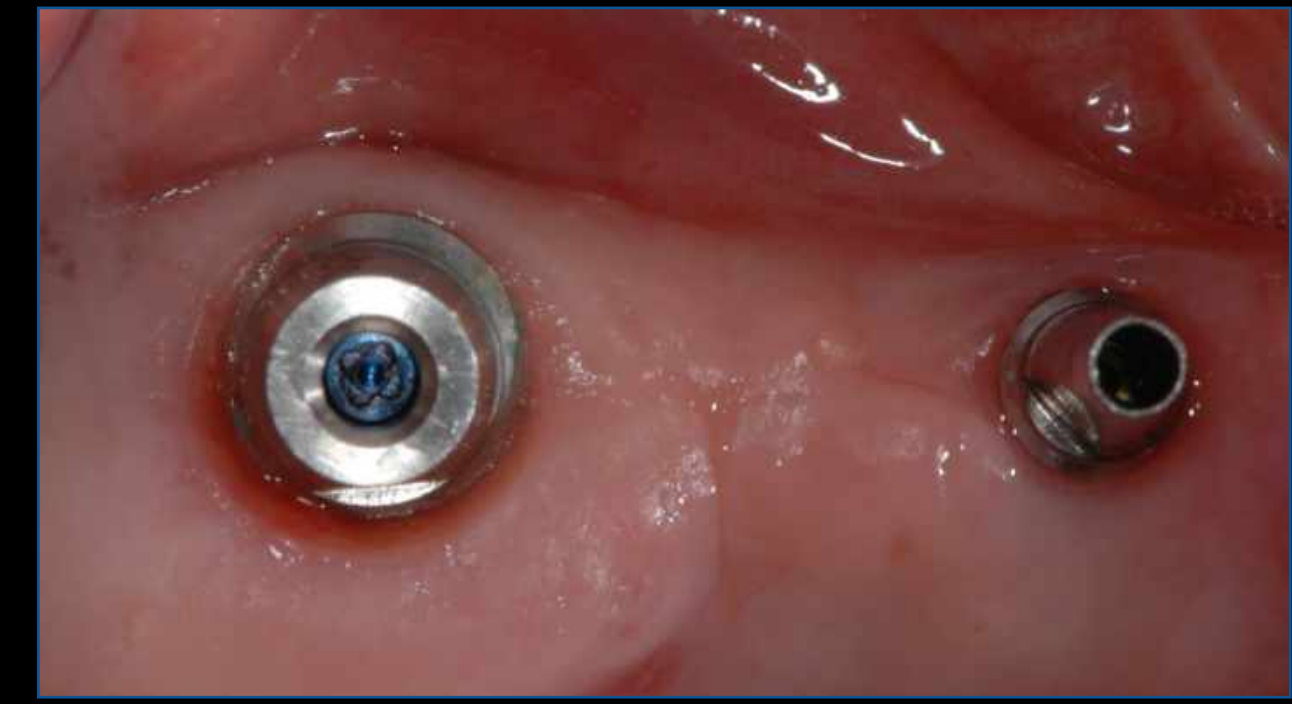
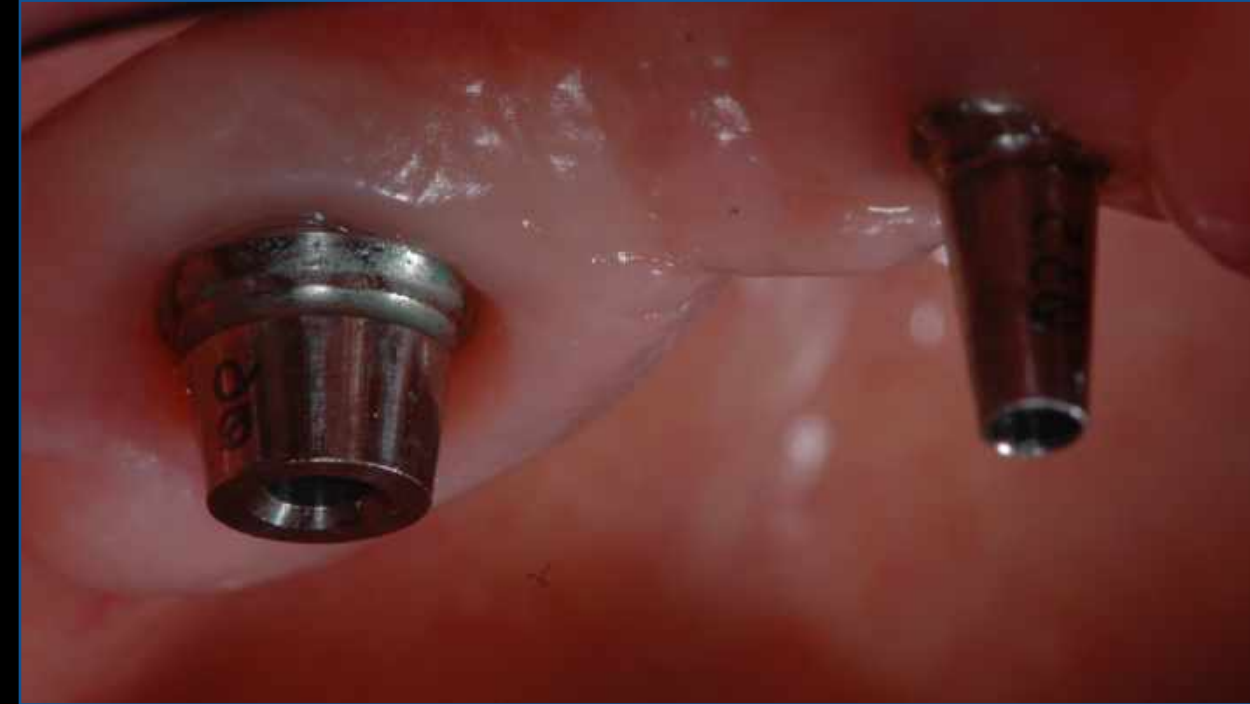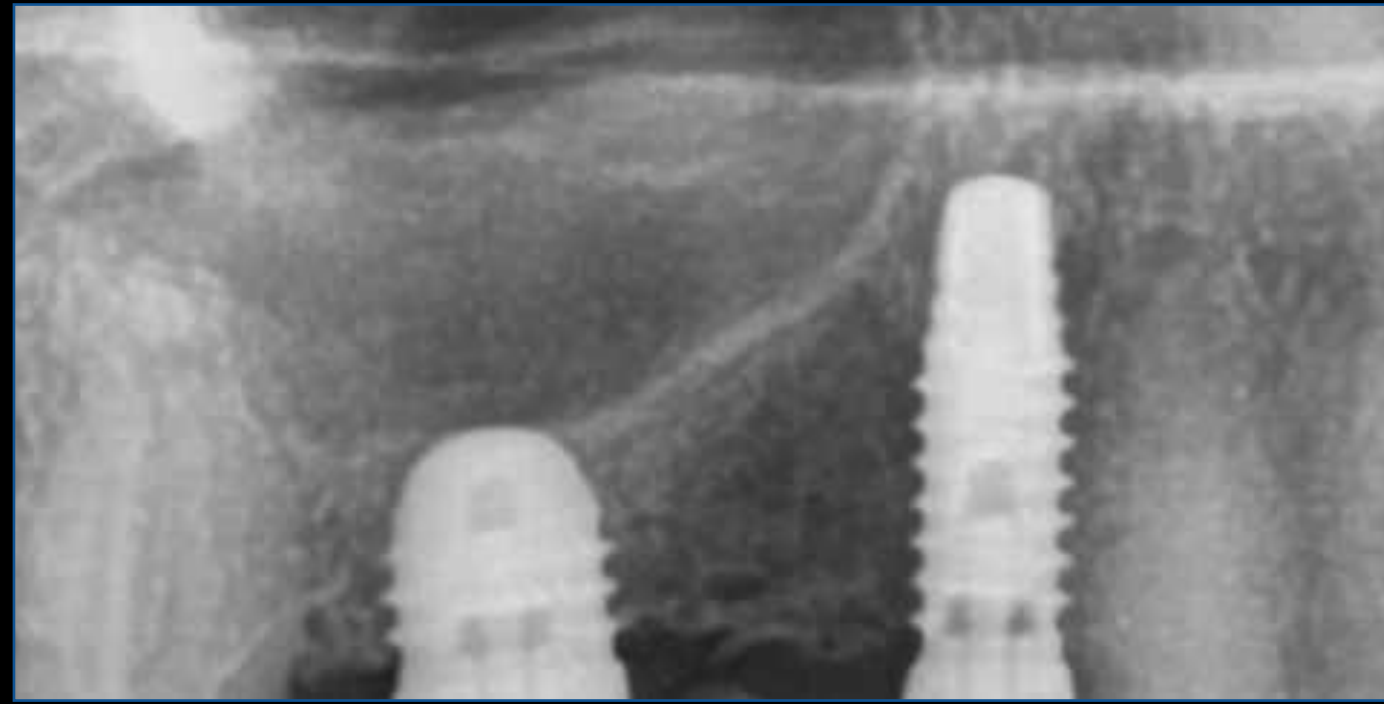Fig. 108 — Maxillaire : coupe frontale.

1 - Cellule ethmoïdo-maxillaire. 2 - Hiatus maxillaire. 3 - Sinus maxillaire. 4 - Processus palatin. 5 - Processus alvéolaire. 6 - Processus zygomatique. 7 - Sillon infra-orbitaire. 8 - Face orbitaire (supérieure).






LES IMPLANTS COURTS



HASSON JN, HASSID J, AUBAZAC D, ZEMAN P. Clinical and Radiological performance of Short dental Implant (6,5mm) : 2 years Follow up. J. of Implant & Advanced Clinical dentistry

Implants courts

Qui est court ?



Les implants courts :
6 et 8mm

Les implants standards :
10mm

Influence du diamètre ?


6mm

8mm

10mm

REG


REF	implant diameter (mm)	implant length (mm)	Surface (mm ²) (*)
OP34080	3,4	8	97
OP34100		10	124
OP34120		12	151
OP34140		14	178
OP34160		16	205
OP34180		18	232
OP40060	4,0	6,5	100
OP40080		8	125
OP40100		10	159
OP40120		12	192
OP40140		14	227
OP40160		16	260
OP40180	18	296	
OP46060	4,6	6,5	115
OP46080		8	145
OP46100		10	184
OP46120		12	223
OP46140		14	263
OP52060	5,2	6,5	131
OP52080		8	165
OP52100		10	210
OP52120		12	255
OP52140		14	300




En terme de surface développée :
 $3,4/10 = 4/8 = 4,6/6,5$
 $4,6/8 = 5,2/6,5$



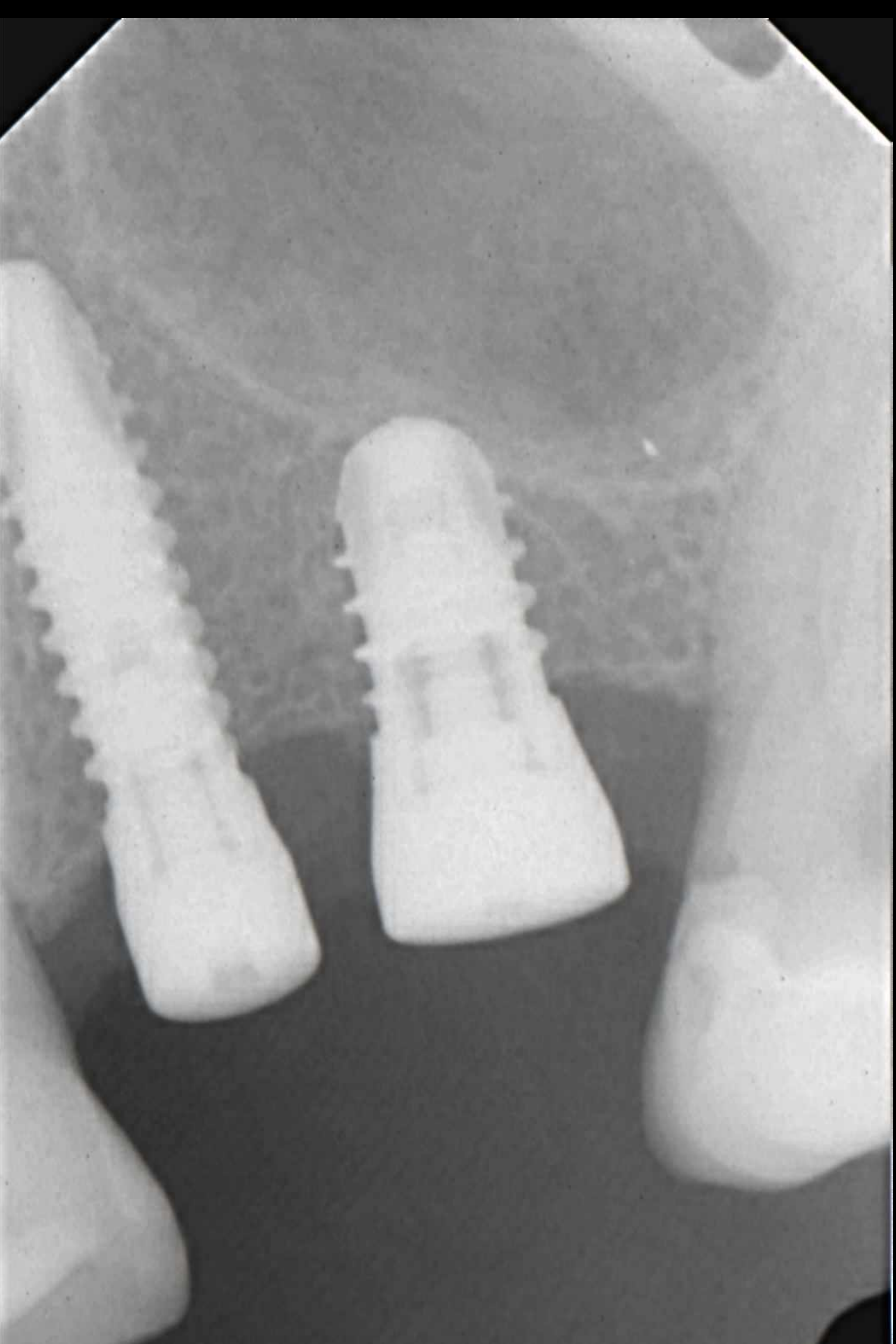
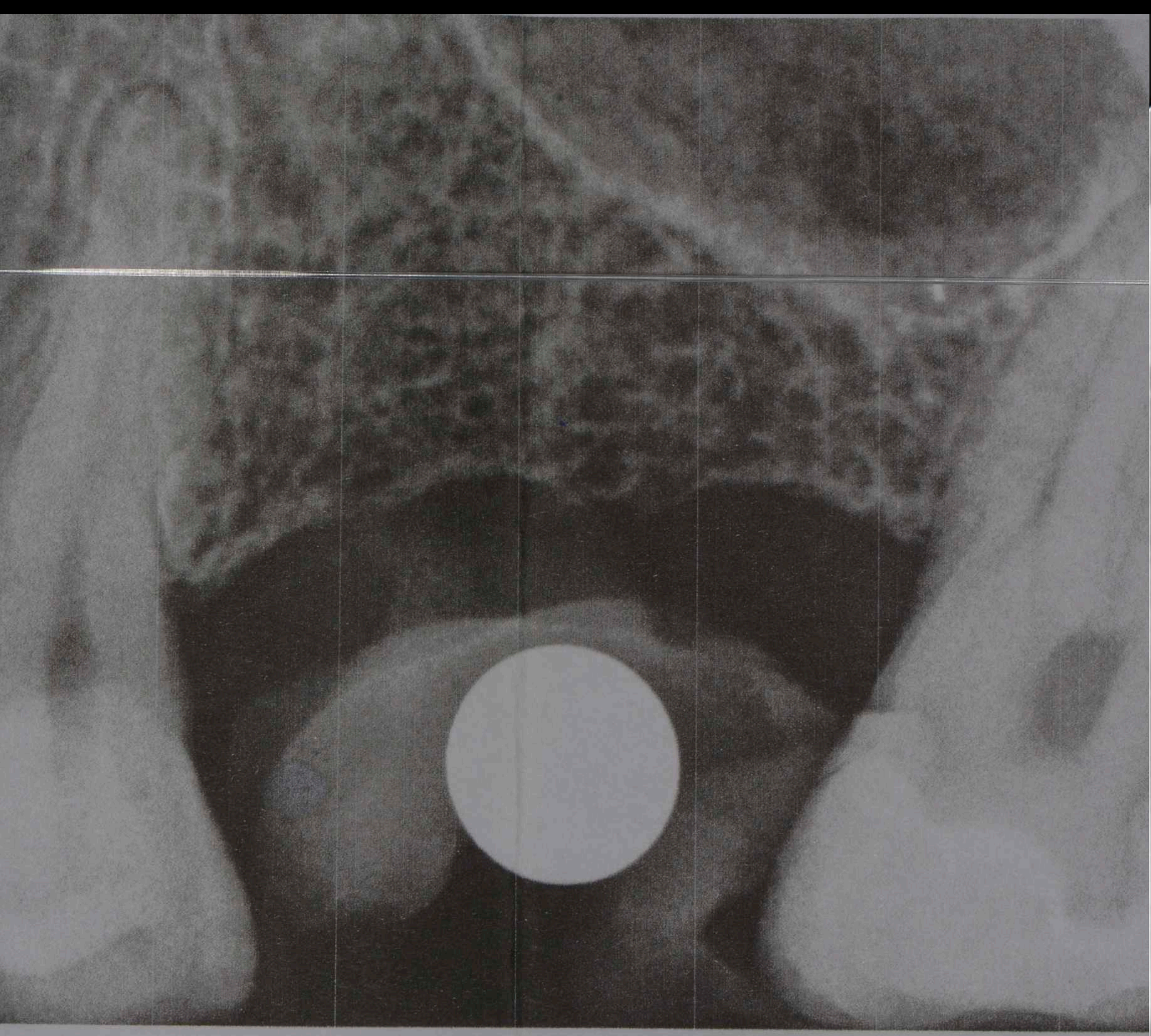
Rôle de l'état de surface



SLA



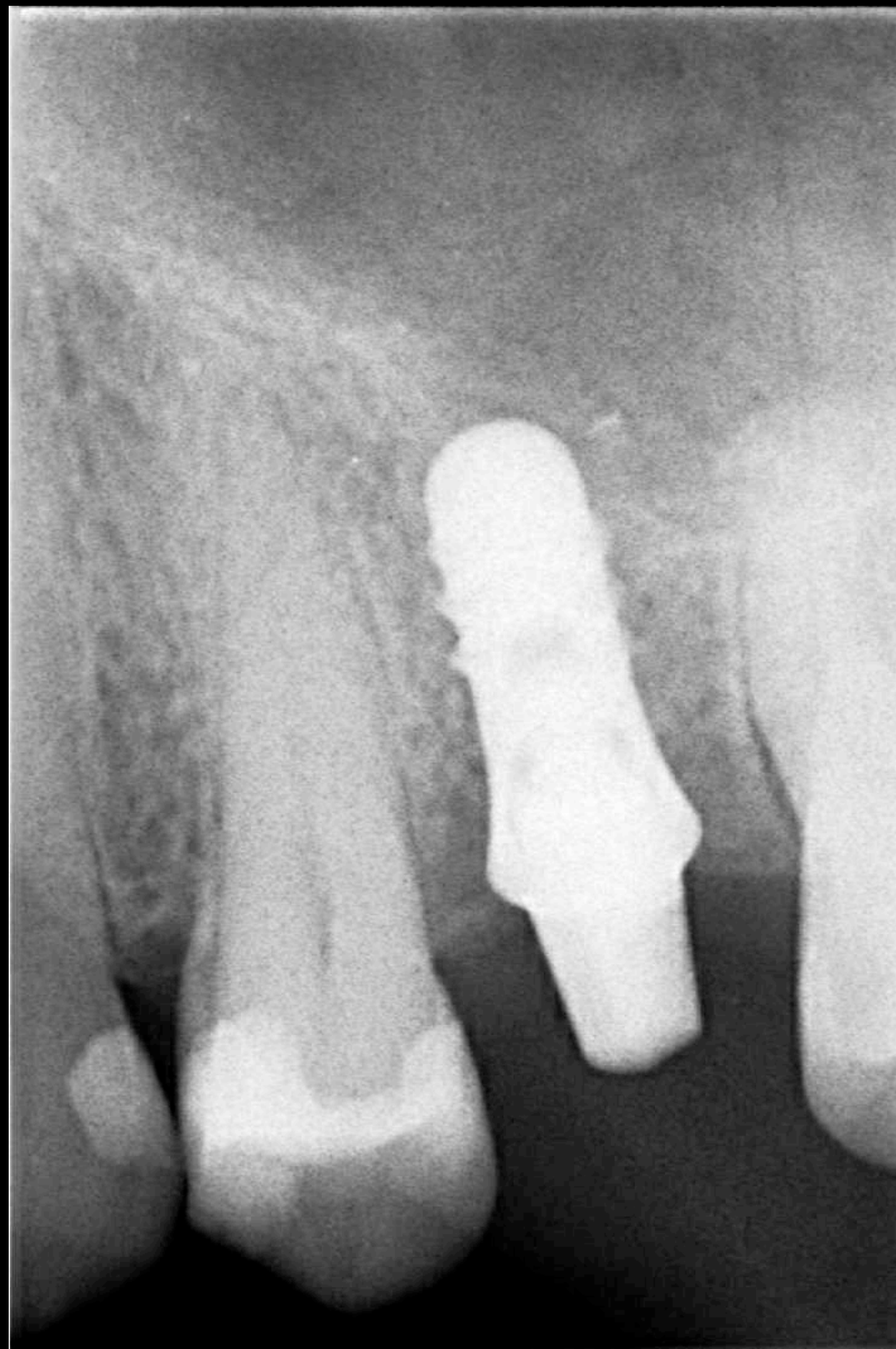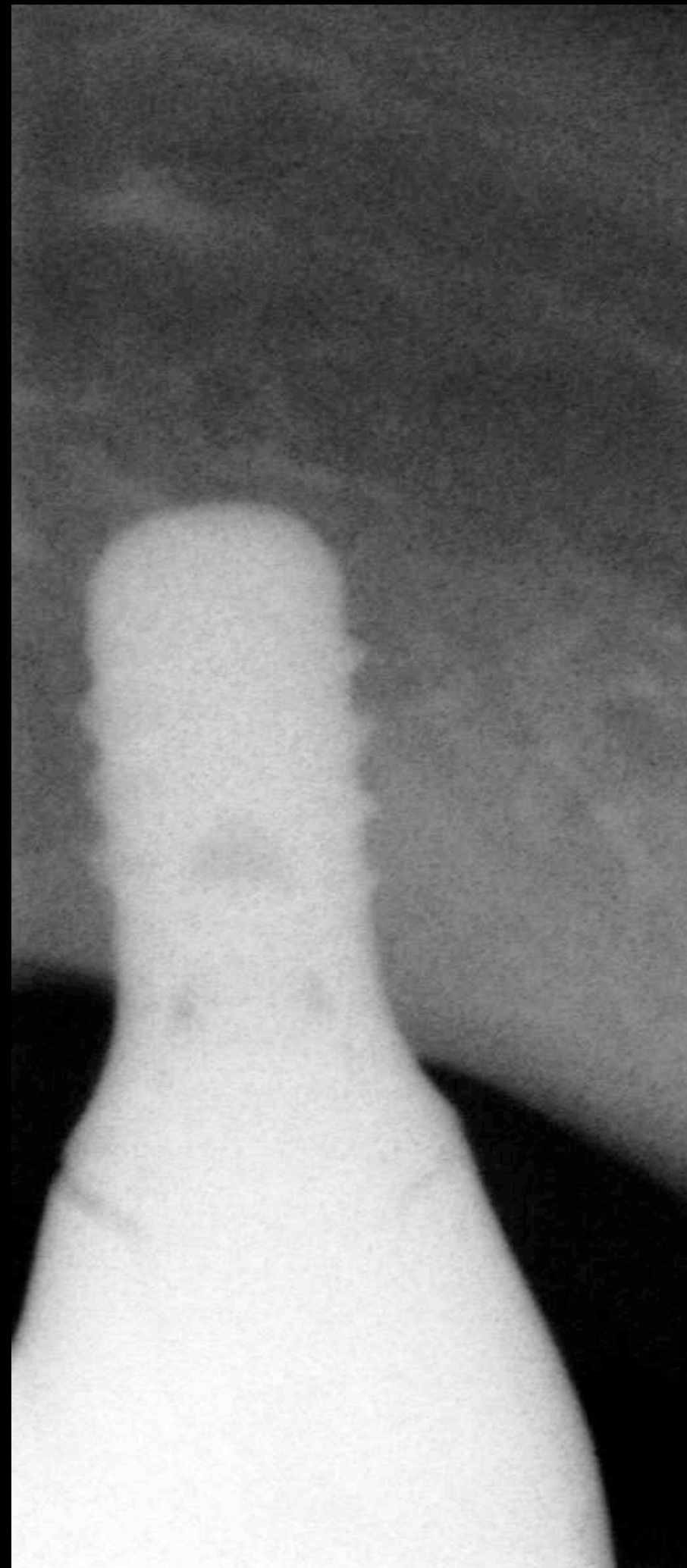TA6V



Implants courts postérieurs

FUGAZOTTO, BEAGLE, VLASSIS, GANELES, J.periodontal 2004-75-327.32

987 implants de 9 mm ou moins
avec **95,1%** de succès

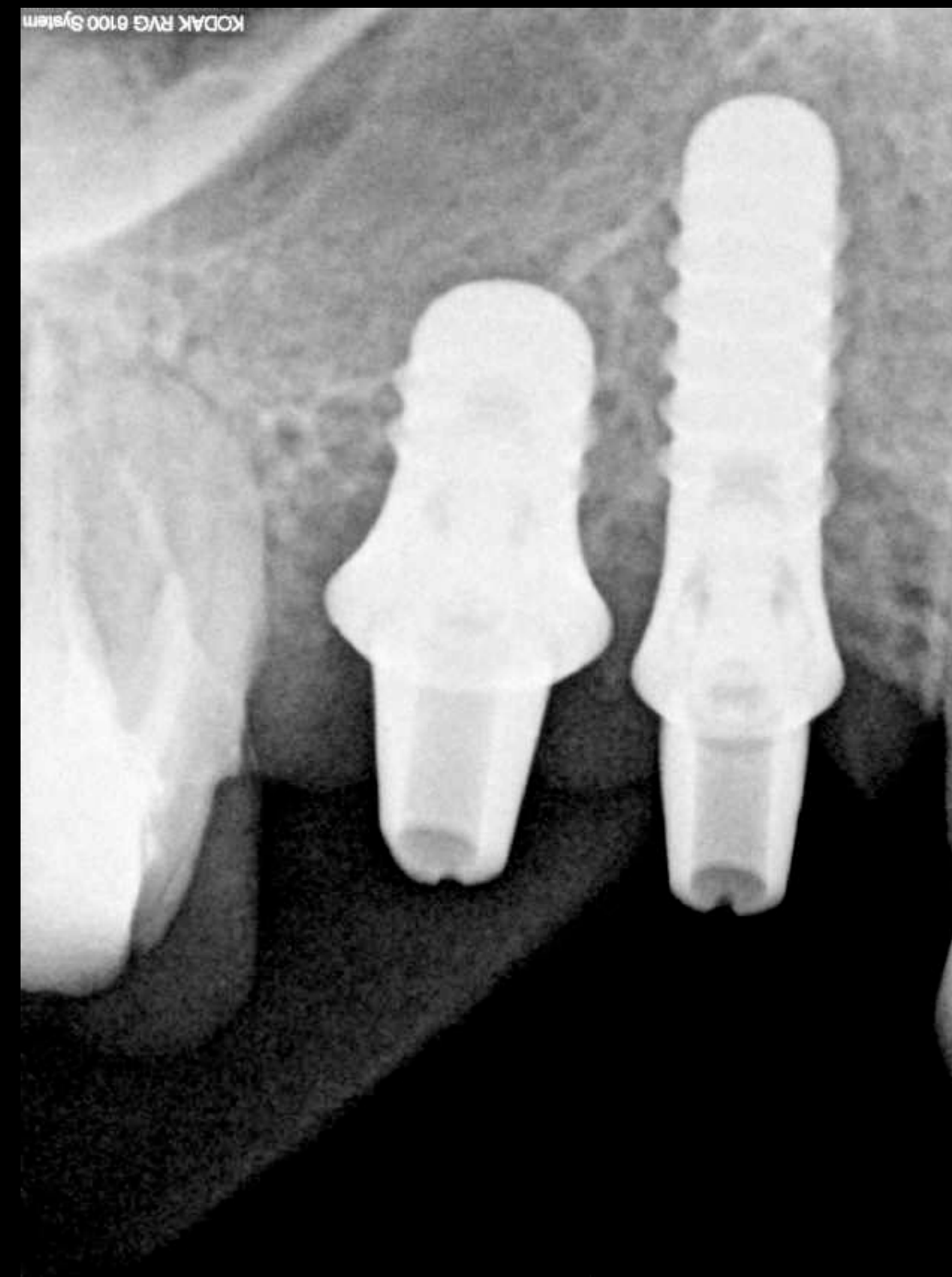


Nedir R, Bischof M, Briaux J-M, Beyer S, Szmukler-Moncler S, Bernard J-P. A 7-year life table analysis from a prospective study on ITI implants with special emphasis on the use of short implants. Results from a private practice. *Clin. Oral Impl. Res.* 15, 2004; 150-157

7 ans de suivie pour un 528 implants (264 SLA et 264 TPS) placé et chargé en cabinet privé pendant au moins une année.

50,8 % \leq ou = à 10 mm.

Taux de succès cumulatif : 99,4%



Facteurs de risque d'échecs des implants

Meta-analyse des implants de 10mm ou moins
majorité de études CSR : 92,5 (usiné)-98,5%(rugueux) = implants + longs

Pas d'analyse en fonction du site ou qualité de l'os

Technique Fiable et reproductible

Implants Courts

Implants 6mm Straumann

Suivi 12 mois à 8 ans

266 implants maxillaires 14 échecs SR : 94,7%

364 mandibulaires 5 échec SR : 98,6%

Meta- Analyse ==> Cumulative Success Rate 93,7%

76% des échecs = échecs précoce

Difficultés à stabiliser l'implant court

Mieux vaut avoir 7mm de hauteur et une crête large

Praticien dépendant



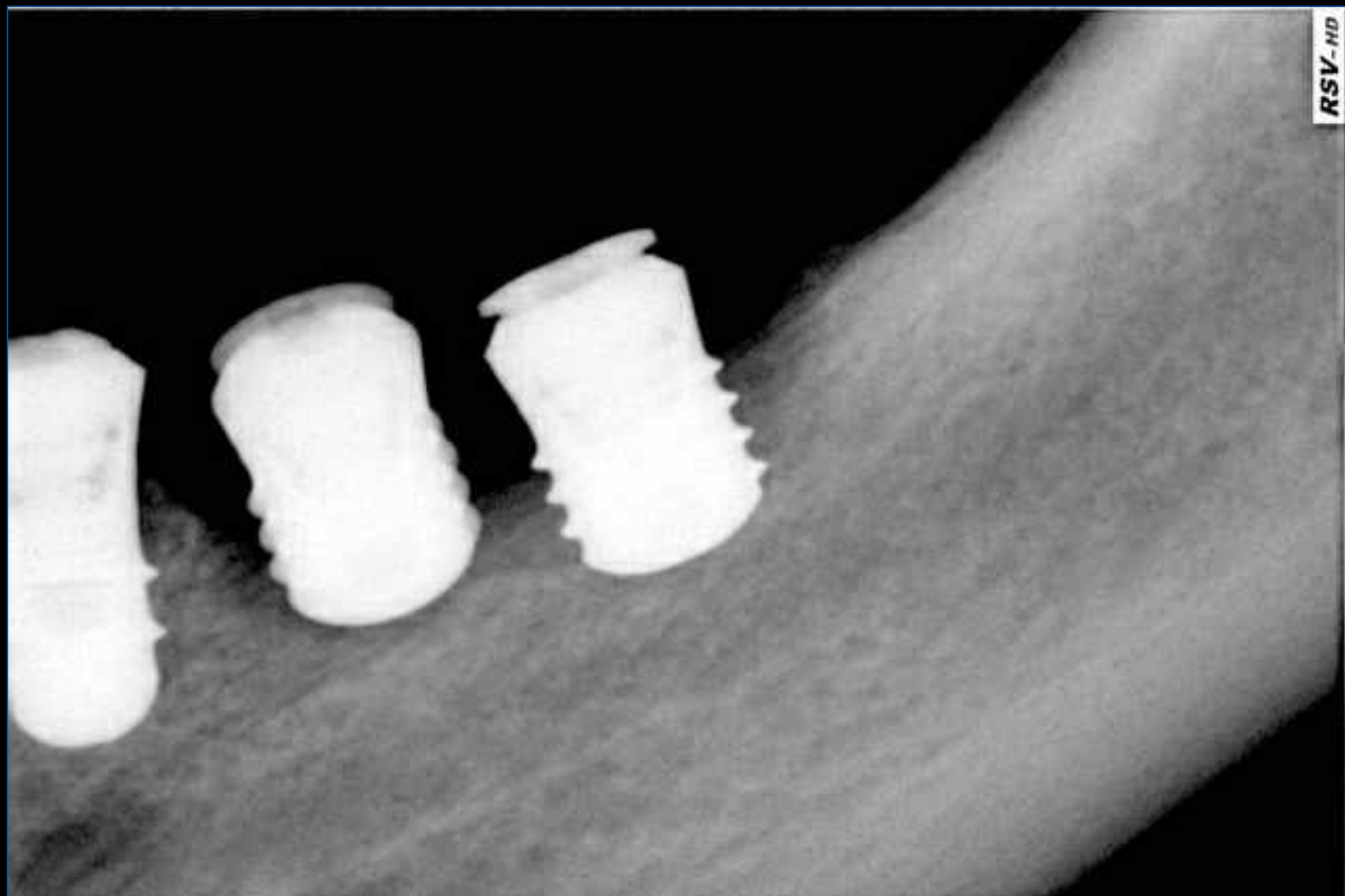
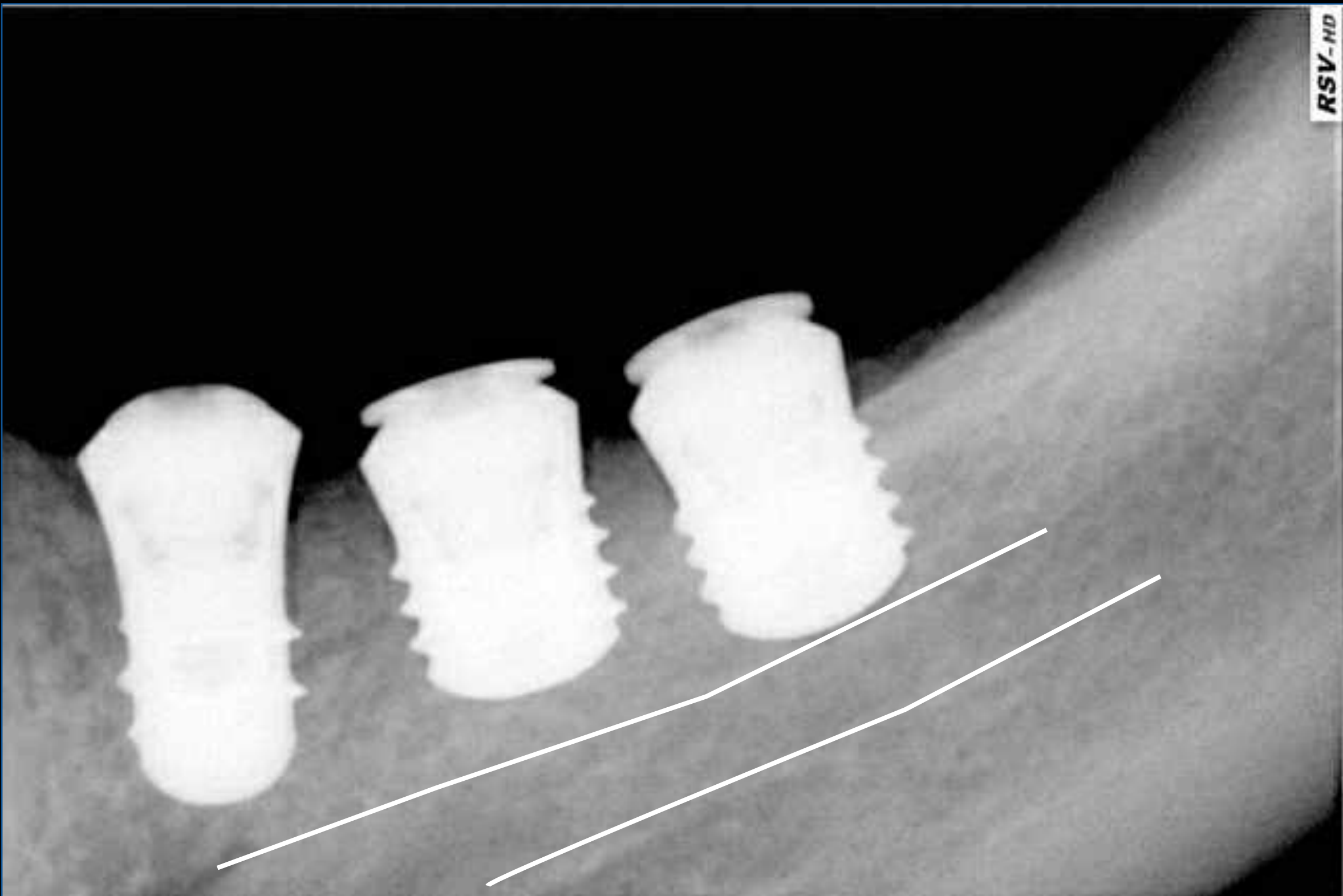
Implants courts

Géométrie de l'implant



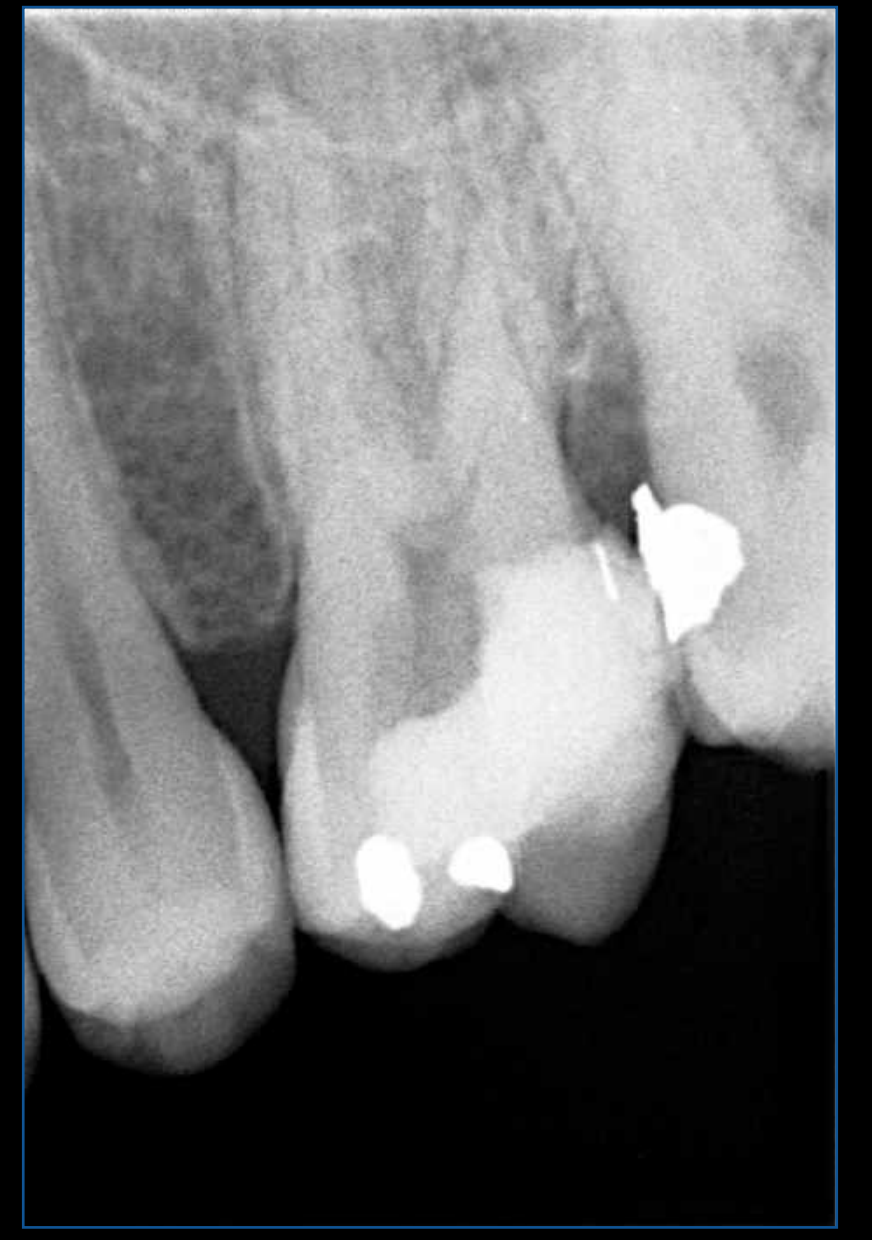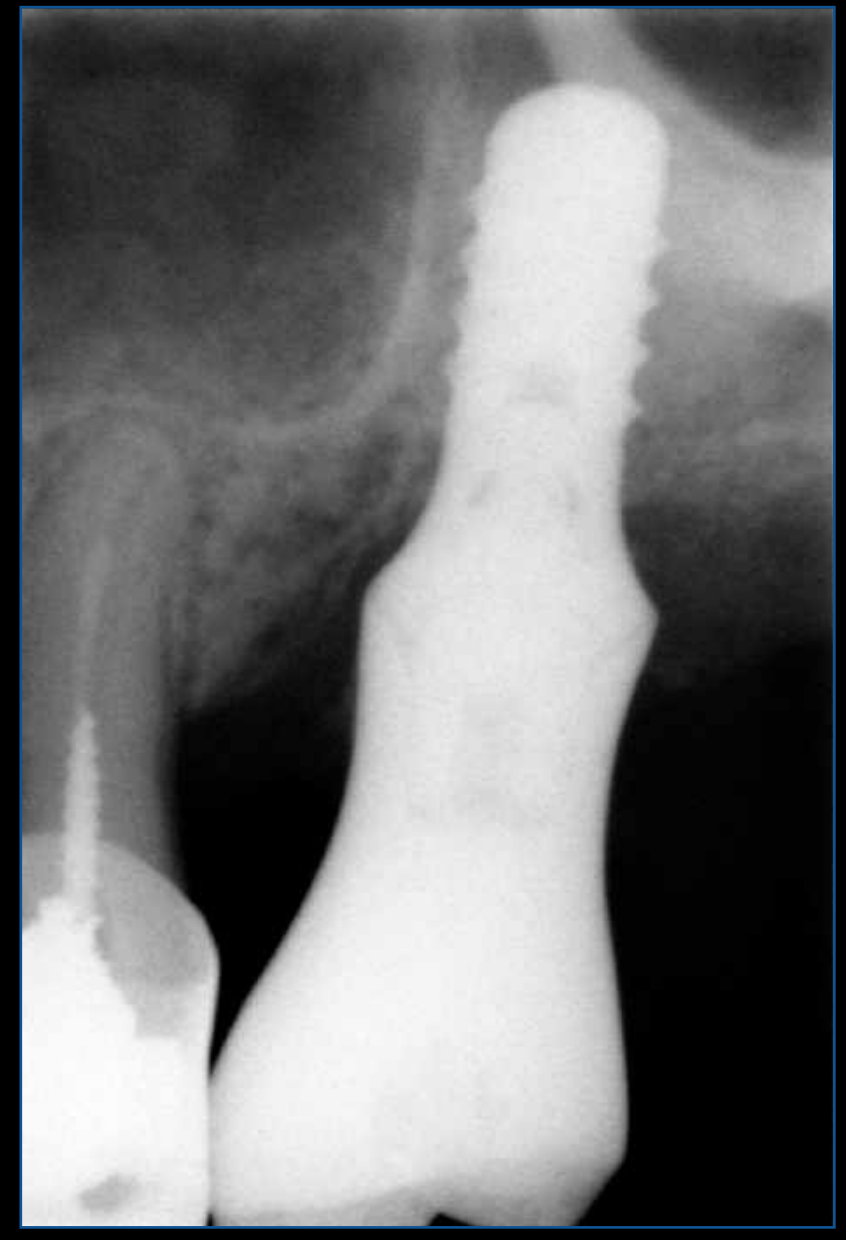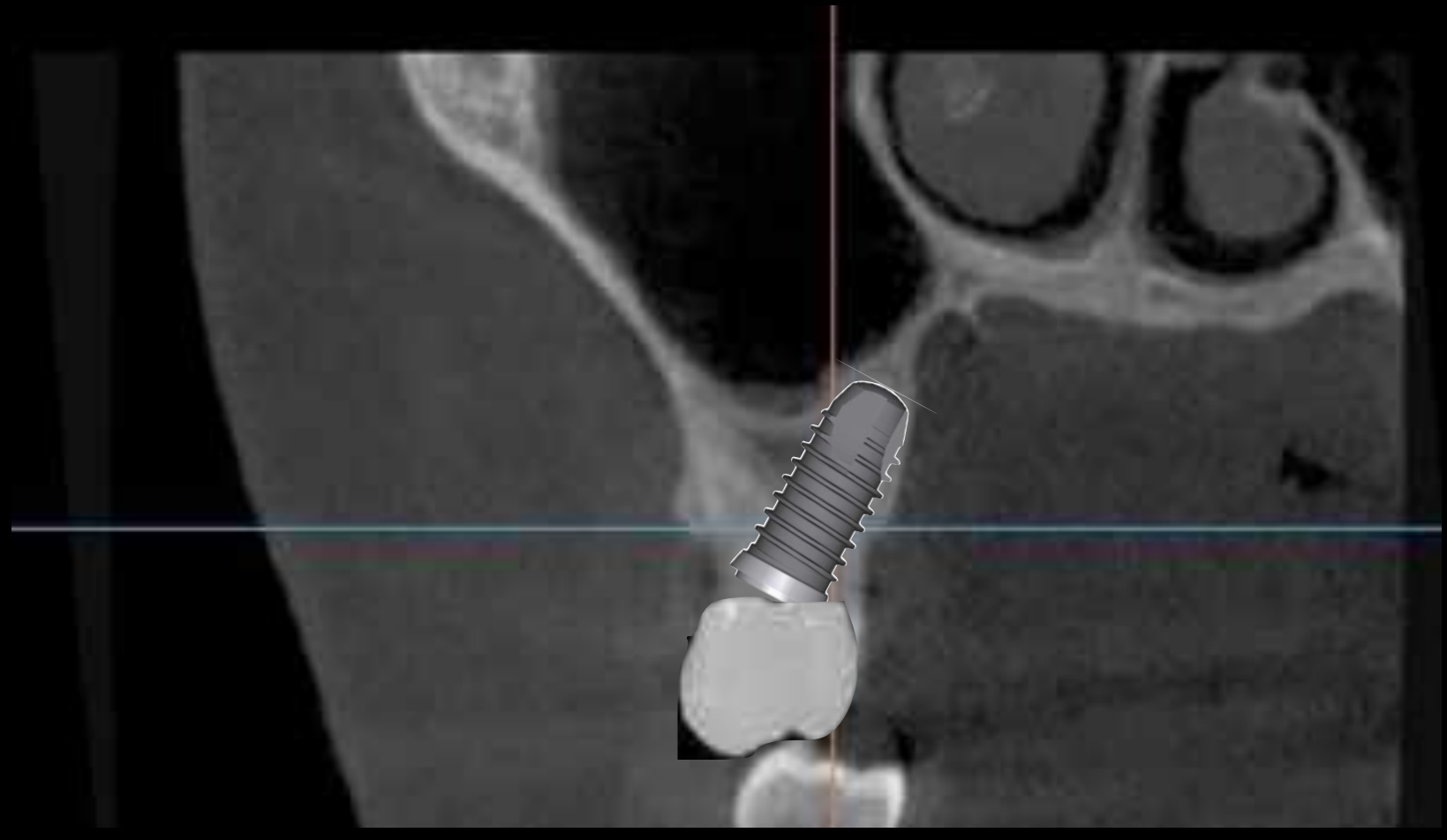
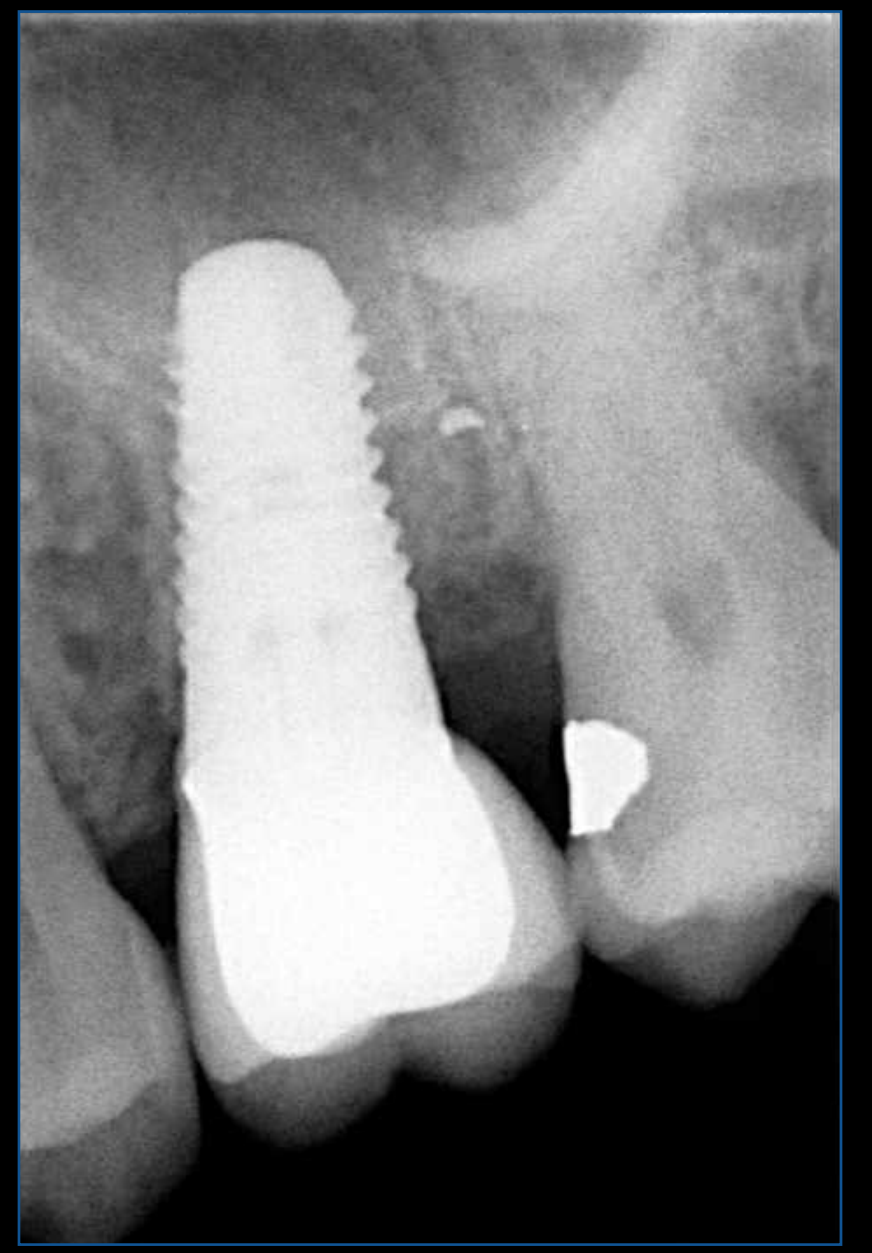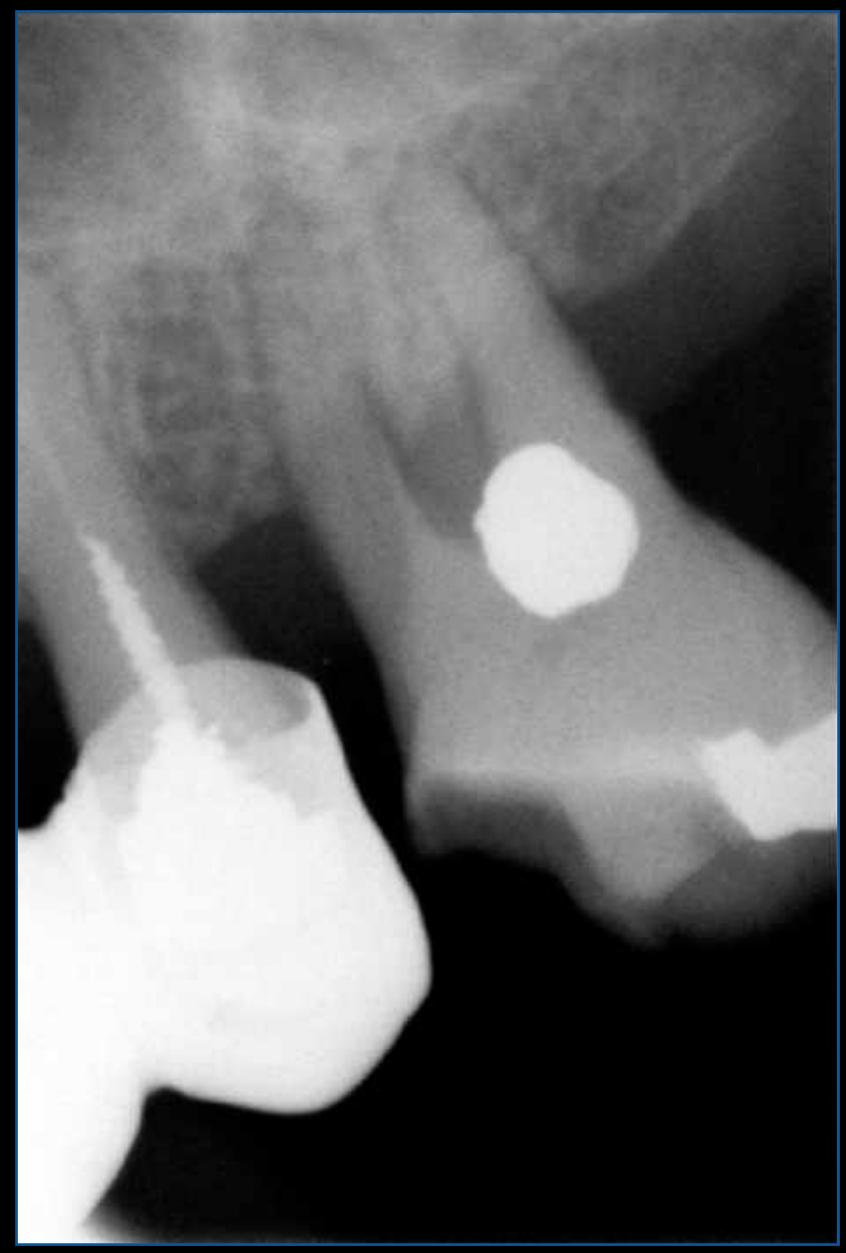
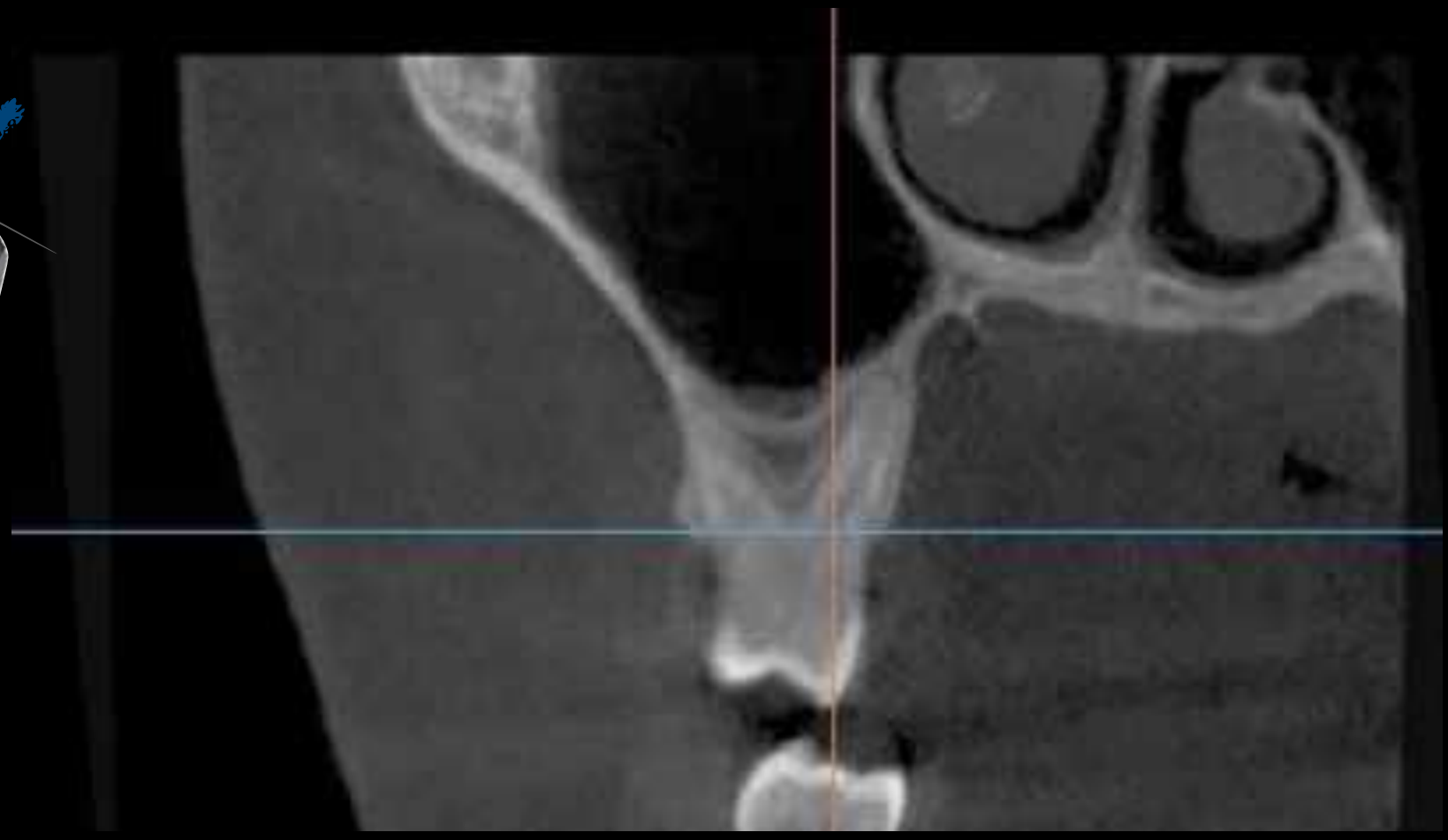
LES IMPLANTS COURTS

Implants Courts

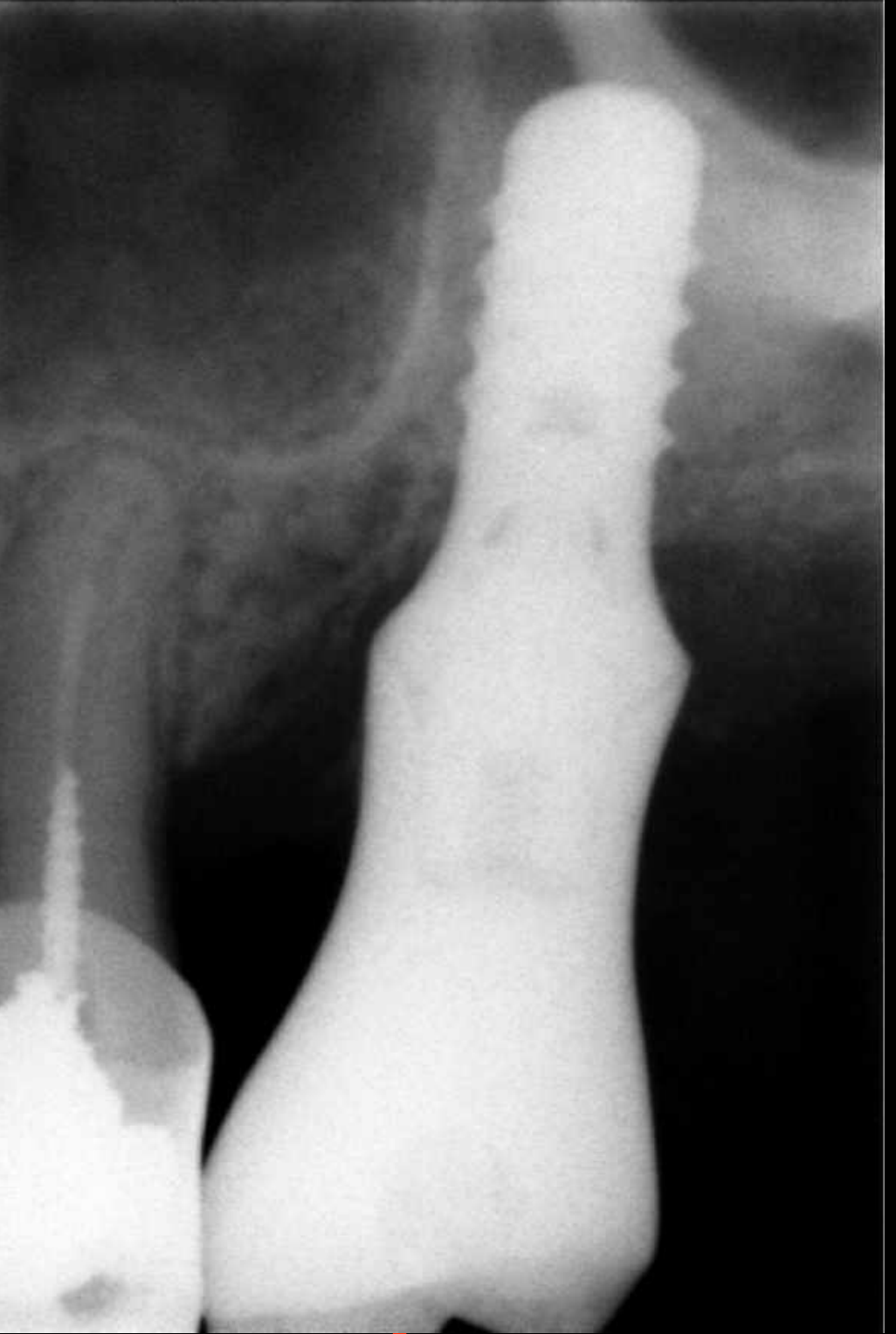

LES IMPLANTS ANGULES

CONTOURNEMENT PALATIN DU SINUS



Rapport couronne/implant

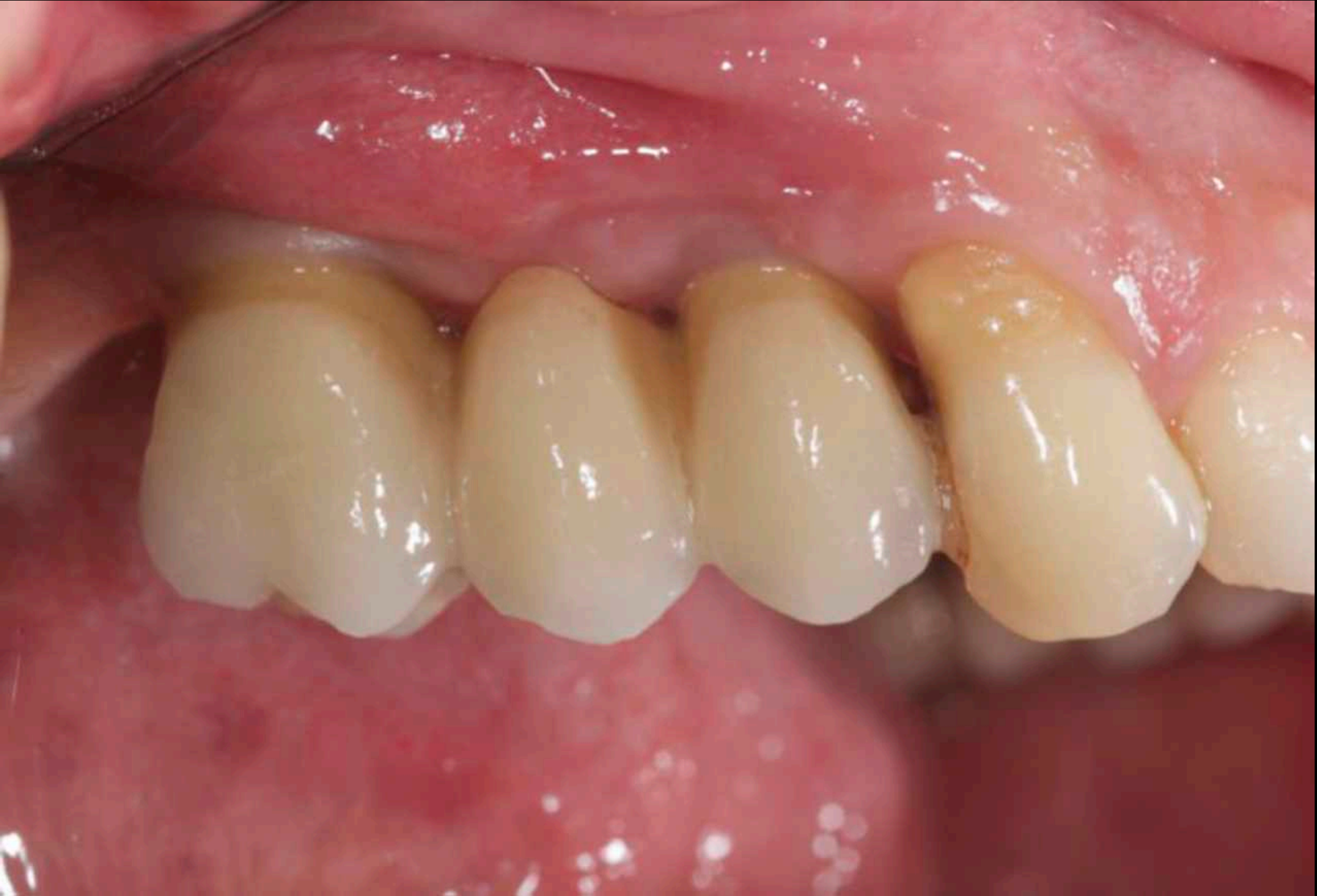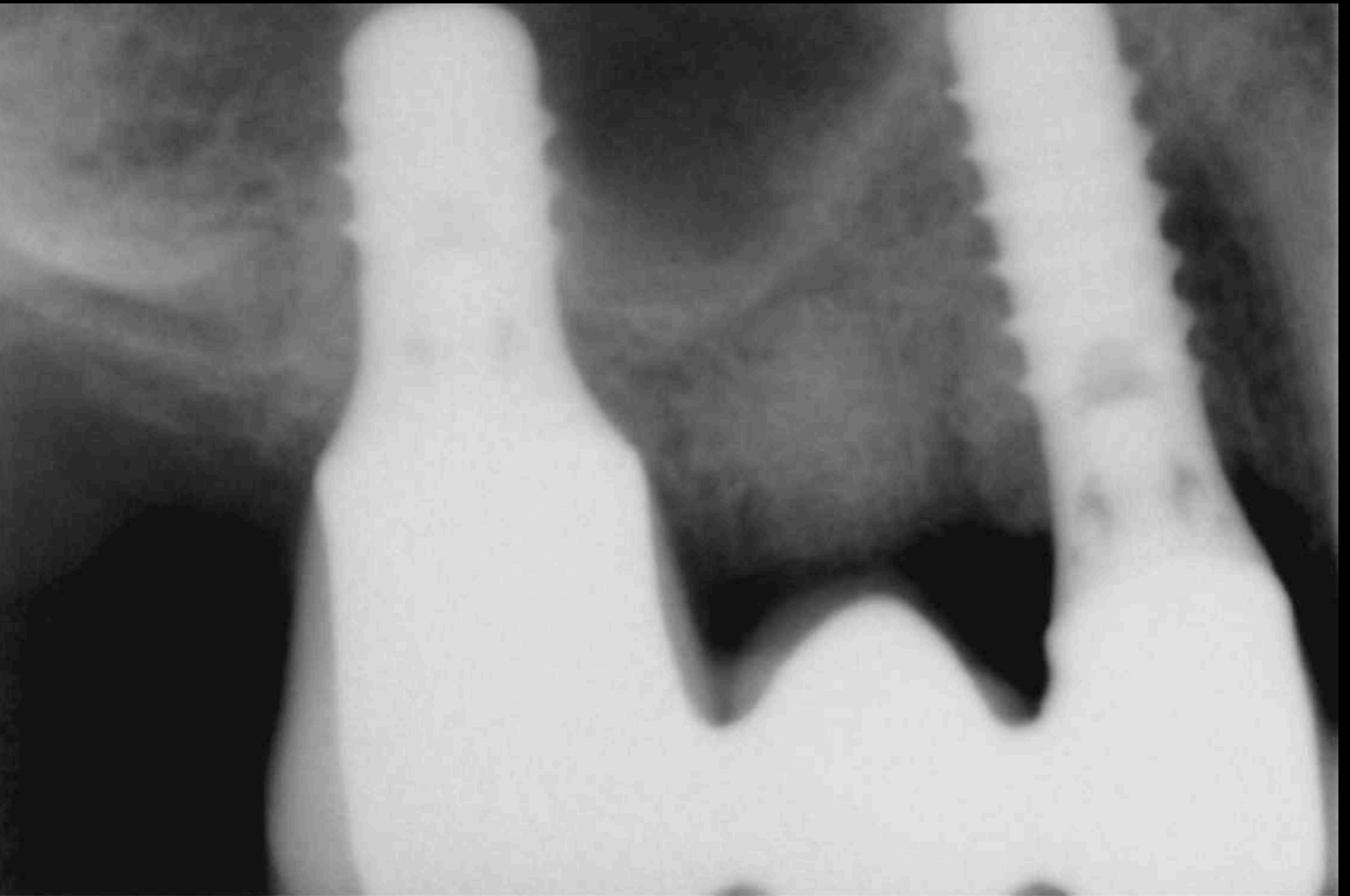
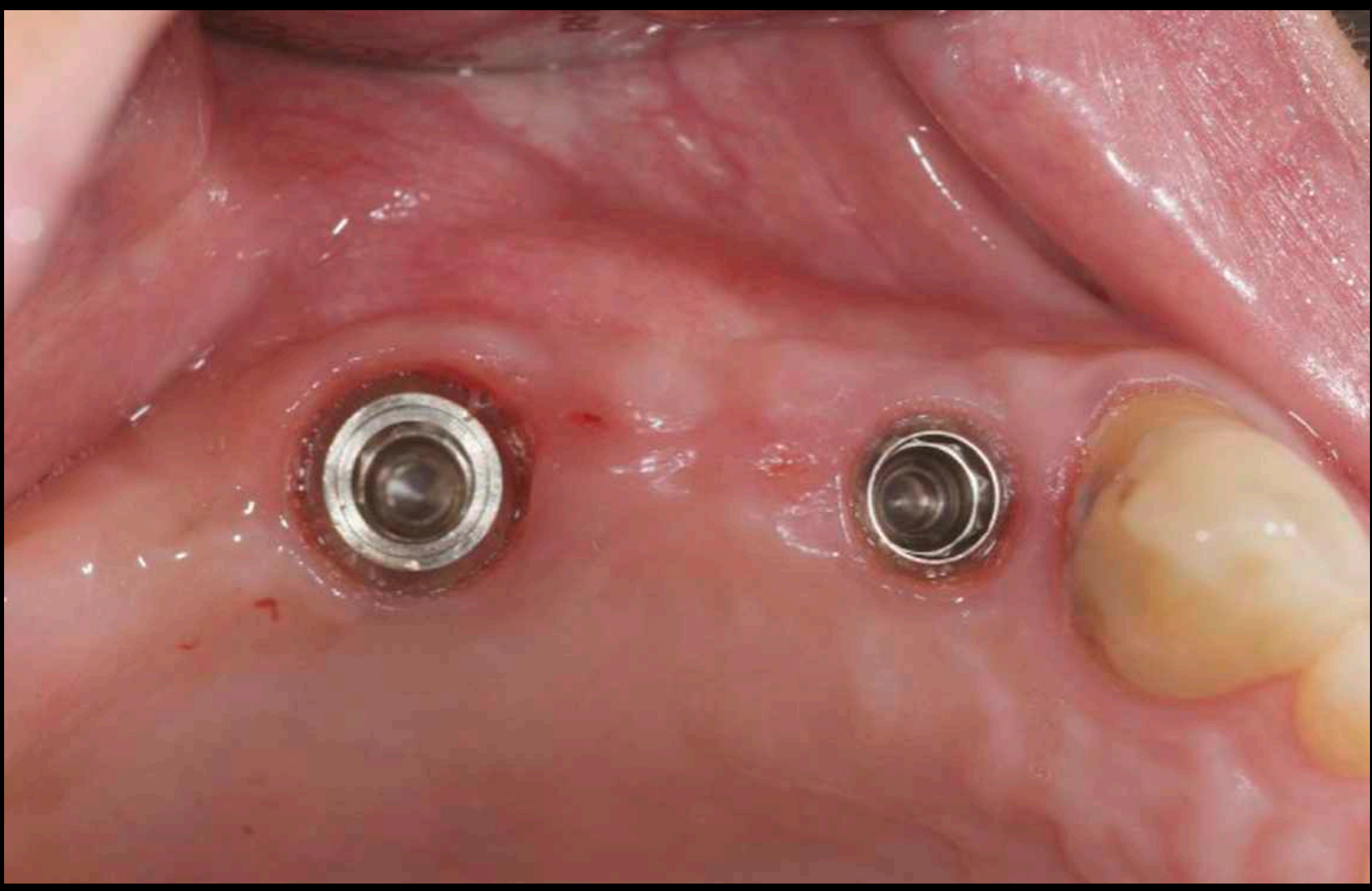

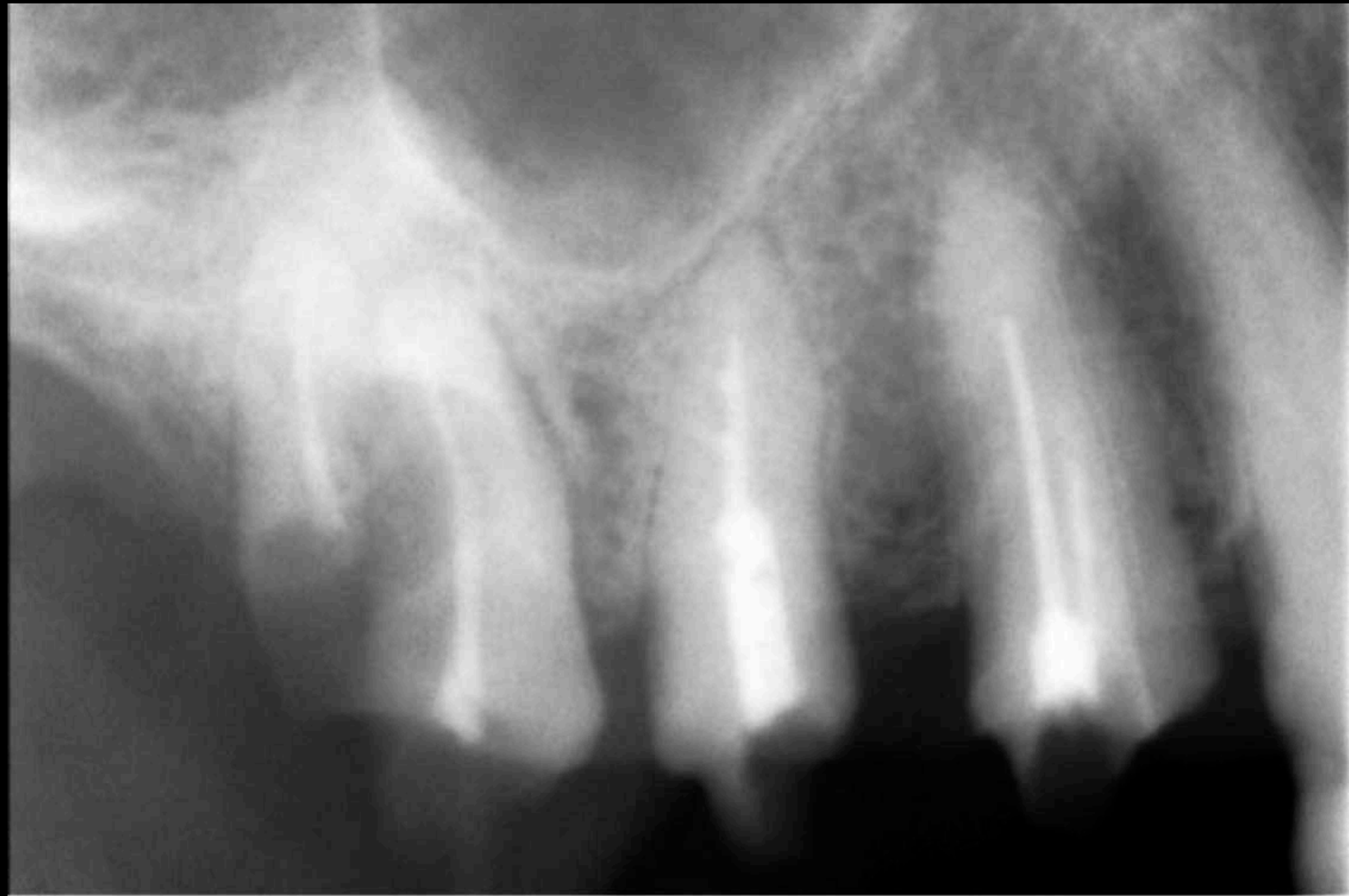
208 implants ITI 3 groupes
Suivi de 6 à 66 mois
 $C/I \leq 1, 1 < C/I \leq 1.5, C/I > 1.5$

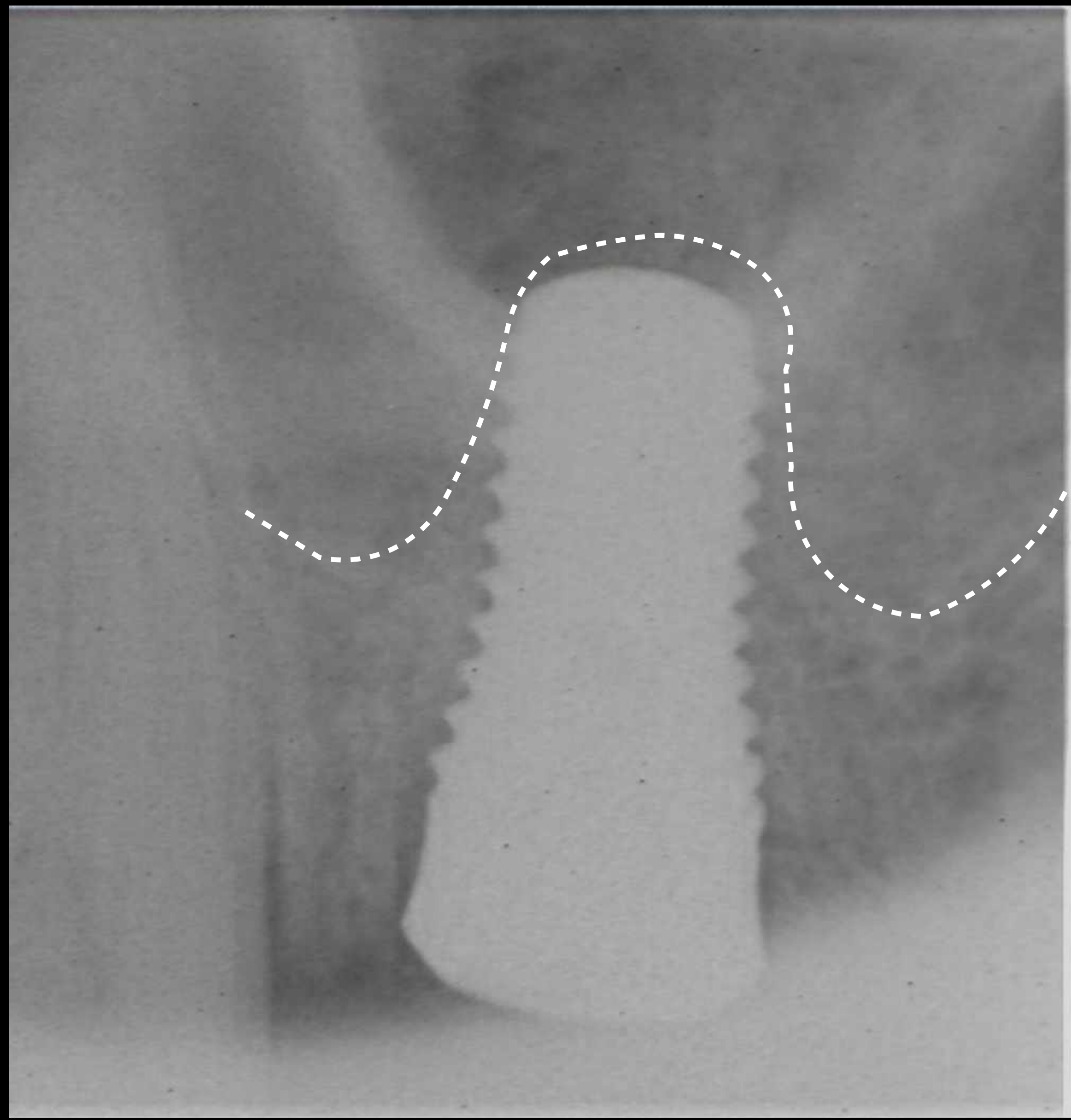
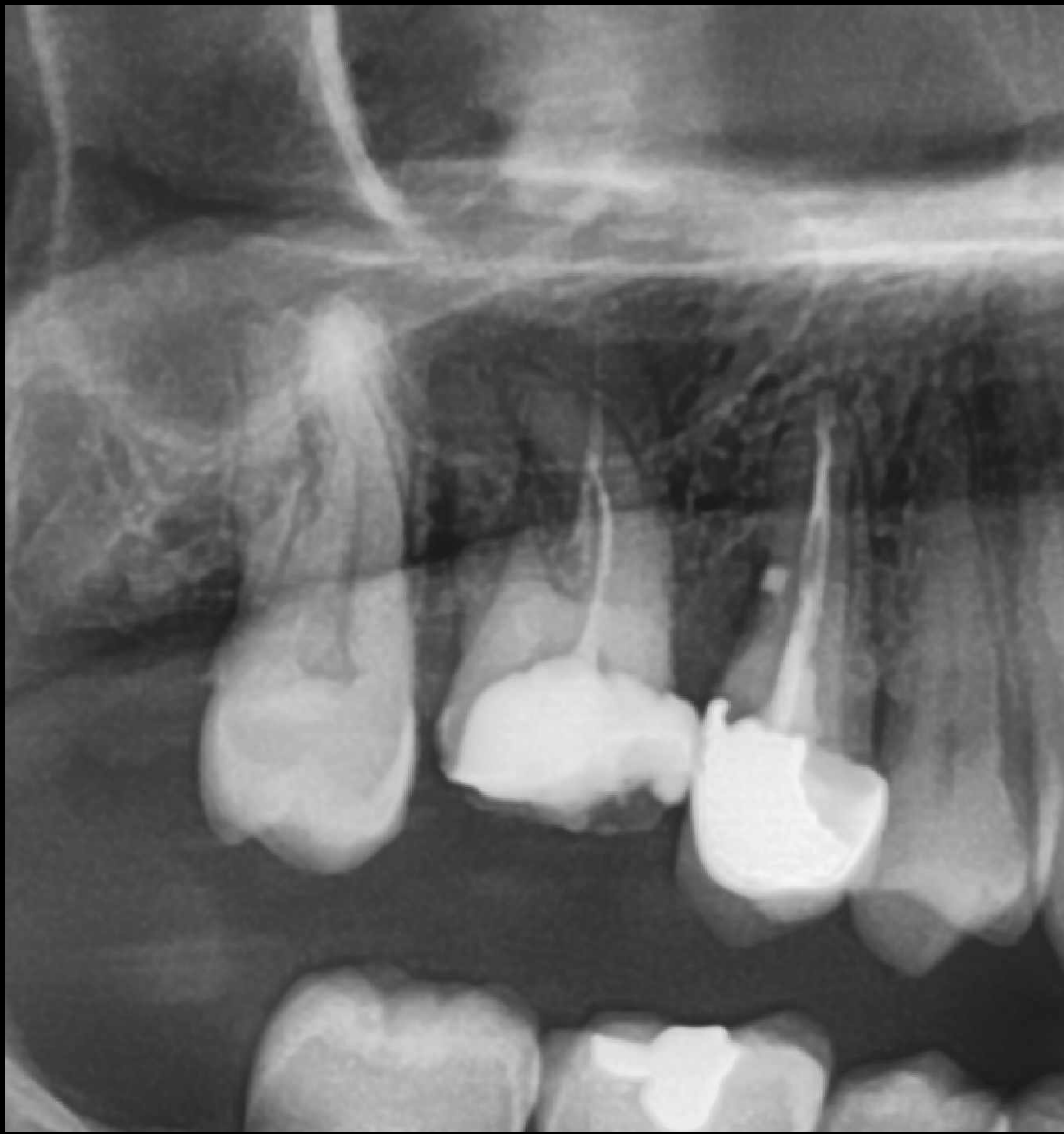Pas de différence significative entre les 3 groupes

SR $C/I > 1$: 97,6%
SR $C/I < 1$: 98,8%

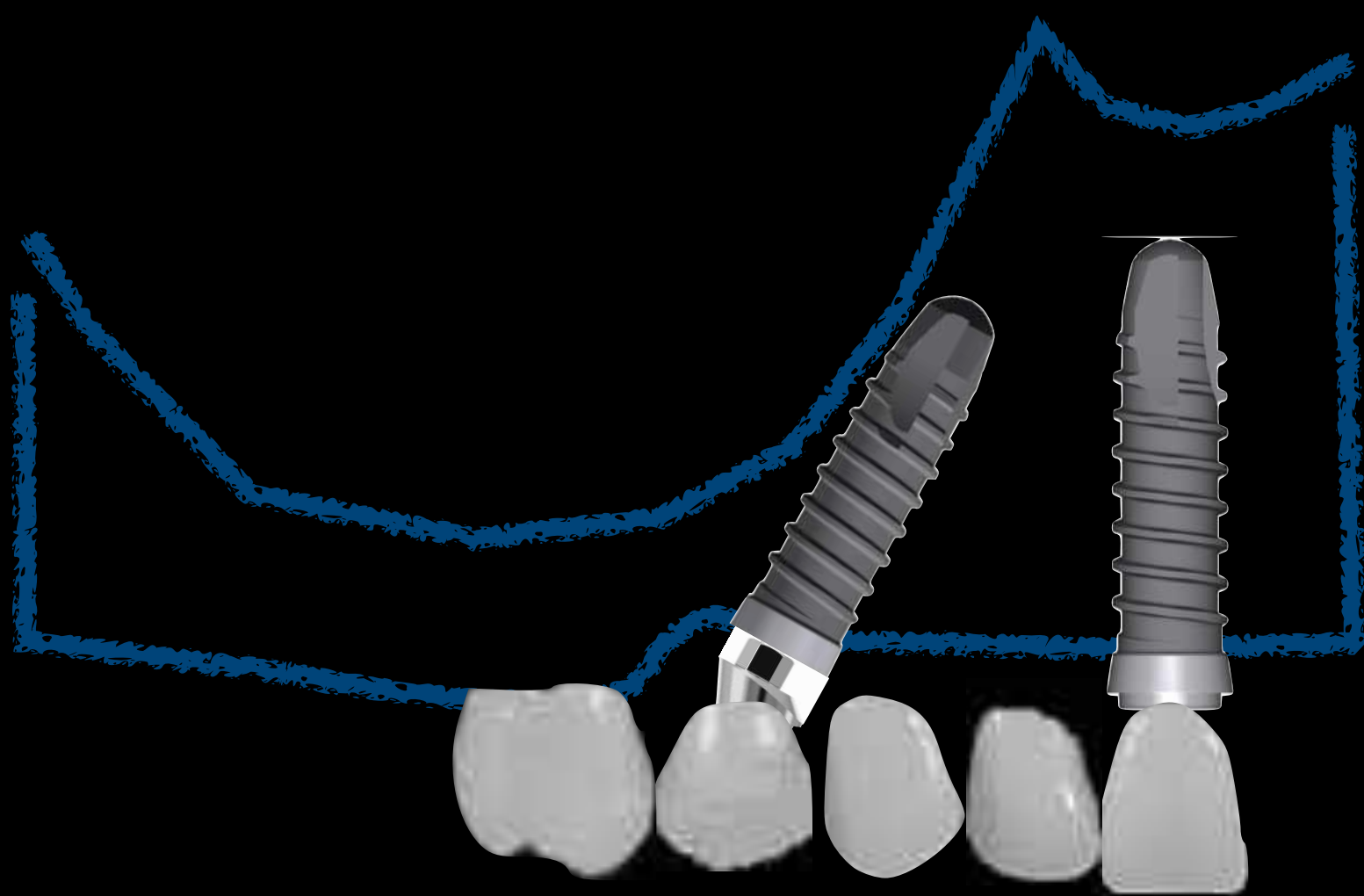
Zhao BH, Feng W, Wang DN, Jang LL, Deng CF, Shang DH, Zhang C. An assessment of different crown-to-implant ratio for implant teeth in the posterior region over 5 years Shanghai Kou Qiang Yi Xue. 2013 Apr;22(2):189-94.



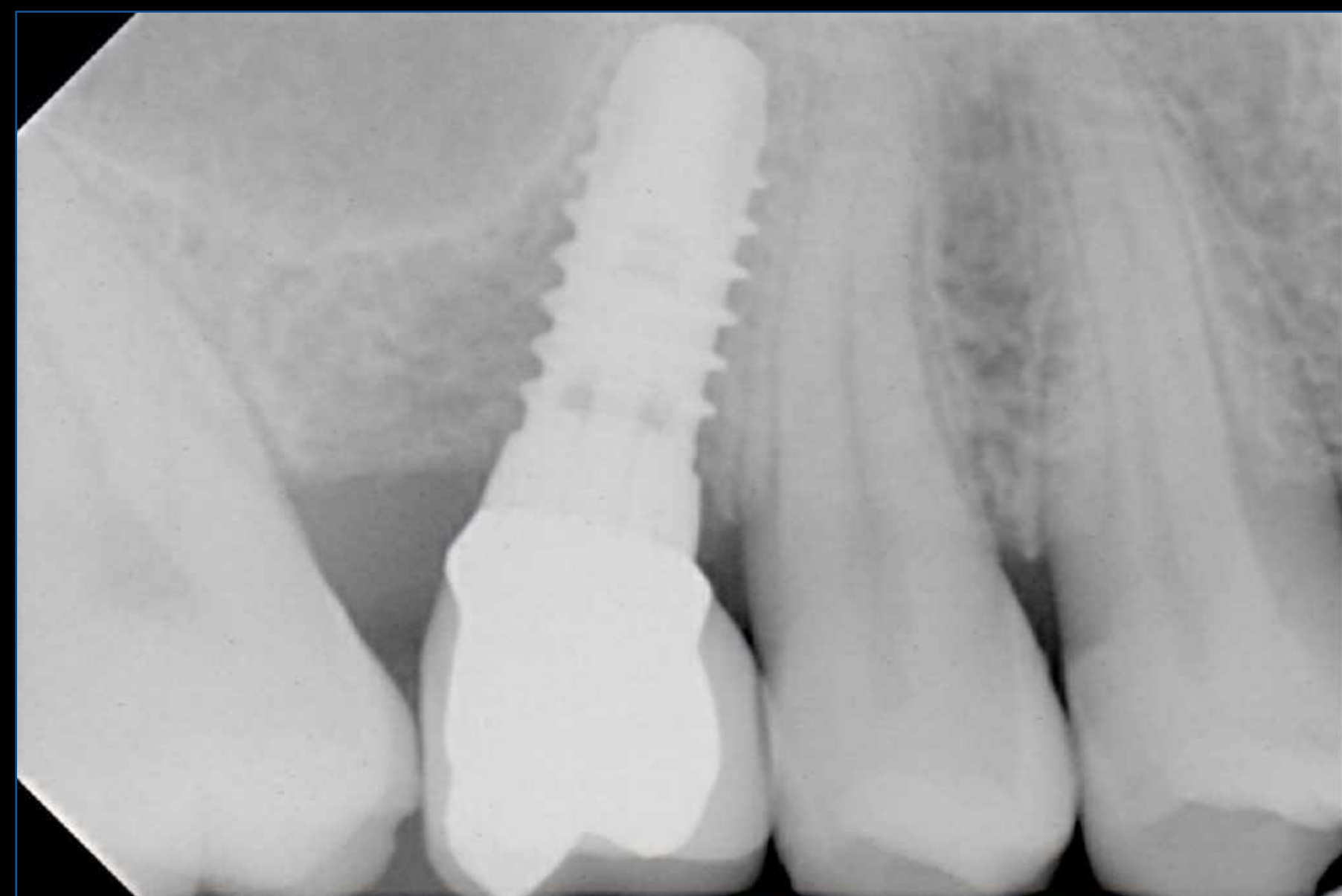
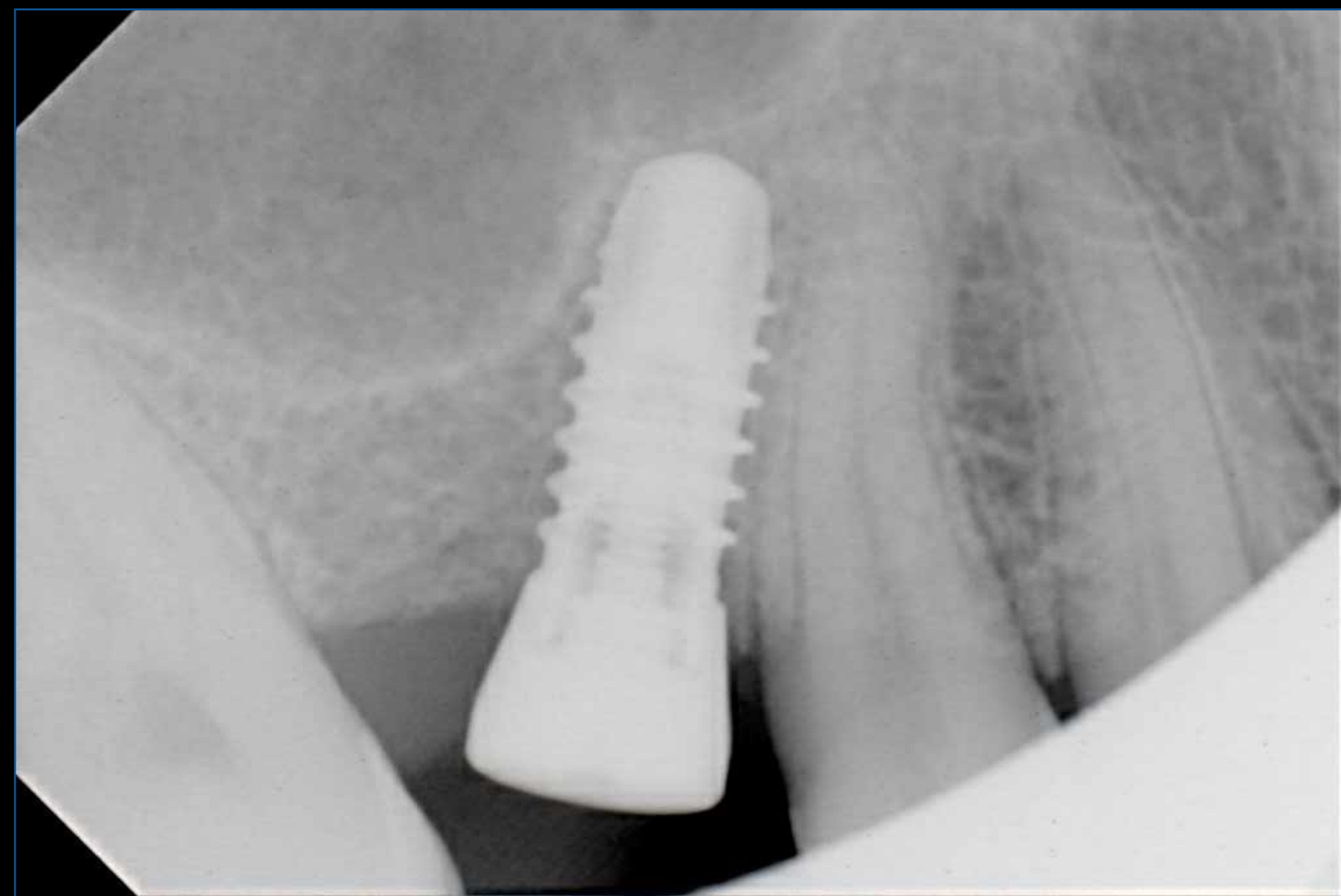
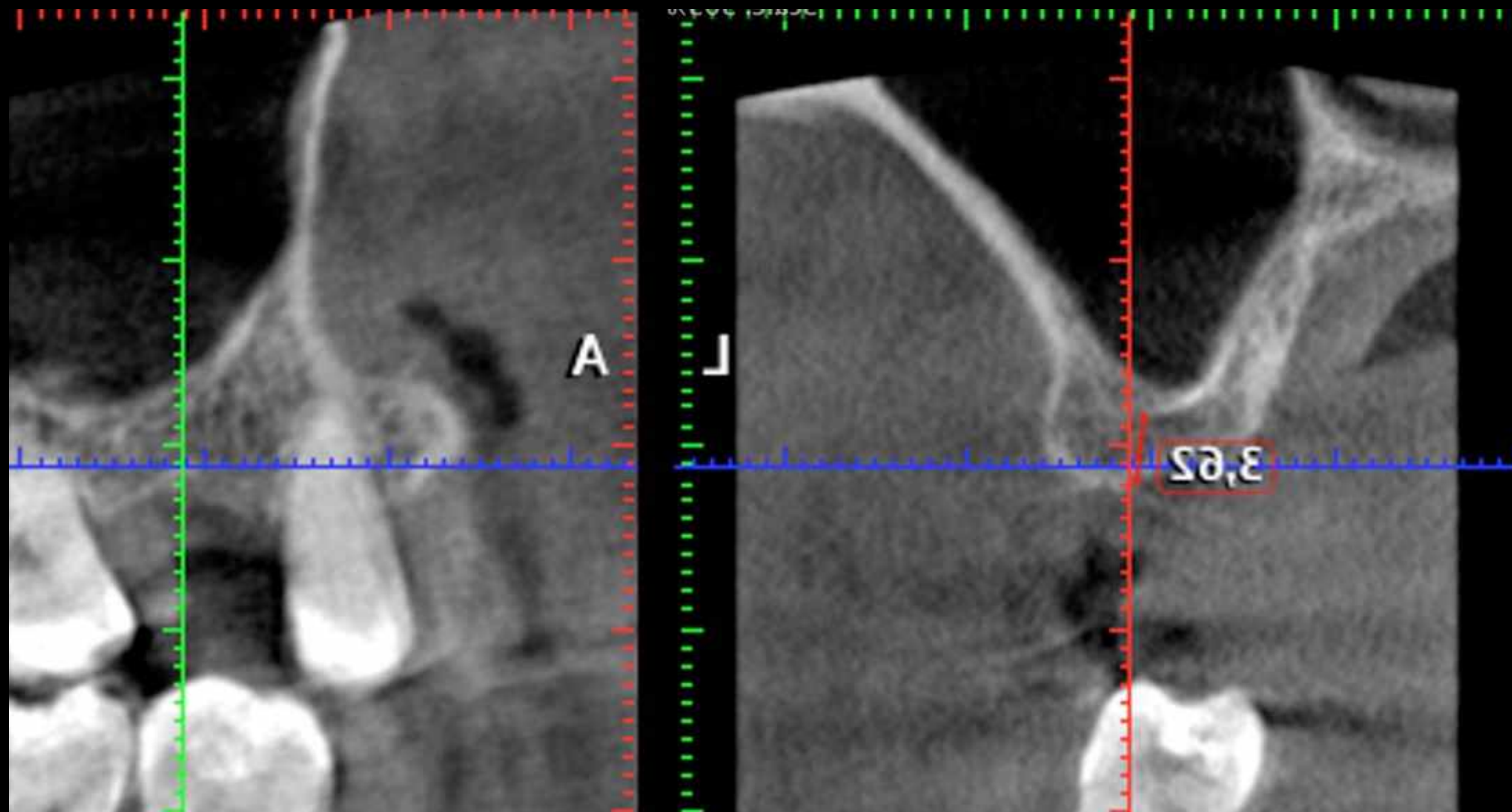
Extraction Implantation Immediate



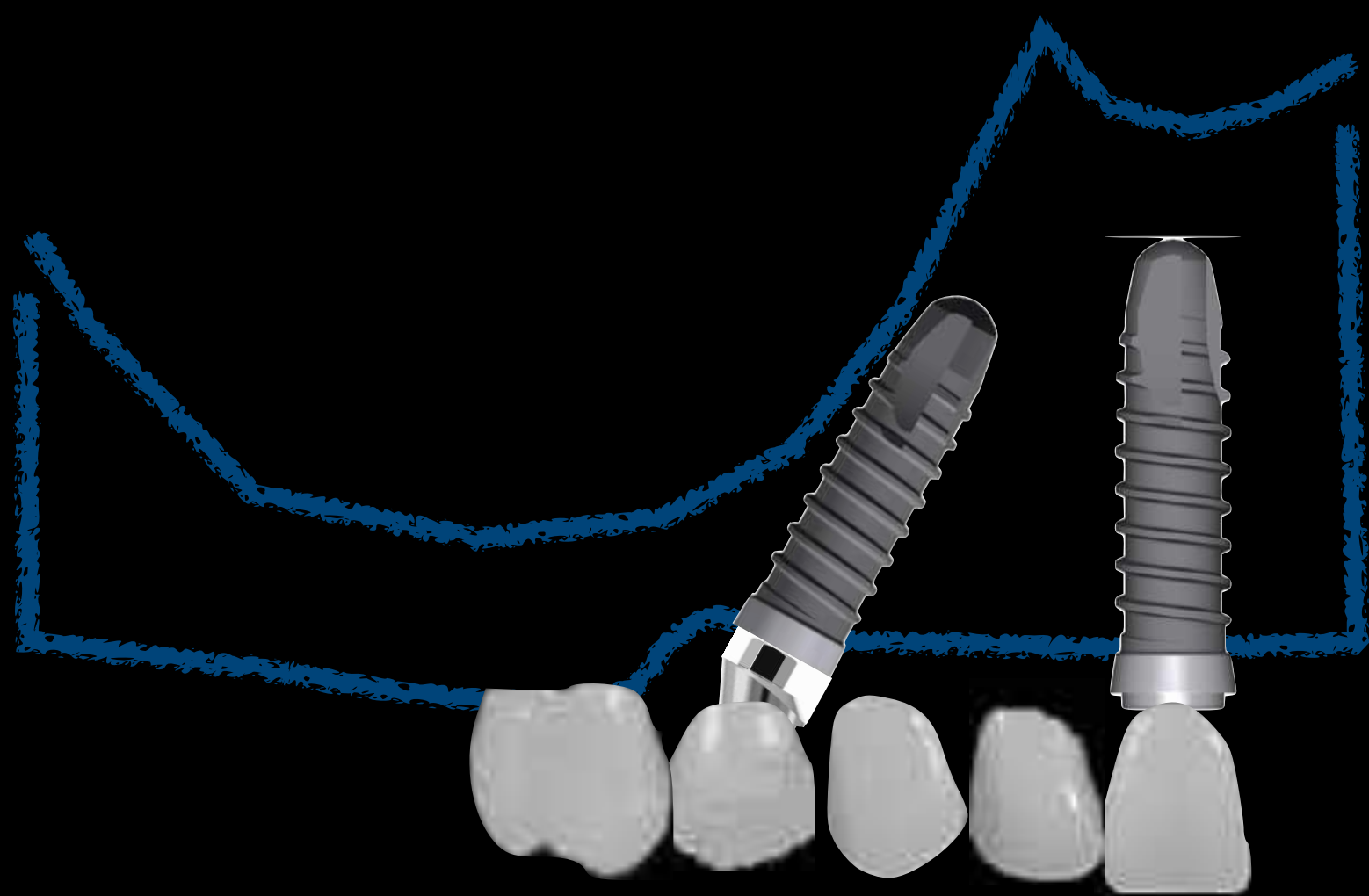
Implants Angulés



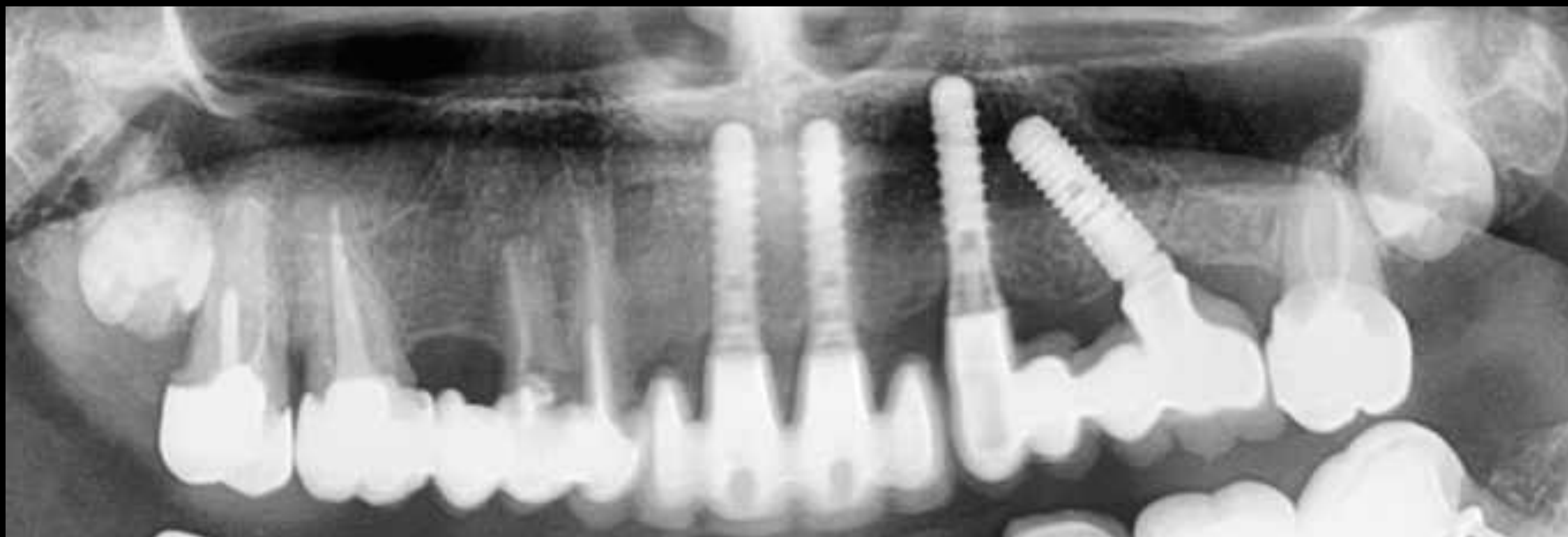
CONTOURNEMENT SAGITTAL MESIAL



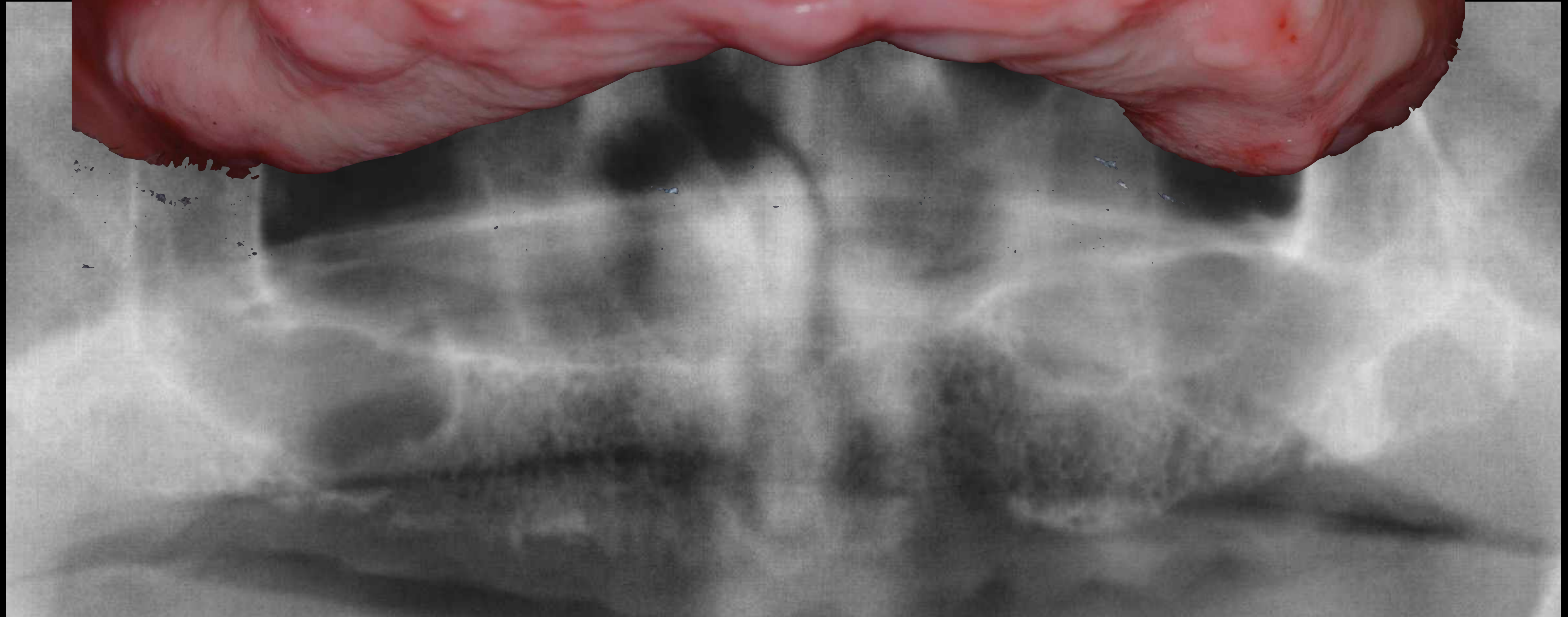
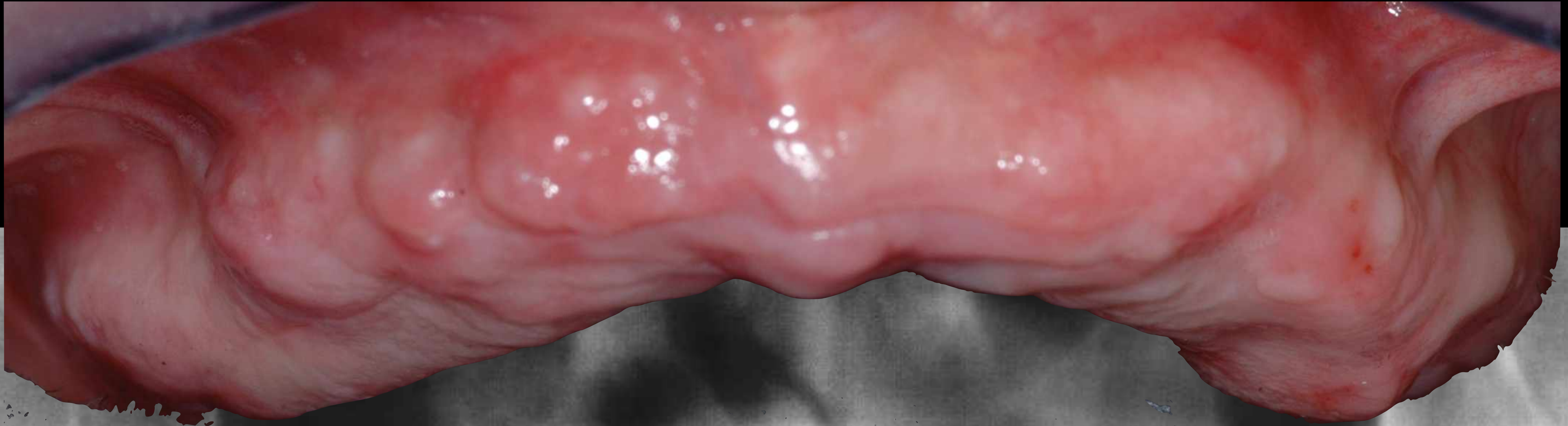Implants Angulés



CONTOURNEMENT SAGITTAL MESIAL Bridge Sectoriel



TRAITEMENT DE L'ÉDENTATION TOTALE





Etude **prospective** : sujets (N=176), 4 groupes :

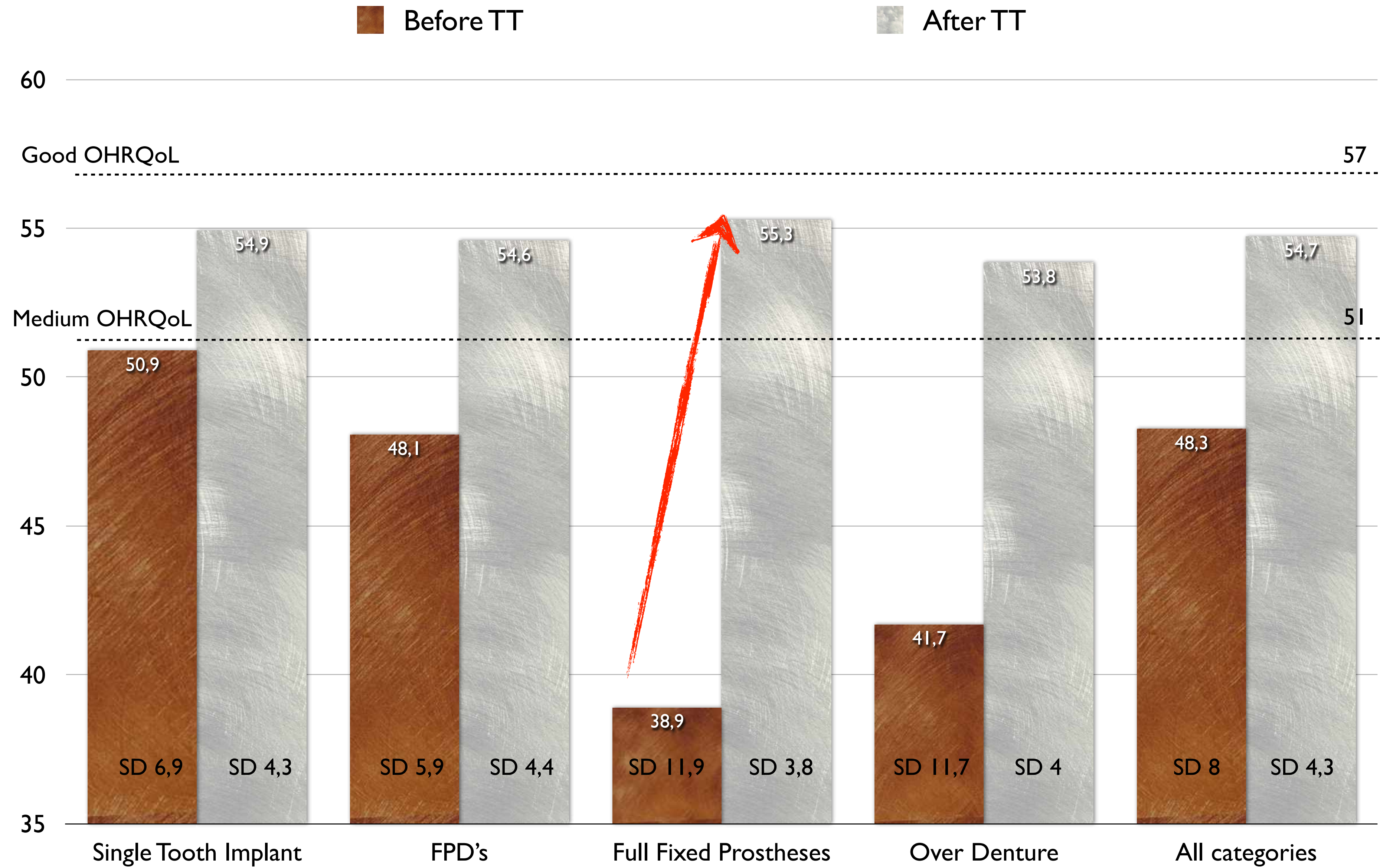
“Single Tooth Implant (N=77)”

“Fixed Partial Denture (N=75)”

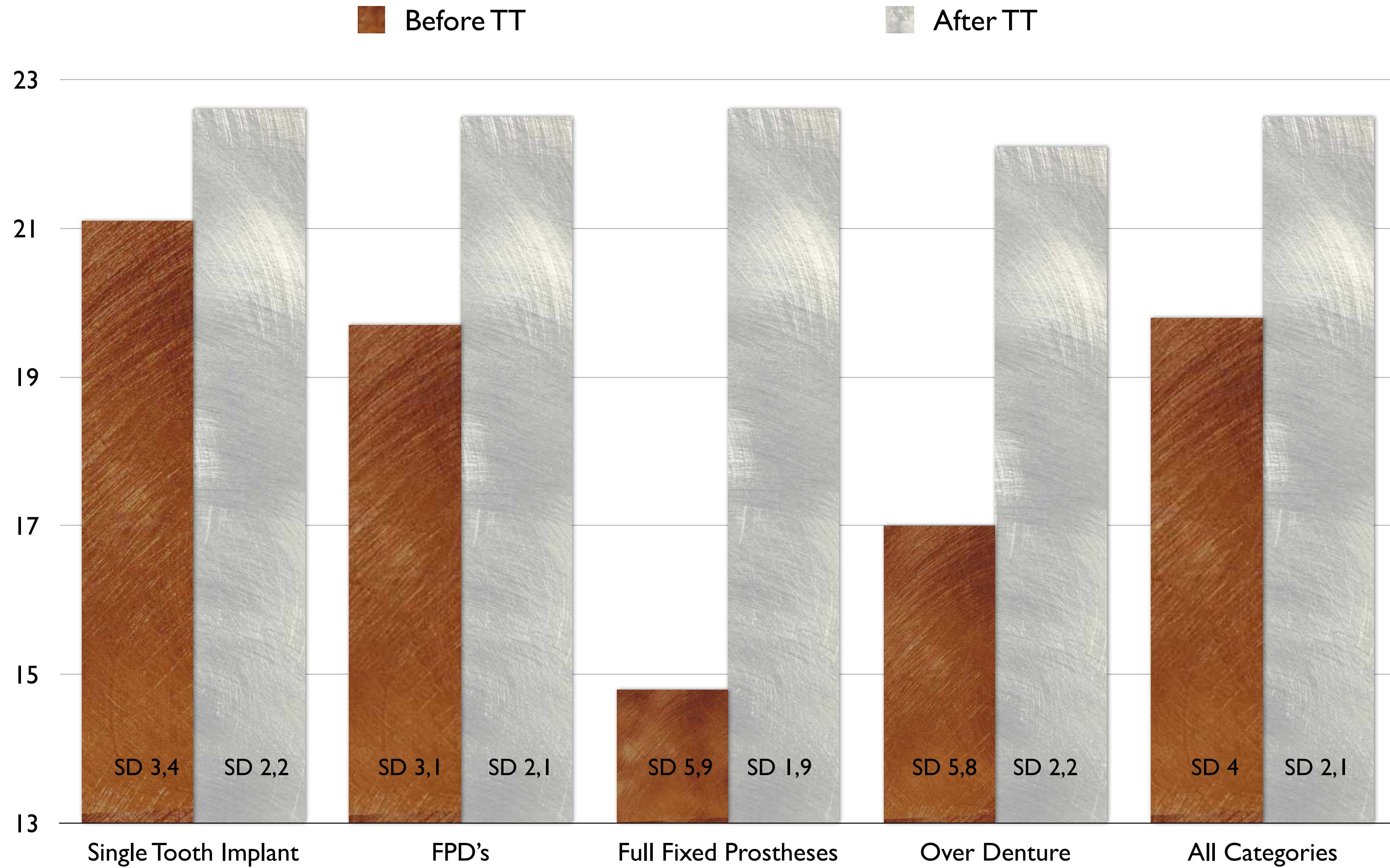
“Full Fixed Prosthesis (N=11)”

“Implant Retained Complete Over-denture (N=13).”

Questionnaire du **GOHAI** avant et après traitement



GOHAI ADD Improvement Before and After Treatment



Statistical Analysis of psysocial items

Revue de littérature



Protocole All-on-four
13 études et 4804 implants

Beaucoup de biais, nécessite des études complémentaires à 5 ans

Patzelt SB, Bahat O, Reynolds MA, Strub JR. The All-on-Four Treatment Concept: A Systematic Review. Clin Implant Dent Relat Res. 2013 Apr 5.

A 1 an - 6 implants

82 angulés cumulative success rate : 98,8%

164 axiaux cumulative success rate : 98,8%

Pertes osseuses 0,9 et 0,8mm

Testori T, Del Fabbro M, Capelli M, Zuffetti F, Francetti L, Weinstein RL. Immediate occlusal loading and tilted implants for the rehabilitation of the atrophic edentulous maxilla: 1-year interim results of a multicenter prospective study. Clin Oral Implants Res. 2008 Mar;19(3):227-32.

A 1 an All-on-four mandibulaires

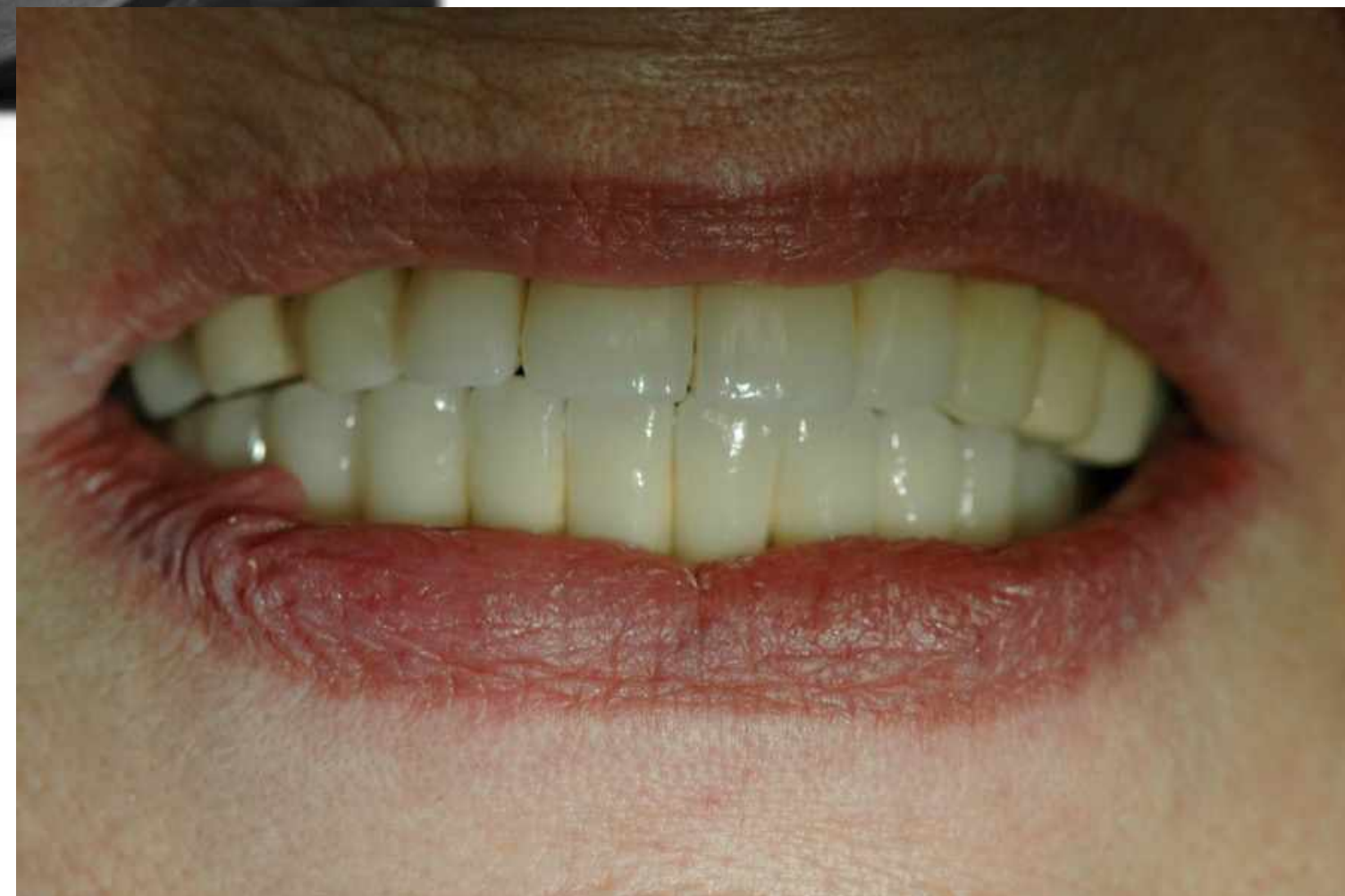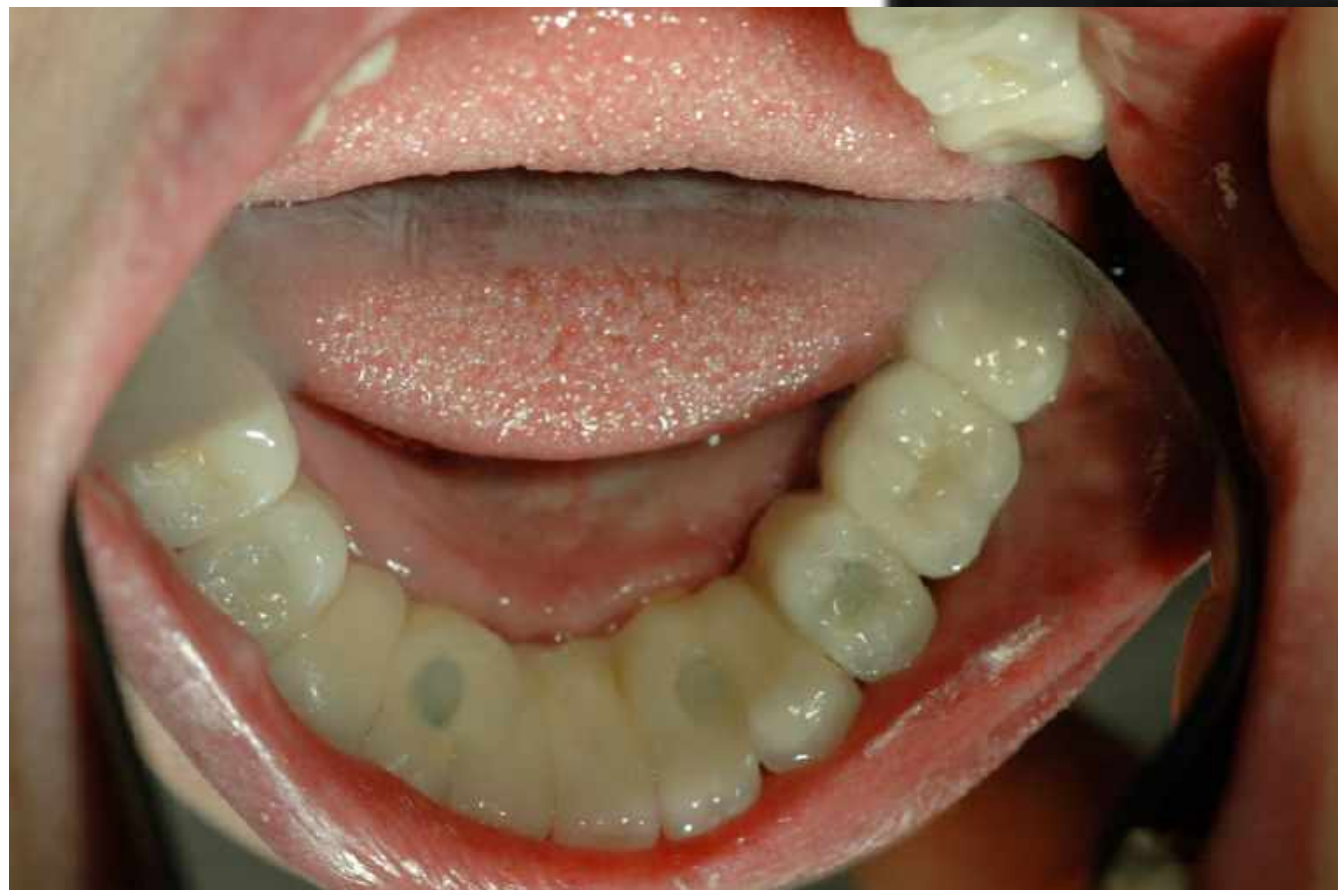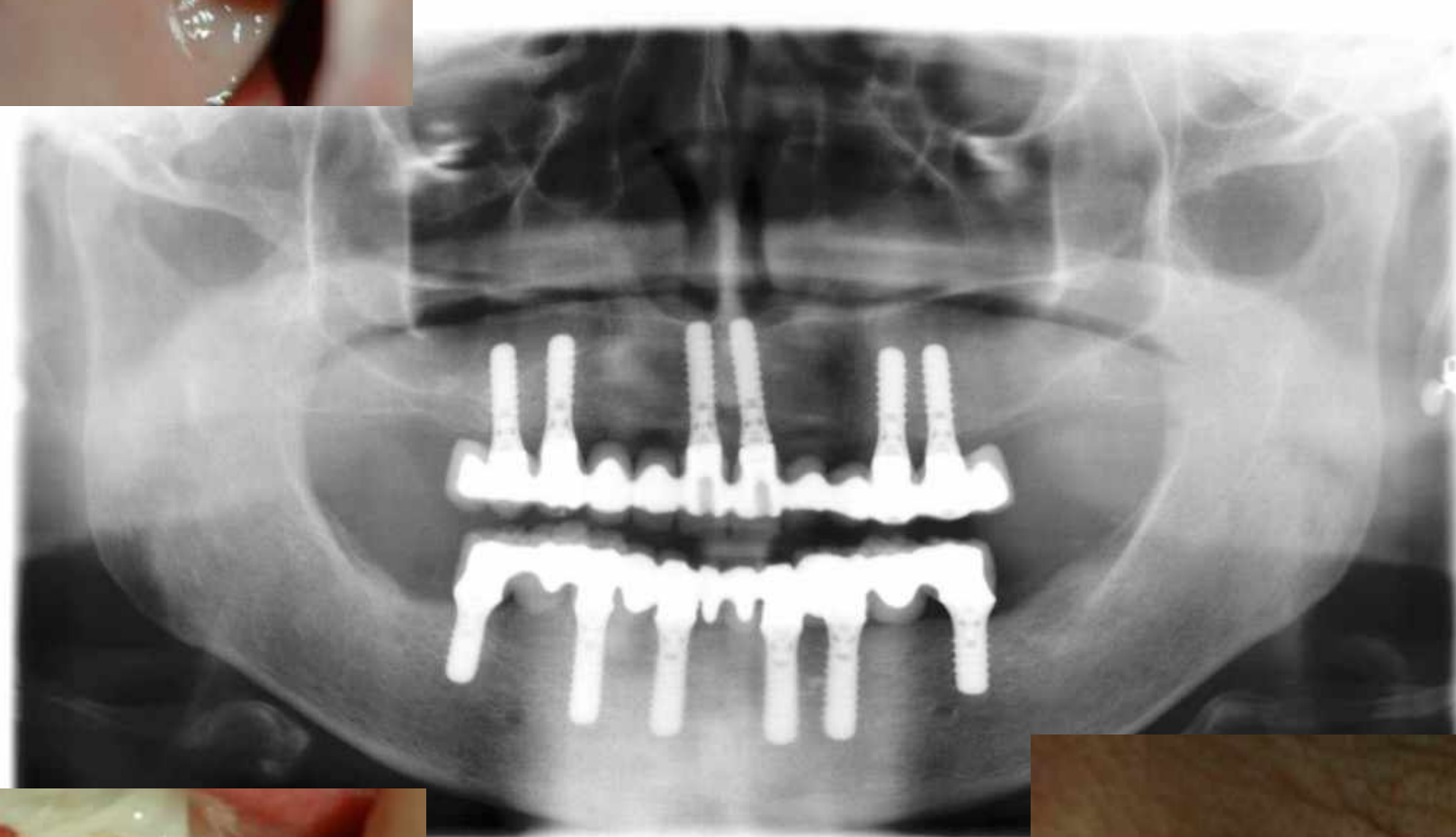
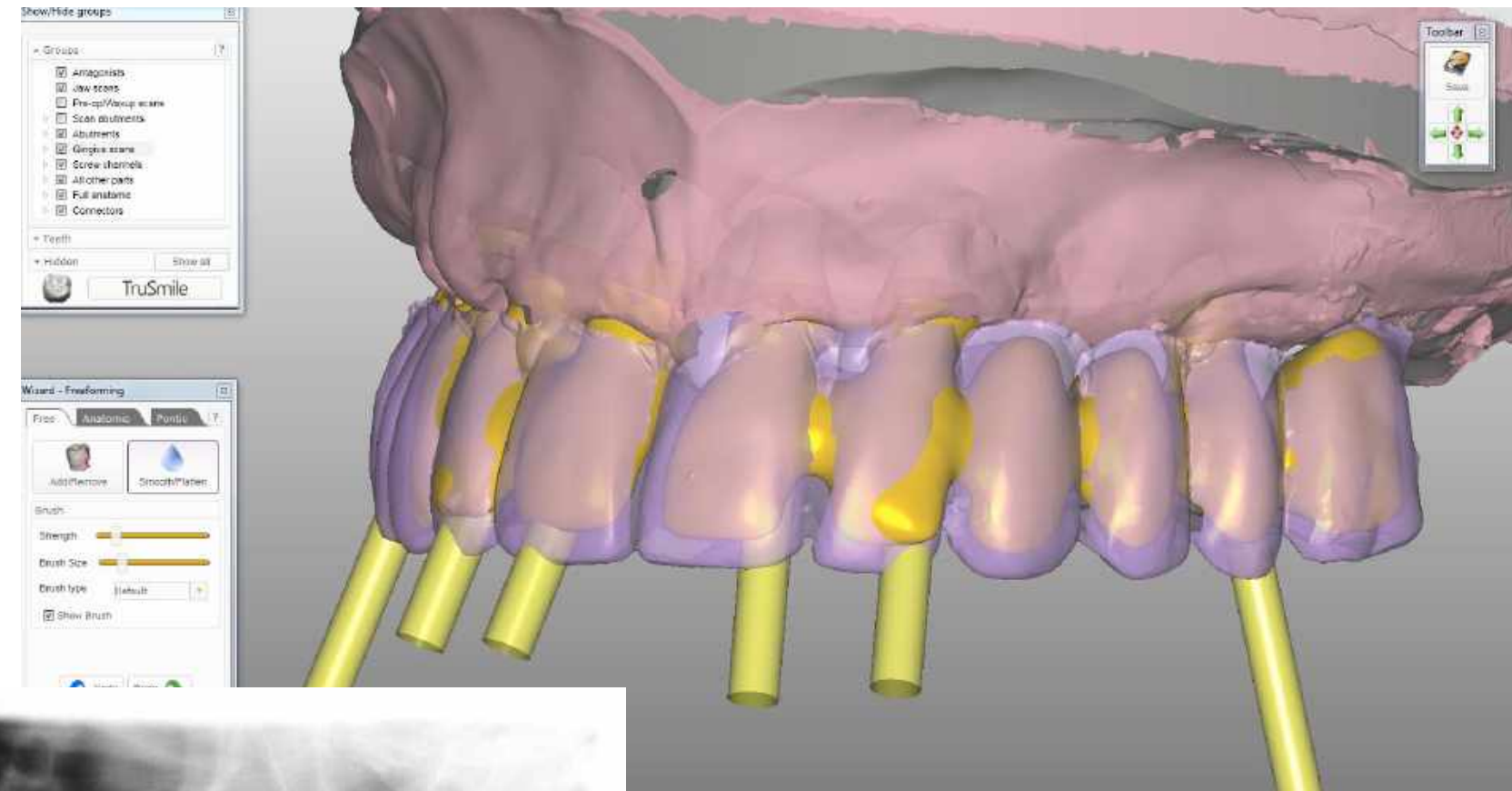
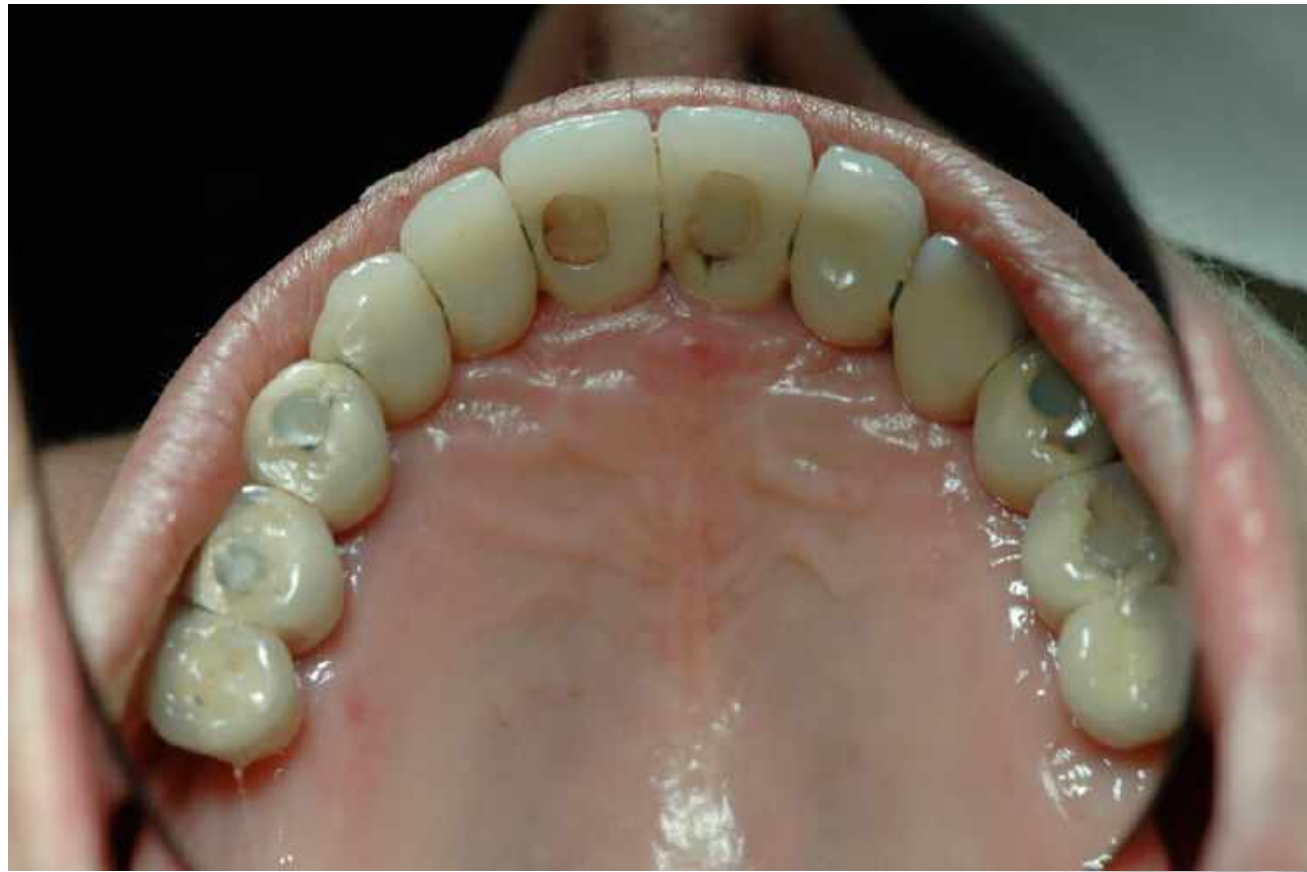100% succès implantaire et prothétique

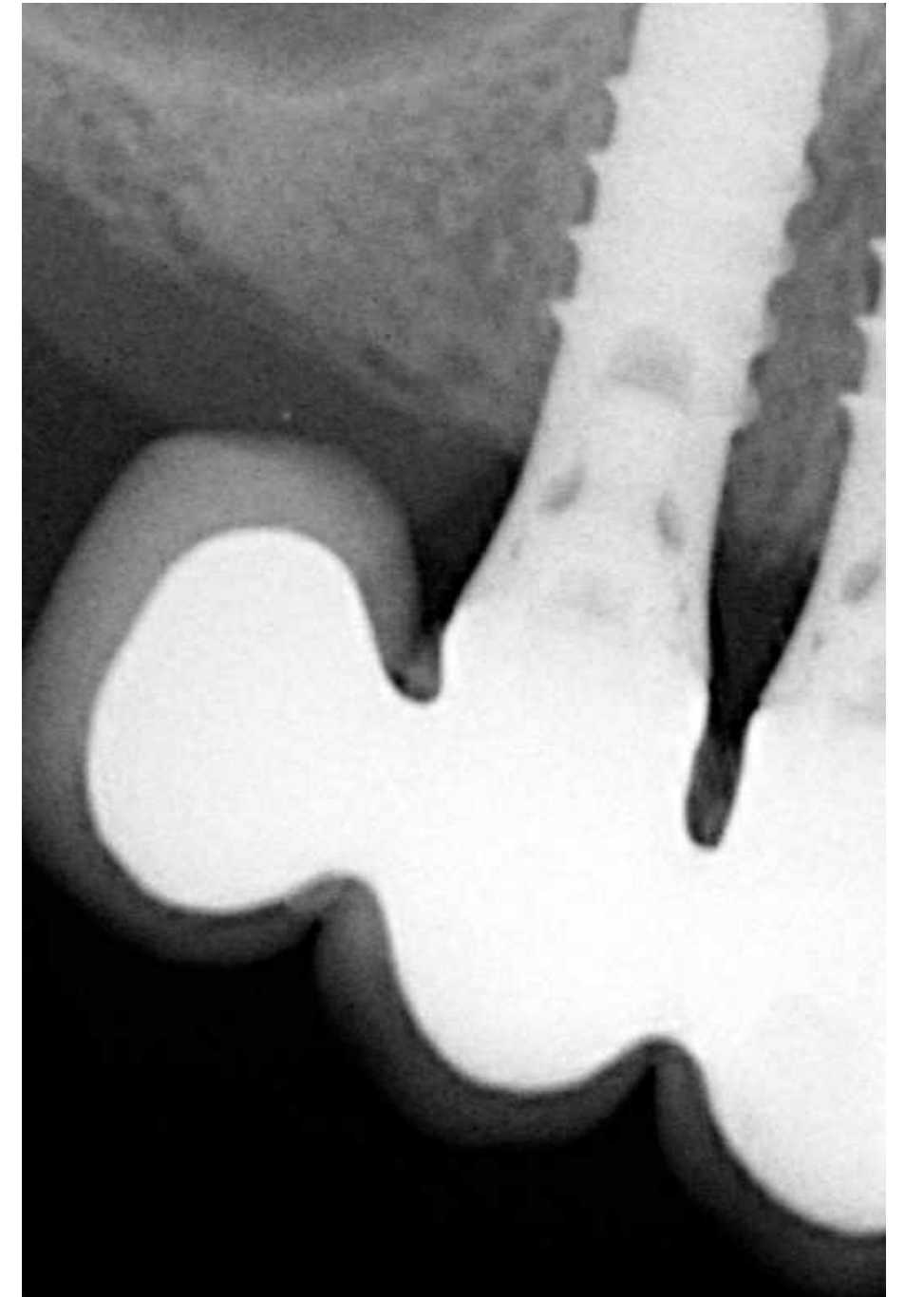
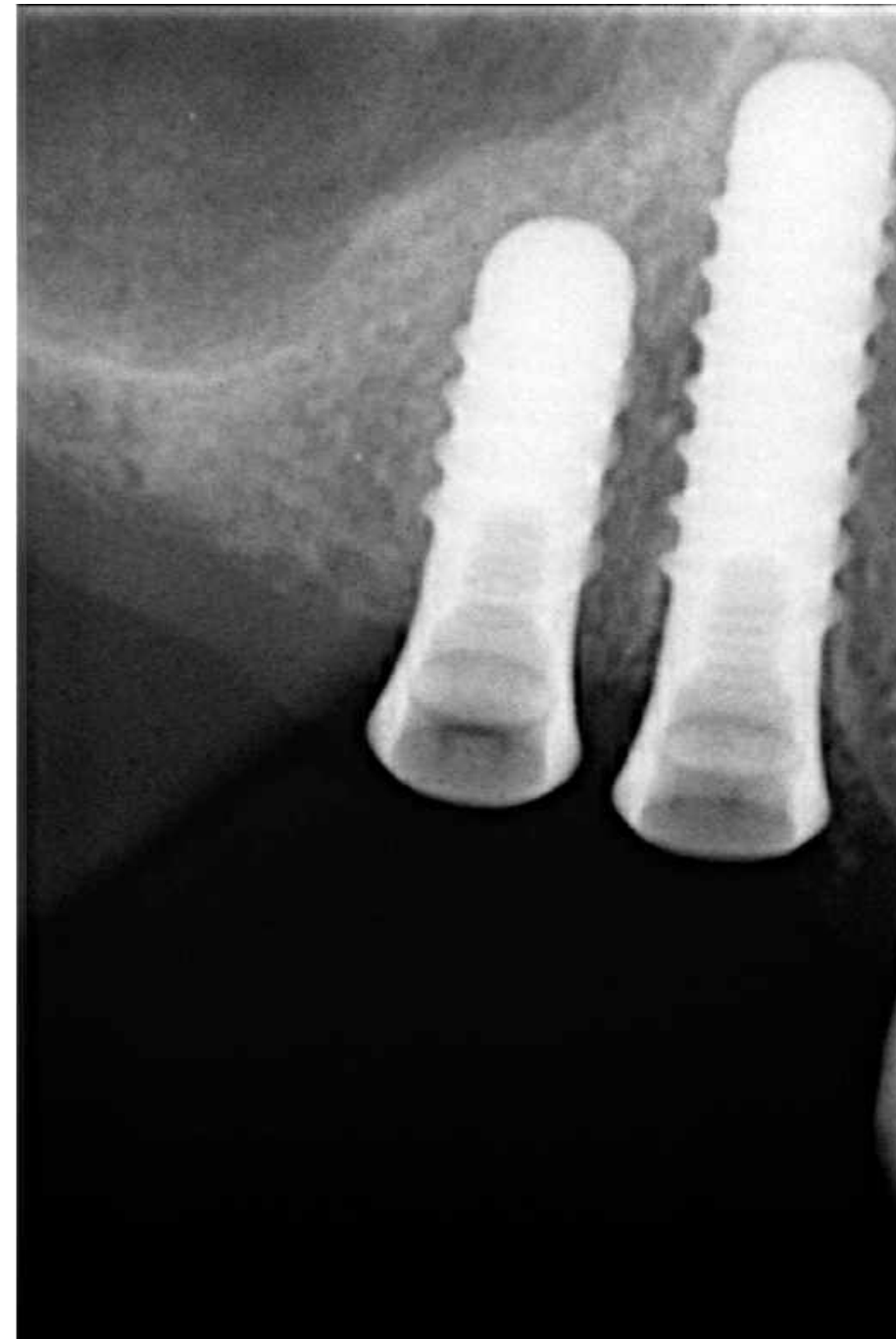
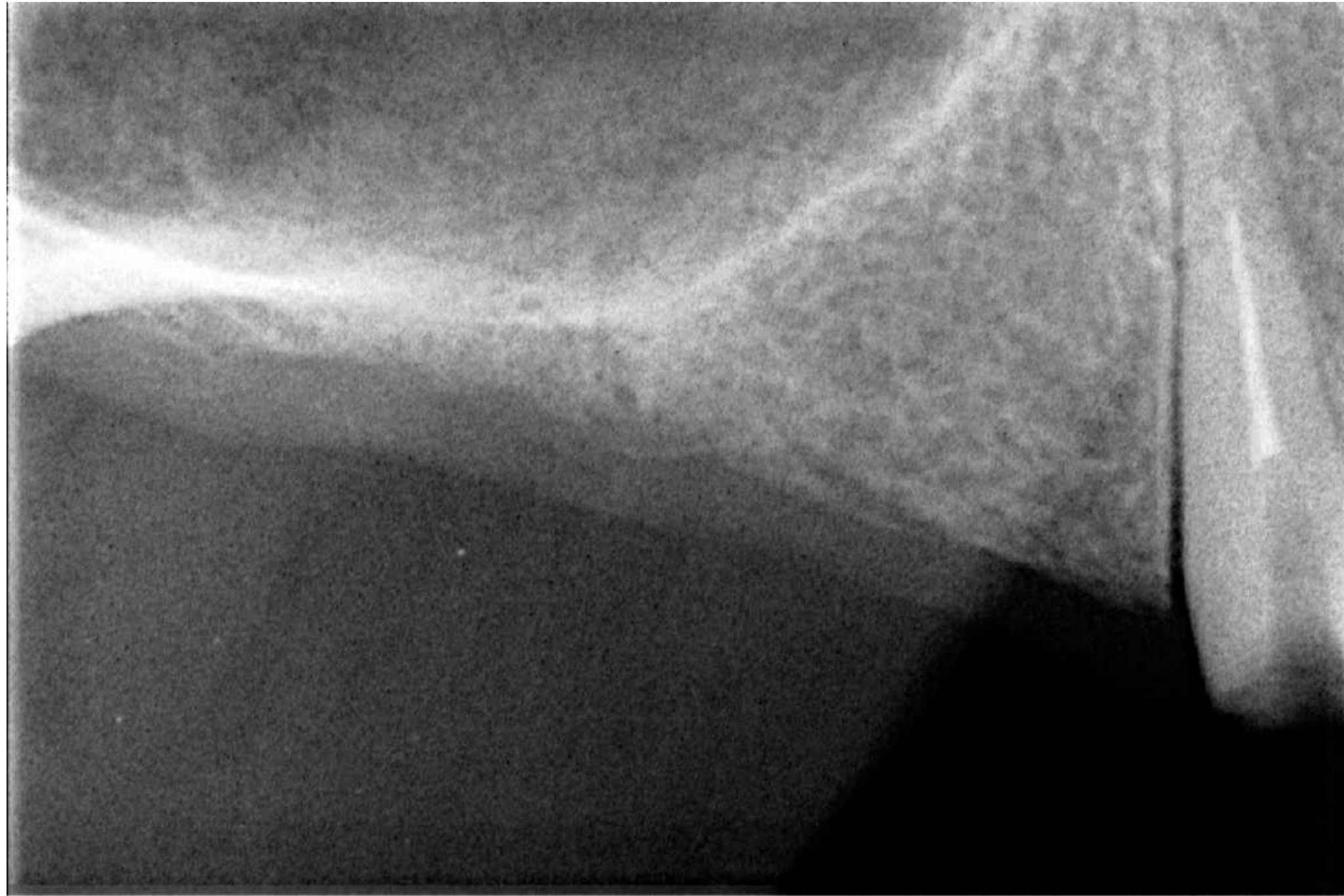
Francetti L, Agliardi E, Testori T, Romeo D, Taschieri S, Del Fabbro M. Immediate rehabilitation of the mandible with fixed full prosthesis supported by axial and tilted implants: interim results of a single cohort prospective study. Clin Implant Dent Relat Res. 2008 Dec;10(4):255-63.

Guidelines : ITI Treatment Guide Vol.4 Protocoles de Mise en Charge Immédiate

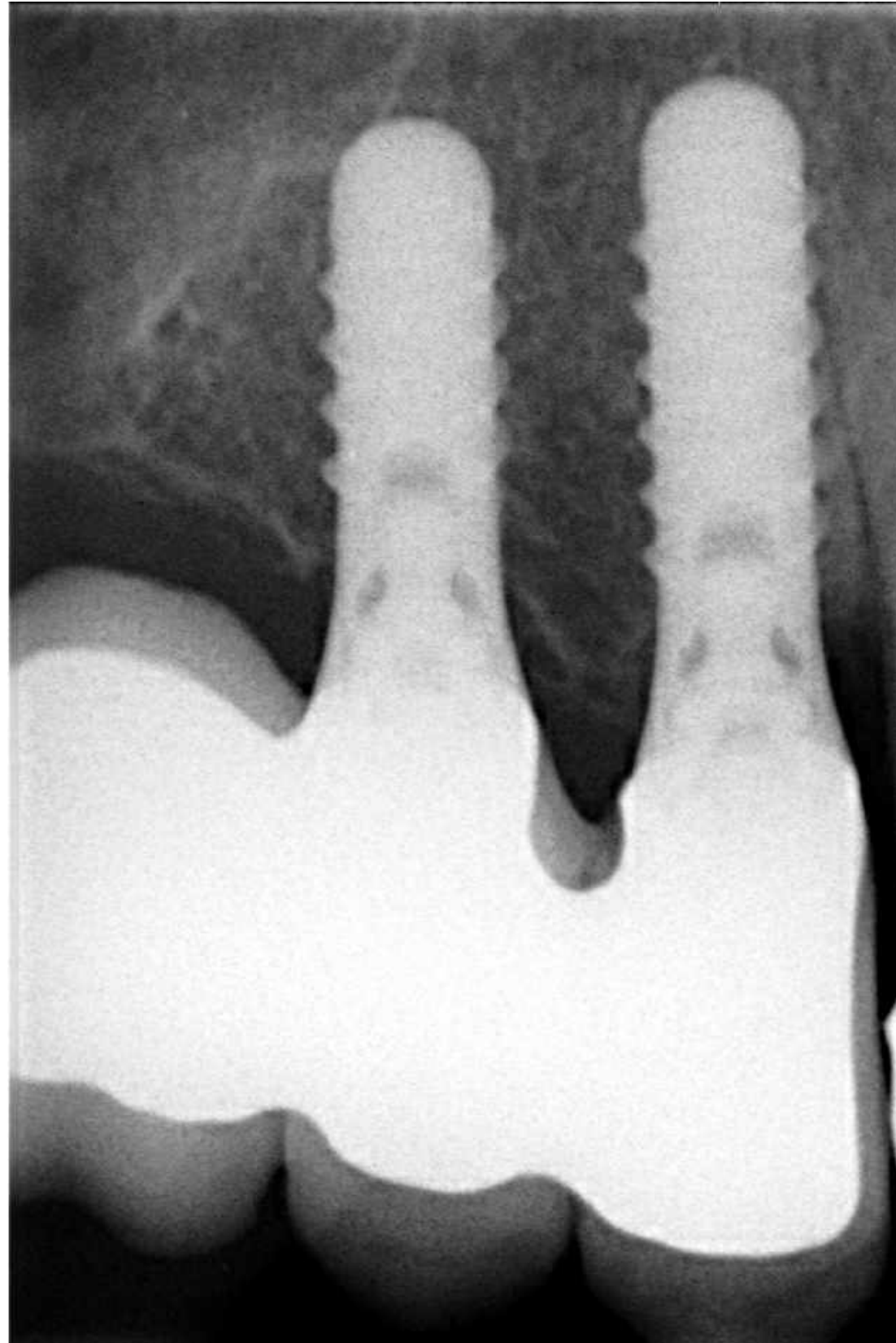


Conception des implants et des prothèses				
Mise en charge conventionnelle	DC	VSC	VSC	VSC
Mise en charge précoce	DCI	DC	DC	DC
Mise en charge immédiate	DCI	BDC	BDC	BDC

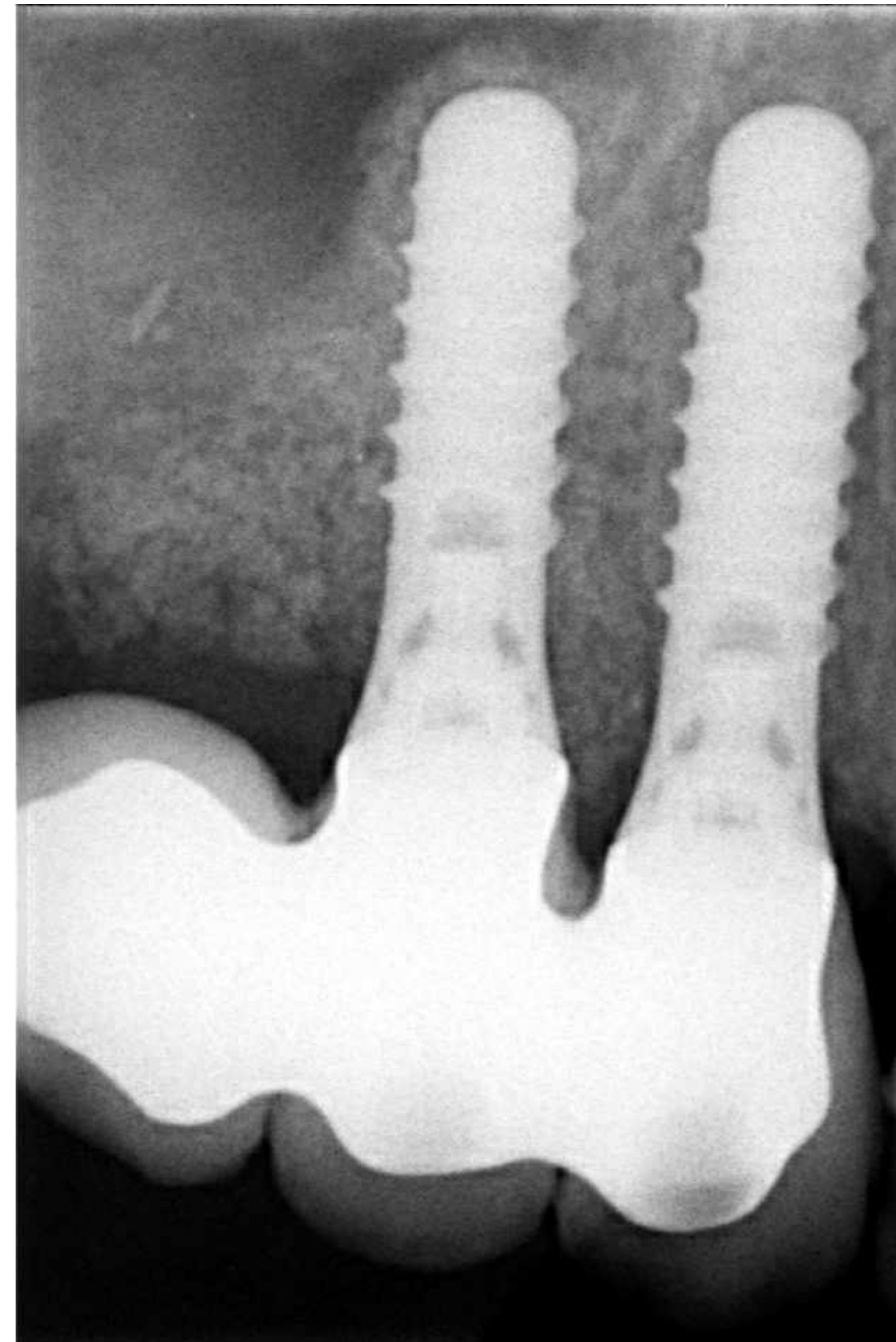




9 ans



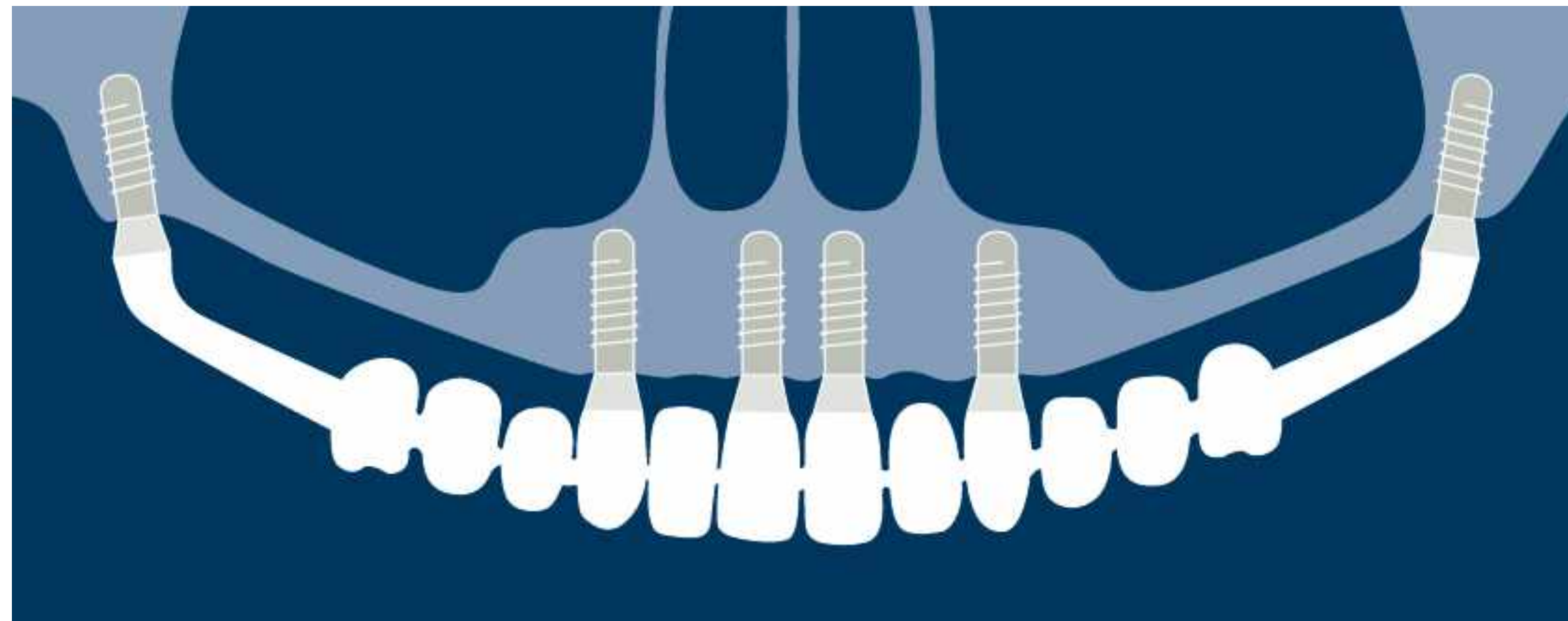
7 ans



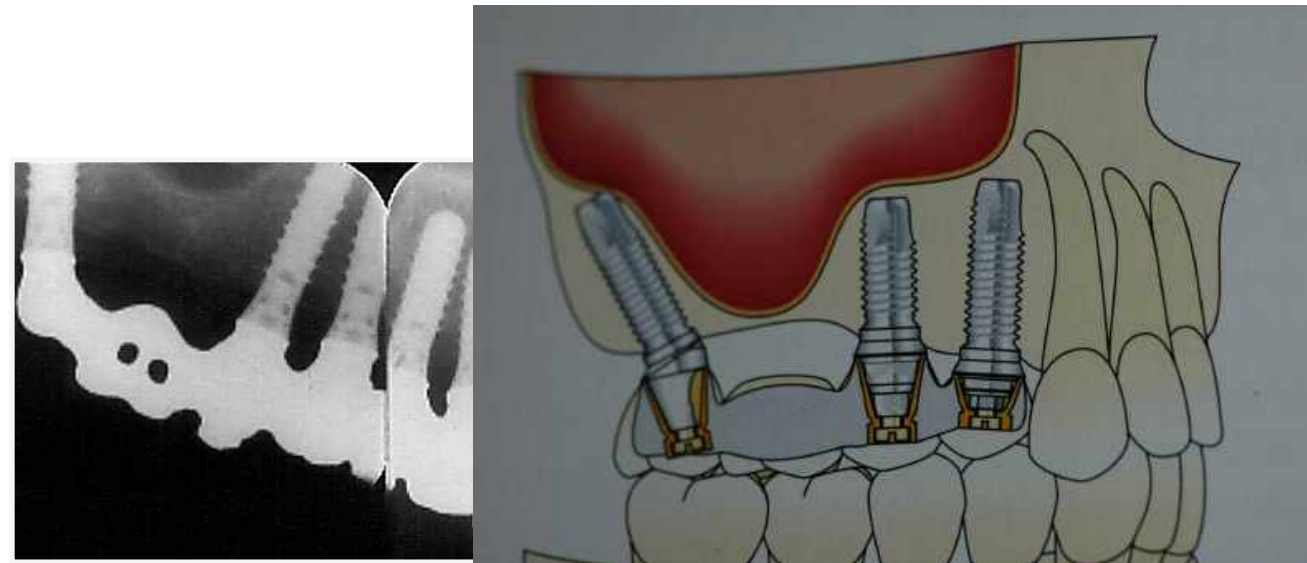
5 ans

Taux de succès implantaires en mise en charge immédiate complète

1. L'implant tubérositaire 4,8/10 WN est-elle une option fiable ?

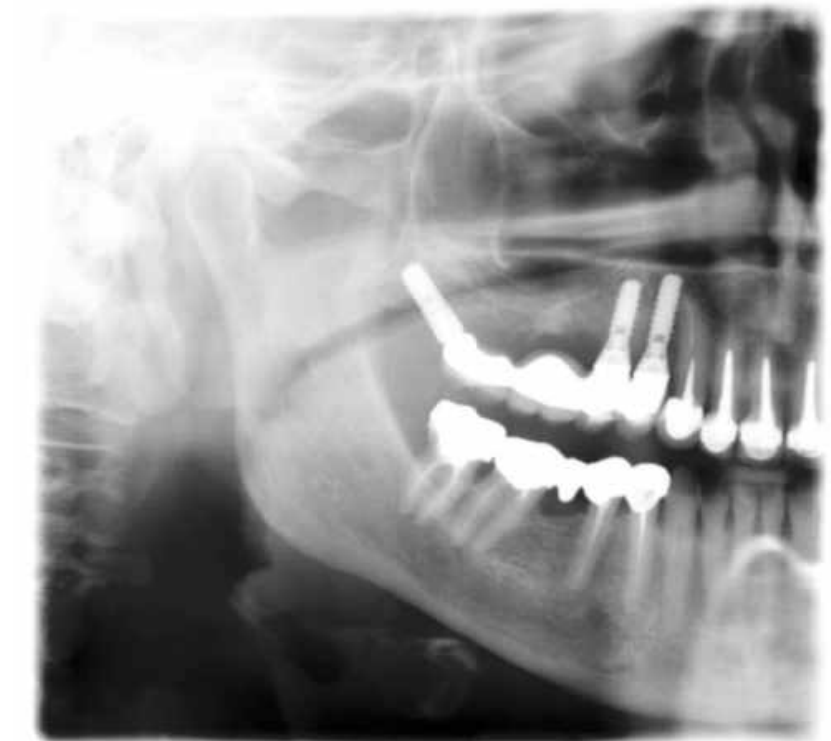

Revue de littérature



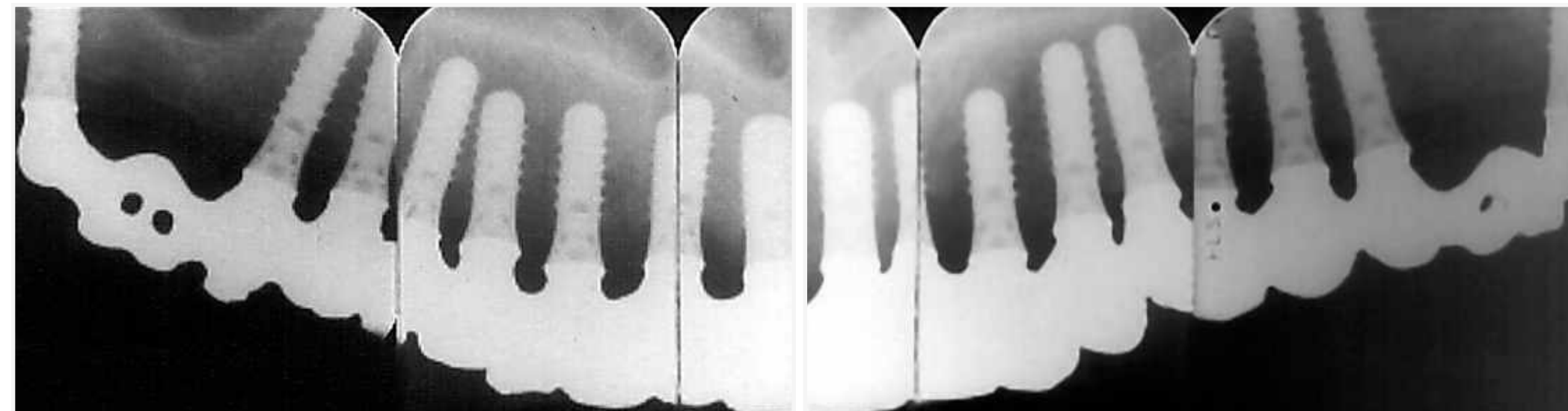
120 implants dans 45 sinus

Taux de survie implants
dans greffe de sinus : 97,5%
dans région postérieure maxillaire : 90,3%

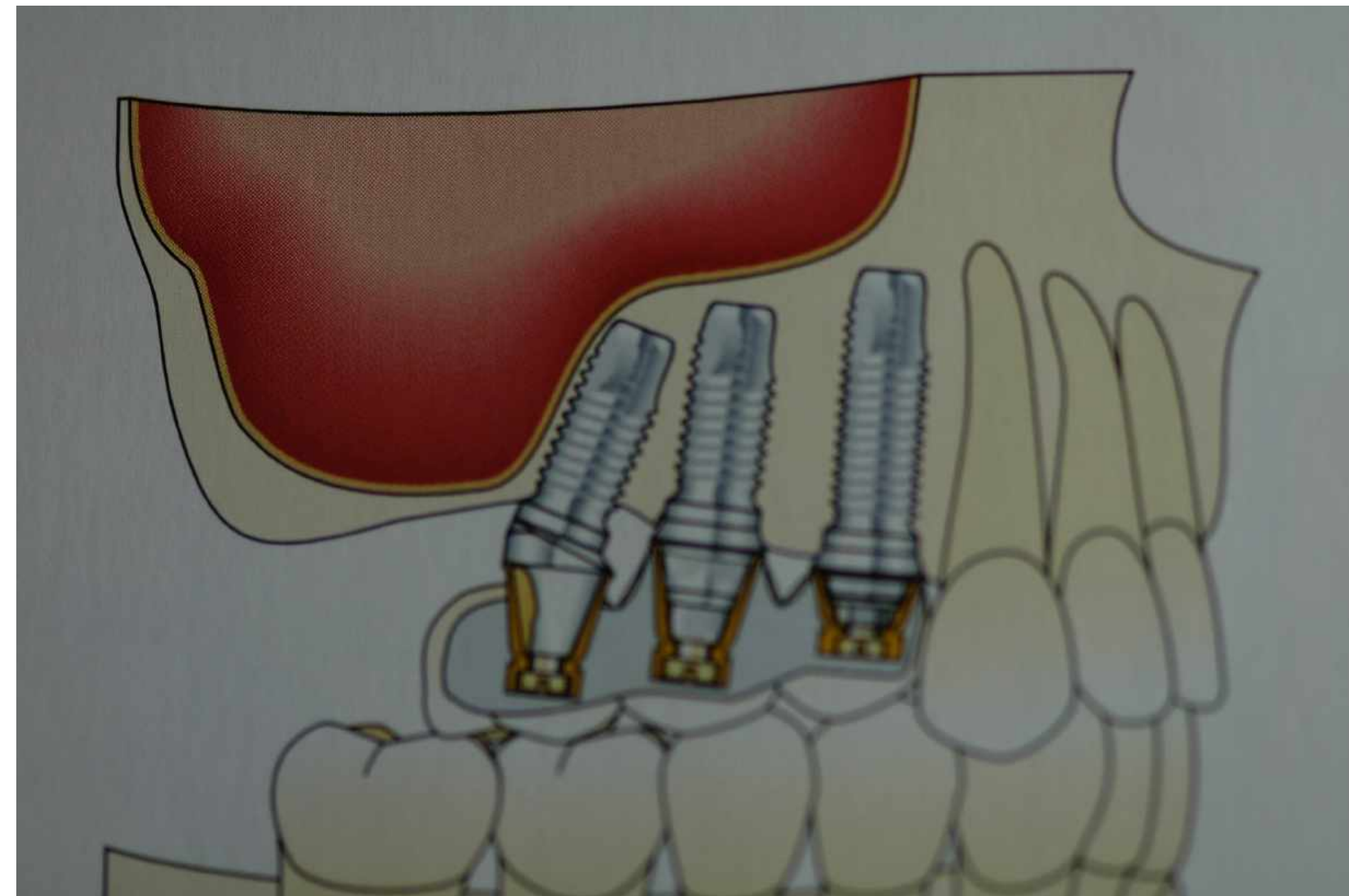
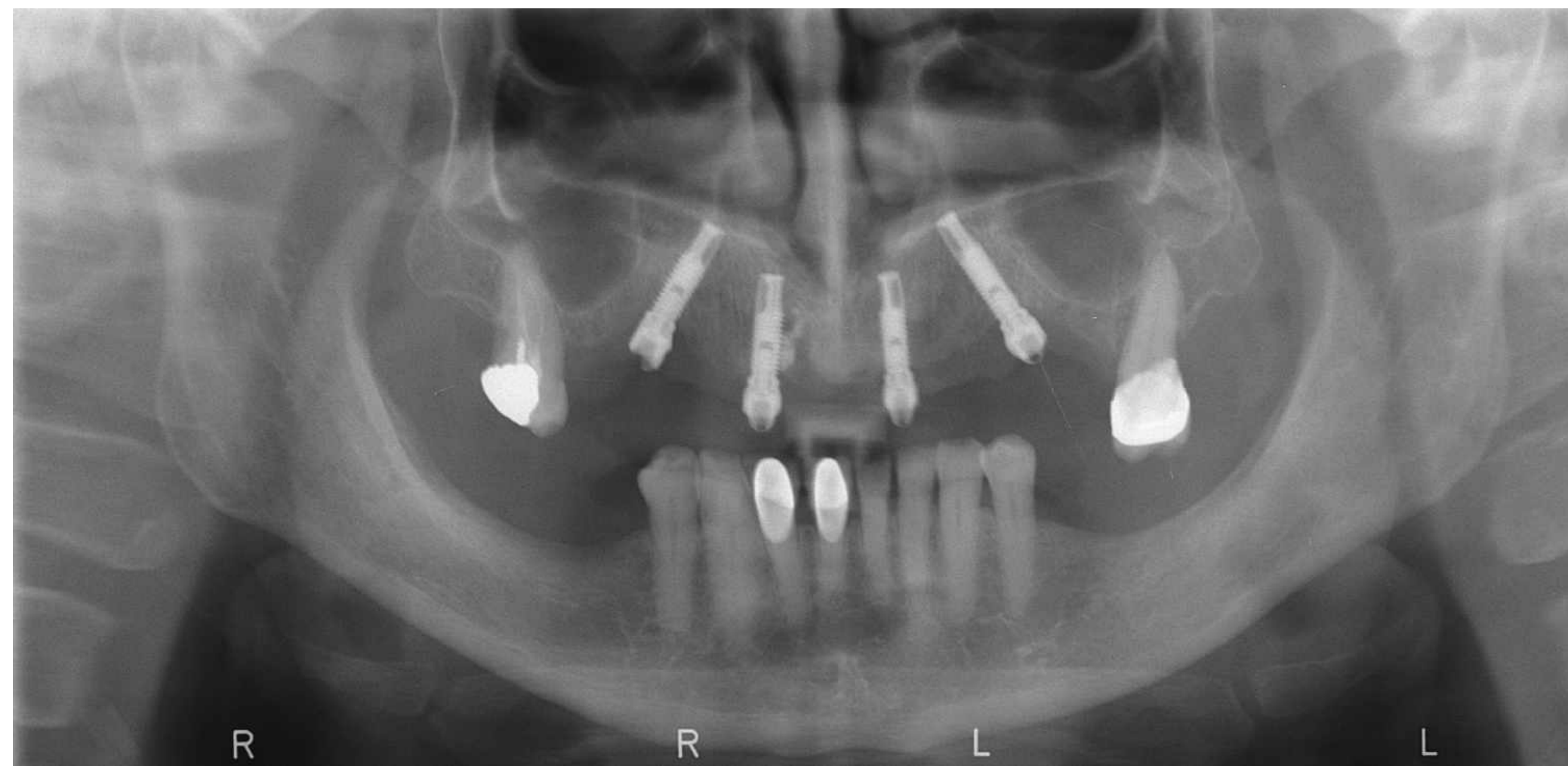


Pas en mise en charge immédiate

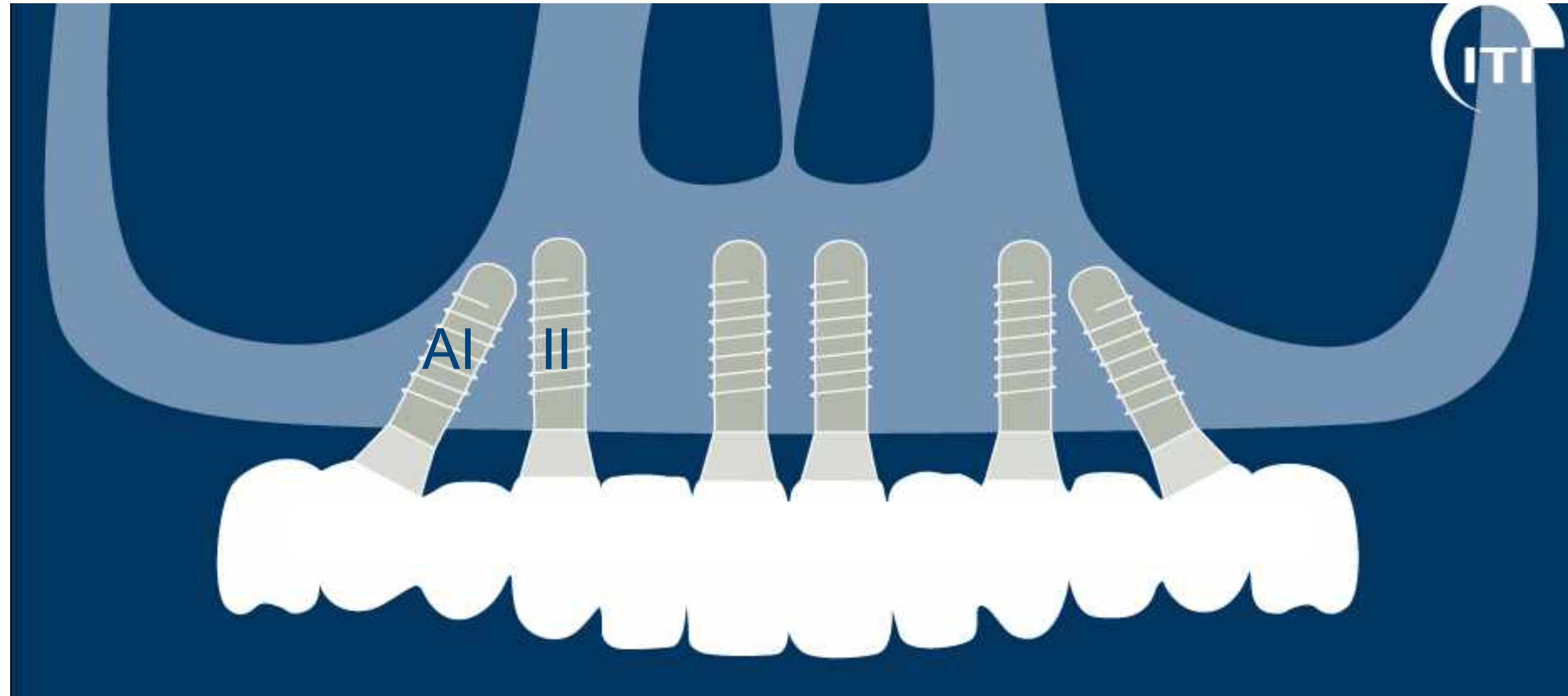
Olson JW et al, Long-Term assessment (5 to 71 months) of endosseous dental implants placed in the augmented maxillary sinus. *Ann Periodontol.* 2000 Dec;5(1):152-6.



Dentes Na Hora !



Teeth in an hour !



FILLION M^(1,2), AUBAZAC D^(1,3), CHAPAT Q⁽⁴⁾, NICOLAS E⁽⁴⁾. Bone Level changes around tilted implants in Fixed Complete Denture and Fixed Partial Denture : a retrospective study Europerio7 Vienna 2012. Poster n°0991

Objectifs de l'étude :



Stabilité osseuse péri-implantaire de l'implant angulé (AI)

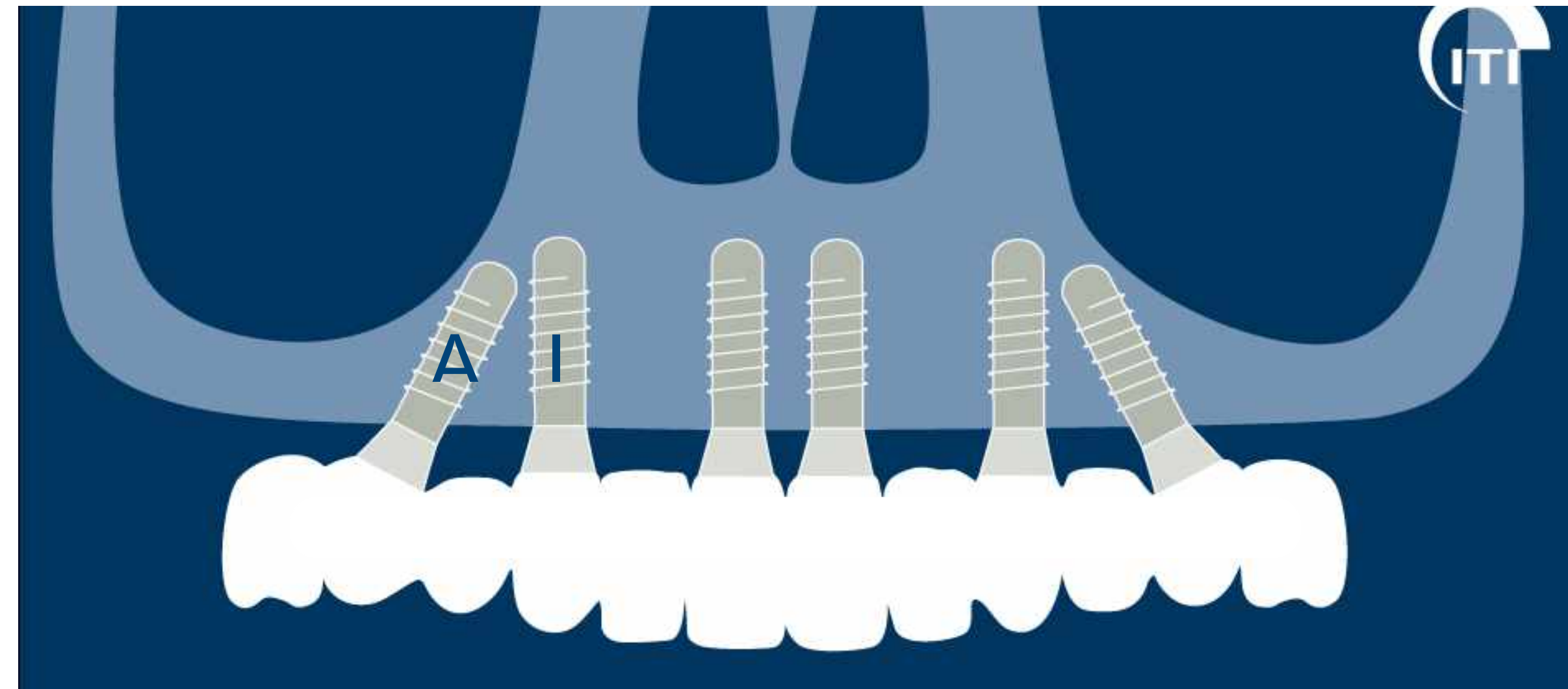
Stabilité osseuse péri-implantaire de l'implant axial intermédiaire (II)

Angulation limite ?

Bridge complet ou sectoriel ?

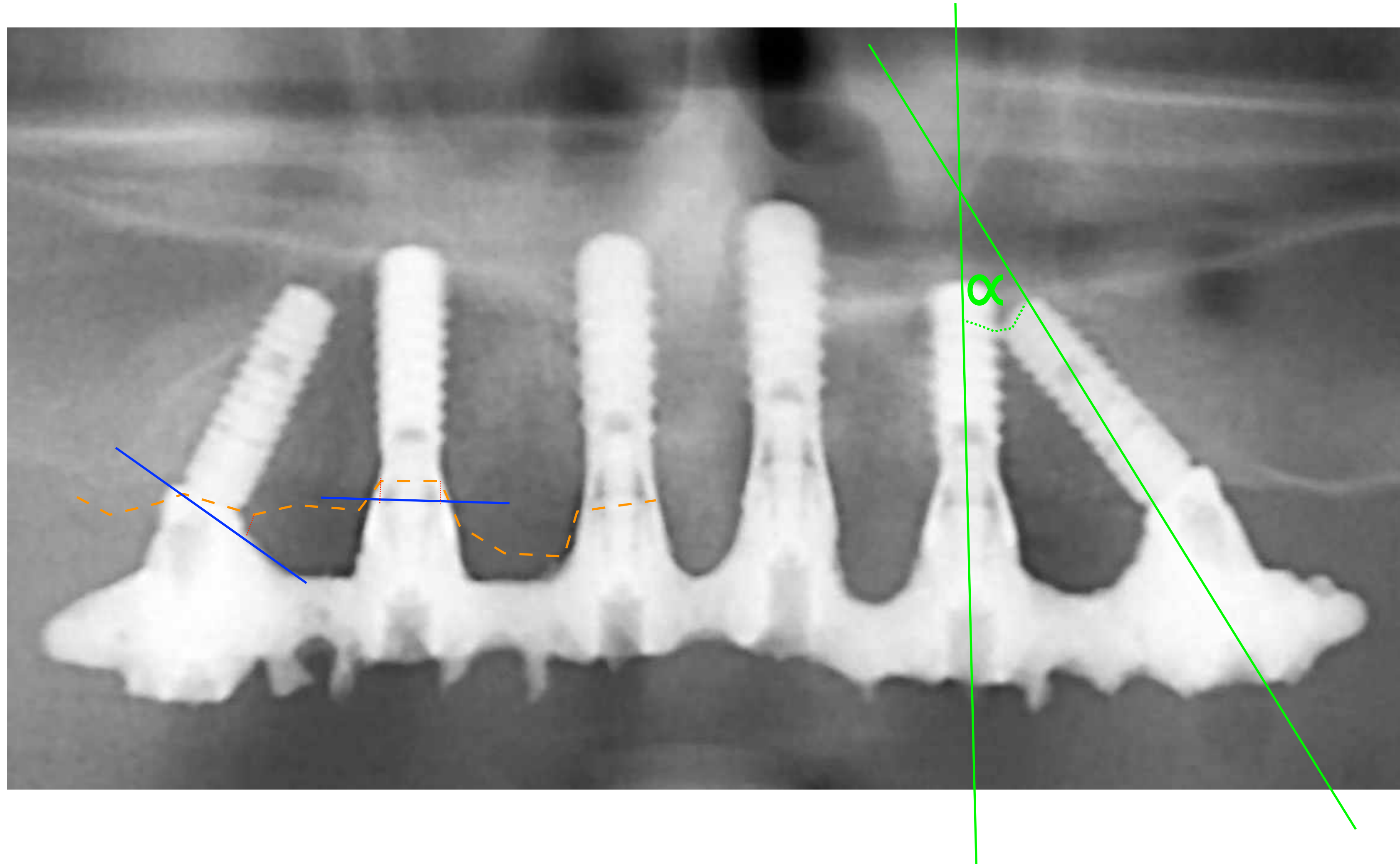
Taux de succès implantaire

Comparaison de nos résultats à la littérature



FILLION M^(1,2), AUBAZAC D^(1,3), CHAPAT Q⁽⁴⁾, NICOLAS E⁽⁴⁾. Bone Level changes around tilted implants in Fixed Complete Denture and Fixed Partial Denture : a retrospective study Europerio7 Vienna 2012. Poster n°0991

Matériel et Méthode :



Groupe test :

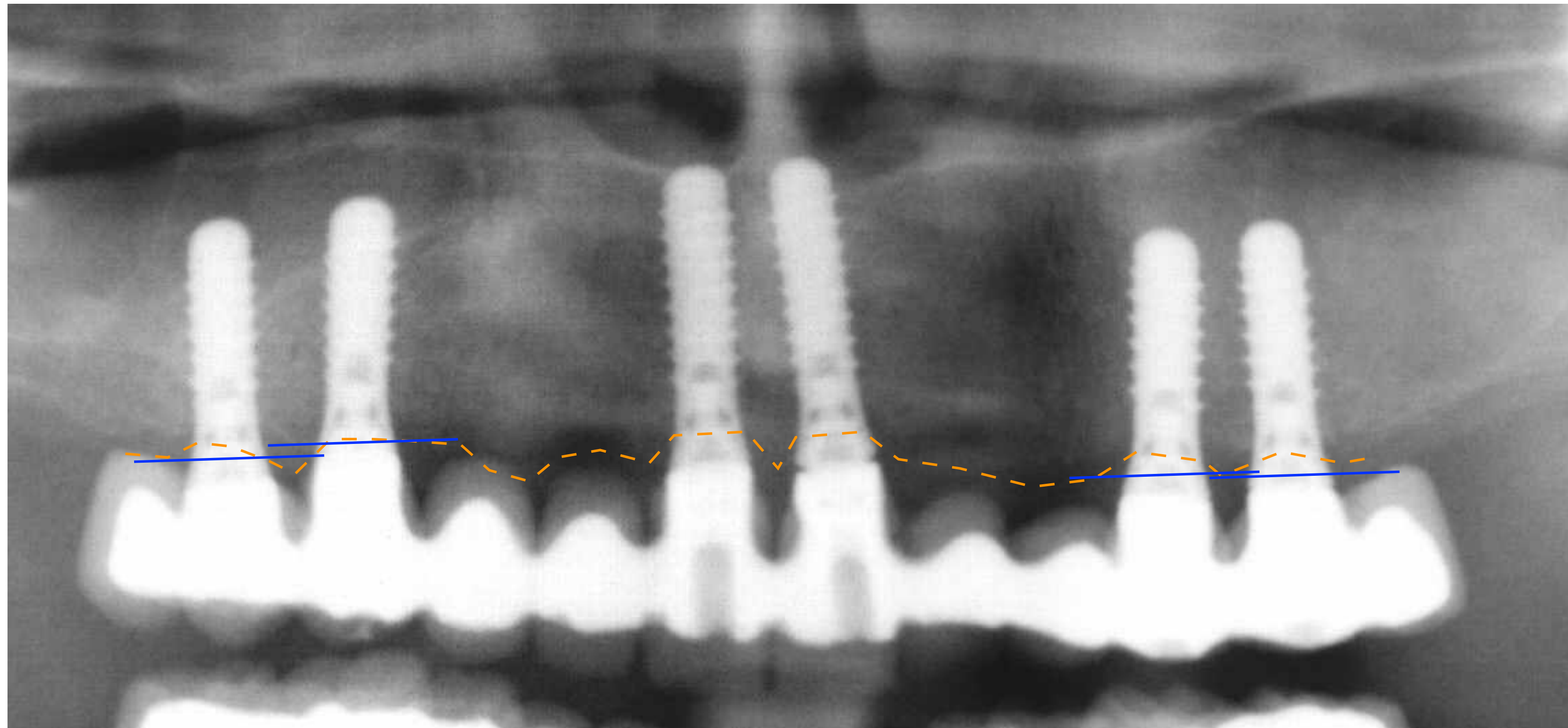
Investigateur calibré indépendant

Niveaux osseux comparés sur éléments radio remarquables

Angles sur grand axe

Exclusions :
Implants tubérositaires angulés

FILLION M^(1,2), AUBAZAC D^(1,3), CHAPAT Q⁽⁴⁾, NICOLAS E⁽⁴⁾. Bone Level changes around tilted implants in Fixed Complete Denture and Fixed Partial Denture : a retrospective study Europerio7 Vienna 2012. Poster n°0991



Groupe témoin :

Cantilevers distaux

Niveaux osseux comparés sur
éléments radio remarquables

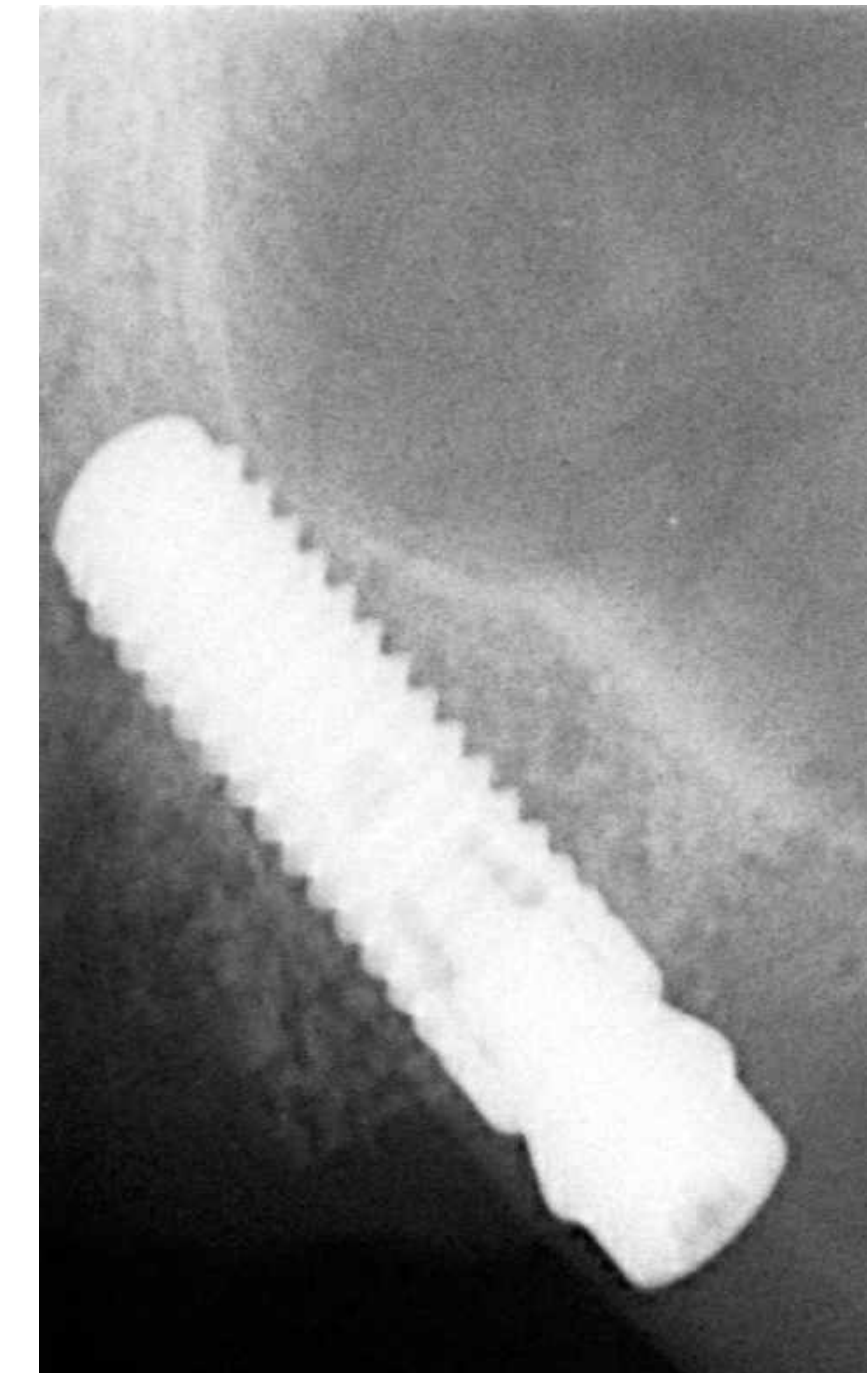
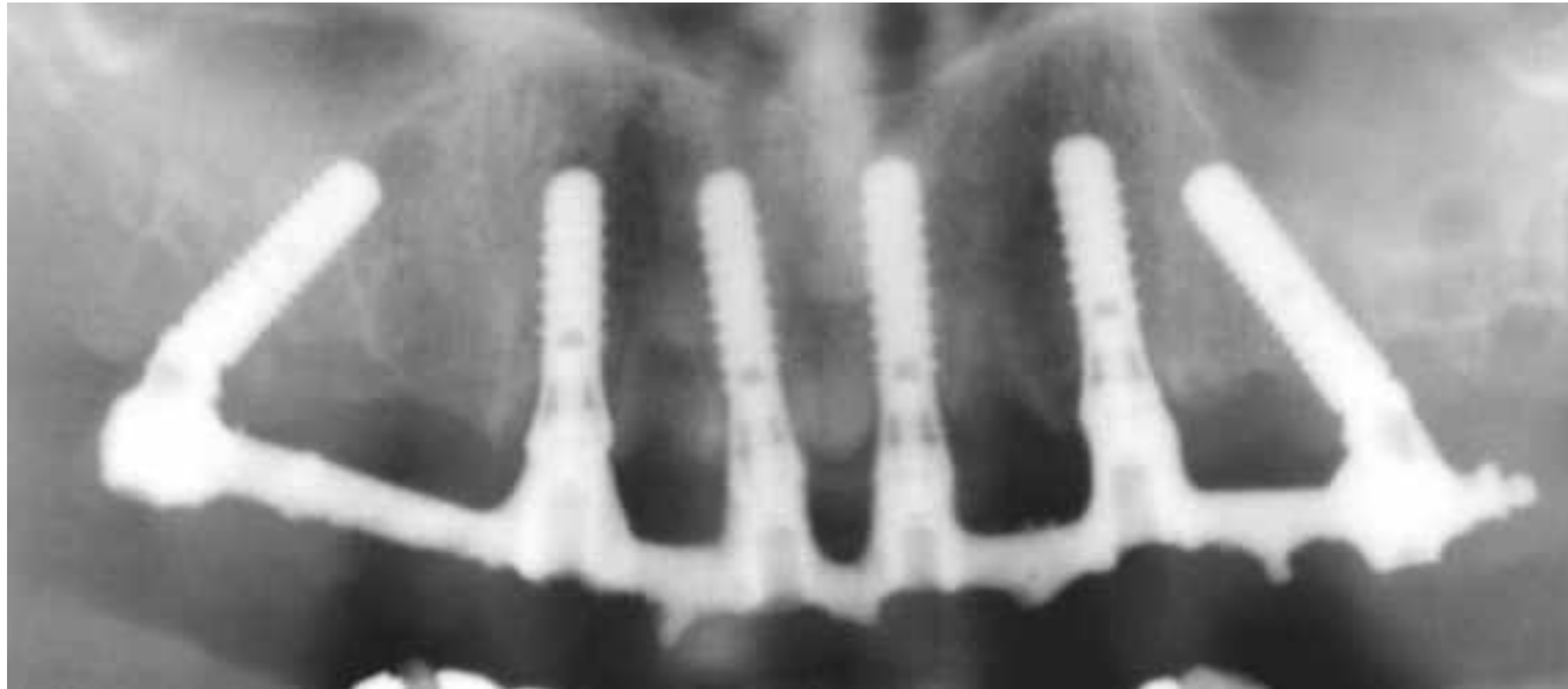
Exclusions :

Implants tubérositaires angulés

TYPE D'ÉTUDE ET ANALYSE STATISTIQUE



Etude rétrospective monocentrique multi-opérateurs



- Les pertes osseuses sont comparées par une série de test-t de STUDENT ($\alpha=0,05$).
- L'influence du genre, de la position implantaire, les habitudes tabagiques et la présence ou non d'un cantilever sont également testées par une série de tests-t. Dans le groupe "implants angulés", les éventuelles différences de perte osseuse selon le degré d'angulation sont testés de la même manière.

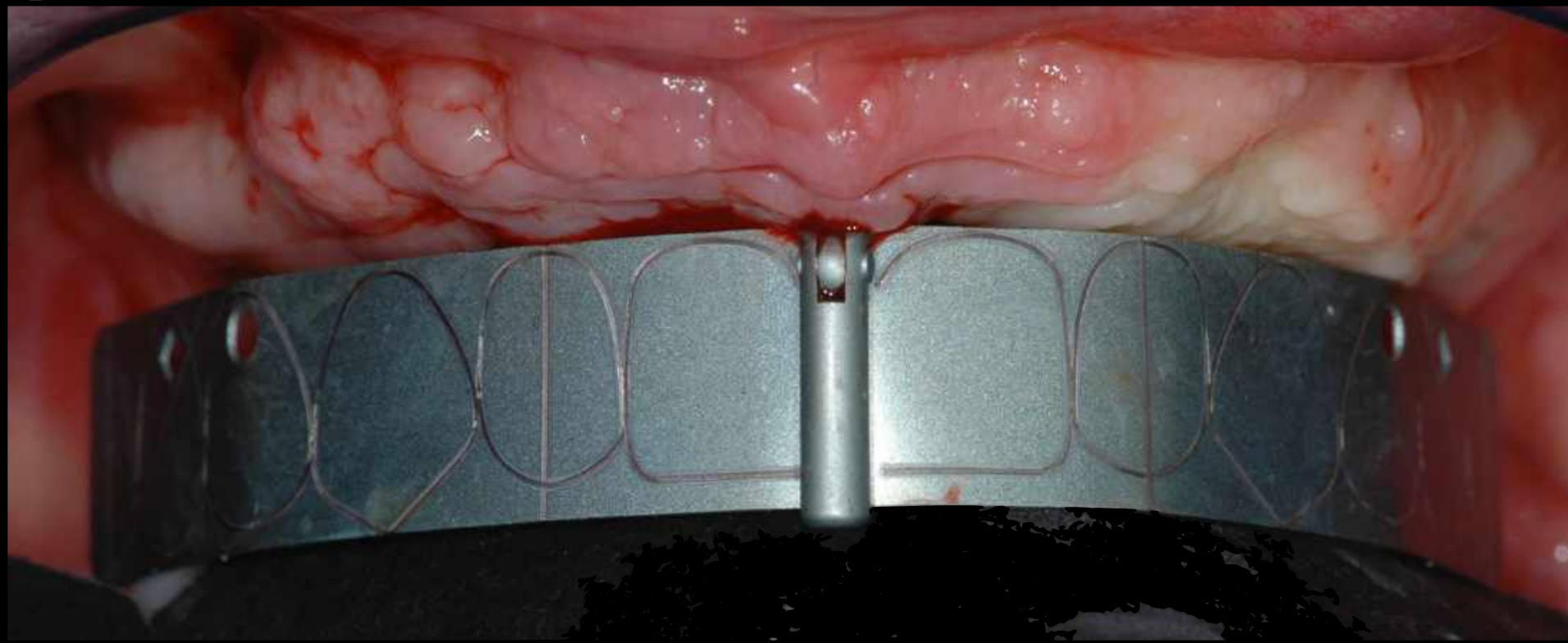
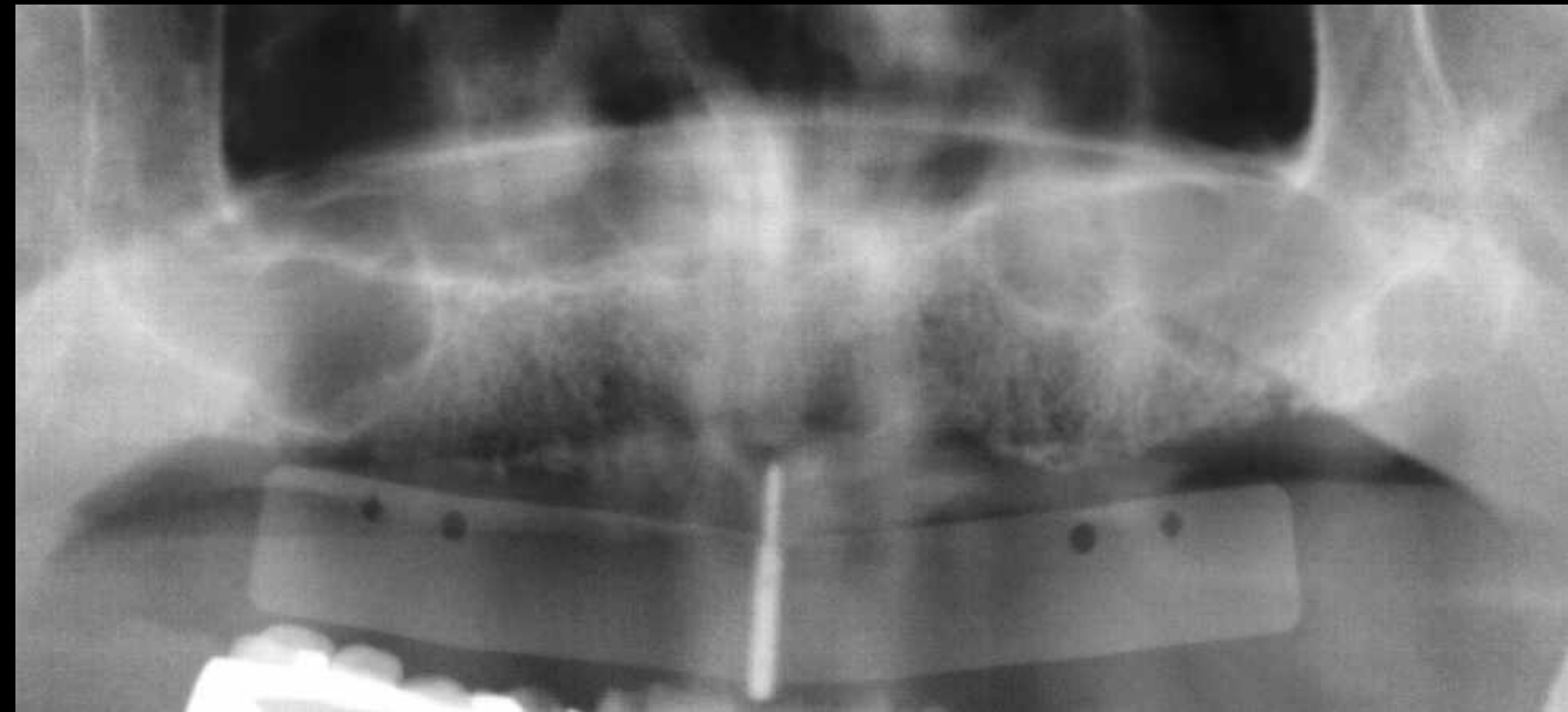
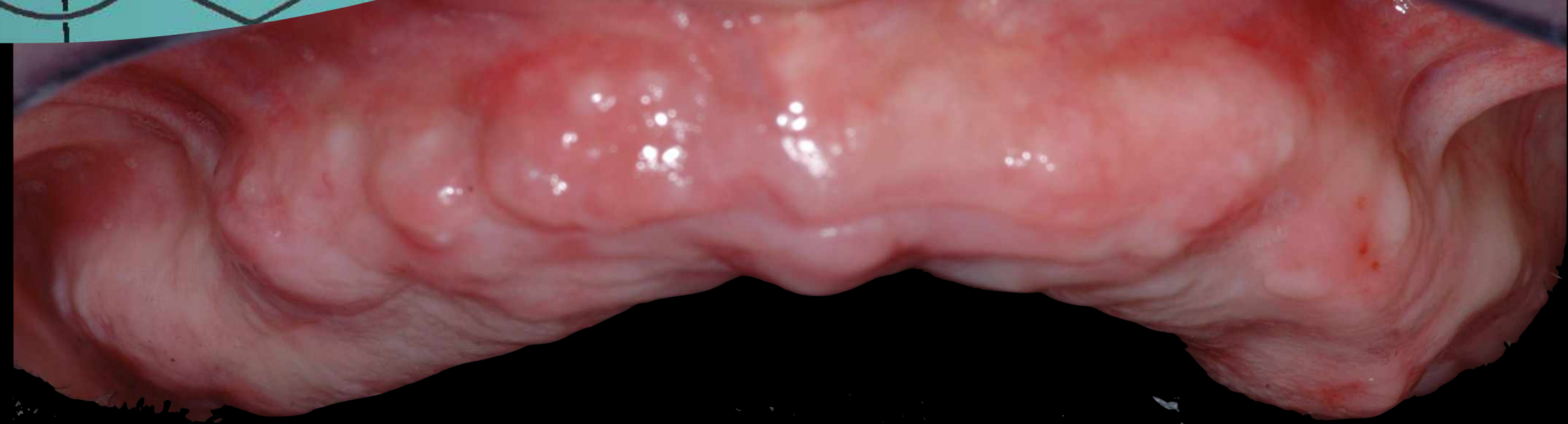
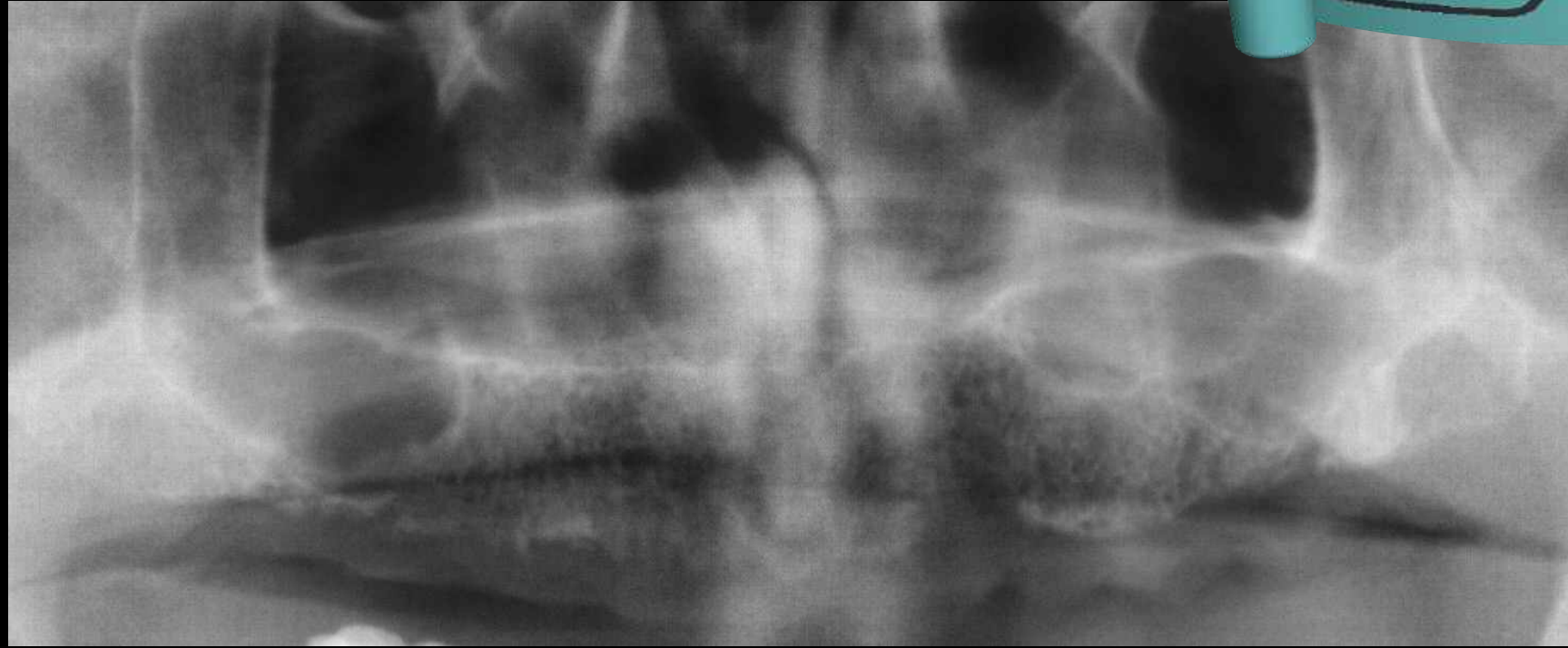Implant type	Bone loss	Standard deviation	P value
<i>Test Group</i>			
Posterior tilted	-0.59	0.89	P = 0.113 *
Axial Intercalary	-0.66	0.89	P = 0.735
<i>Control Group</i>			
Posterior axial	-1.06	1.42	P = 0.113 *
Axial intercalary	-0.77	1.47	P = 0.735

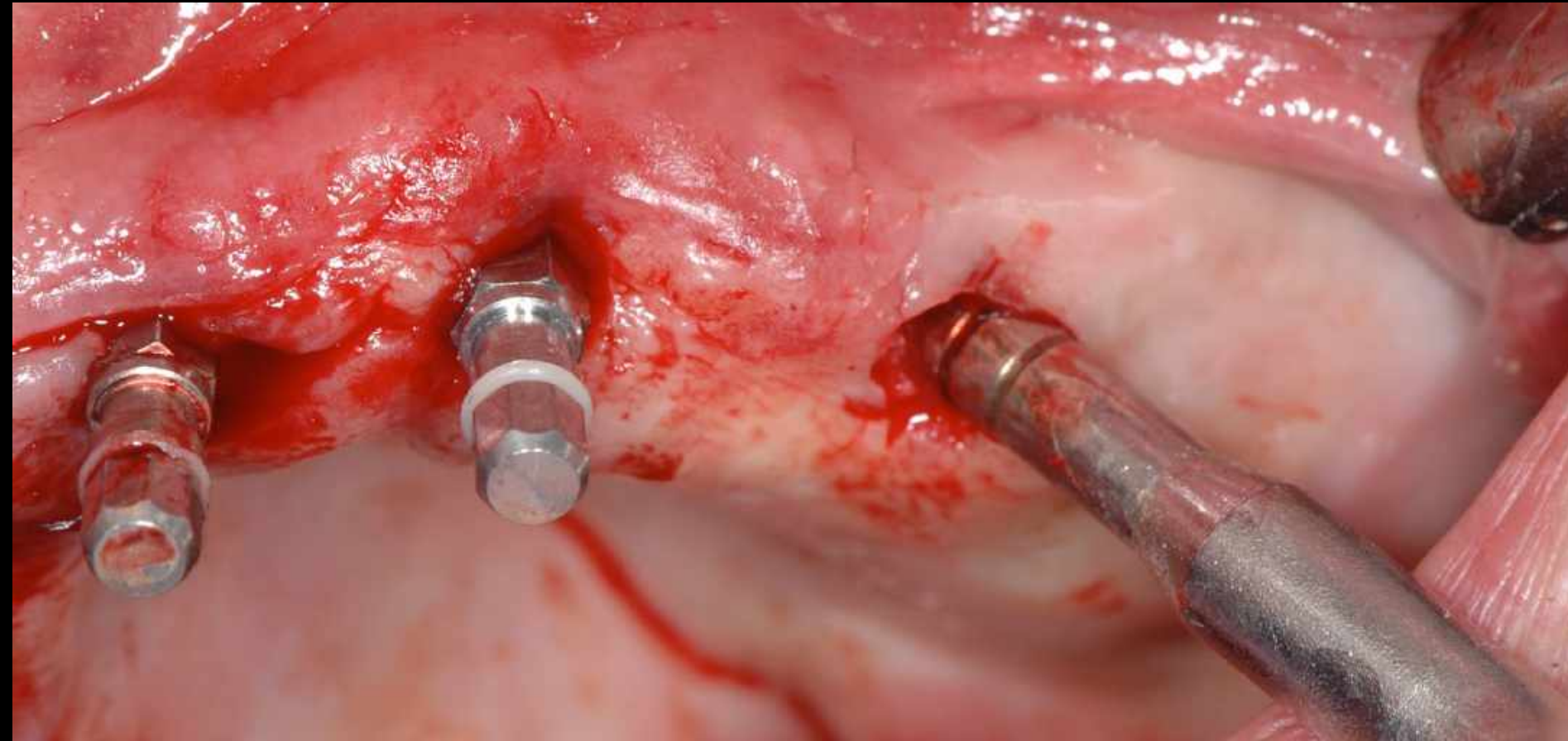
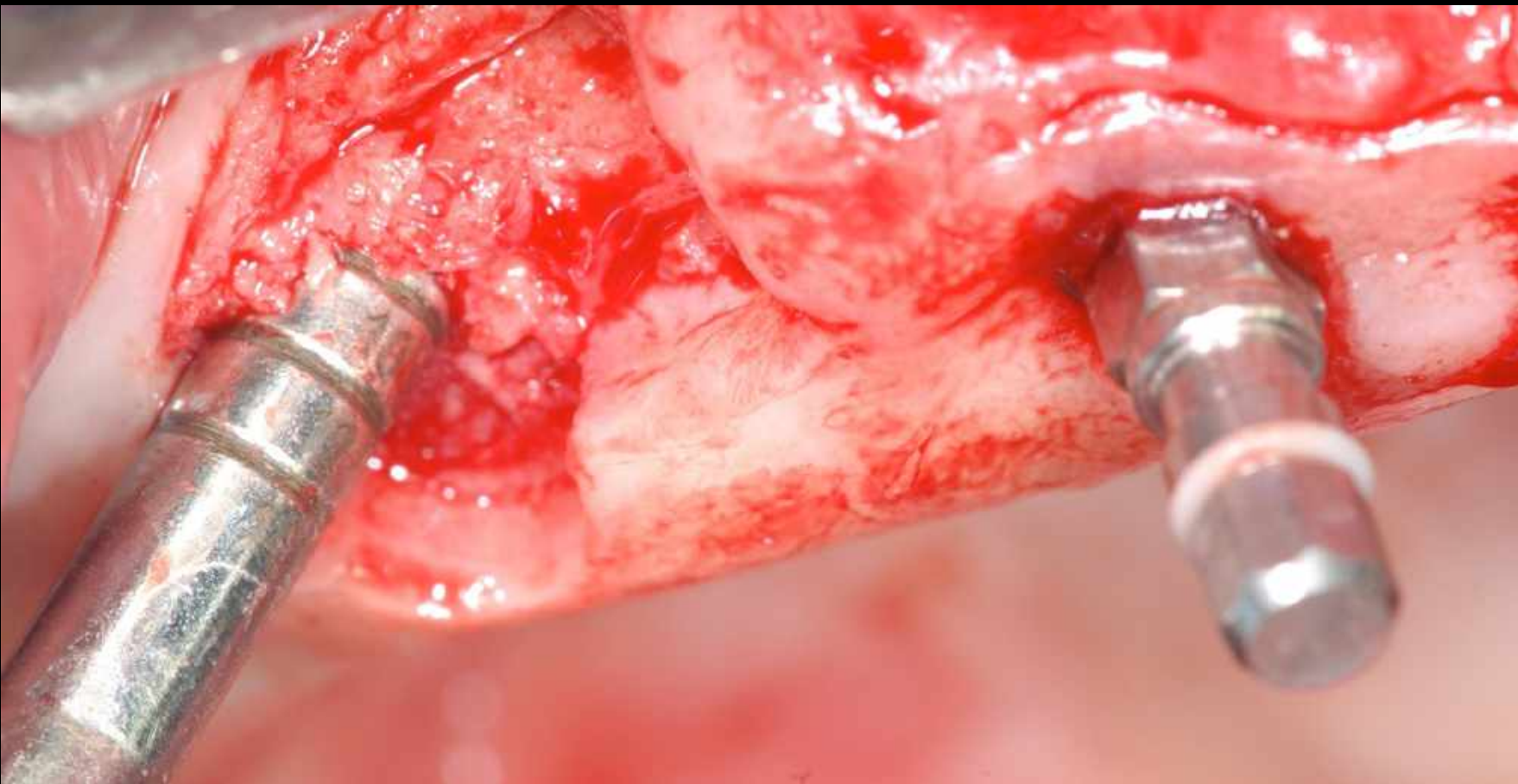
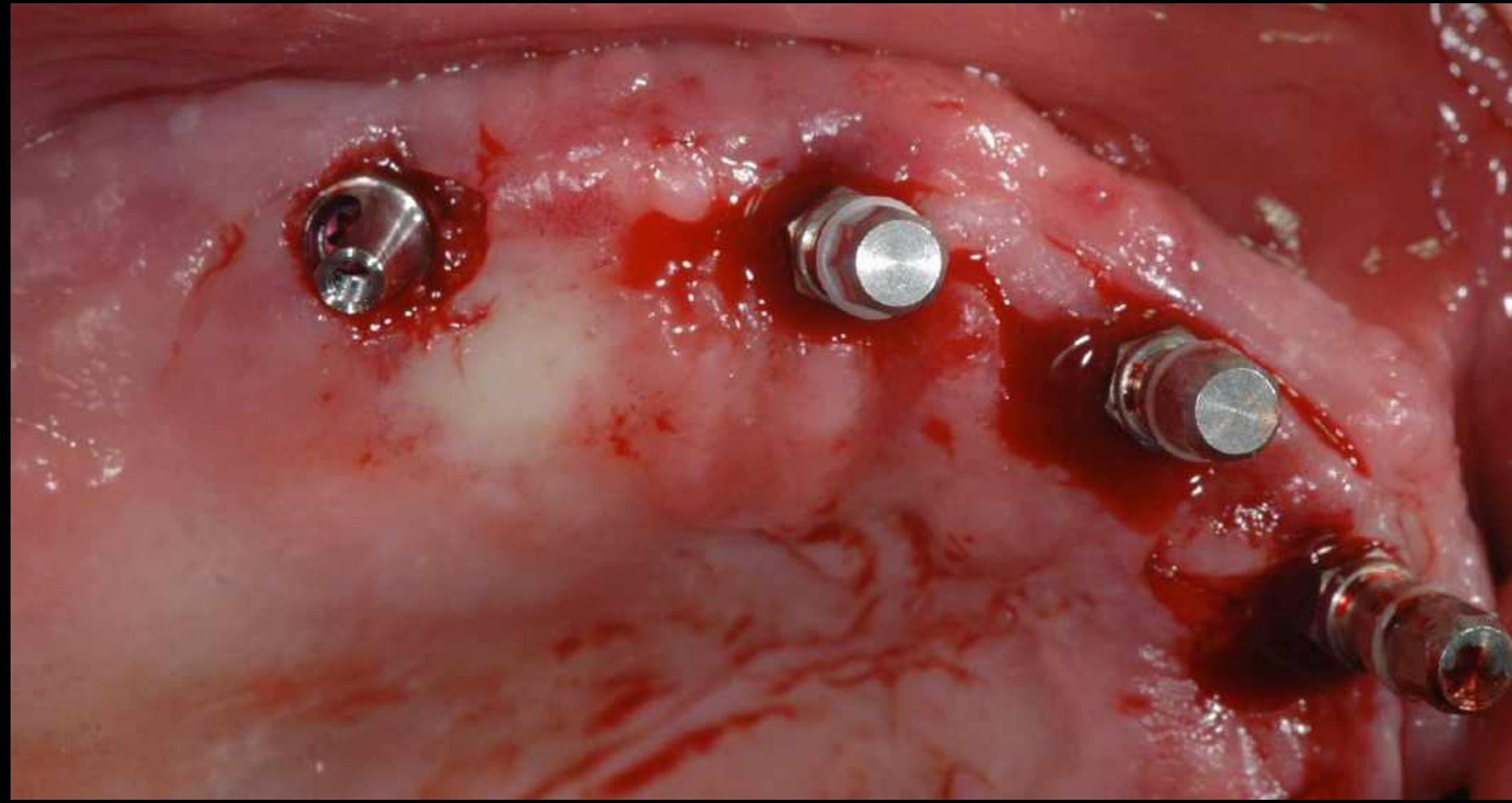
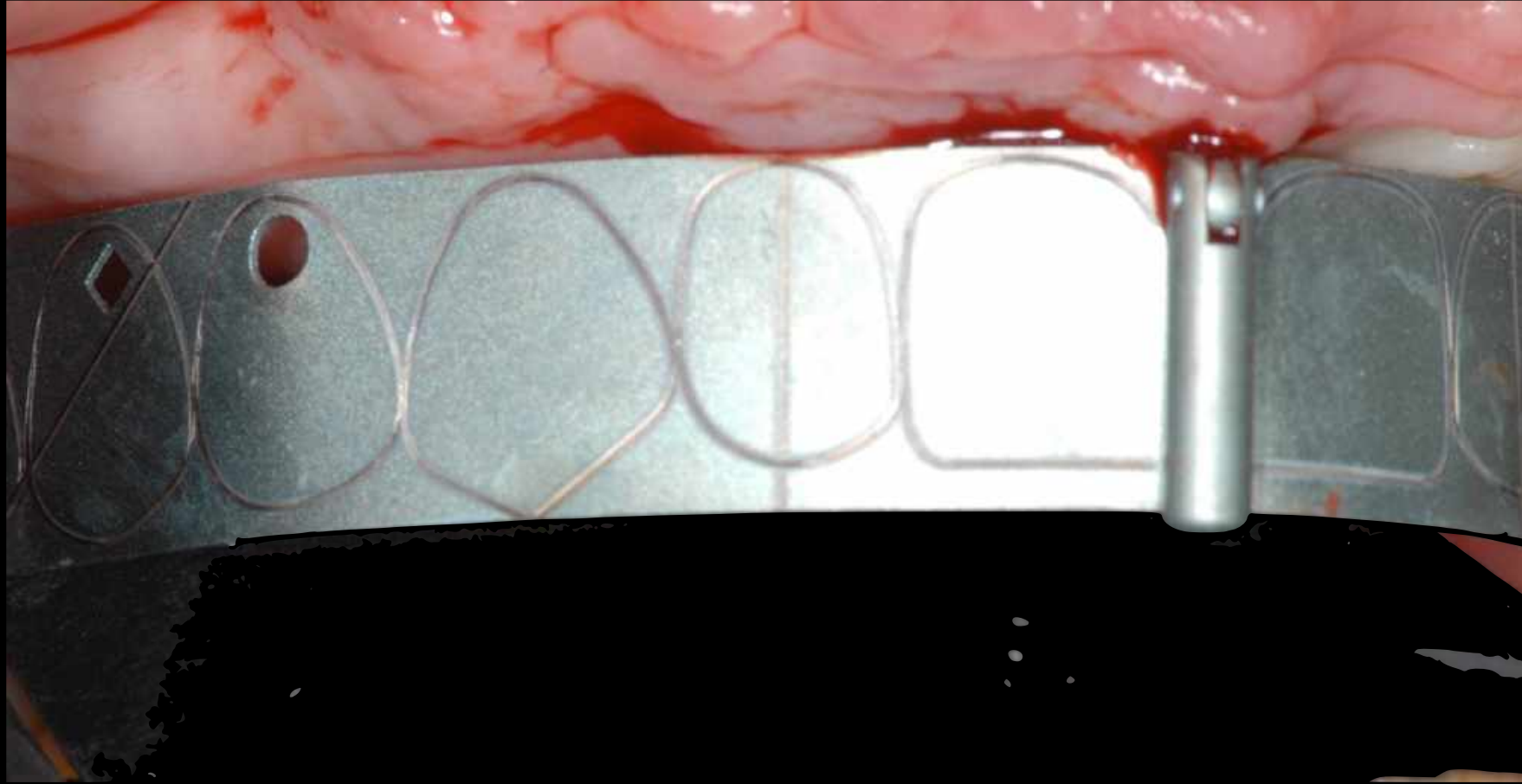
Table : bone loss for axial and tilted implants

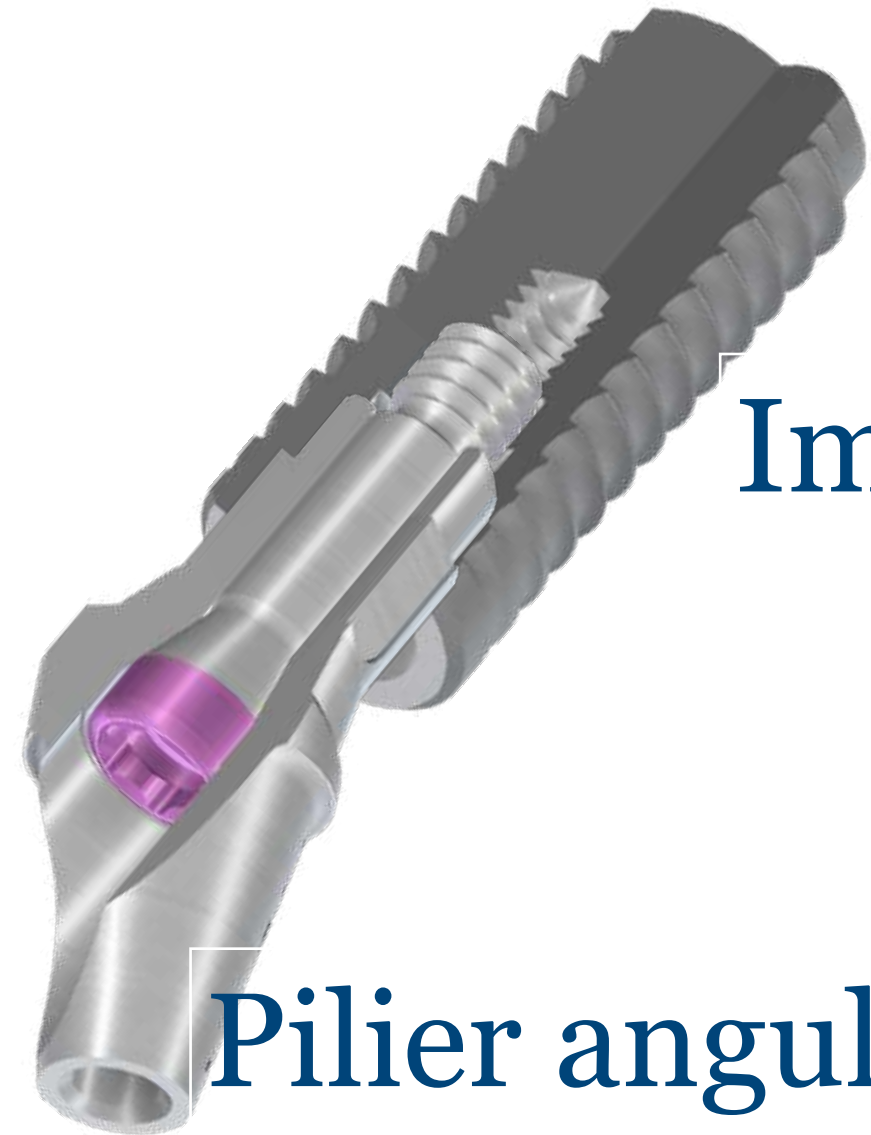
No significant difference was found between implants placed with an angle over than 30 degree.

Implants postérieurs :
Différence statistiquement significative
entre groupe test et contrôle

Les implants sous-sinusiens et
tubérositaires perdent plus d'os que les
implants angulés







Implant

Pilier angulé



Transfert

Cas particulier des implants angulés

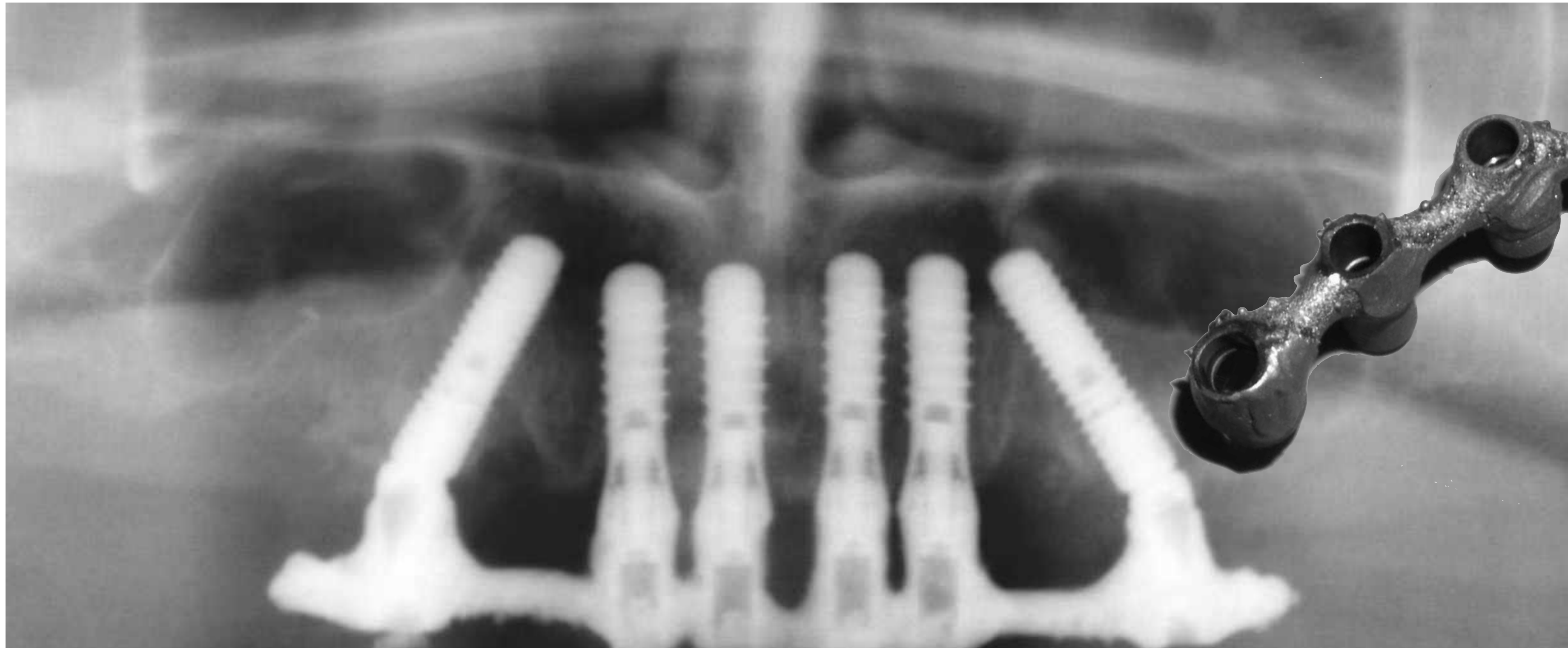
Le pilier est vissé définitivement :

Empreinte du pilier

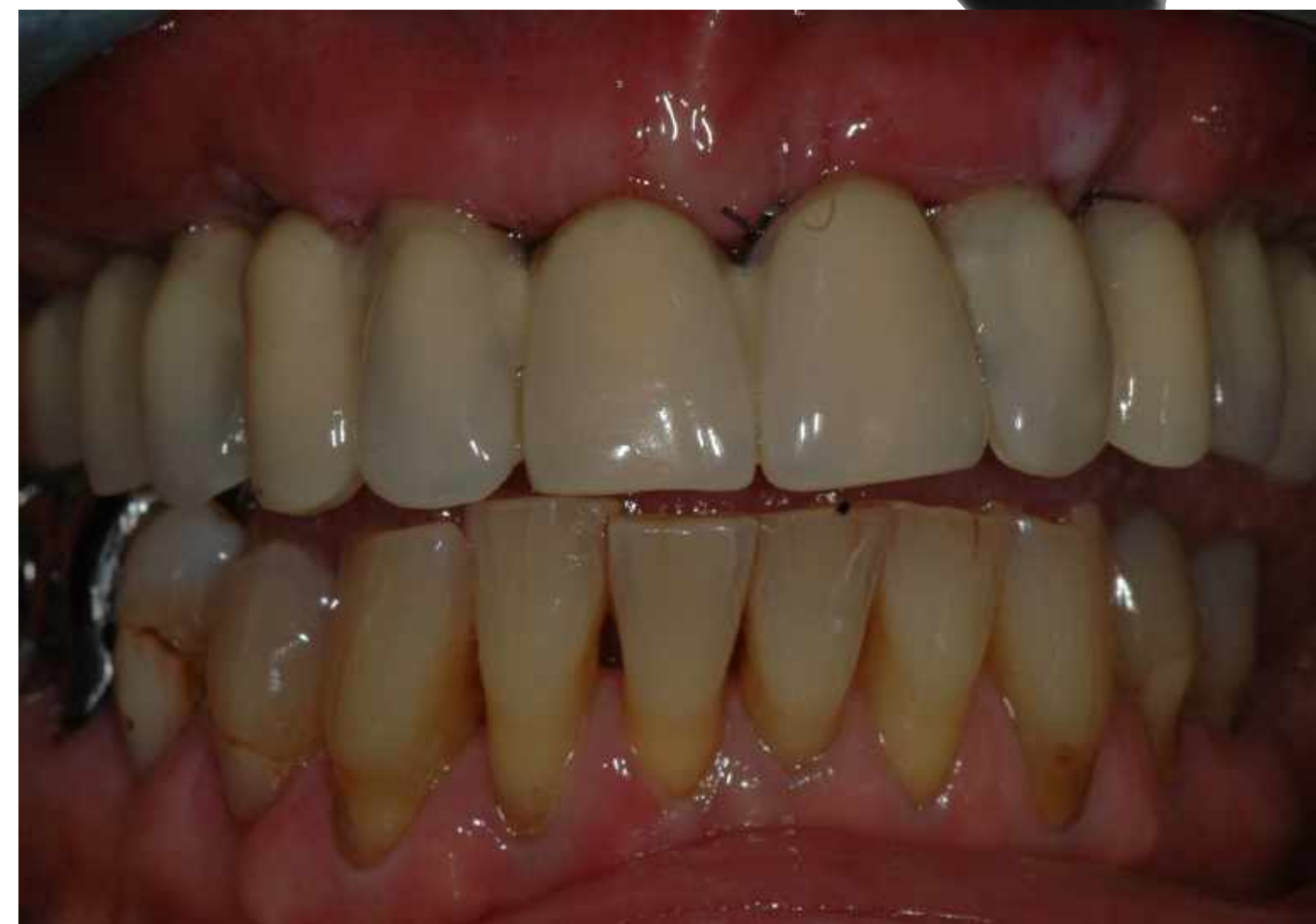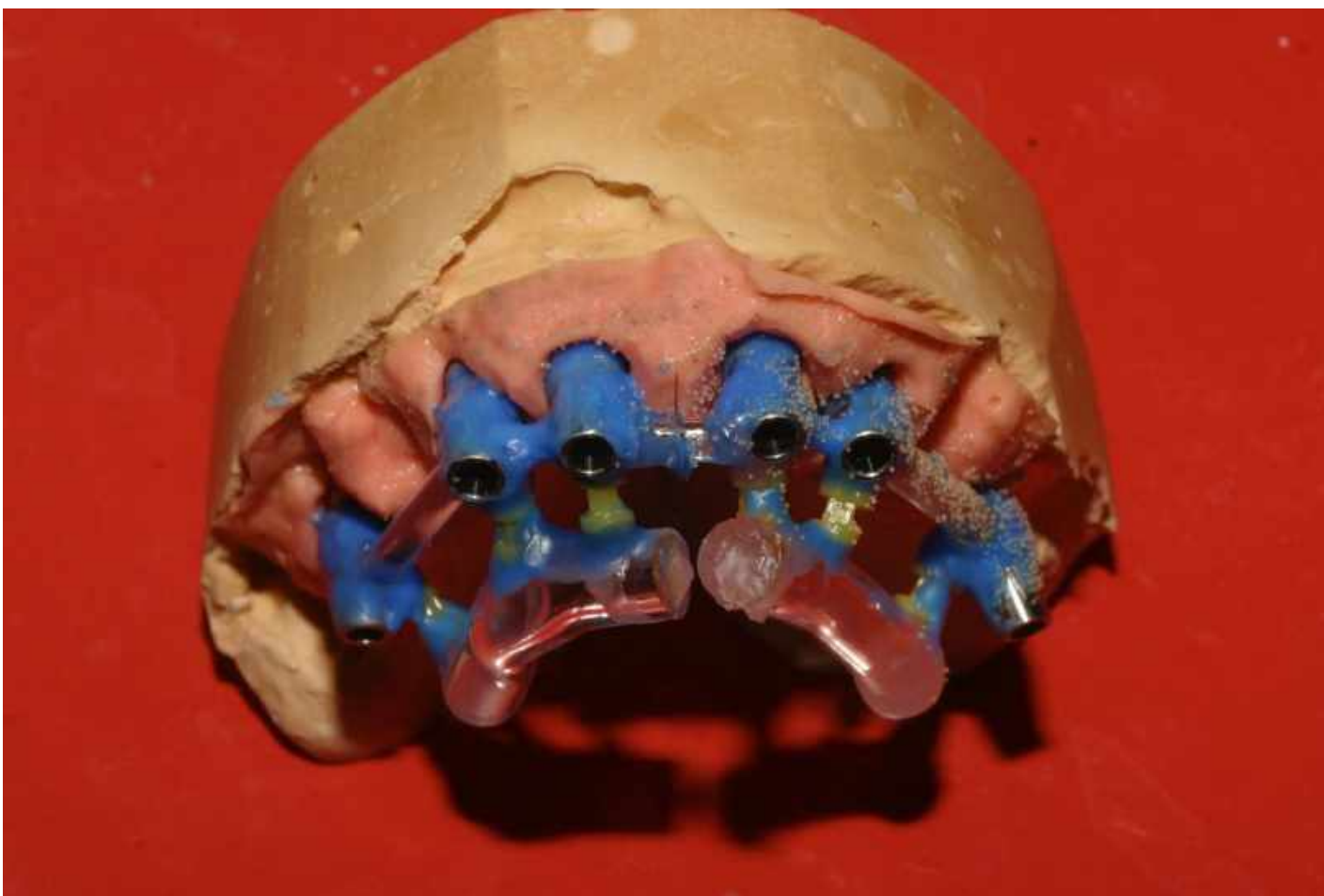
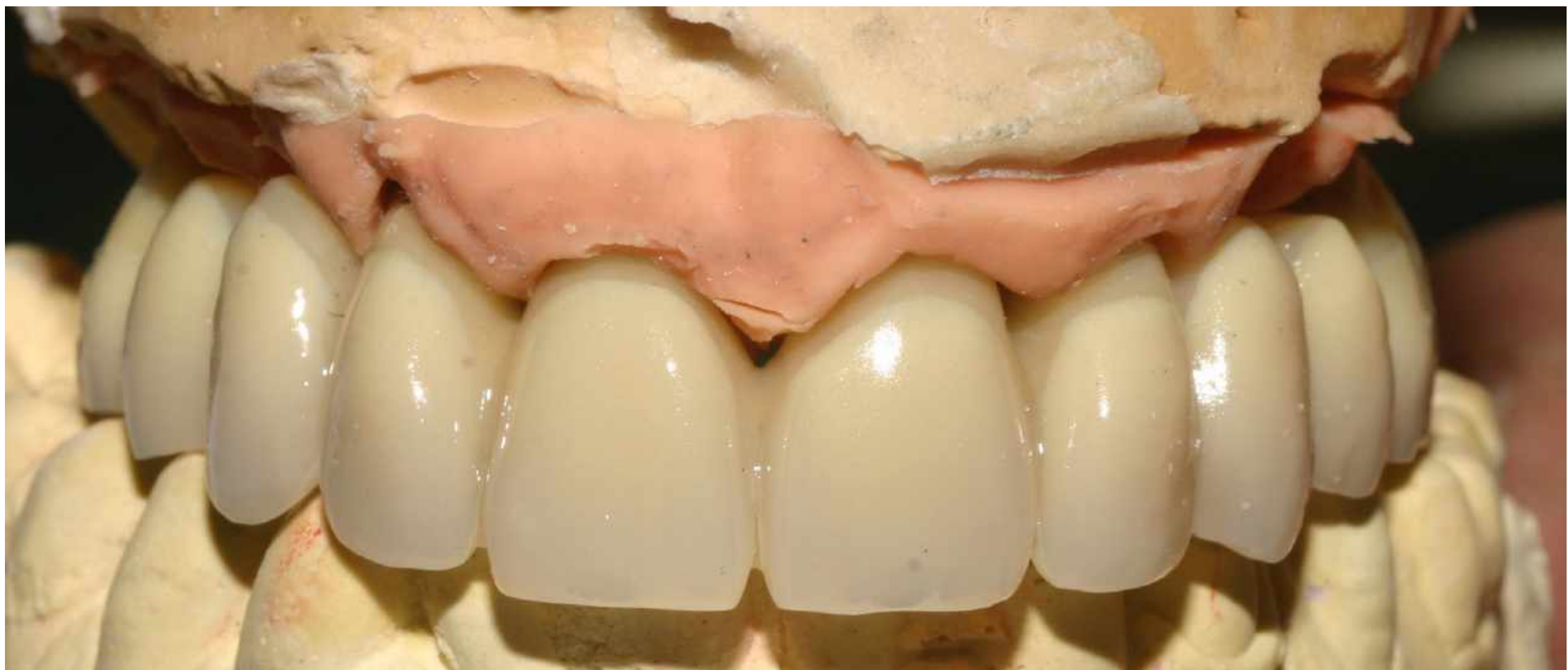
Vissage de l'analogue (pilier + implant)

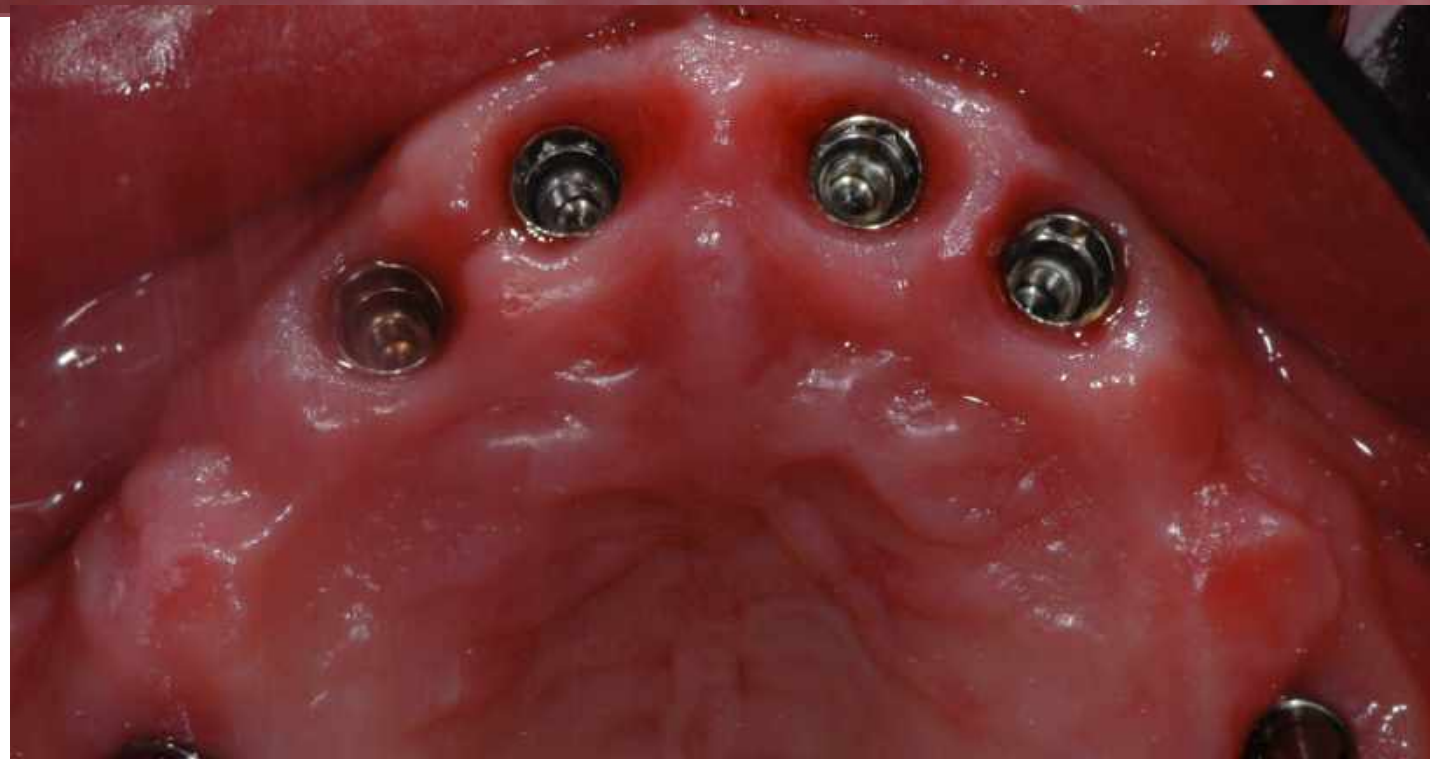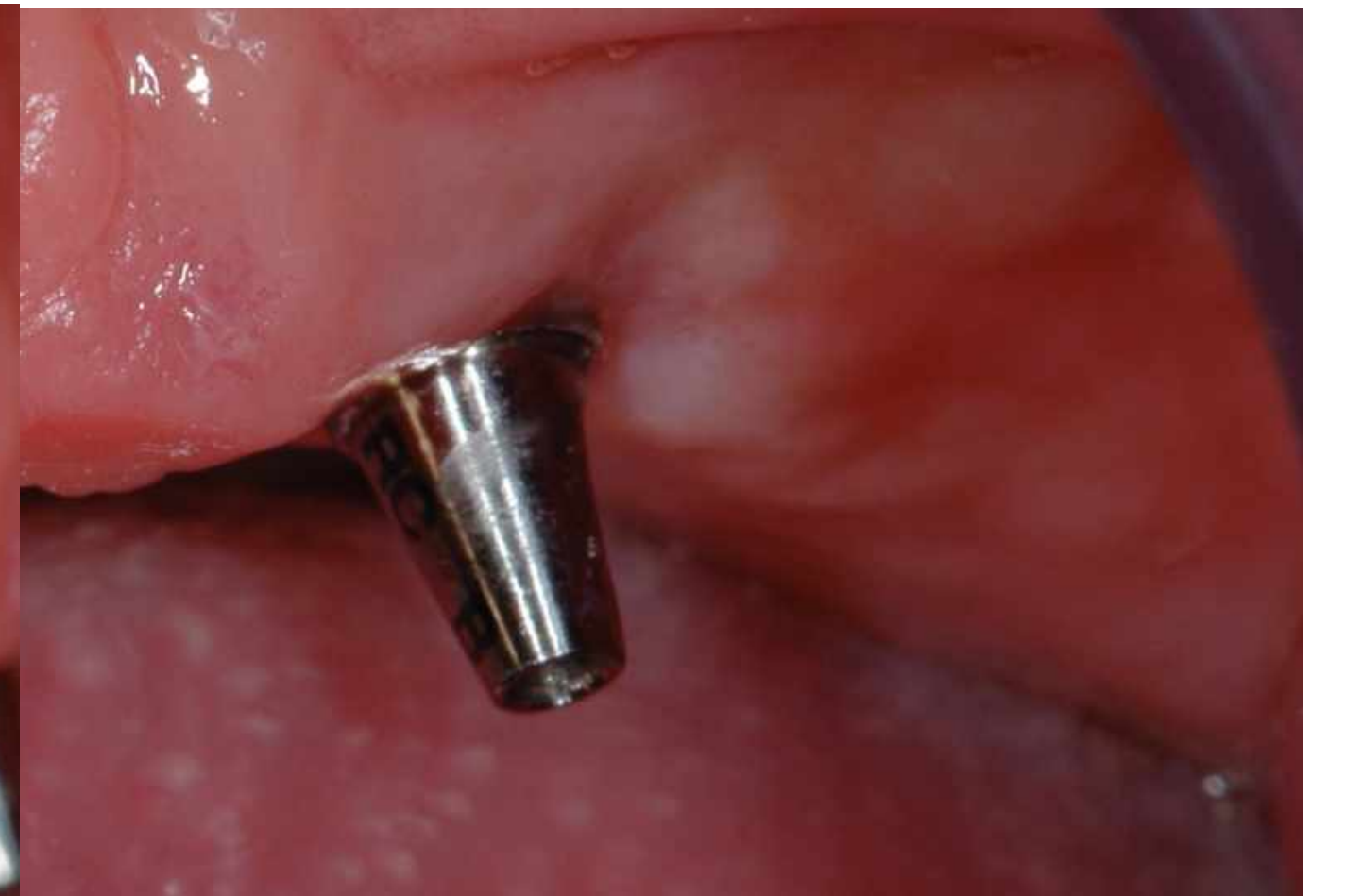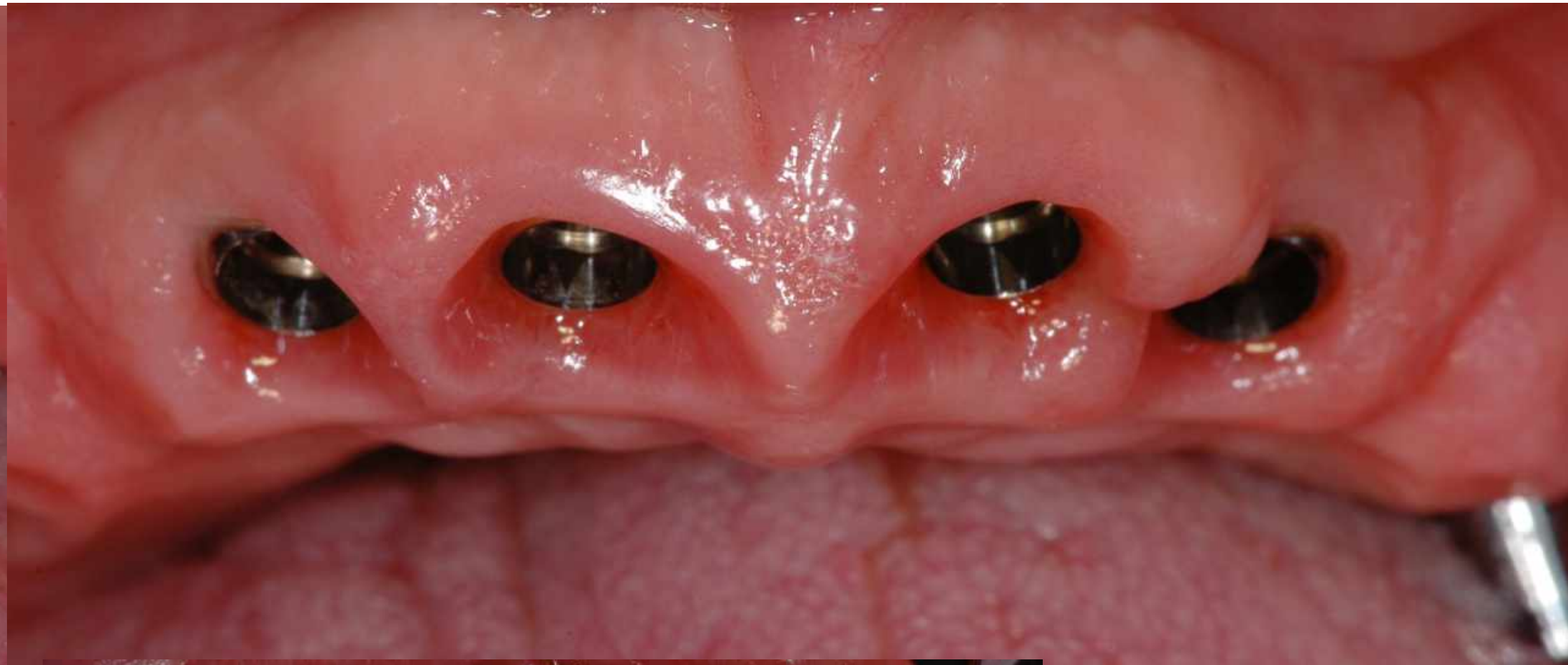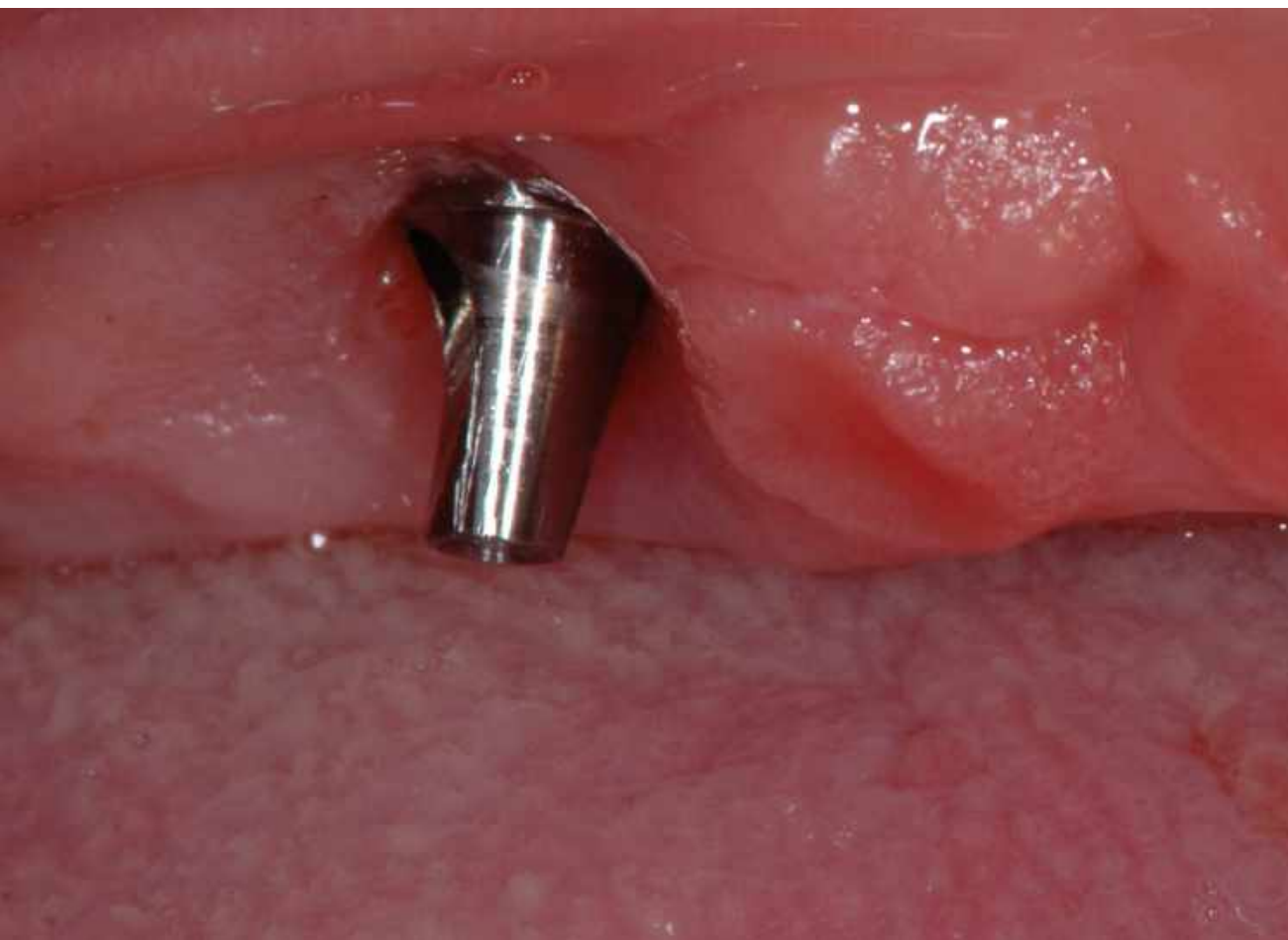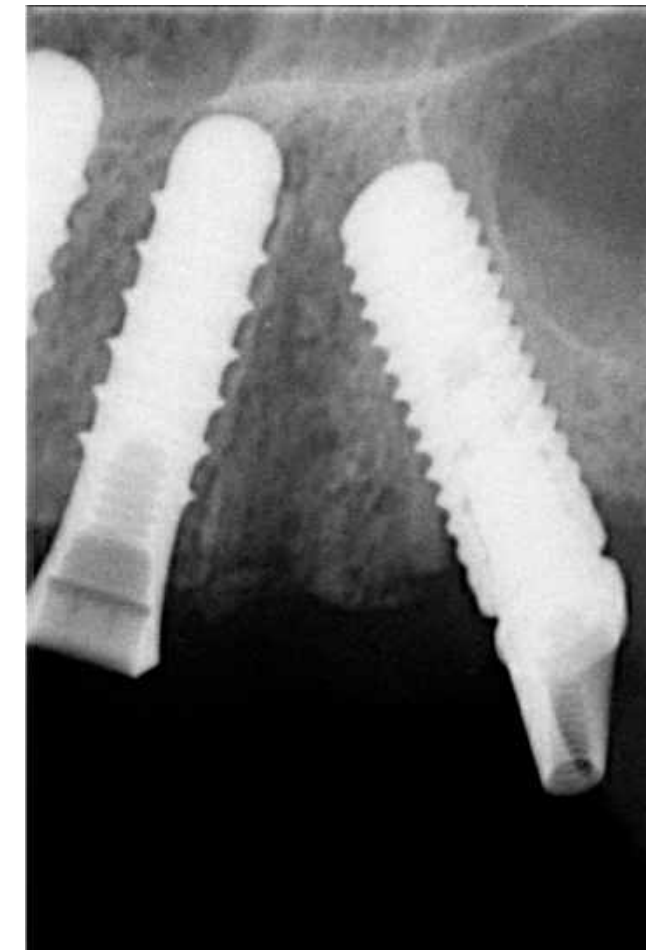
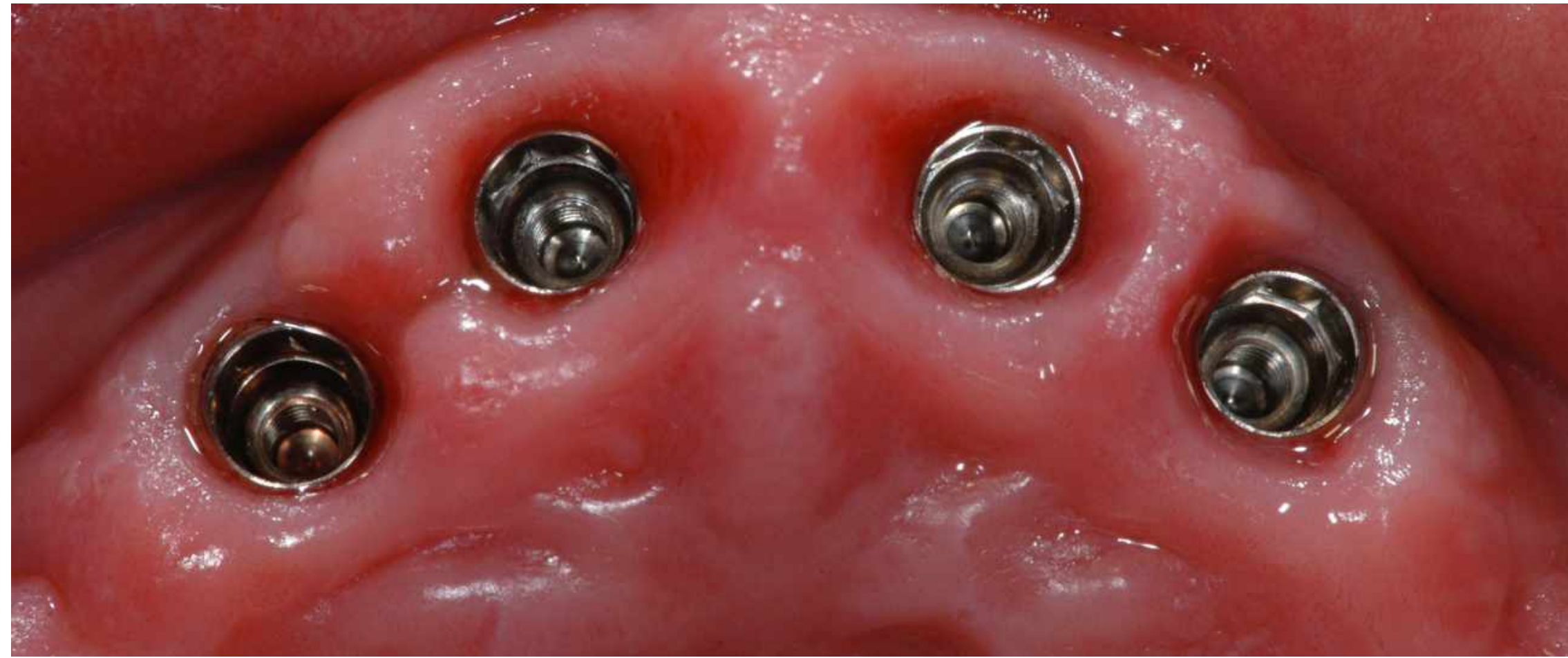
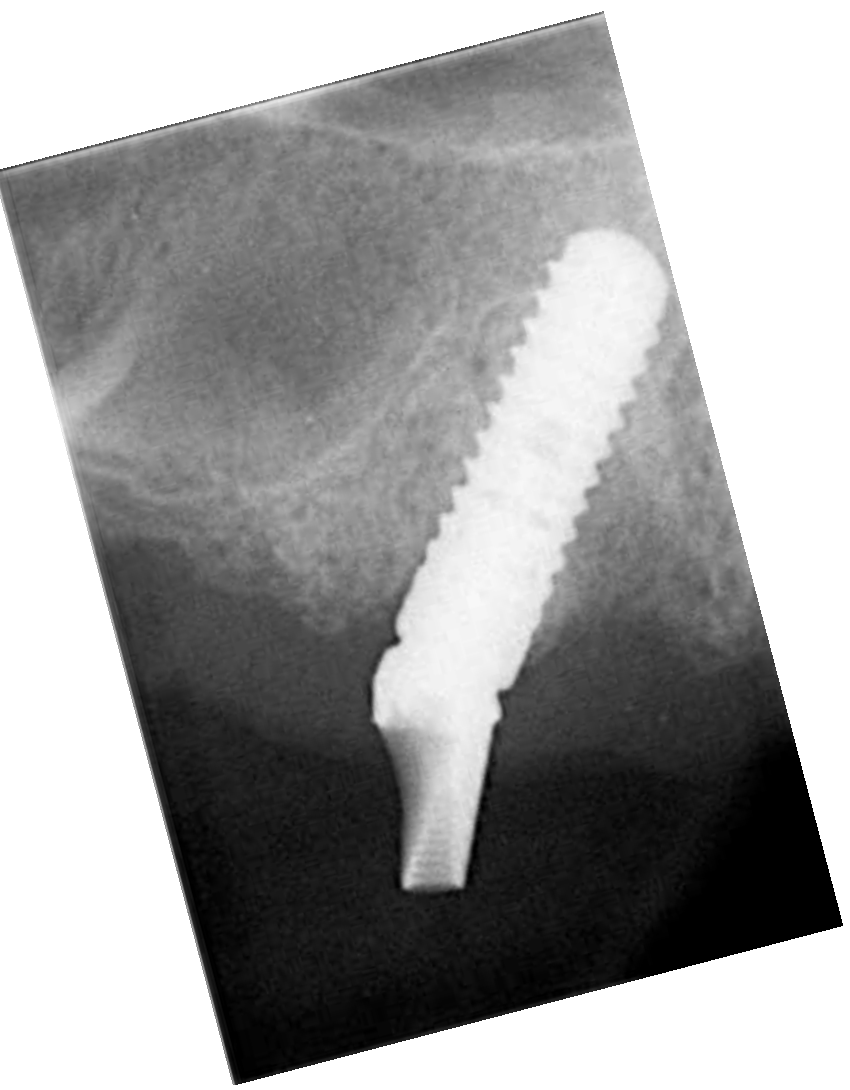


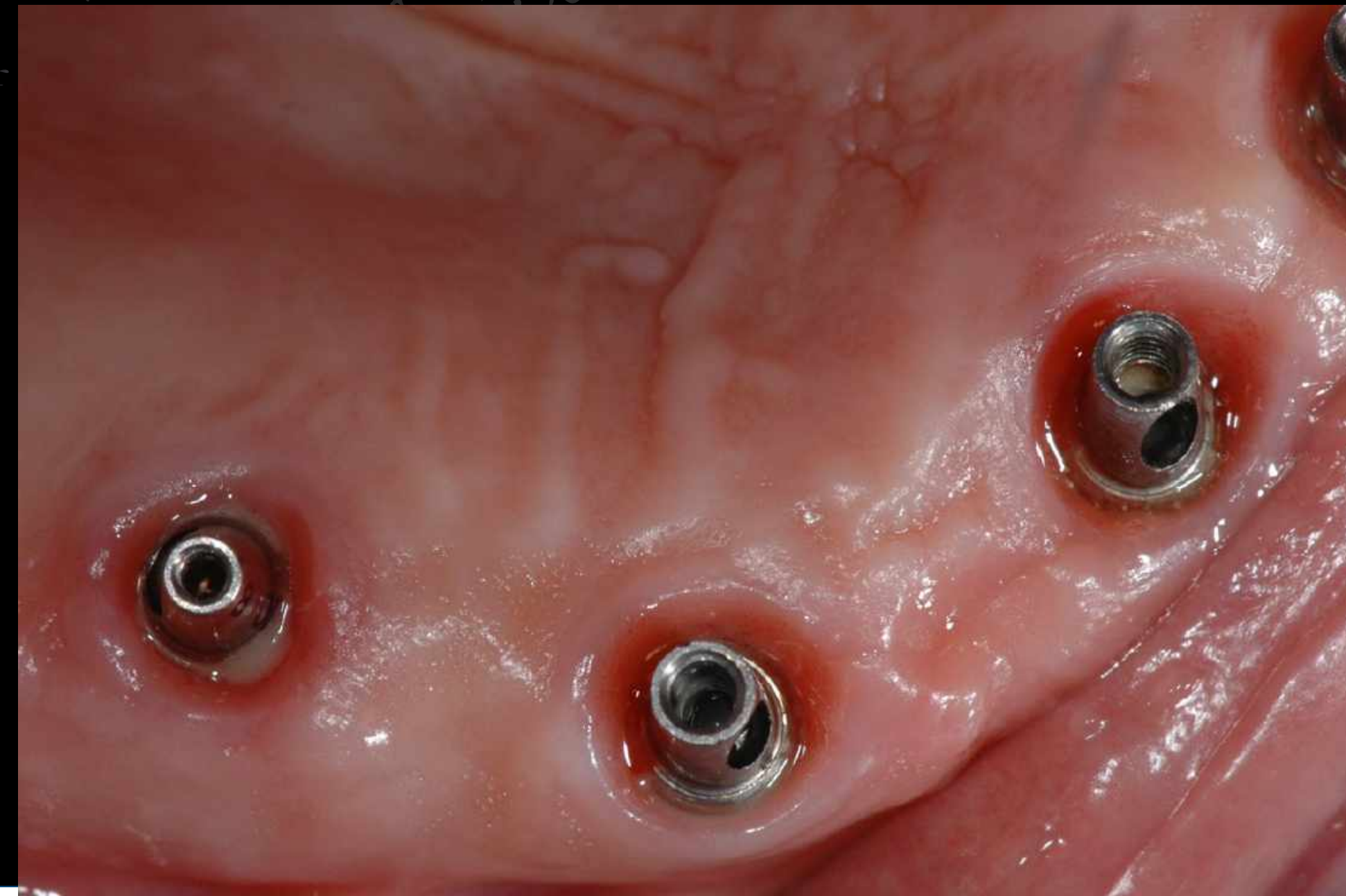
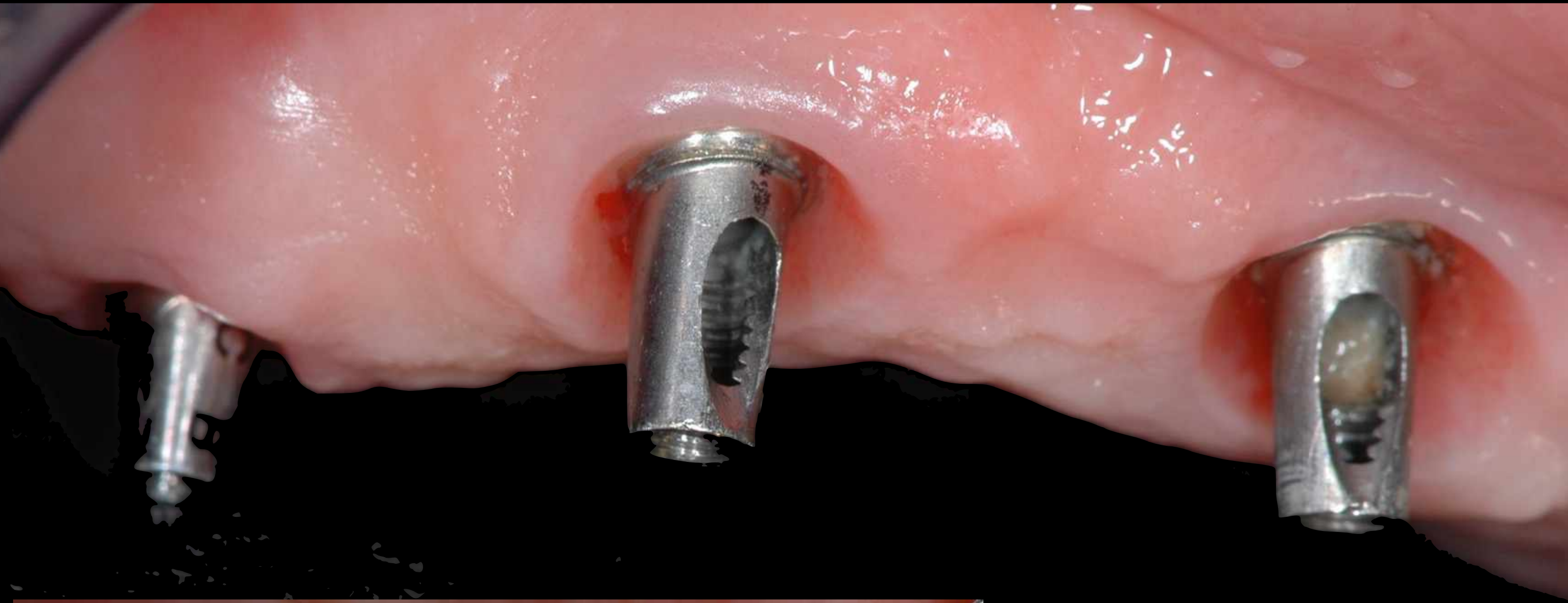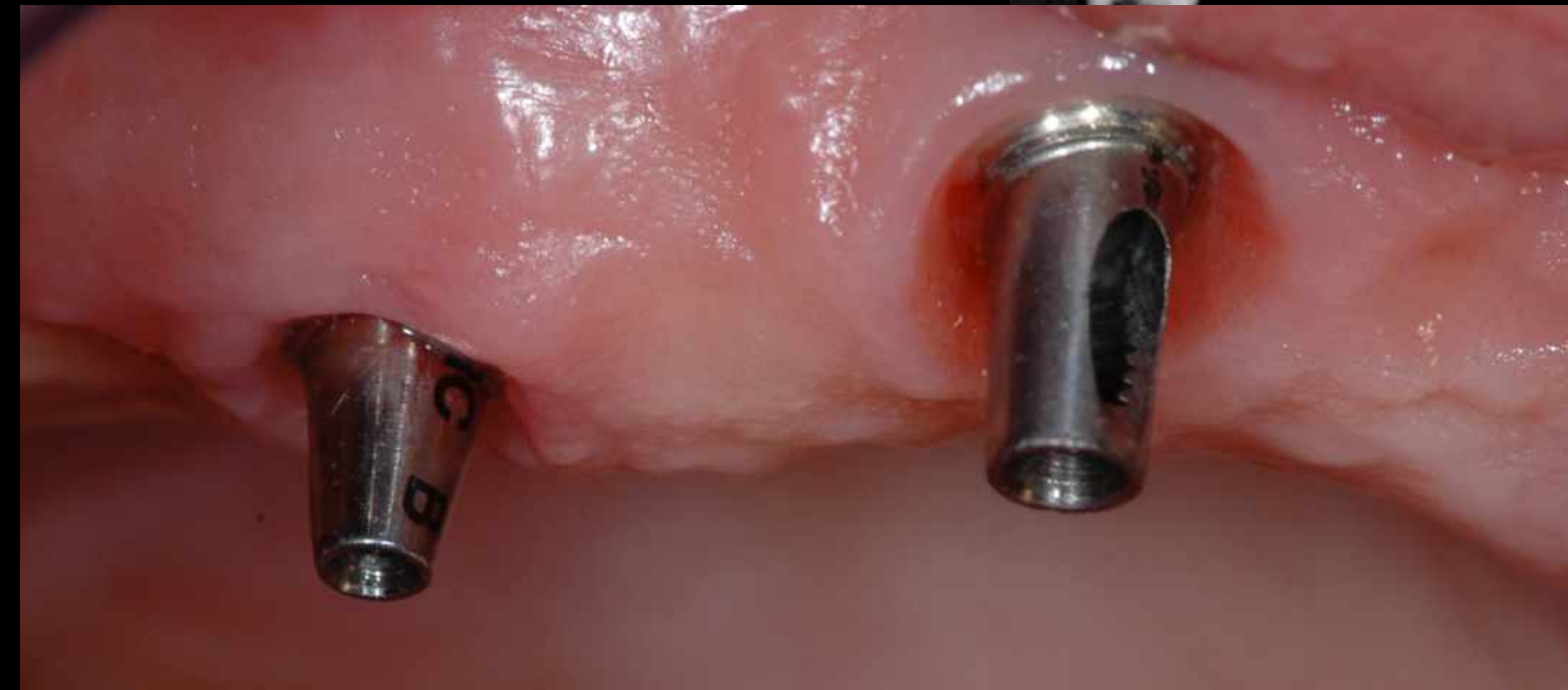
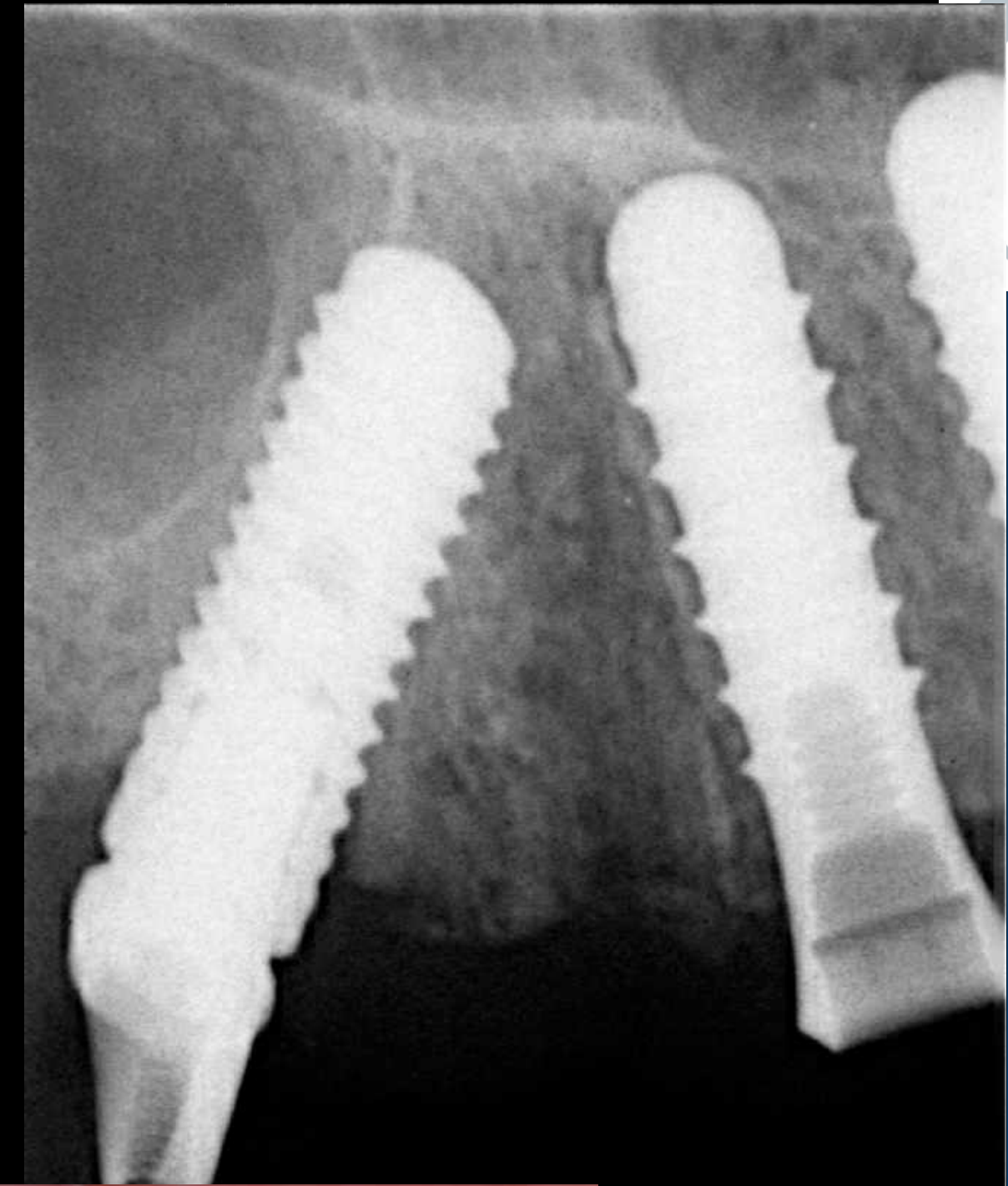
Analogue :
implant BL
+
pilier
angulé

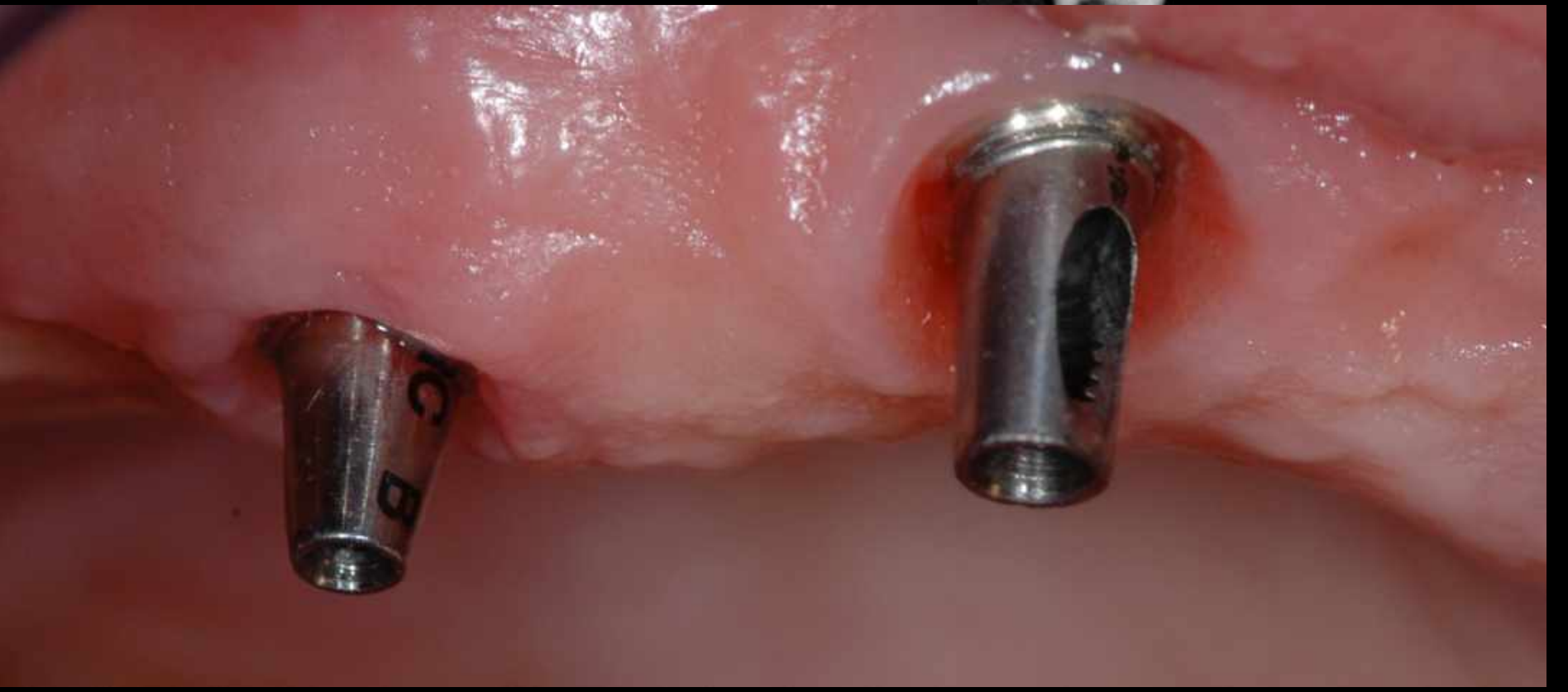
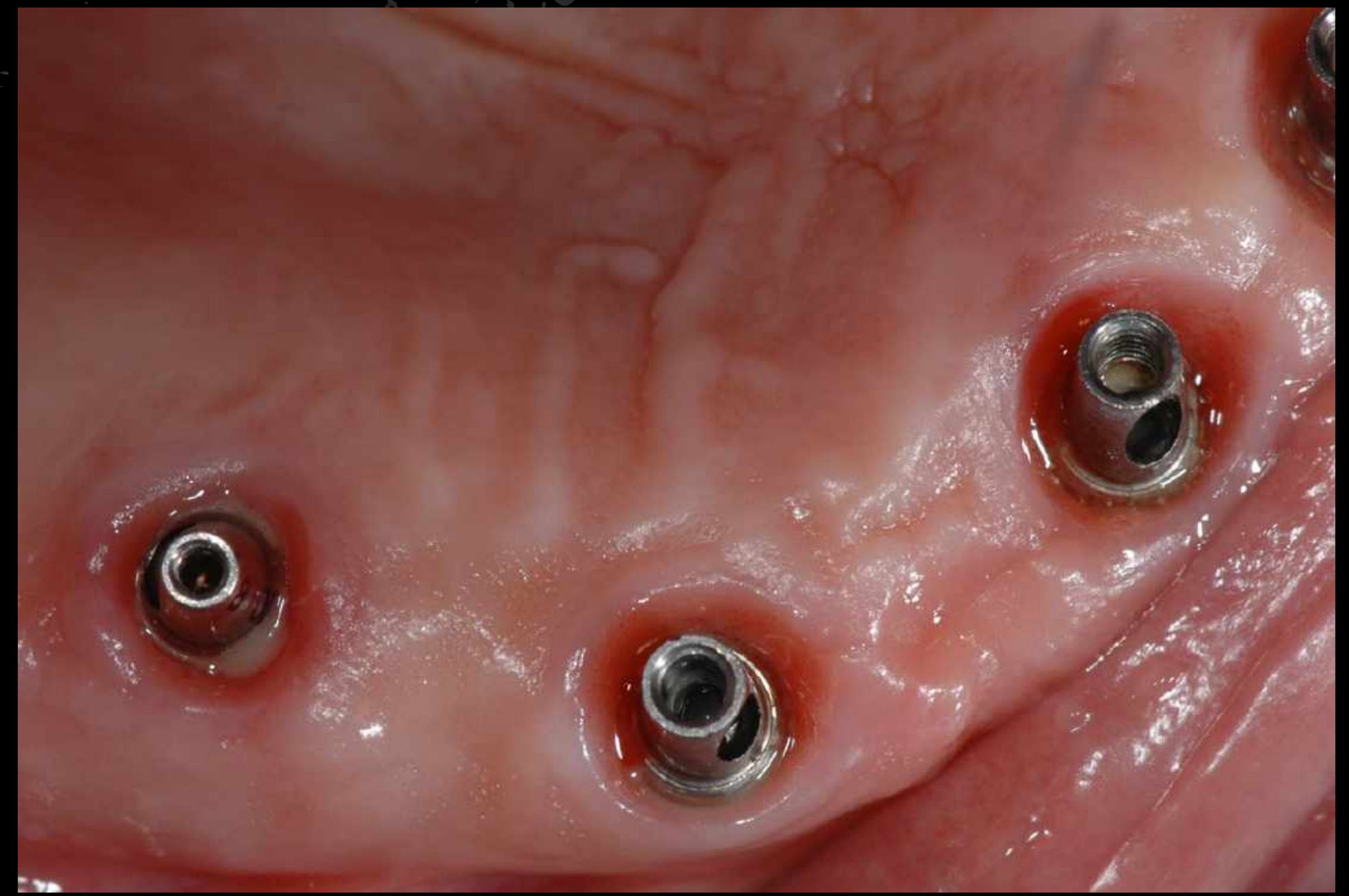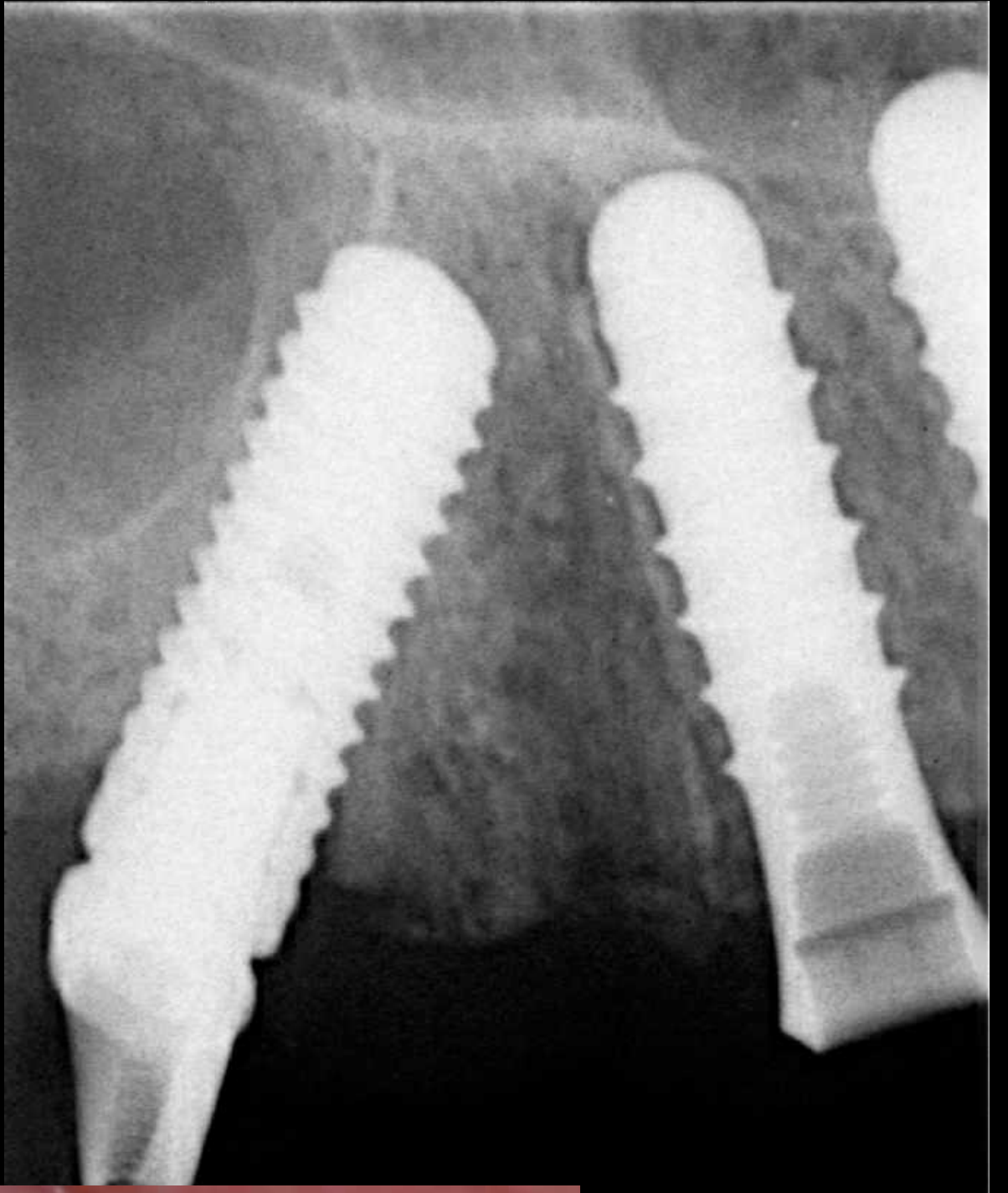

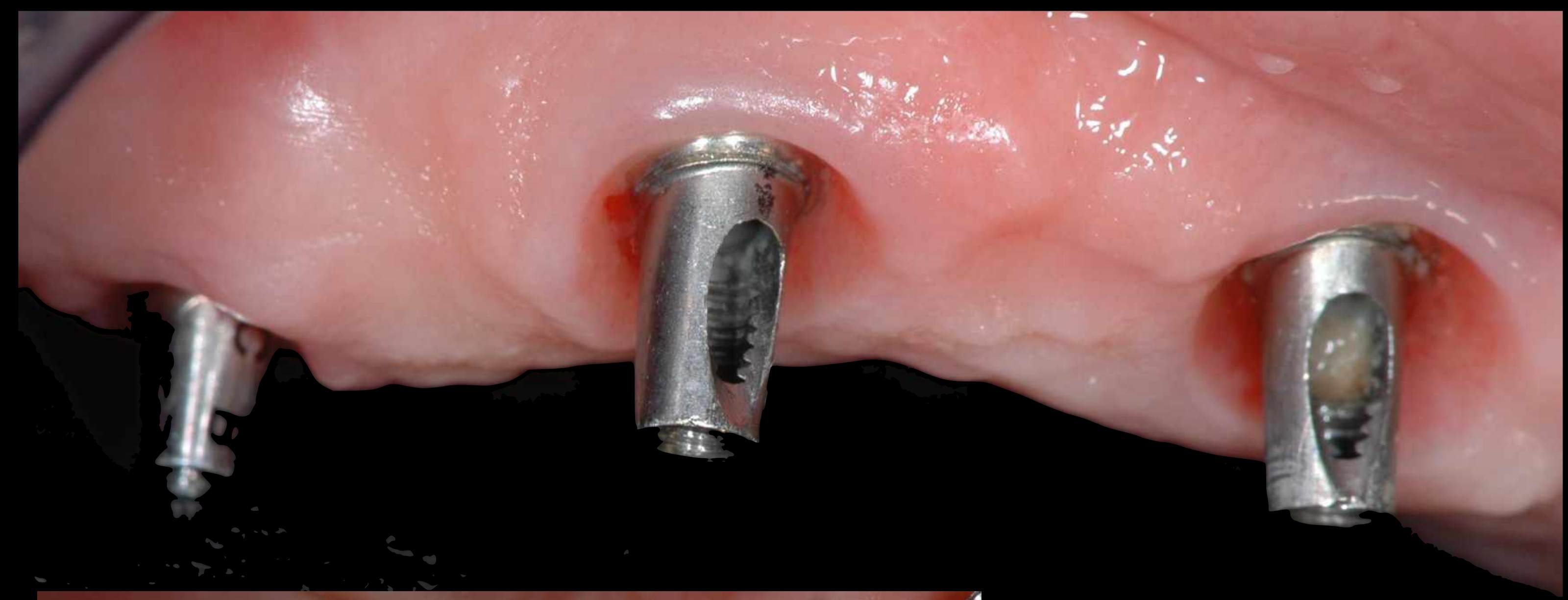
ITI

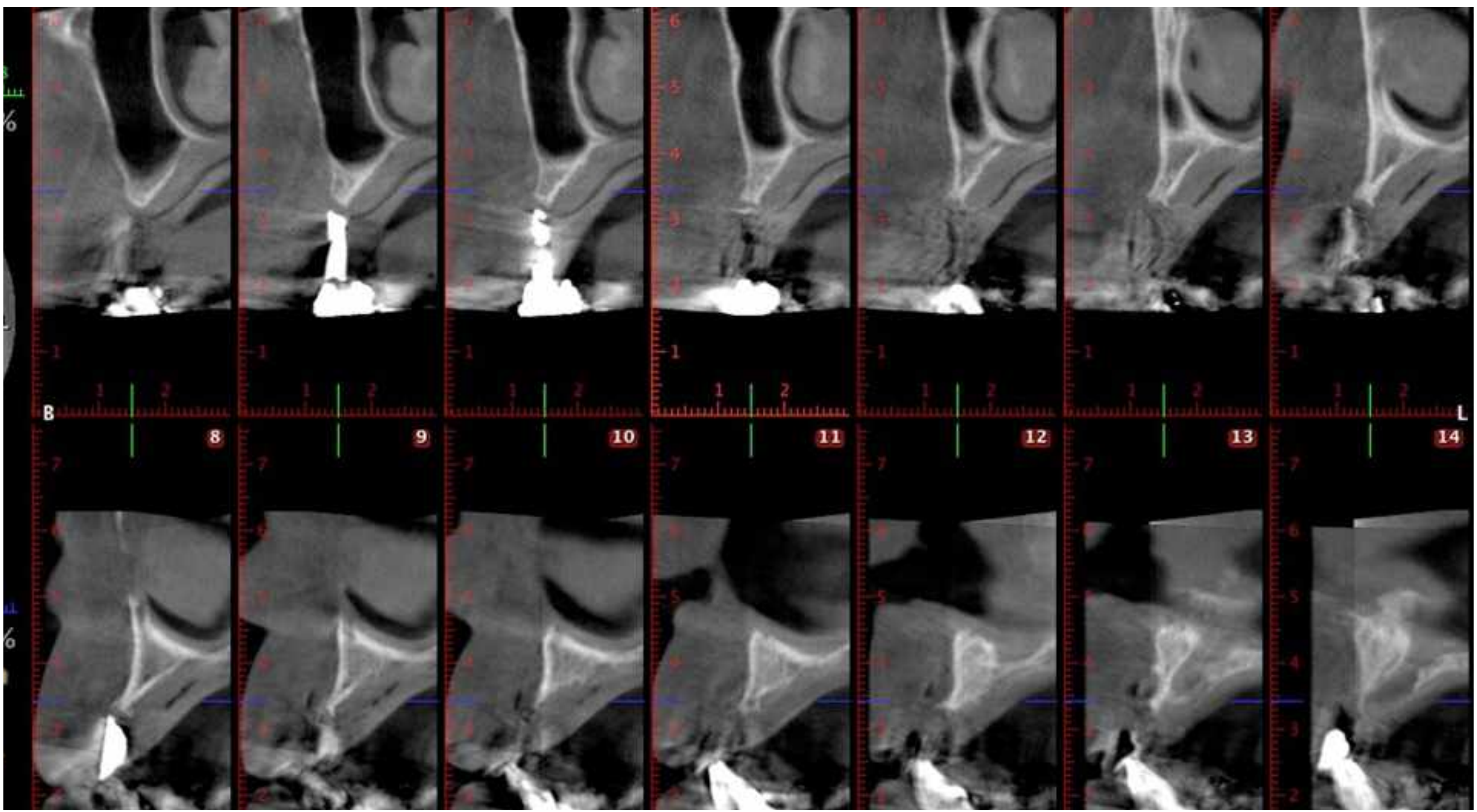
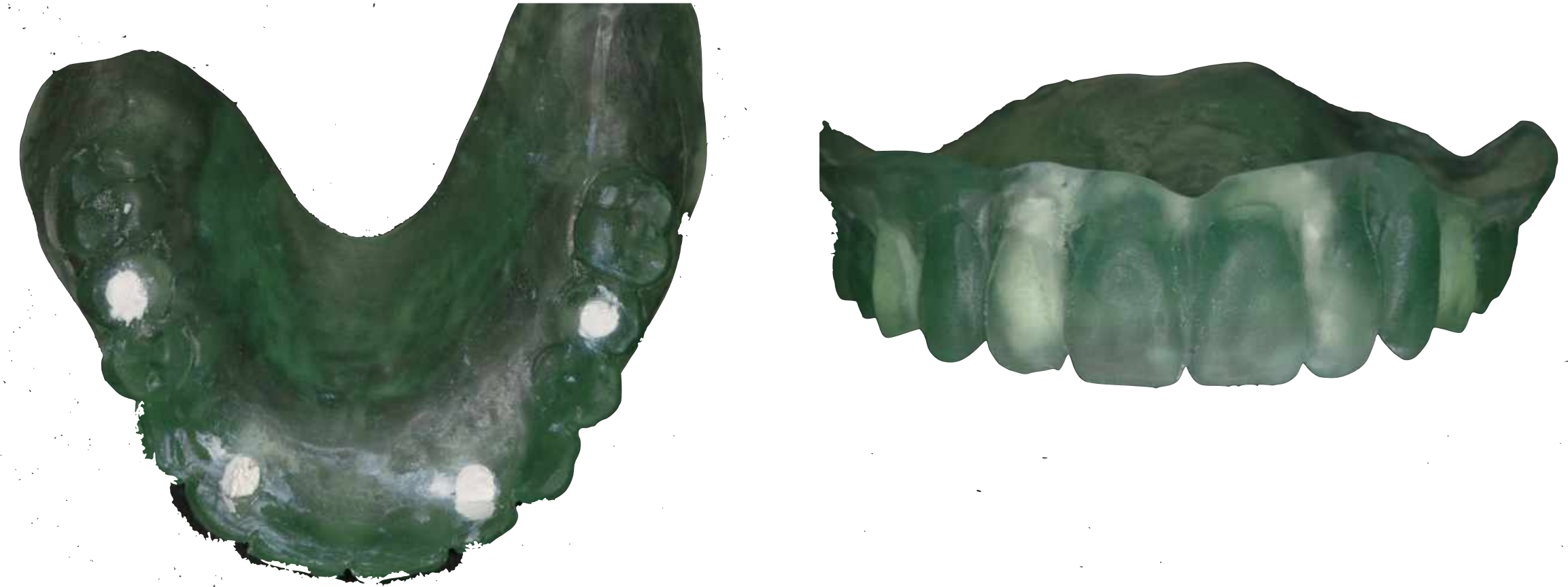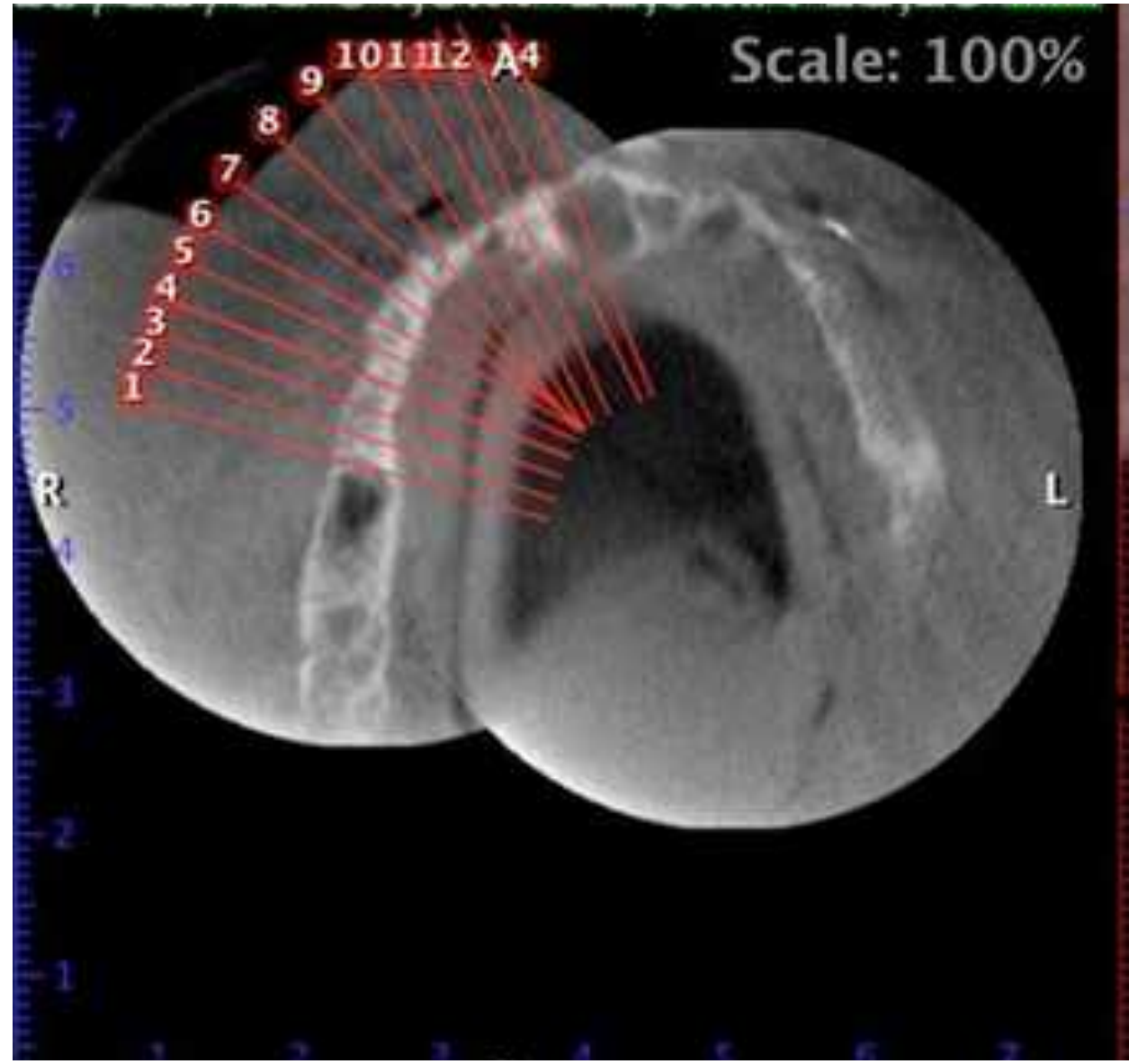

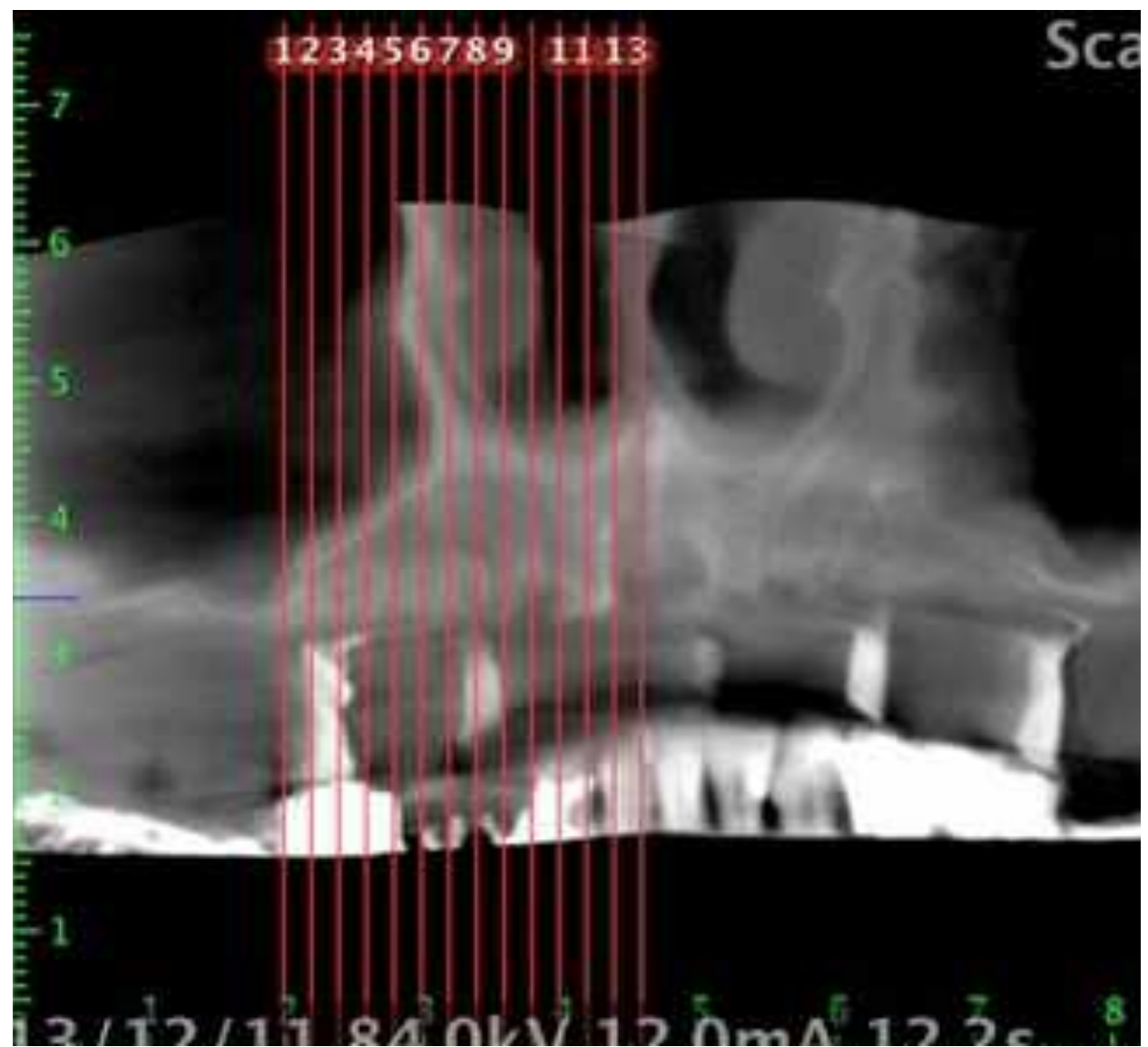
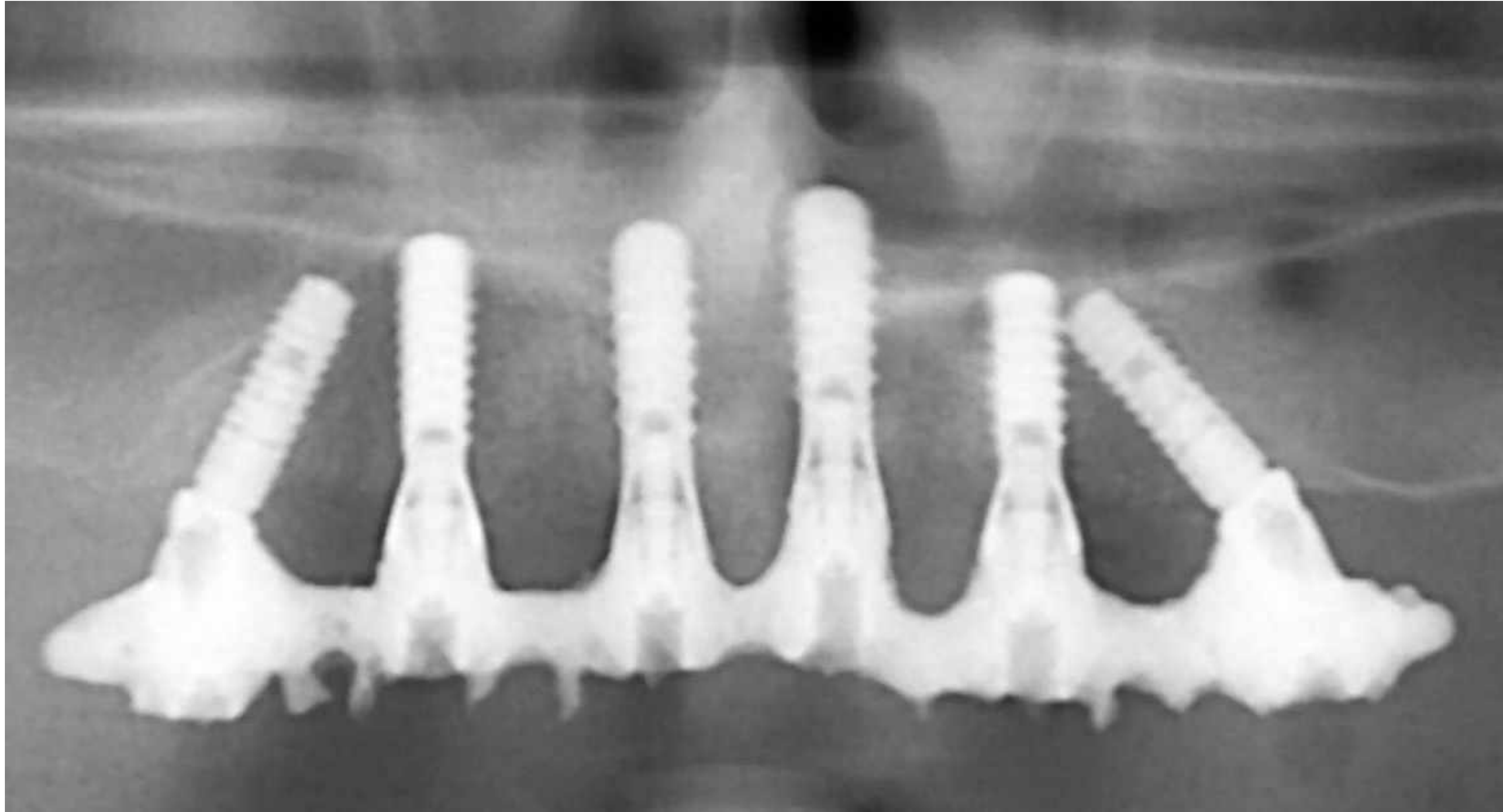


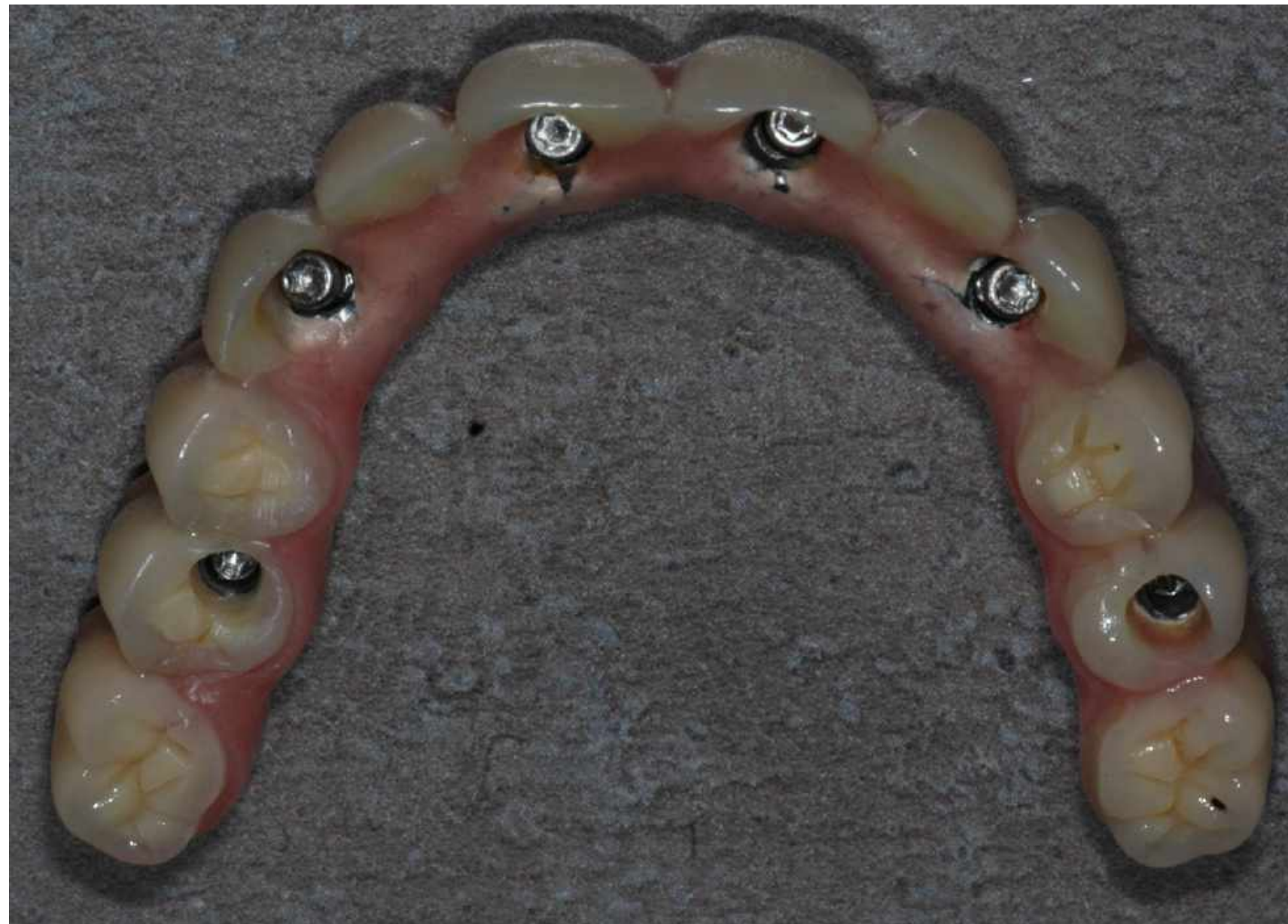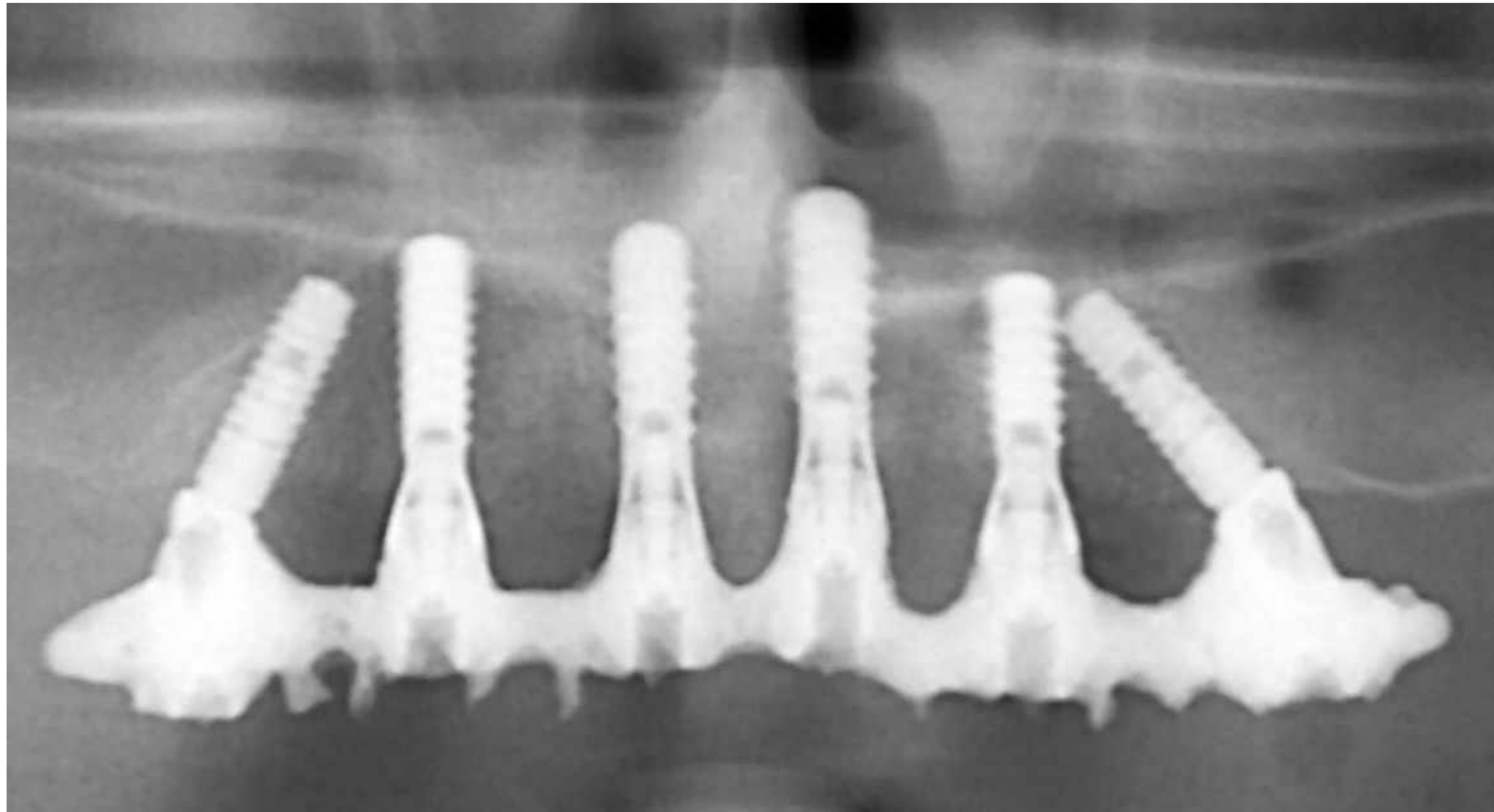




Roxolid







Questionnaire GOHAI

Patient : CALOART Danielle Date : 02/05/2012

Au cours de ces trois derniers mois

1 - Avez-vous limité la quantité ou le genre d'aliments que vous mangez en raison de problèmes avec vos dents ou vos appareils dentaires ?

5 jamais rarement parfois souvent toujours

2 - Avez-vous eu des difficultés pour mordre ou mastiquer certains aliments durs tels que de la viande ou une pomme ?

5 jamais rarement parfois souvent toujours

3 - Avez-vous pu avaler convenablement ?

5 jamais rarement parfois souvent toujours

4 - Vos dents ou vos appareils dentaires vous ont-ils empêché de parler comme vous le vouliez ?

5 jamais rarement parfois souvent toujours

5 - Avez-vous pu manger de tout de manière confortable ?

5 jamais rarement parfois souvent toujours

6 - Avez-vous limité vos contacts avec les gens à cause de l'état de vos dents, de vos gencives ou de vos appareils dentaires

5 jamais rarement parfois souvent toujours

7 - Avez-vous été satisfait(e) ou content(e) de l'aspect de vos dents, de vos gencives ou de vos appareils dentaires ?

5 jamais rarement parfois souvent toujours

8 - Avez-vous pris un (des) médicament(s) pour soulager la douleur ou une sensation d'inconfort dans votre bouche ?

5 jamais rarement parfois souvent toujours

9 - Vos problèmes de dents, de gencives ou d'appareil dentaire vous ont-ils inquiété(e) ou préoccupé(e) ?

5 jamais rarement parfois souvent toujours

10 - Vous êtes-vous senti(e) gêné ou mal à l'aise à cause de problèmes avec vos dents ou vos appareils dentaires ?

5 jamais rarement parfois souvent toujours

11 - Avez-vous éprouvé de l'embarras pour manger devant les autres à cause de problèmes avec vos dents ou vos appareils dentaires ?

5 jamais rarement parfois souvent toujours

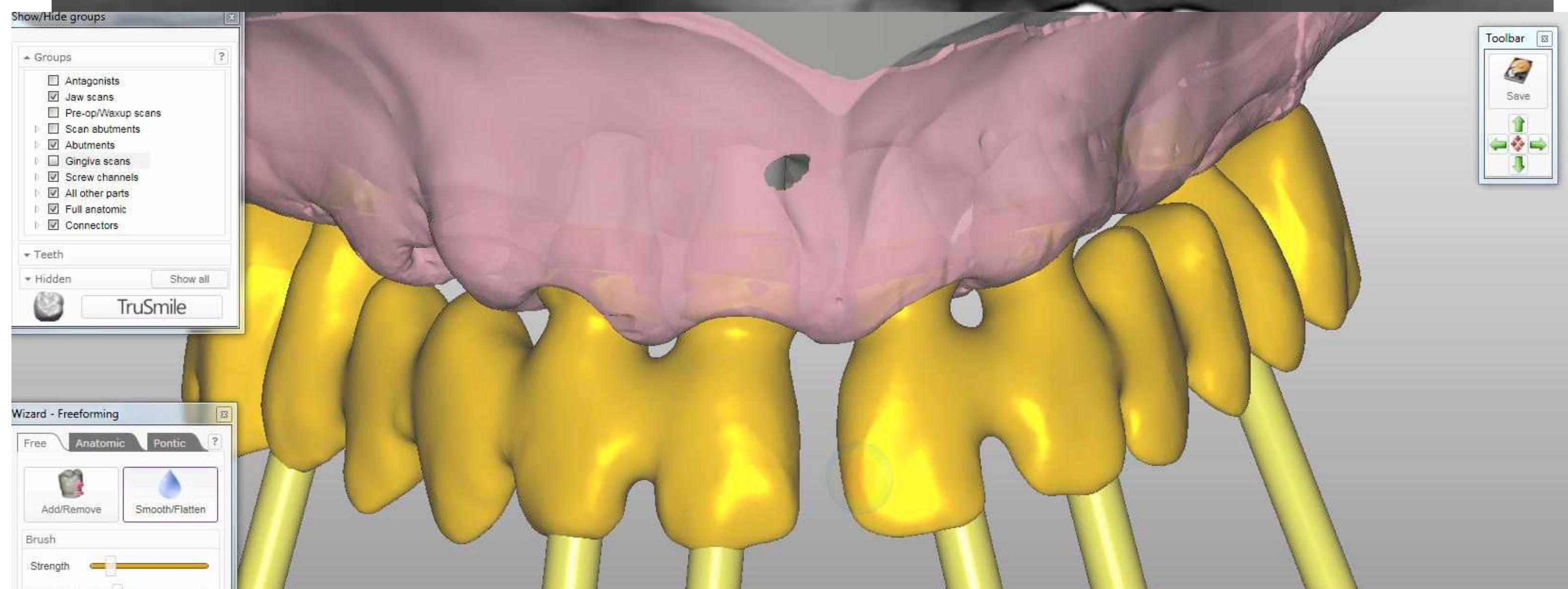
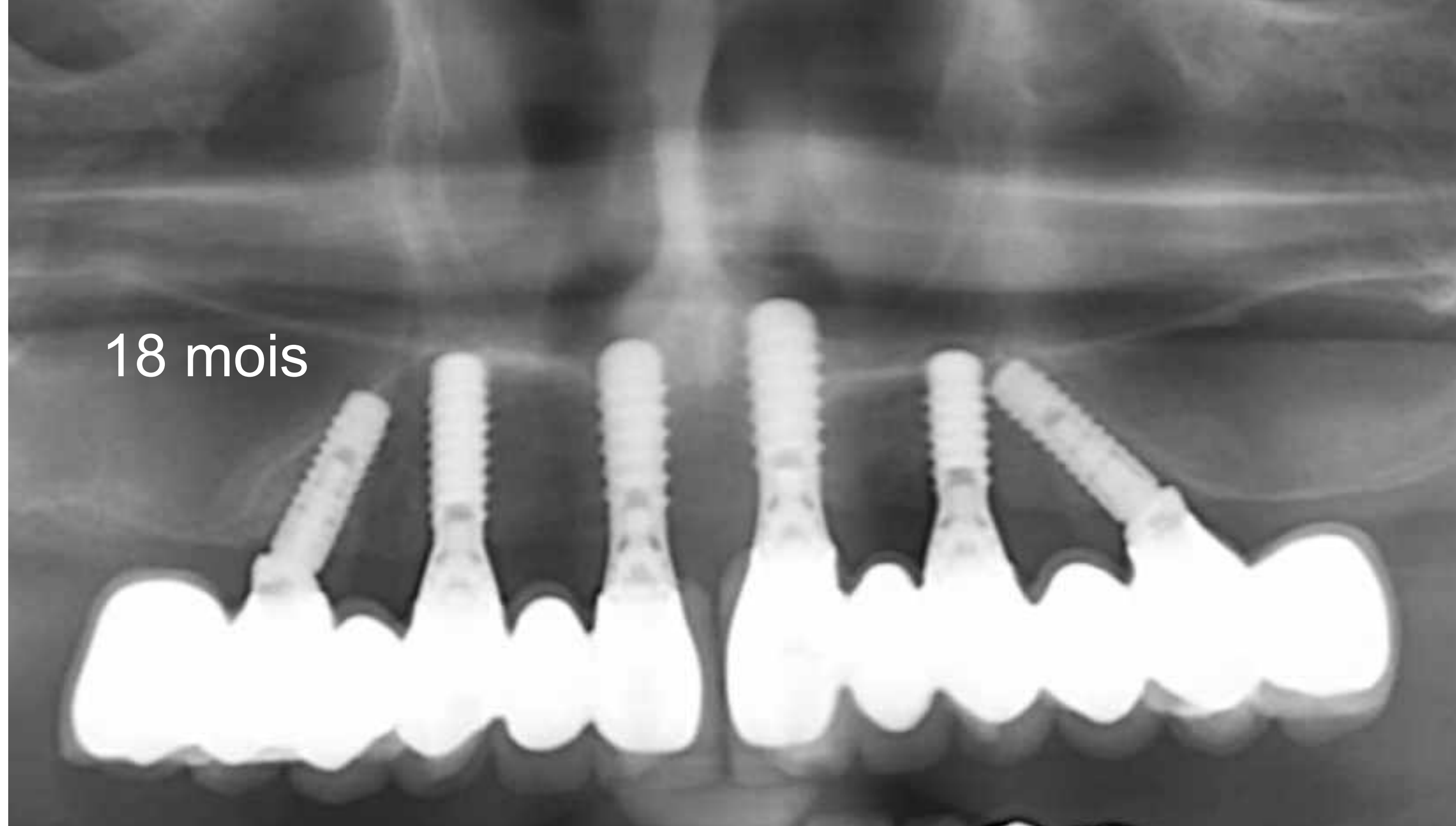
12 - Vos dents ou vos gencives ont-elles été sensibles au froid, au chaud ou aux aliments sucrés ?

4 jamais rarement parfois souvent toujours

59




Bonne Qualité de
Vie Orale :
Score > 56




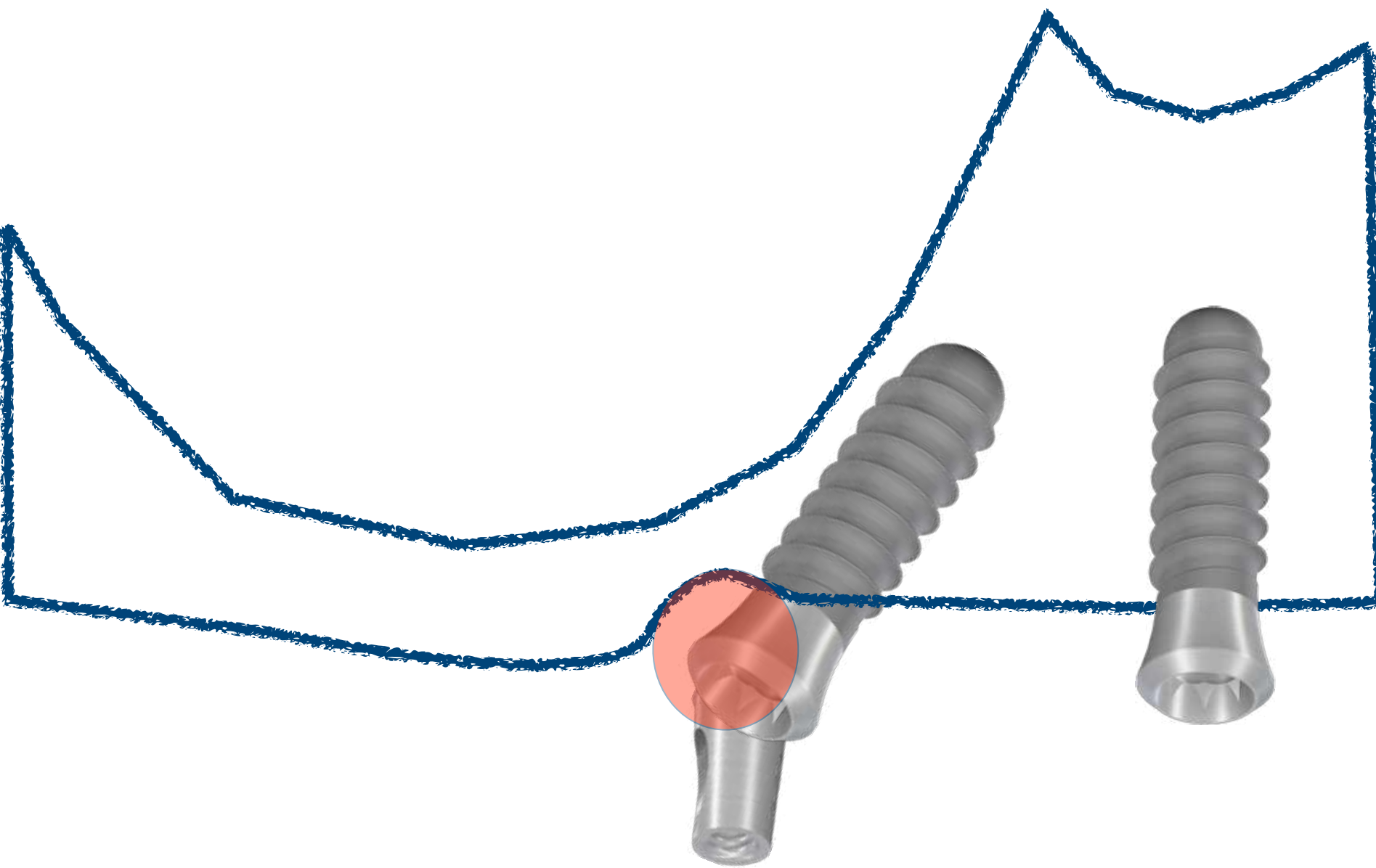


Angulation des implants



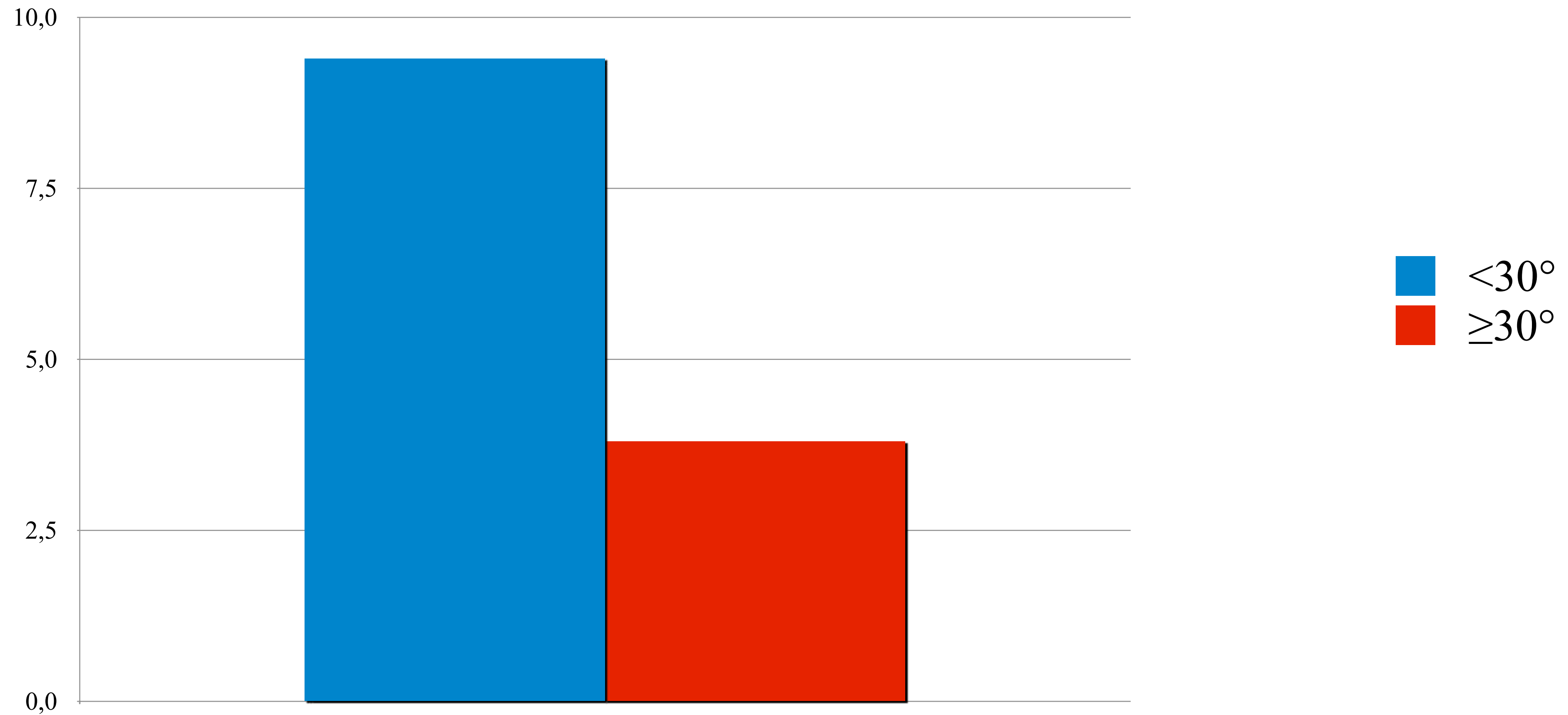
1. Il est préférable d'utiliser un implant Tissue Level
2. Il est indispensable de respecter une angulation inférieure 30°
3. Il n'y a pas d'angulation limite à l'utilisation d'un implant angulé
4. Le switching platform associé à un pilier angulé limite la perte osseuse peri-implantaire



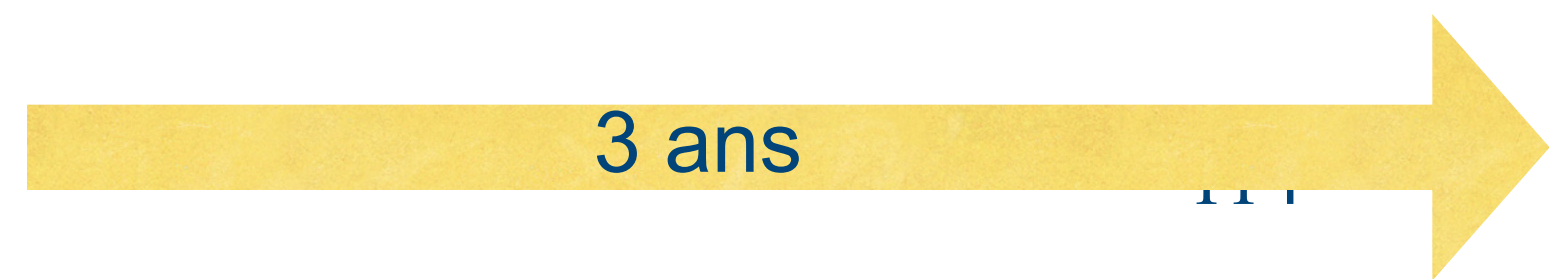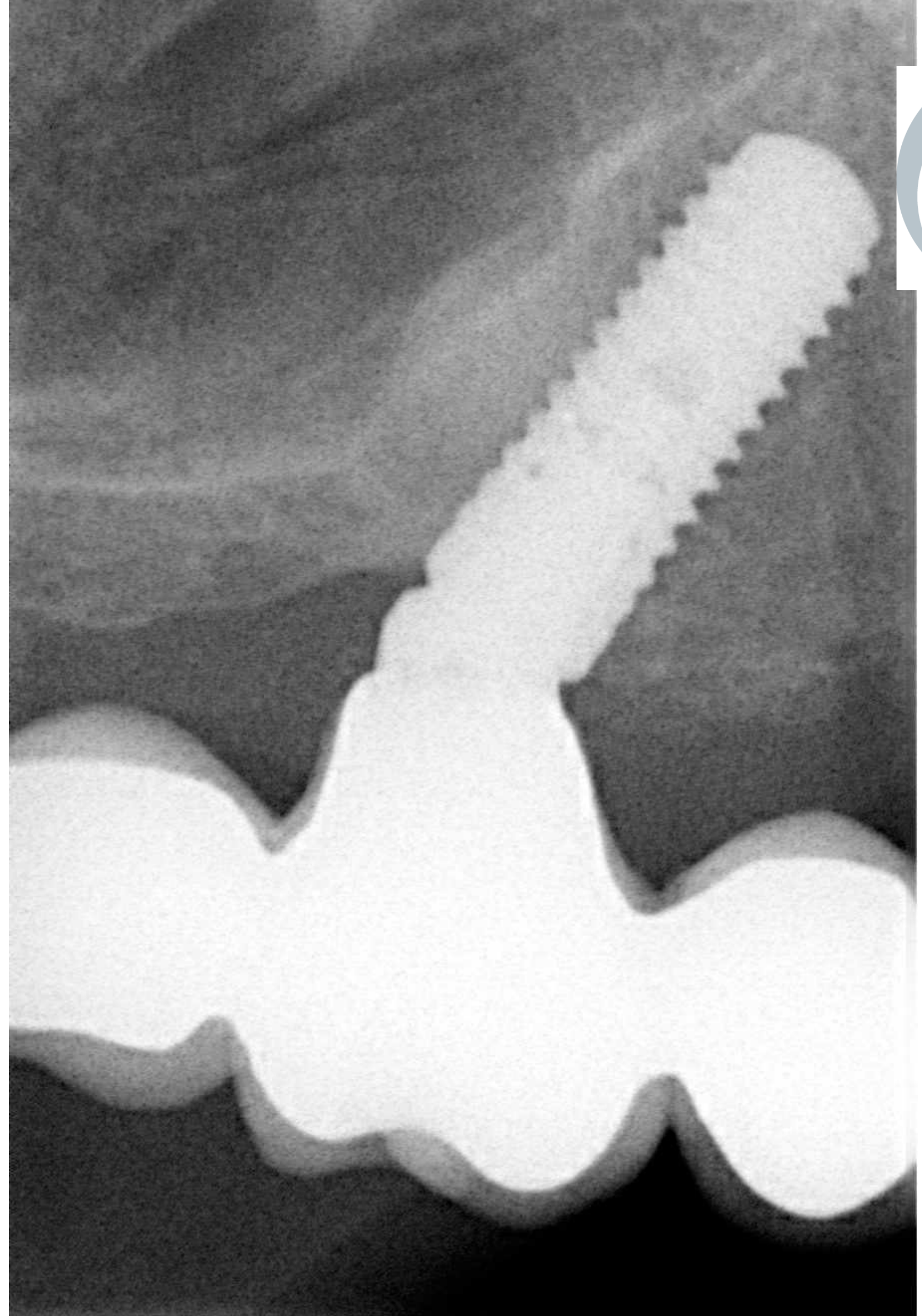
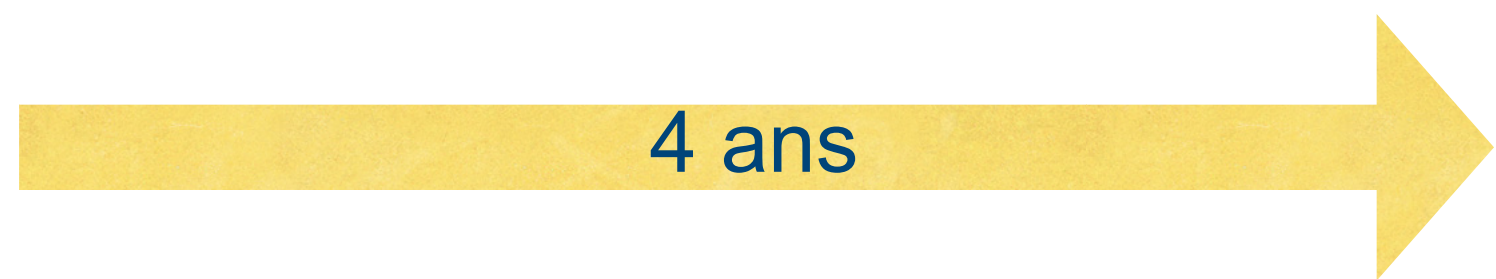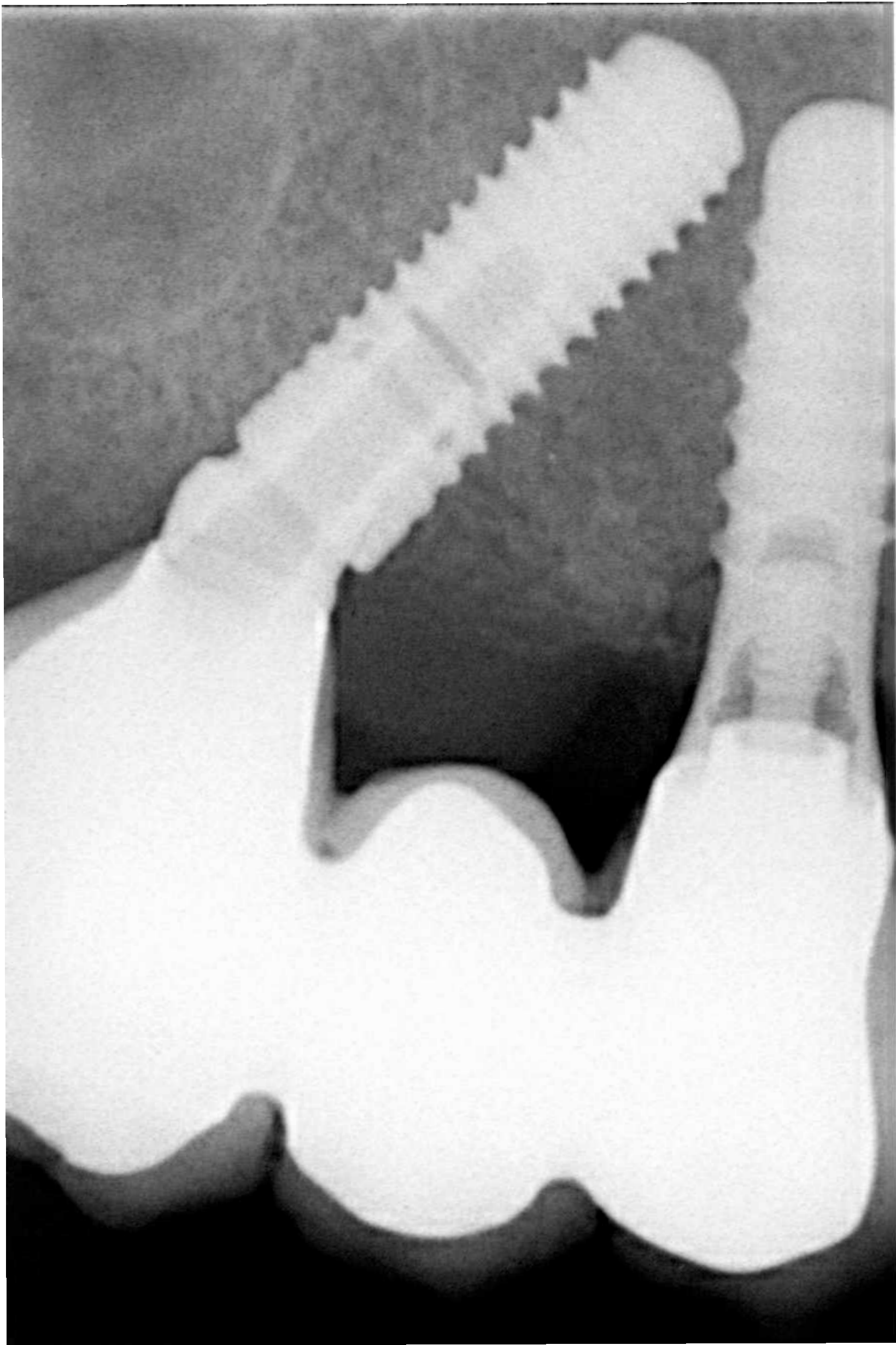
Remaniements osseux

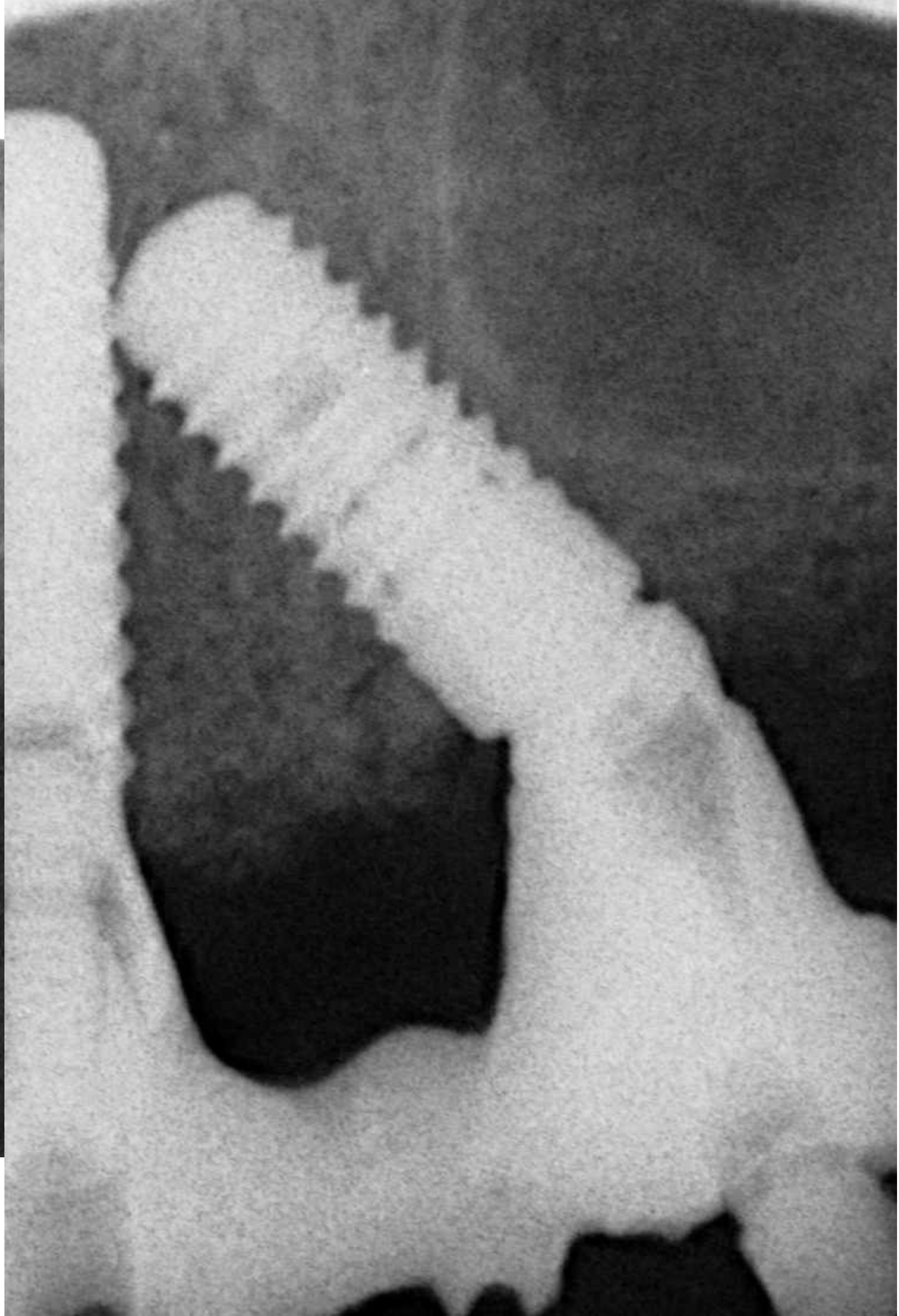
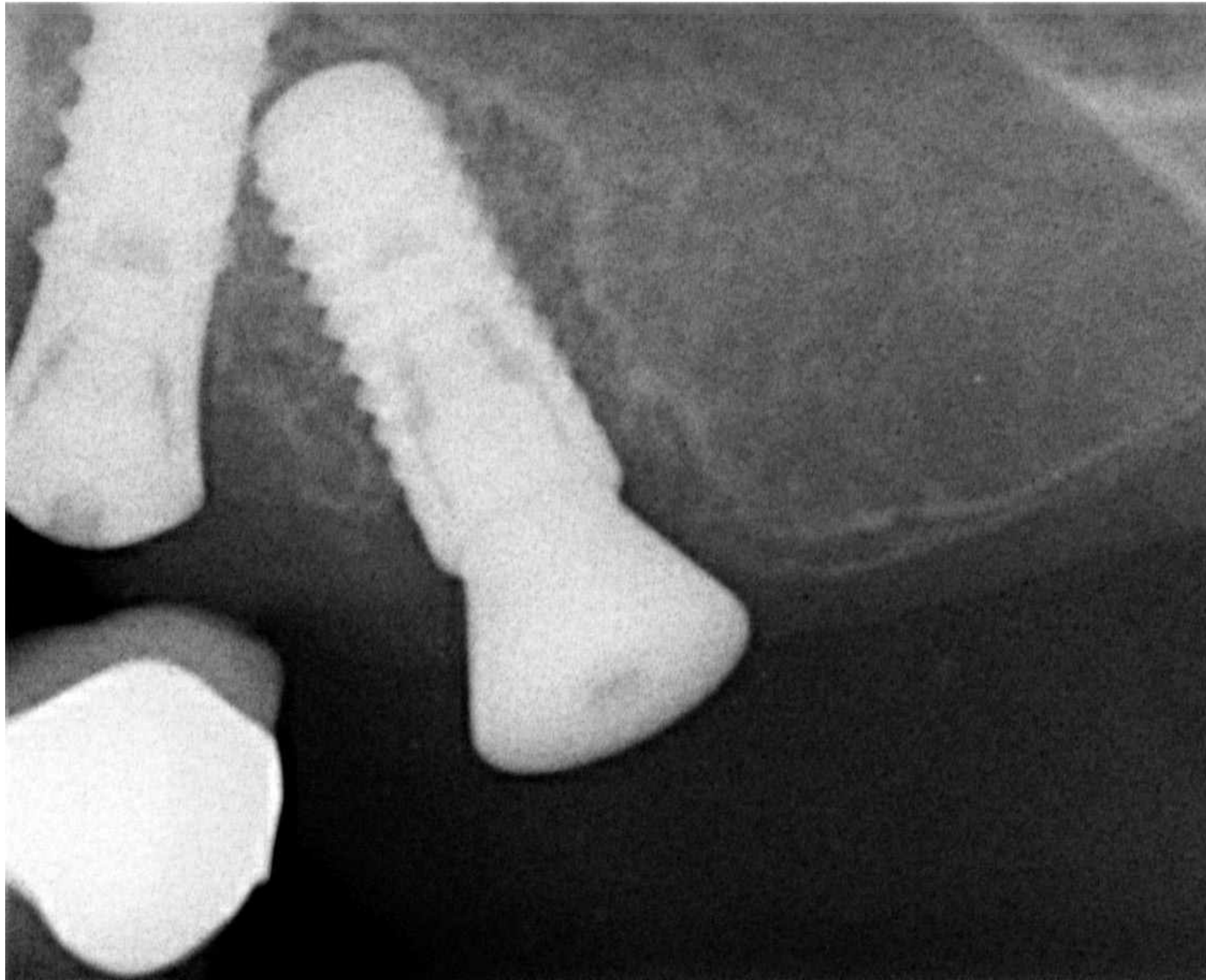


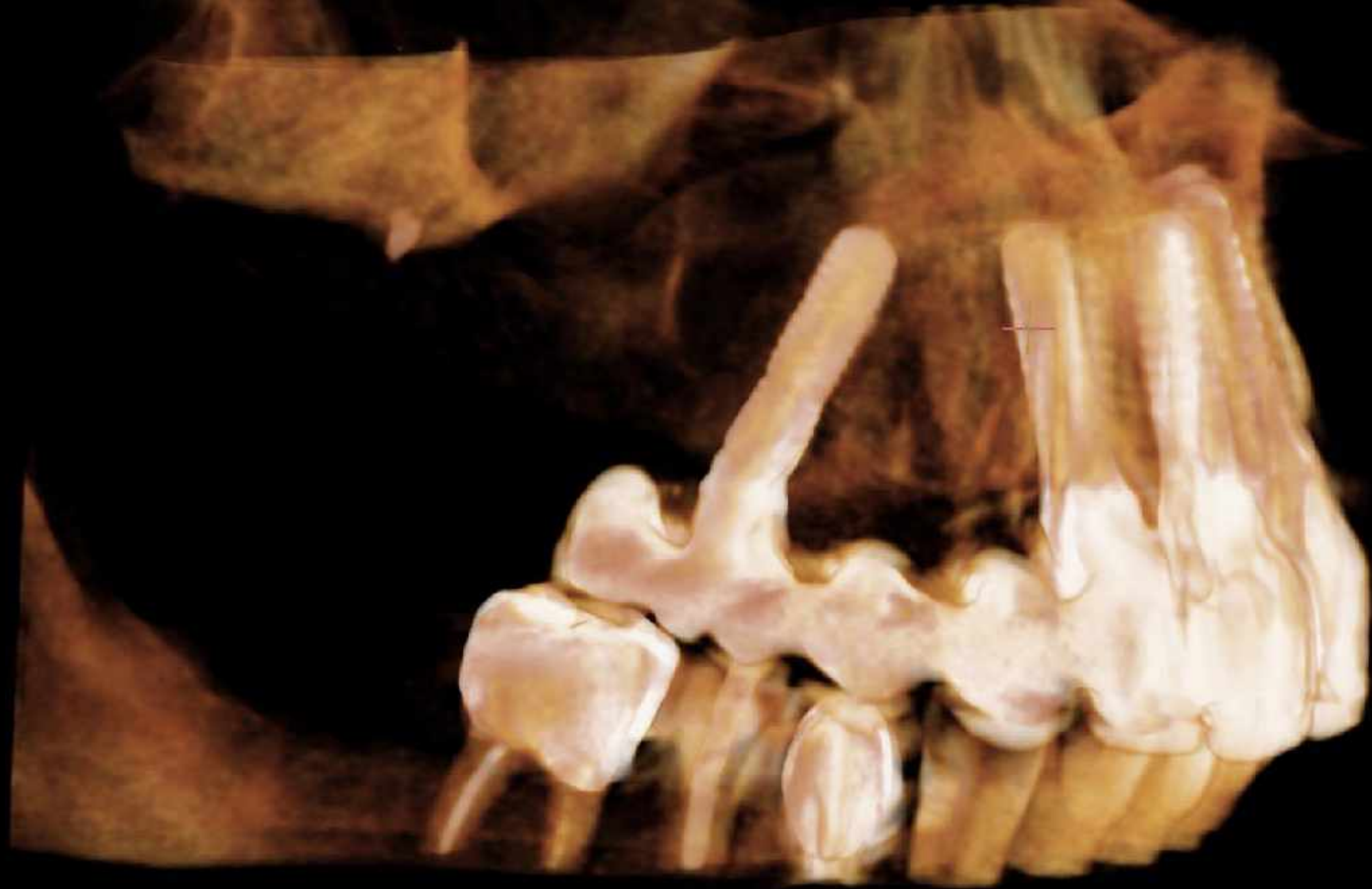INFLUENCE DE L'ANGULATION

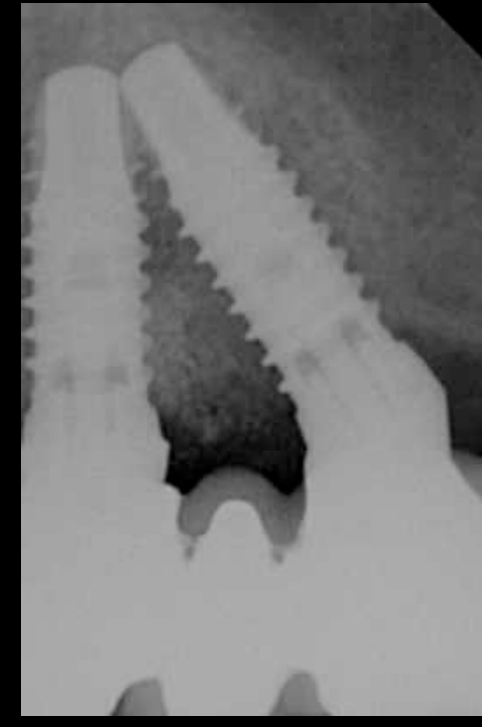
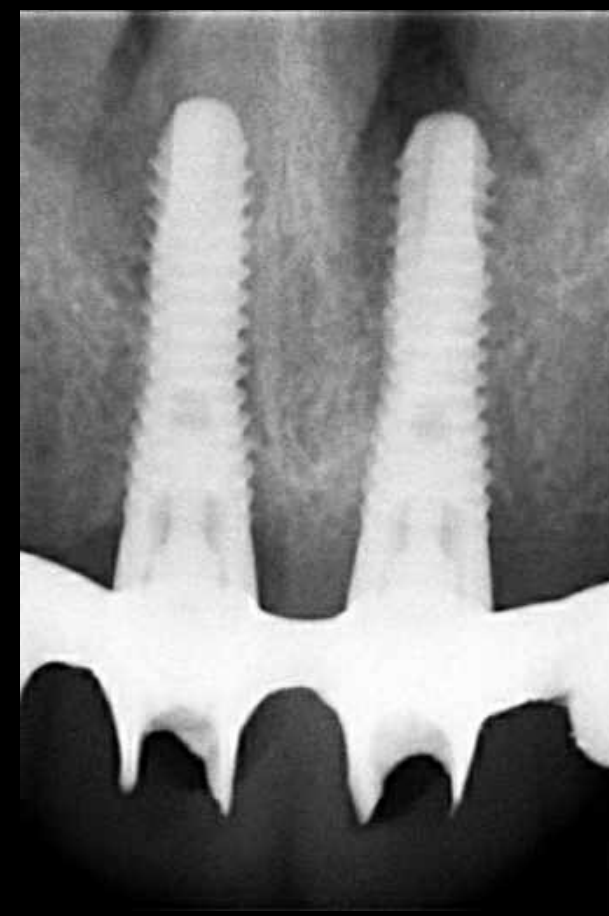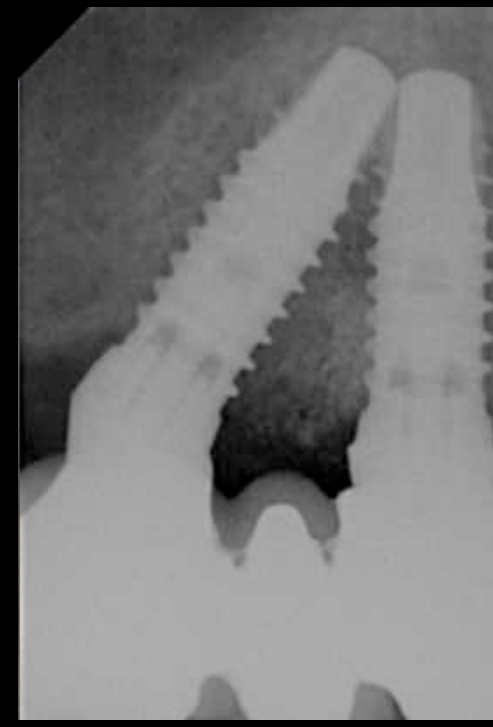



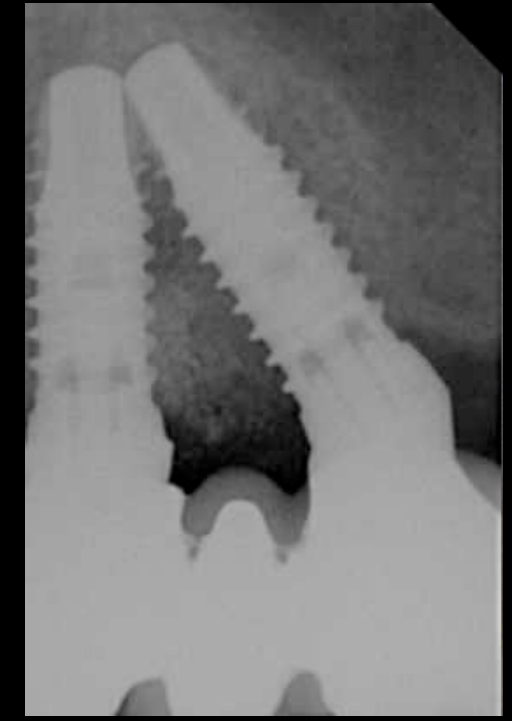
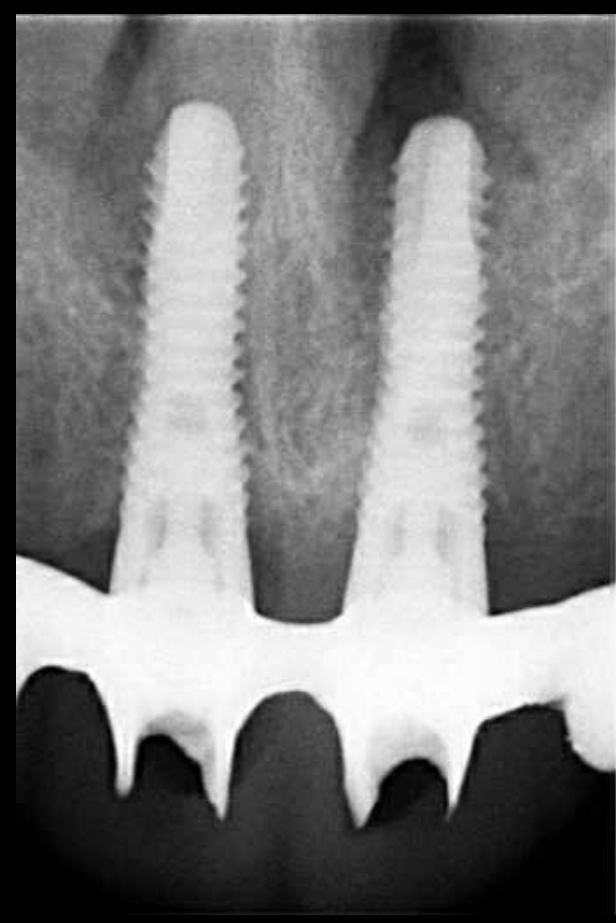
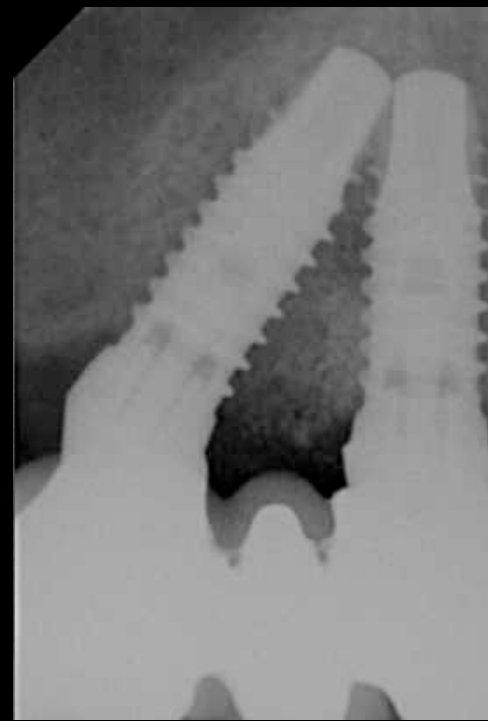
FILLION M^(1,2), AUBAZAC D^(1,3), CHAPAT Q⁽⁴⁾, NICOLAS E⁽⁴⁾. Bone Level changes around tilted implants in Fixed Complete Denture and Fixed Partial Denture : a retrospective study Europerio7 Vienna 2012. Poster n°0991

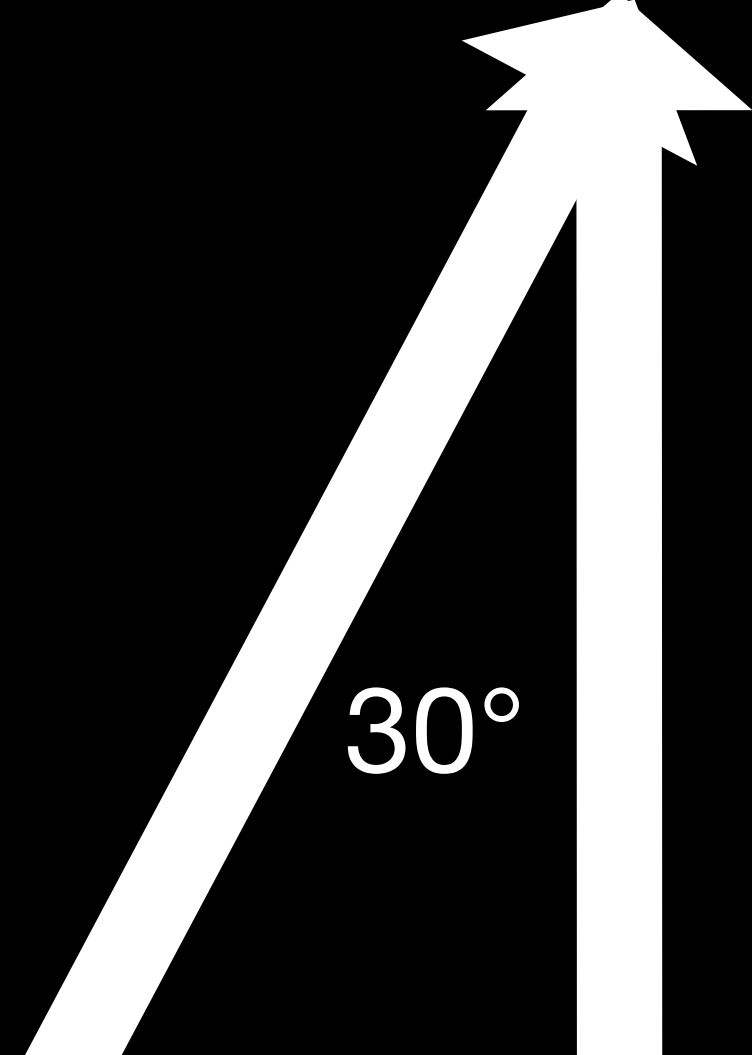

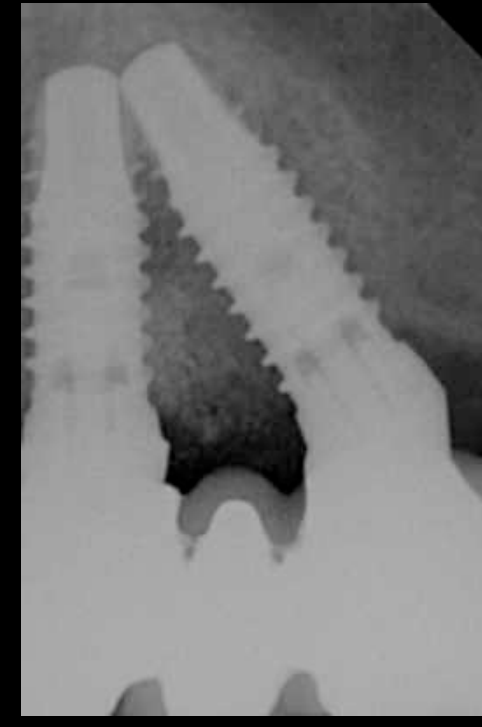
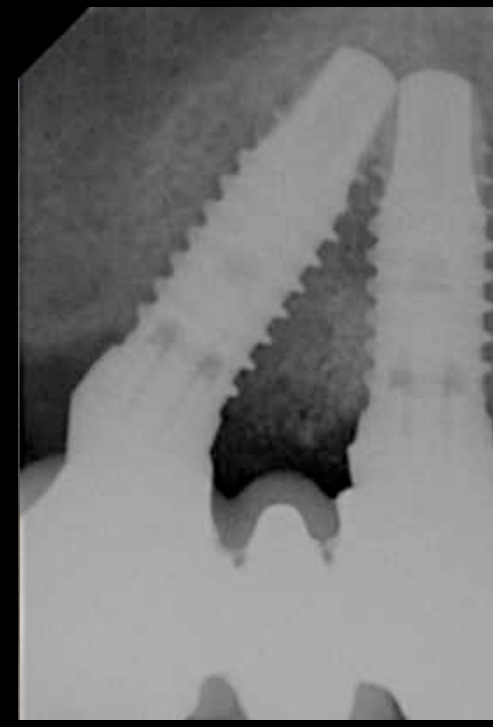






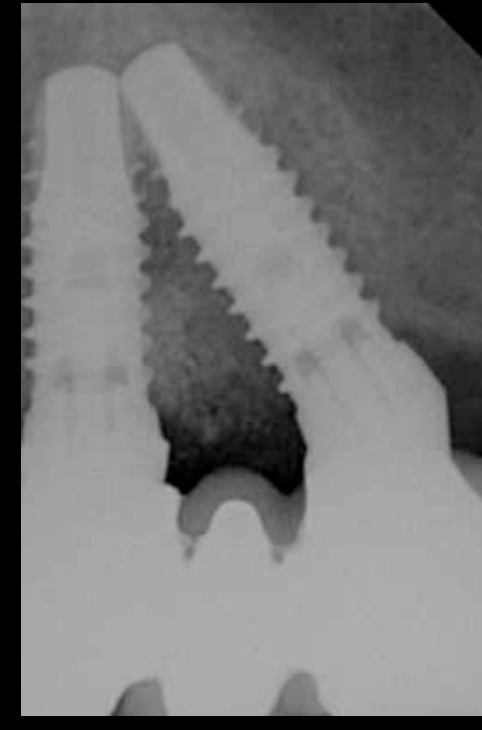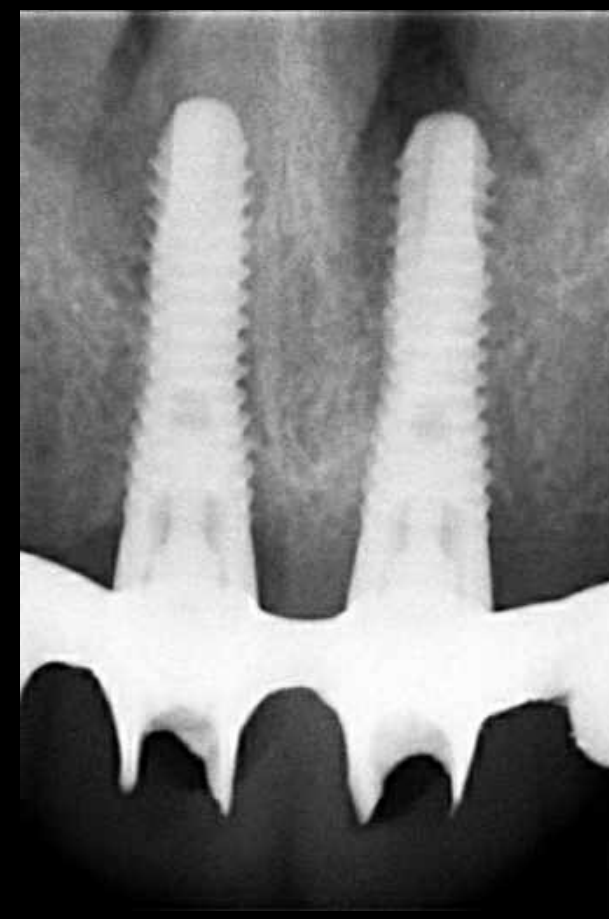
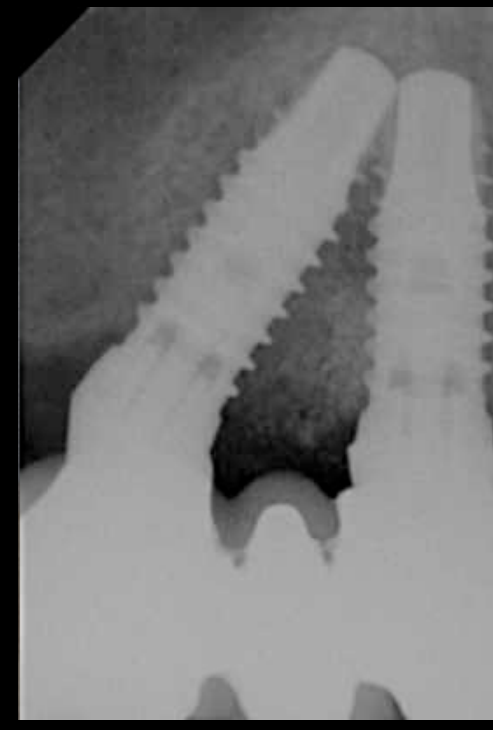





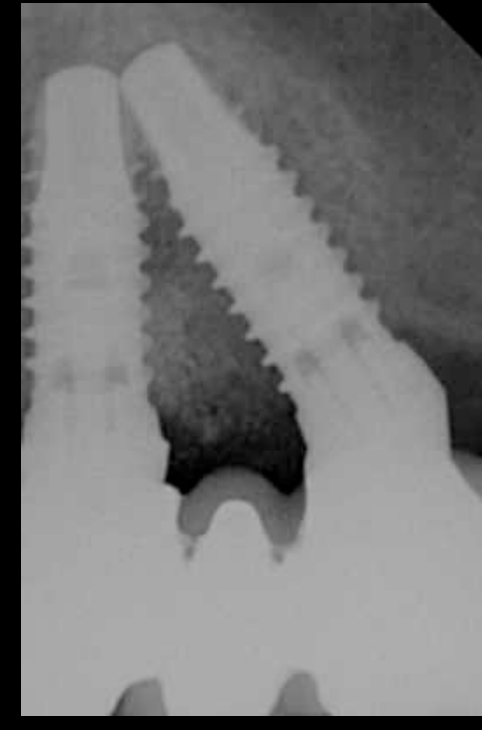
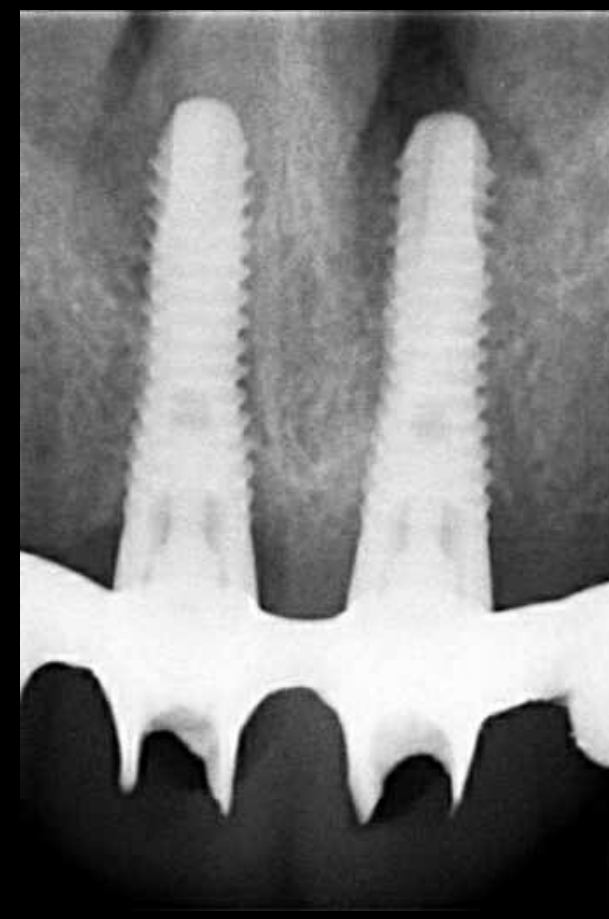
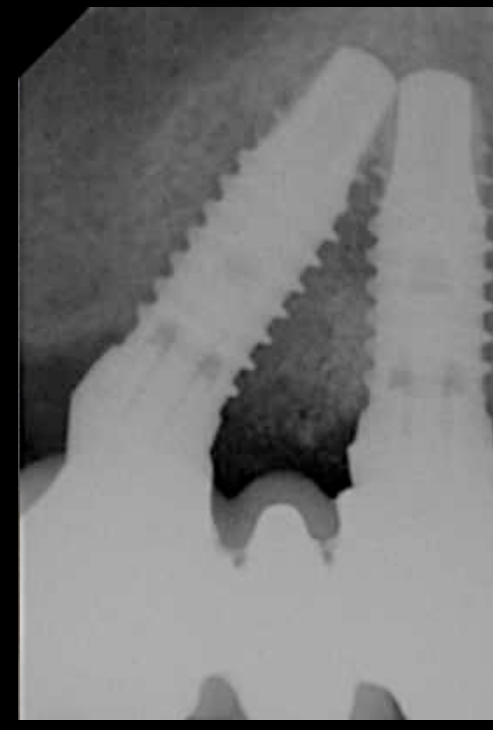




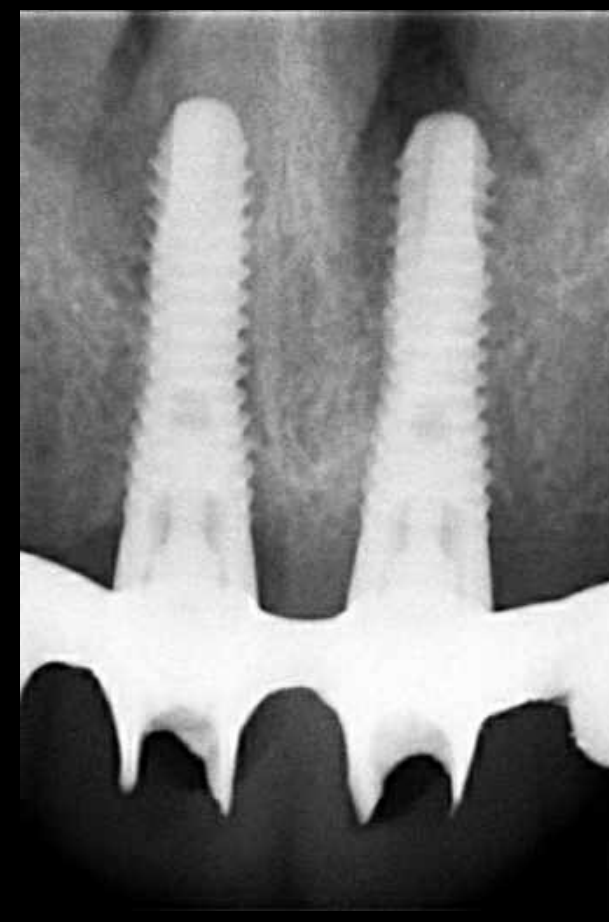
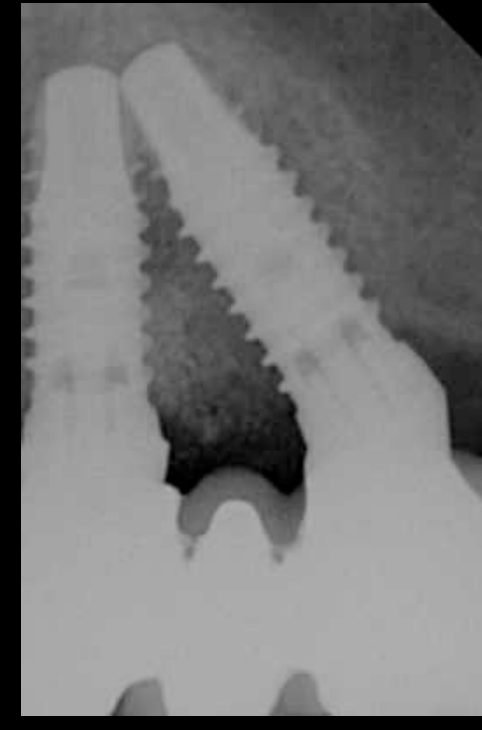
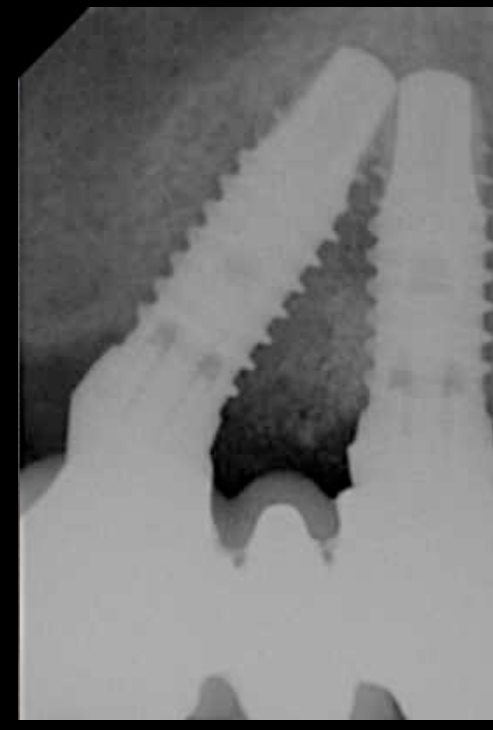




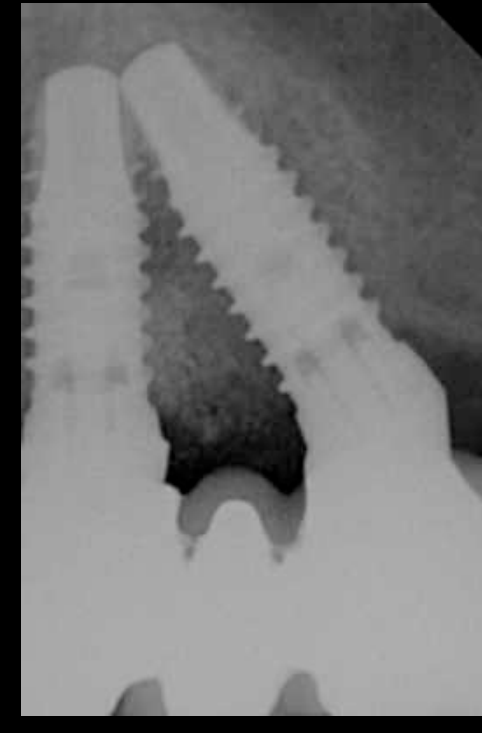
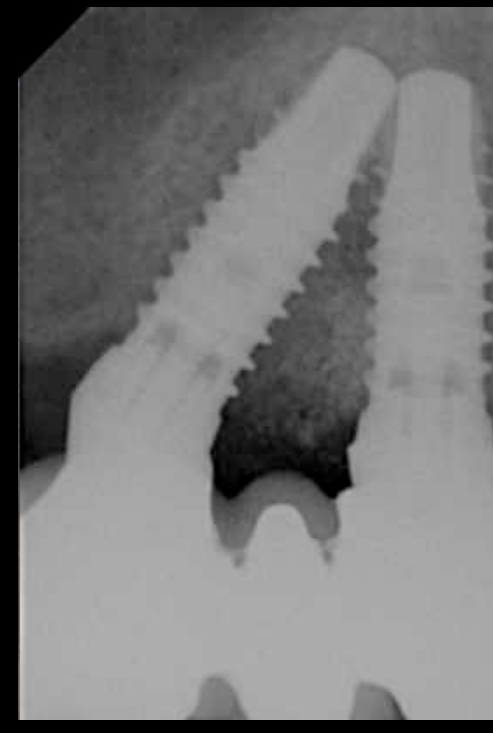






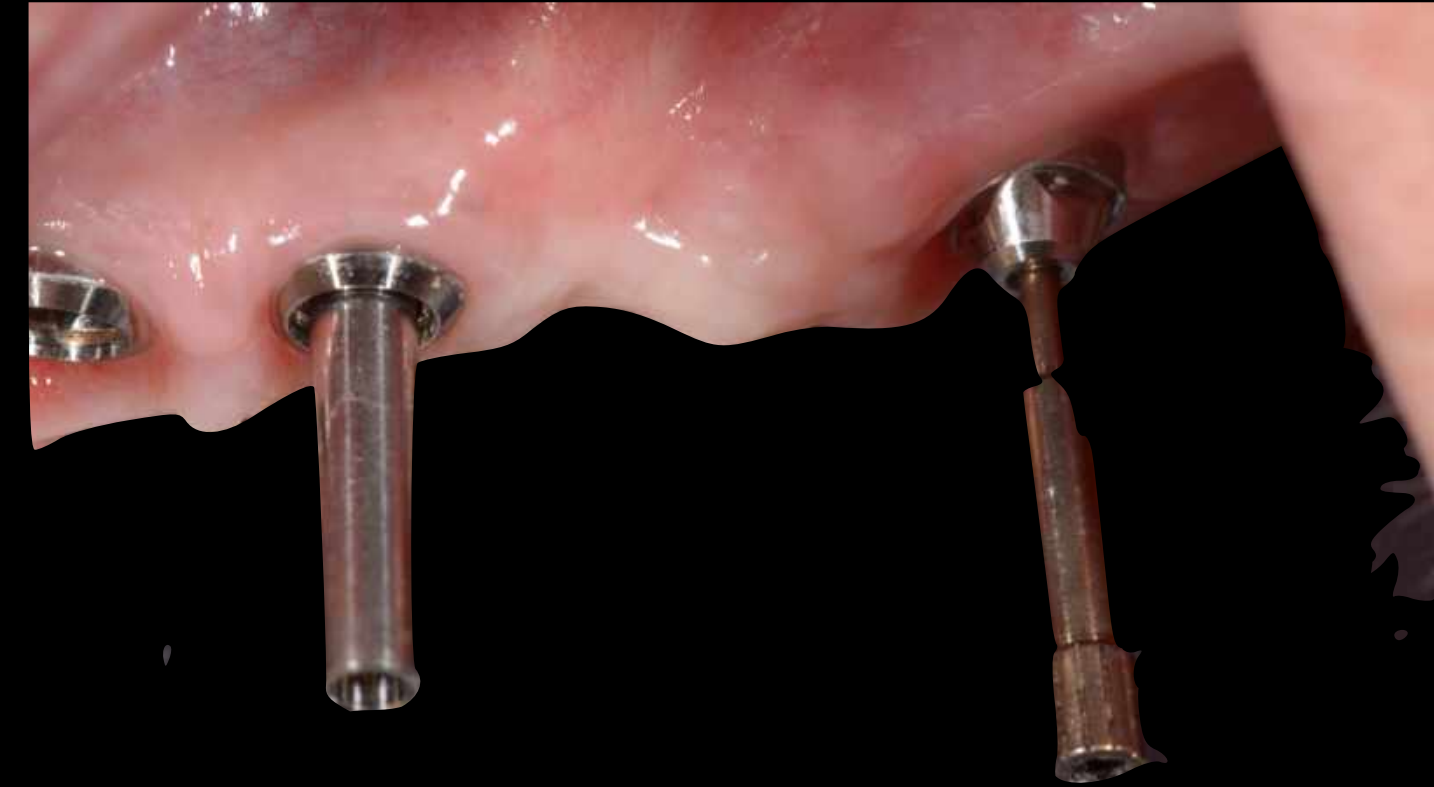

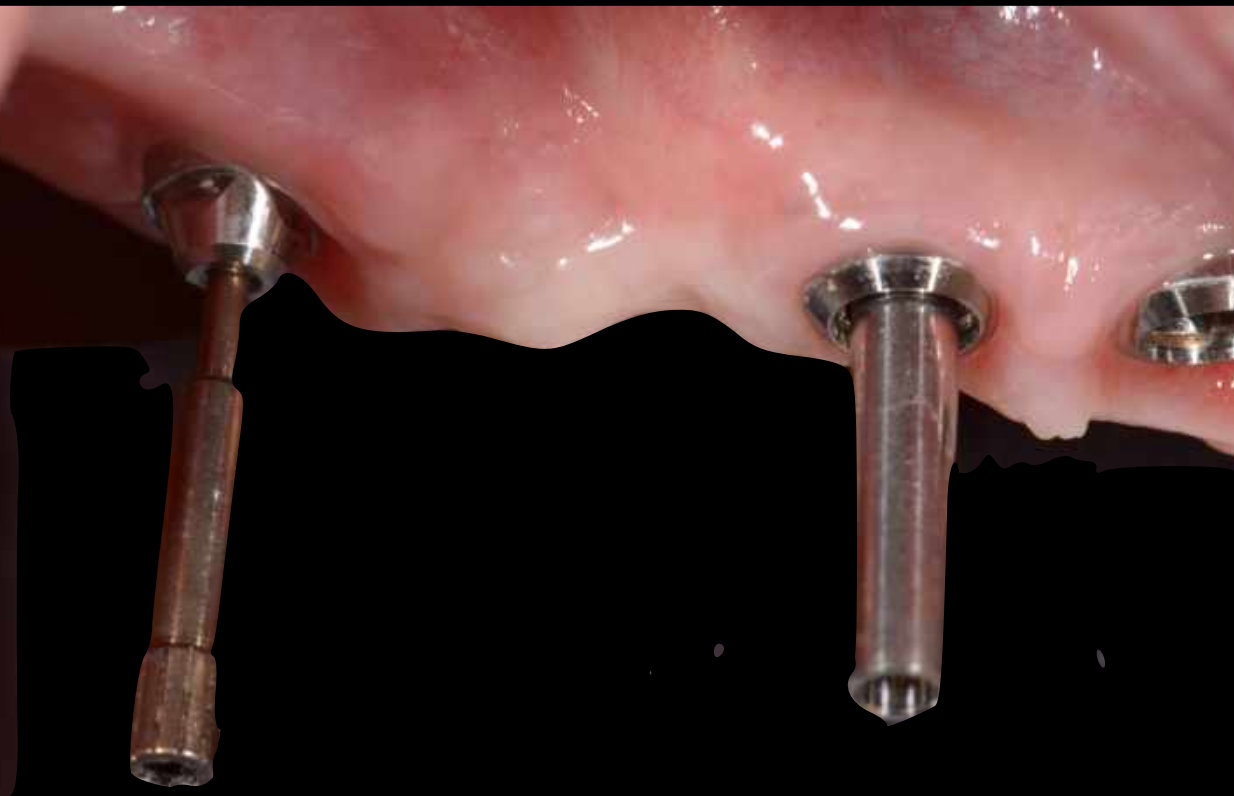
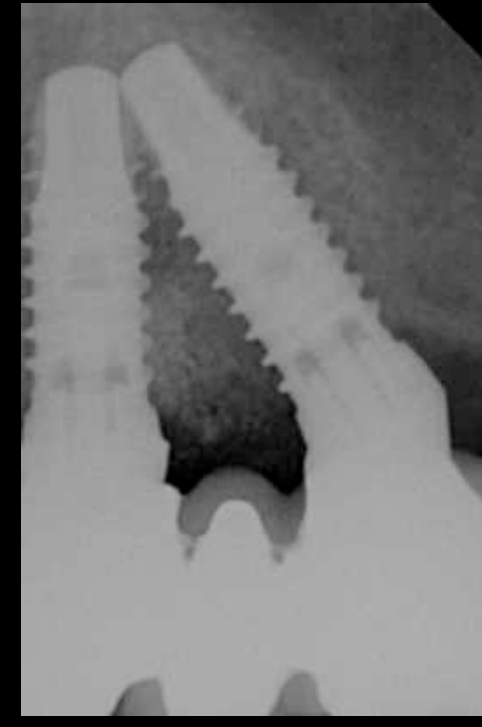
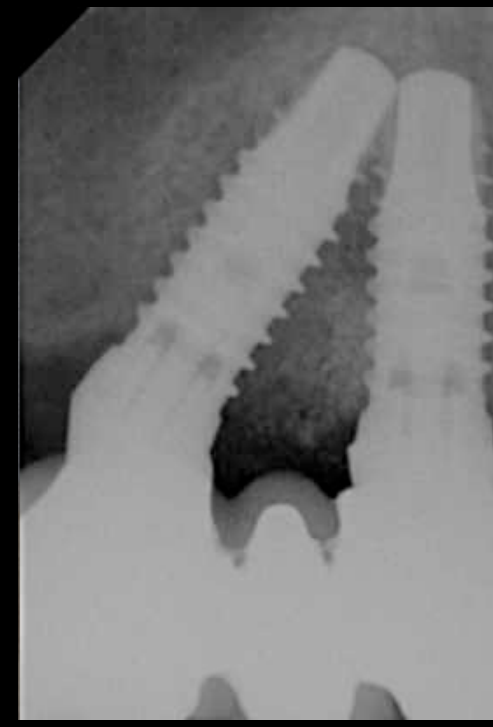
30°

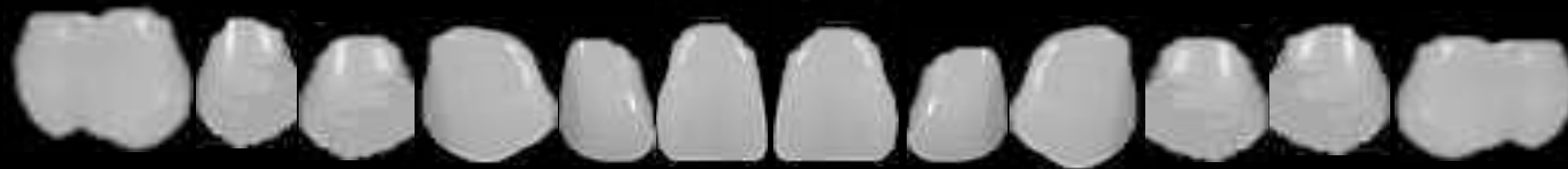
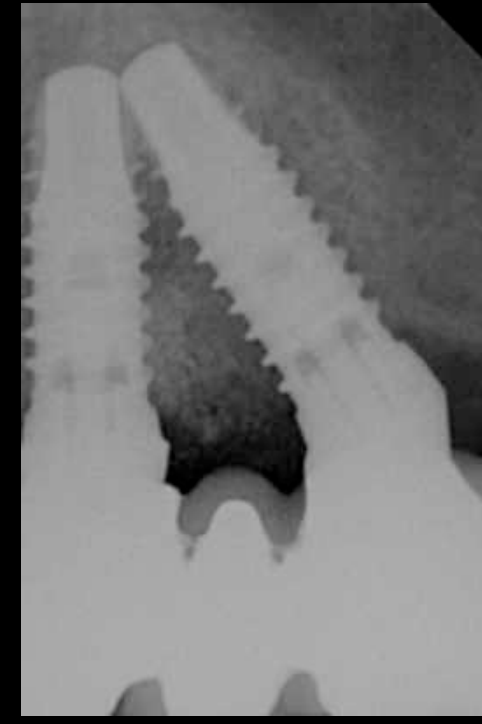
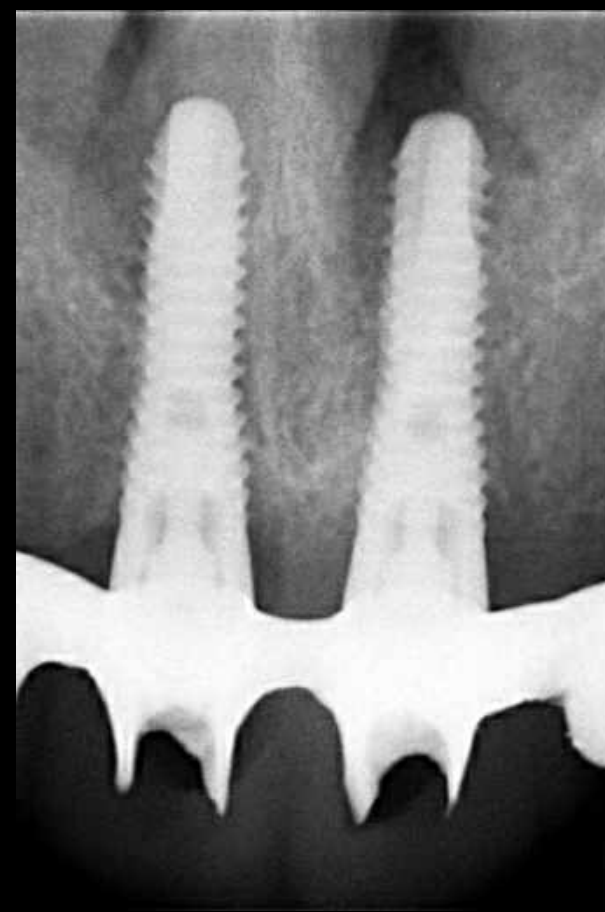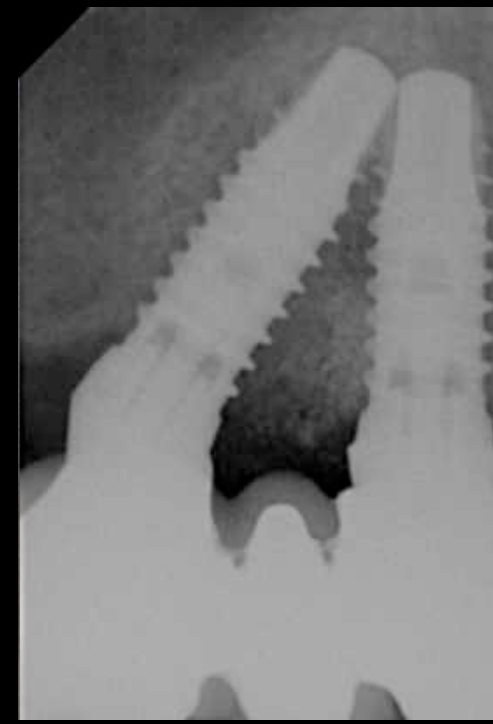





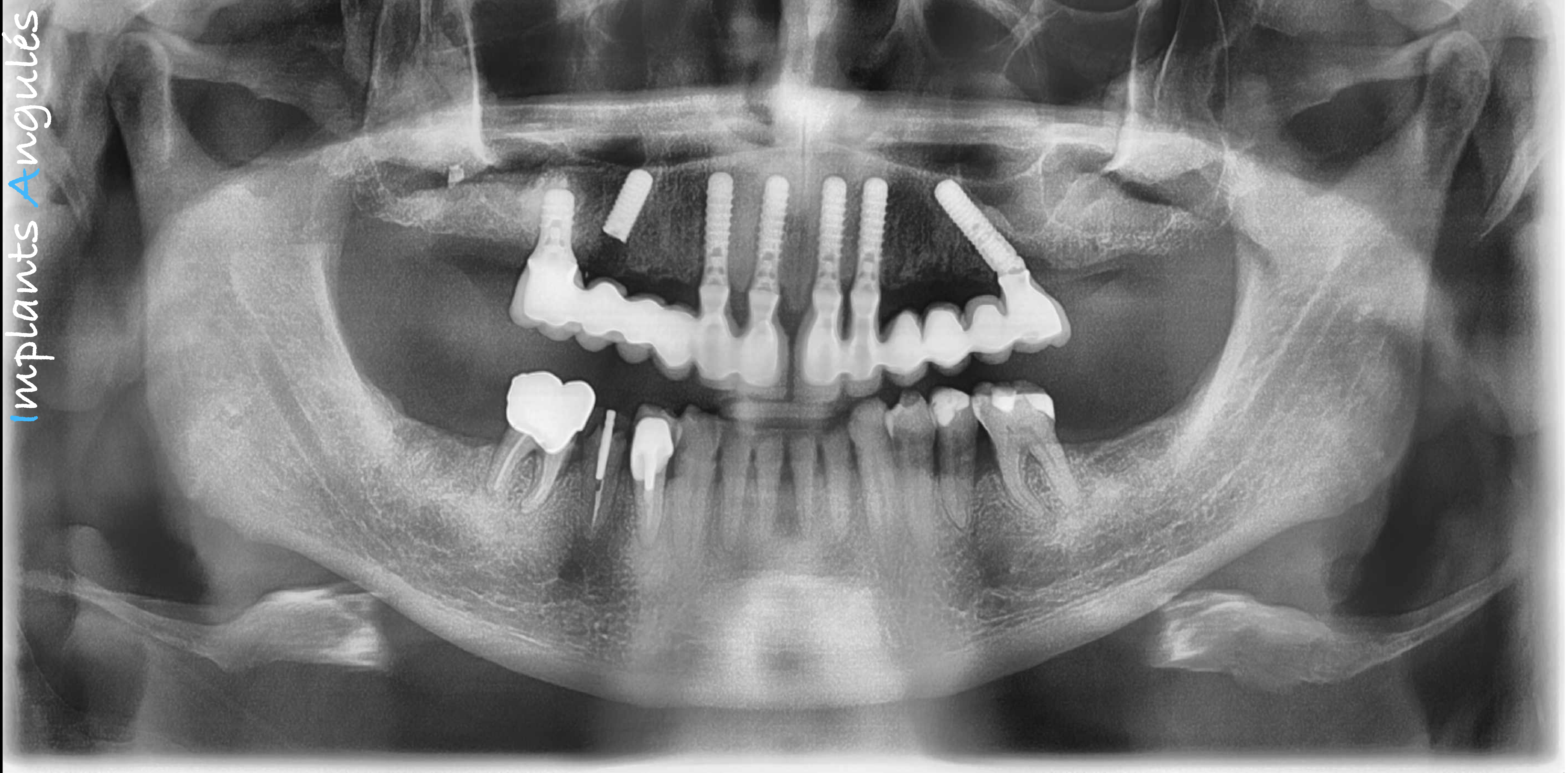
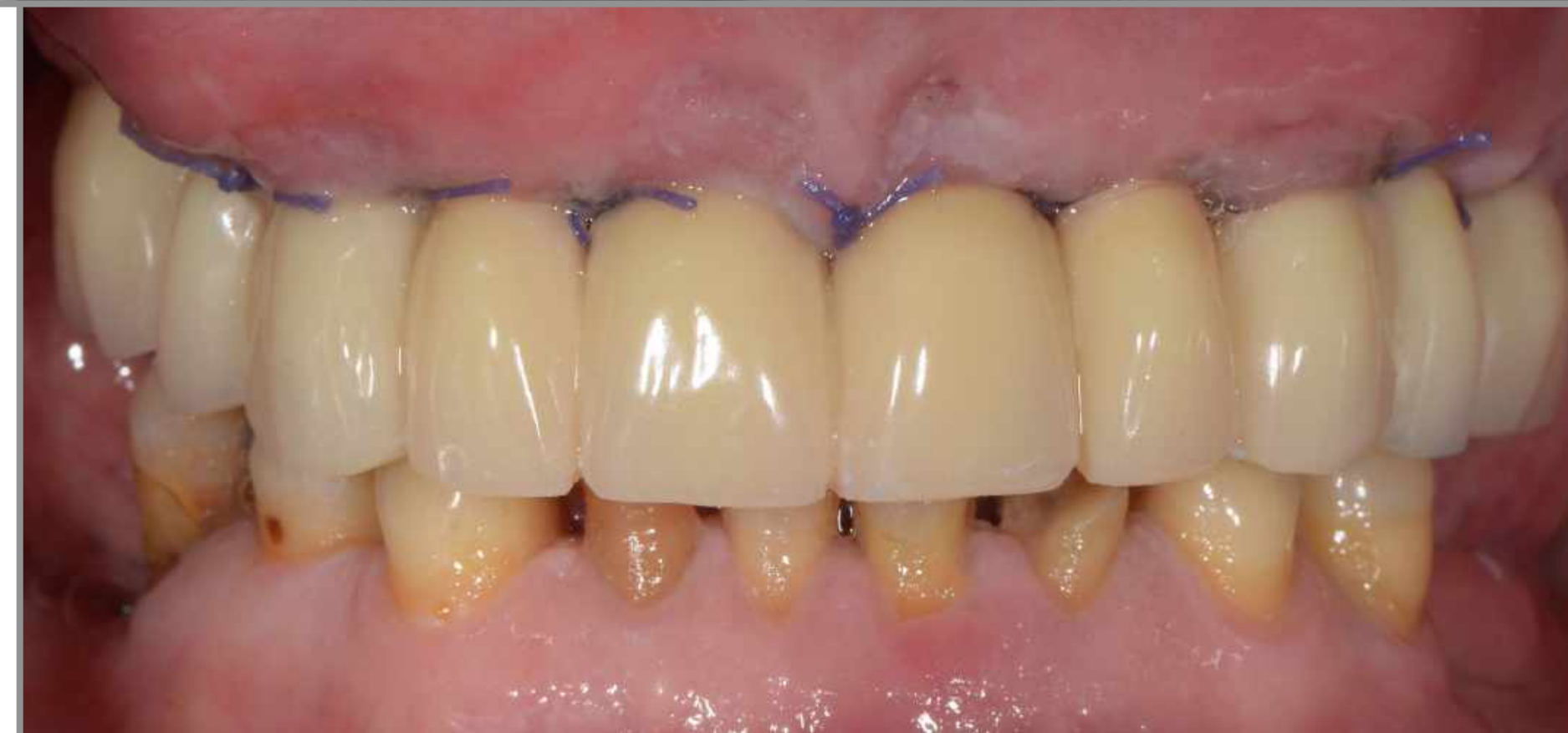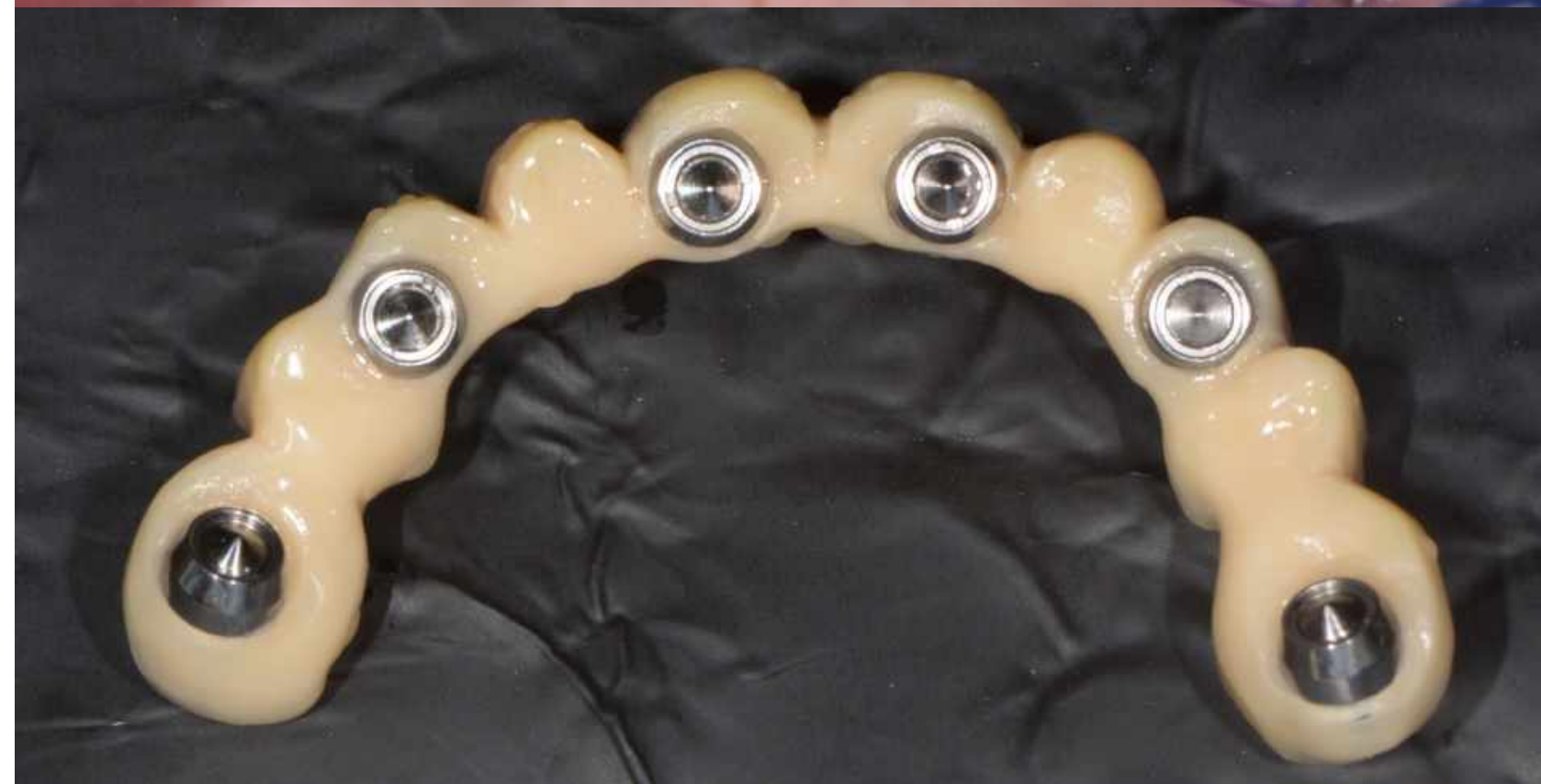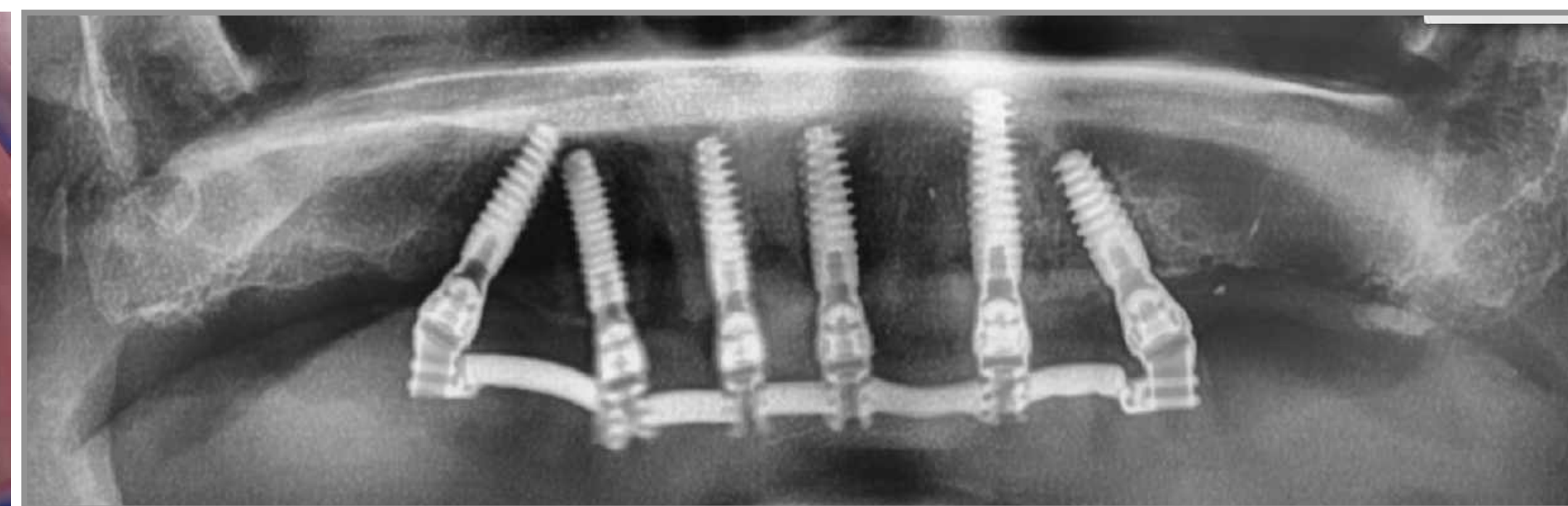
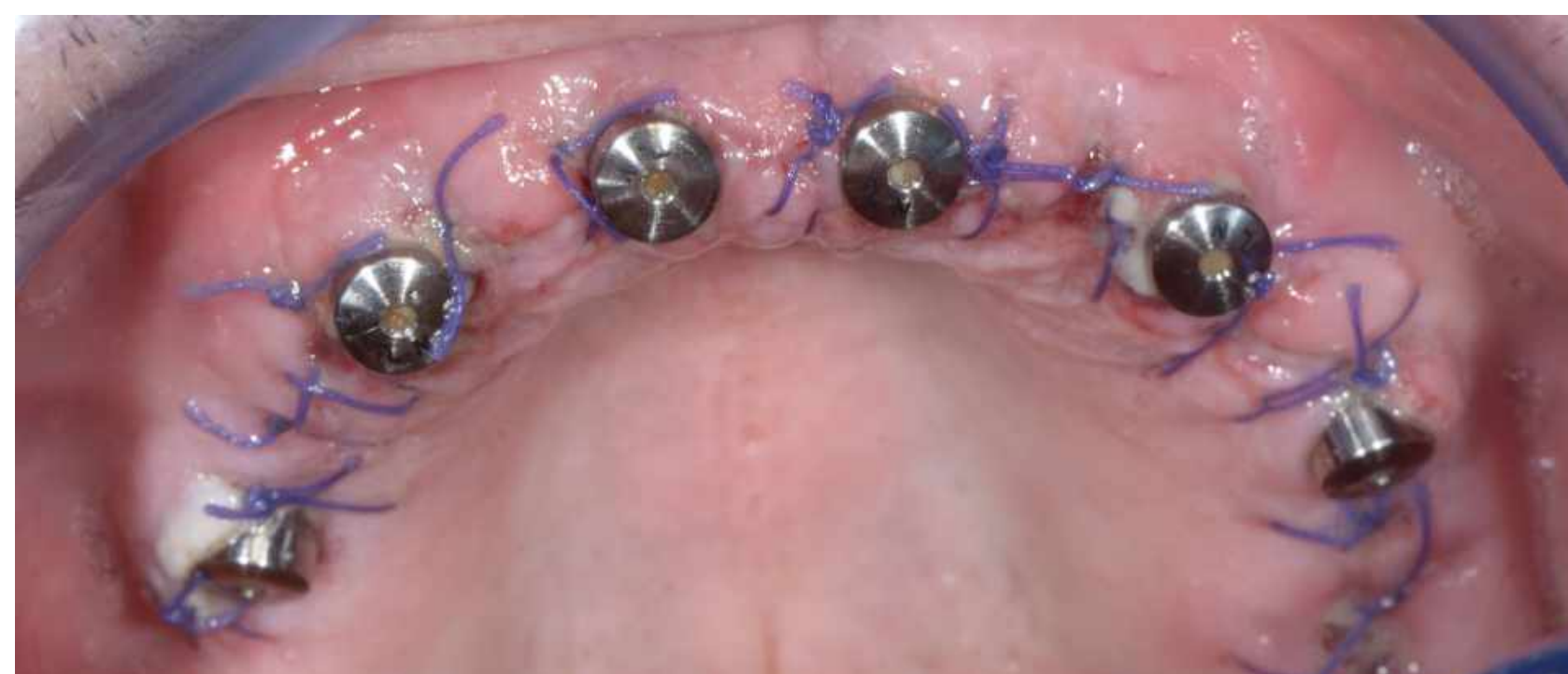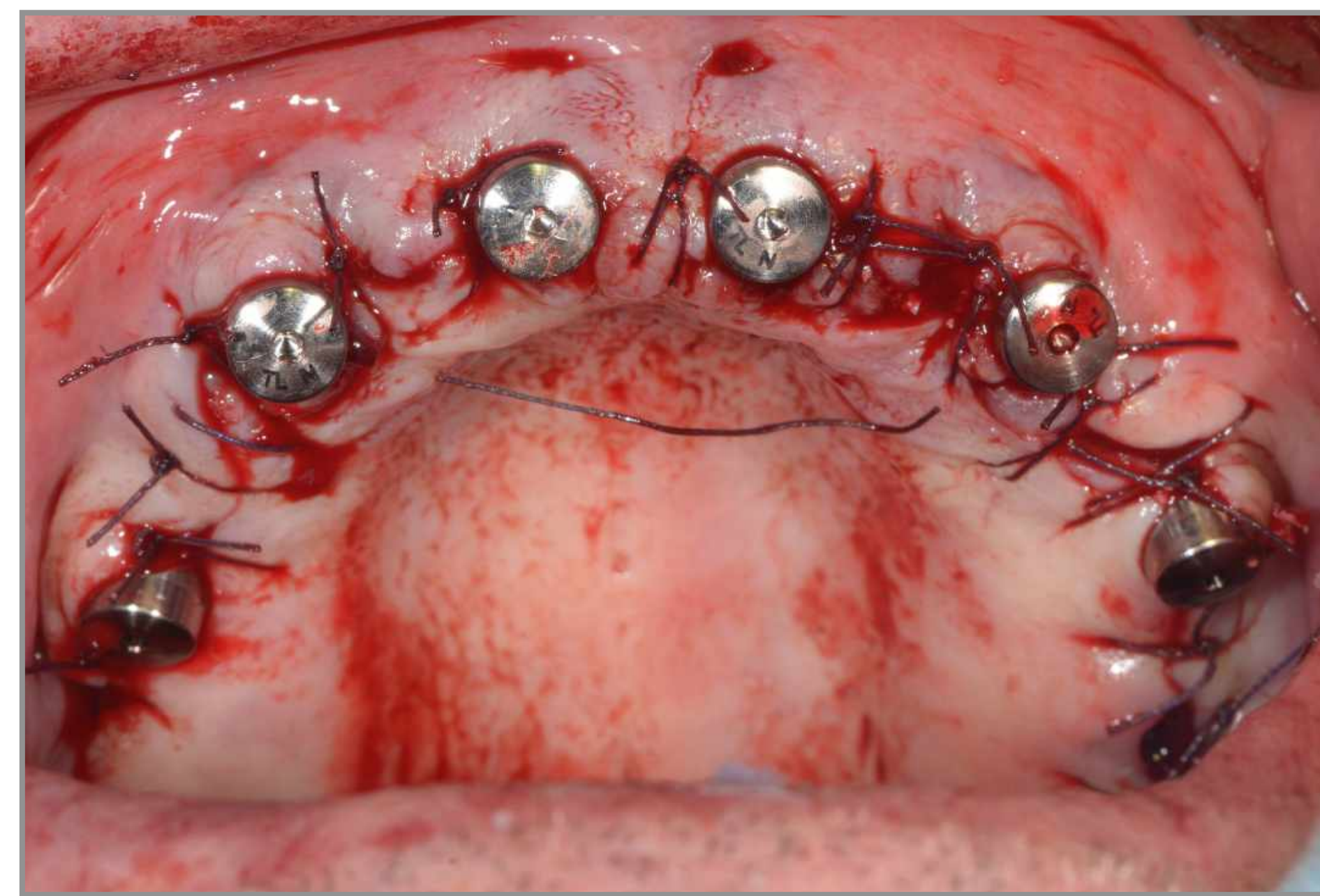
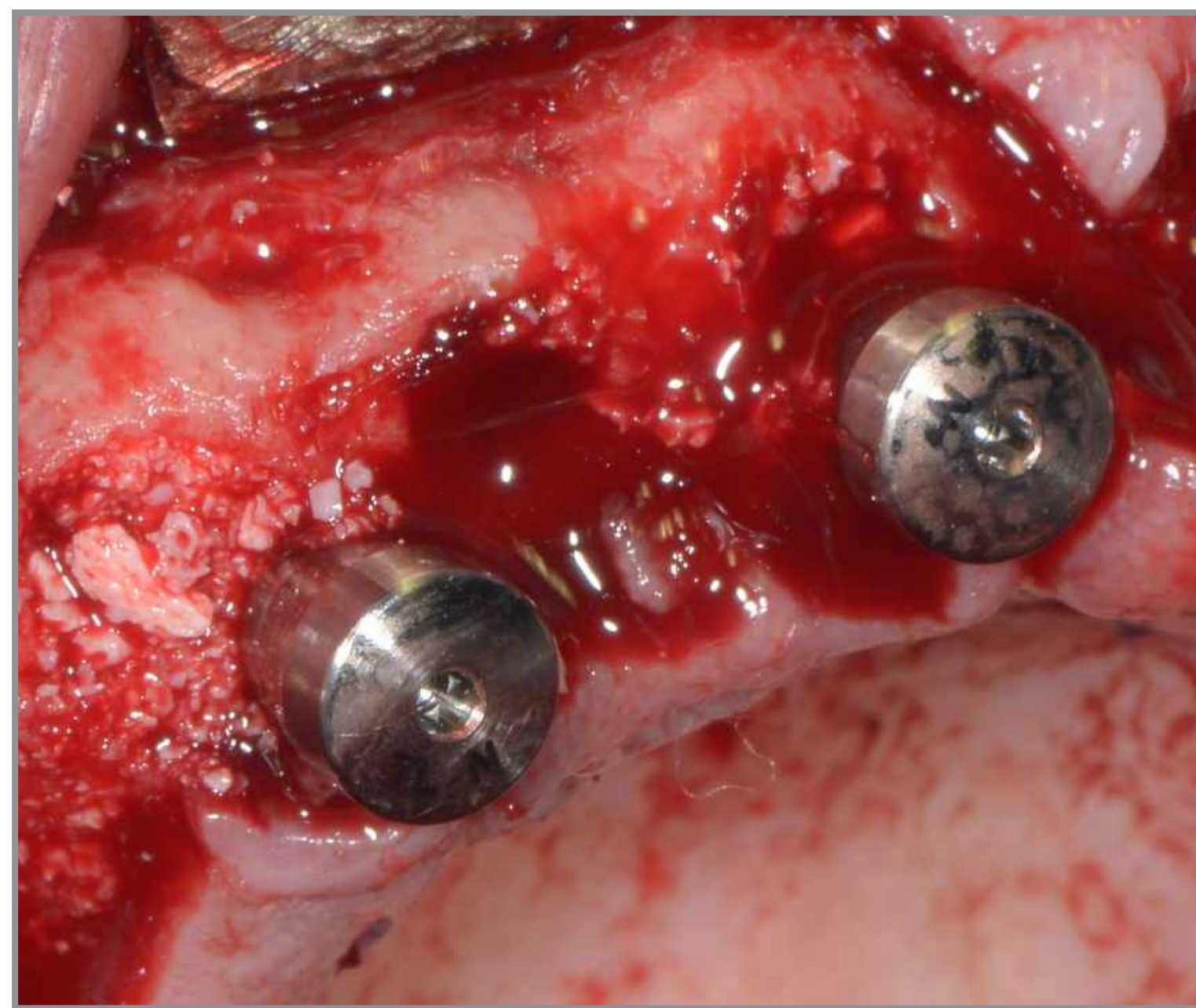




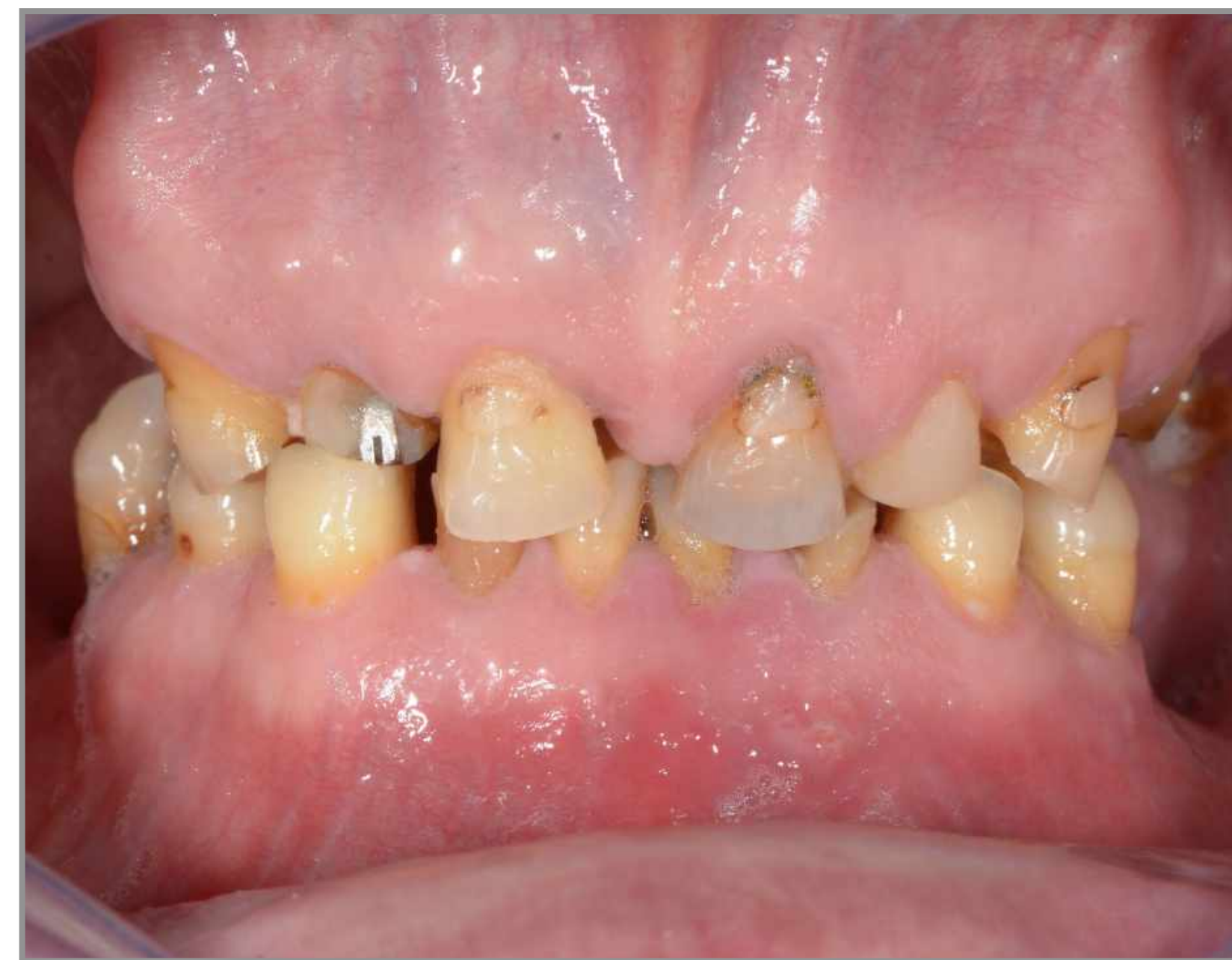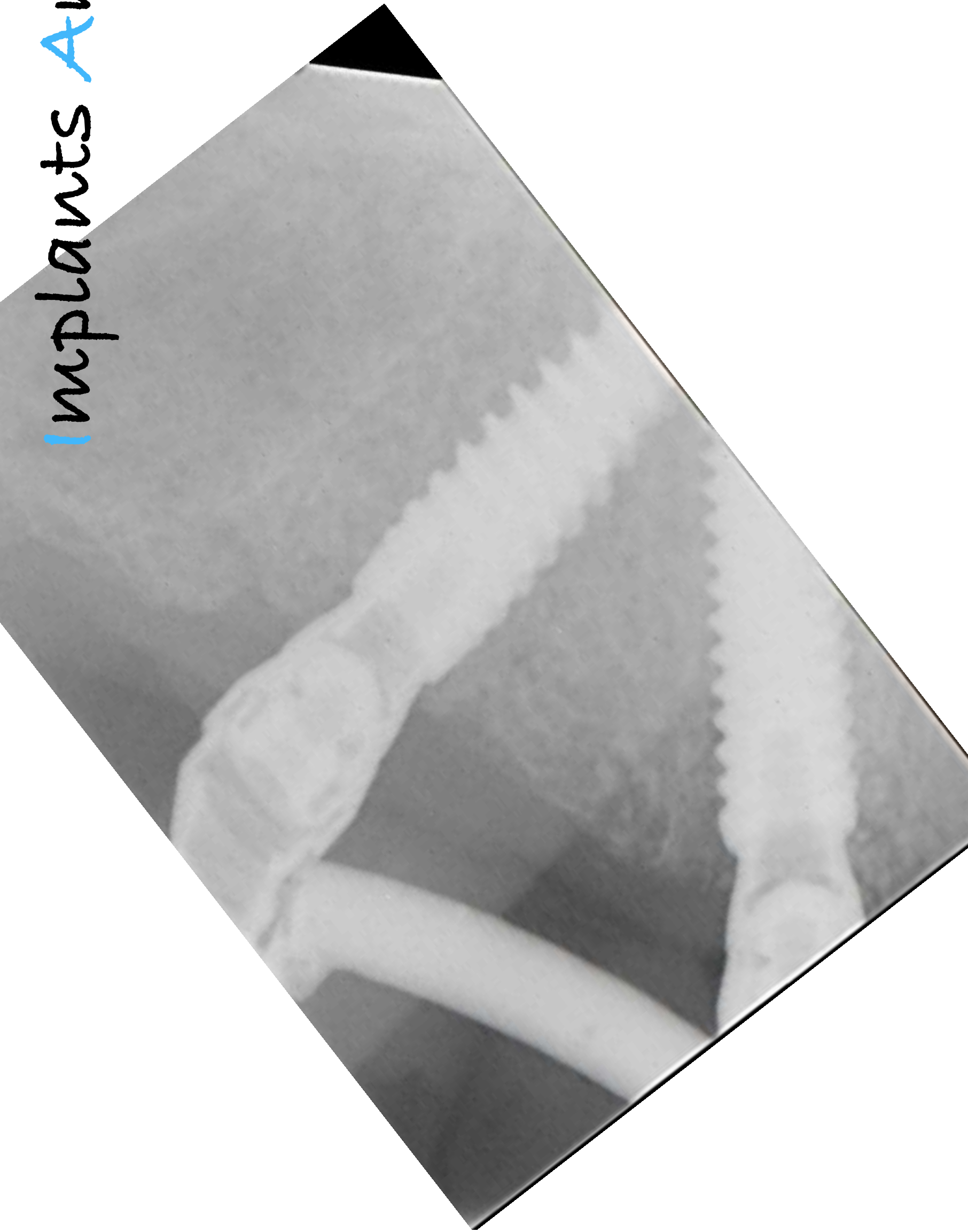


Implants Angulés

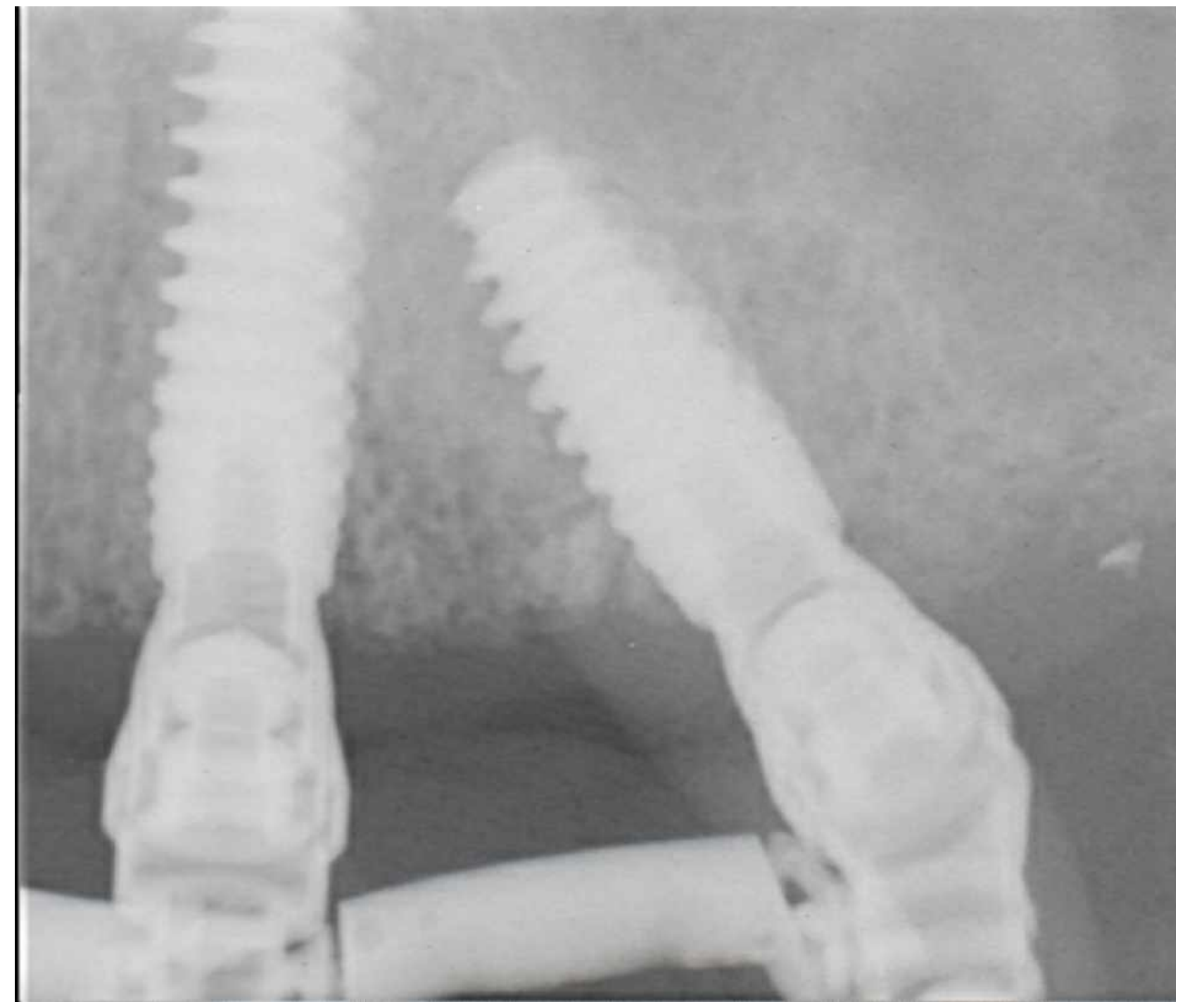
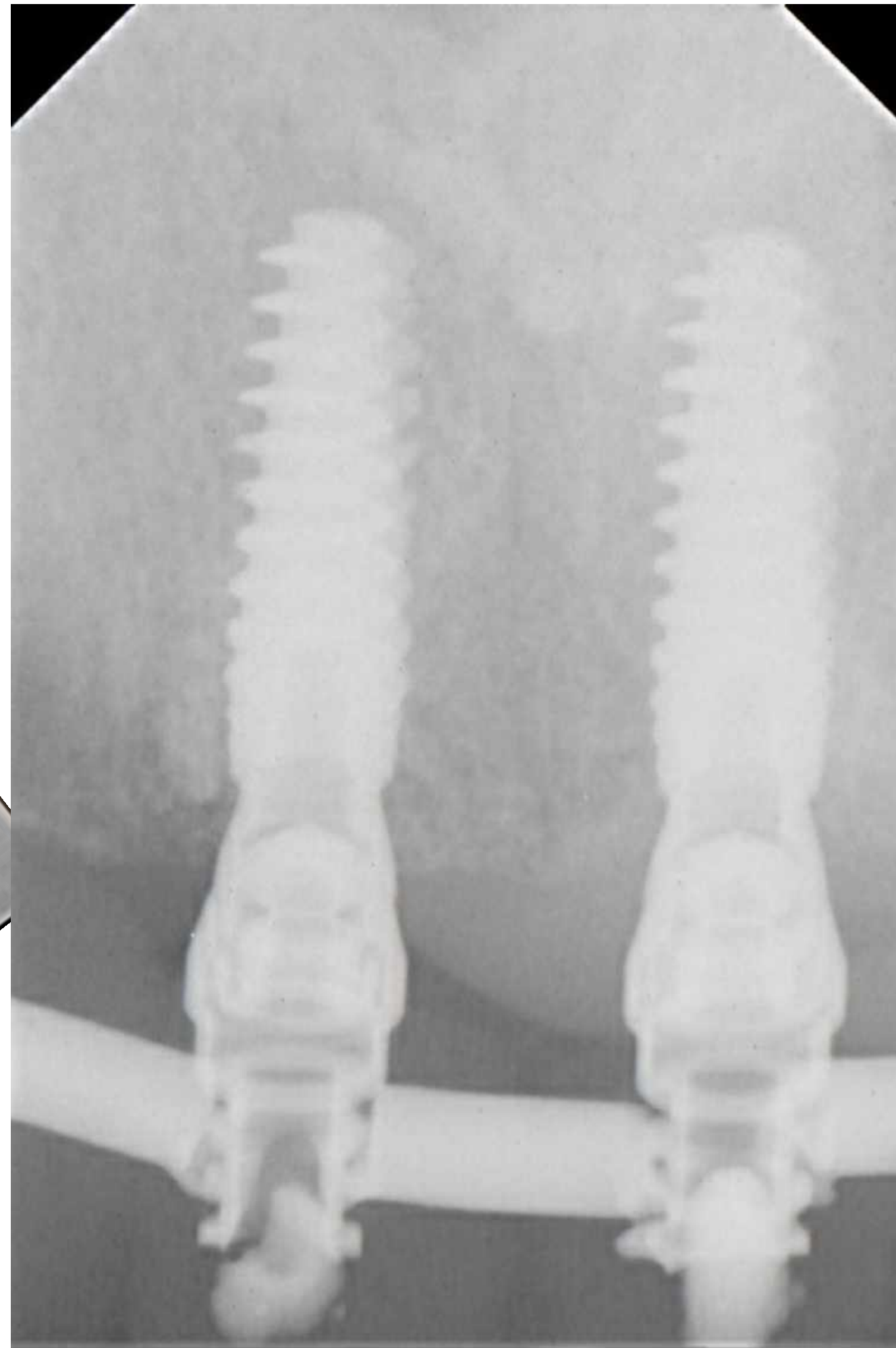



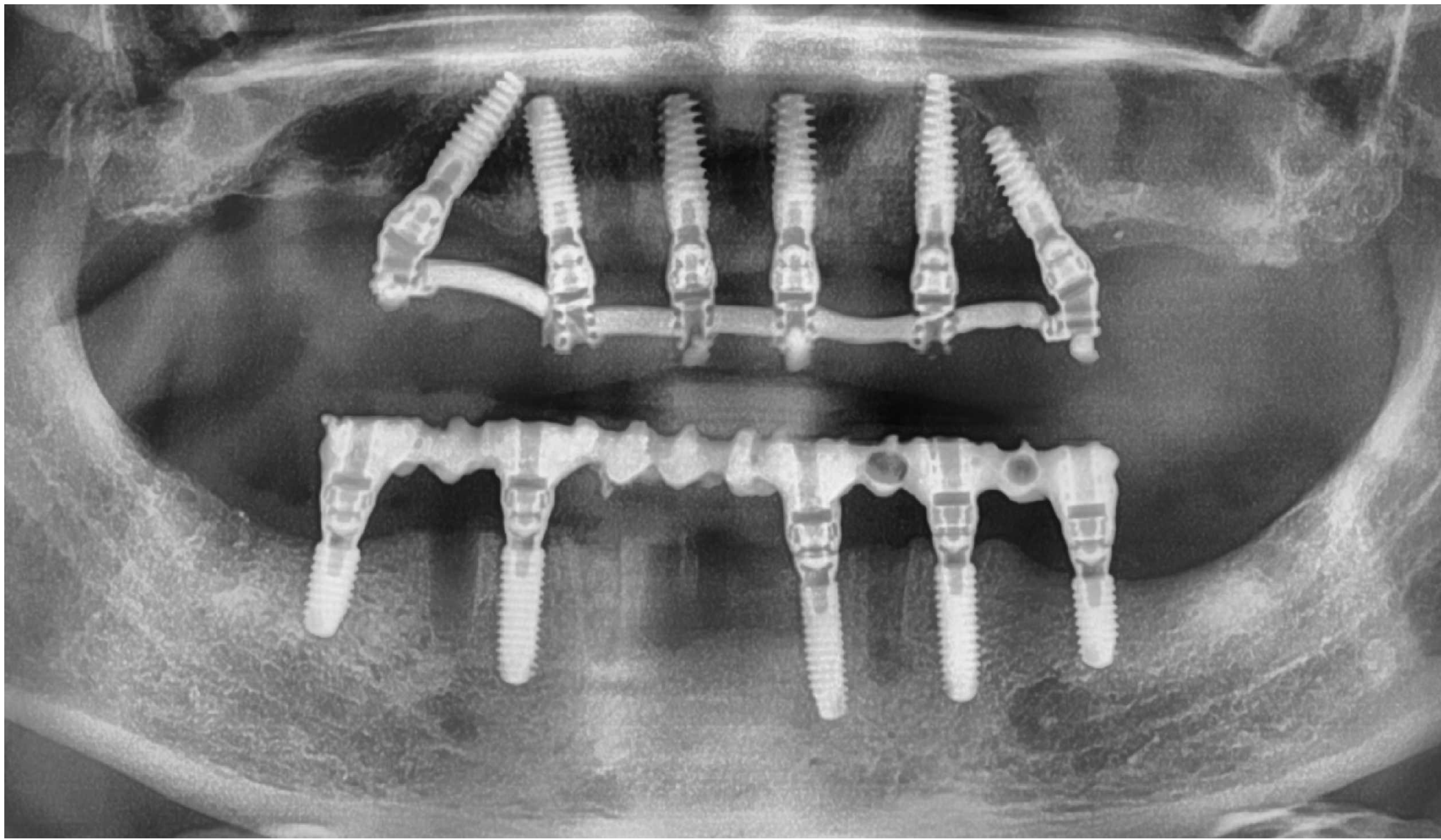
Implants Angulés



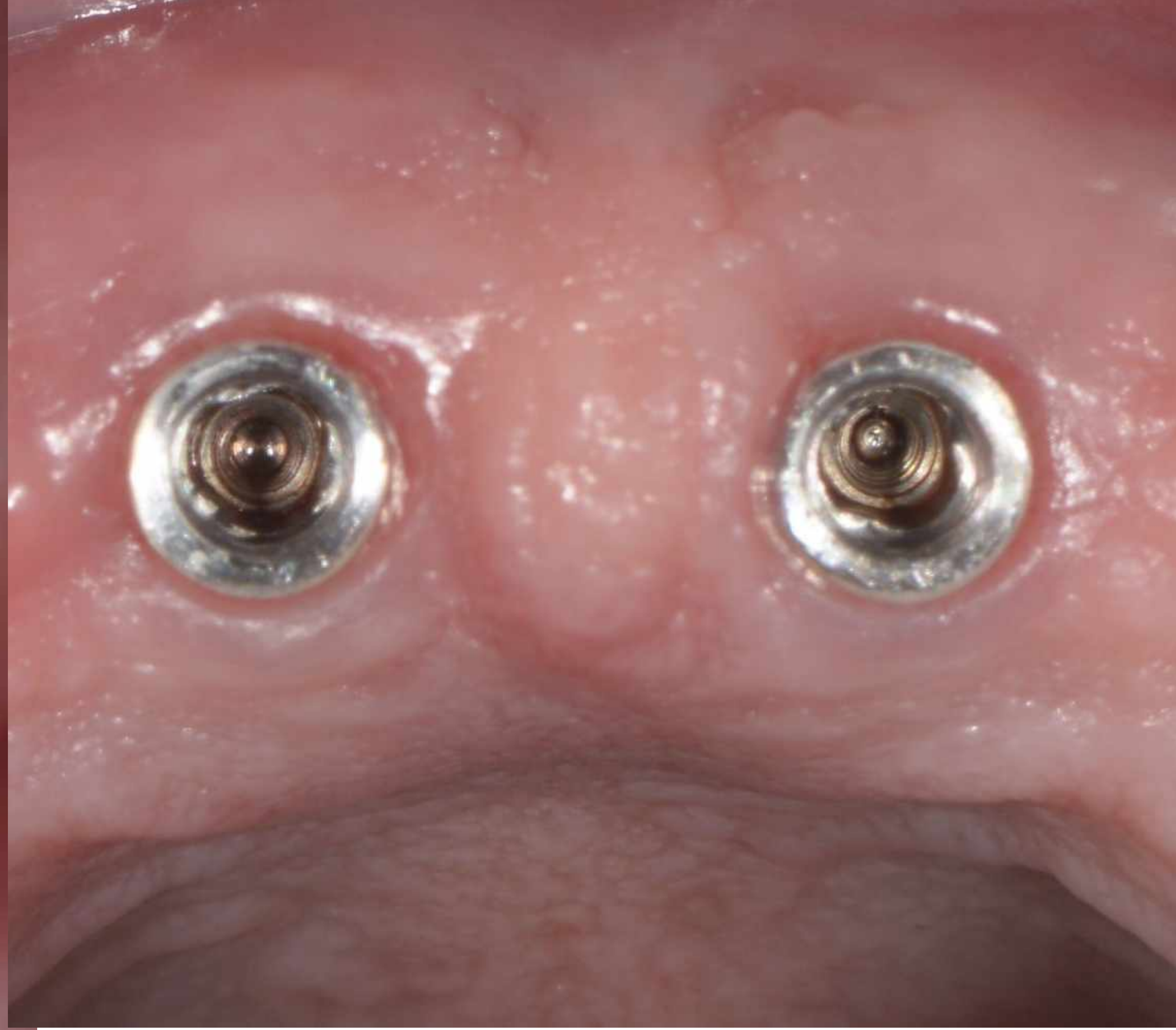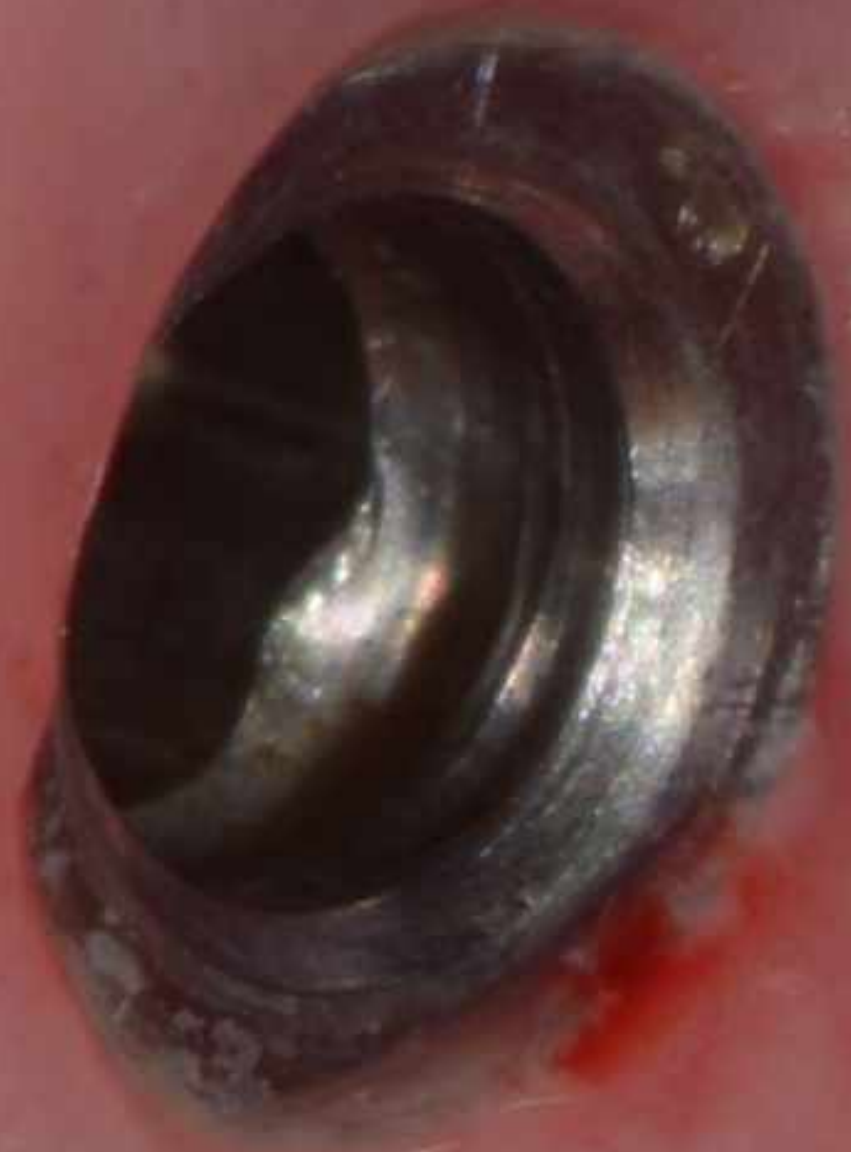Contrôle à 10s



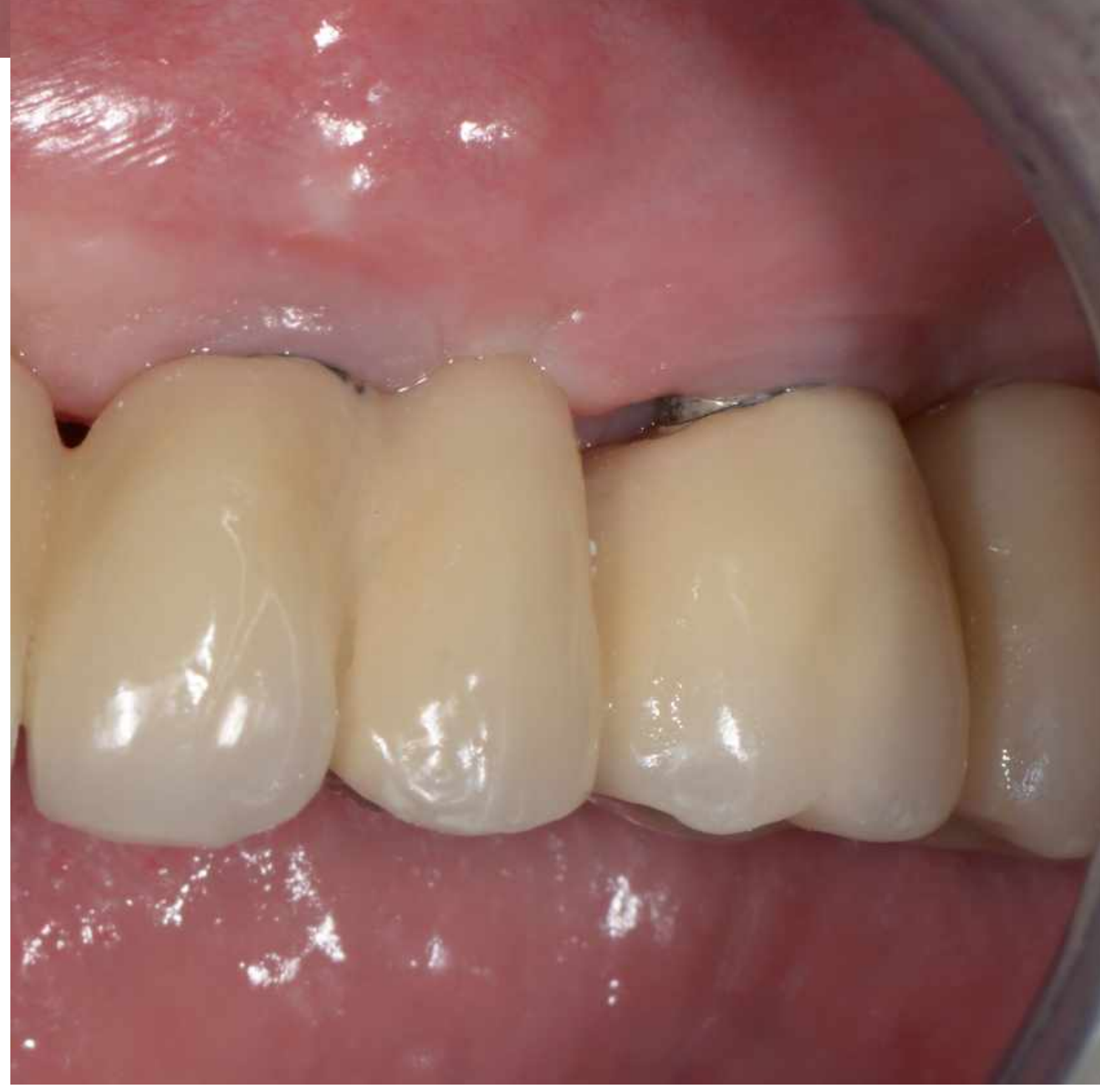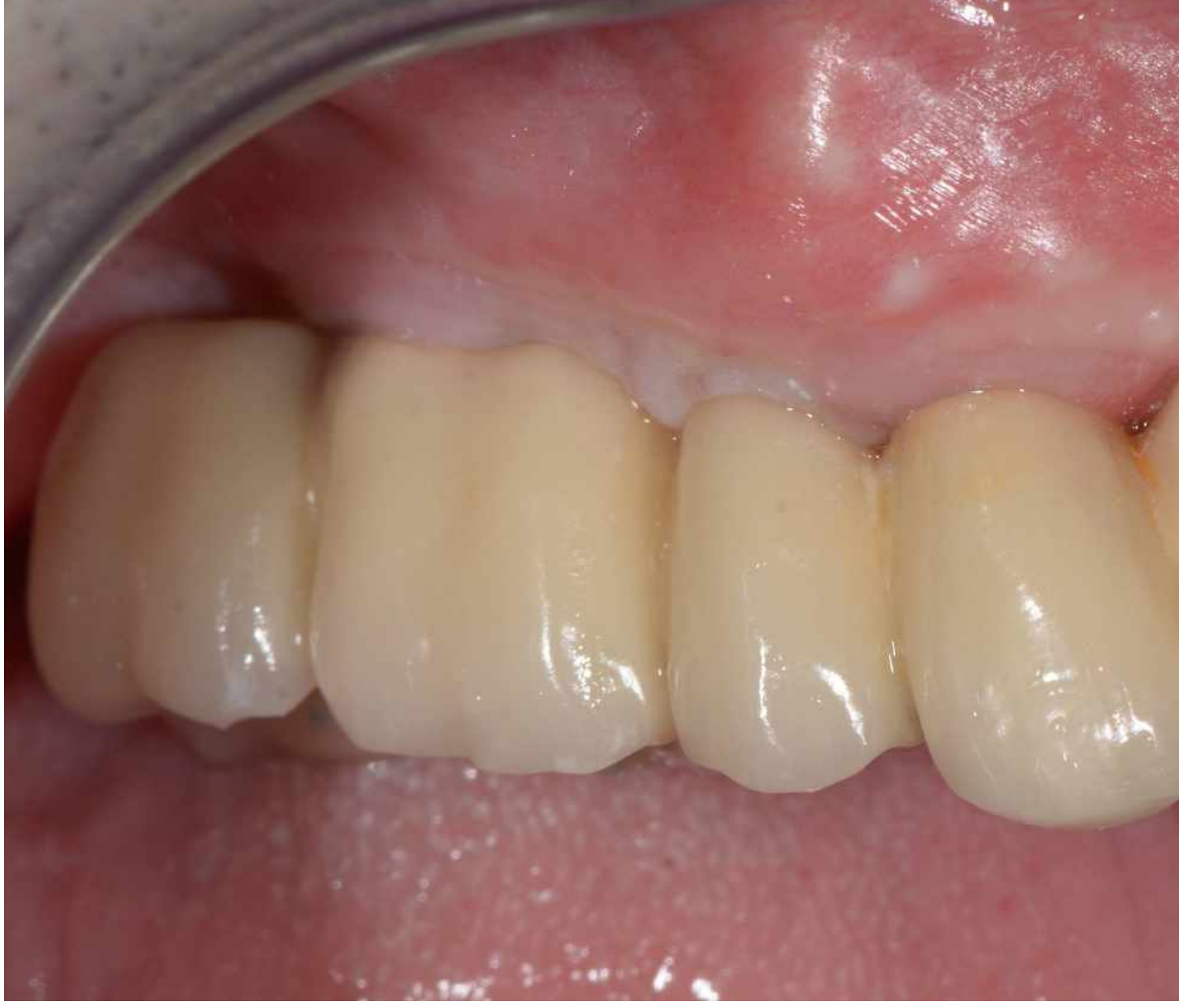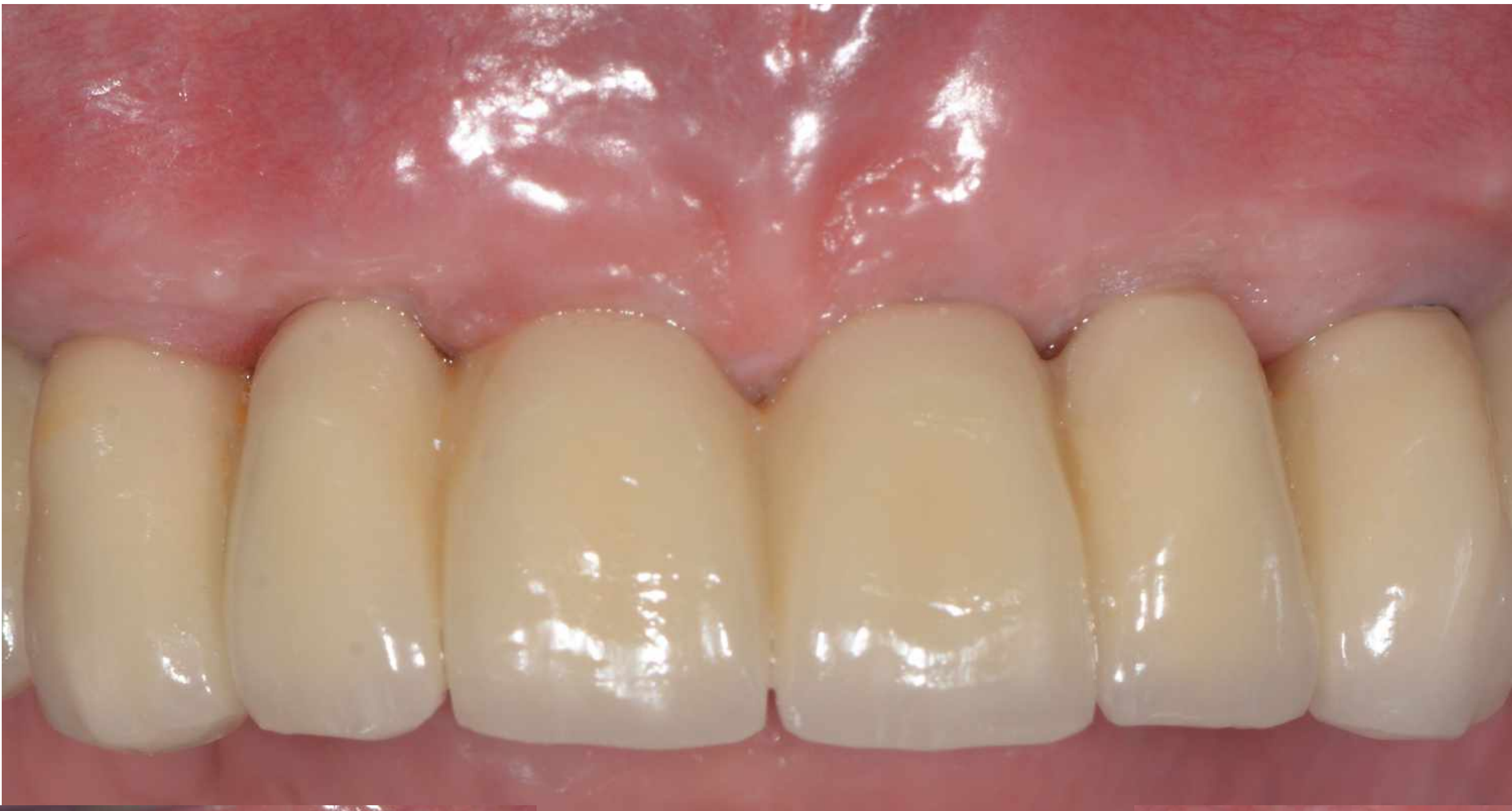Implants Angulés



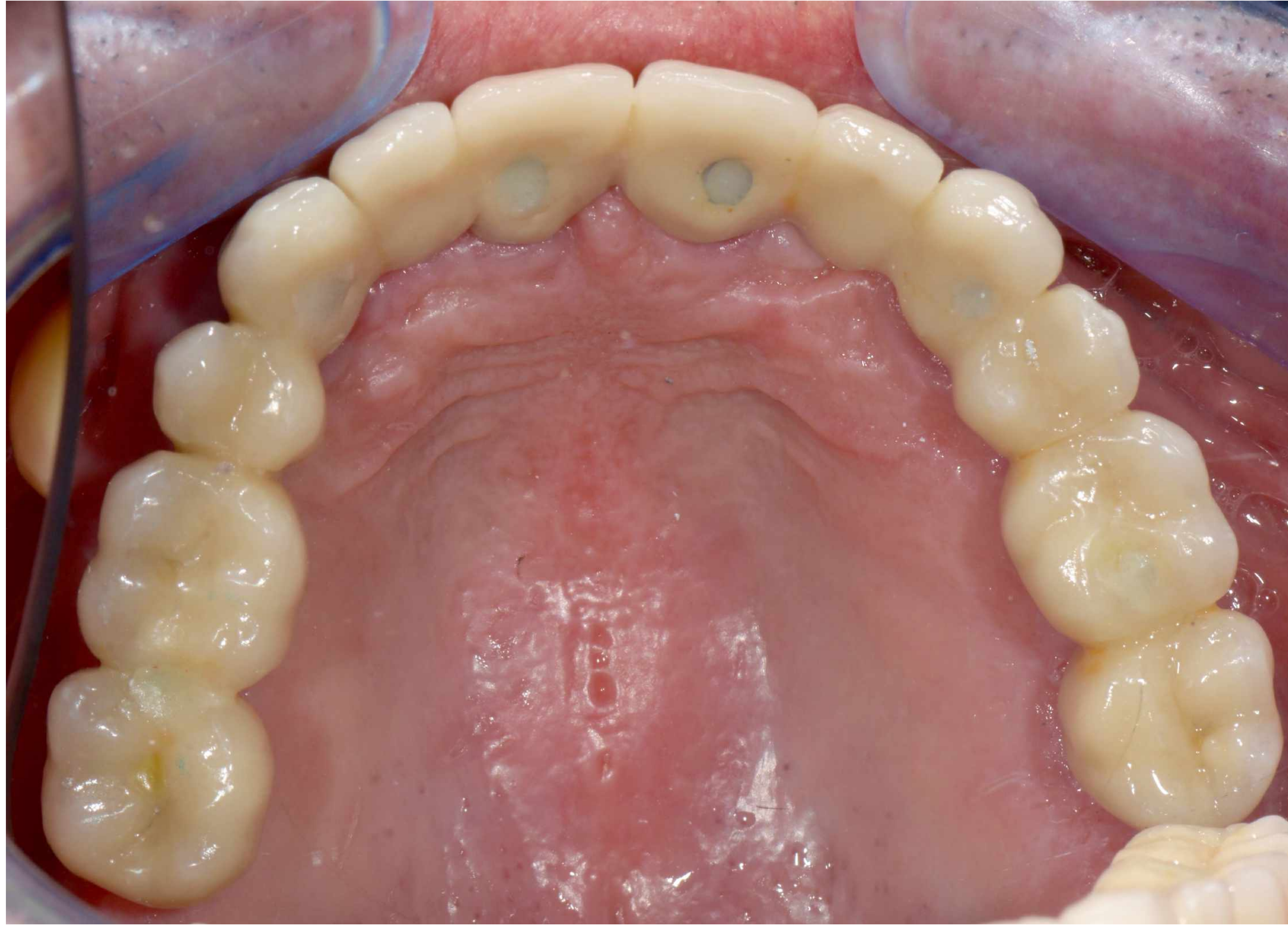
Implants Angulés

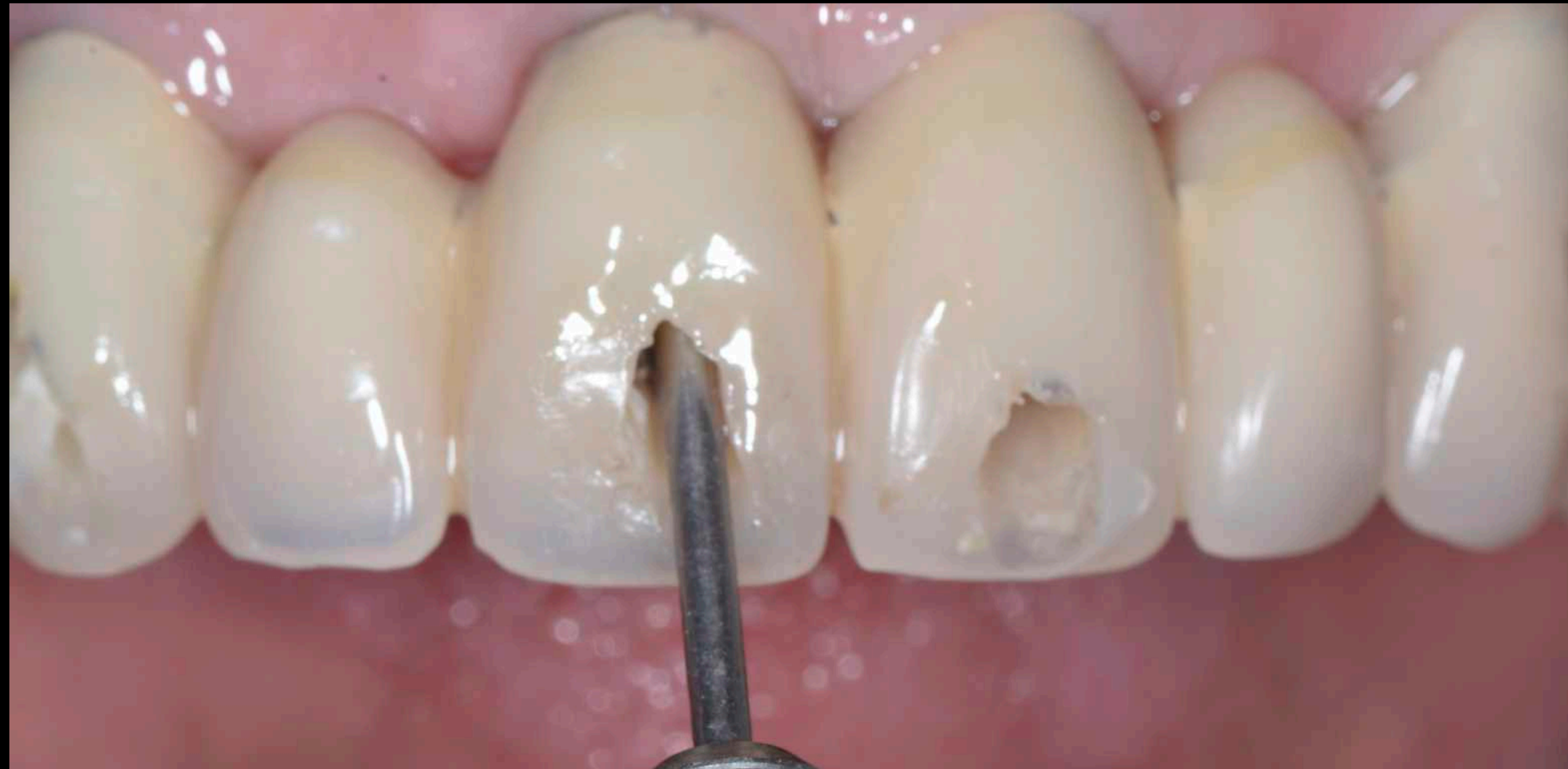
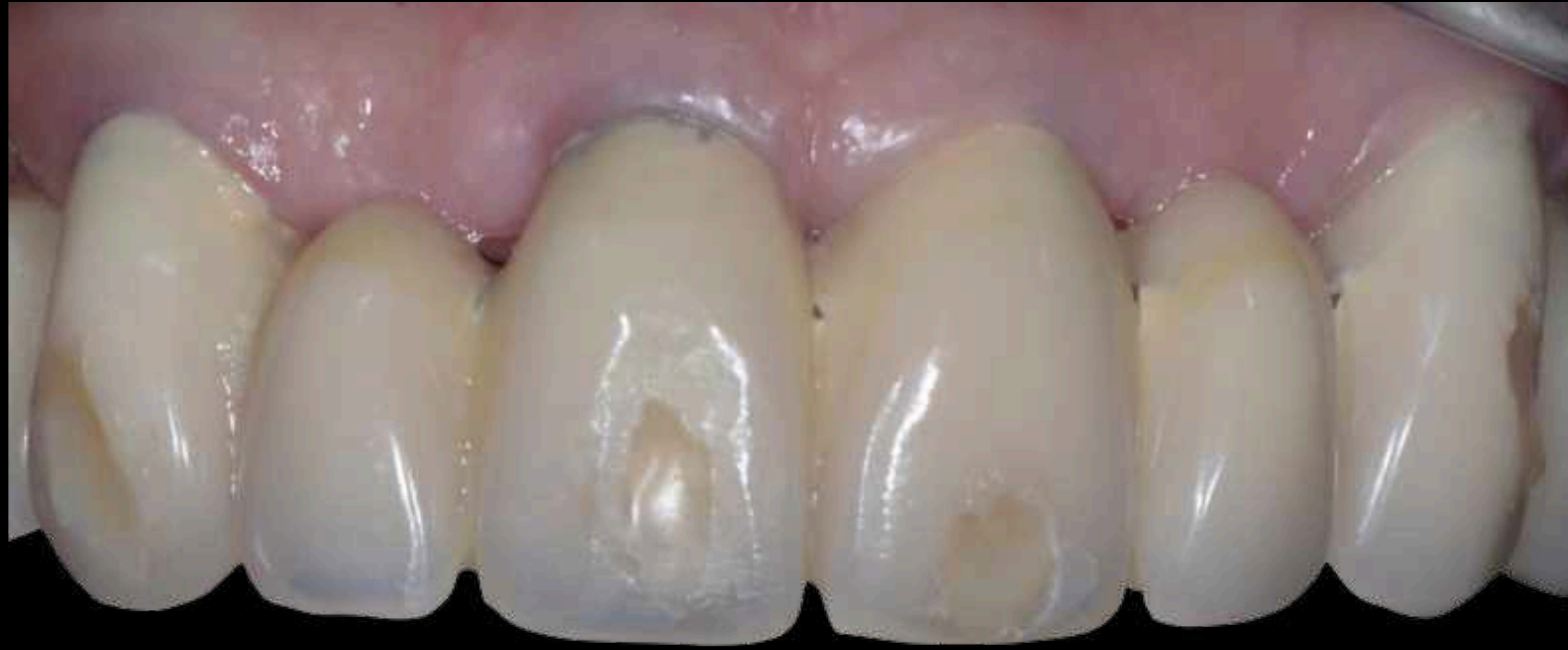
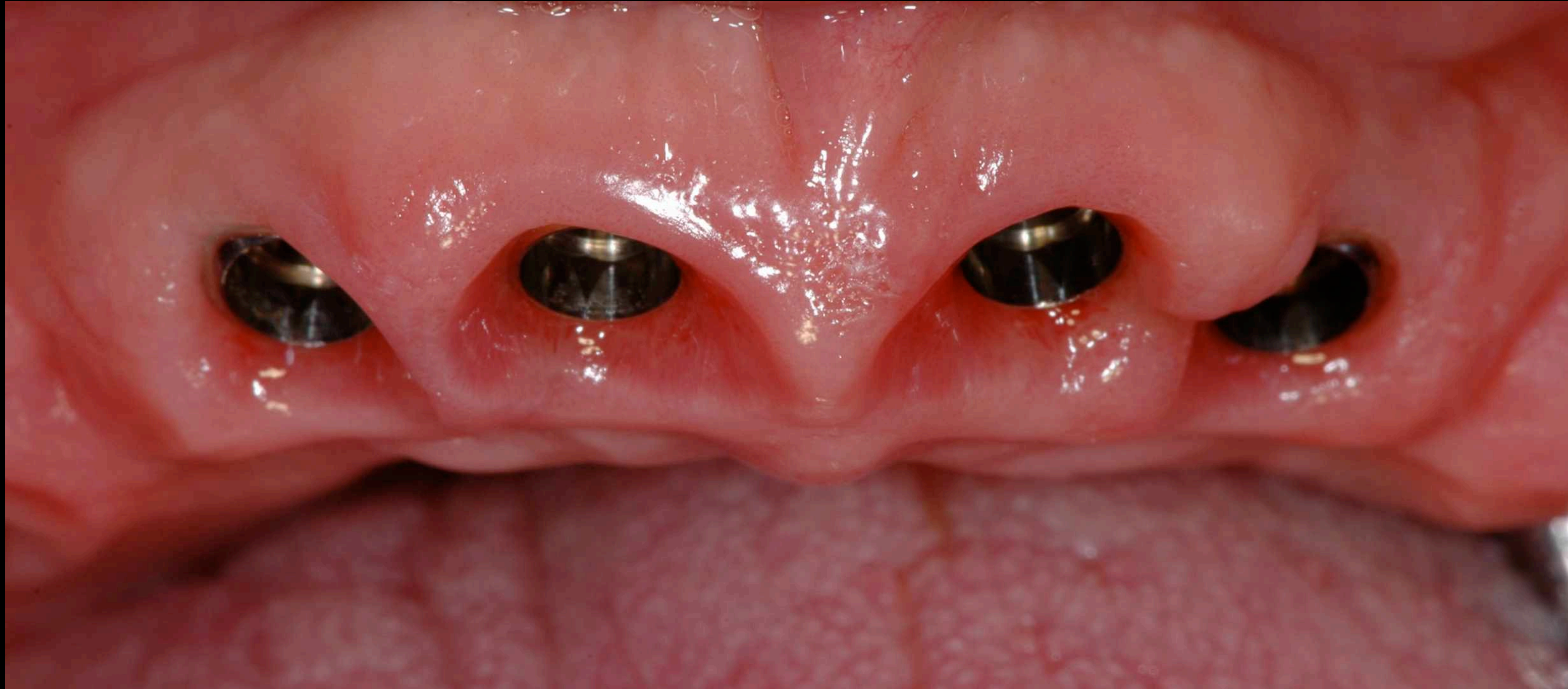
Implants Angulés

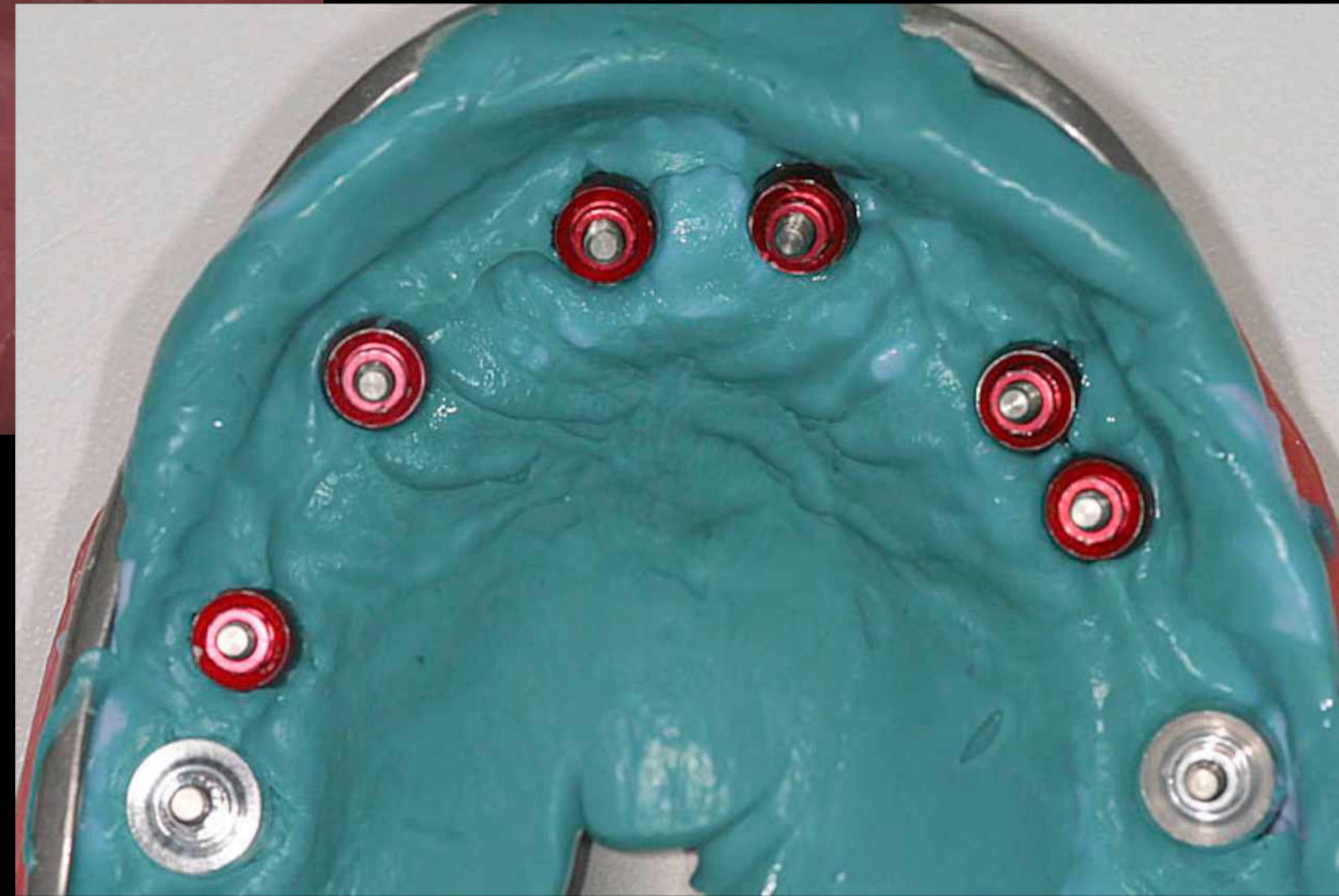
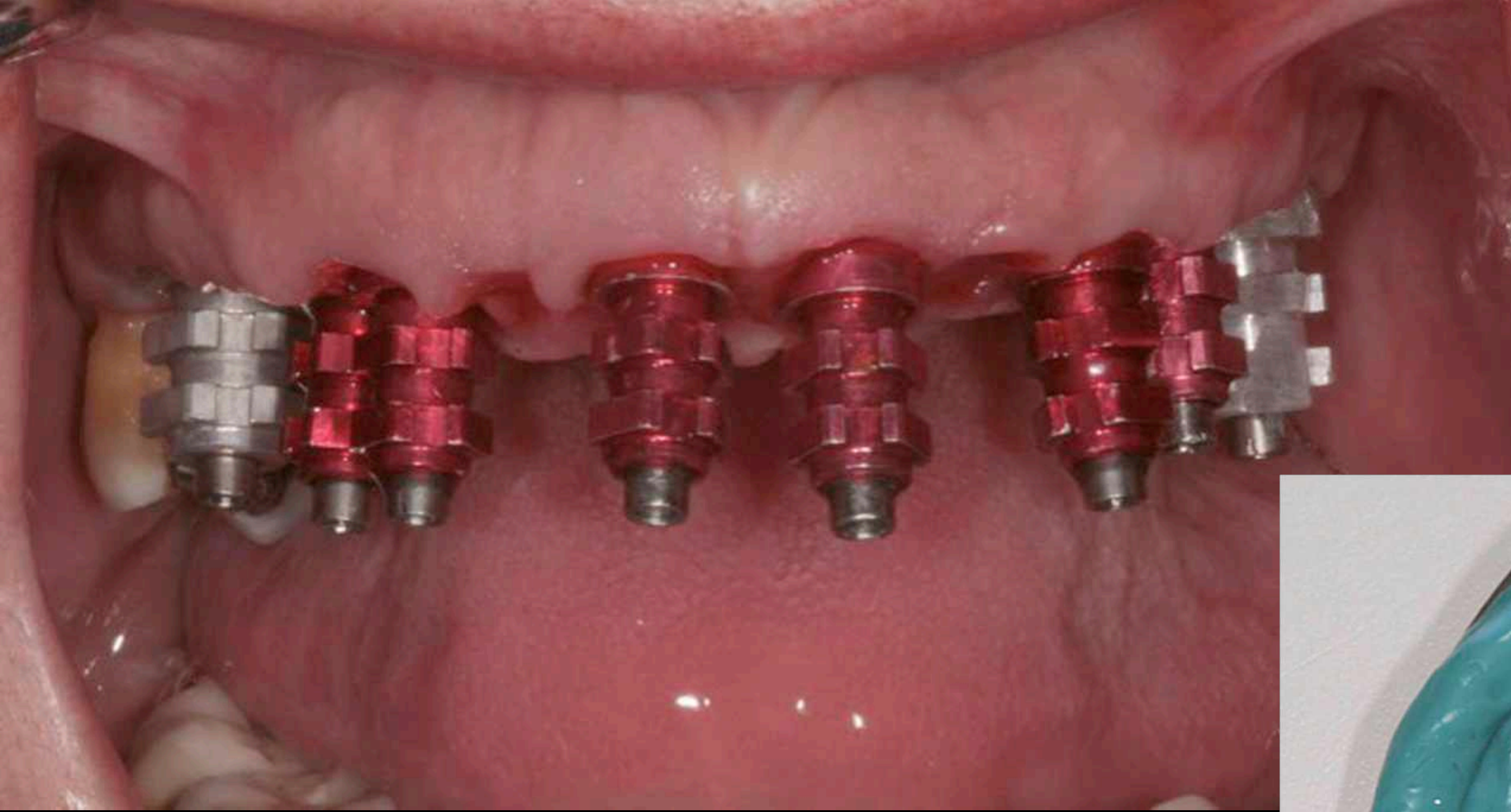



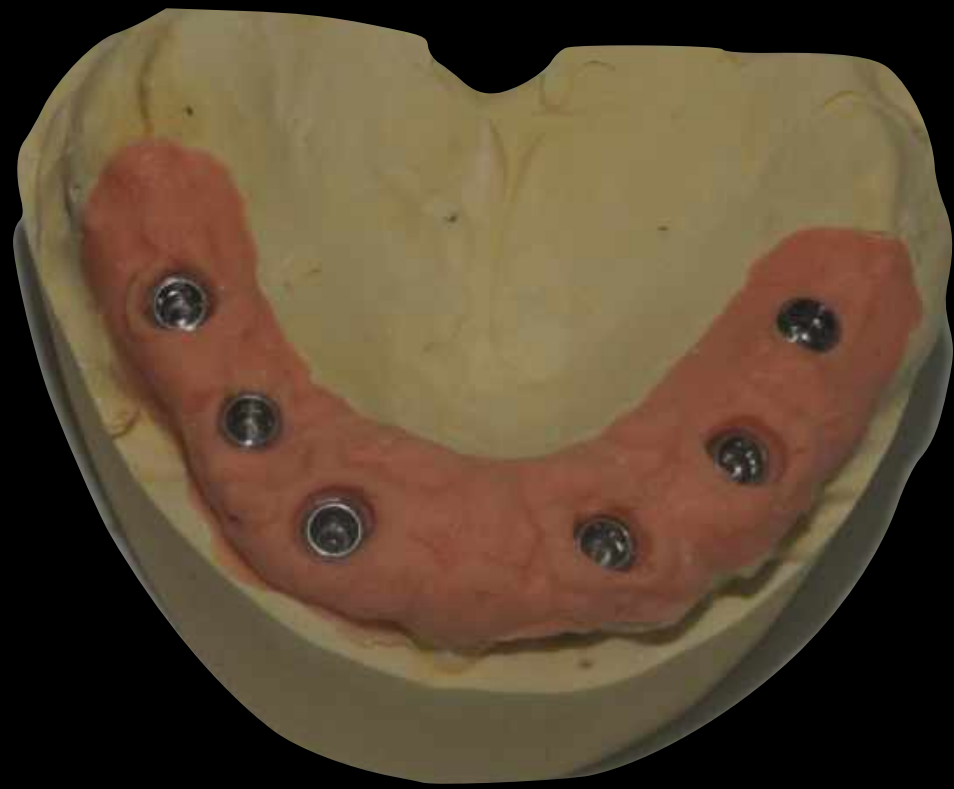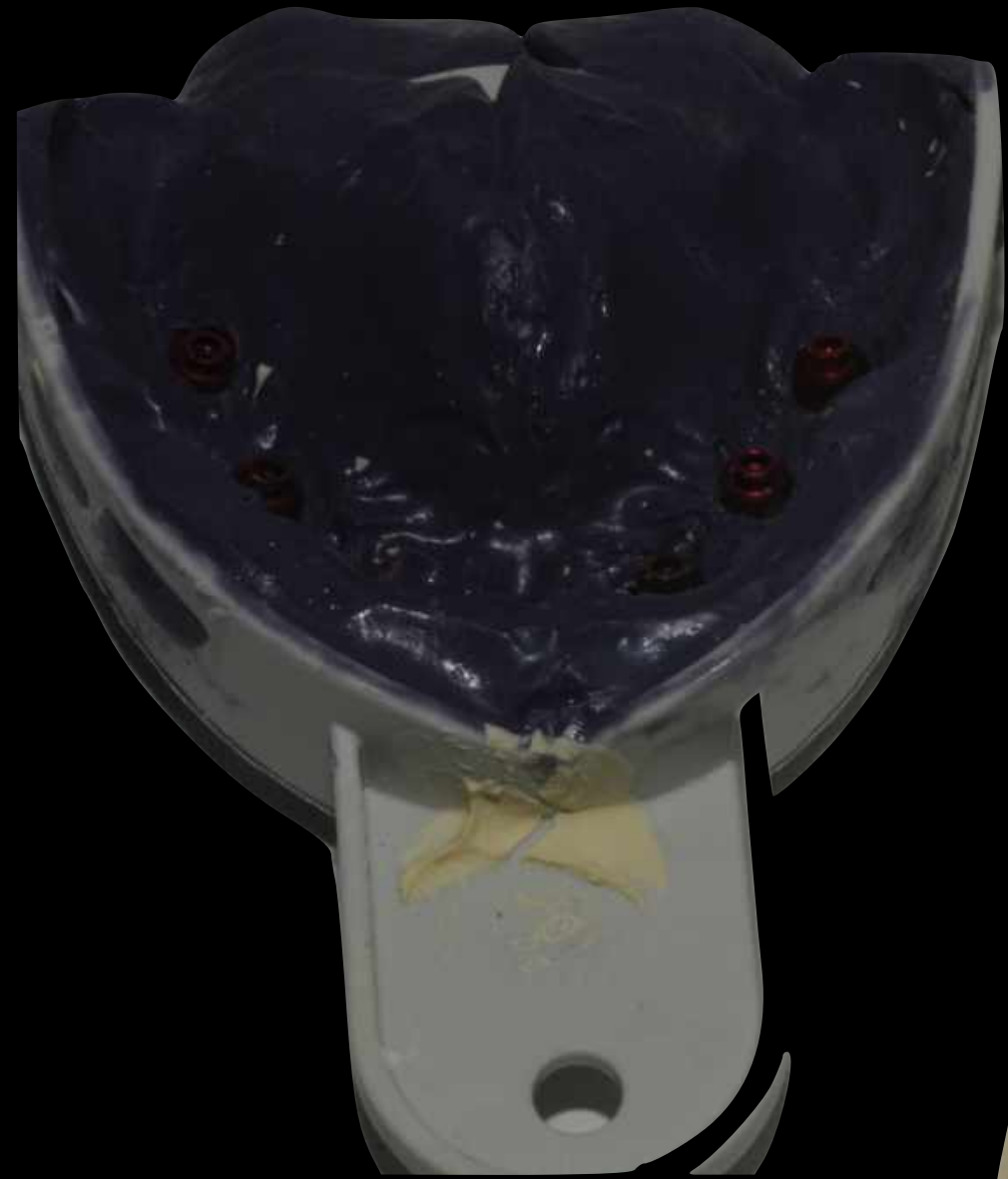
Implants Angulés

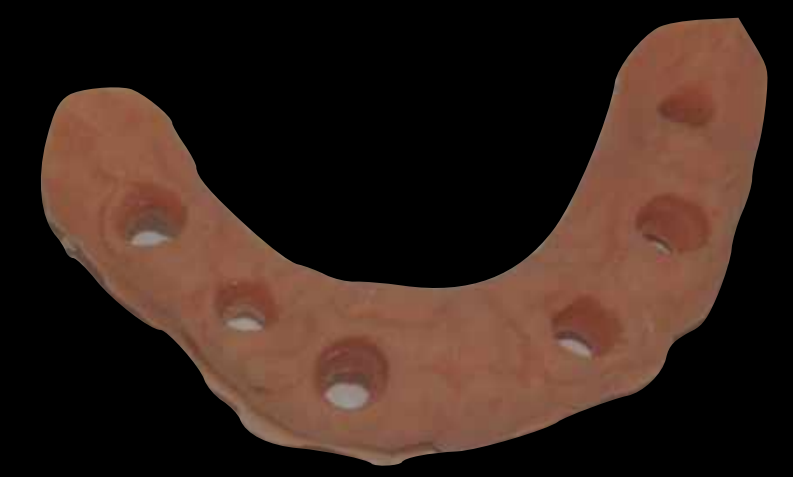
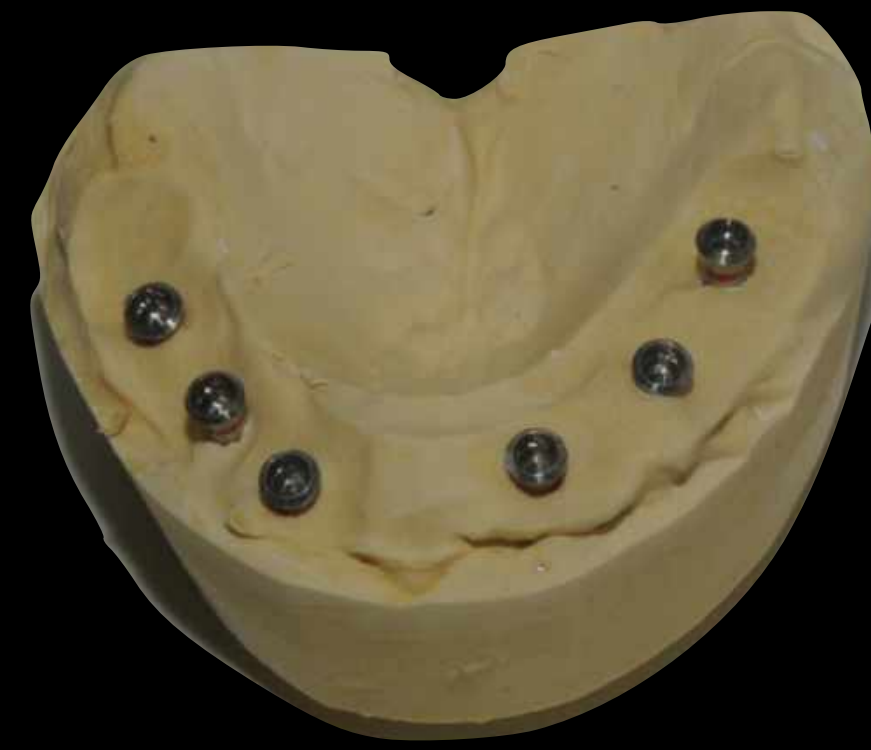

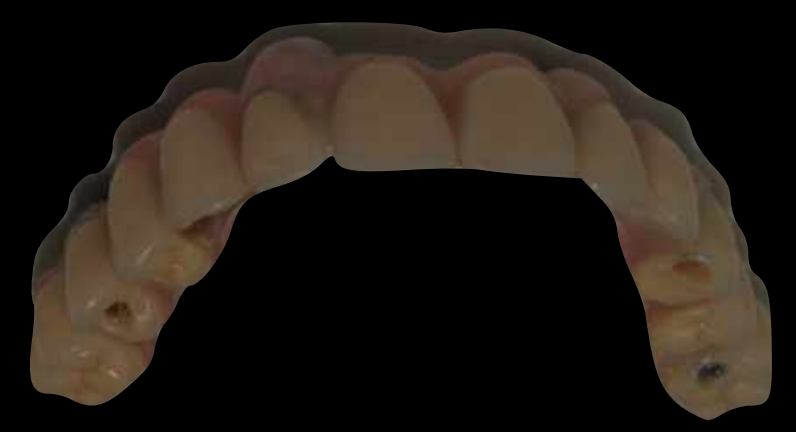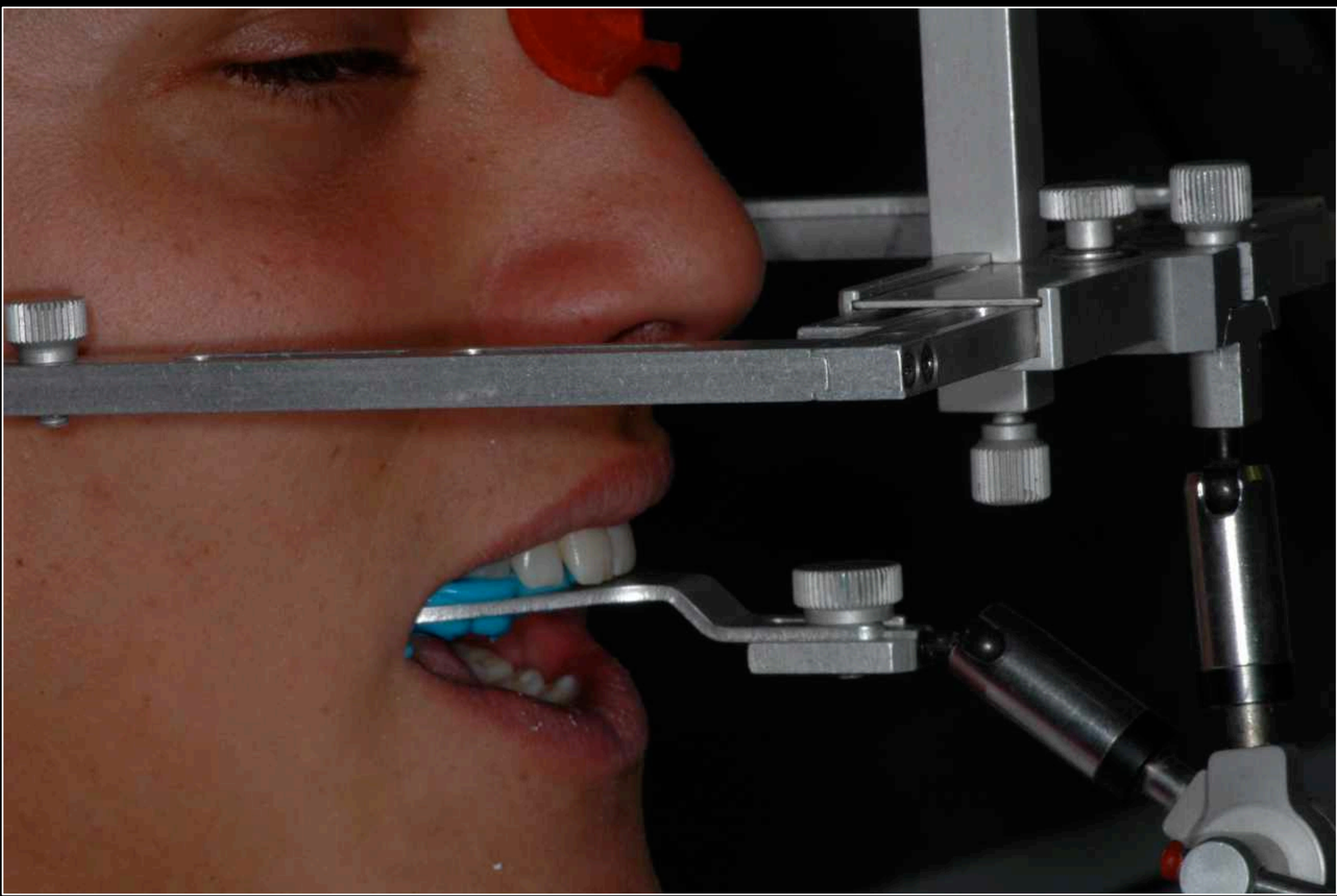


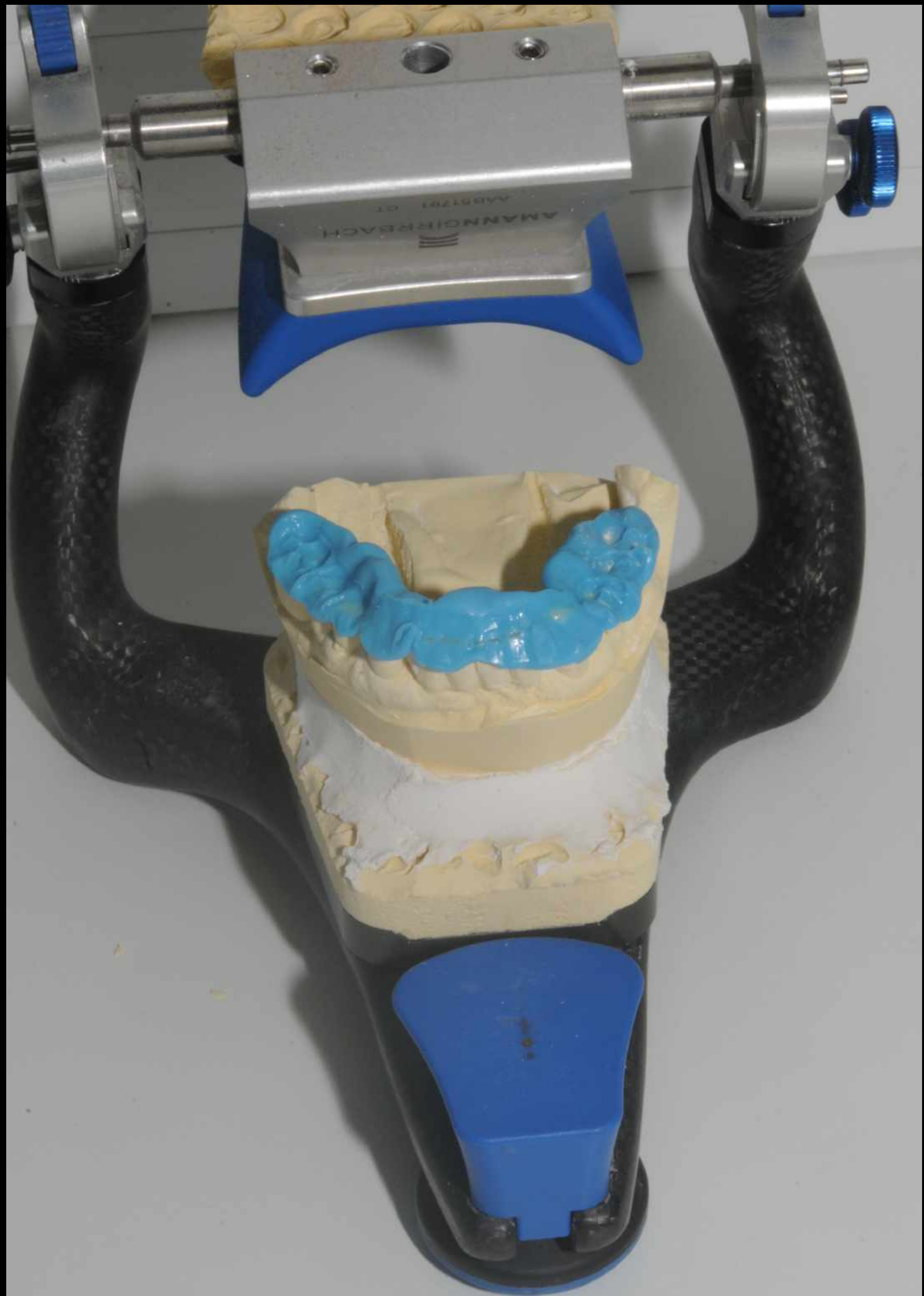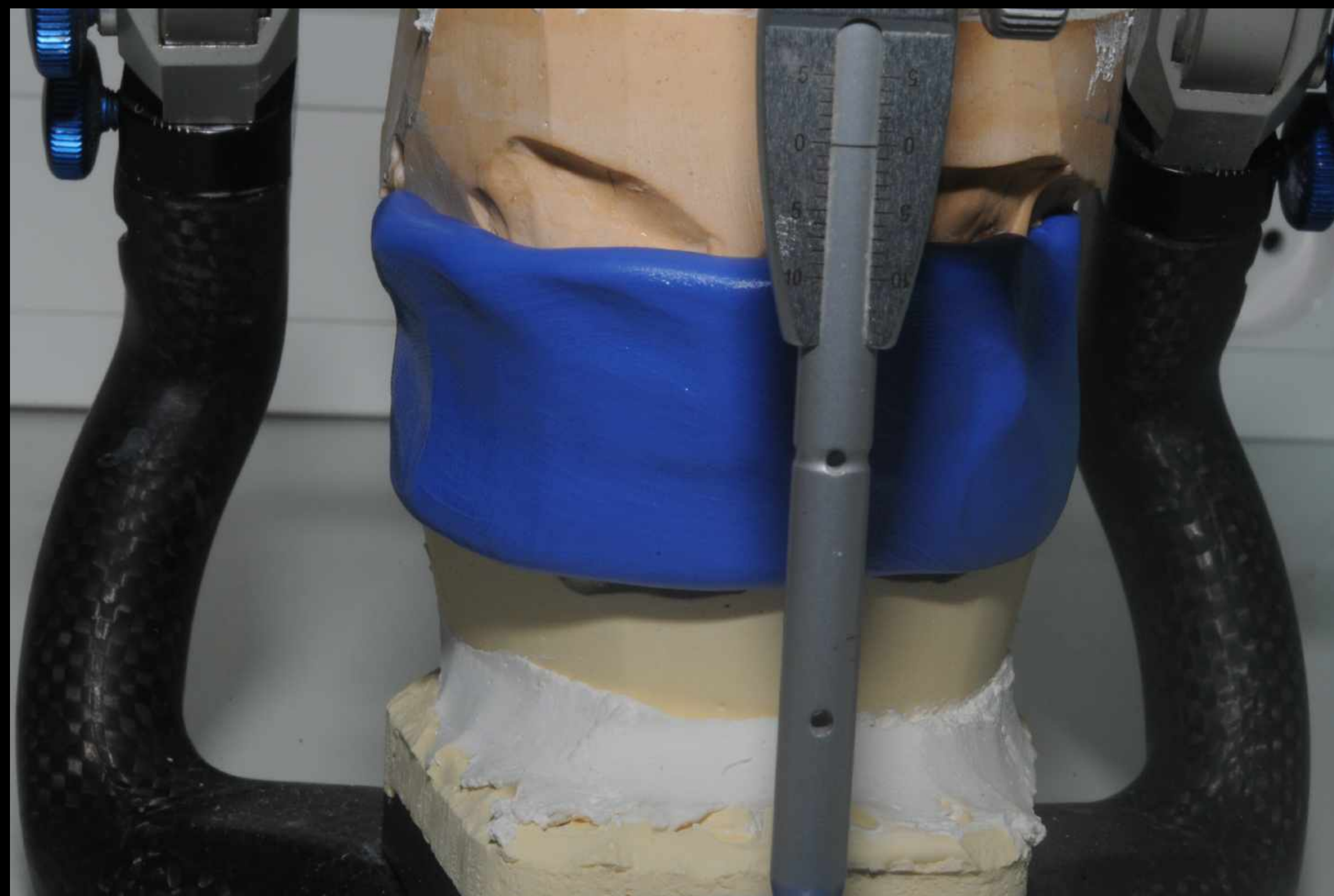
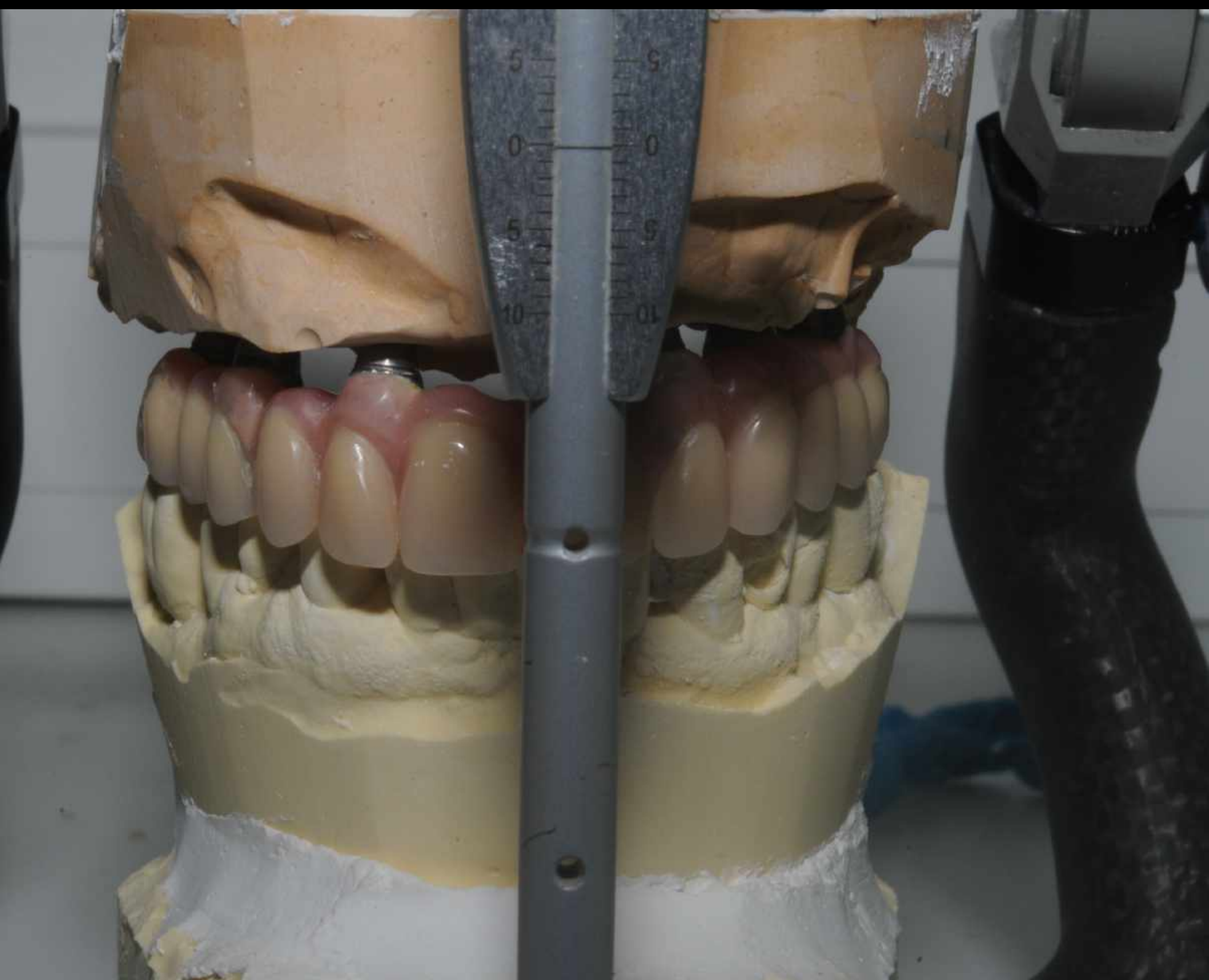


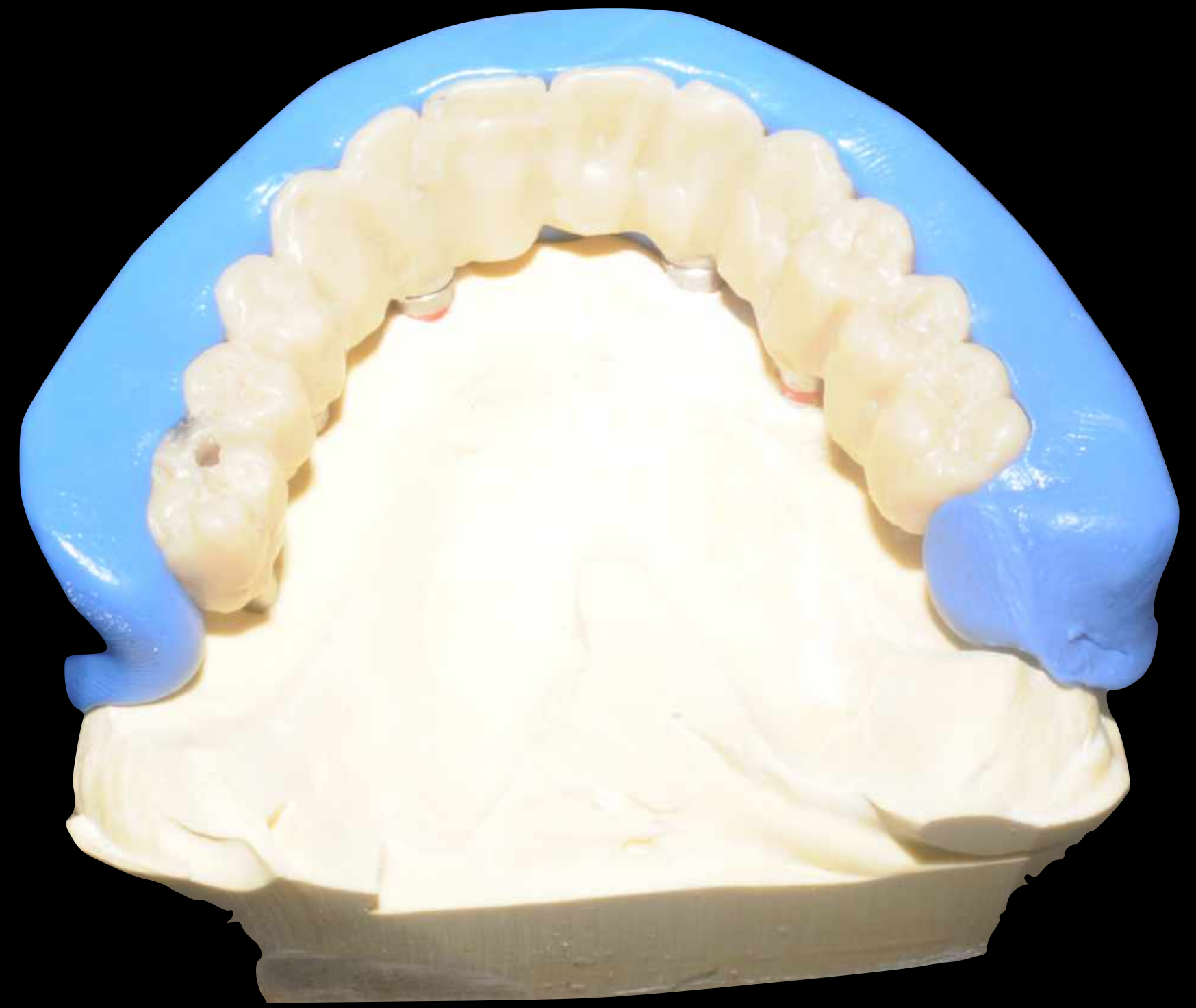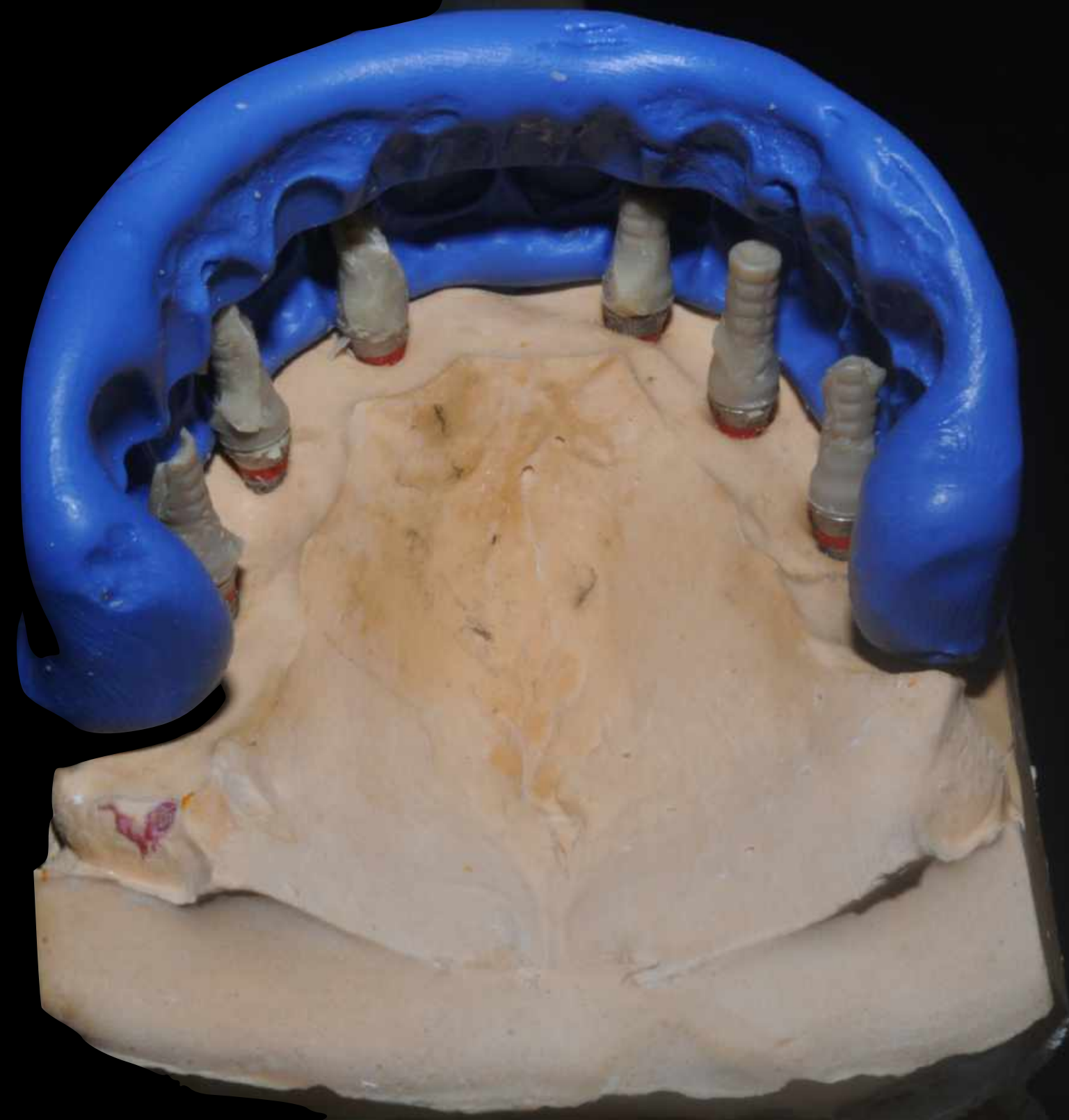


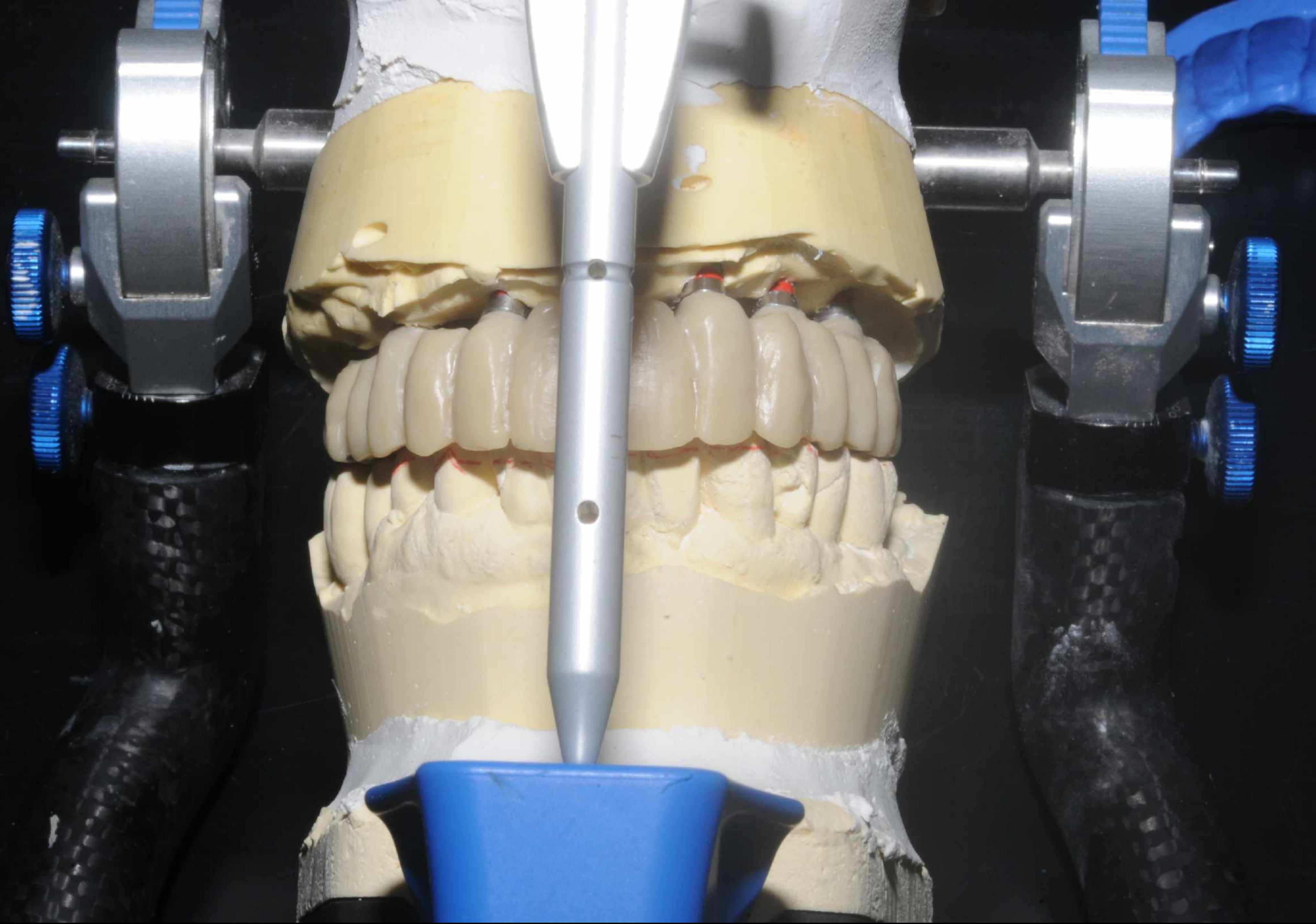

















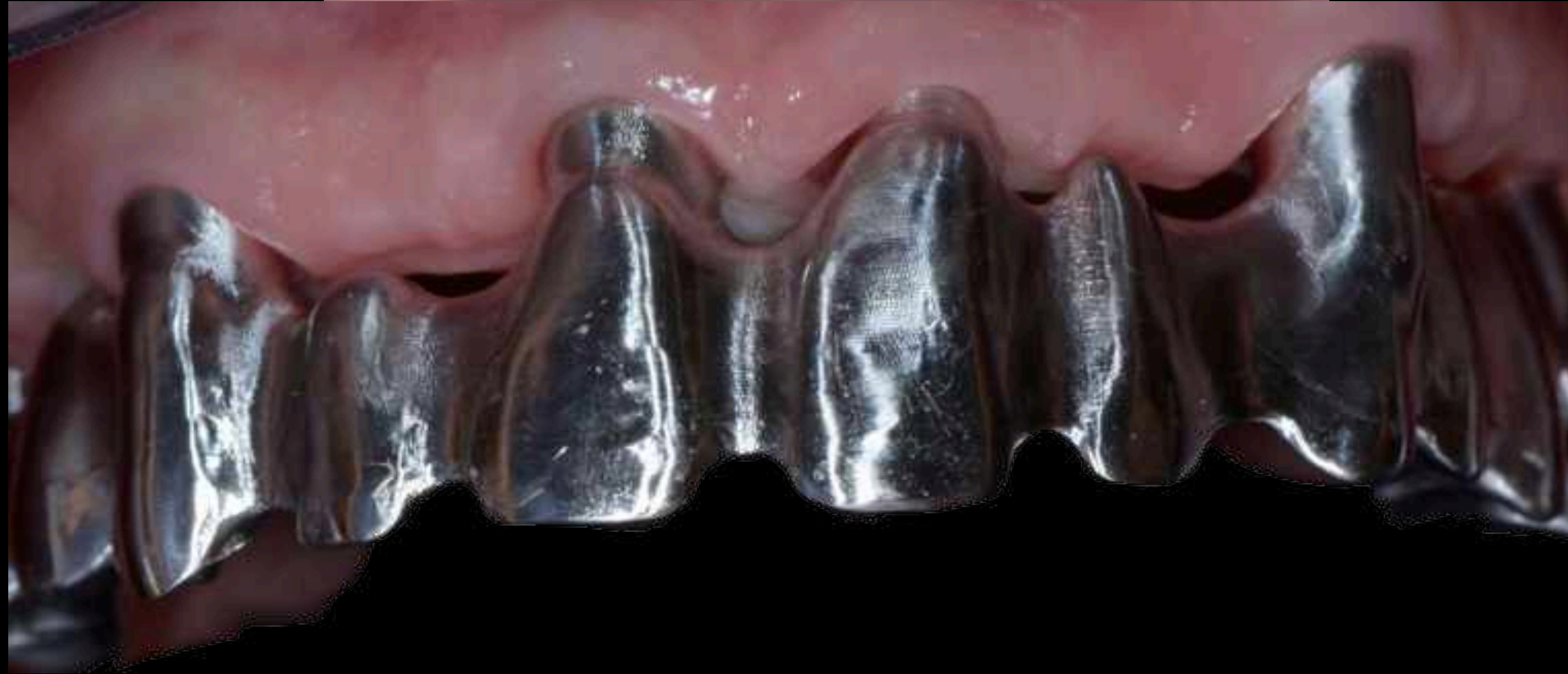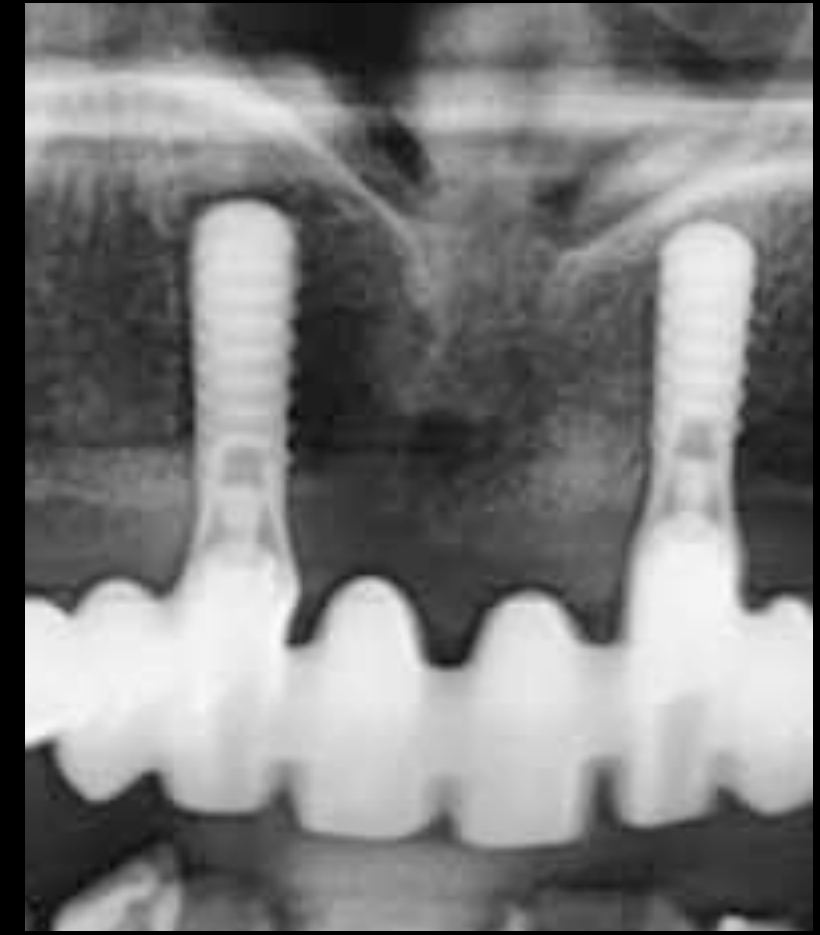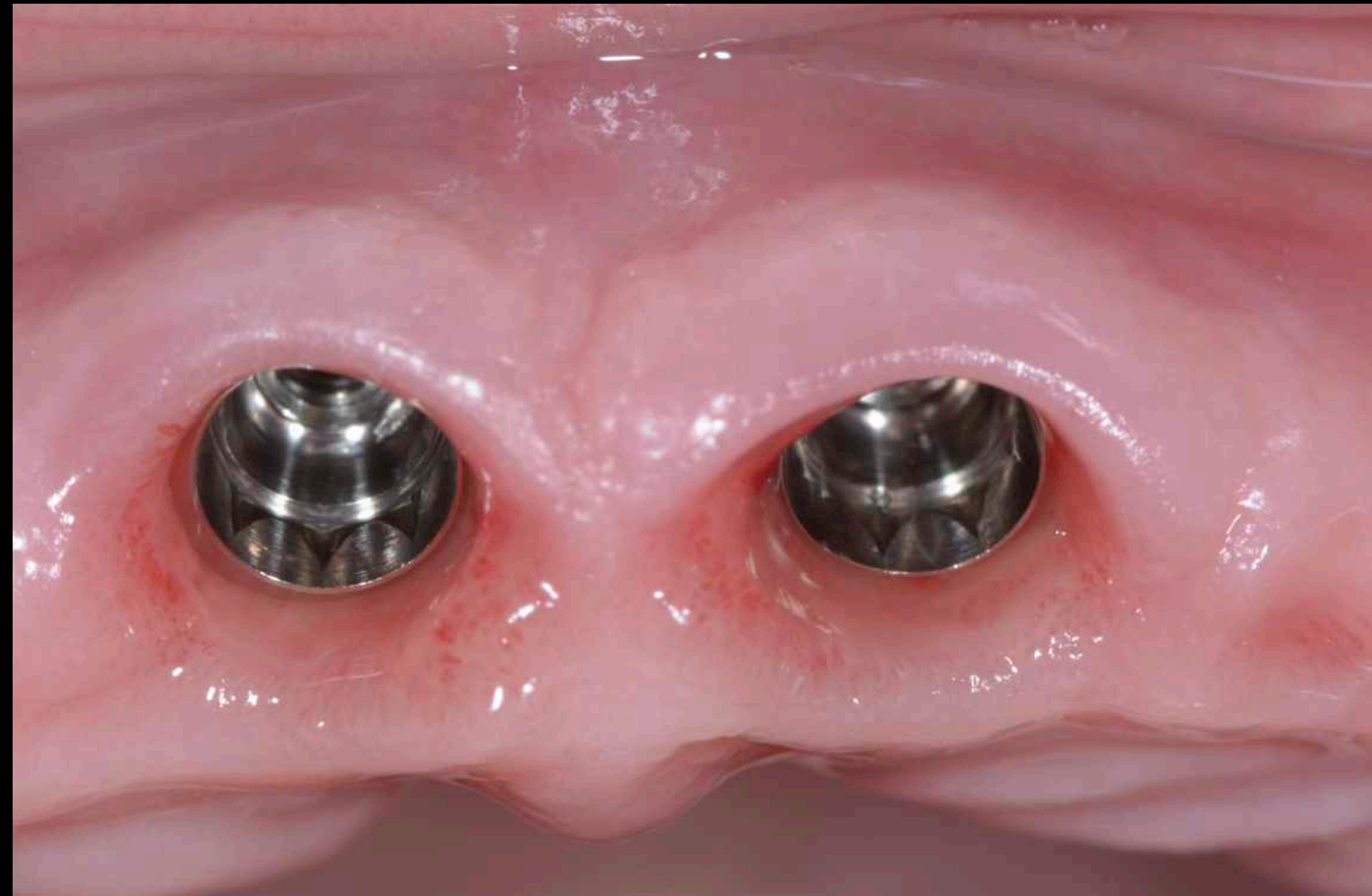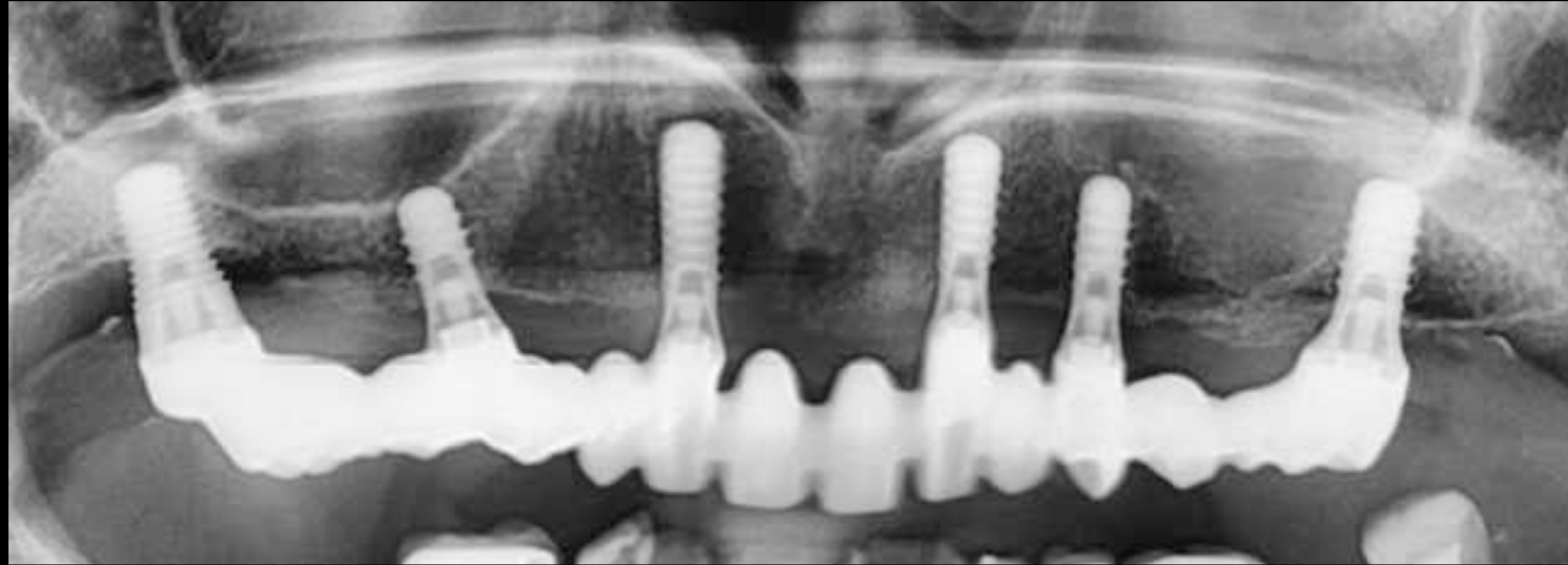


createch
SERVICE

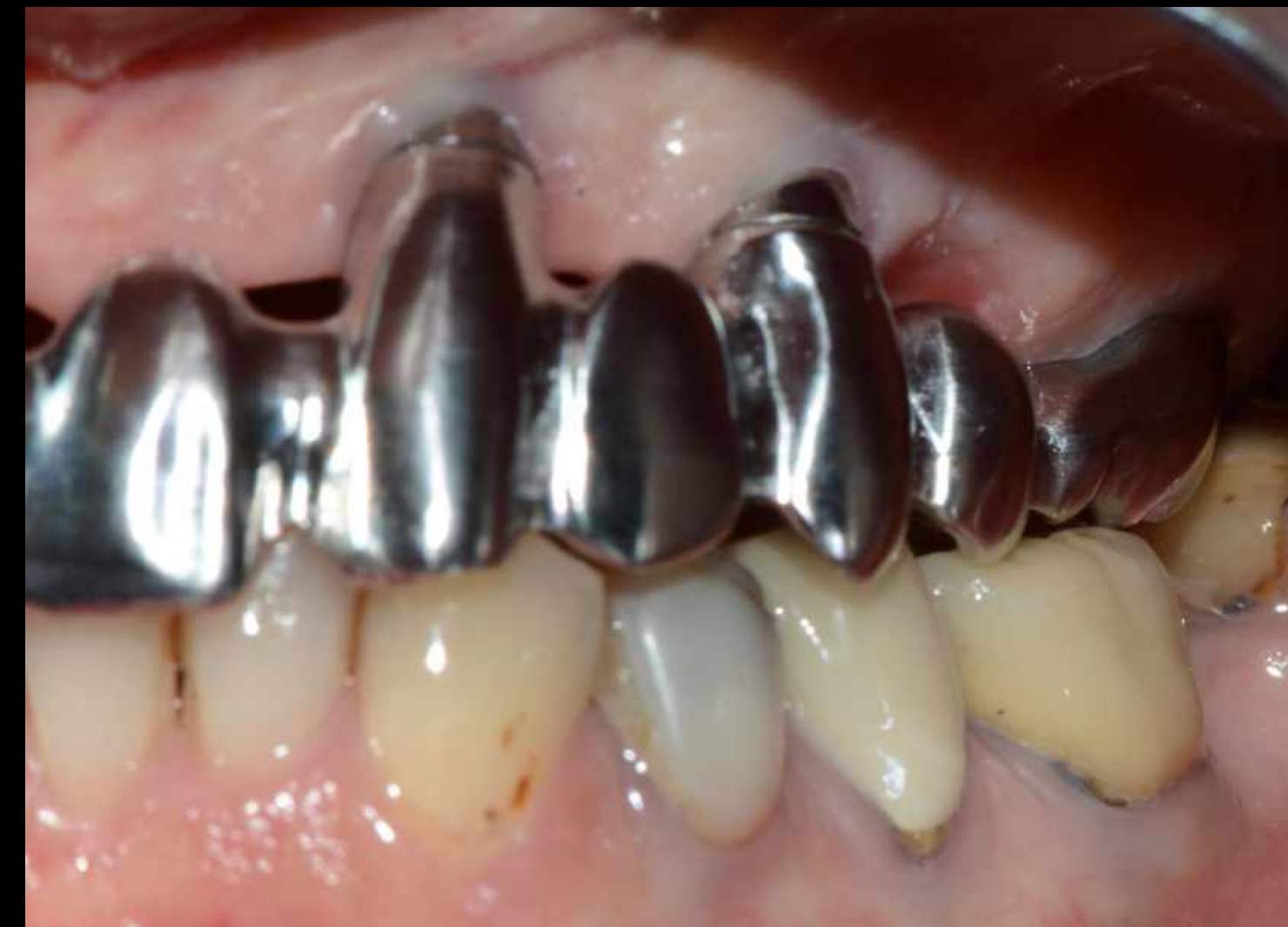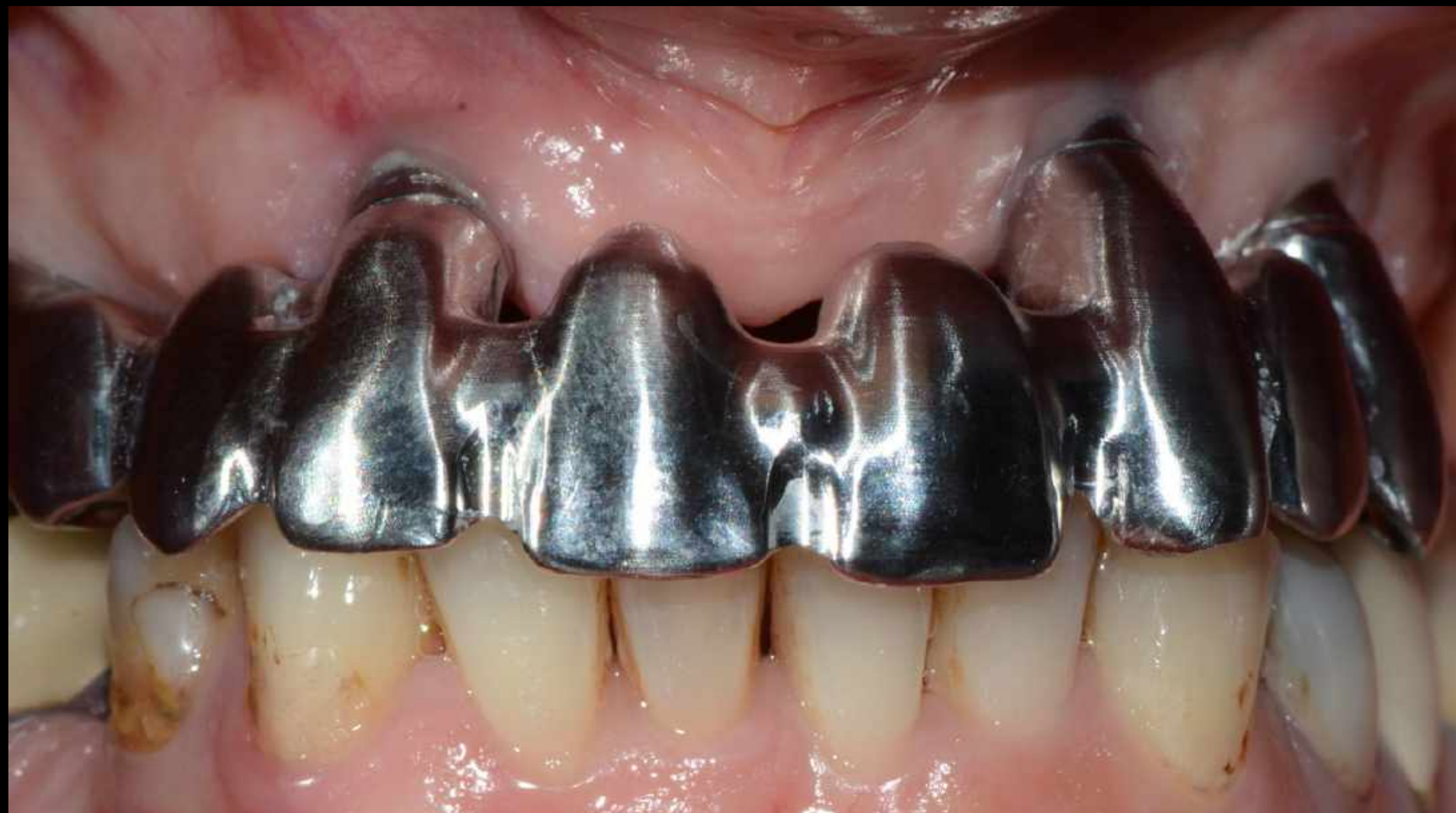ĐÀ LẠT - QUẢNG TRUNG



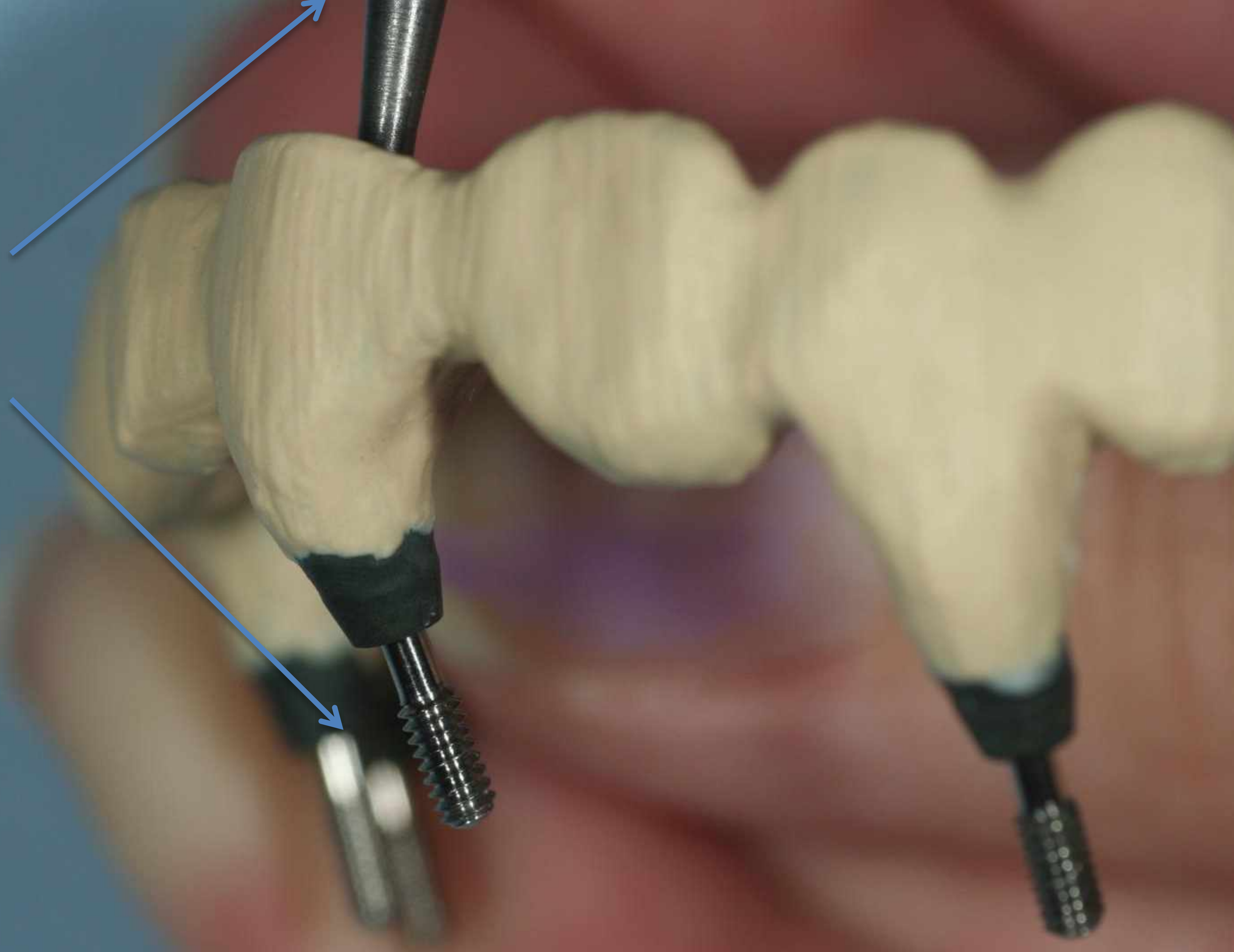




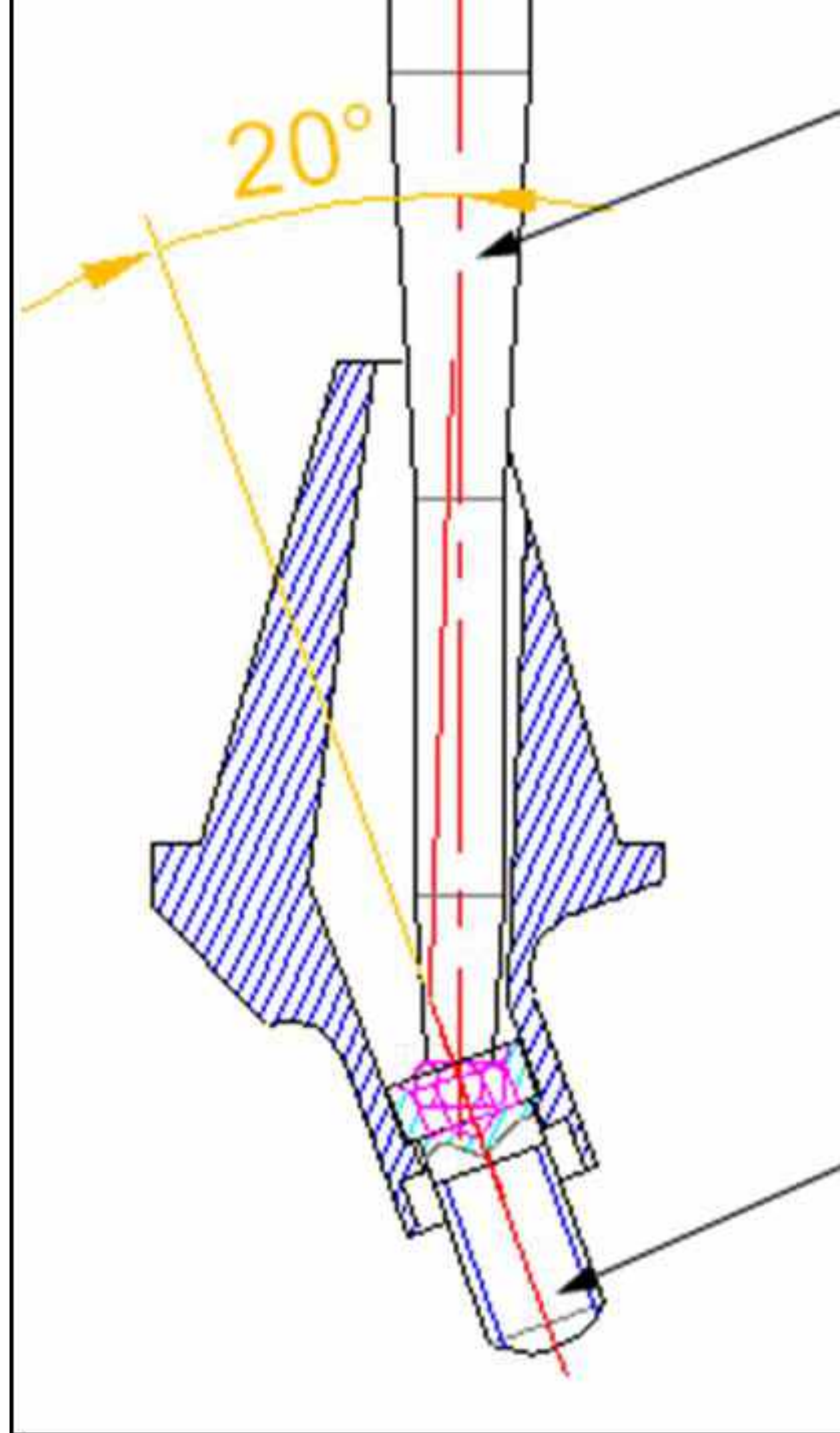
Panoramique de contrôle : verification de l'adaptation de l'armature

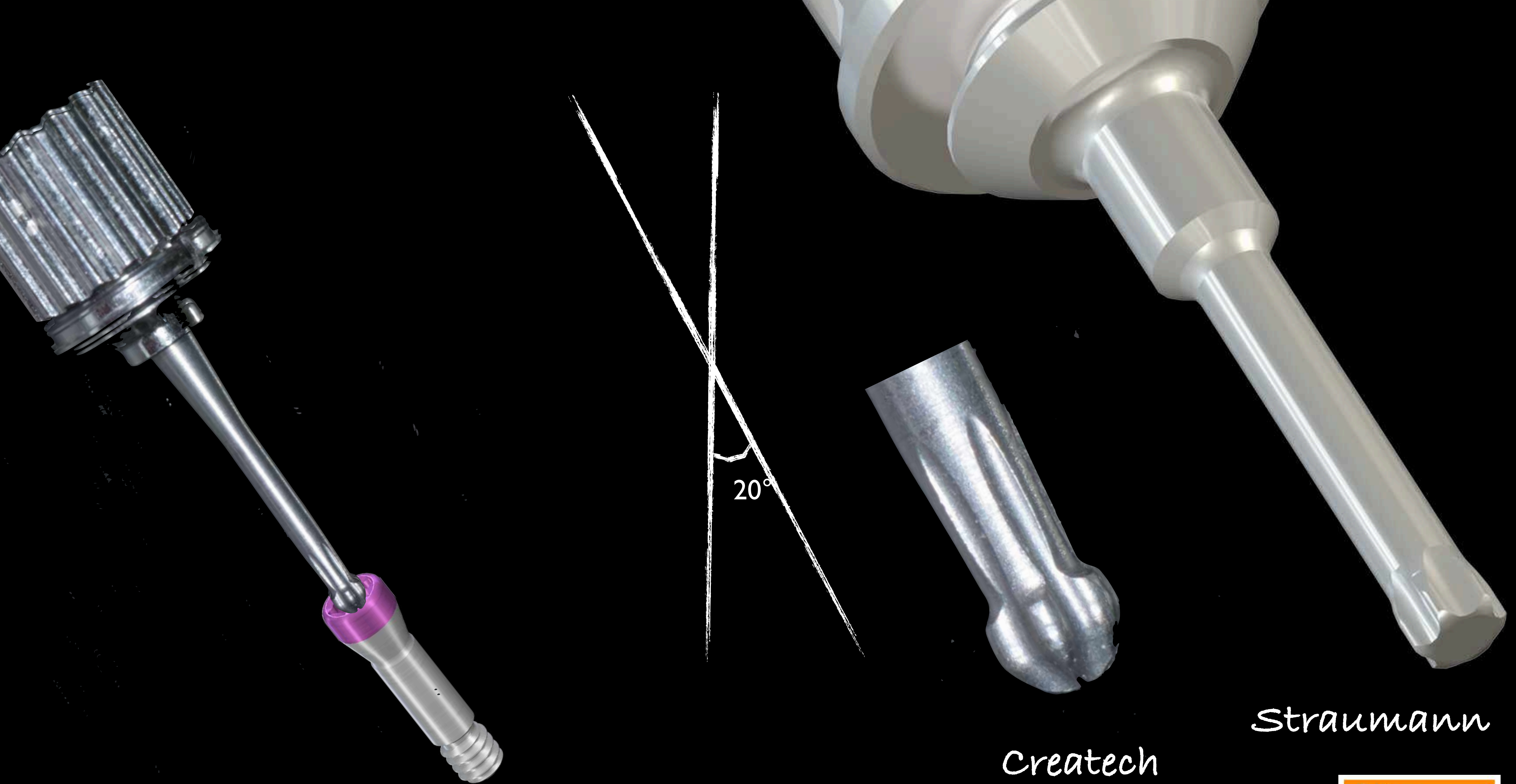


25 ° angulation



à vis au delà

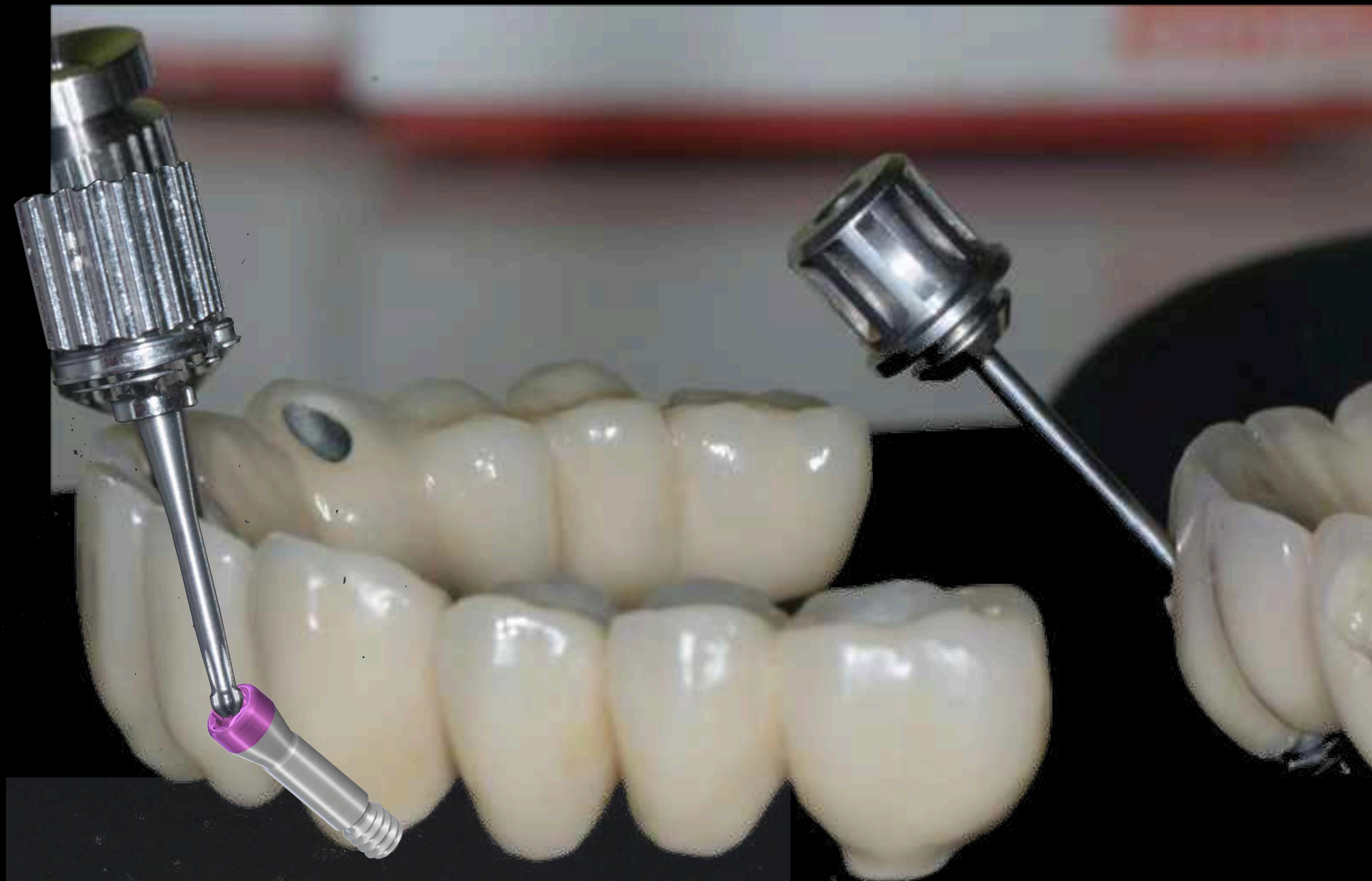


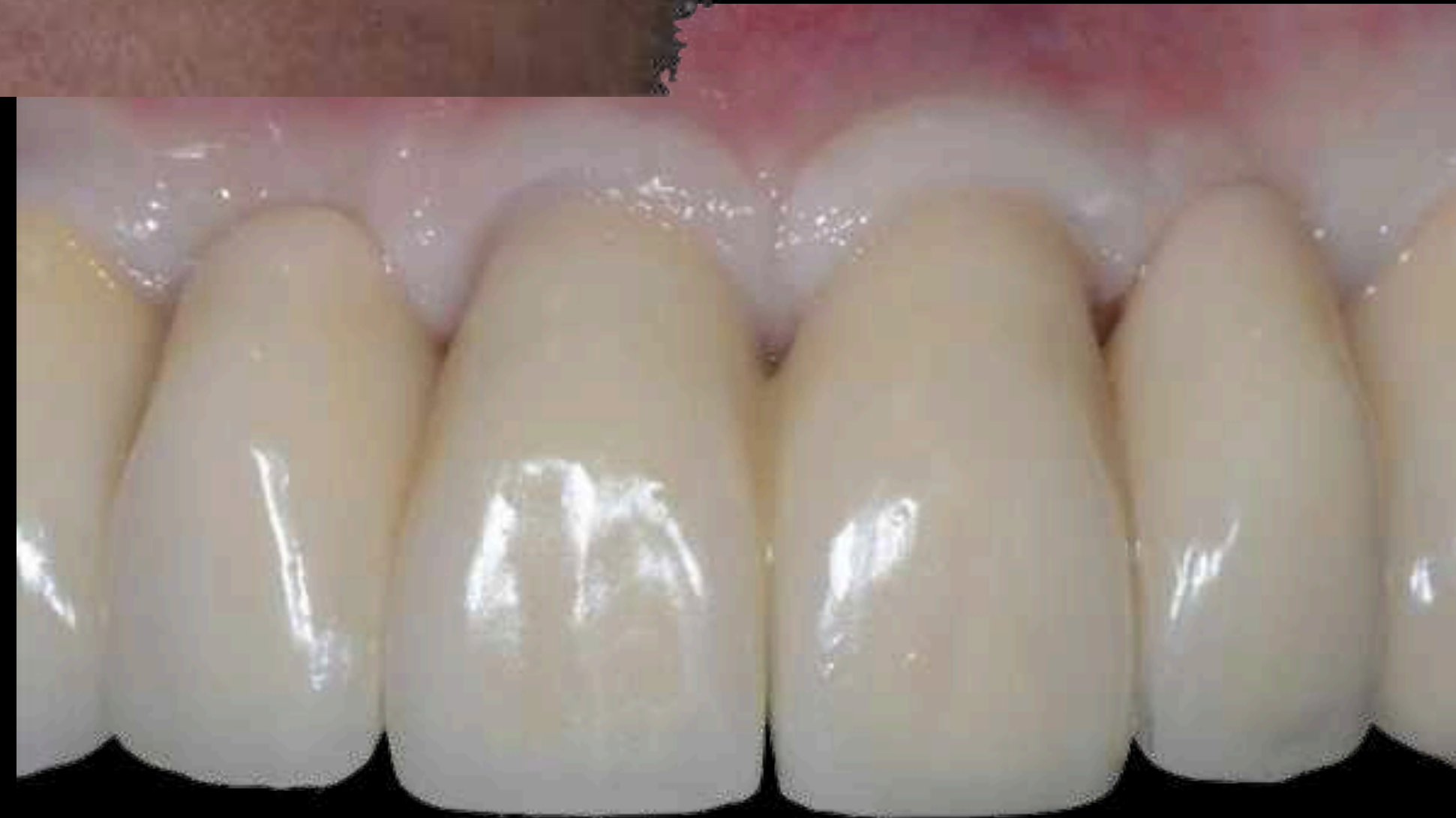
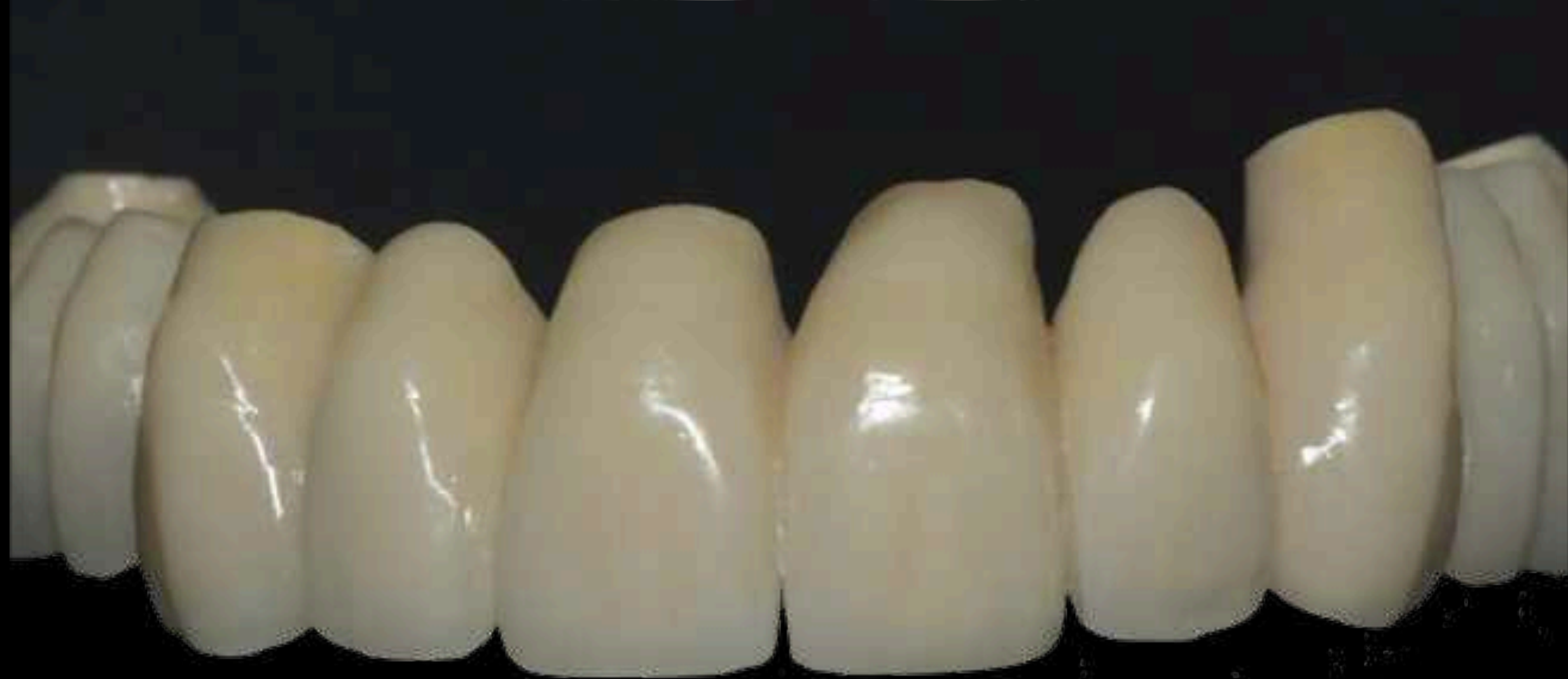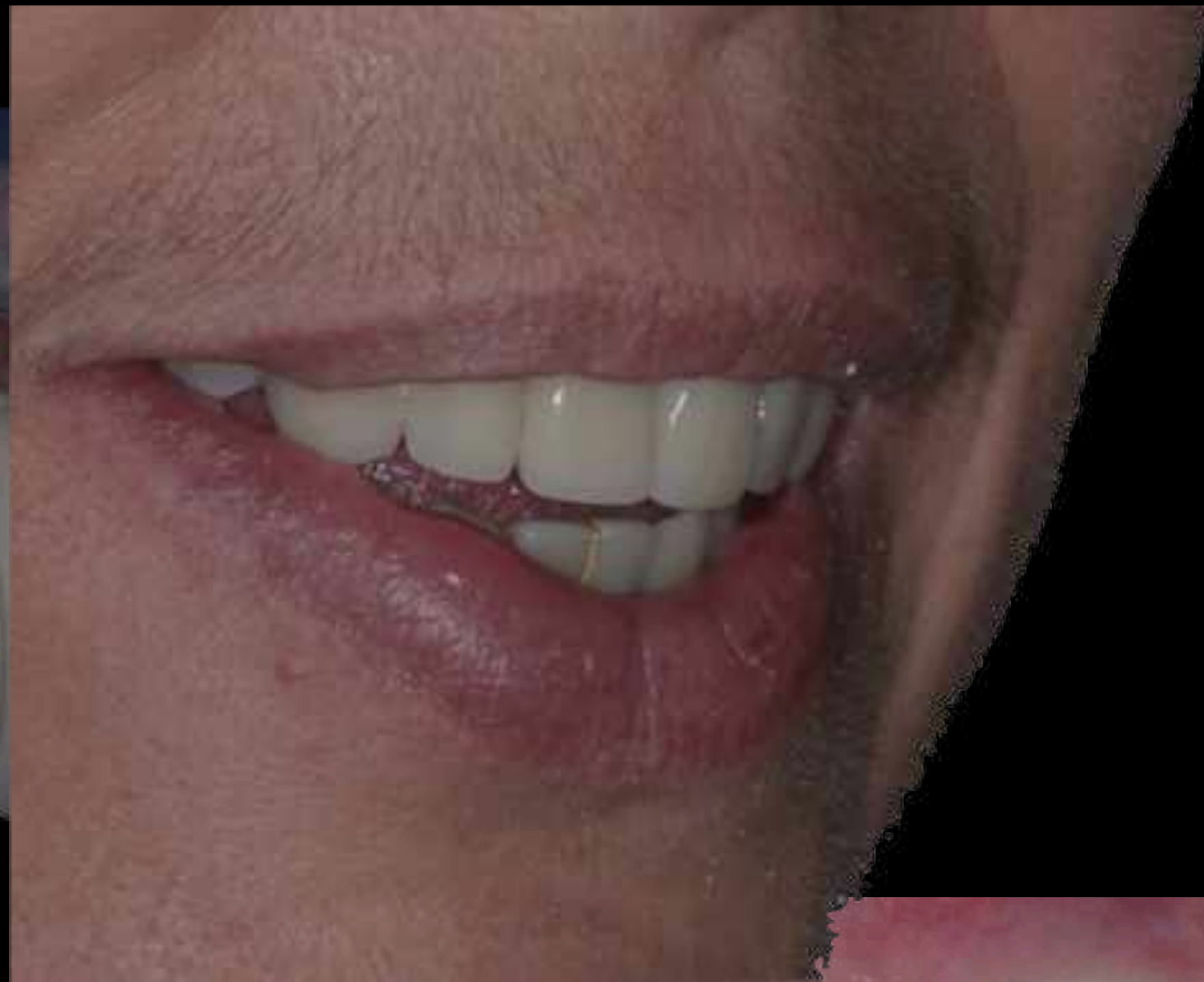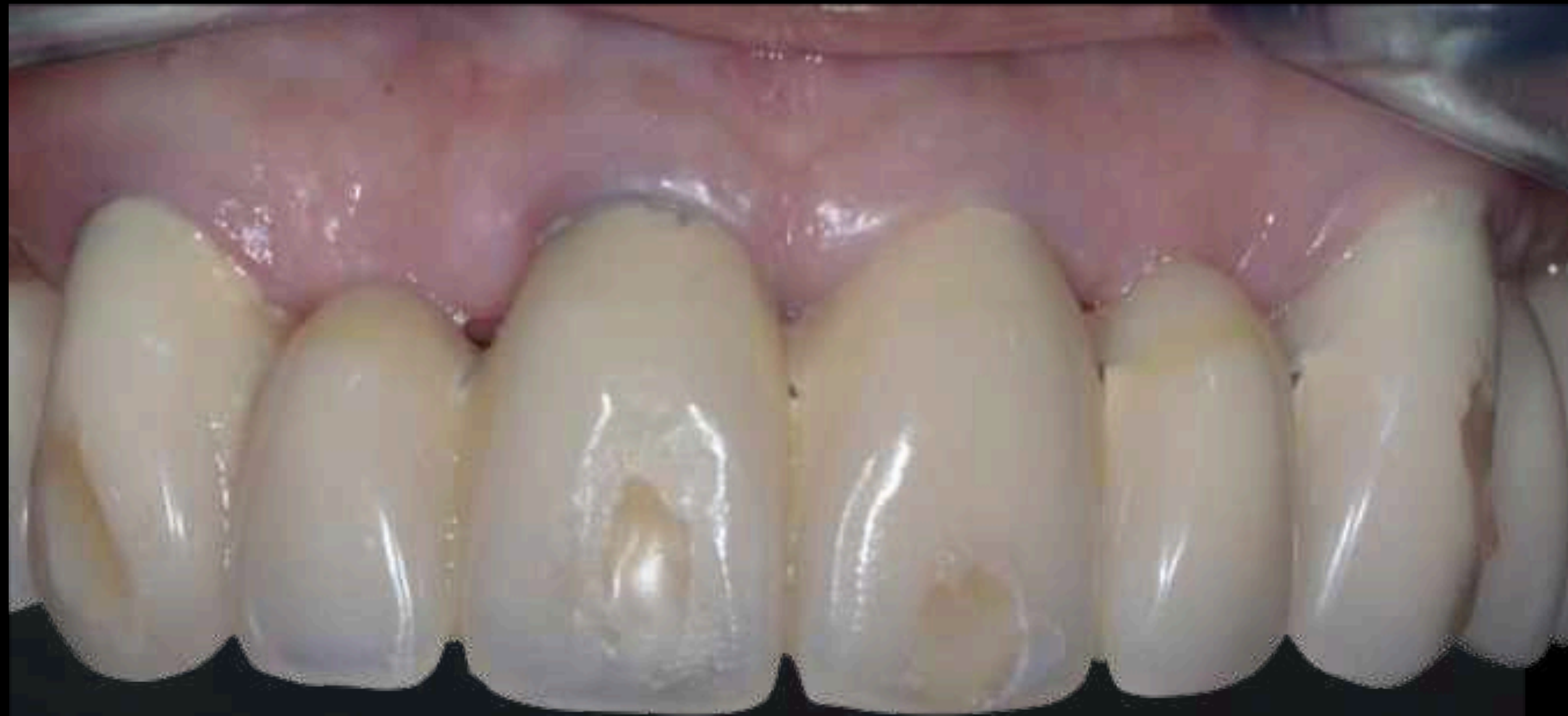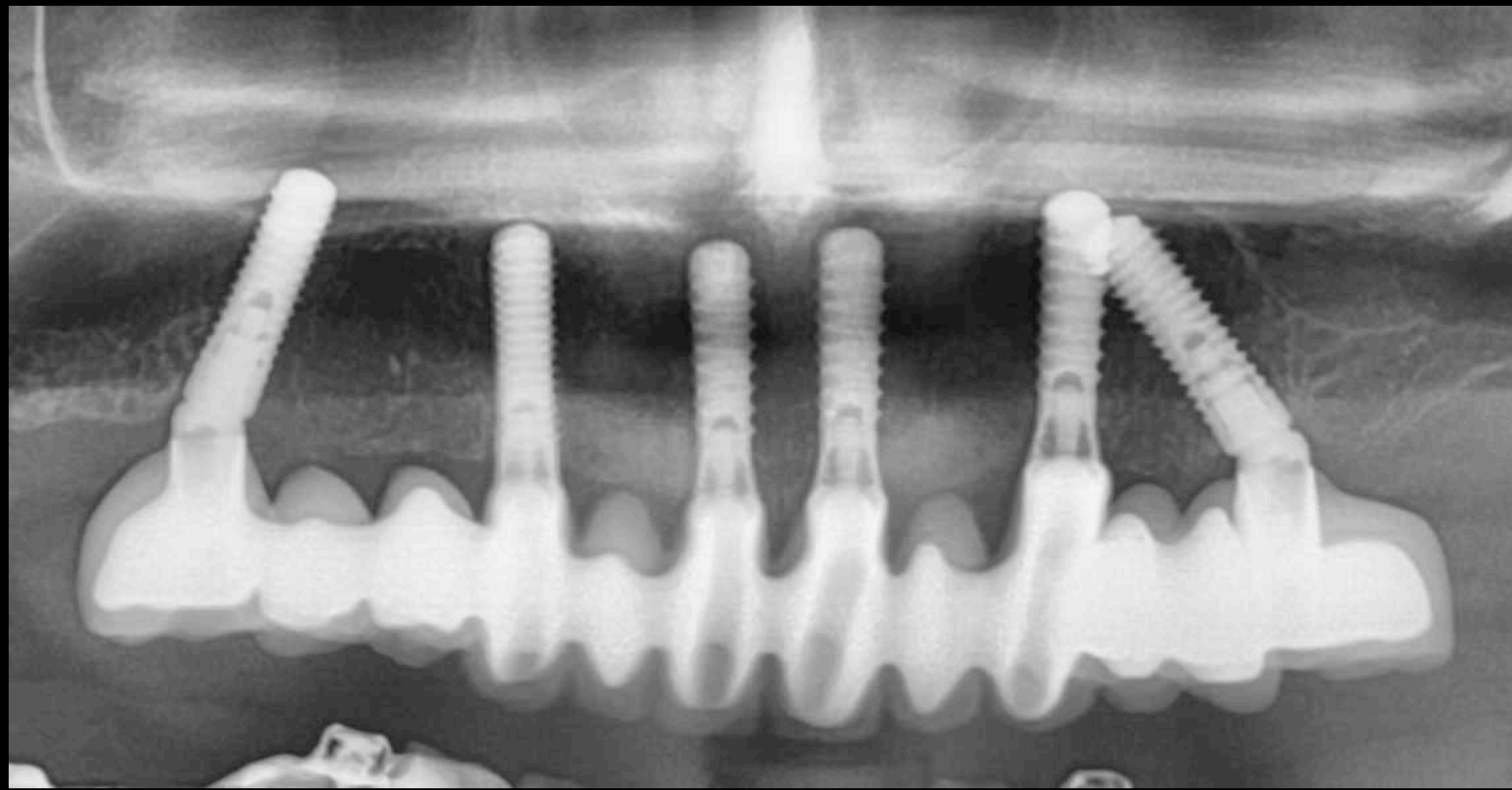
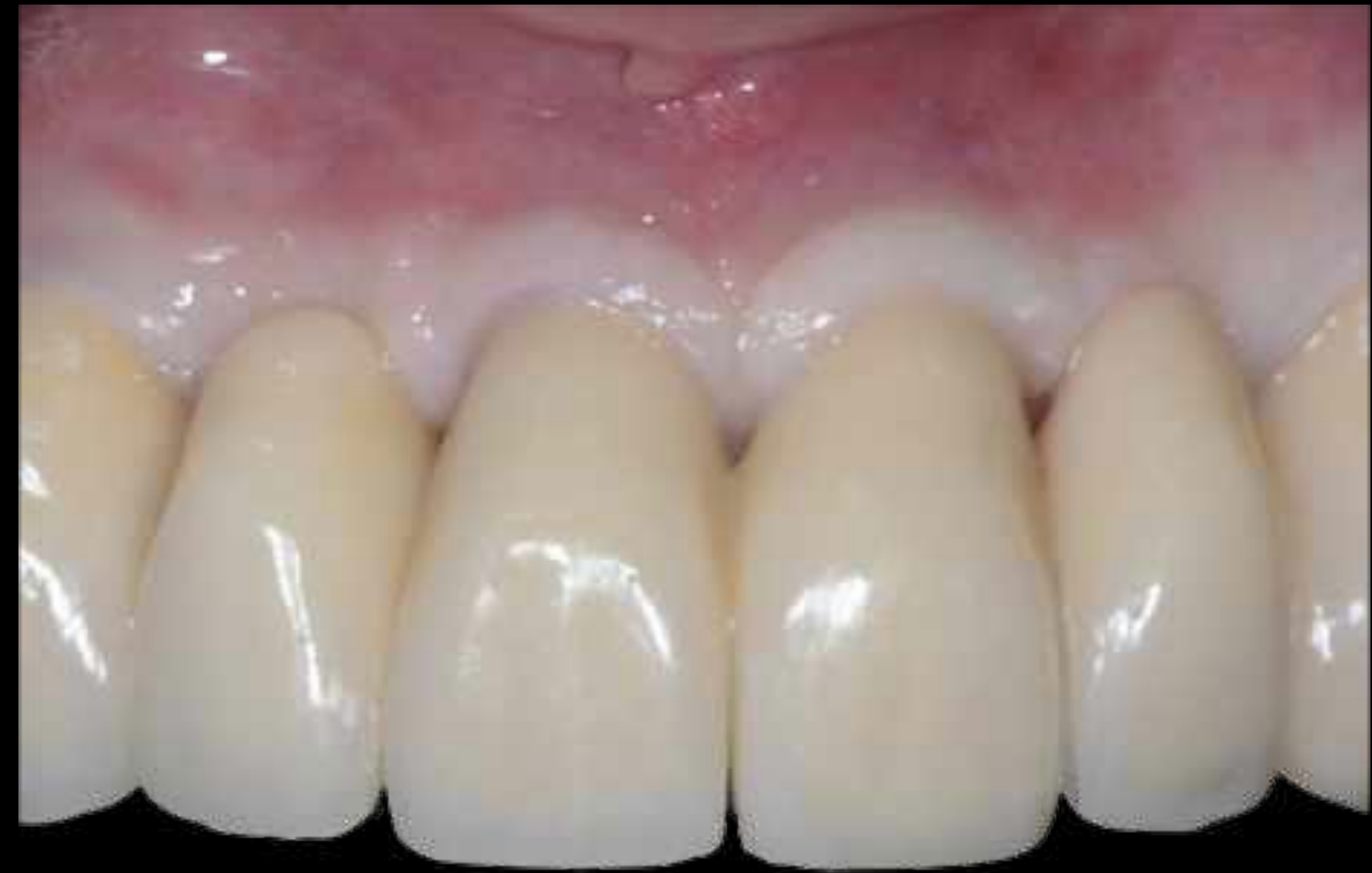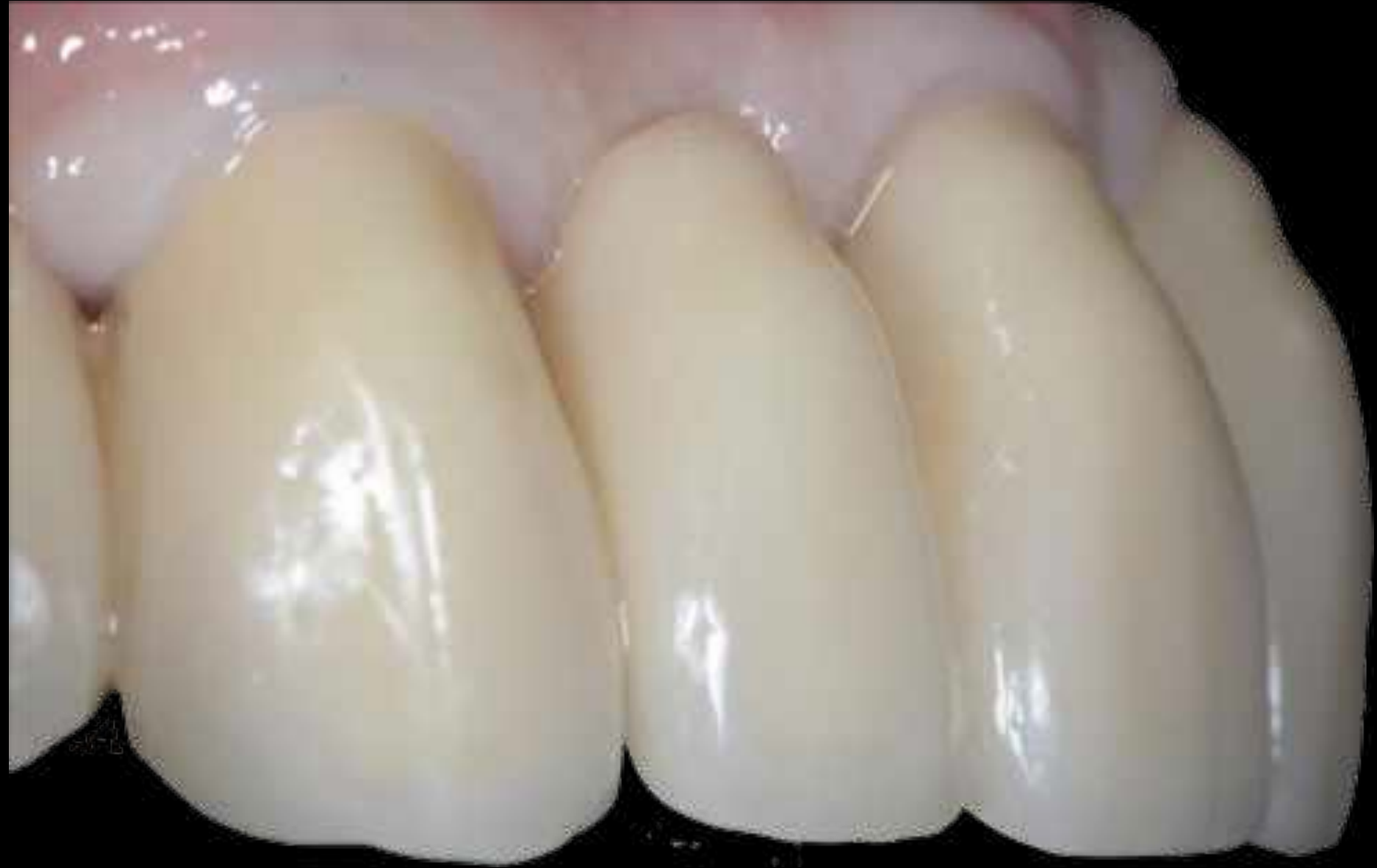20°

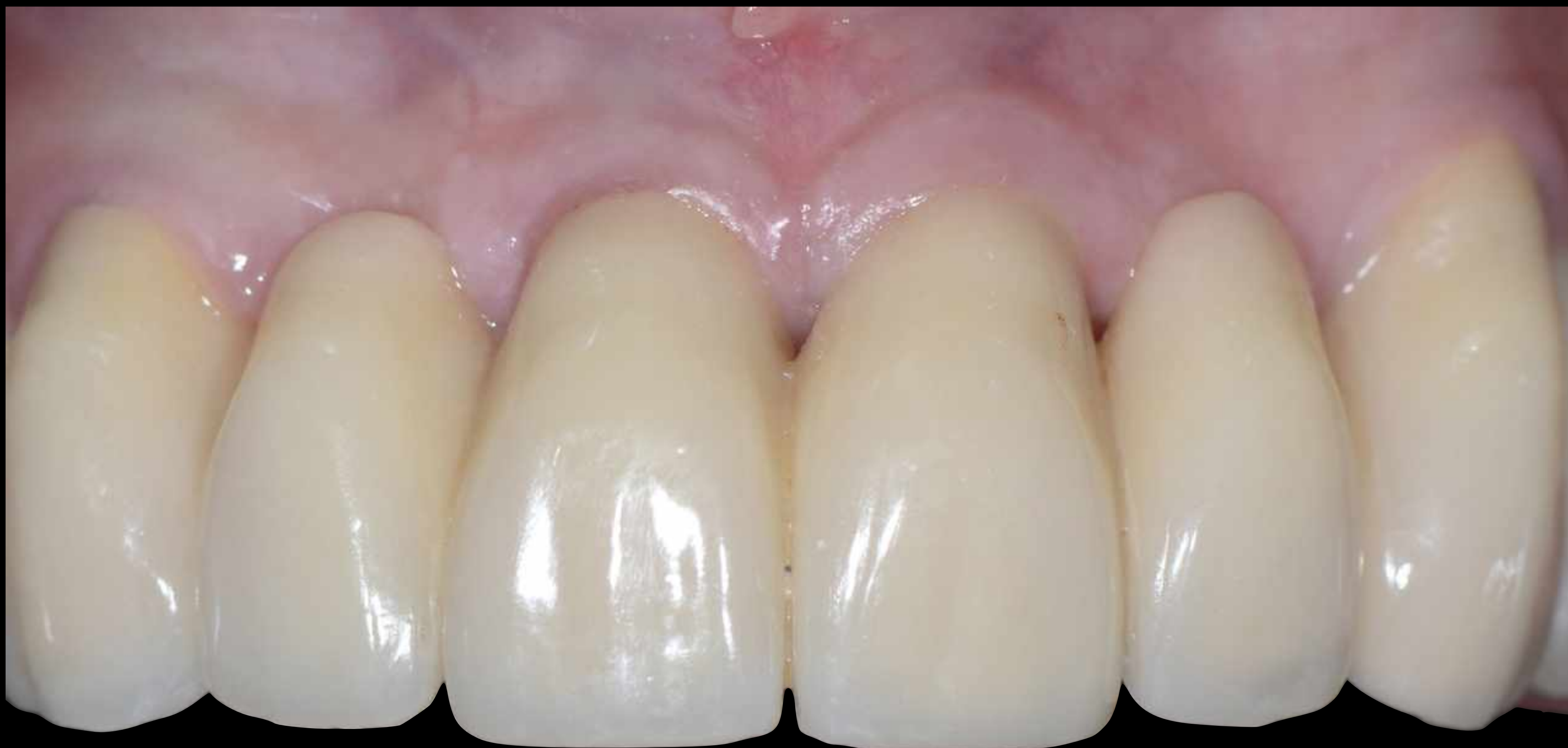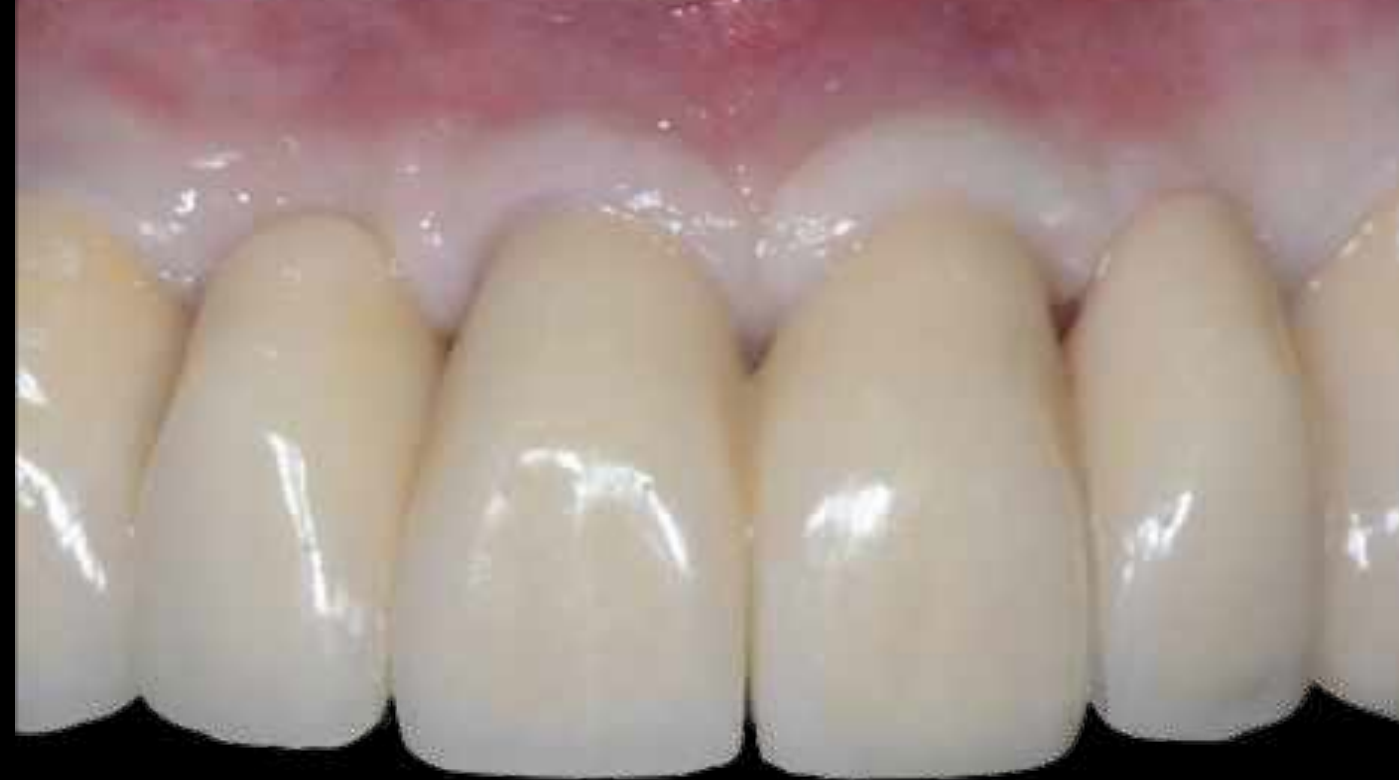Createch

Straumann

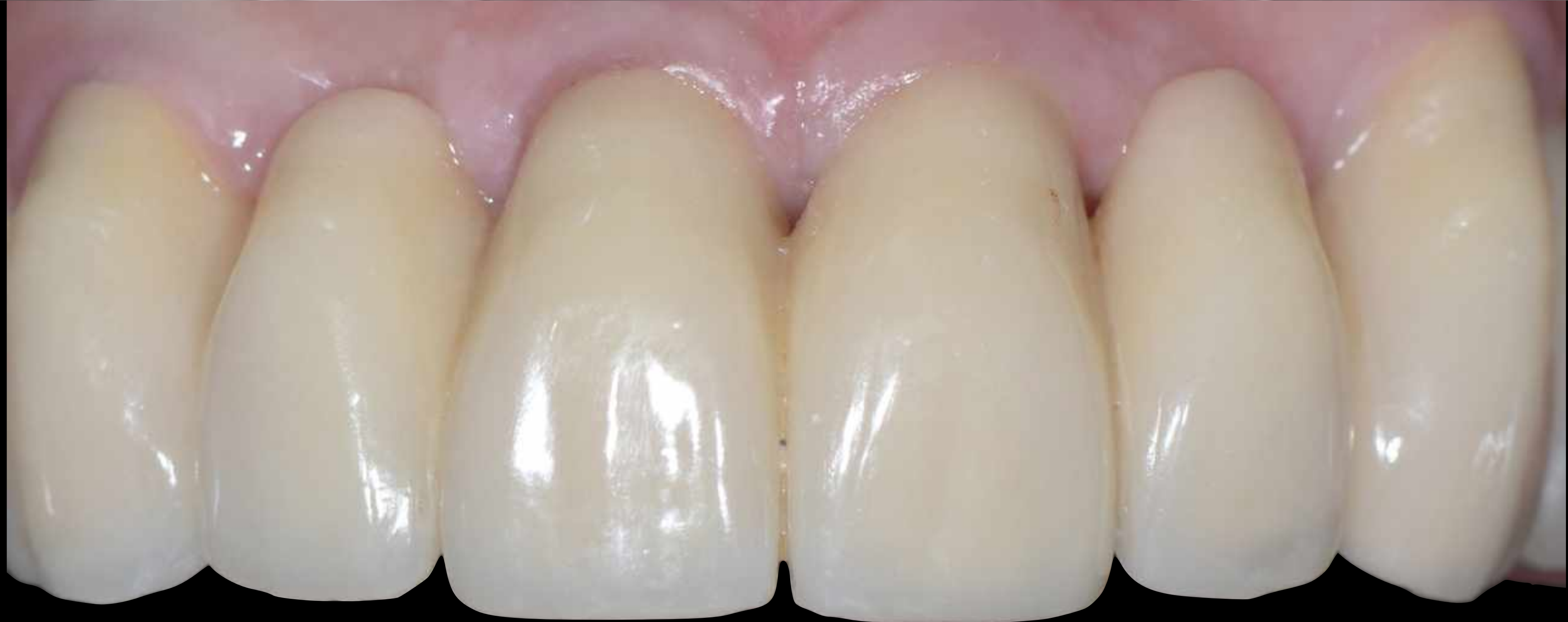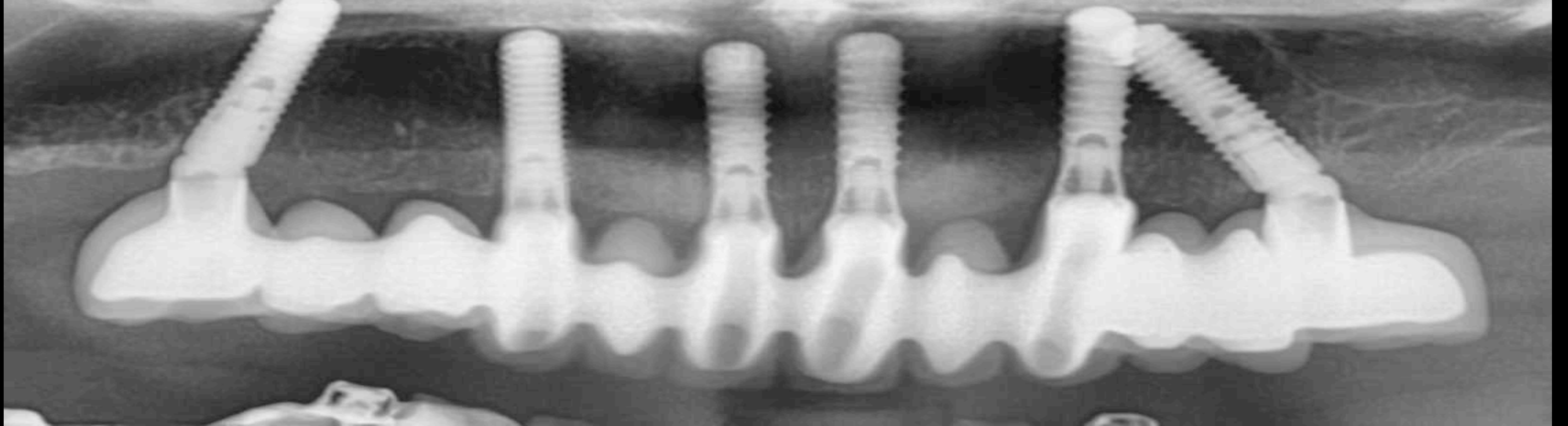



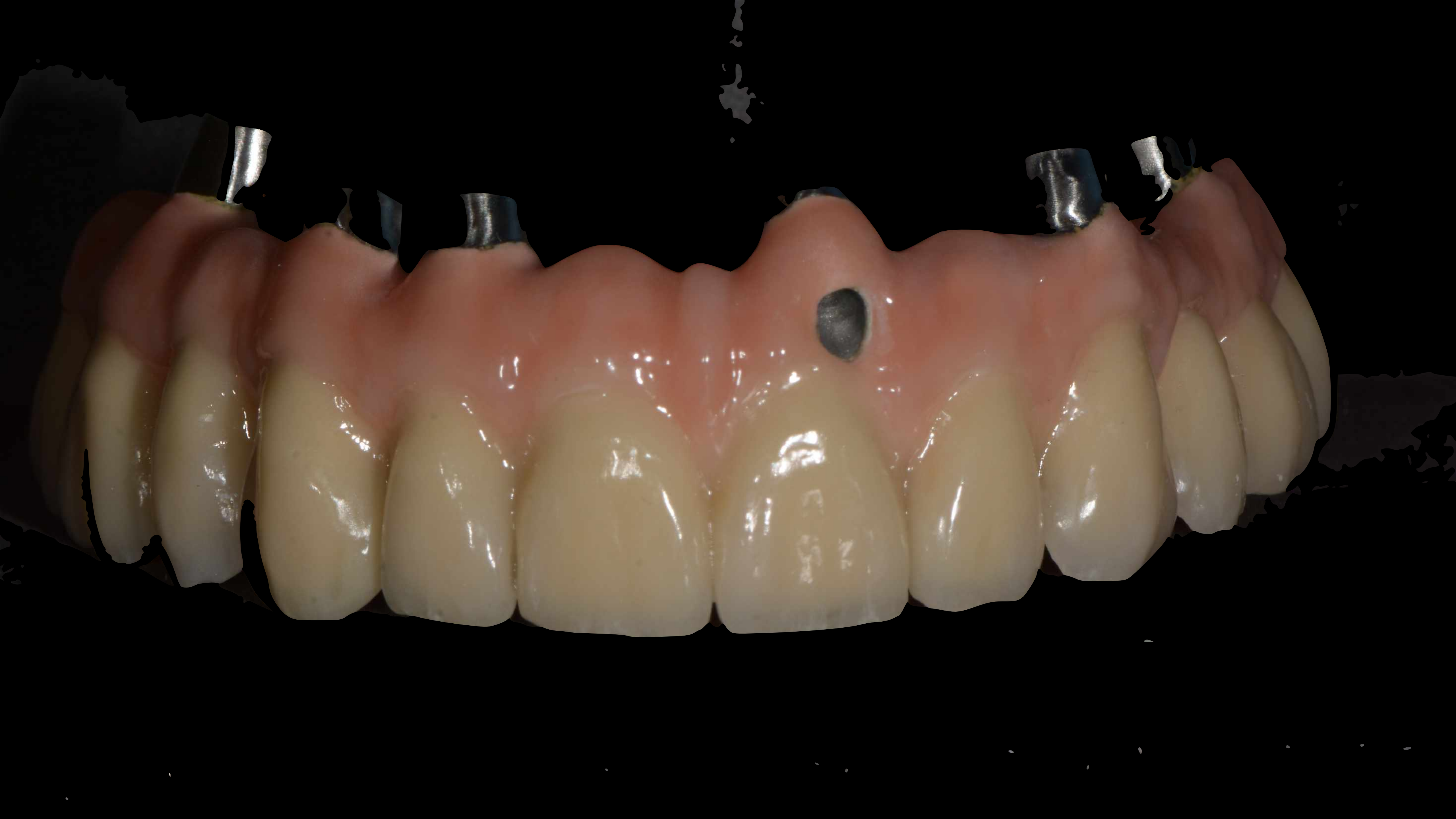
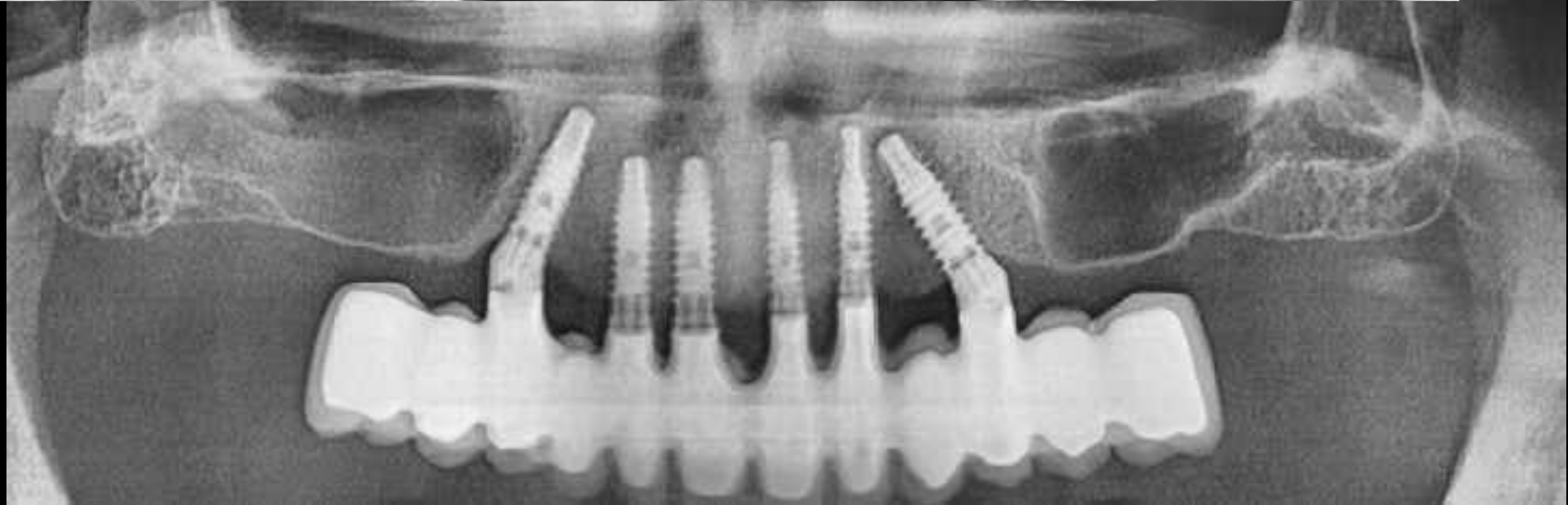


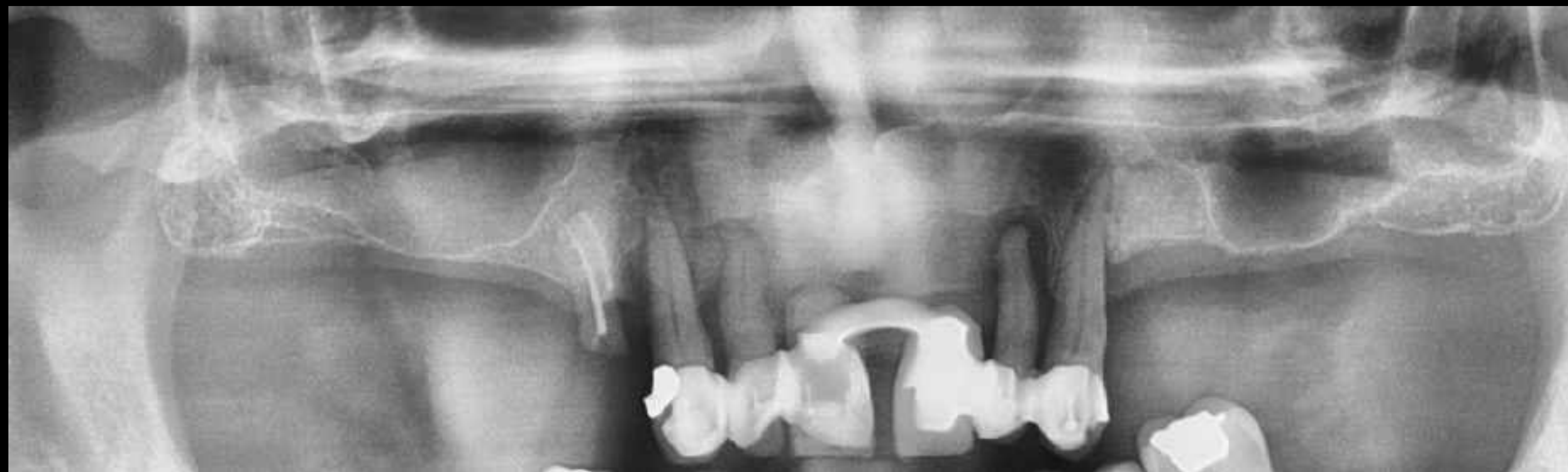

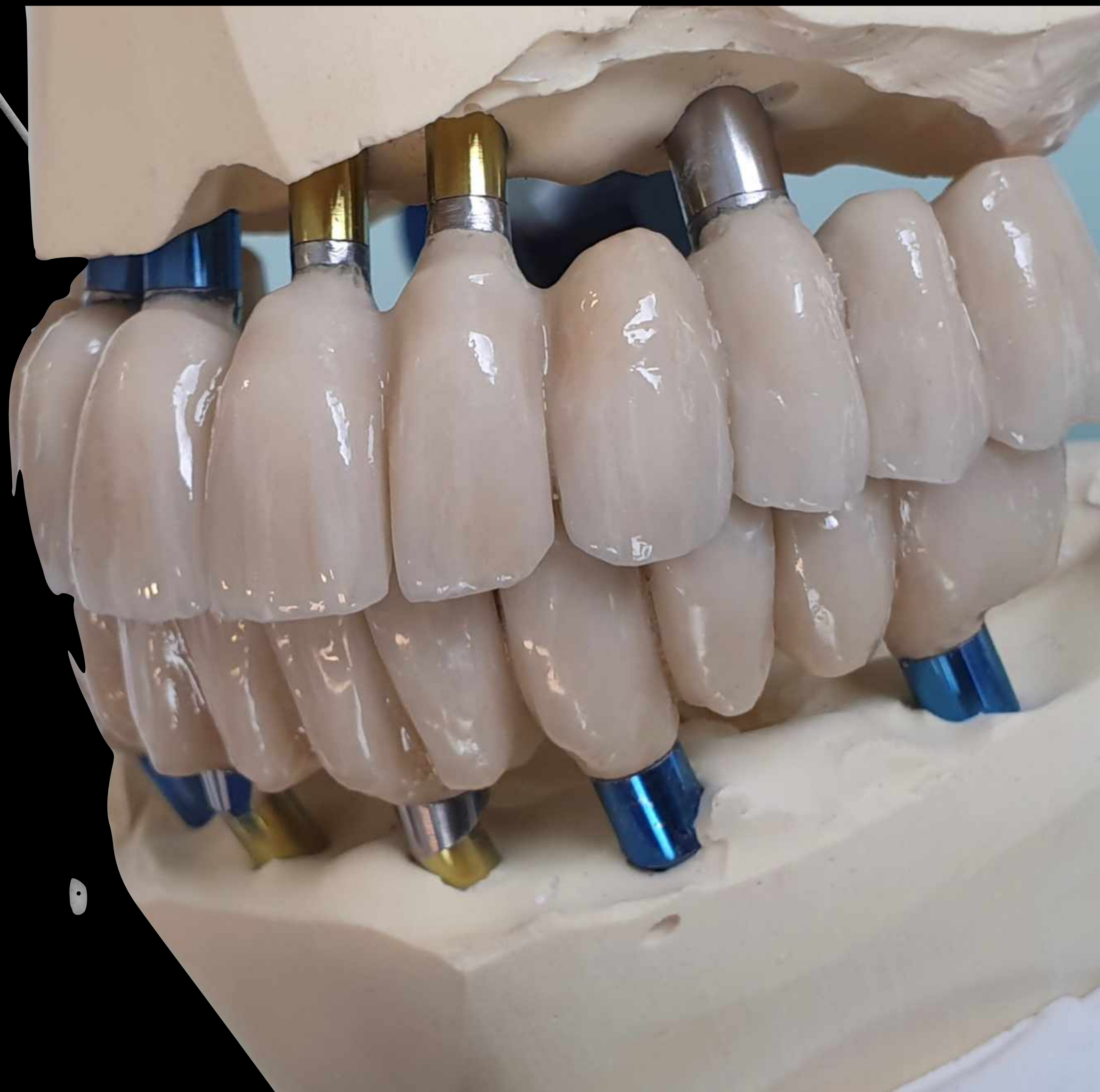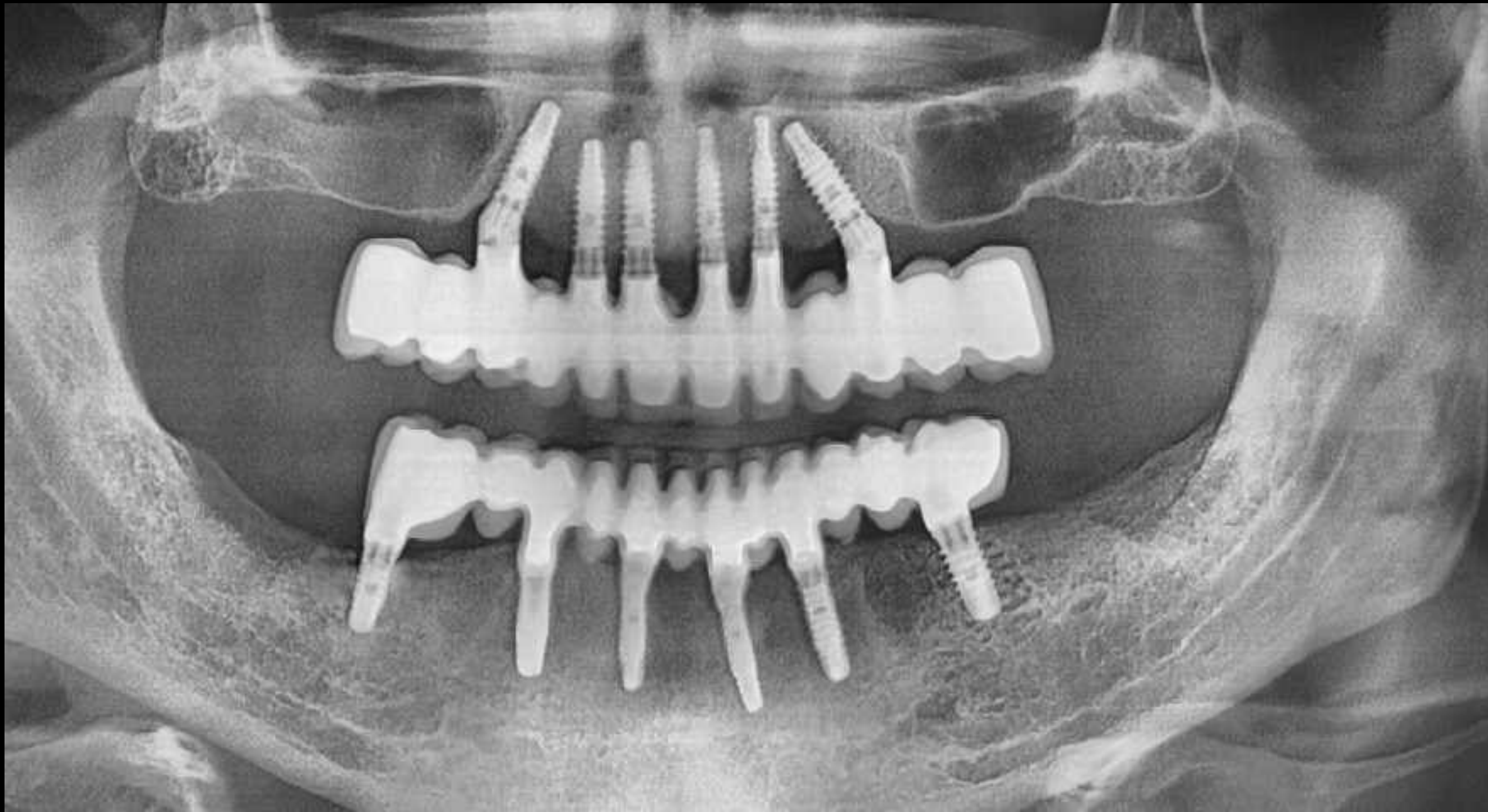
I an



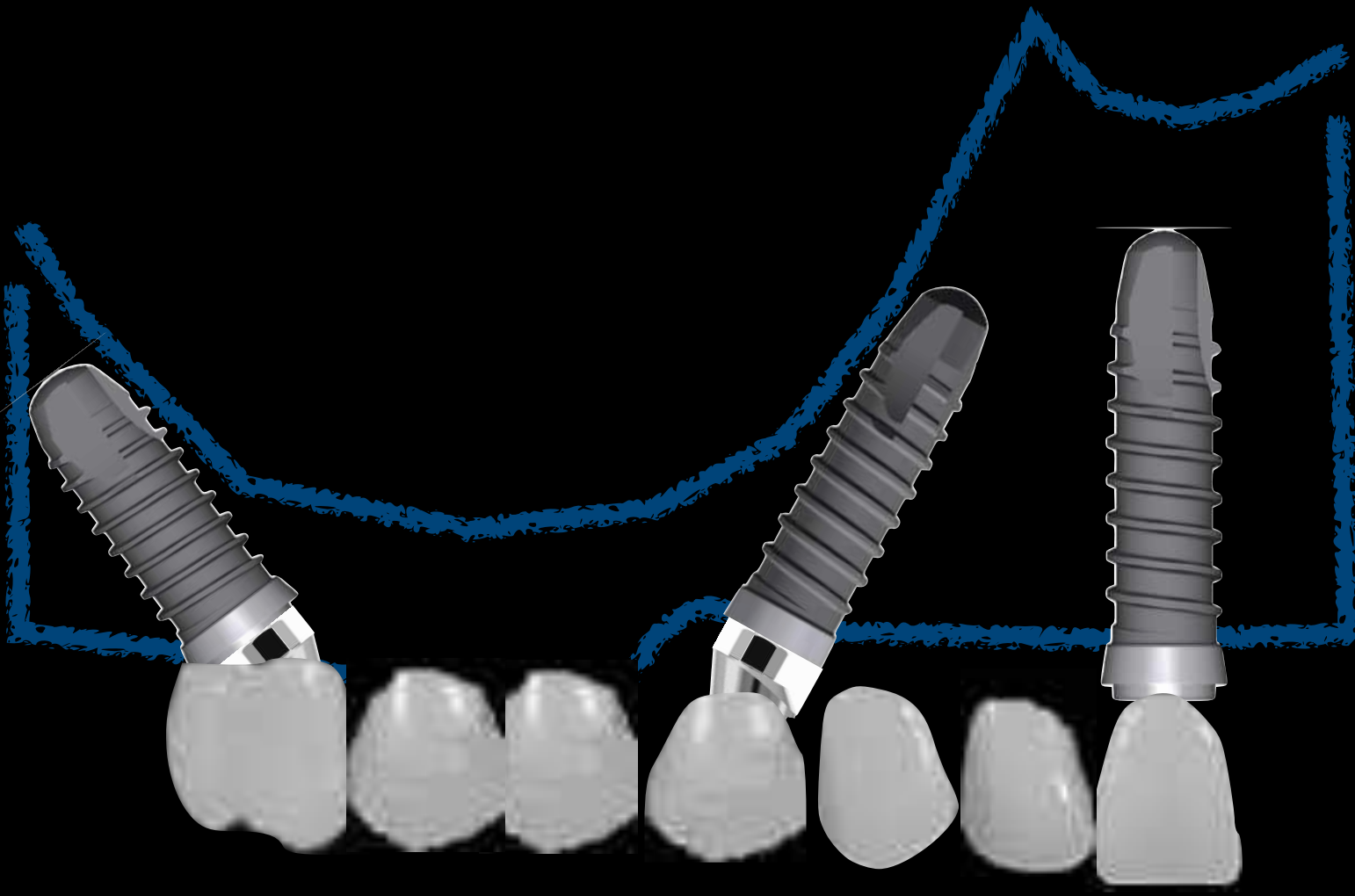








Implants Angulés

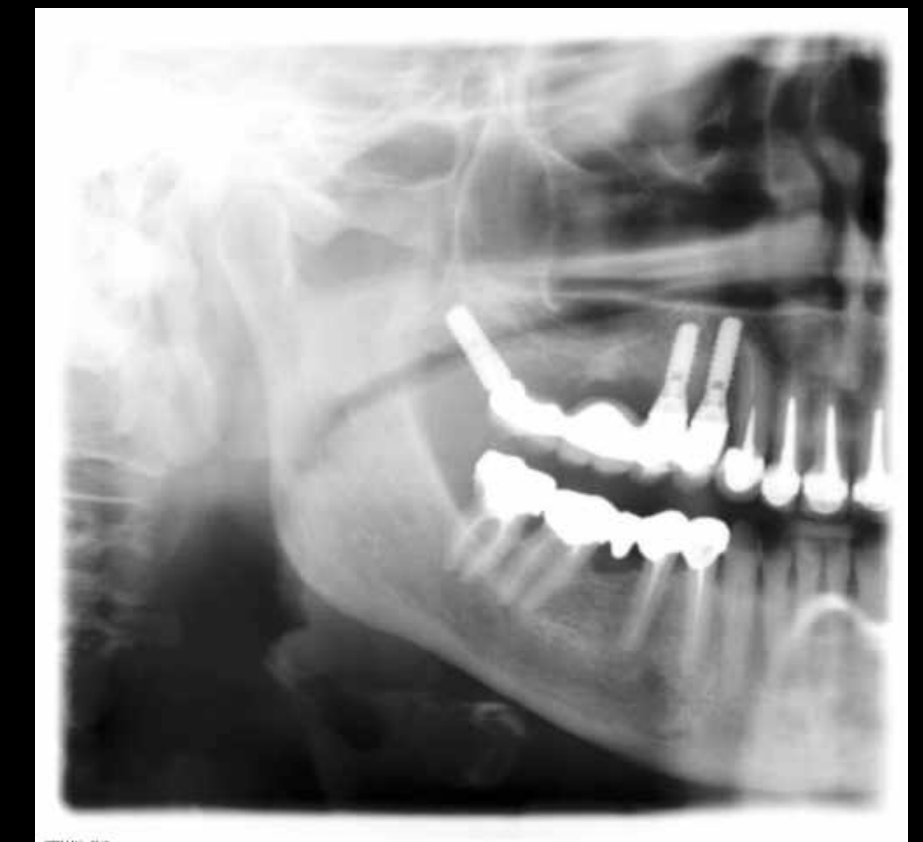

CONTOURNEMENT SAGITTAL DISTAL DU SINUS

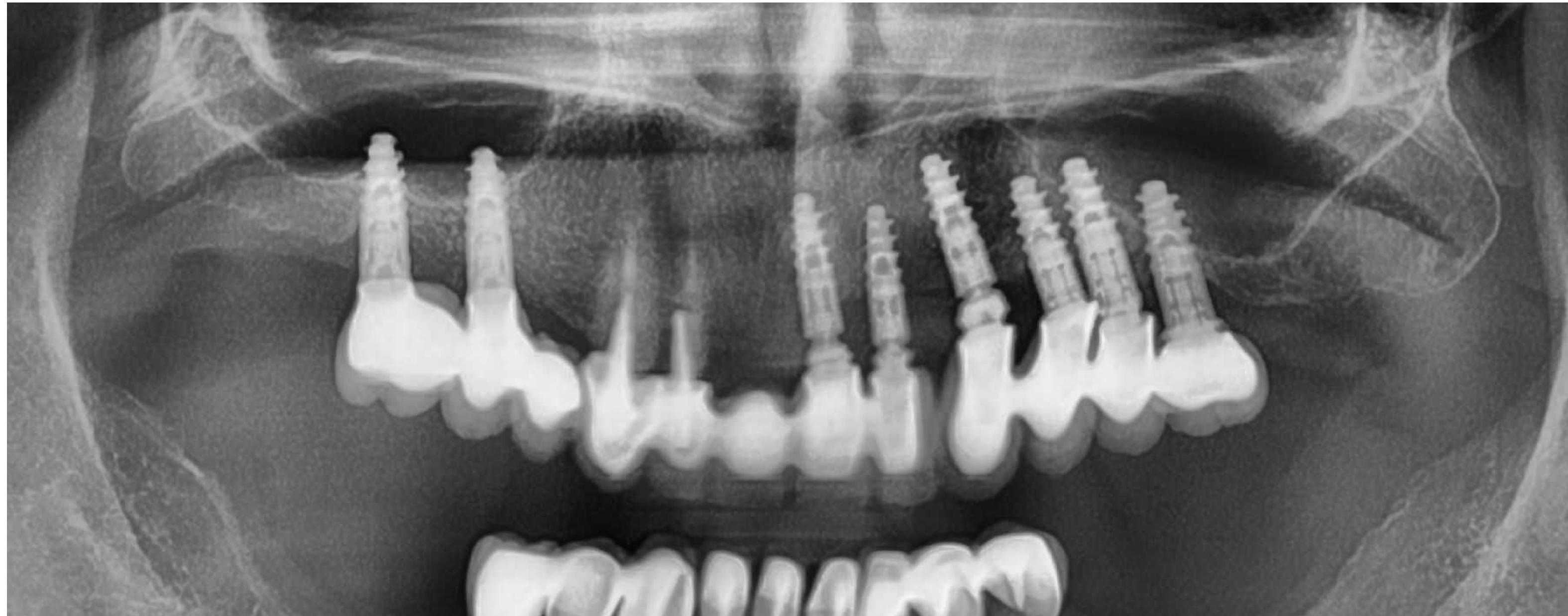120 implants dans 45 sinus

Taux de survie implants
dans greffe de sinus : 97,5%

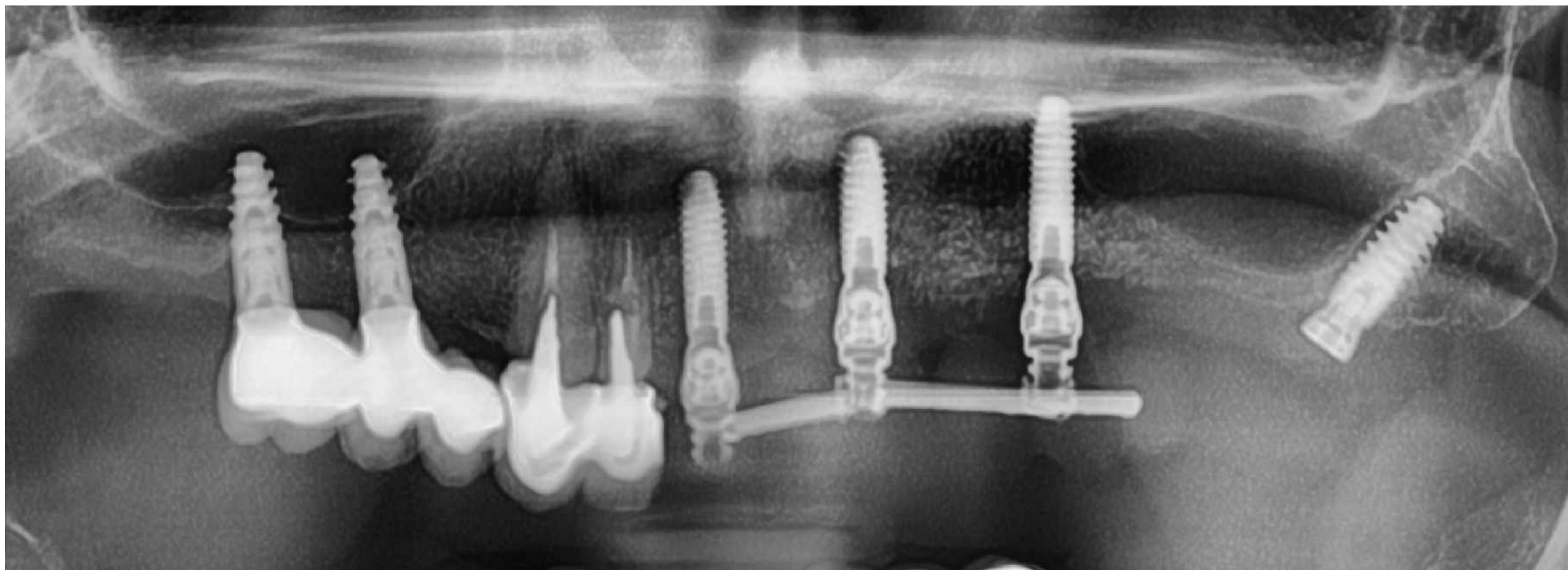
dans région postérieure maxillaire : 90,3%



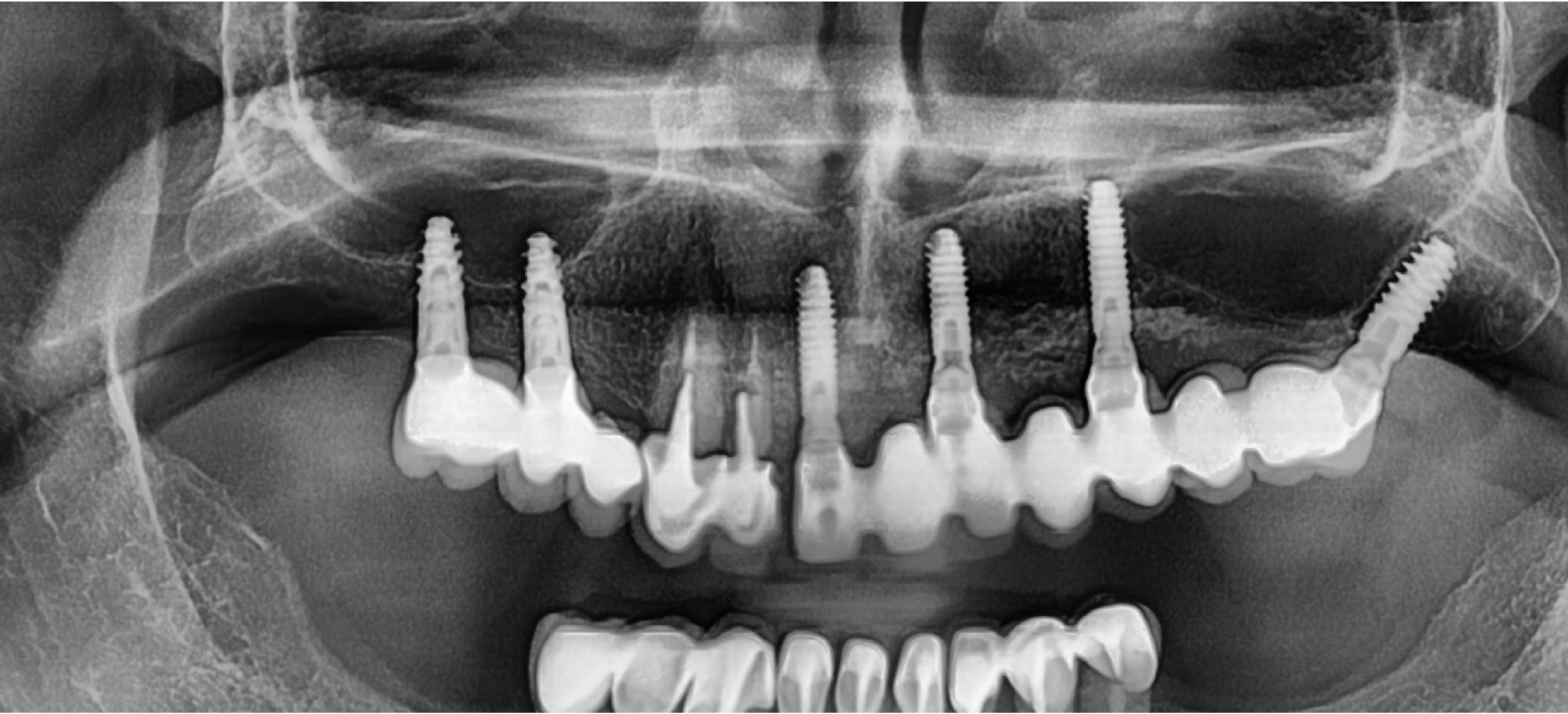Olson JW et al, Long-Term assessment (5 to 71 months) of endosseous dental implants placed in the augmented maxillary sinus. Ann Periodontol. 2000 Dec;5(1):152-6.



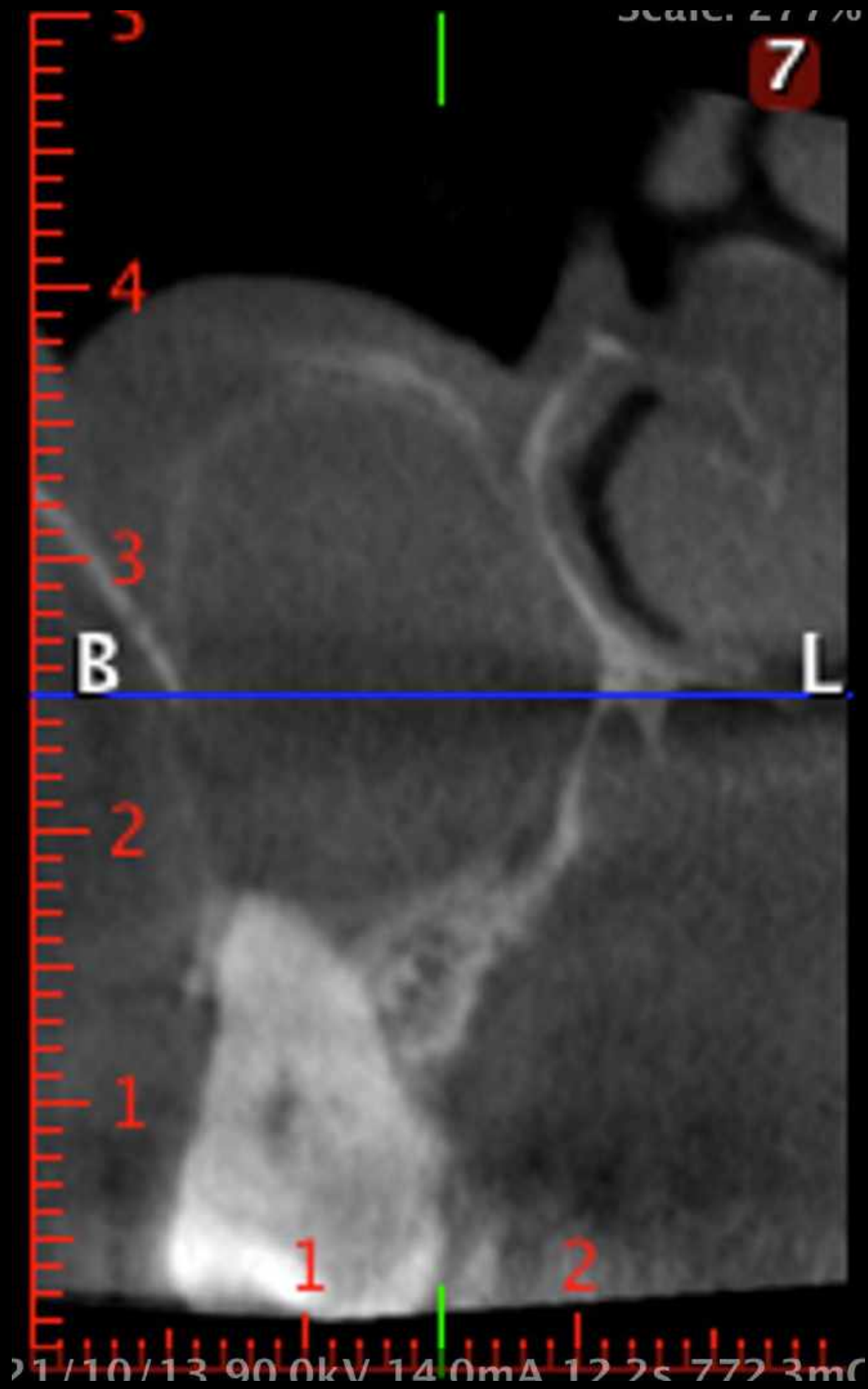
Problème de densité osseuse
tubérosité maxillaire
=
Os très riche en lipide



Possibilité de condenser du
DBBM (non résorbable)
avant
la pose de l'implant



Approche Crestale



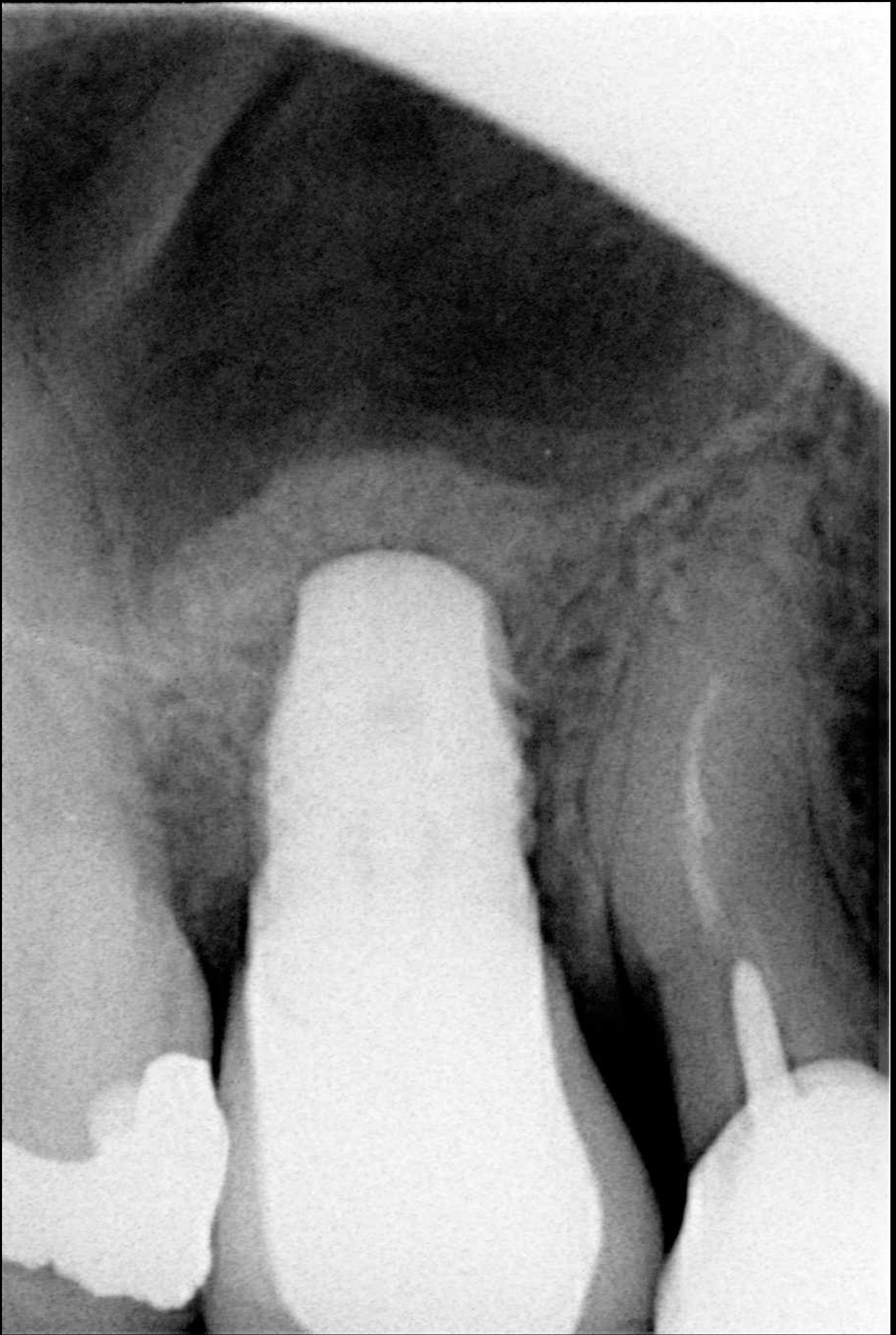
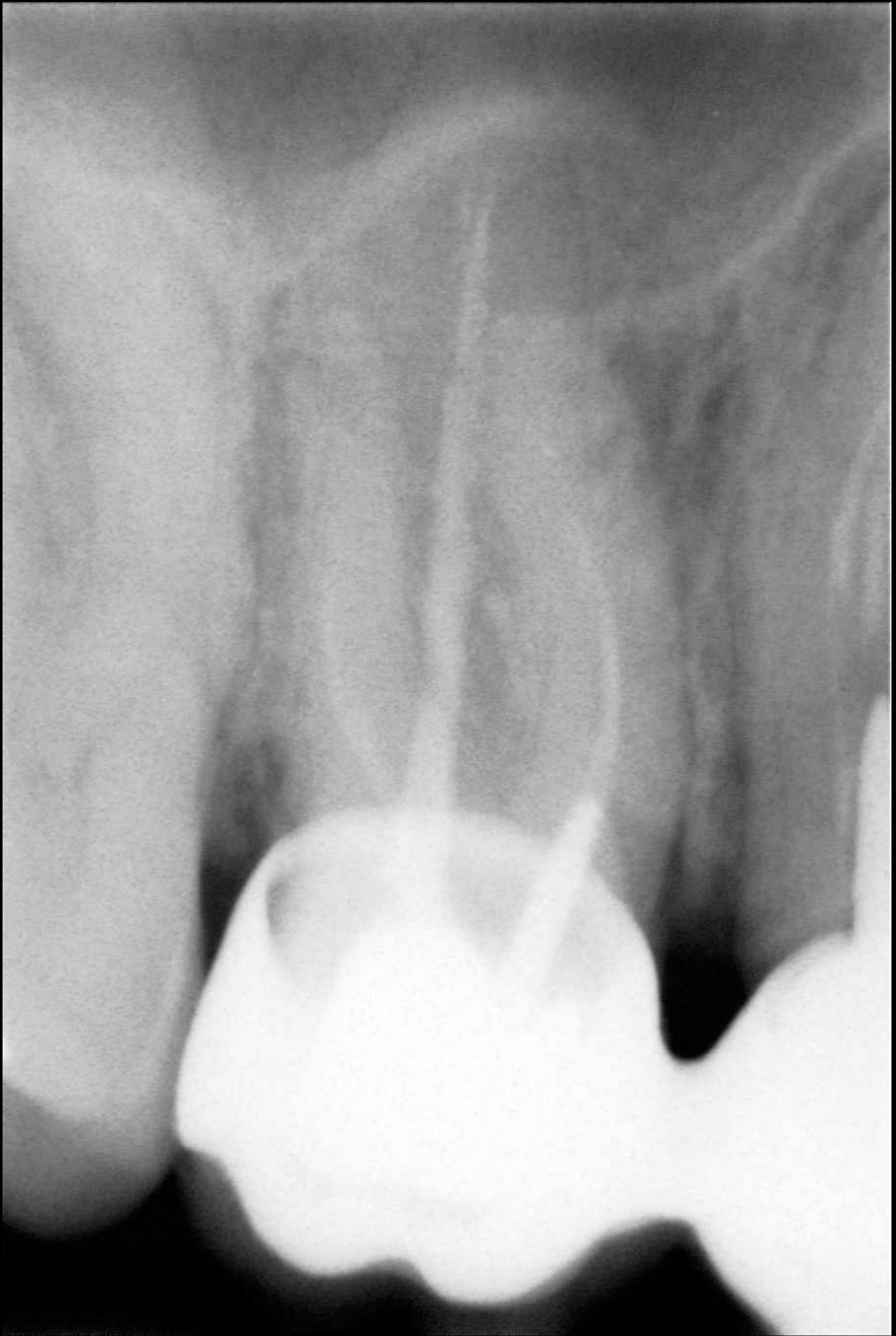
Tatum H. Maxillary and sinus implant reconstructions. Dent Clin North Am 1986;30:207-229

Summers RB. A new concept in maxillary implant surgery : the osteotome technique. Compendium. 1994;15:152-160

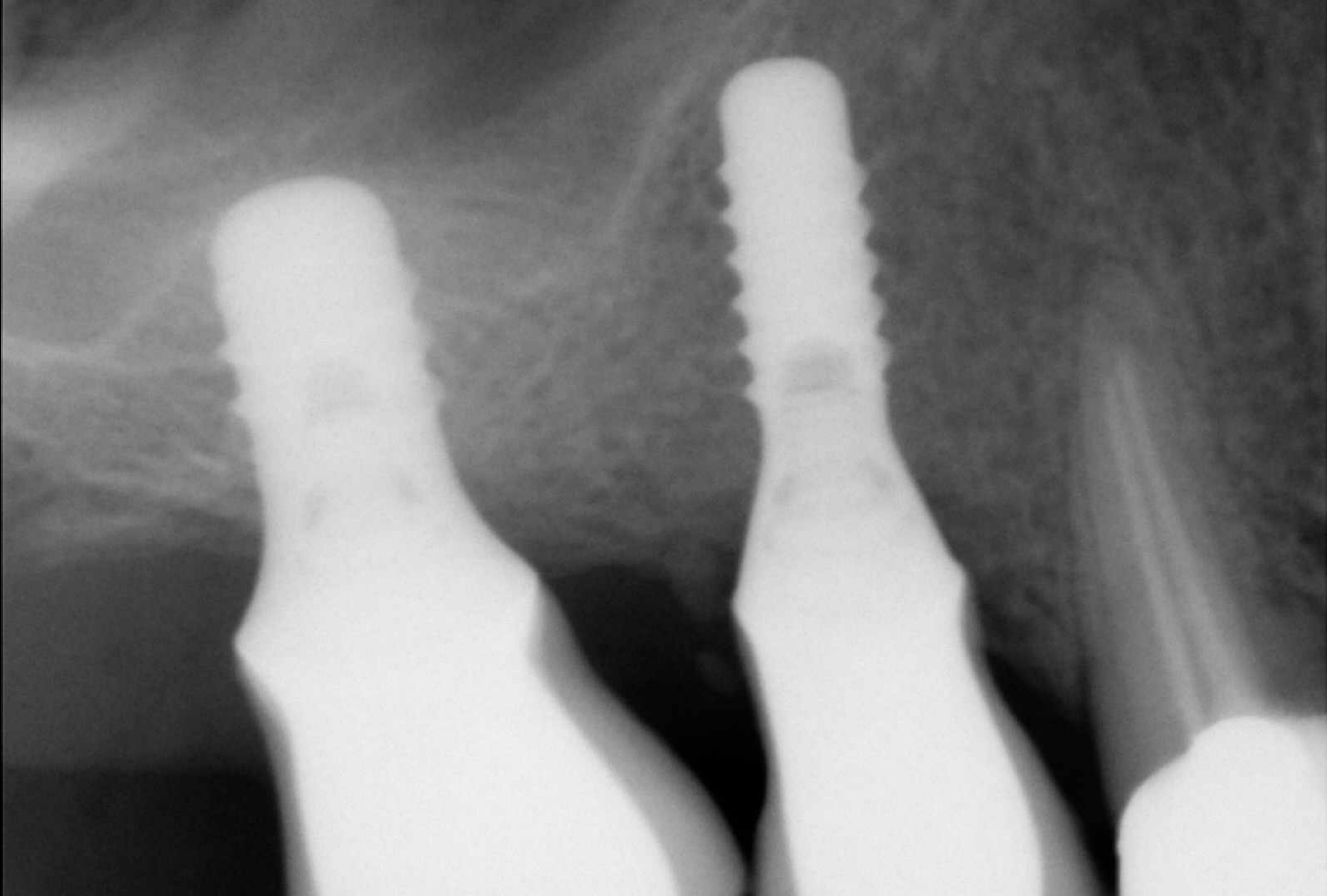Summers RB. The osteotome technique part 2 - The ridge expansion osteotomy (REO) procedure. Compendium 1994;15:422-434

Summers RB. The osteotome technique part 3 - less invasive methods of elevating the sinus floor. Compendium. 1994;15:698-708

Approche Crestale



Approche Crestale



Approche Crestale

Incision crestale.

Fraise boule (corticale).

Foret de 2,2 mm si type III ou II jusqu'à 1 mm de la corticale sinusienne. Si type IV démarrer à l'ostéotome de 2,8 mm.

Foret de 2,8 mm (II et III) à sinus - 1mm

Ostéotome de 3,5 mm et maillet, pour obtenir une fracture du plancher sinusien,

sans entrée de l'instrument dans la cavité.(ou utilisation de la piezo

pour créer l'effraction)

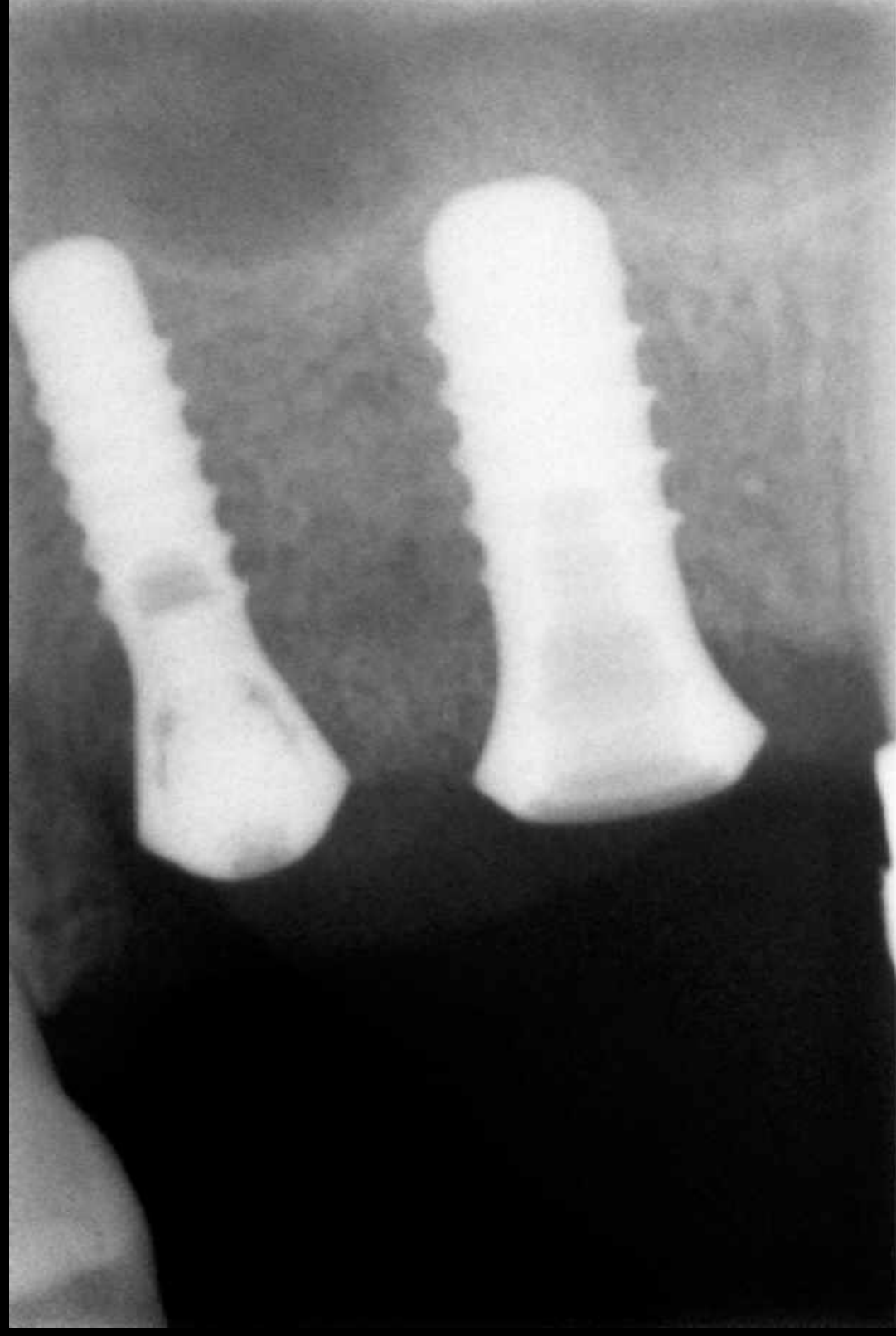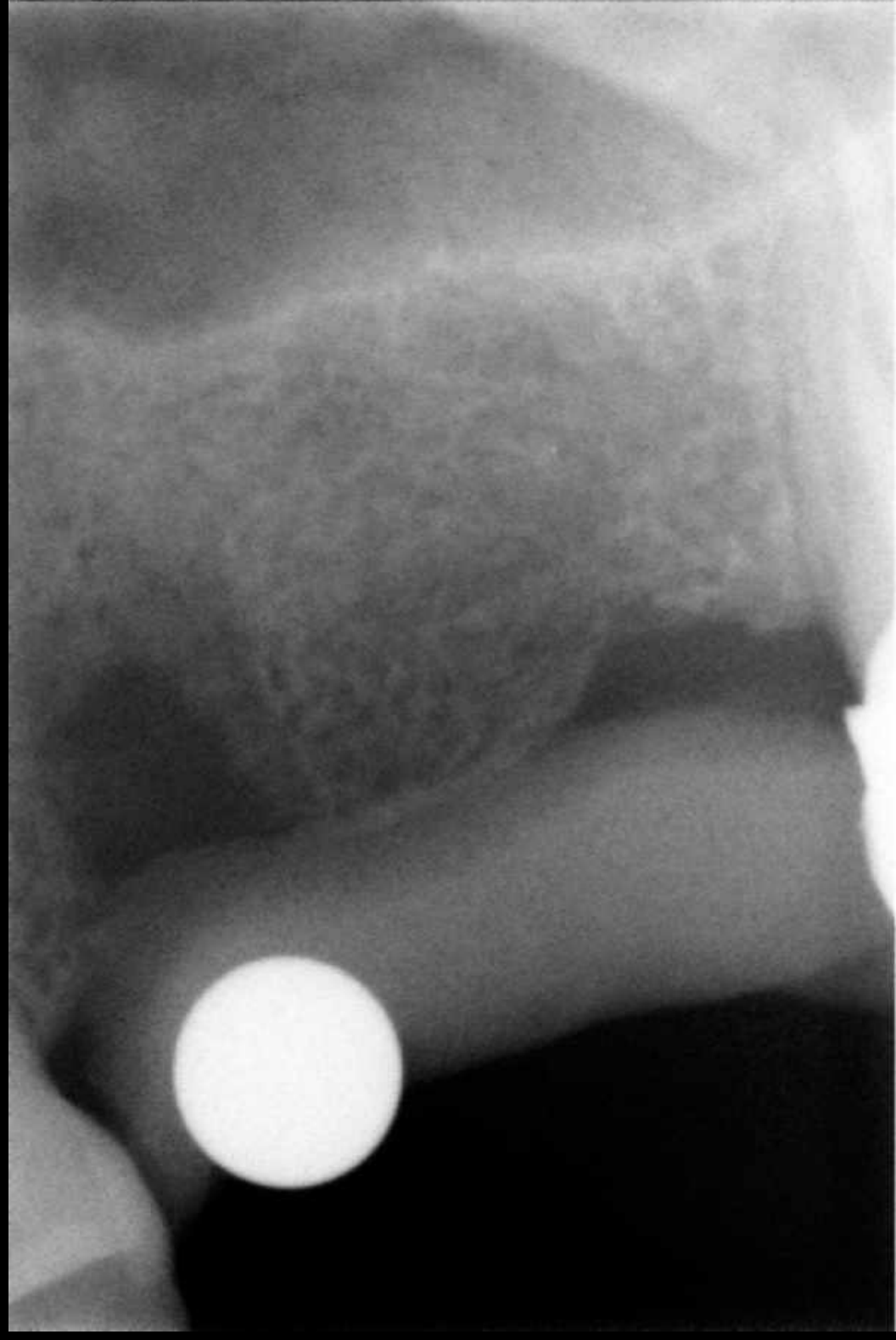Elévation de la membrane avec un matériau de comblement.

Taraudage uniquement de la corticale (II et III).

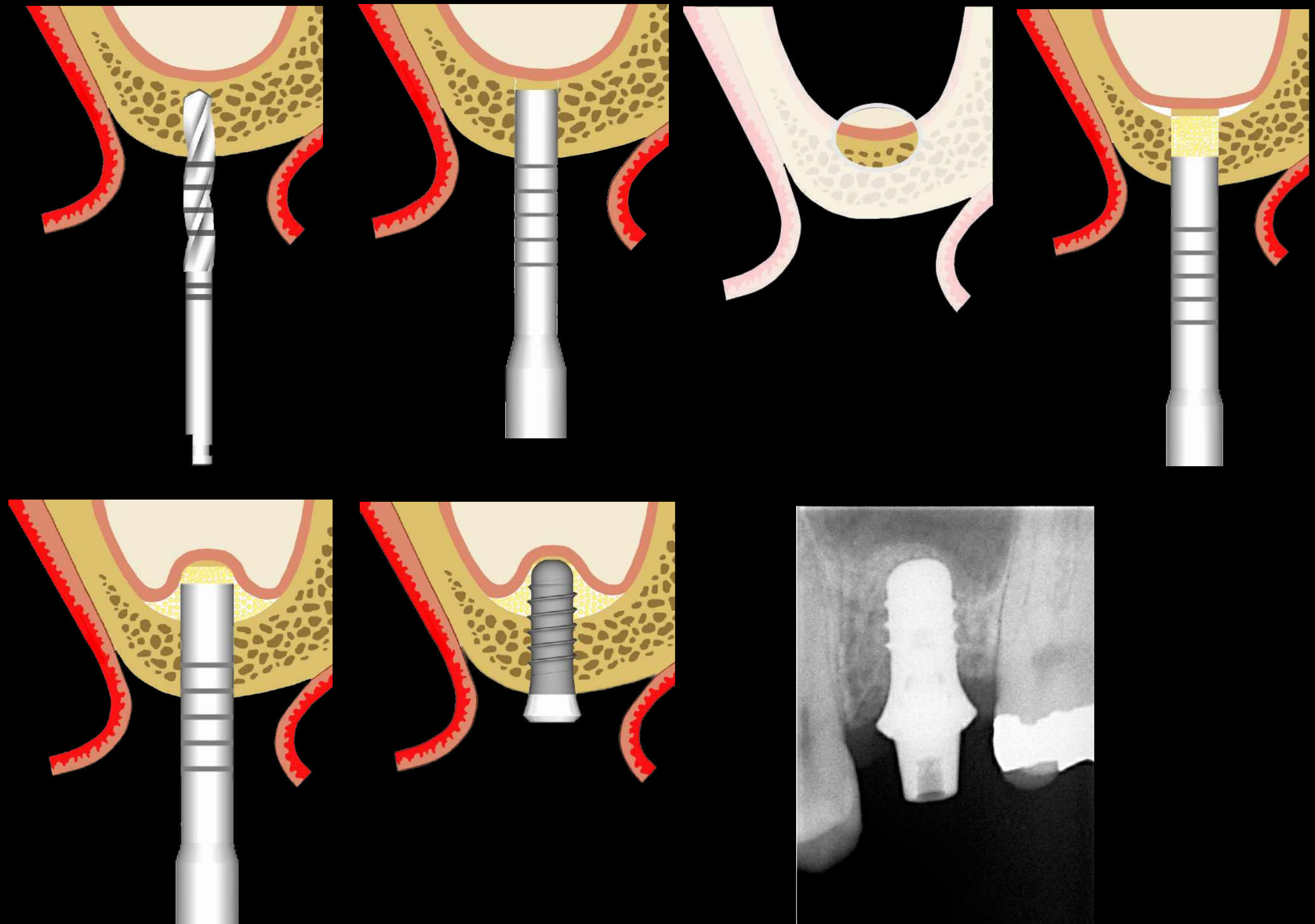
Pose de l'implant.

Former une collection de matériau et de sang contre la membrane sinusienne pour générer une force hydraulique qui va l'élever sans contact direct entre l'instrument et la membrane

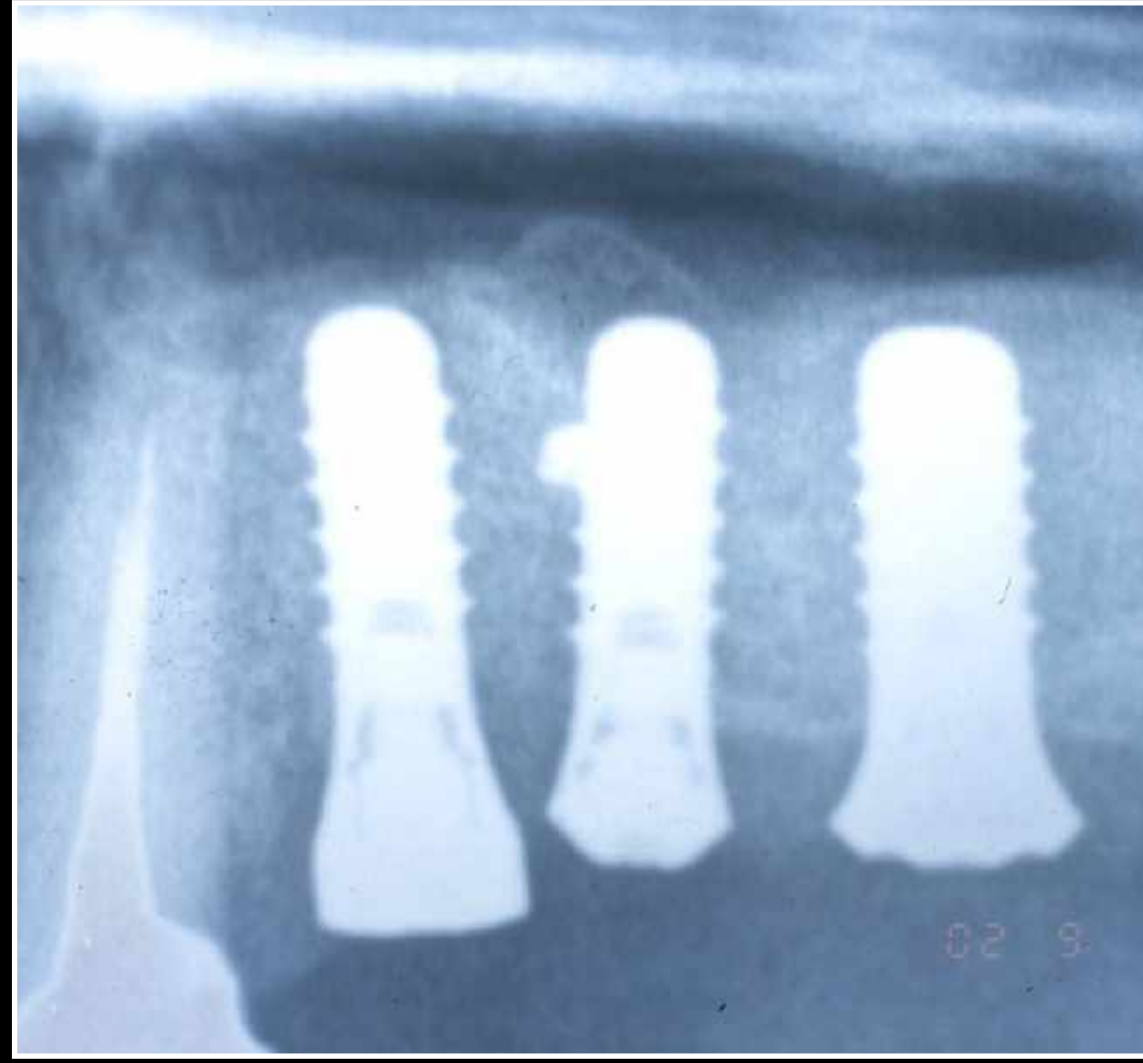
Approche Crestale




Approche crestale



Approche Crestale



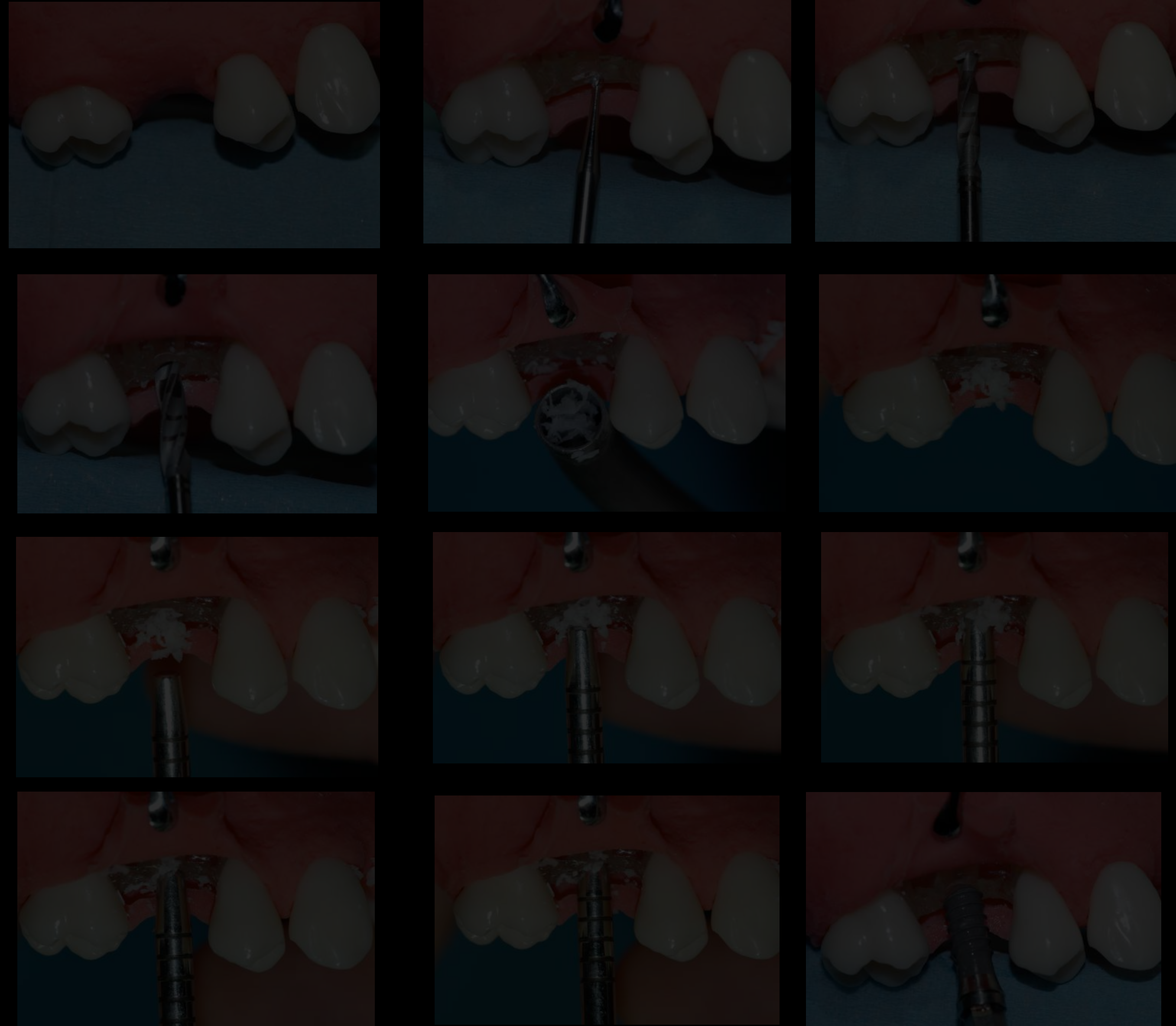
OSTEOTOME POUR LE SINUS.



Apport de l'OsteoSafe Anthogyr

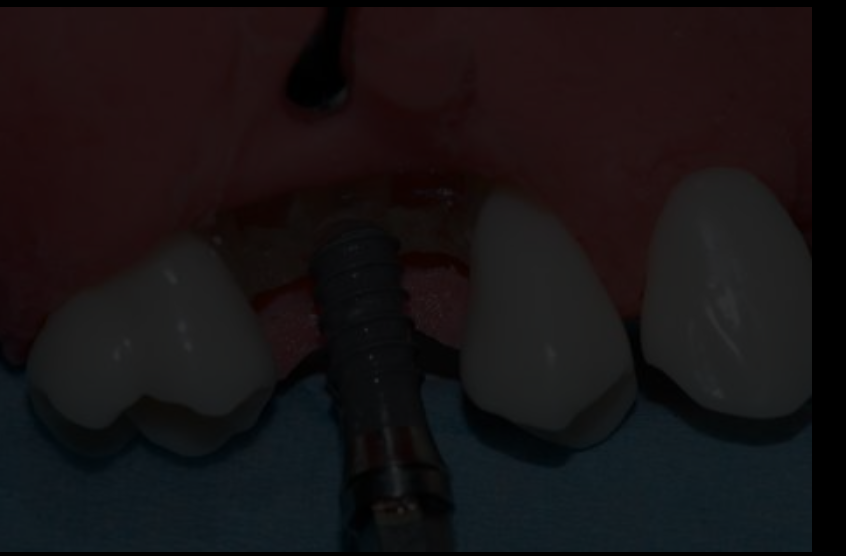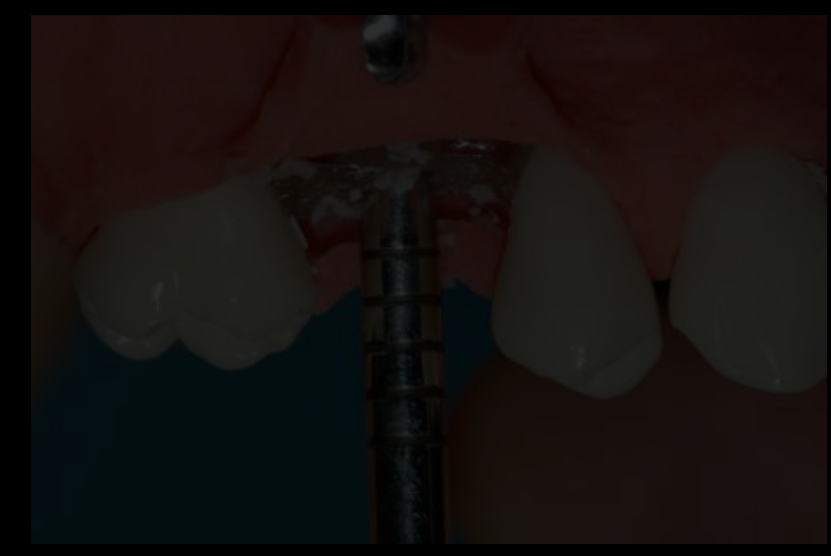
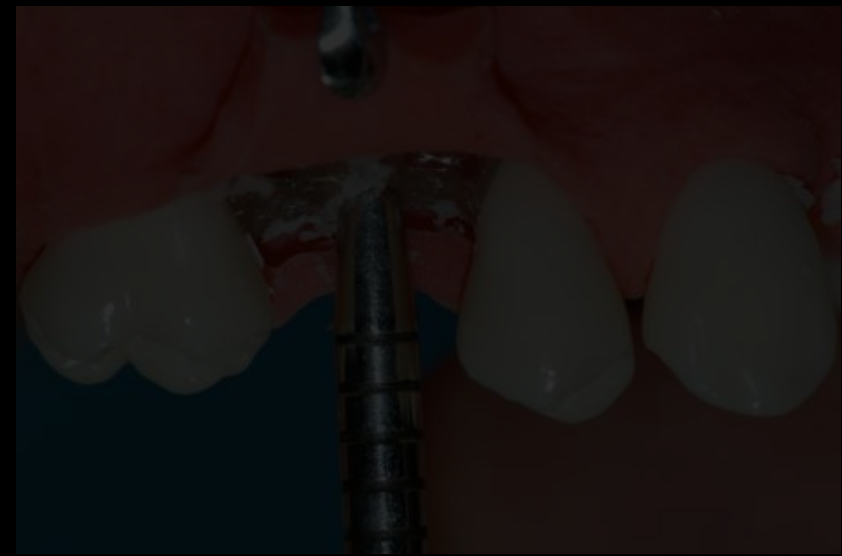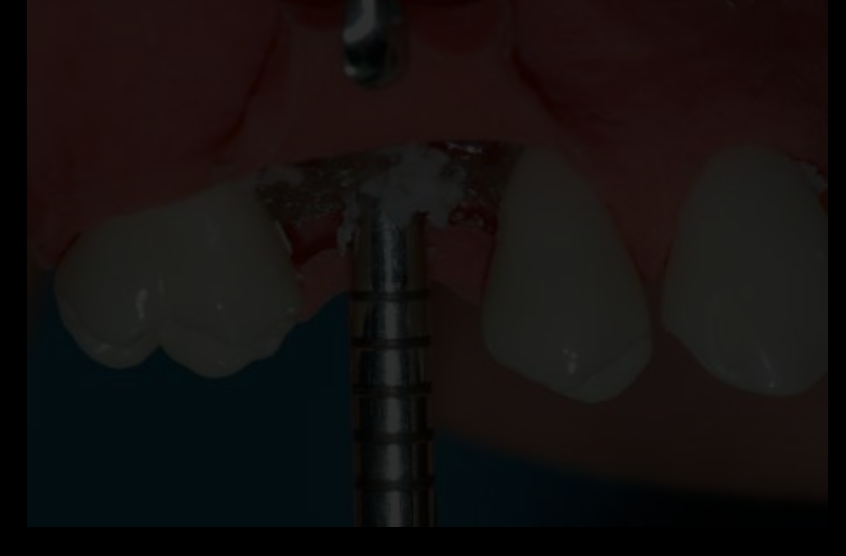
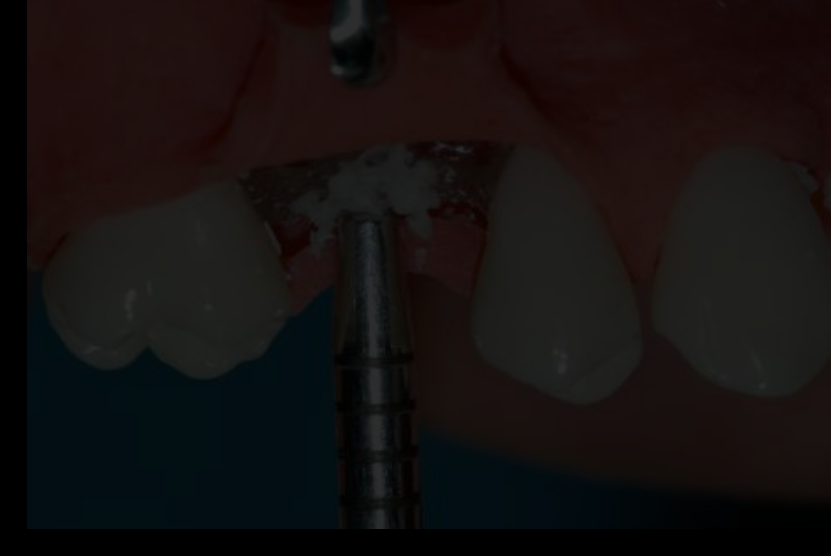
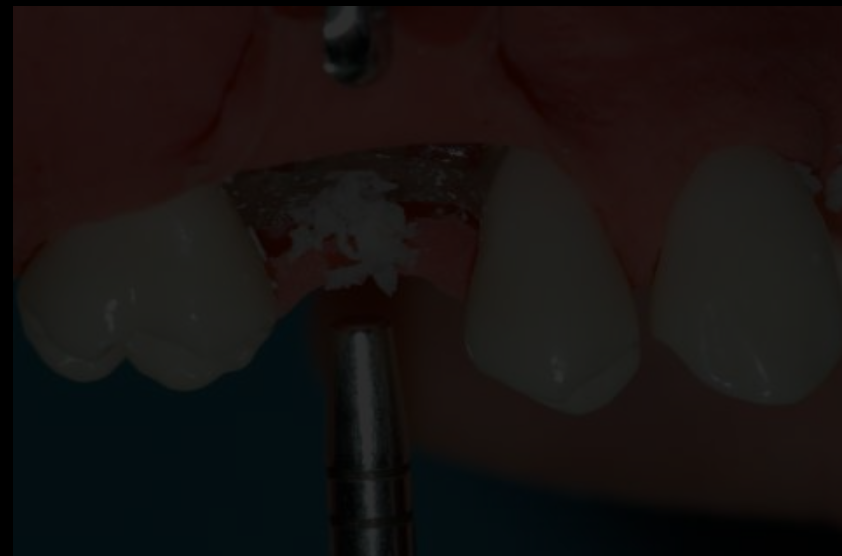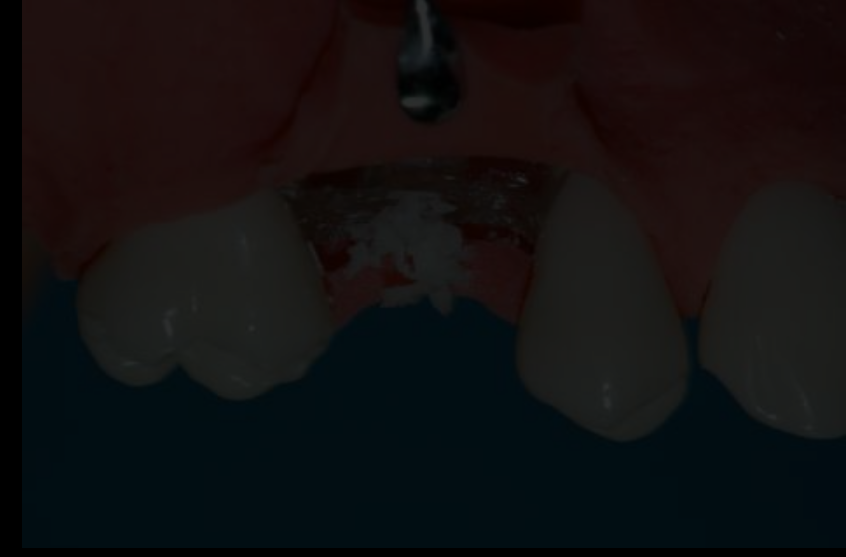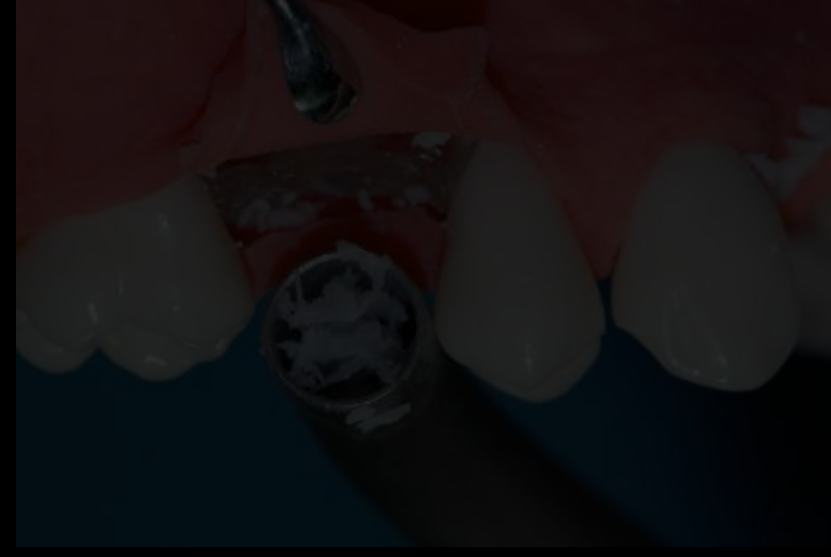
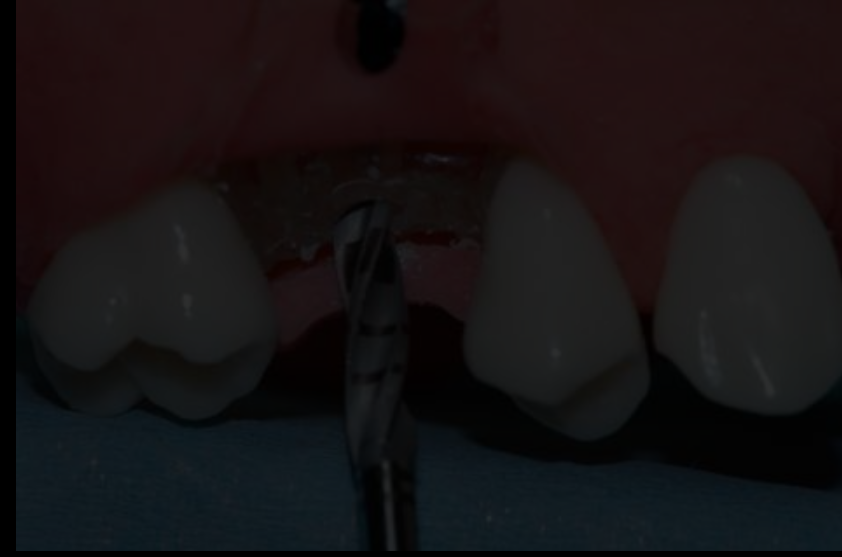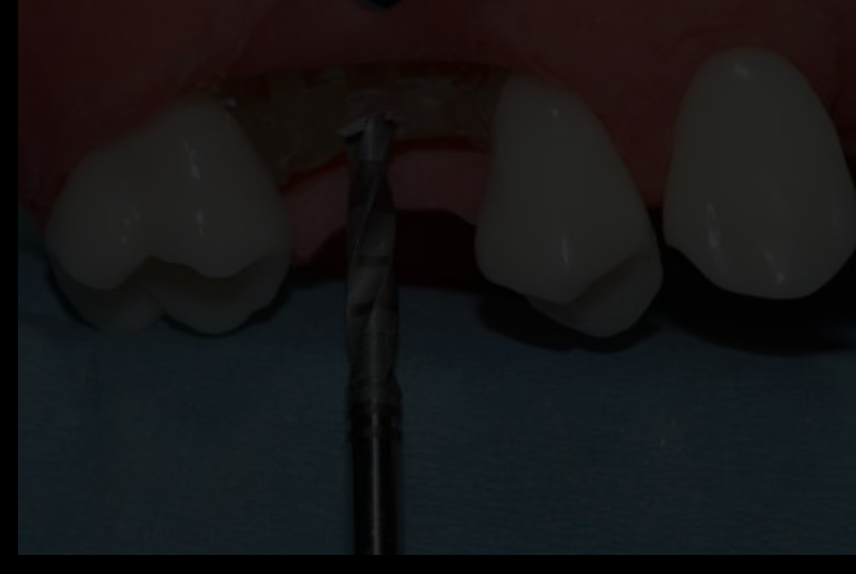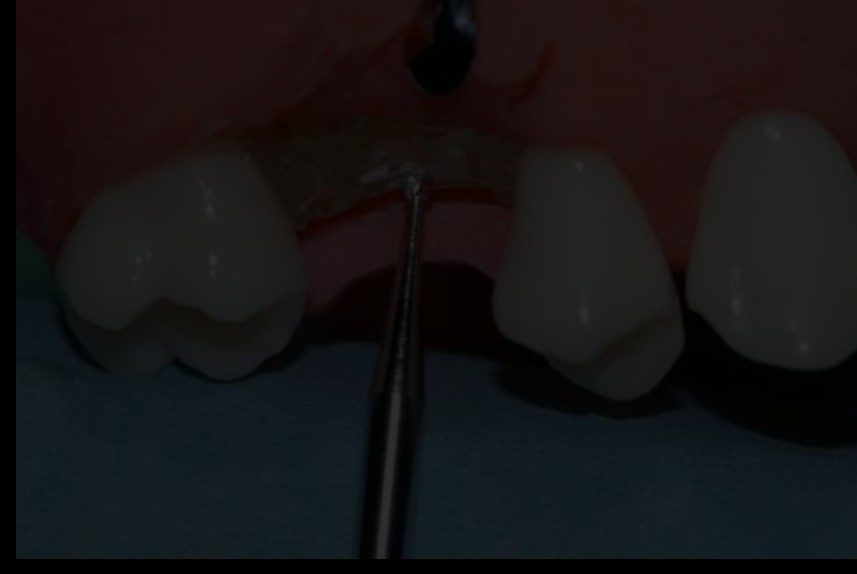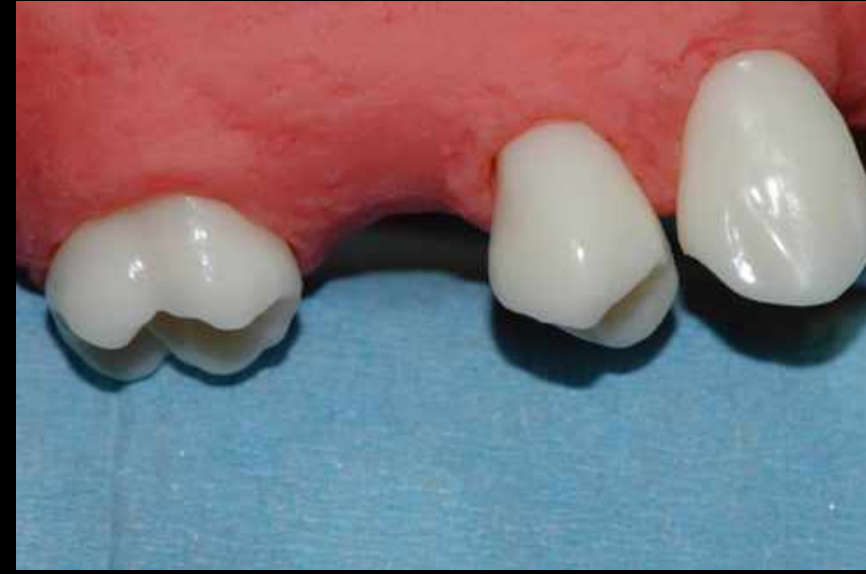Approche Crestale

Summers Modifiée



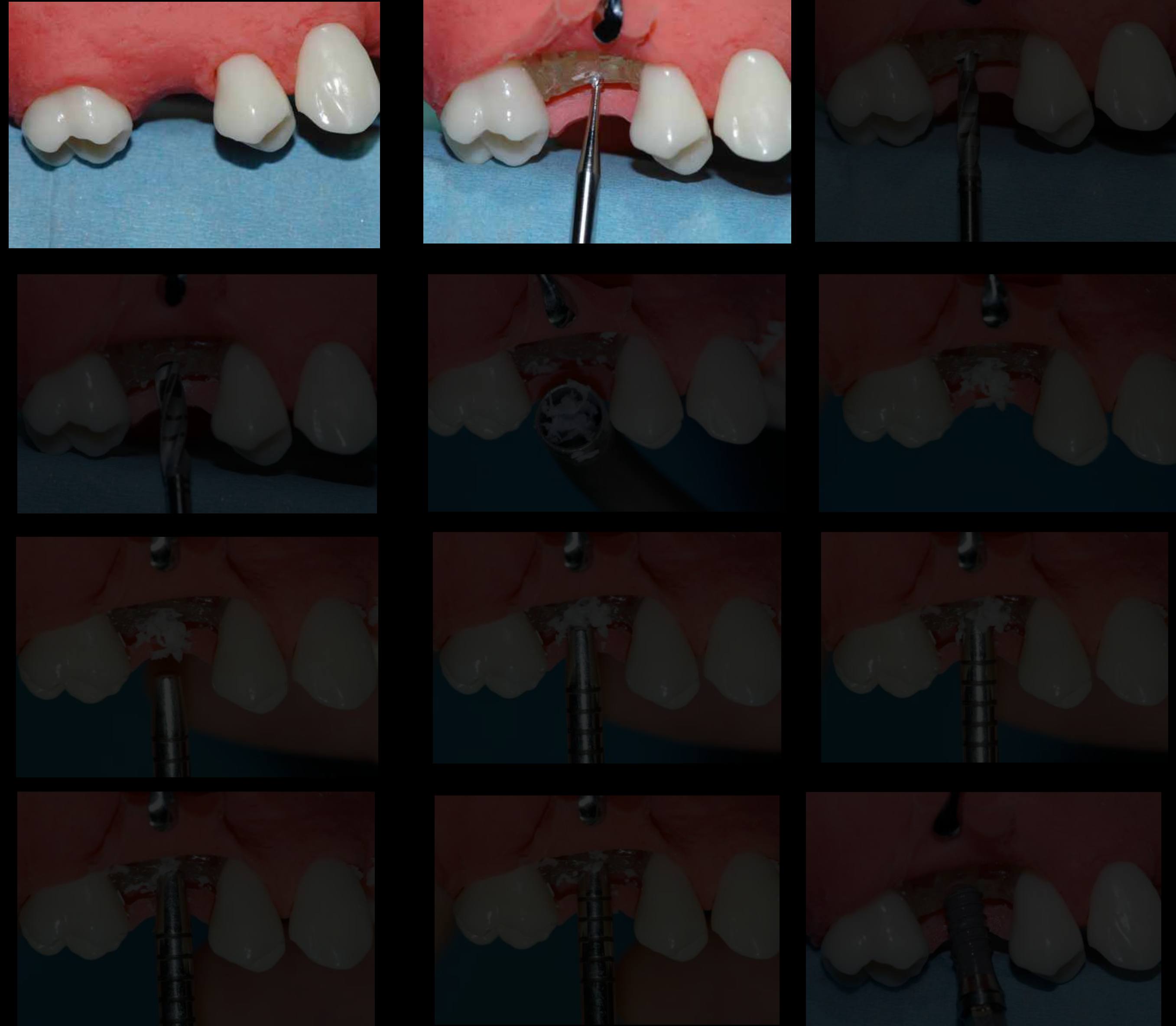
Approche Crestale

Summers Modifiée



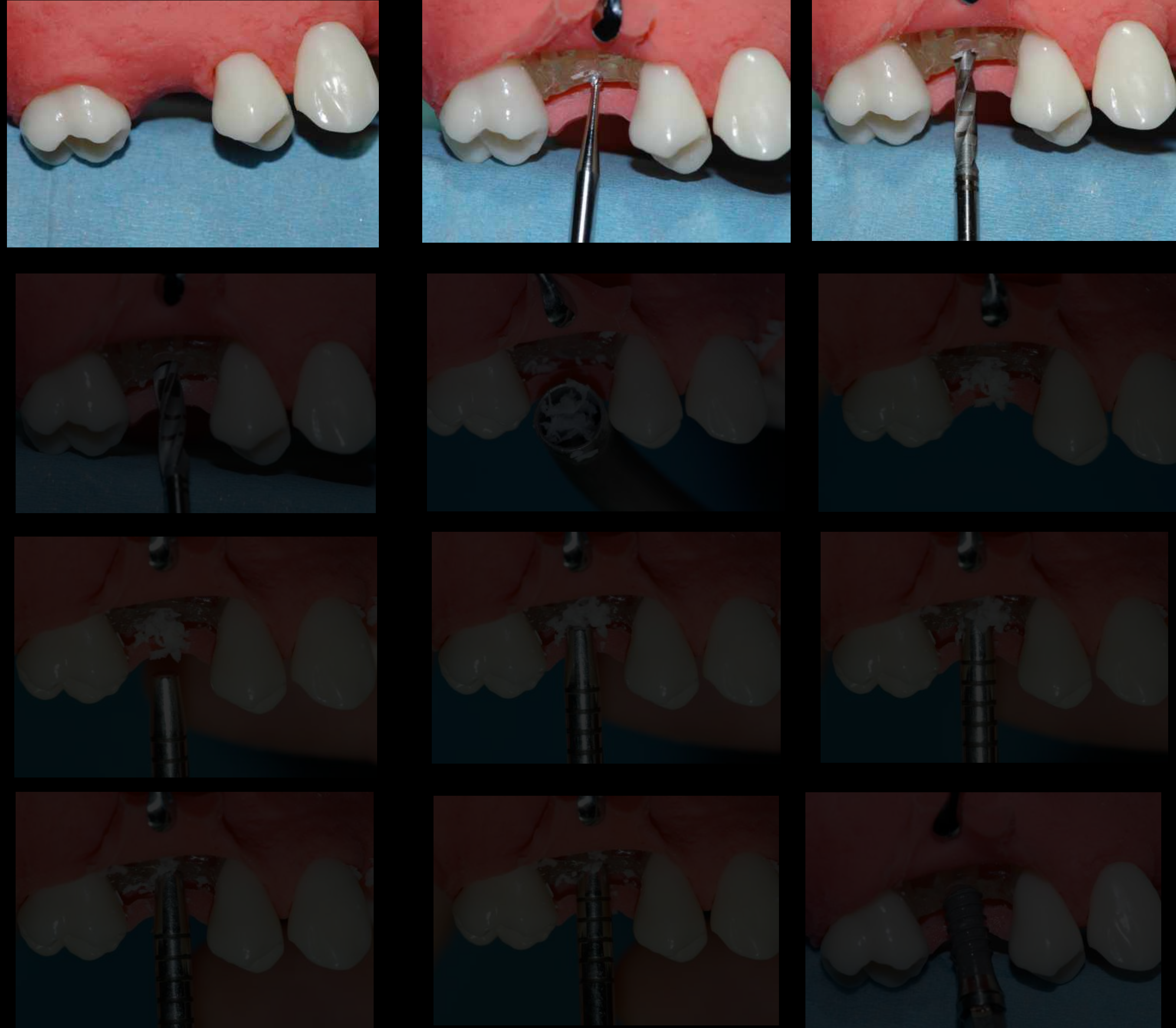
Approche Crestale

Summers Modifiée



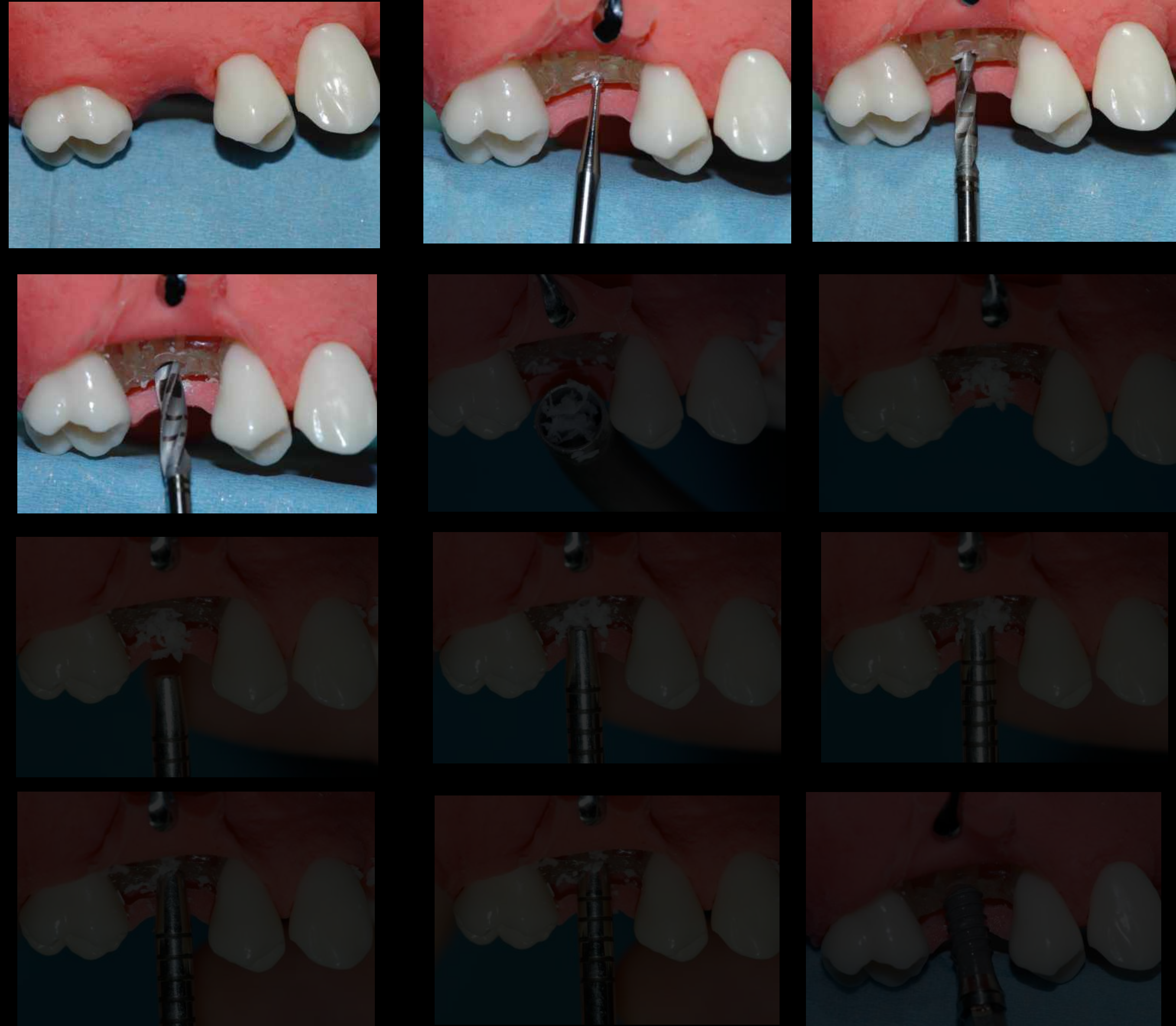
Approche Crestale

Summers Modifiée



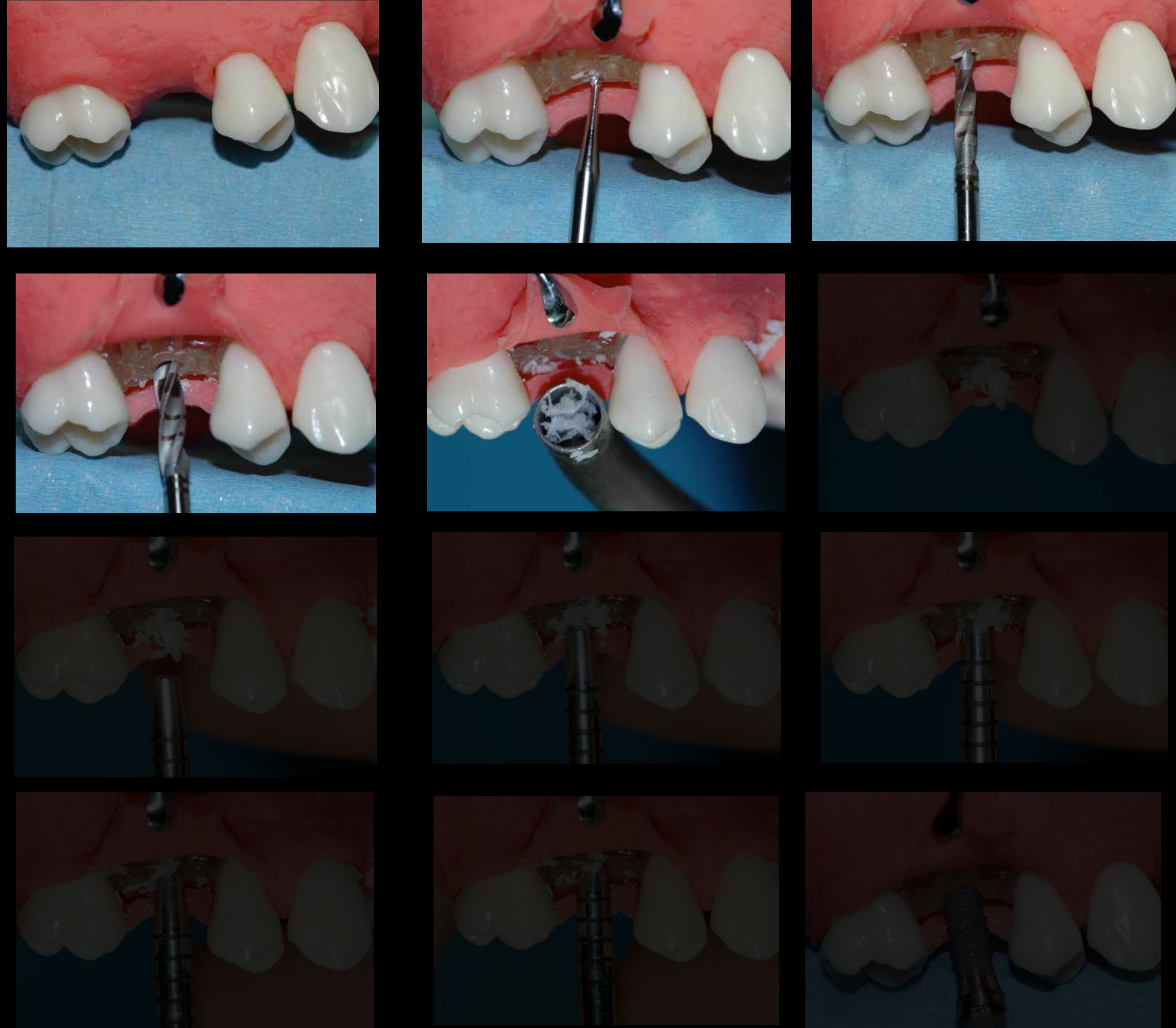
Approche Crestale

Summers Modifiée



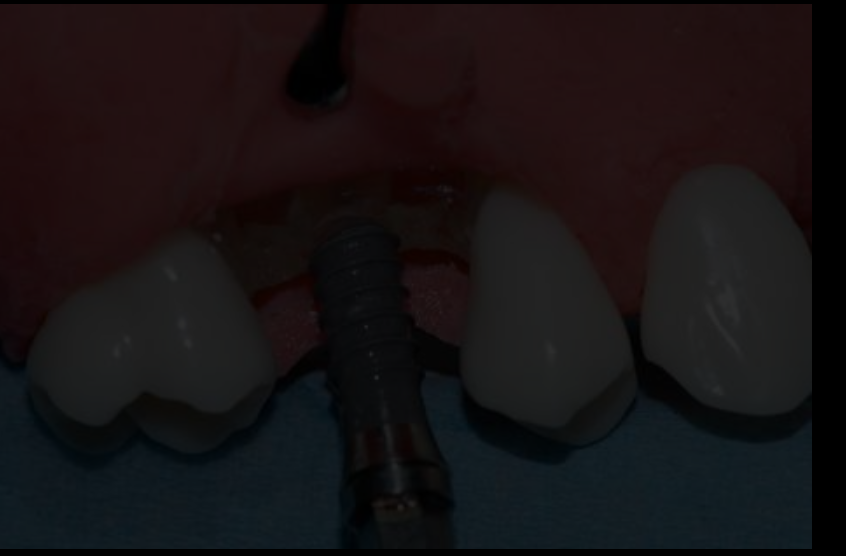
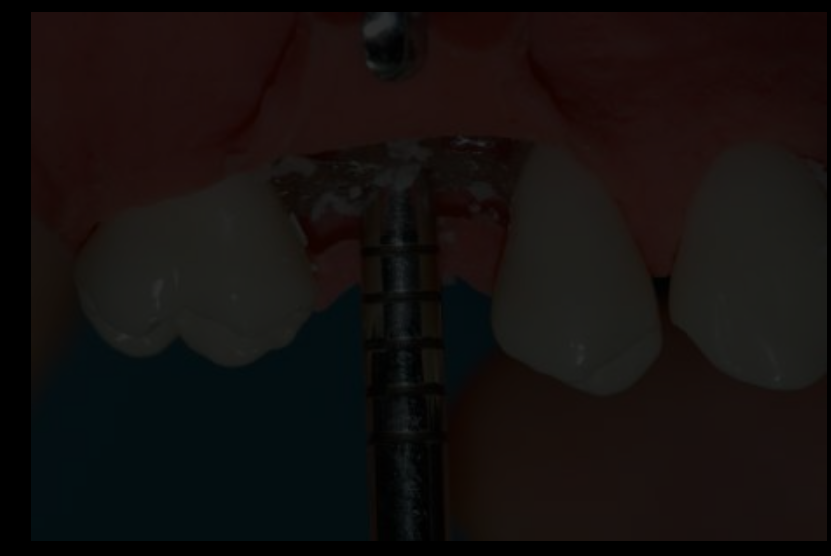
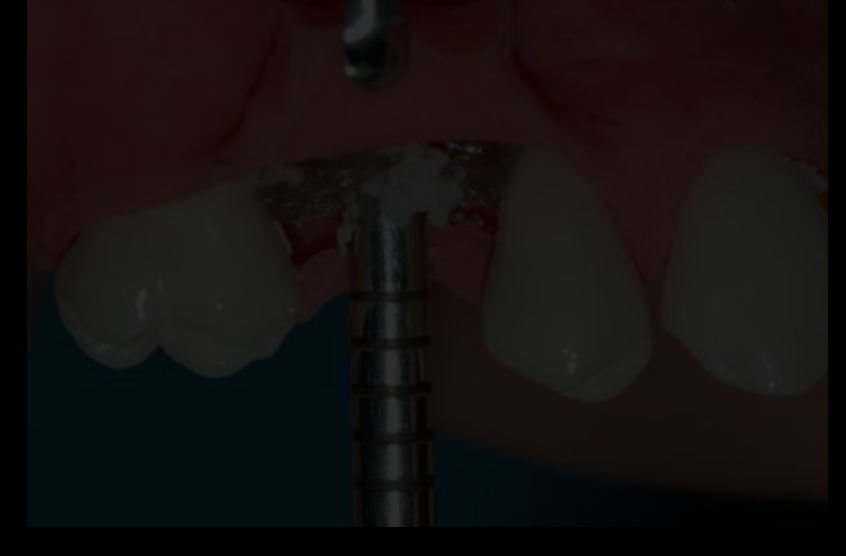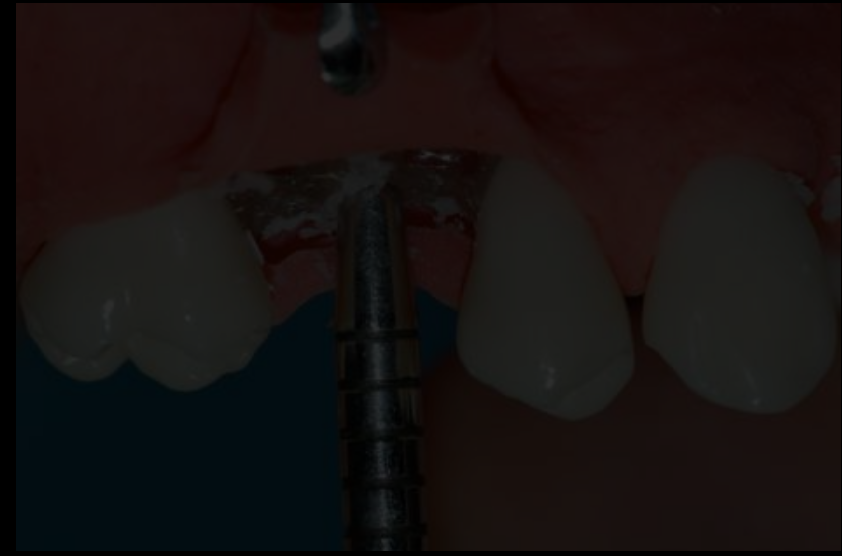
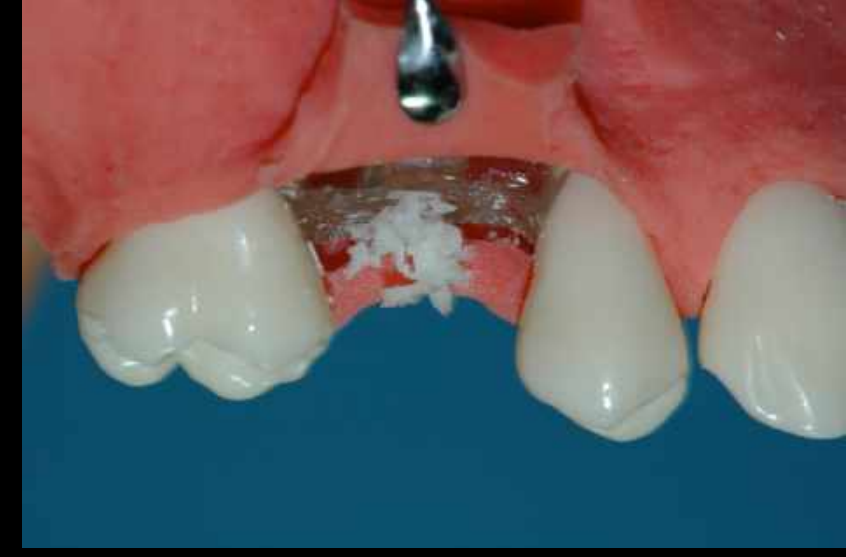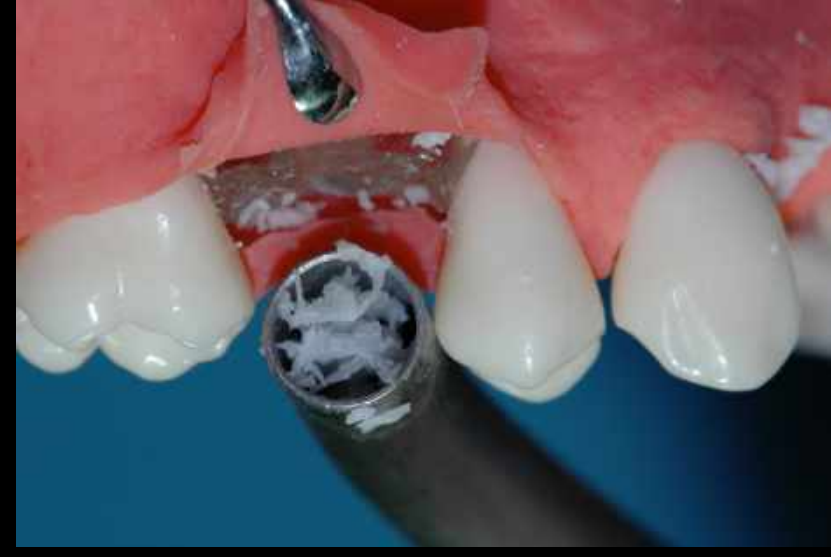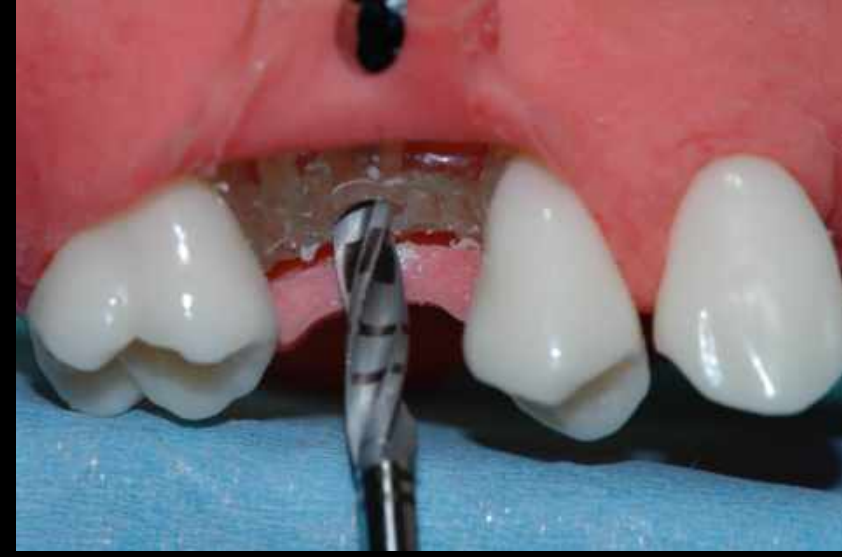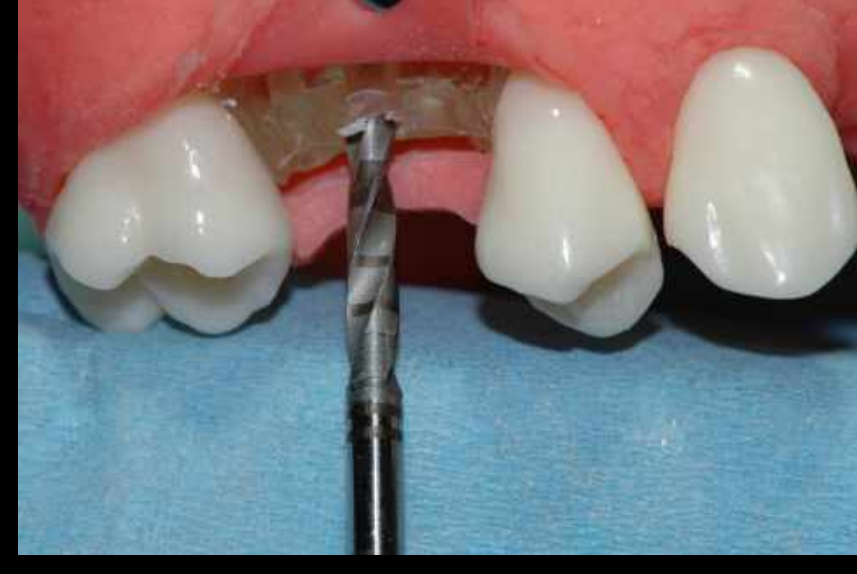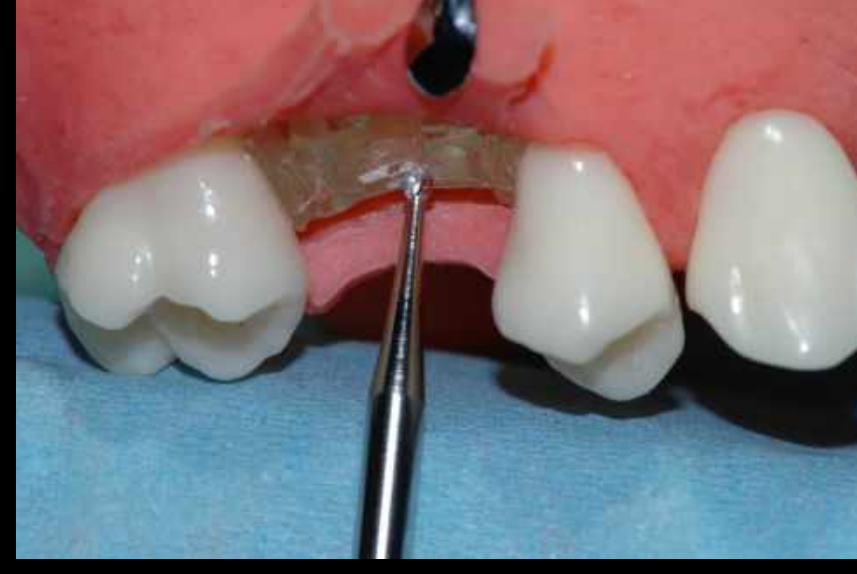Approche Crestale

Summers Modifiée



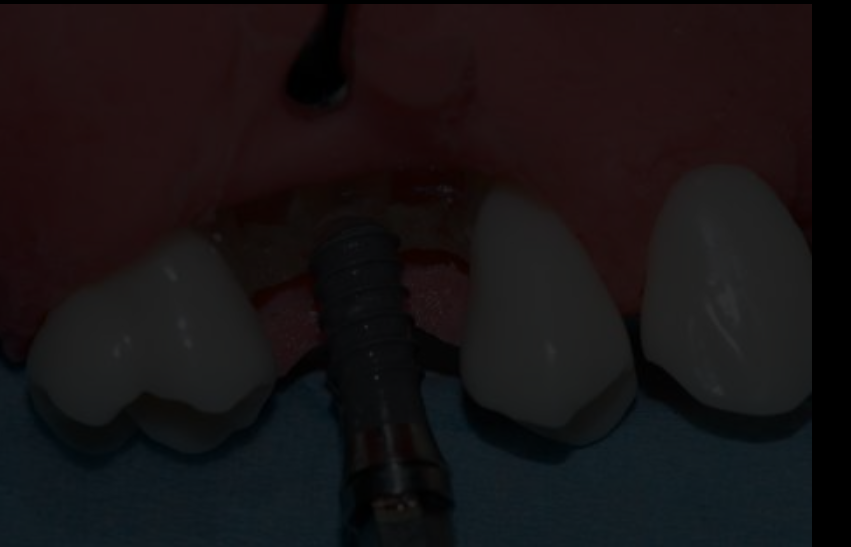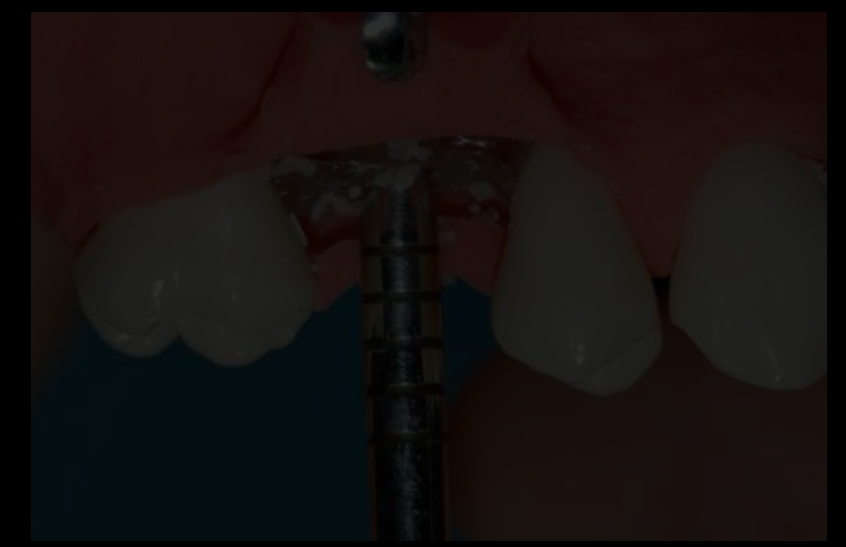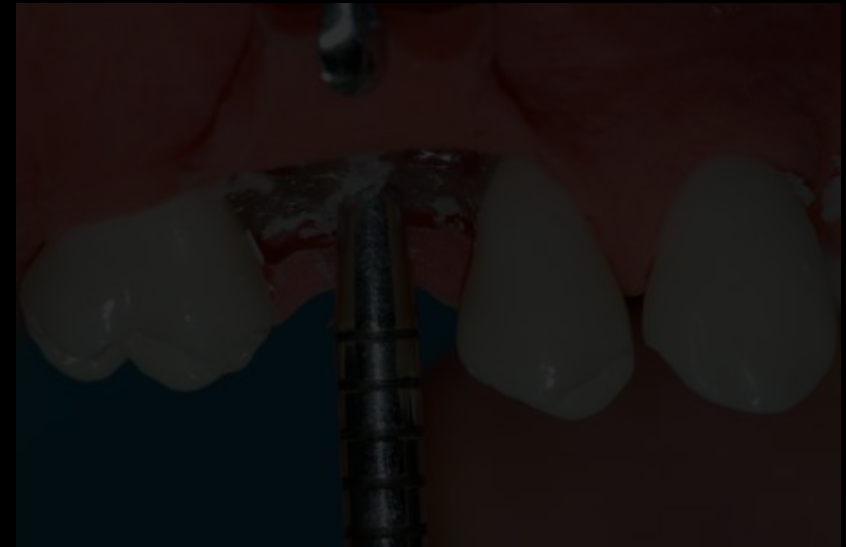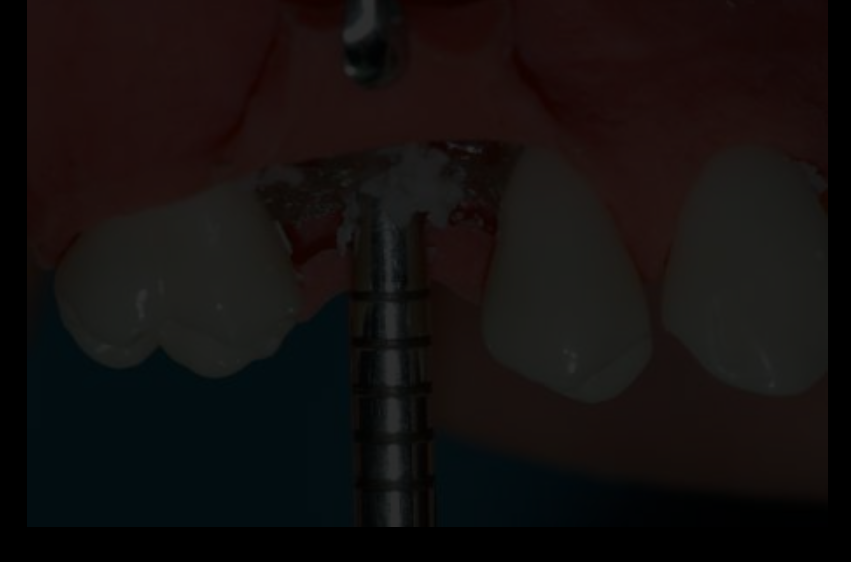
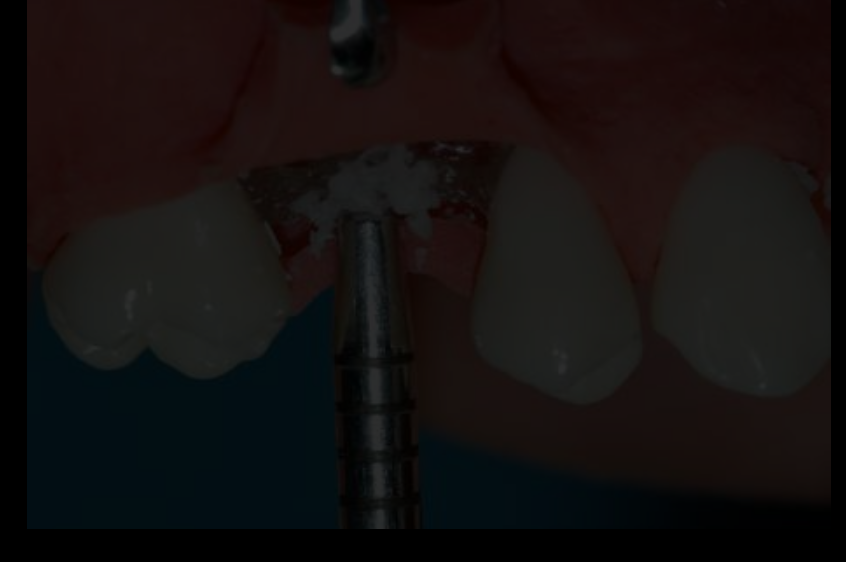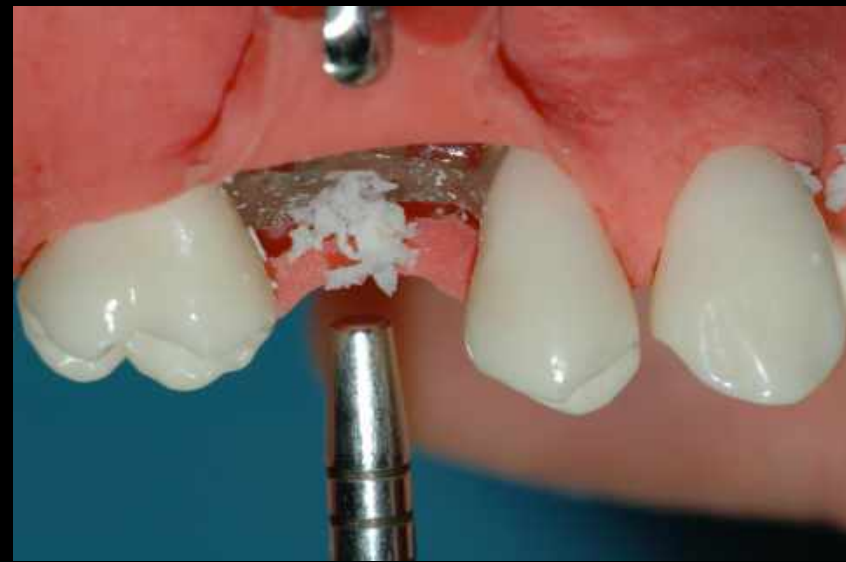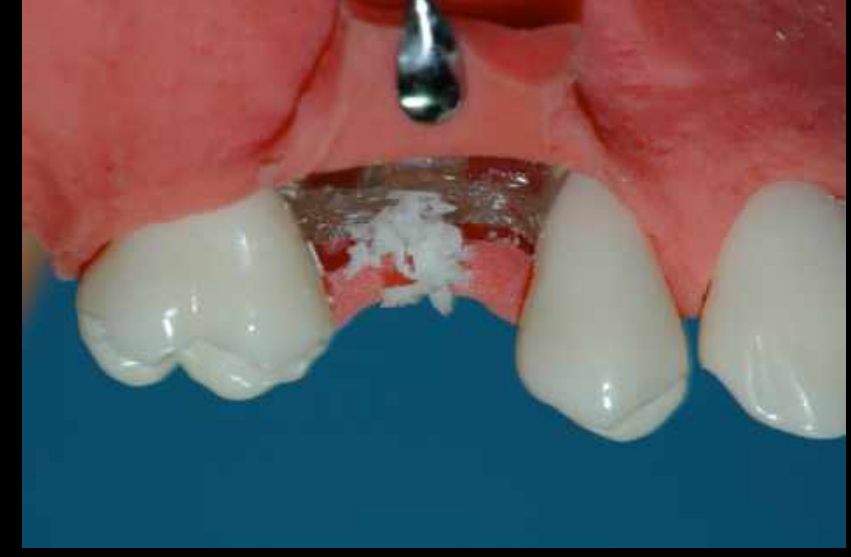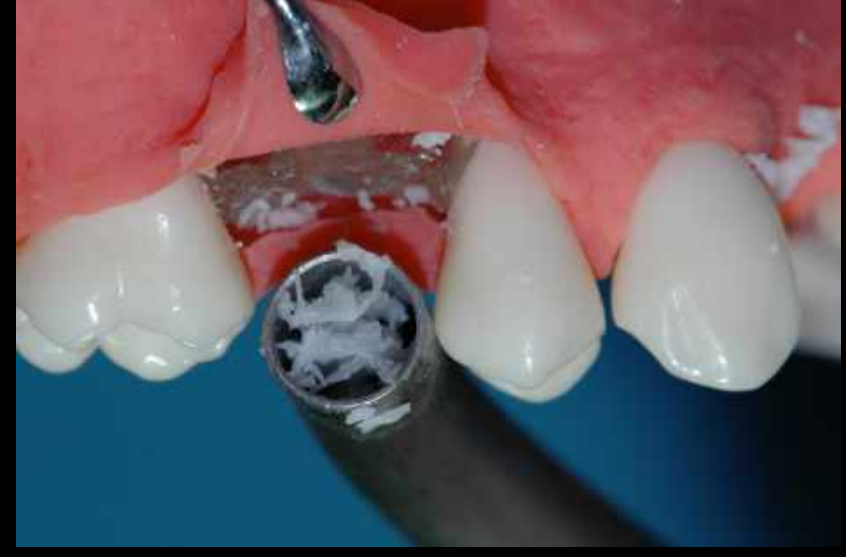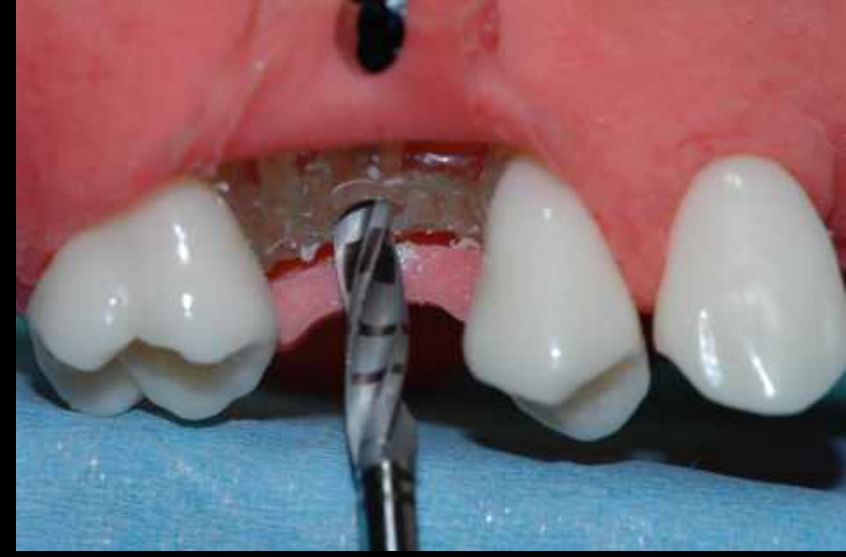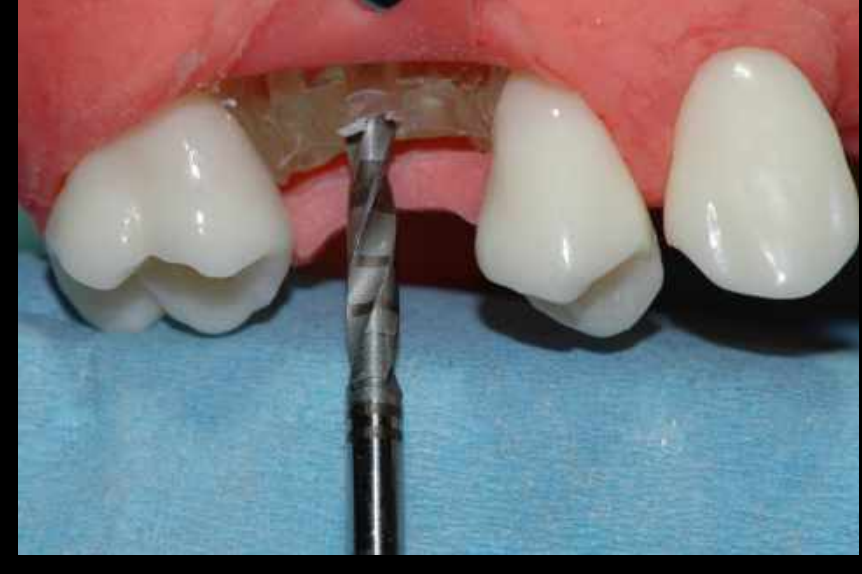Approche Crestale

Summers Modifiée



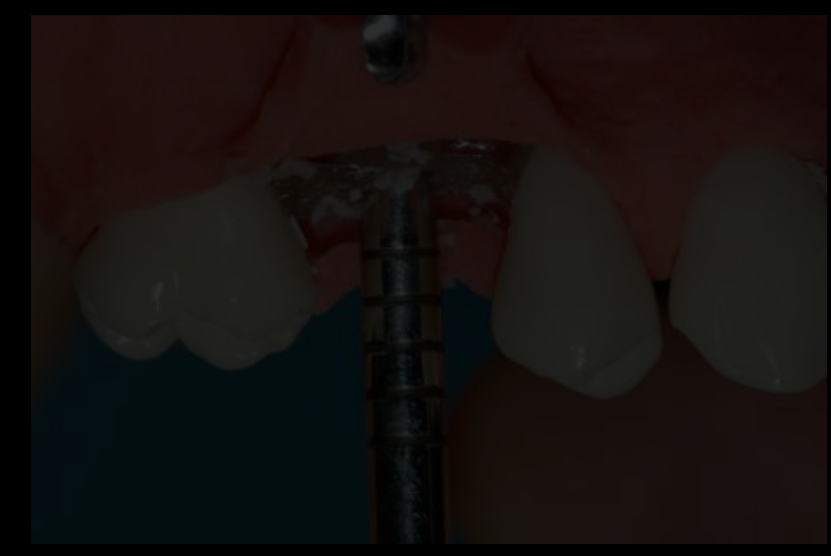
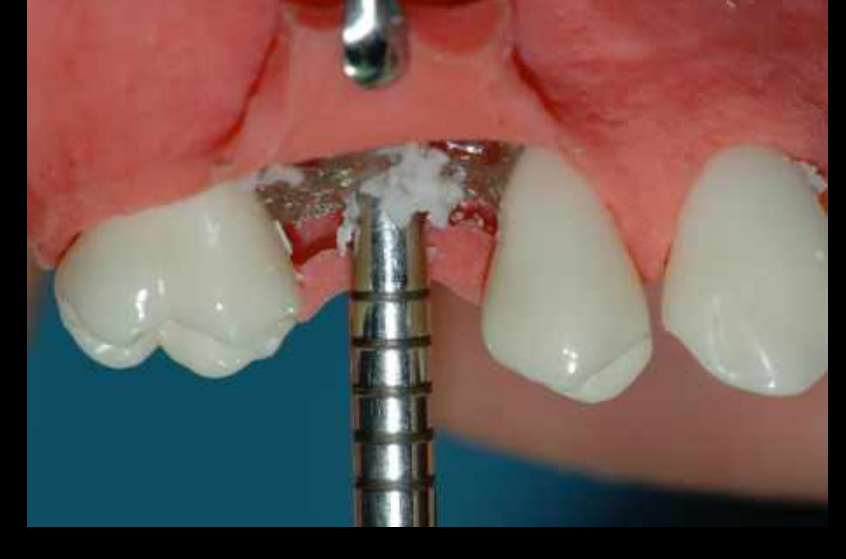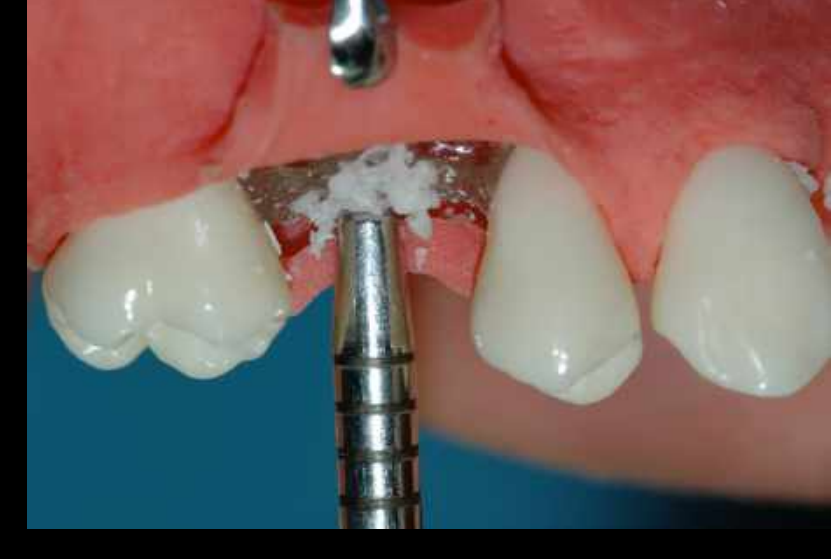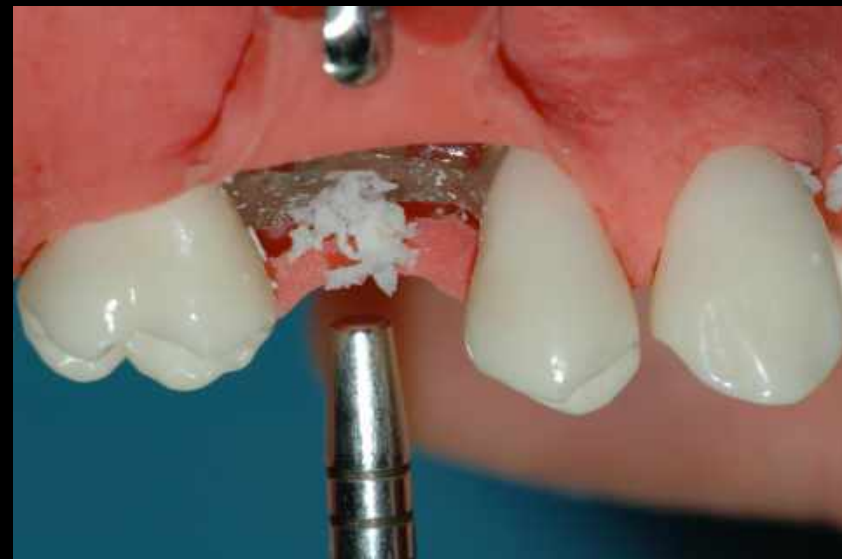Approche Crestale

Summers Modifiée



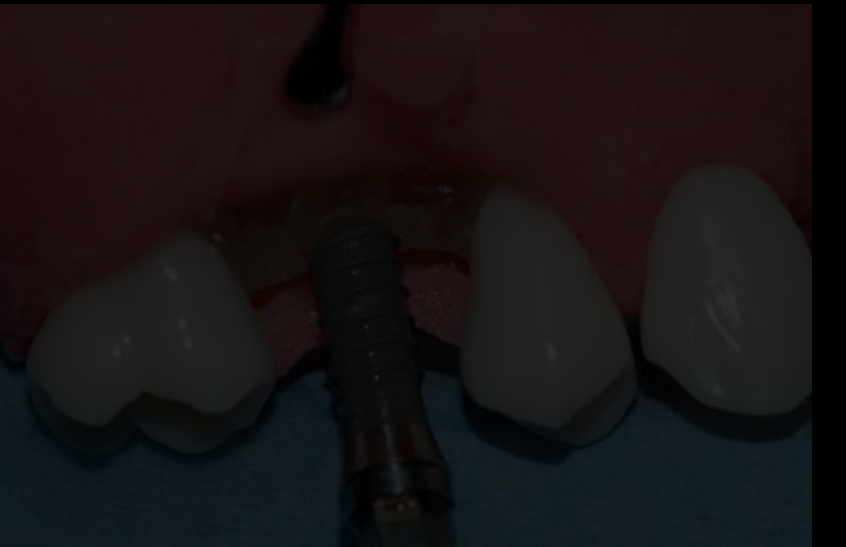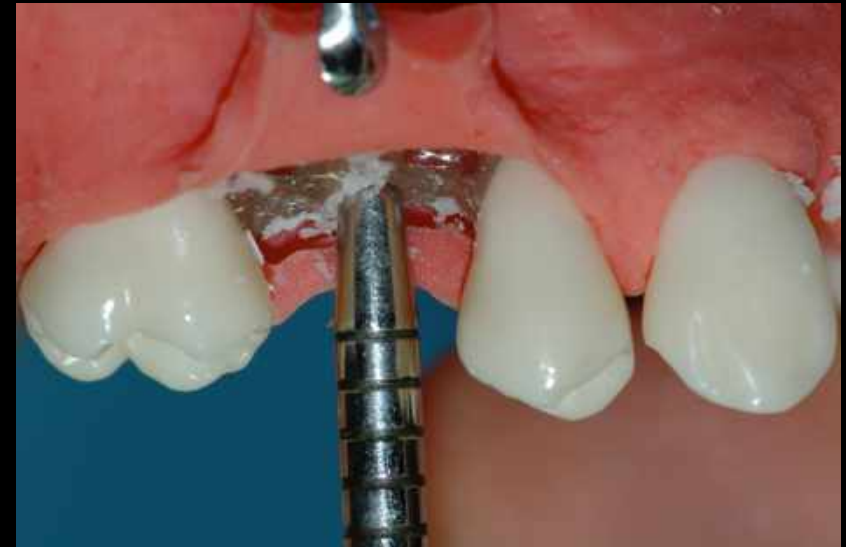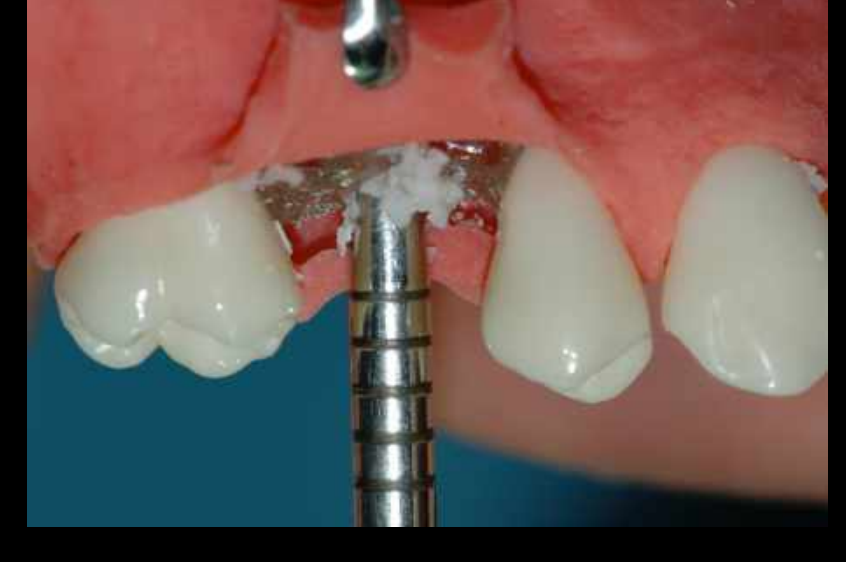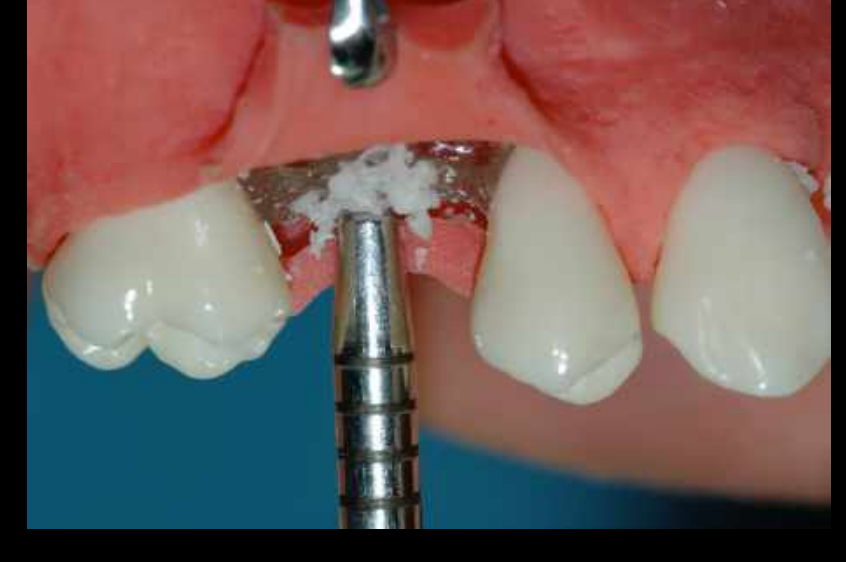Approche Crestale

Summers Modifiée



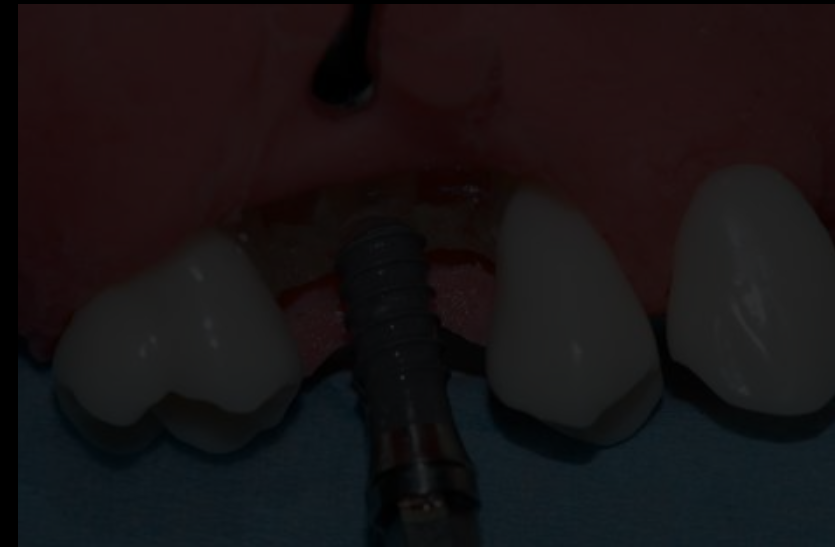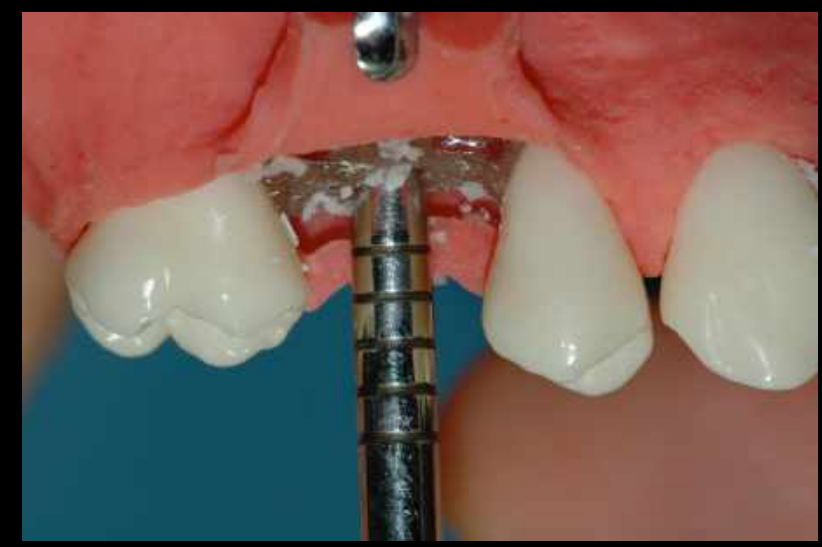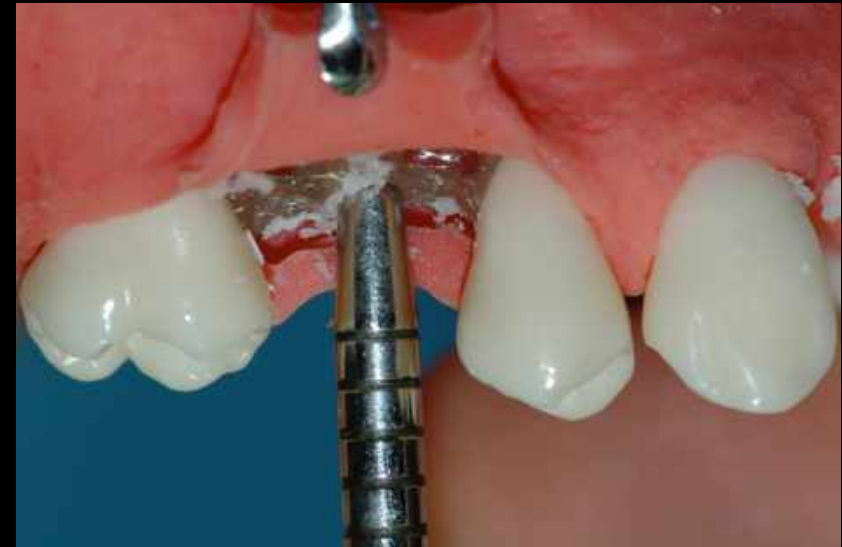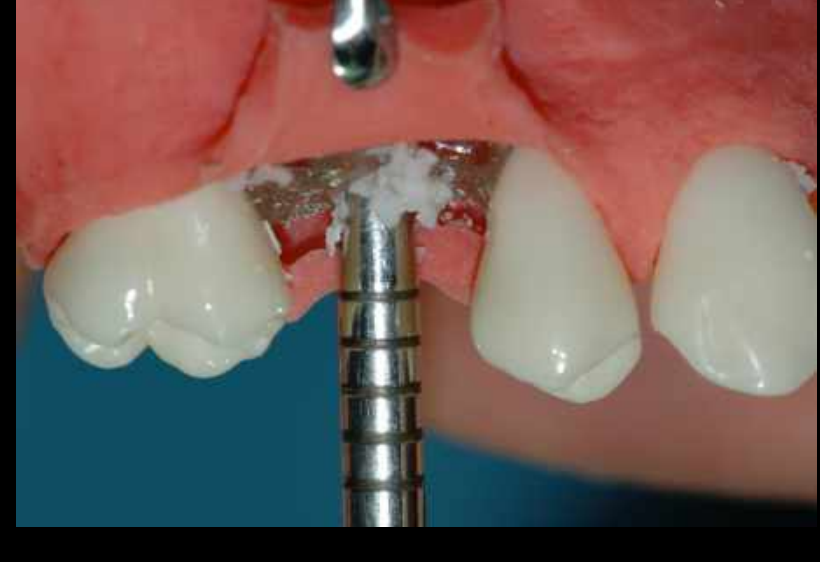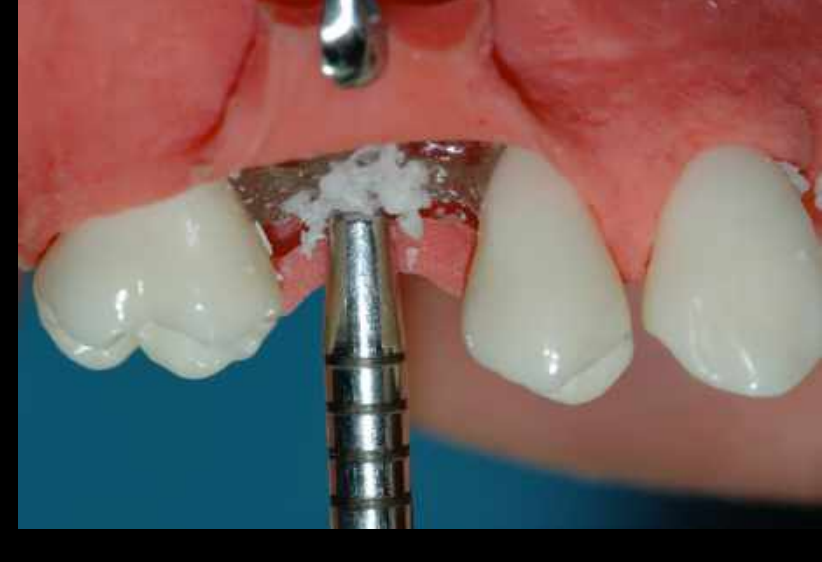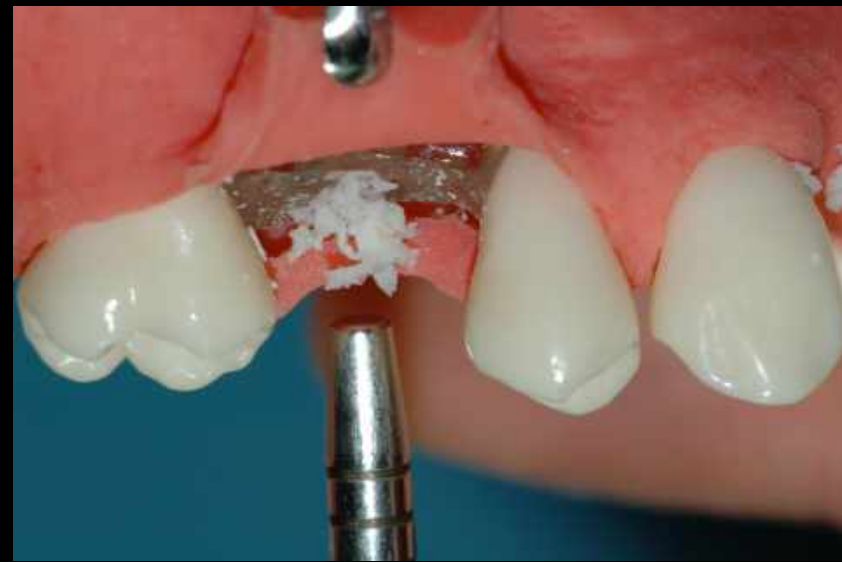Approche Crestale

Summers Modifiée



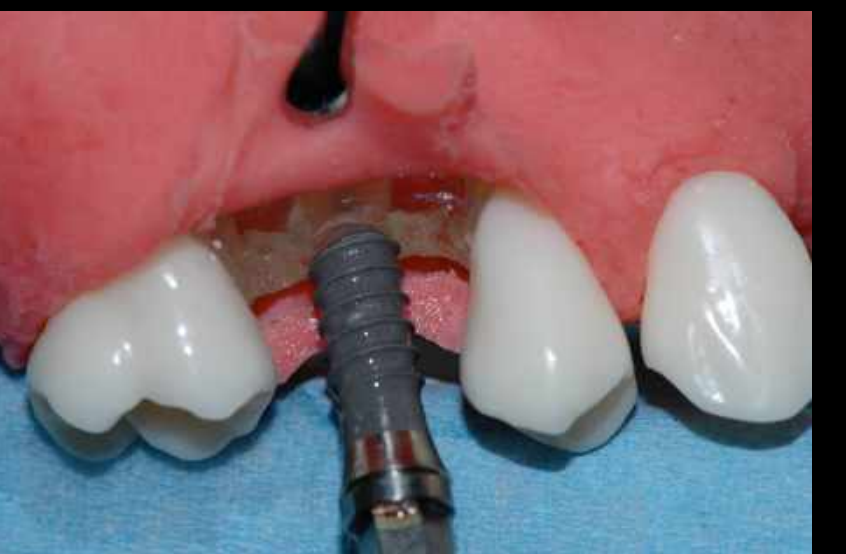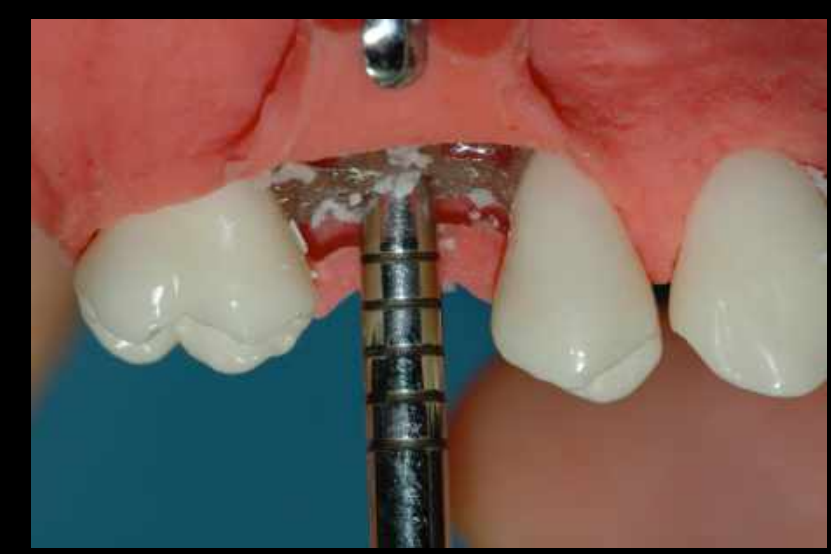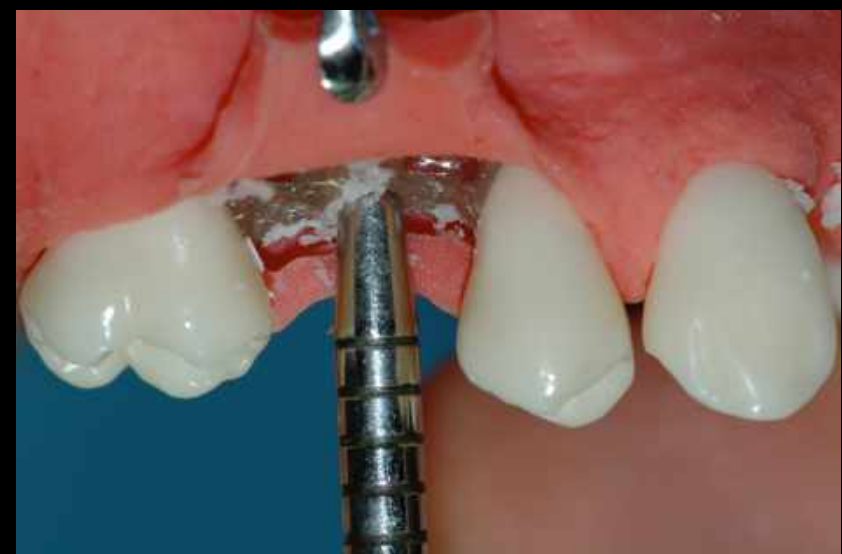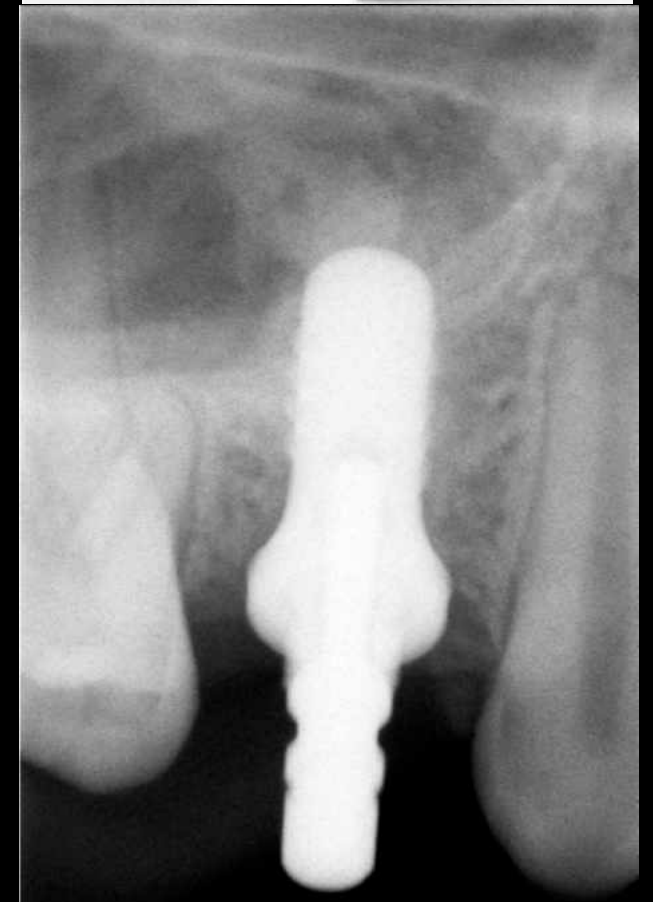
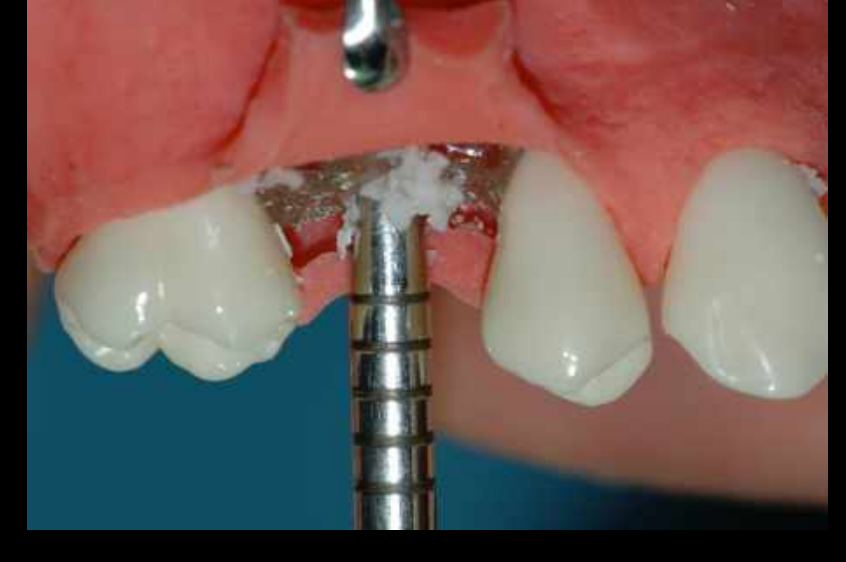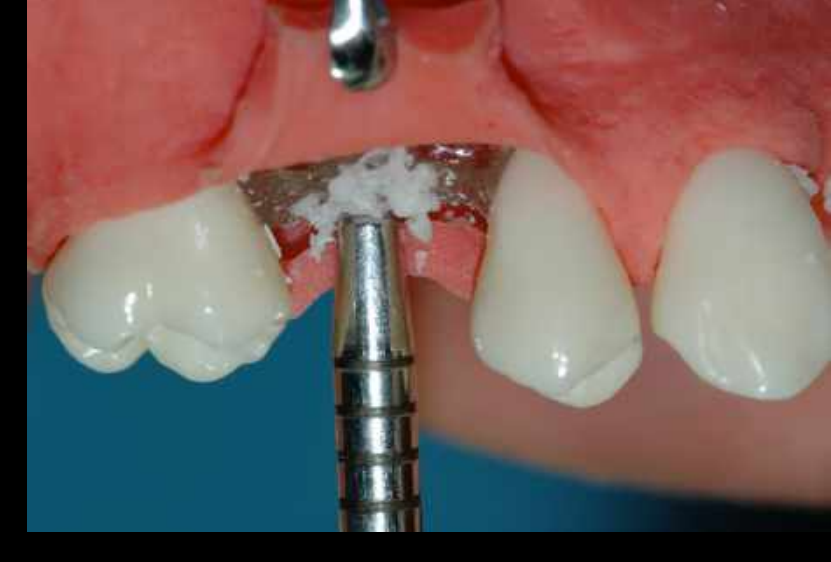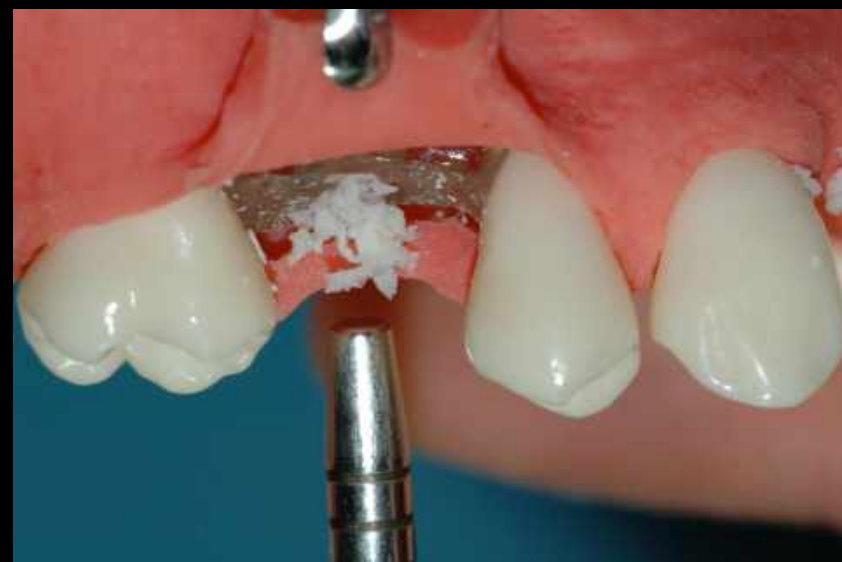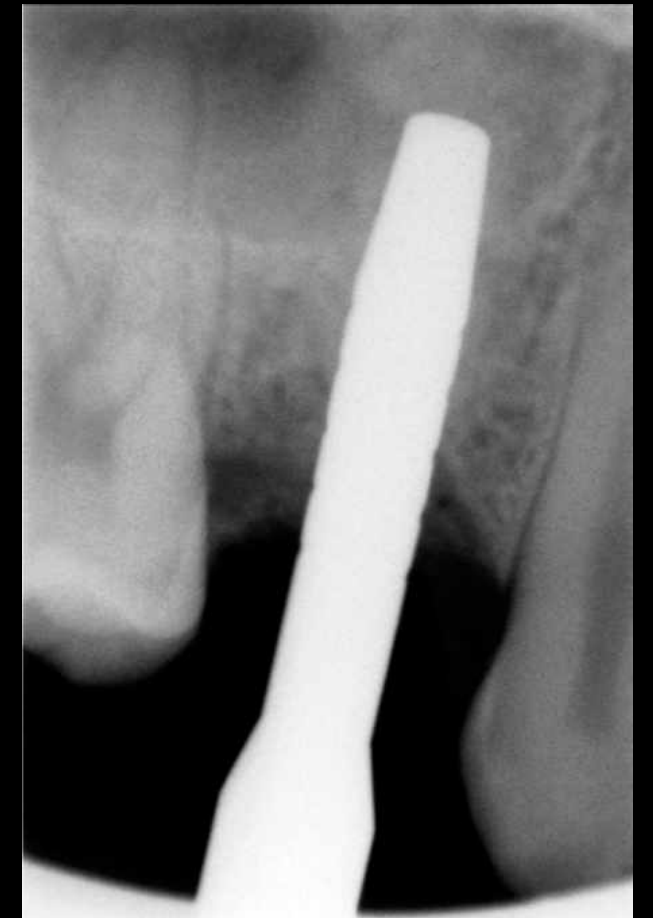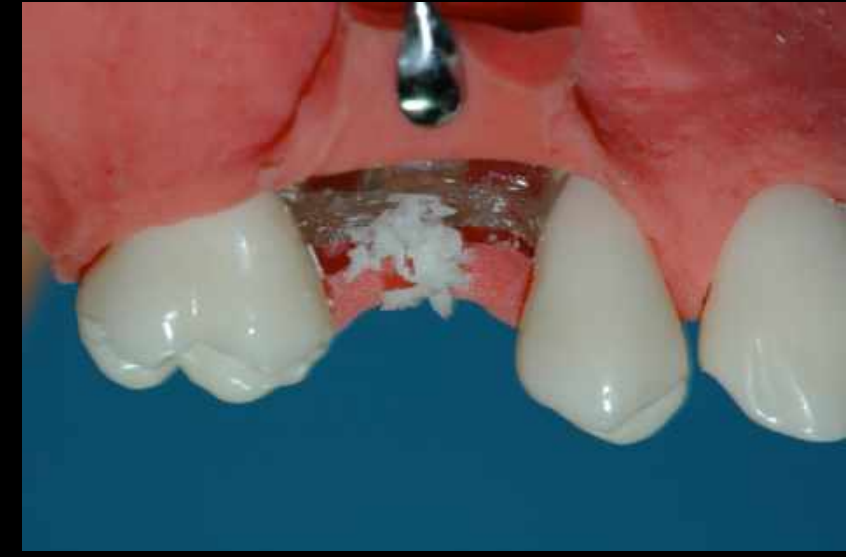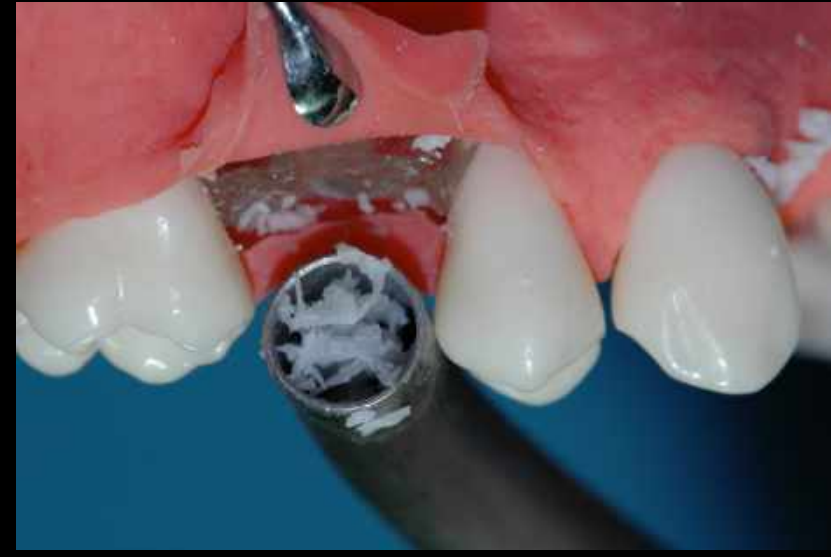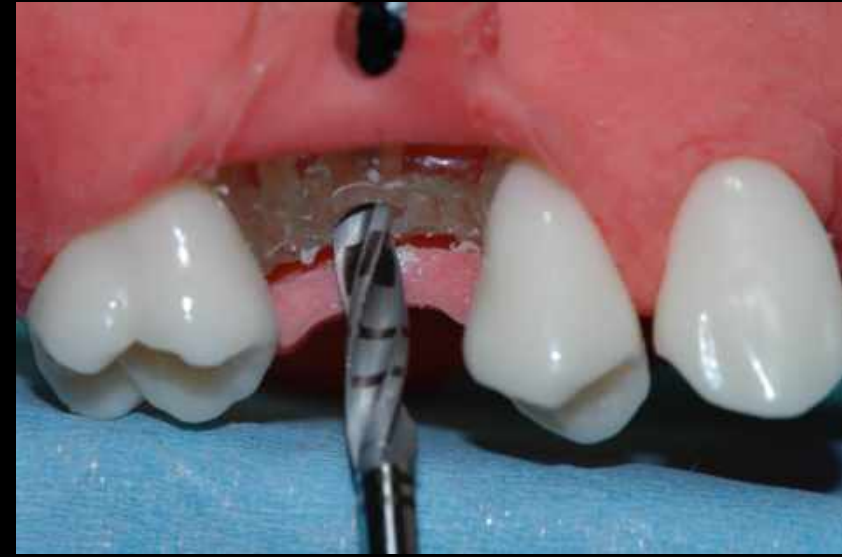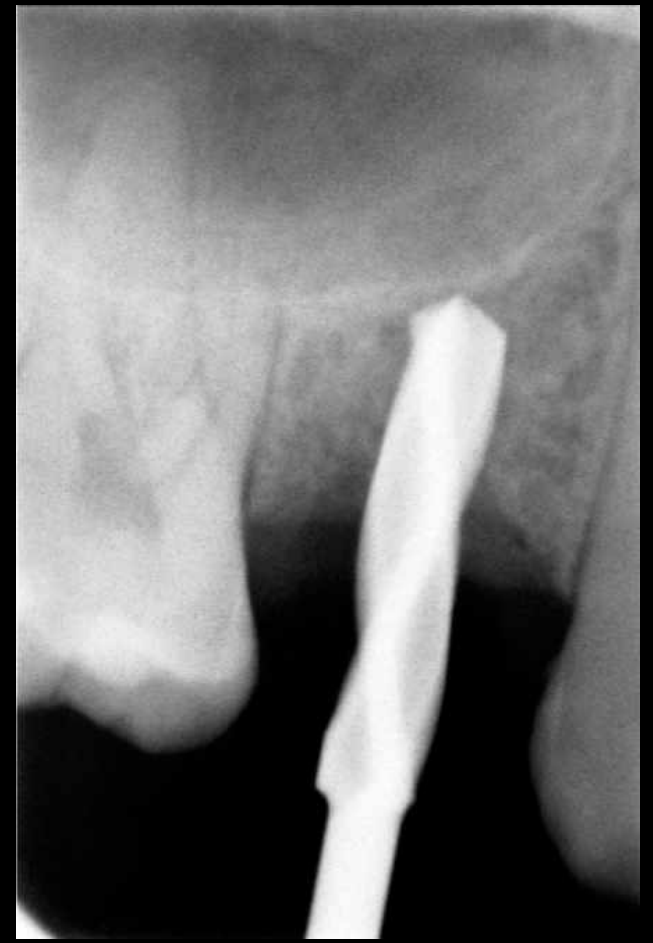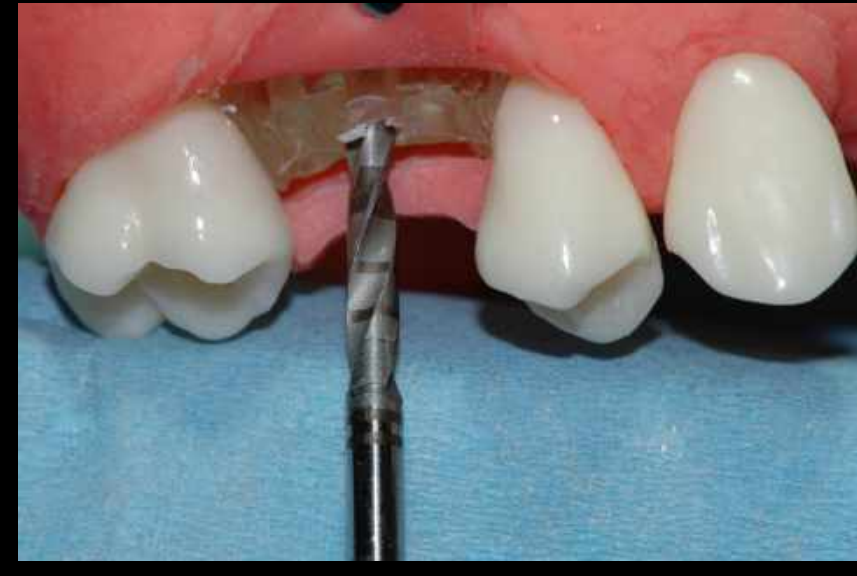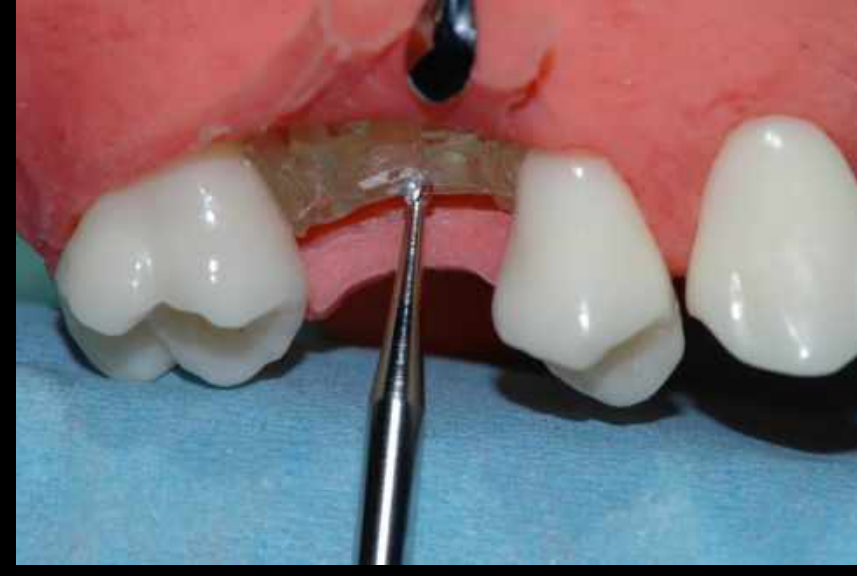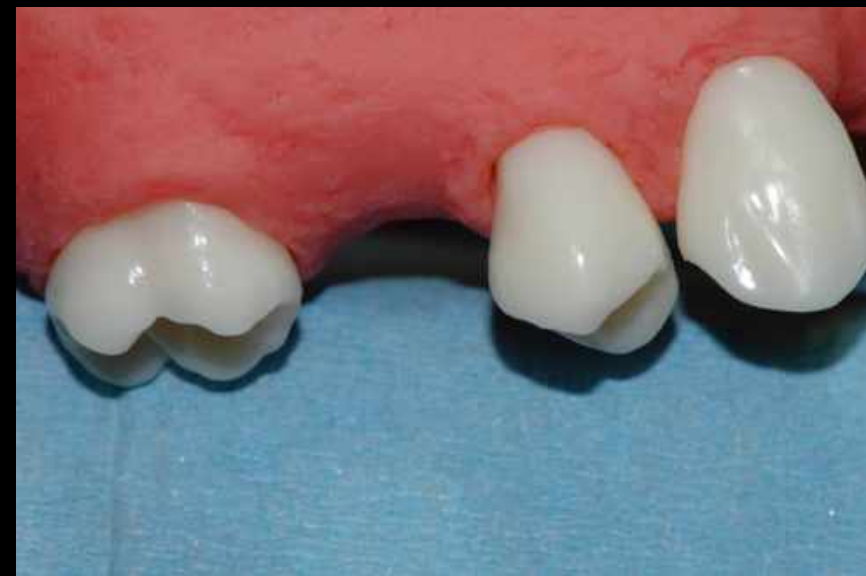Approche Crestale

Summers Modifiée



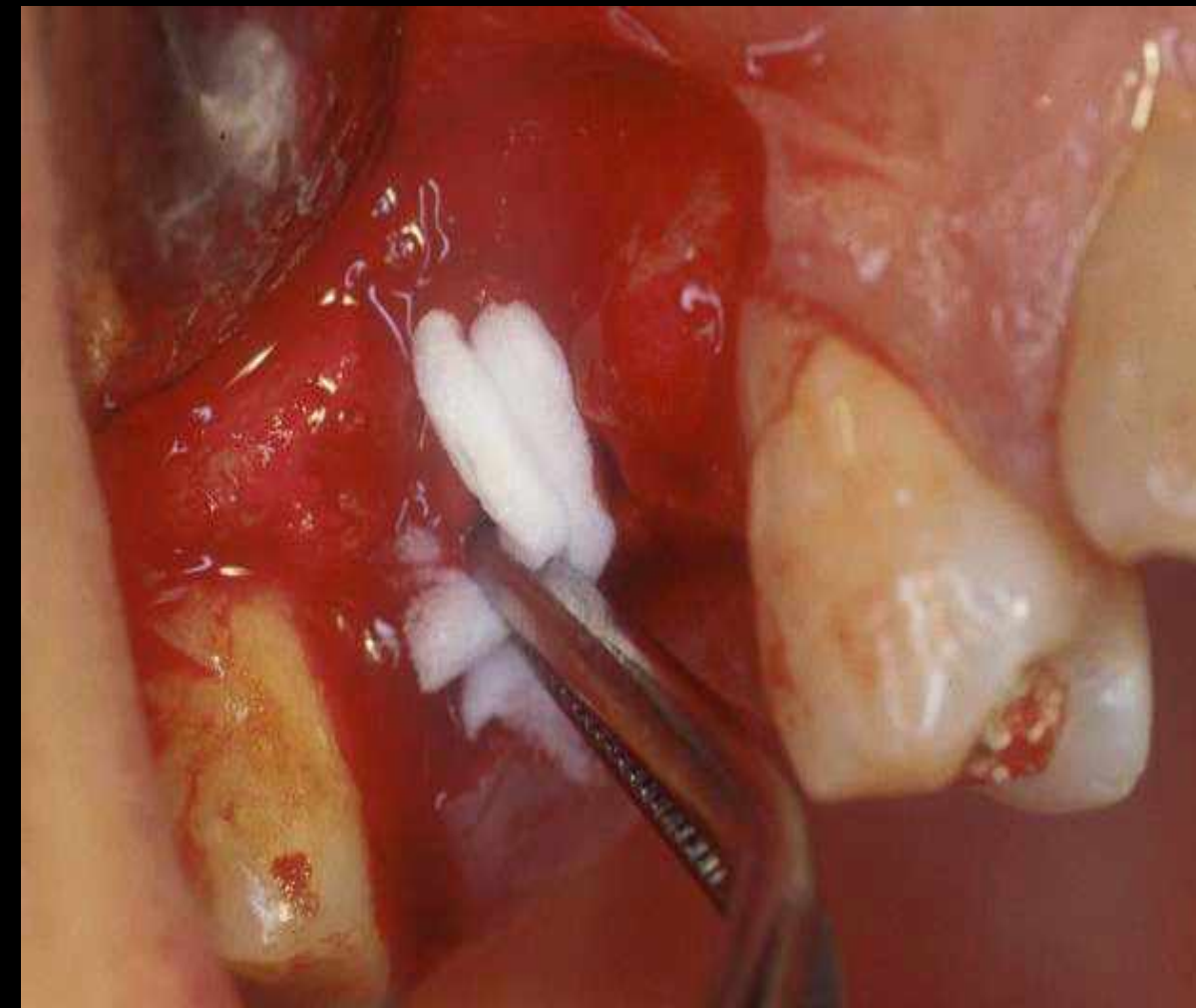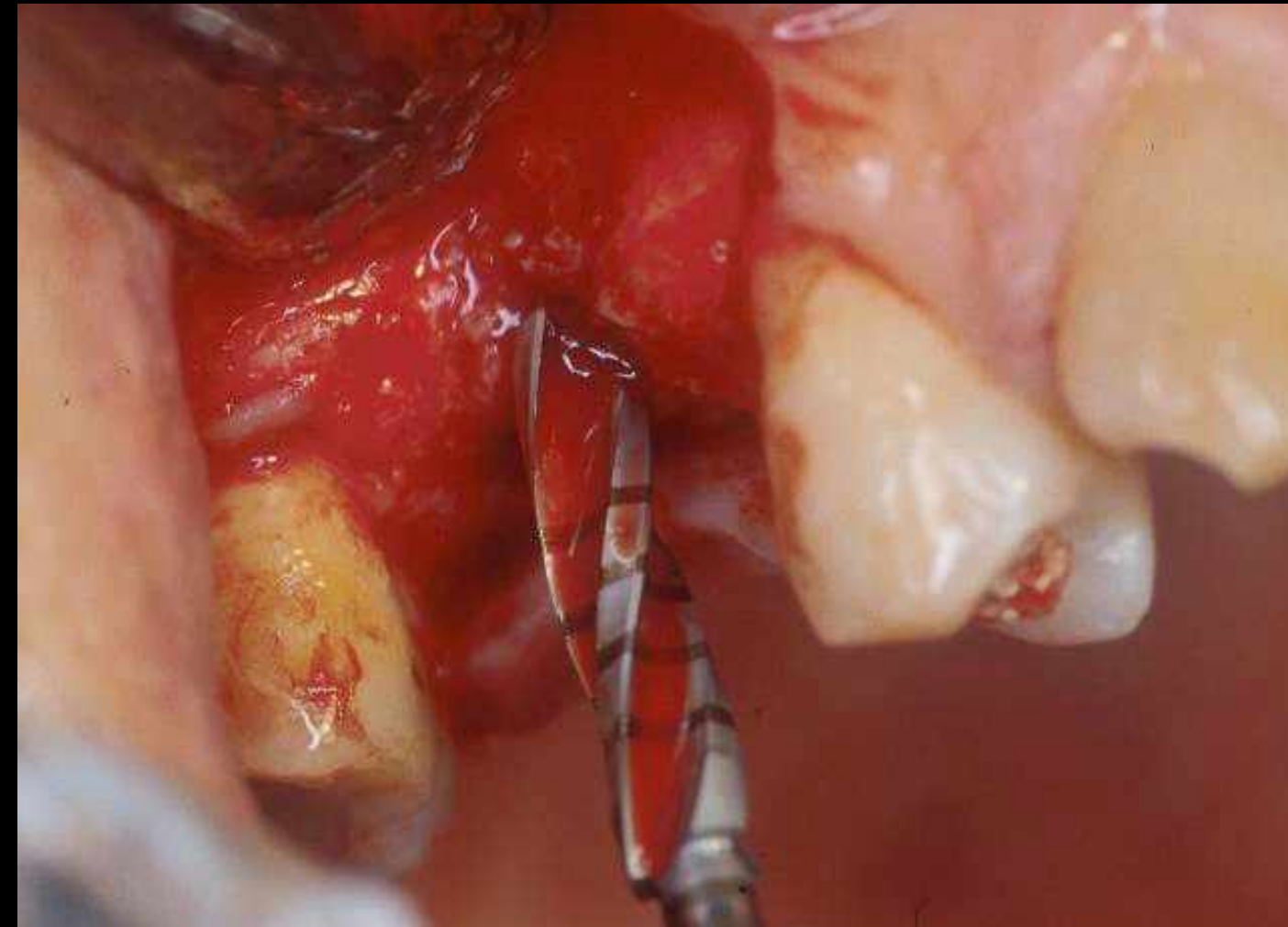
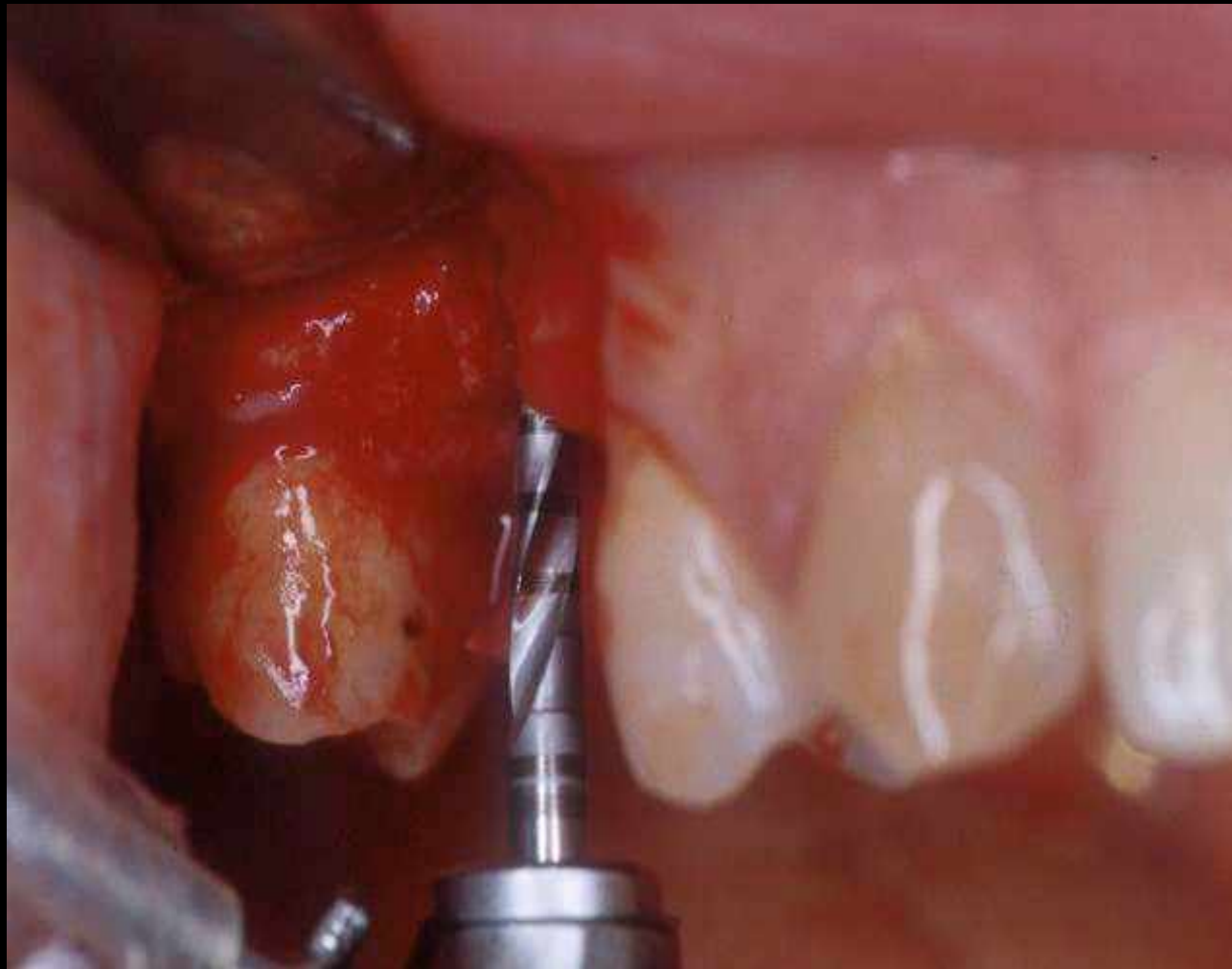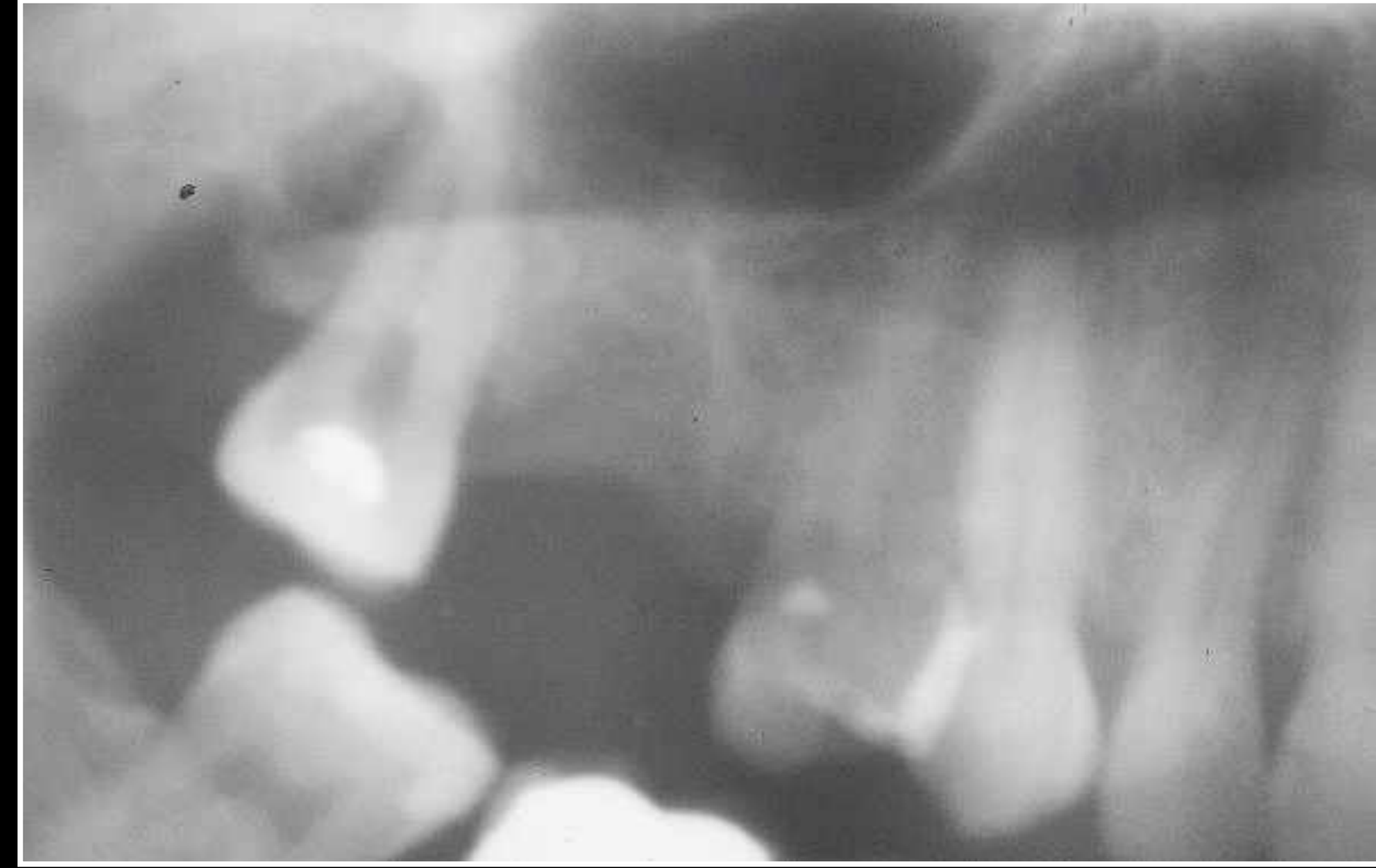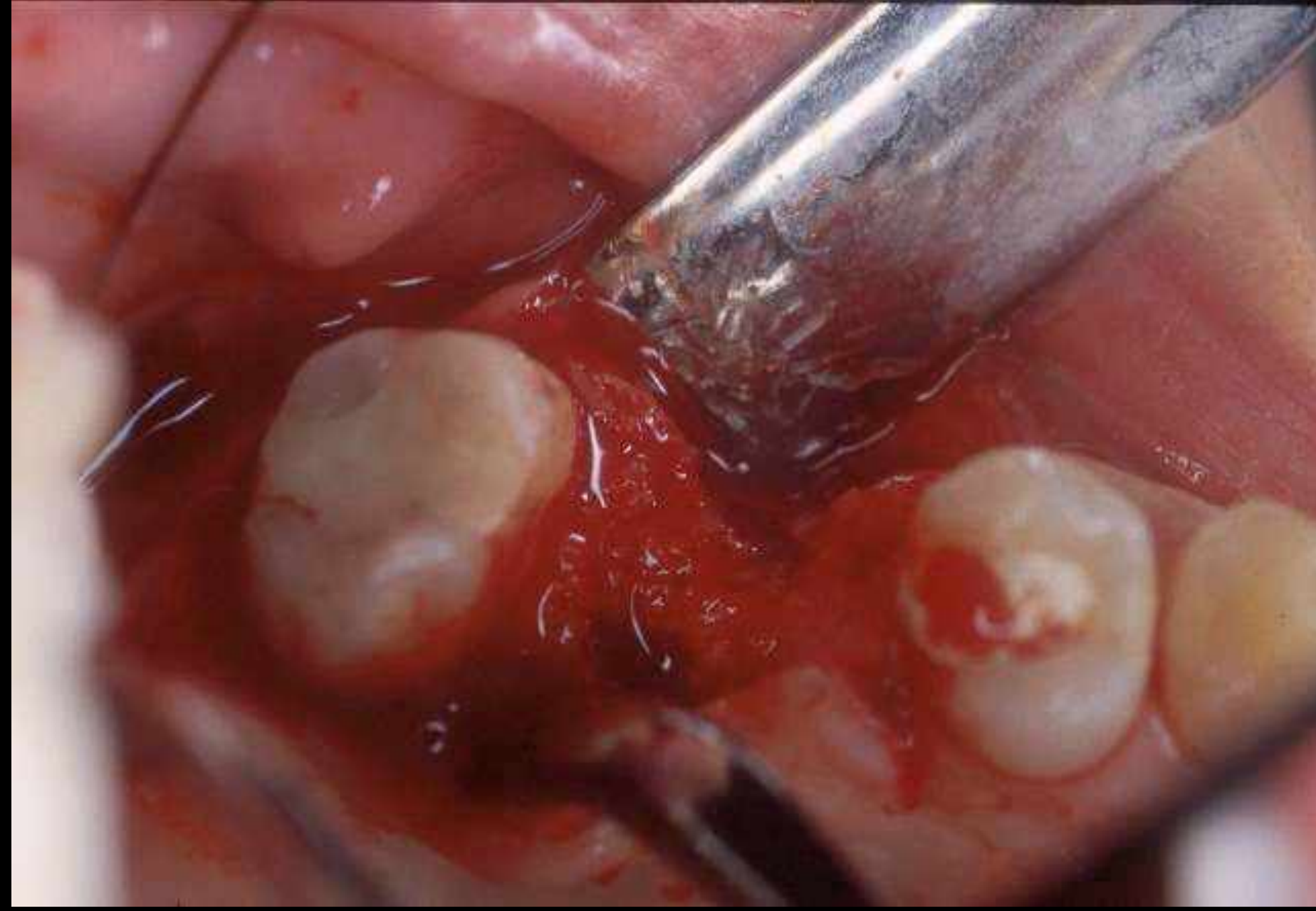
Approche Crestale

Summers Modifiée



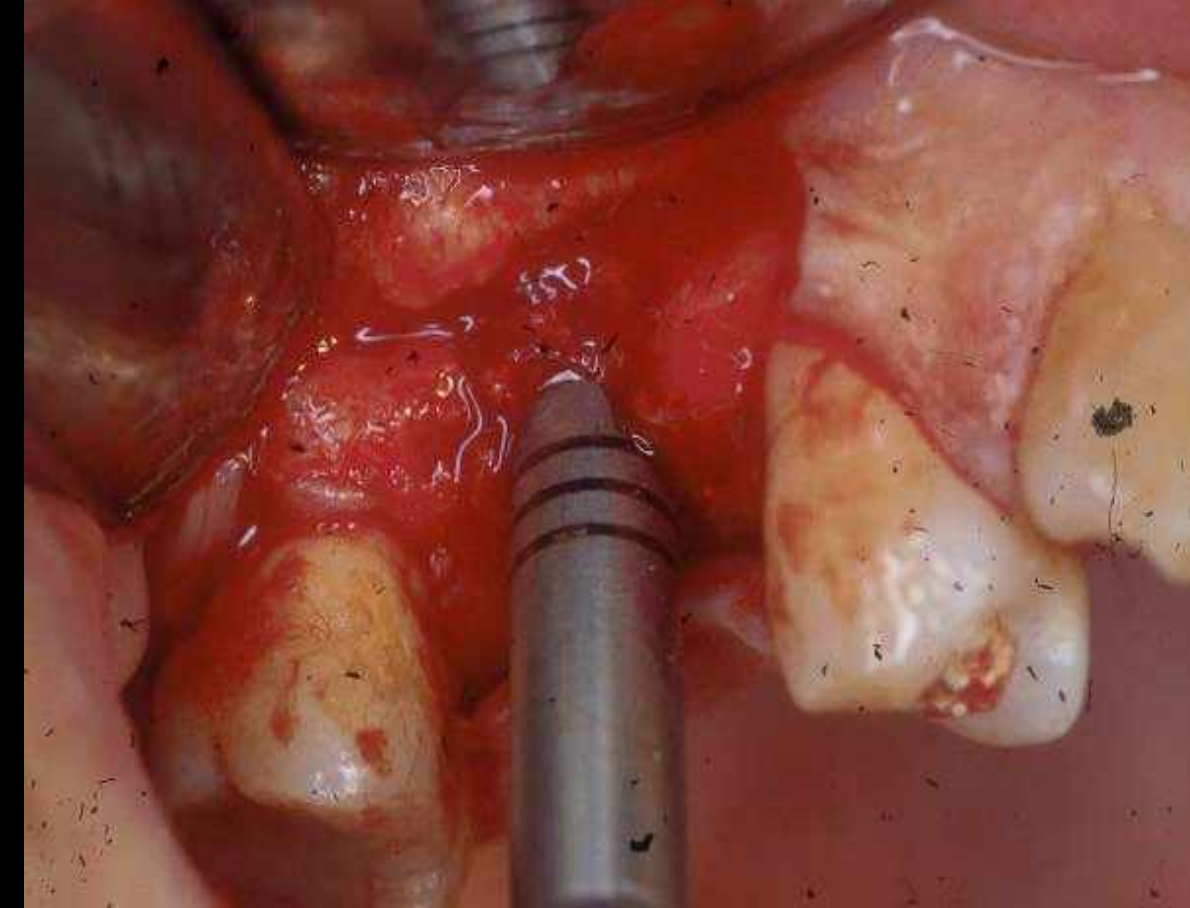
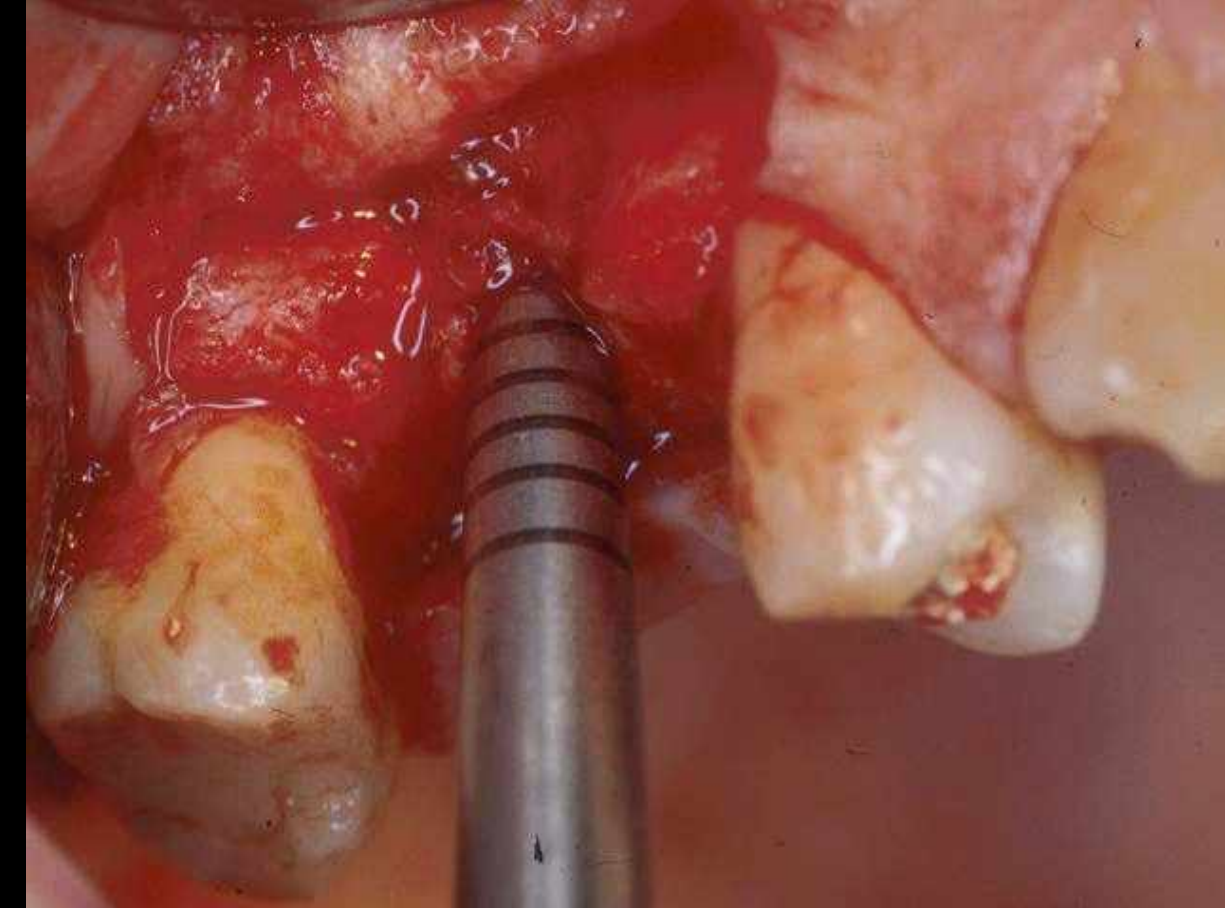
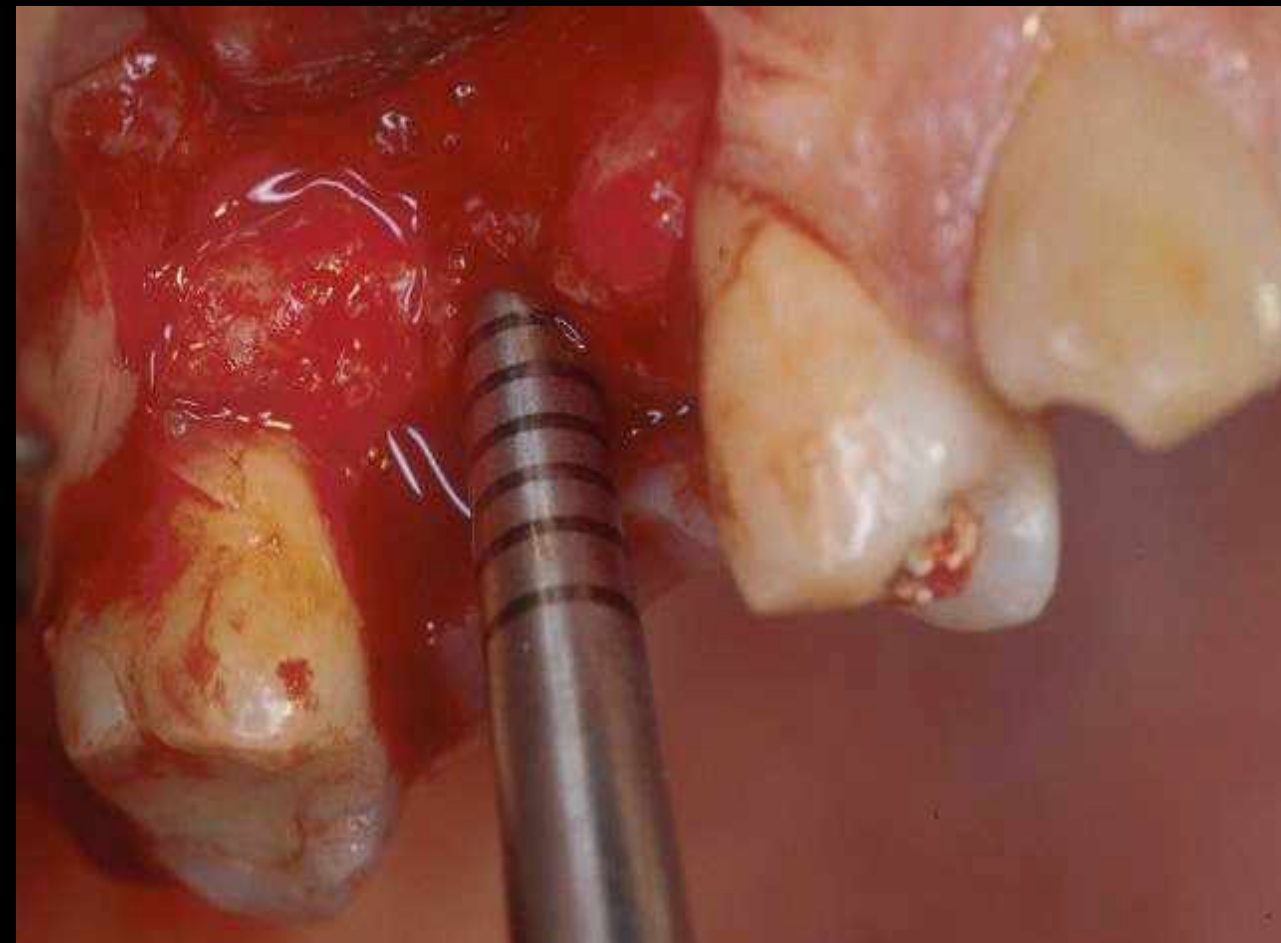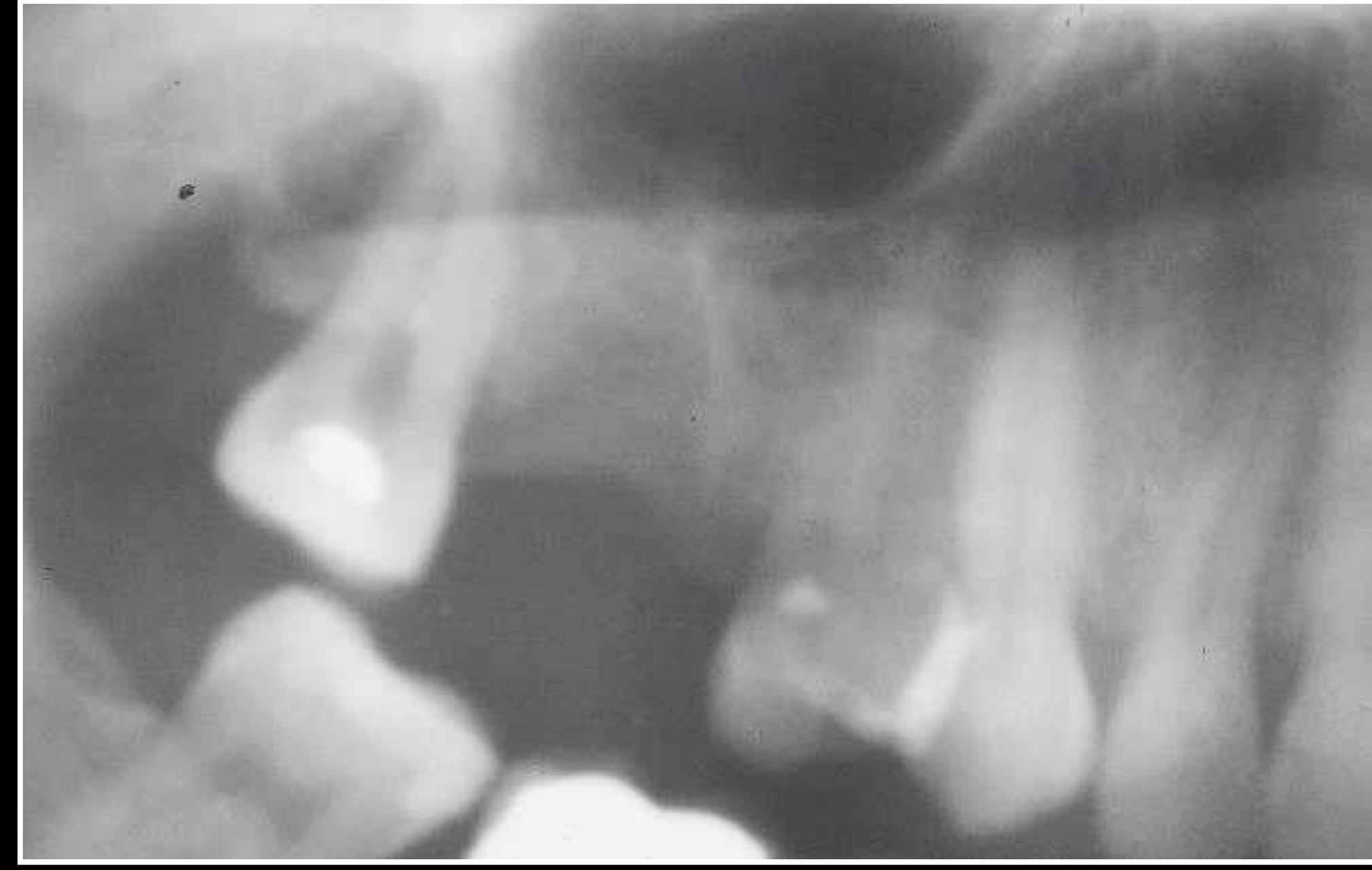Approche Crestale

Summers Modifiée



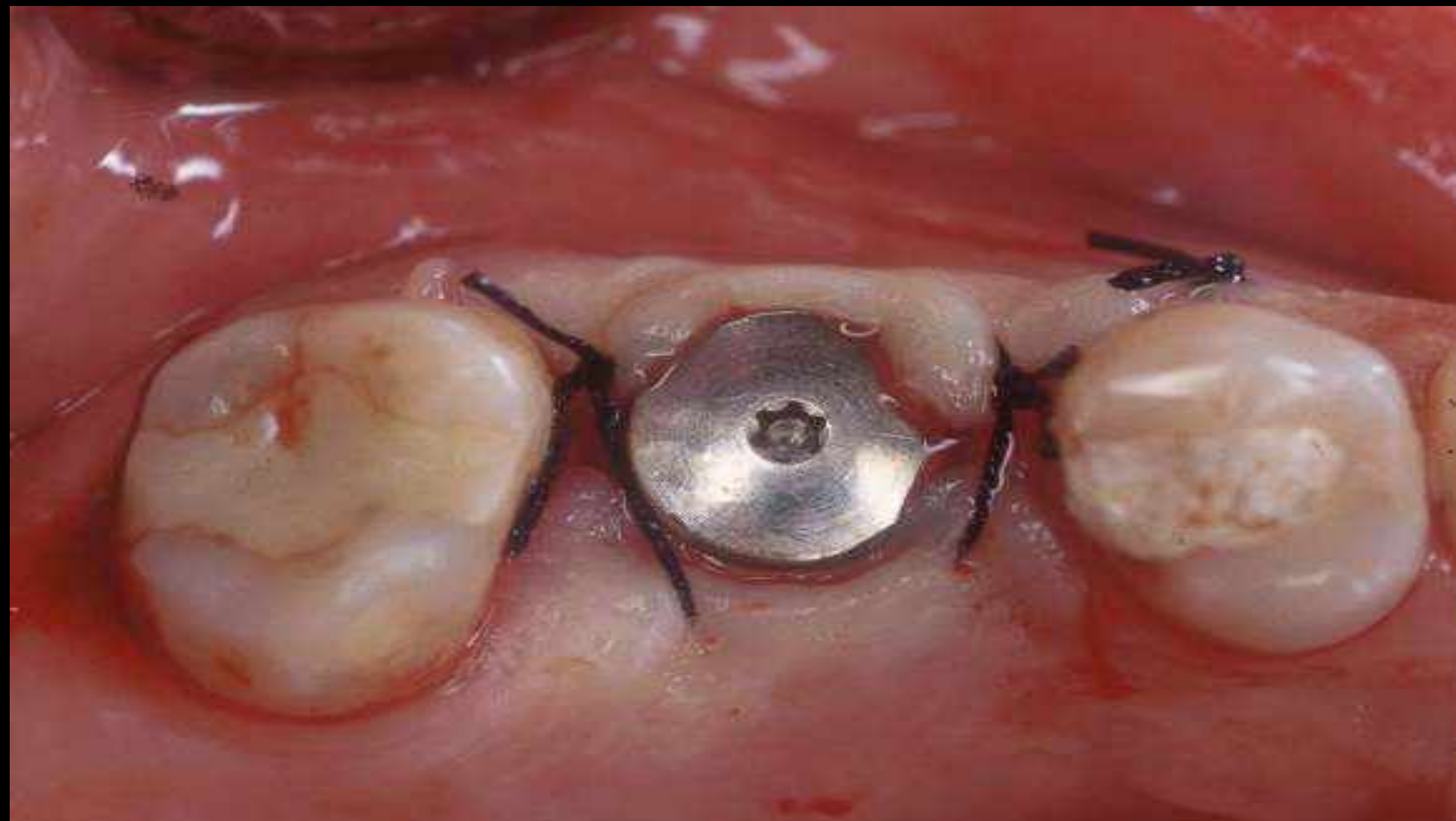
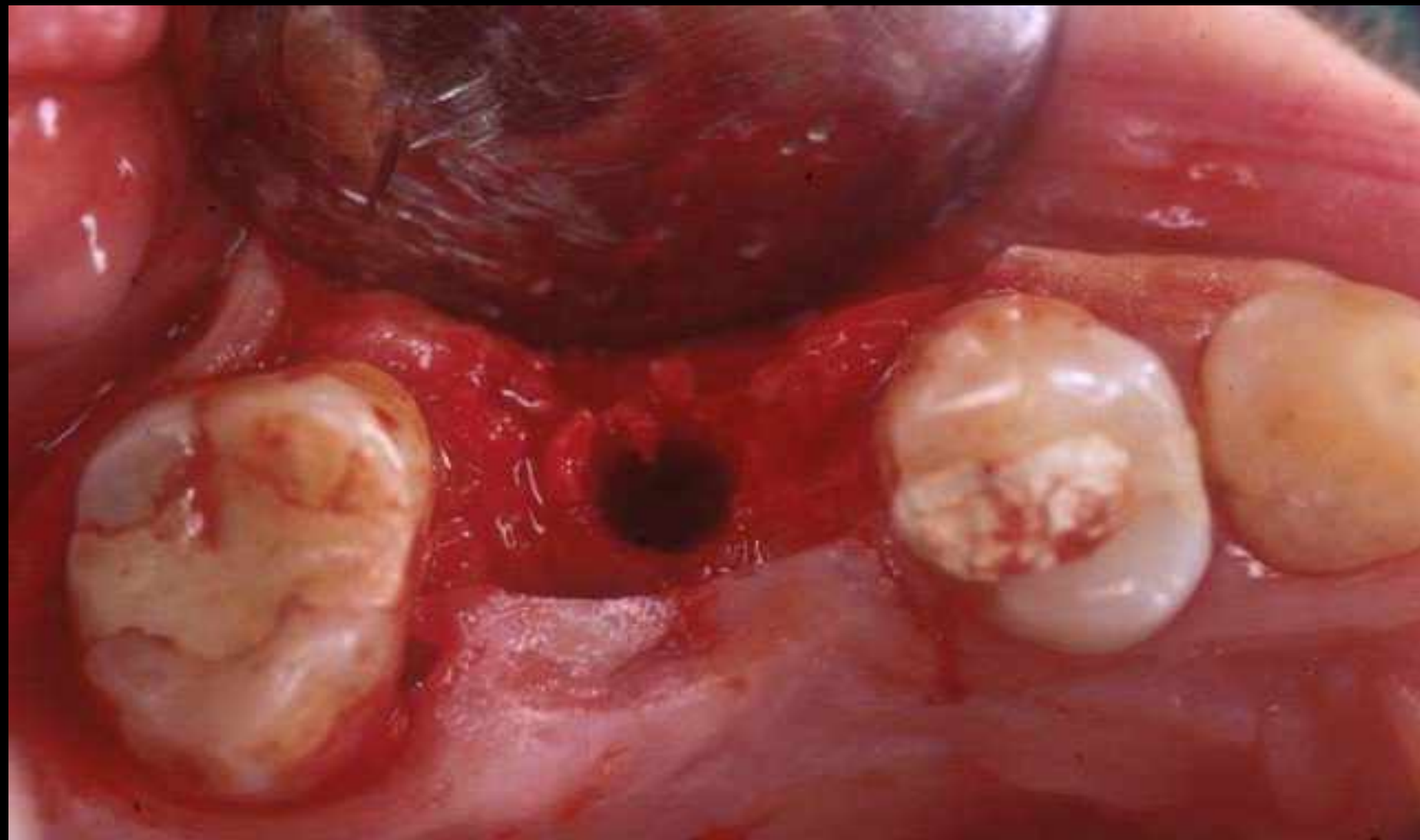
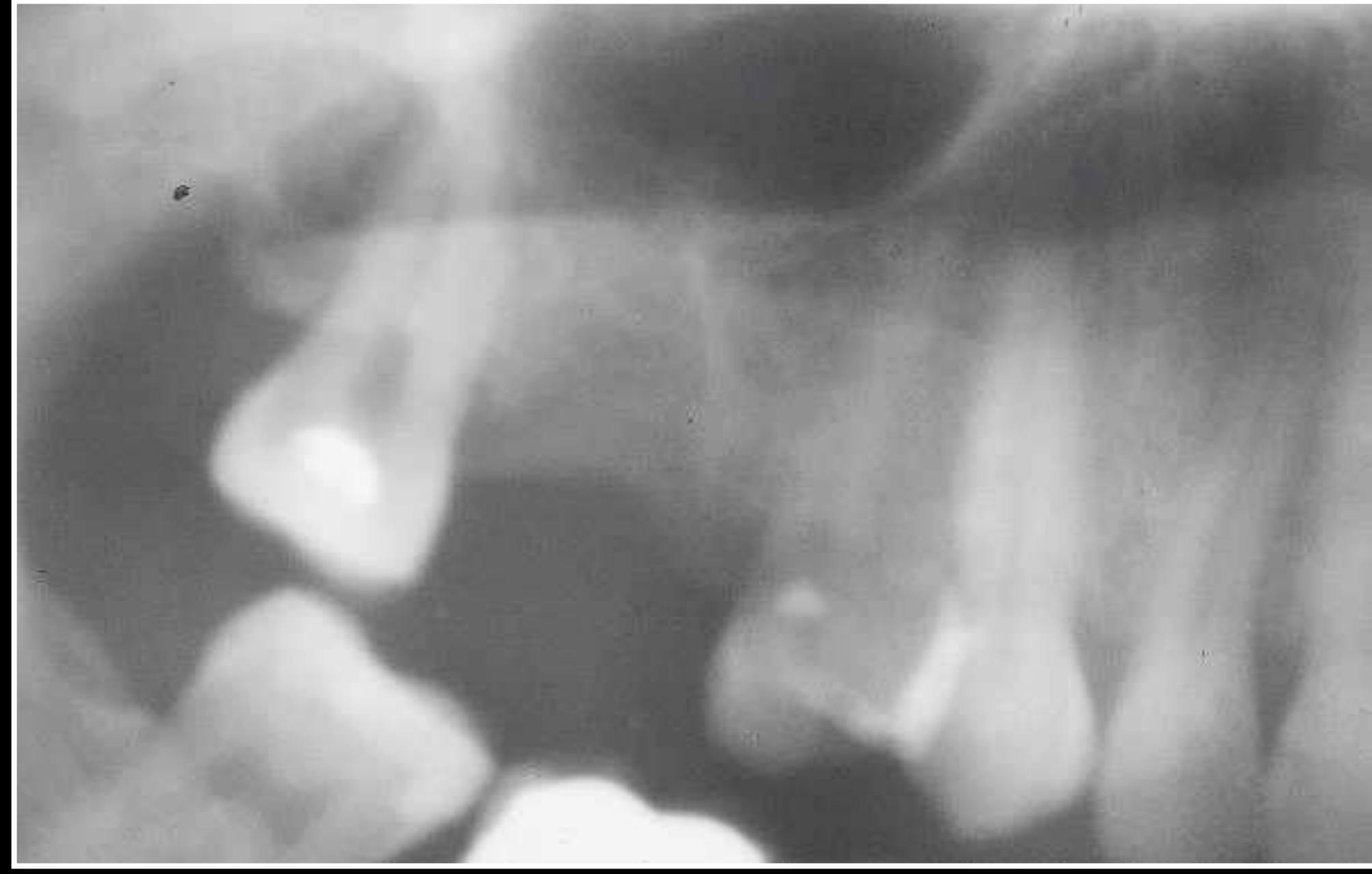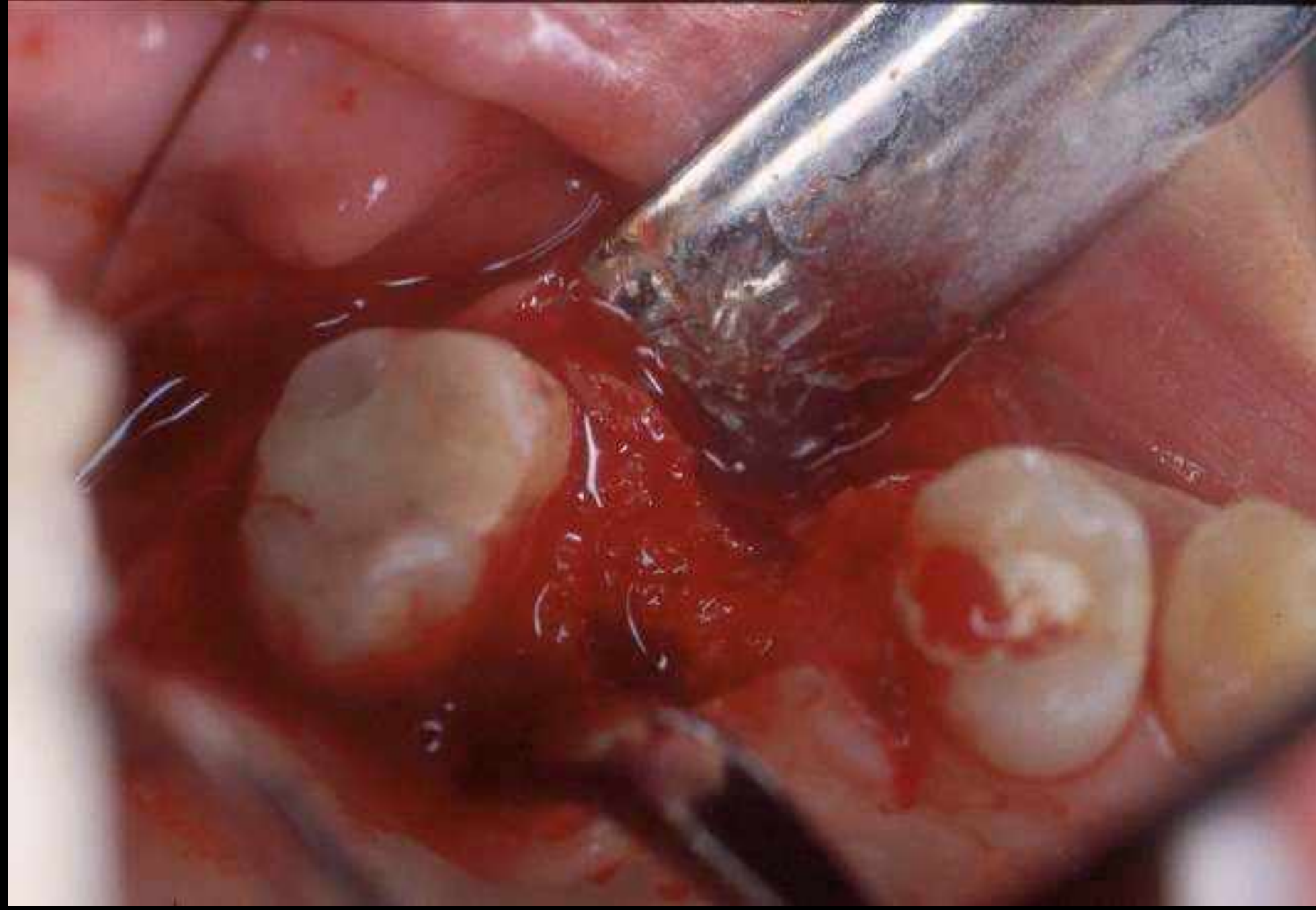
Approche Crestale

Summers Modifiée



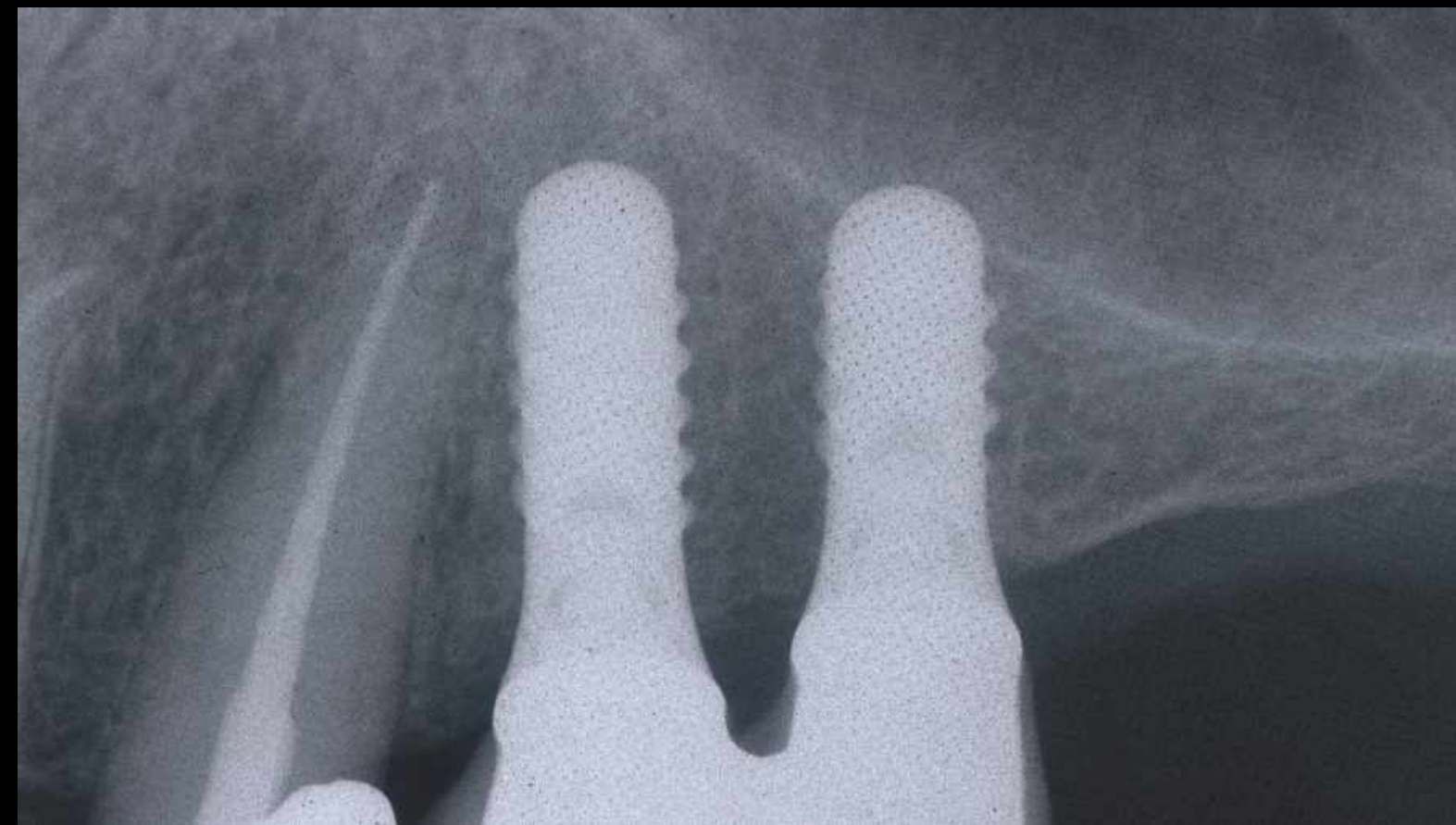
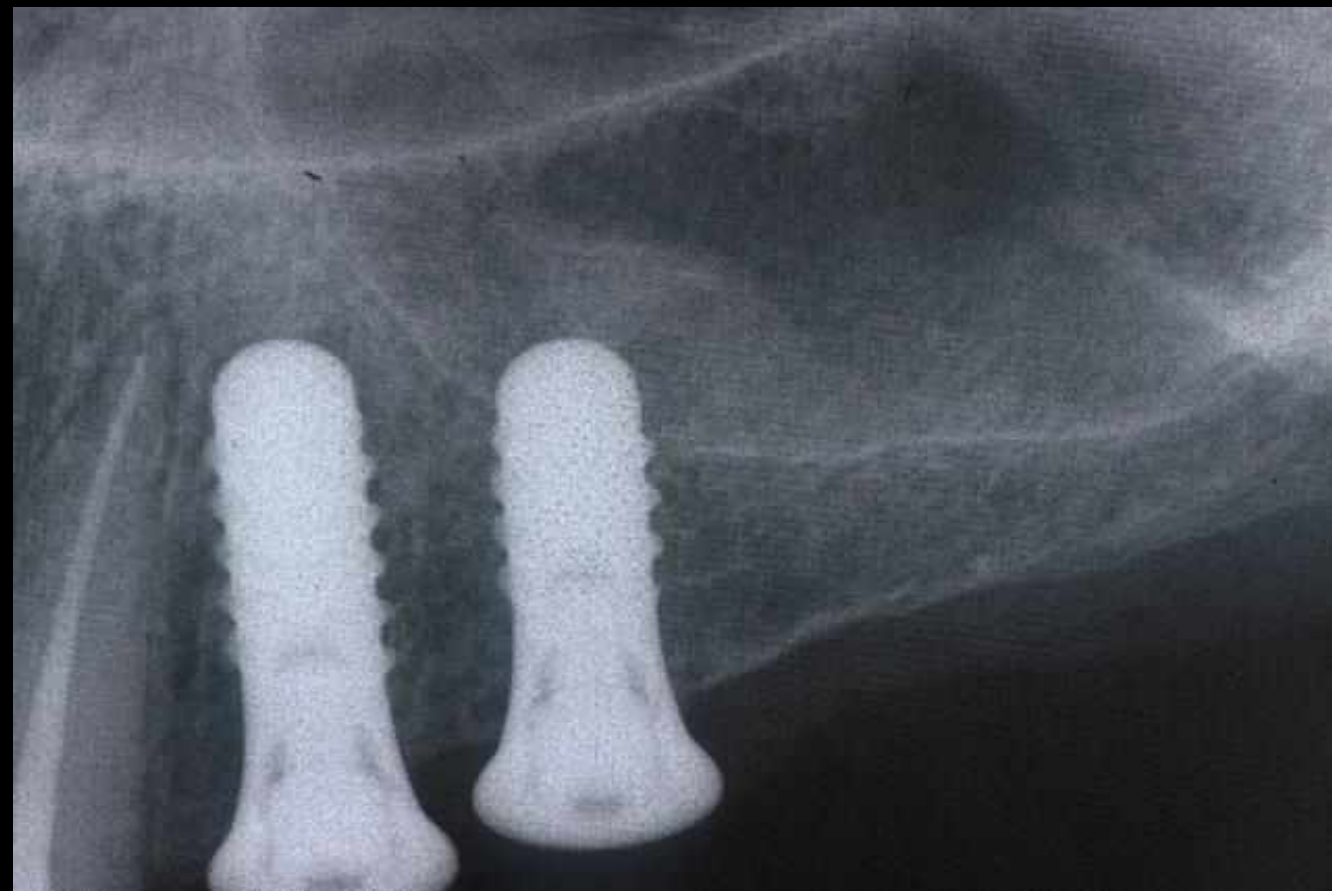
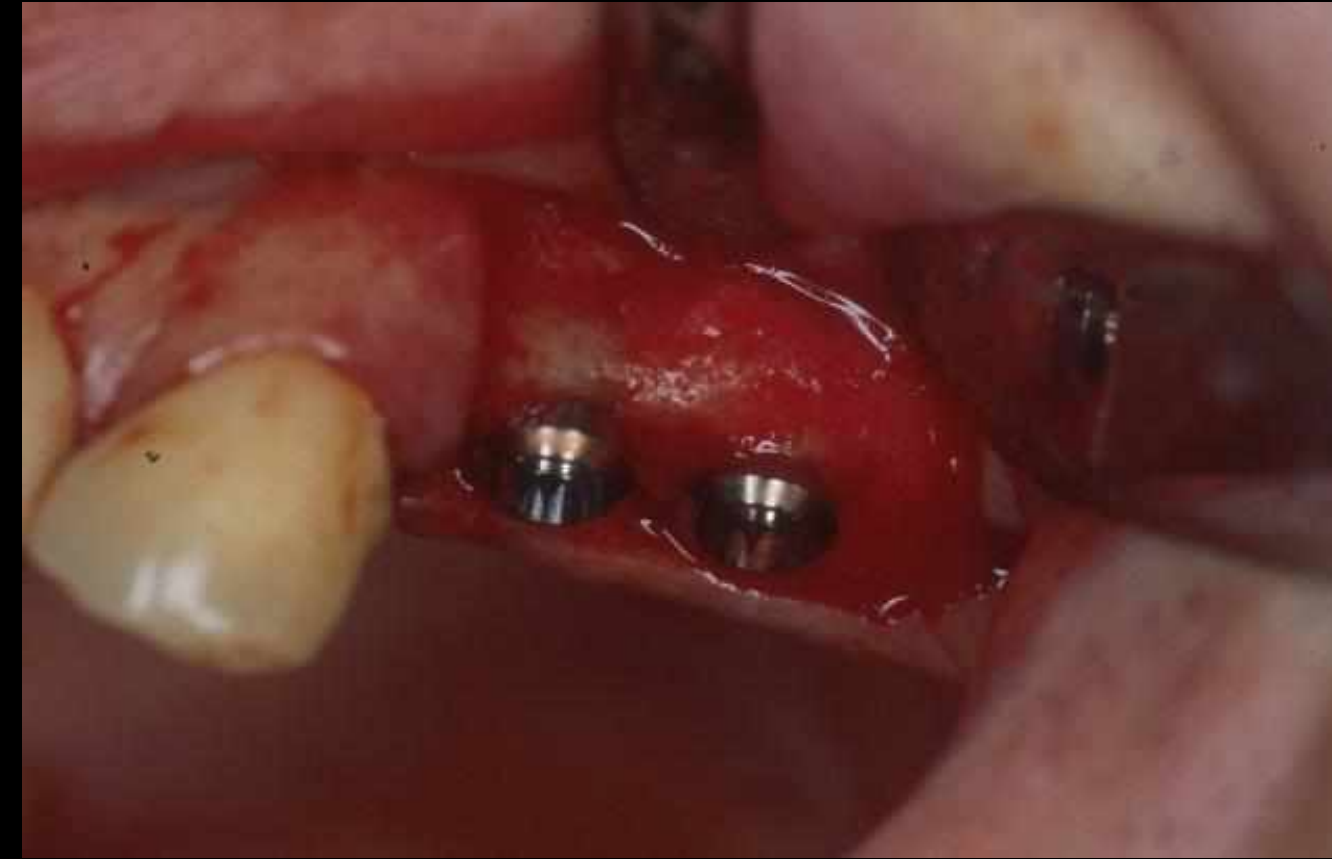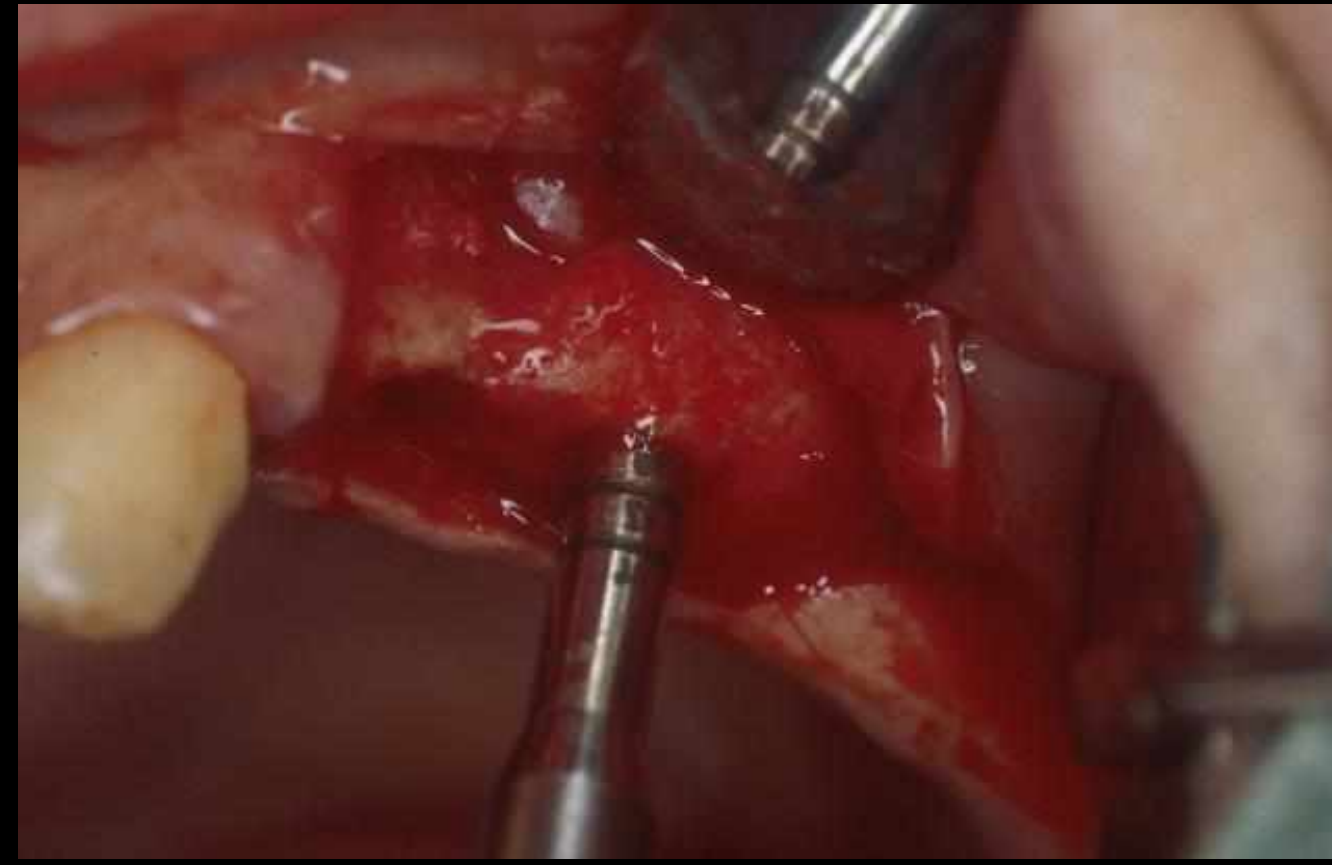
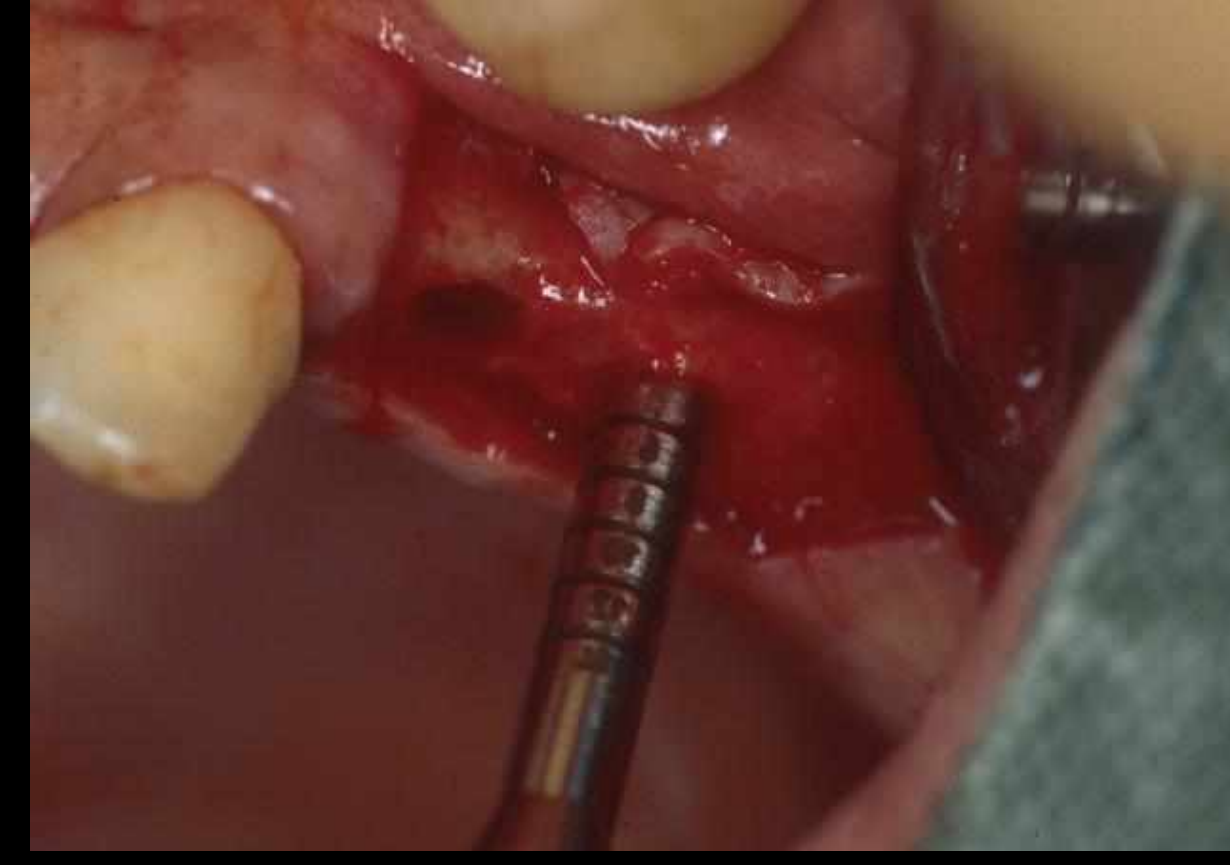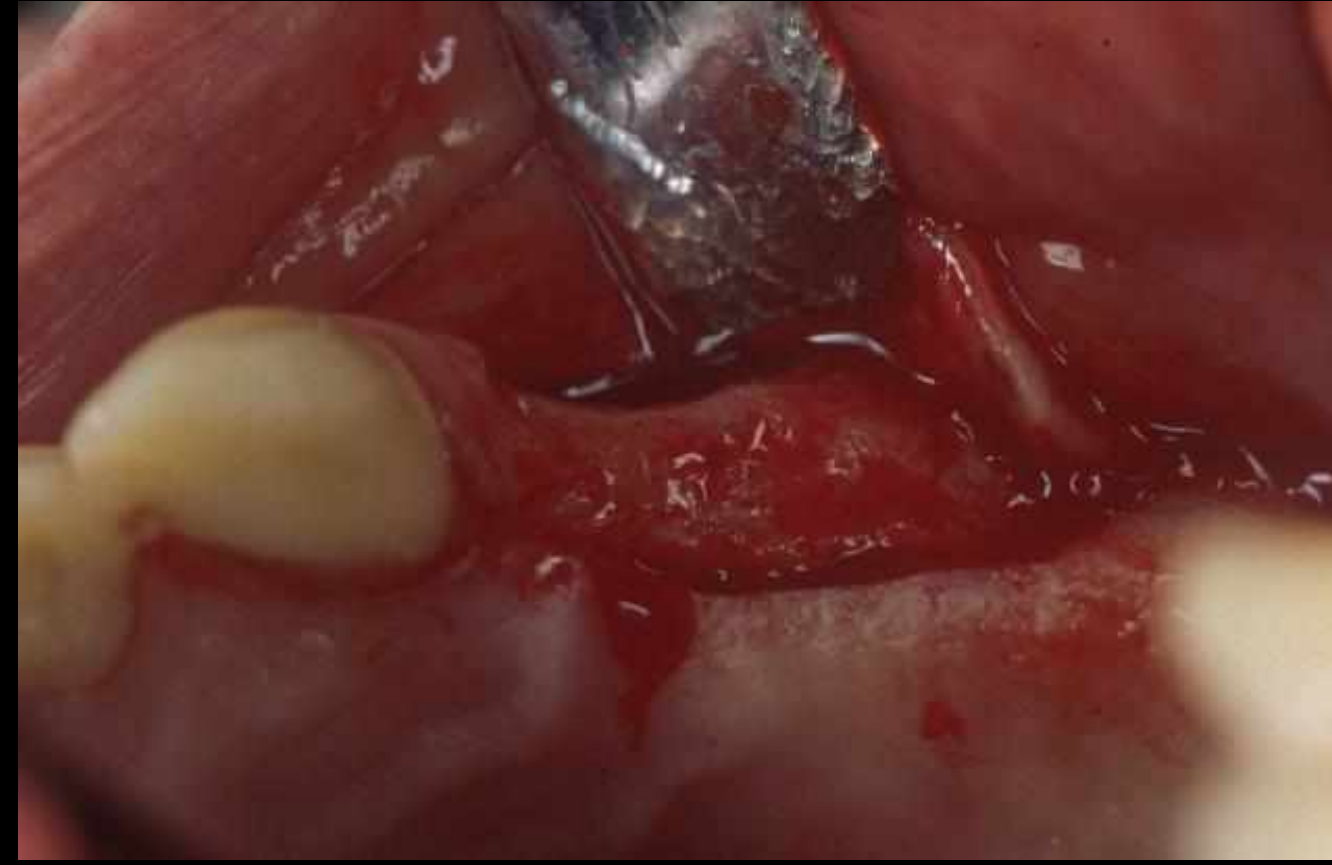
Approche Crestale

Summers Modifiée

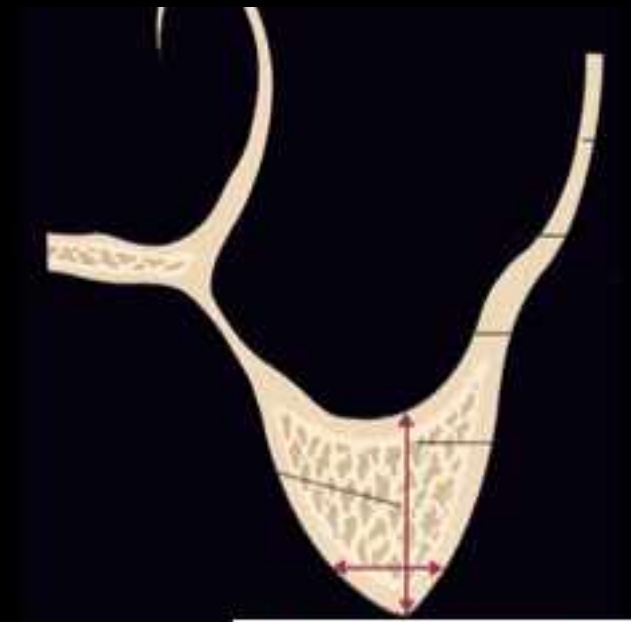
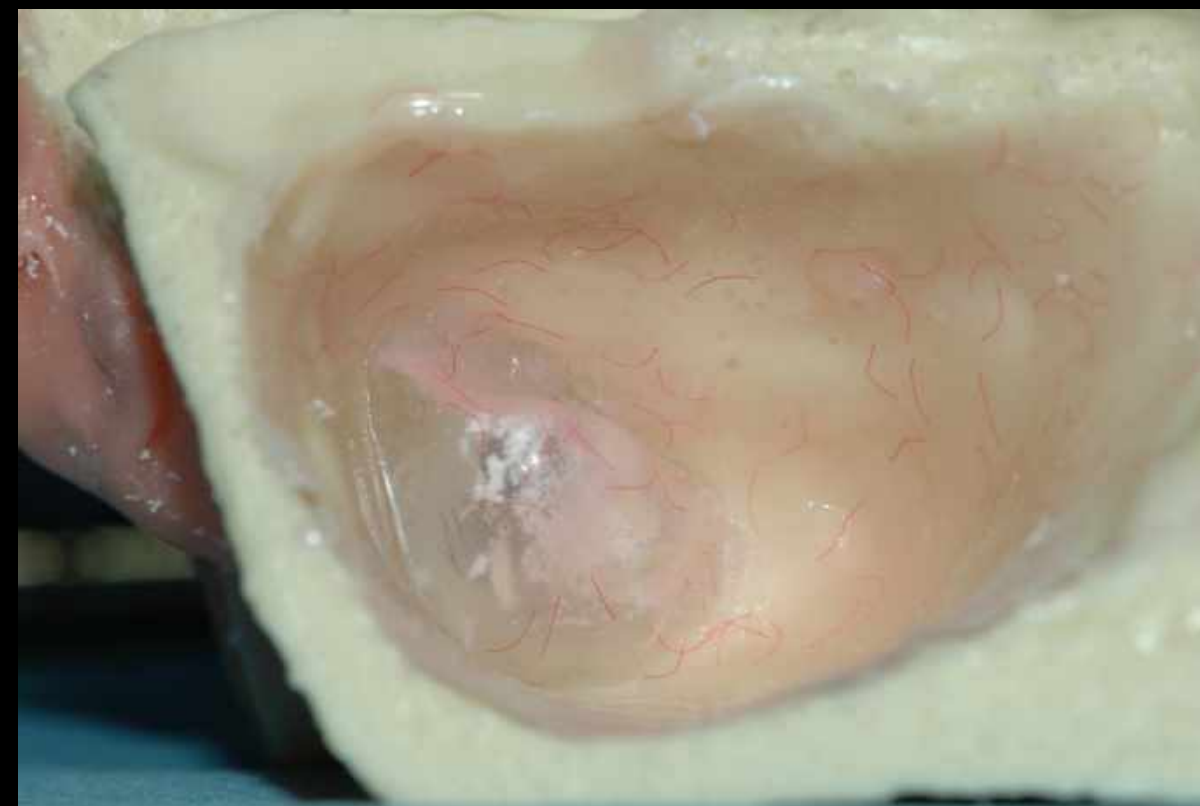
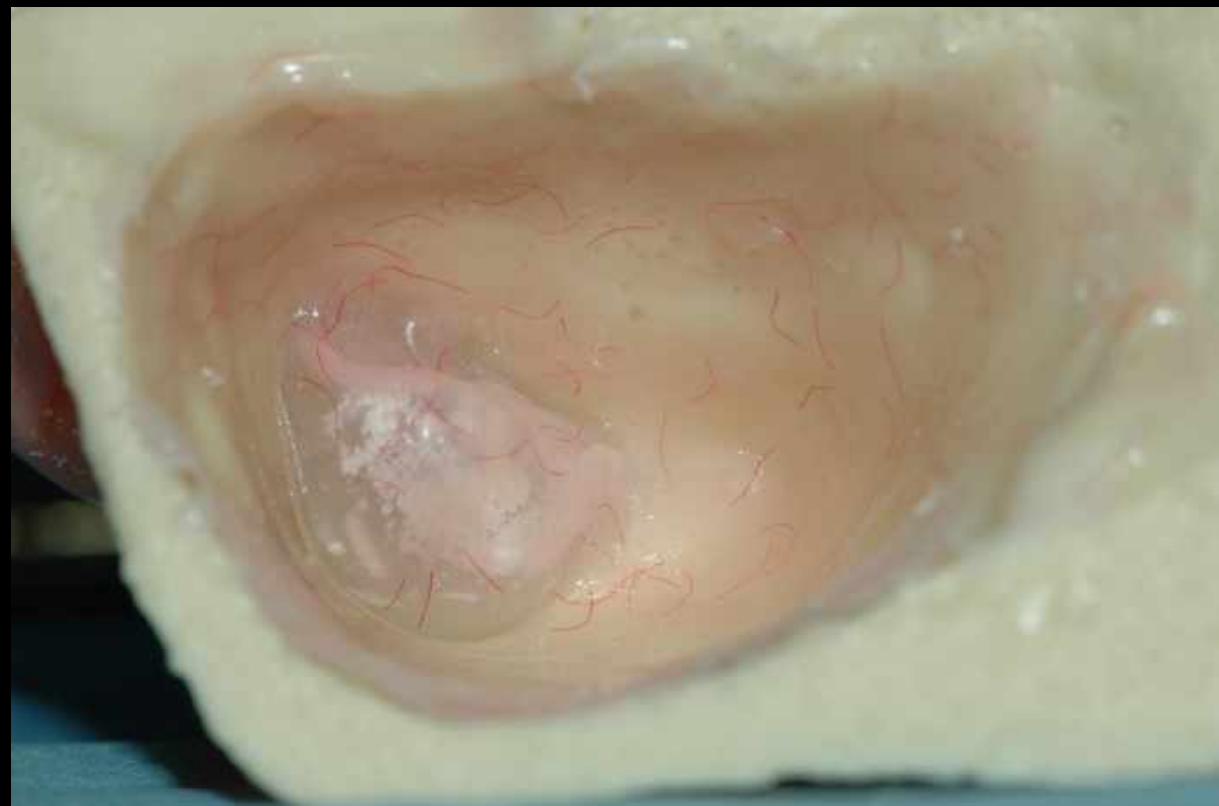
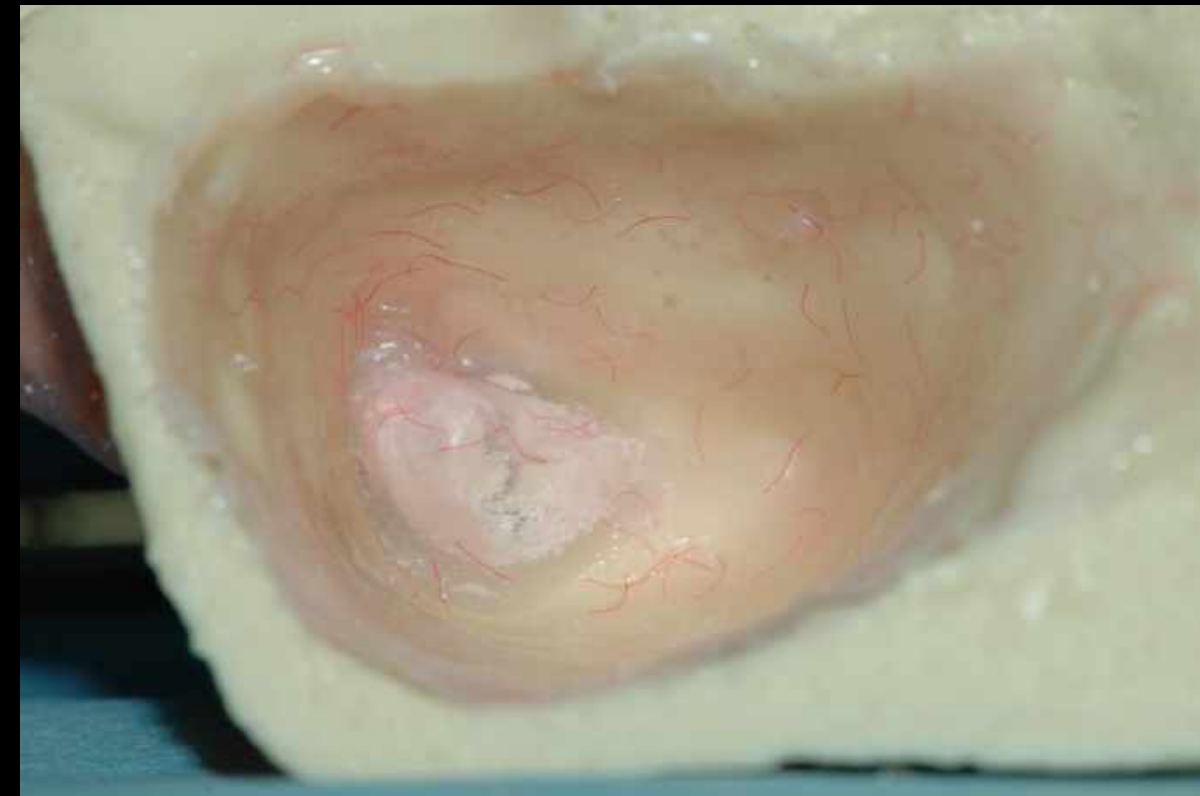
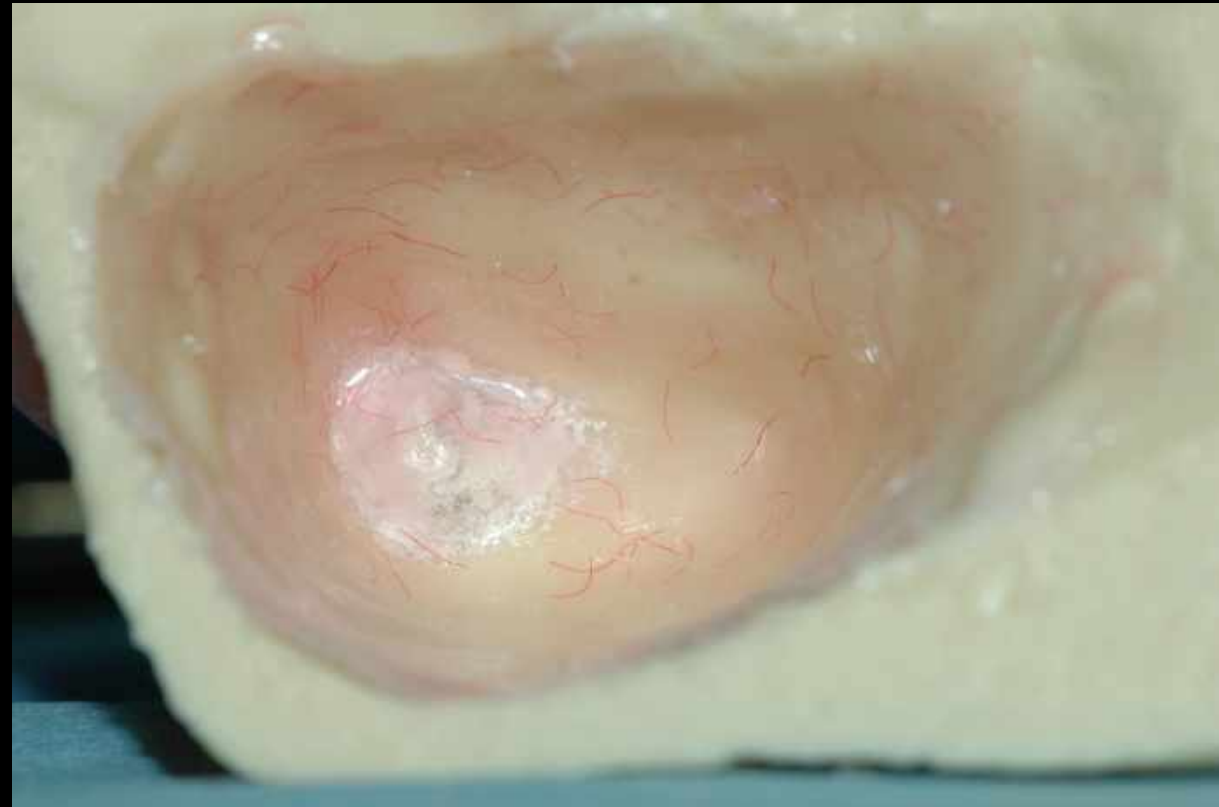Approche Crestale

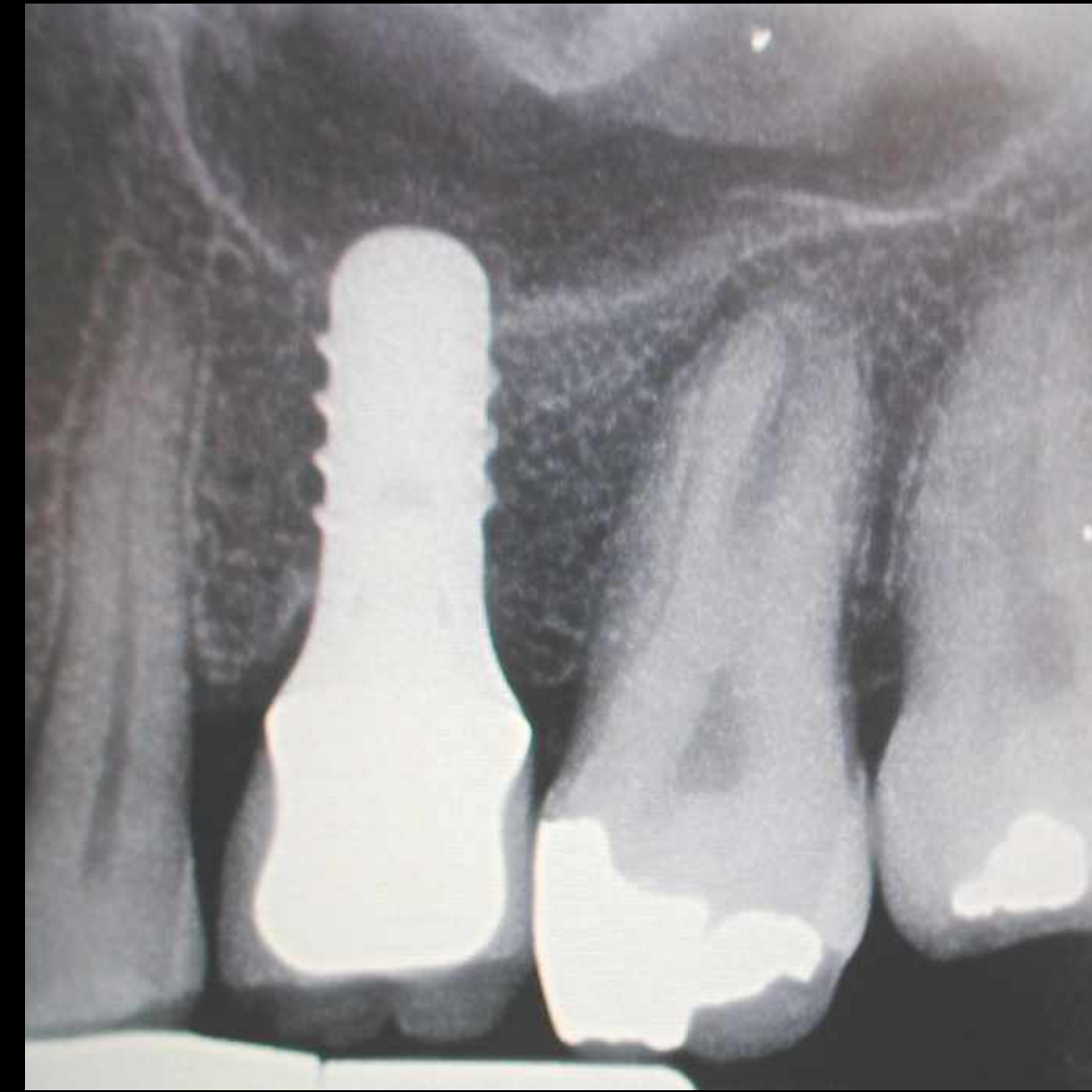
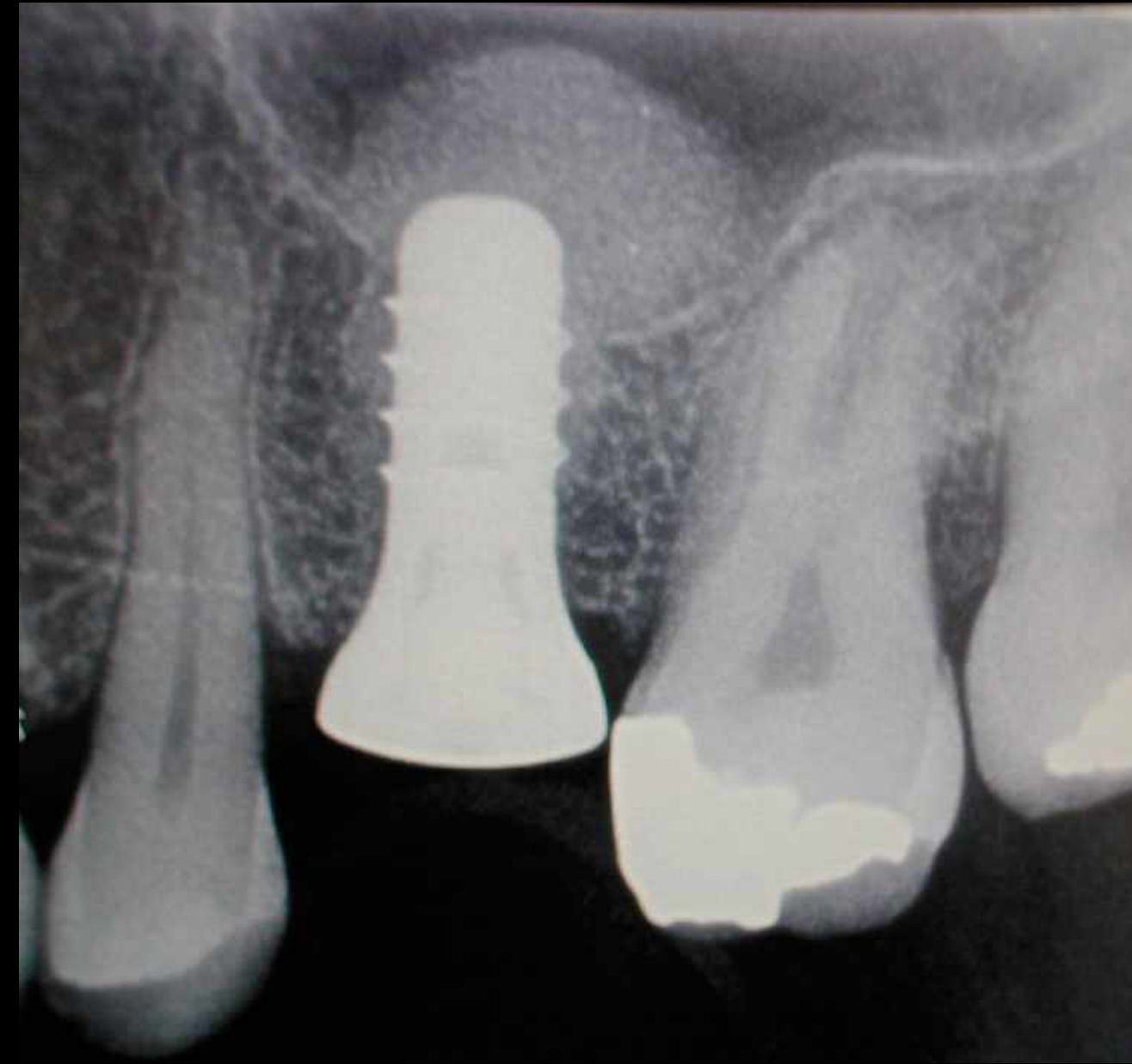Summers Modifiée



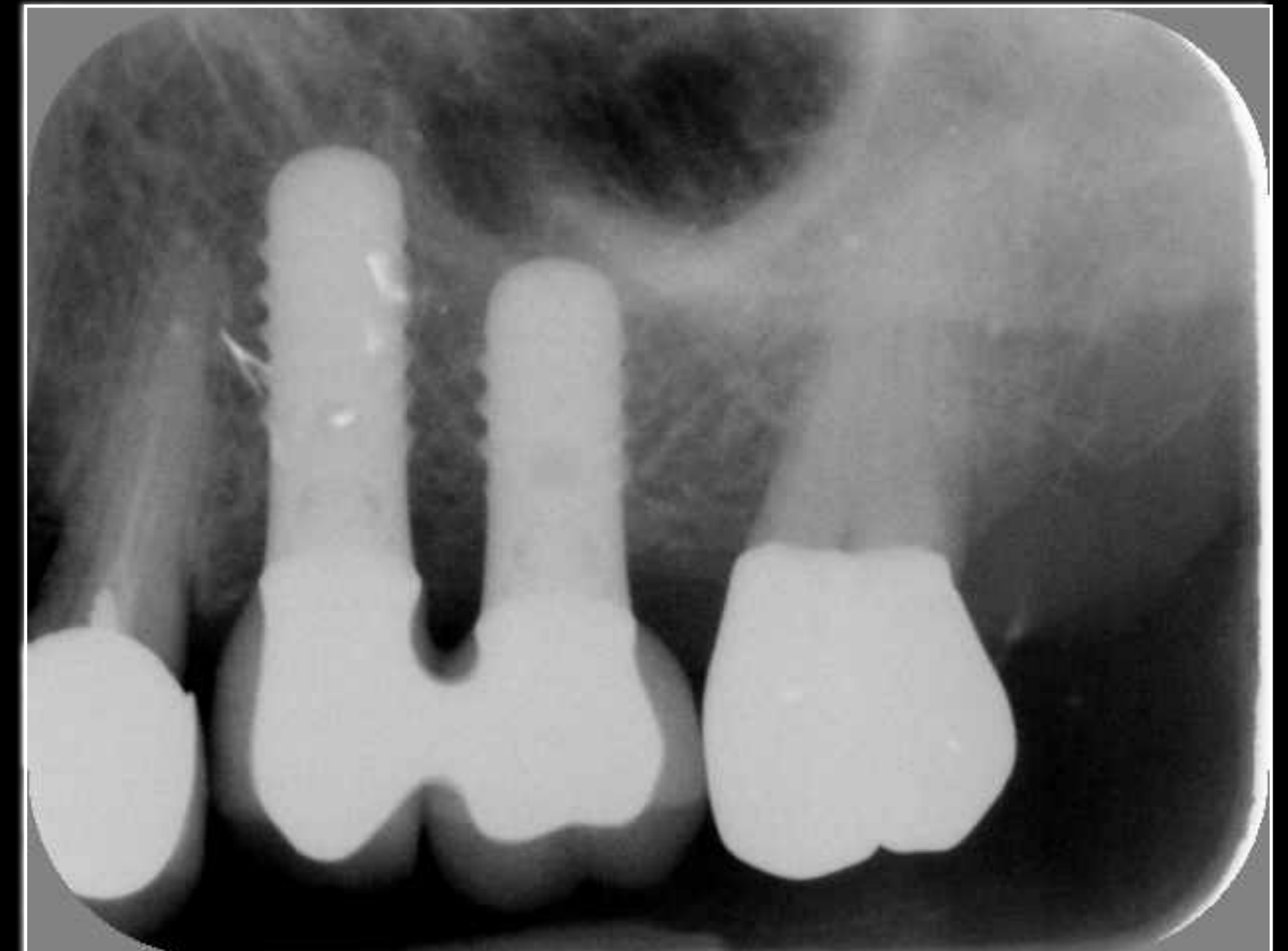
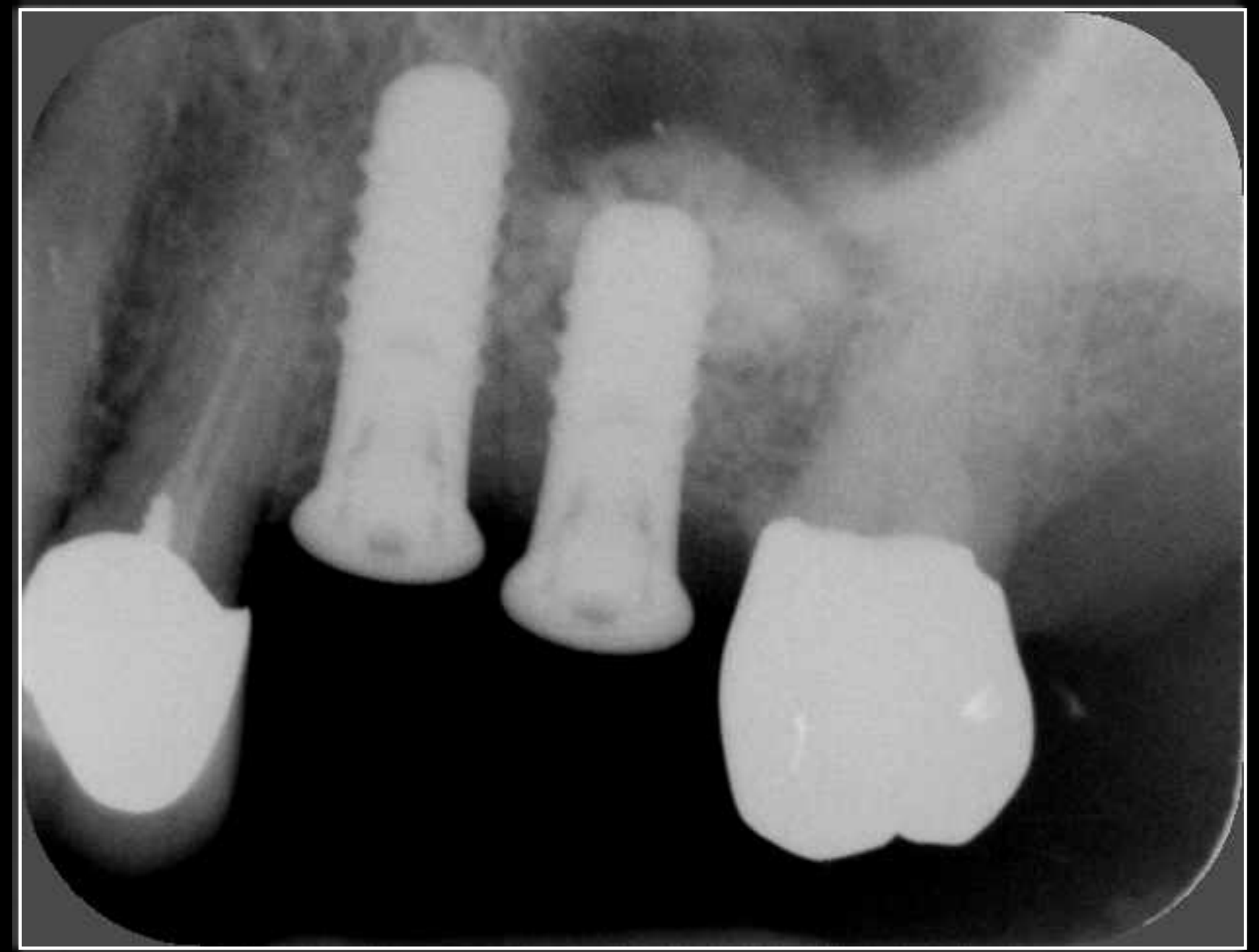
Approche Crestale



Approche Crestale



Approche Crestale



Approche Crestale

Summers Modifiée

Chiapasco M, Zaniboni M, Boisco M. Augmentation procedures for the rehabilitation of deficient edentulous ridges with oral implants. *Clin. Oral Impl. Res.* 17 (suppl. 2), 2006; 136-159.

Sélection de 5 études sur l'élévation sinusienne par voie crestale

Author and year	Study type	No. pts	No. SL	Grafting material	No. implants (timing)	Follow-up (months)	Imp surv %	Imp succ %
Zitzmann & Schärer (1998)	PCS	20	59	BBM	59 (imm)	6-24	94.9	ND
Fugazzotto & De Paoli (2002)	RCS	150	167	AB	137 (del)	36	98.5	97.8
Toffler (2004)	RCS	167	276	BBM+AB	276 (imm)	6-84	94.9	93.5
Rodoni et al. (2005)	PCS	18	ND	BBM	41 (imm)	40-93	100	ND
Leblebicioglu et al. (2005)	RCS	40	54	None	75 (imm)	25	97.3	ND
Total		395			588			

RCS, retrospective case series; PCS, prospective clinical series; no. pts, number of patients treated; no. sl, number of sinus lifting procedures; AB, autogenous bone; BBM, bovine bone mineral; imm, immediate placement; del, delayed placement; imp surv, implant survival rate; imp succ, implant success rate; ND, no data.

Approche Crestale

Summers Modifiée

Ferrigno N, Laureti M, Fanali S. Dental implants placement in conjunction with osteotome sinus floor elevation: a 12-year life-table analysis from a prospective study on 588 ITI® implants.

Clin. Oral Impl. Res. Apr 2006 ; 17(2) : 194-205

588 implant ITI avec la technique en 1 temps aux osteotomes.

323 patients

RBH : 6 à 9 mm

Periode de suivi 59,7 mois (12 à 144)

Taux de succès et de survie cumulé : 94,8% et 90,8%

12 mm : 93,4 %

10 mm : 90,5 %

8 mm : 88,9%

103 imp 8 mm = RBH : 6 à 7 mm

342 imp 10 mm = RBH : 7 à 8 mm

143 impl 12 mm = RBH : 8 à 9 mm

S : 447

HS : 90

WNI : 51

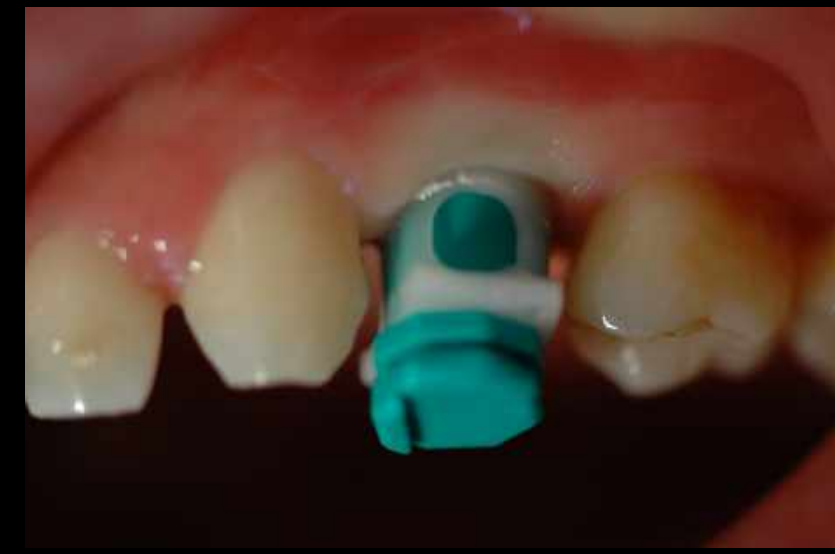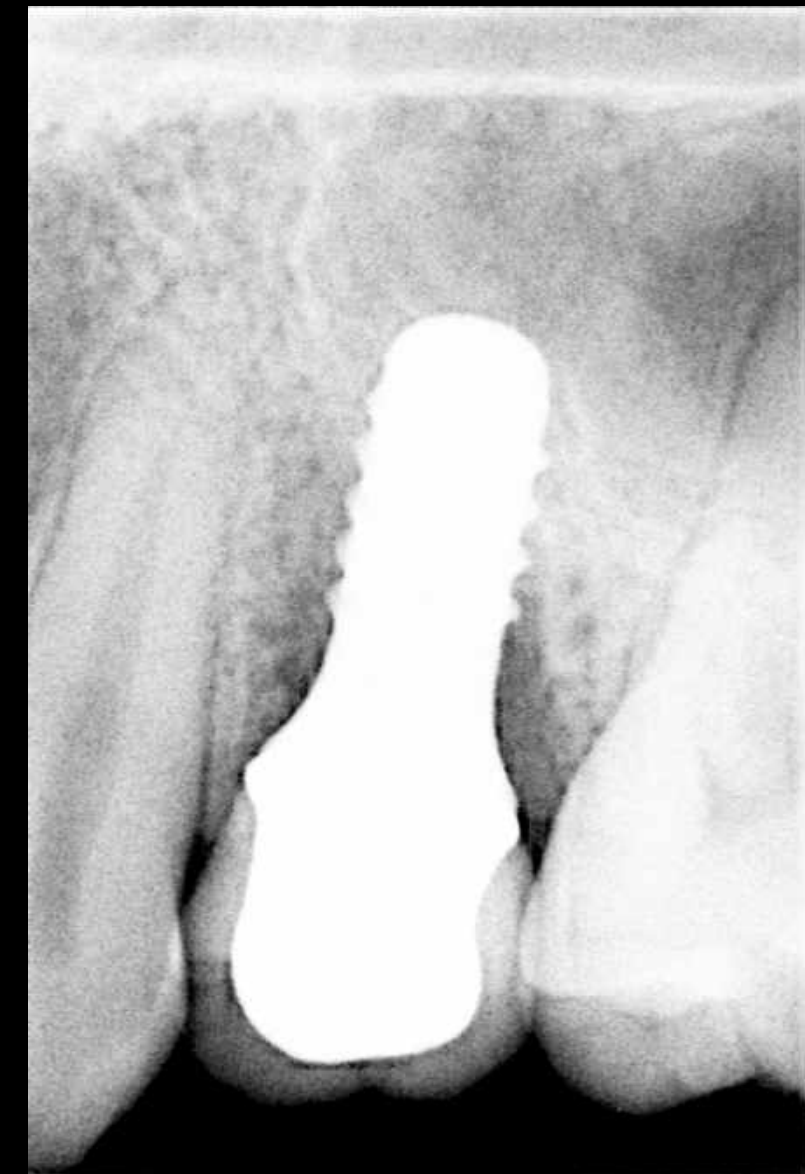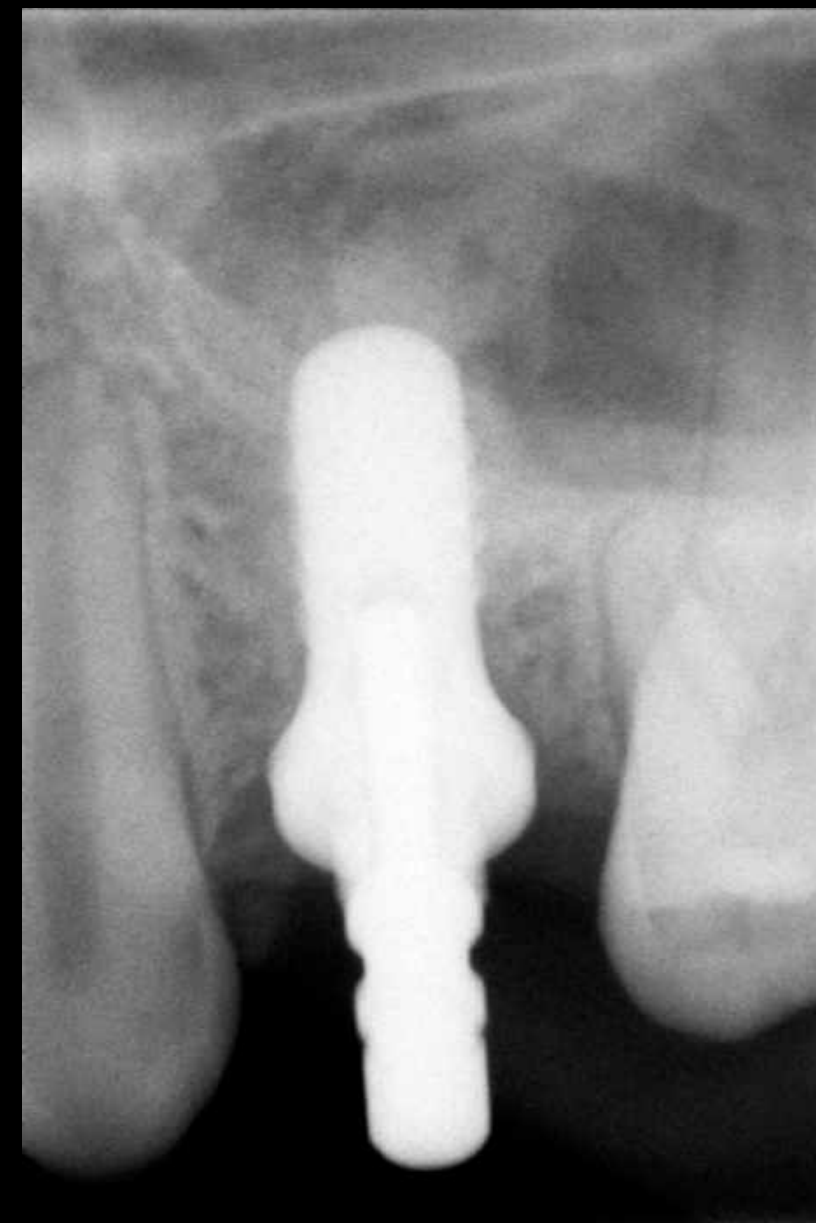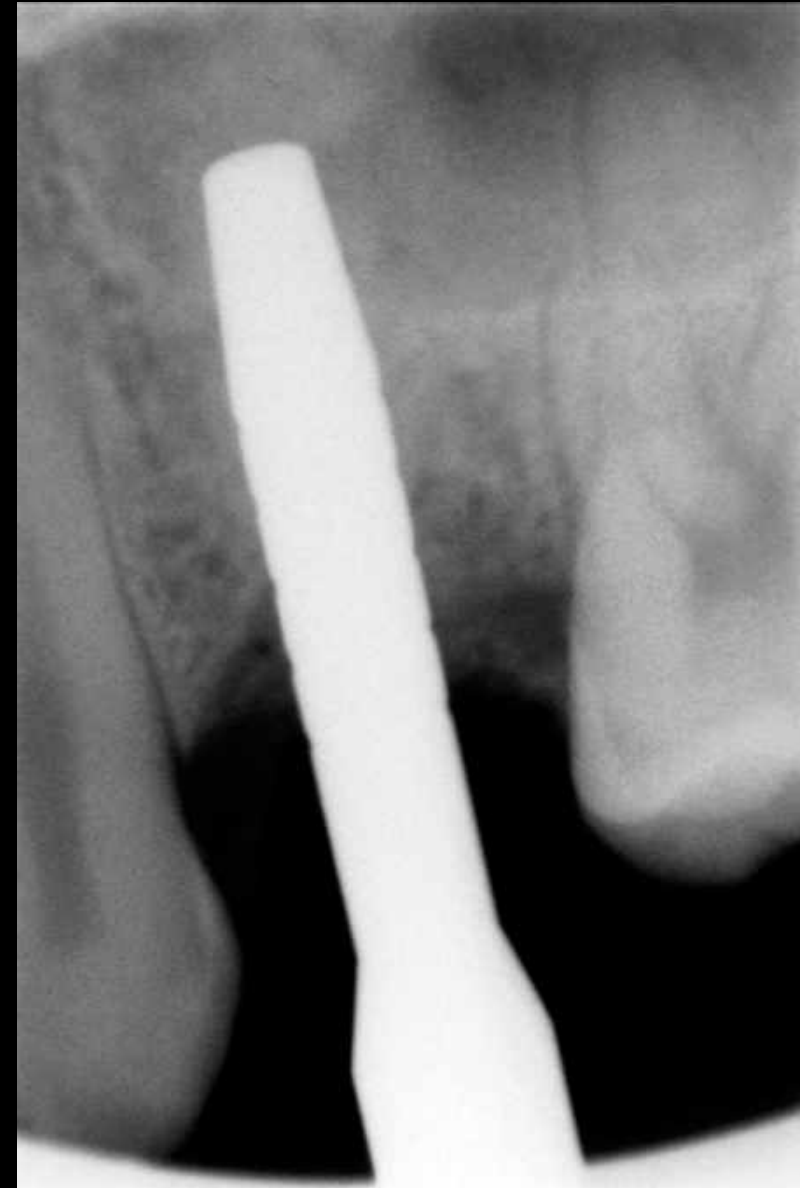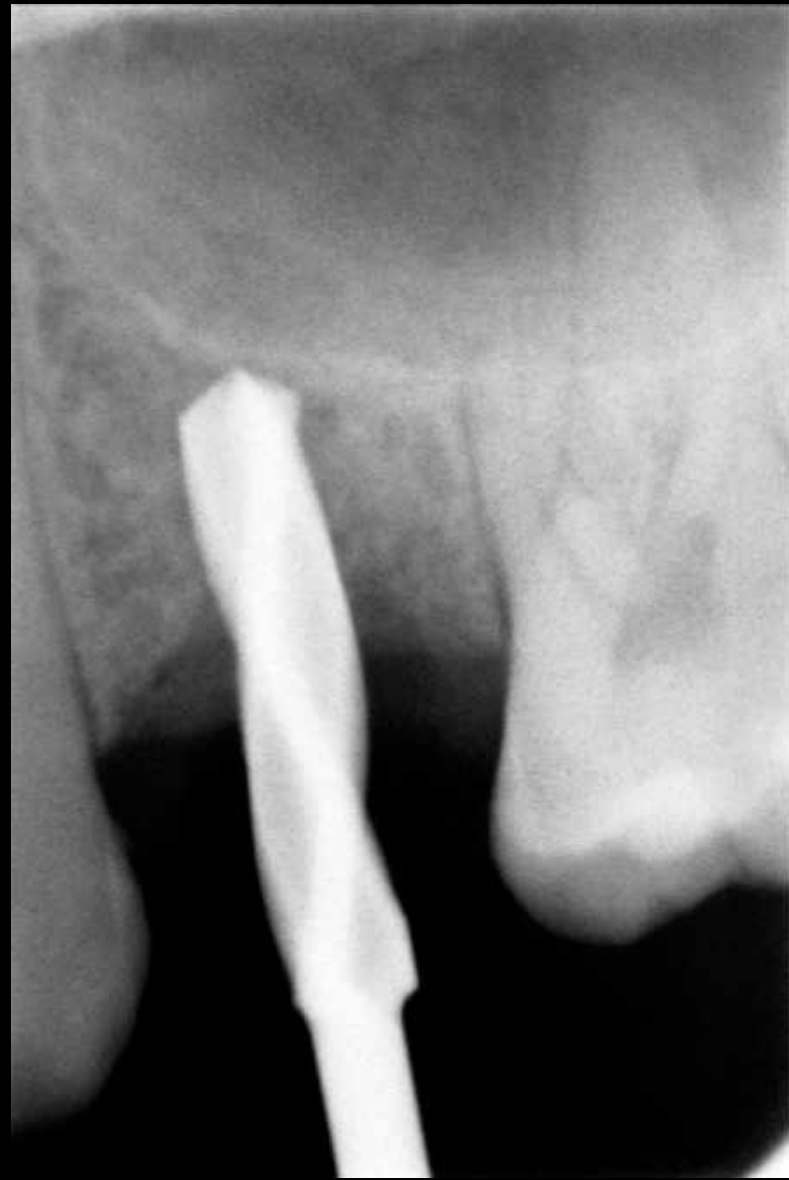354 TPS

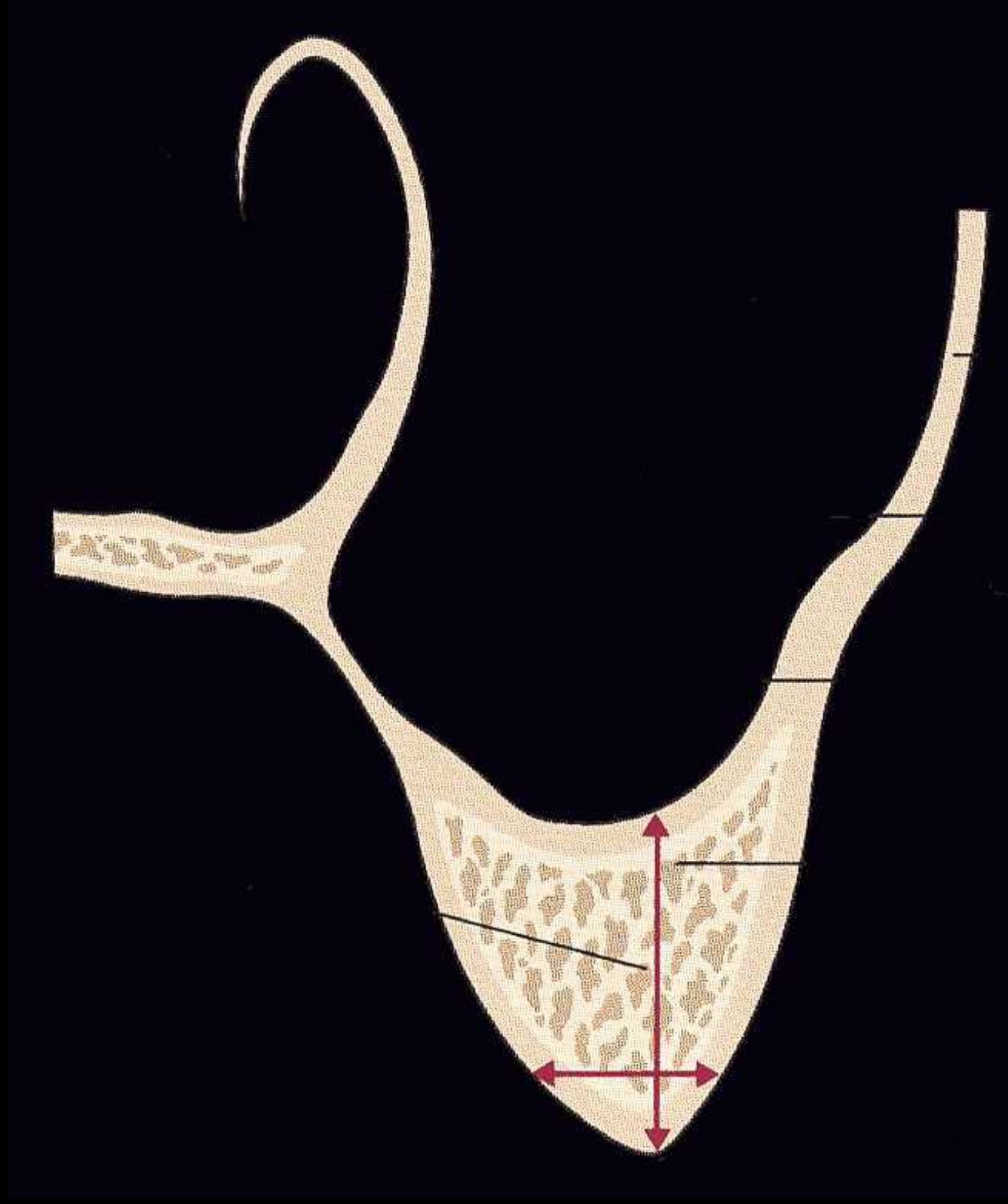
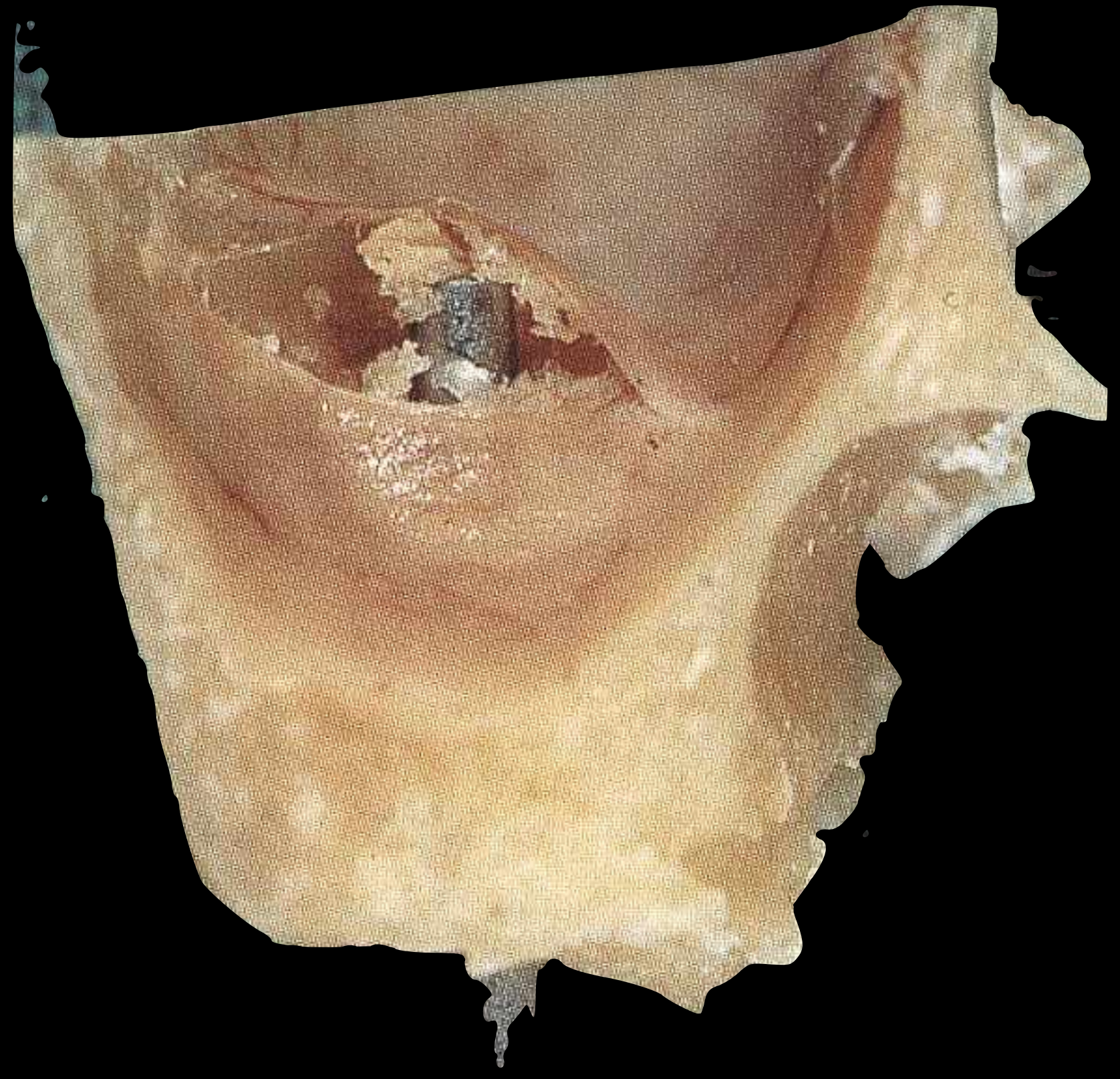
234 SLA (4 ans)

23 WNI de 8 mm

Approche Crestale

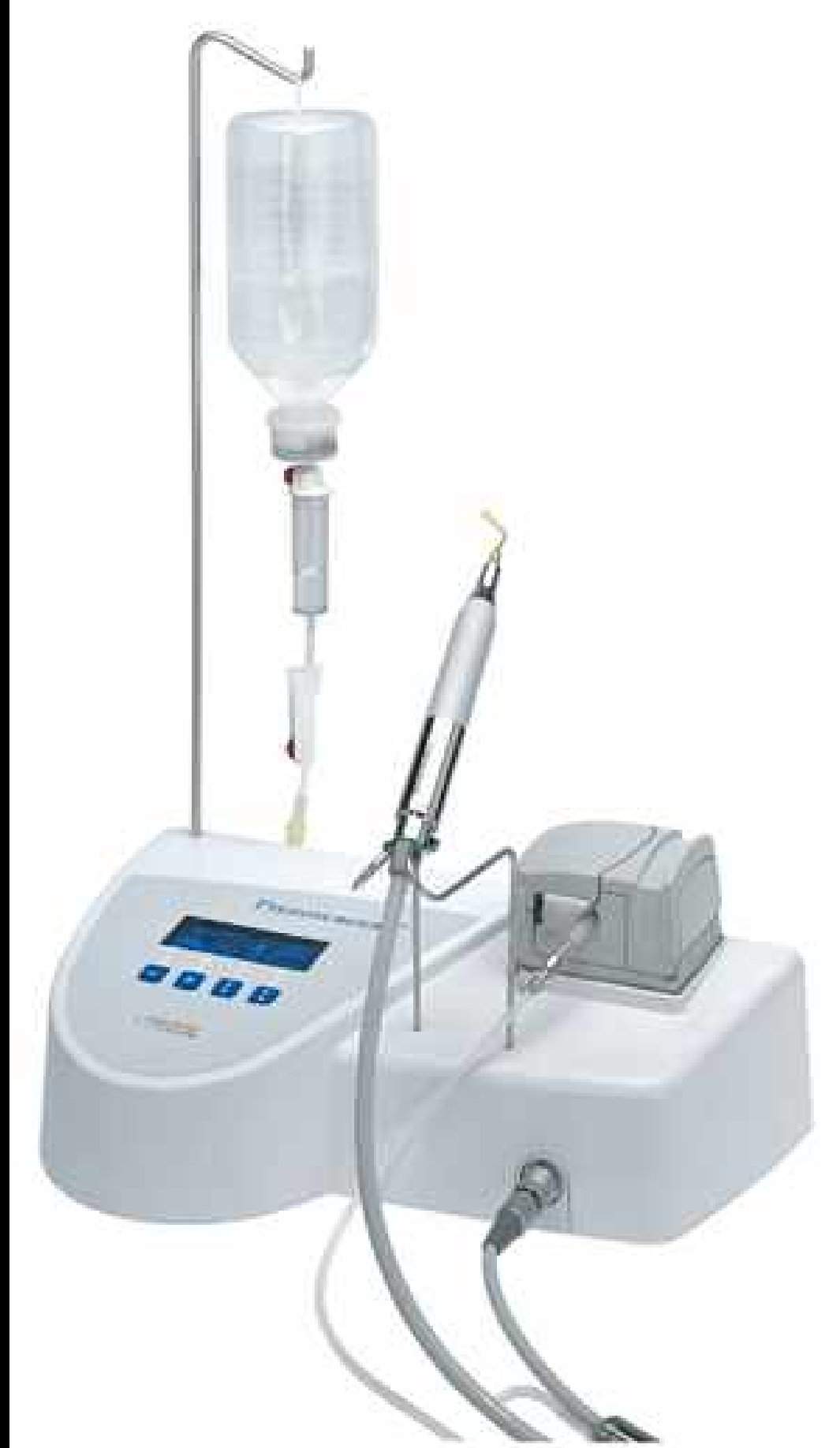
Summers Modifiée





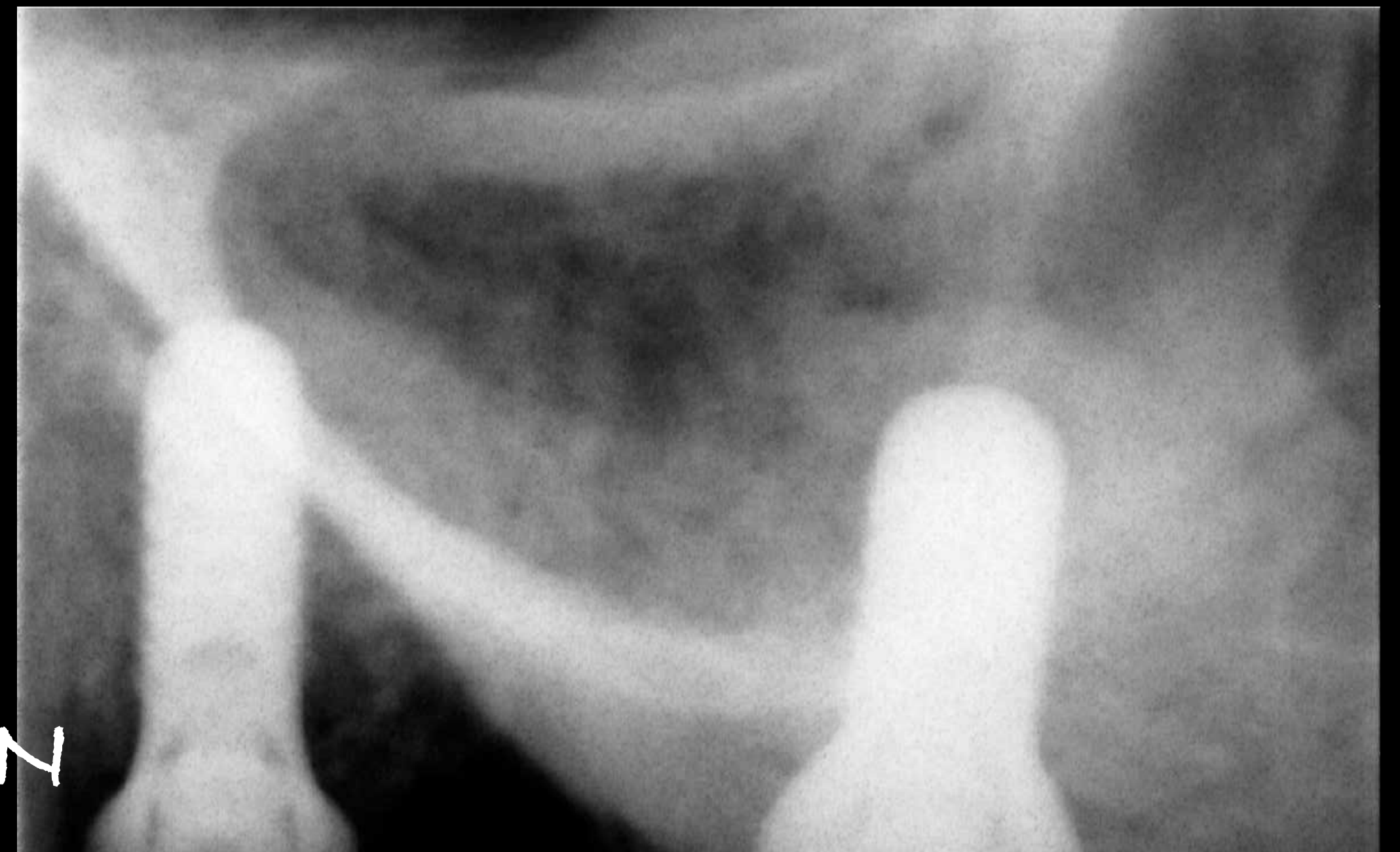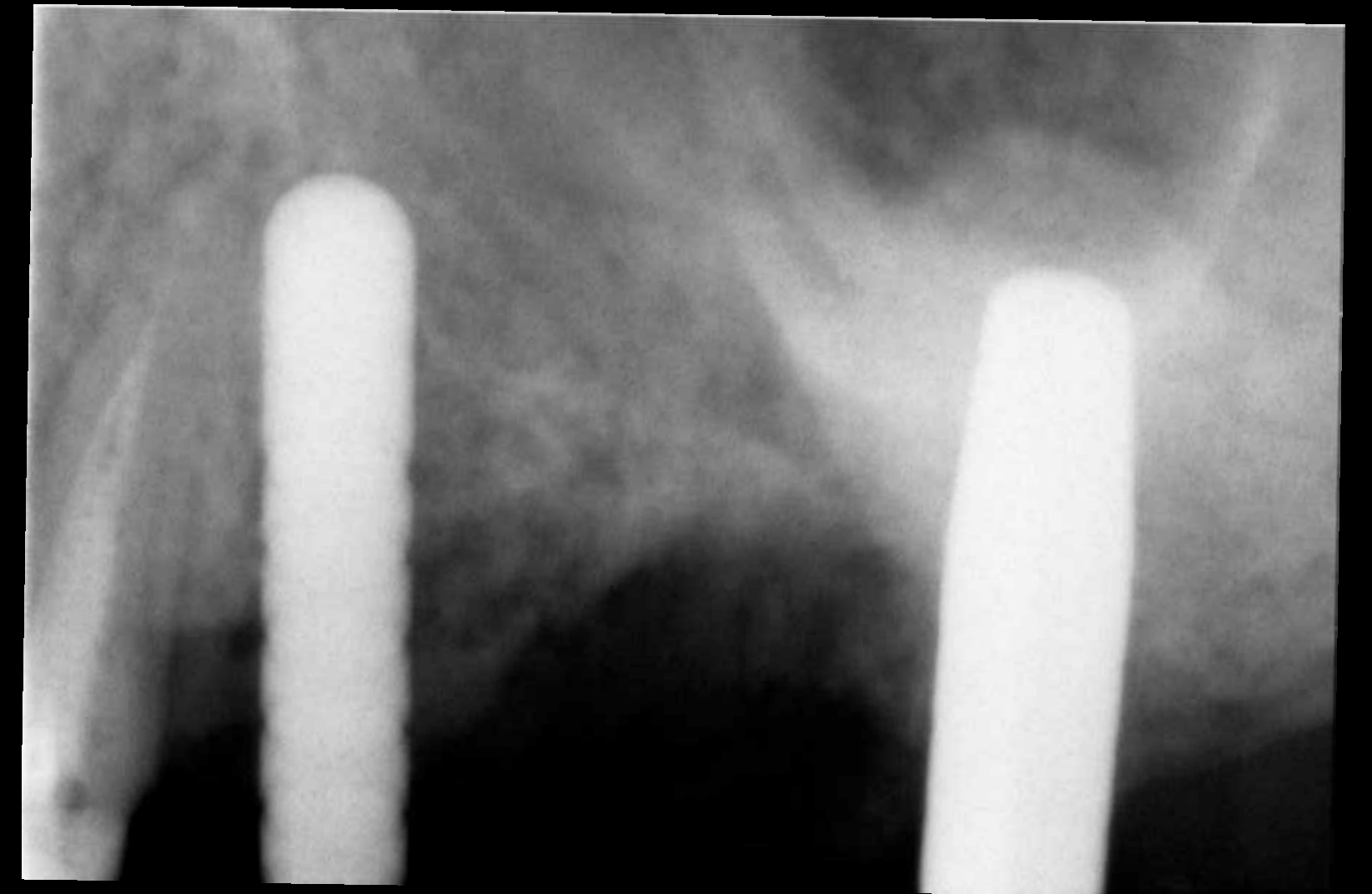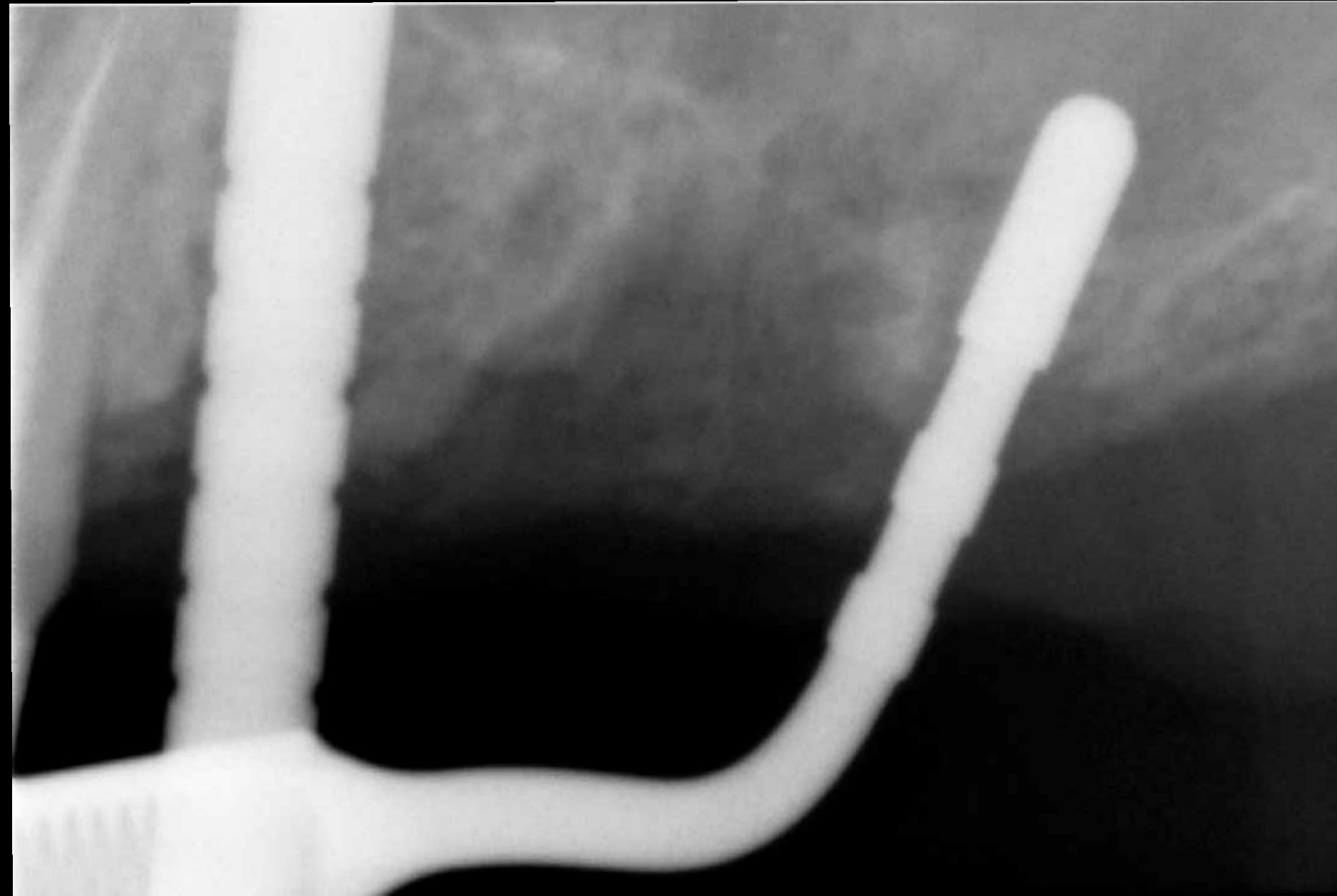Approche Crestale

Summers Modifiée



Approche Crestale

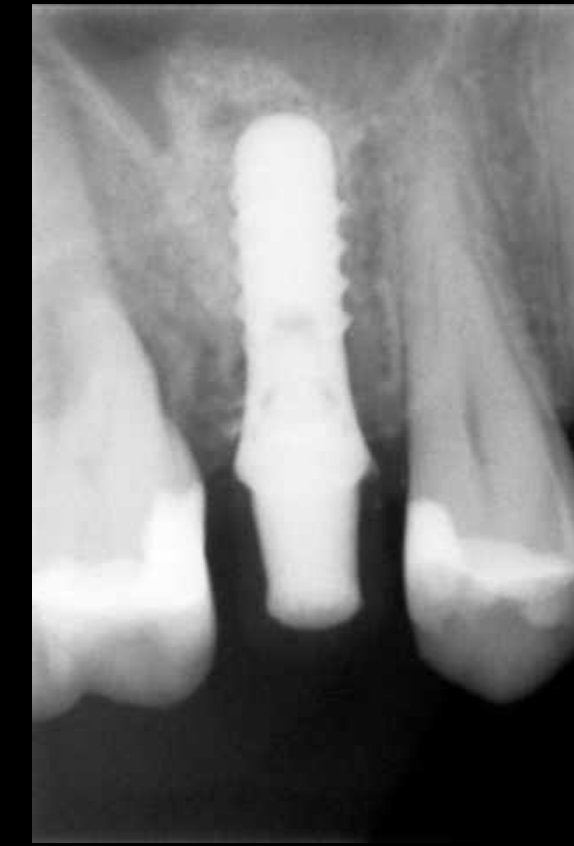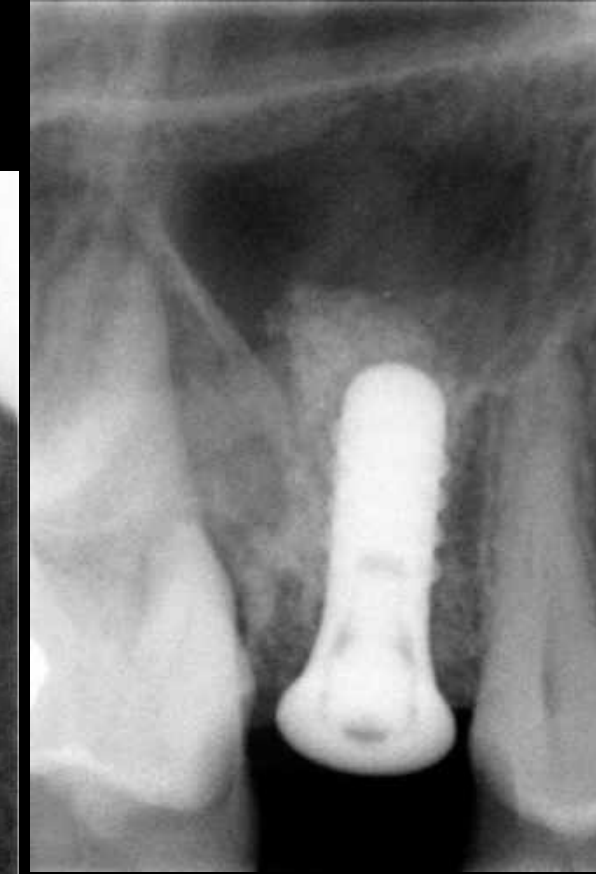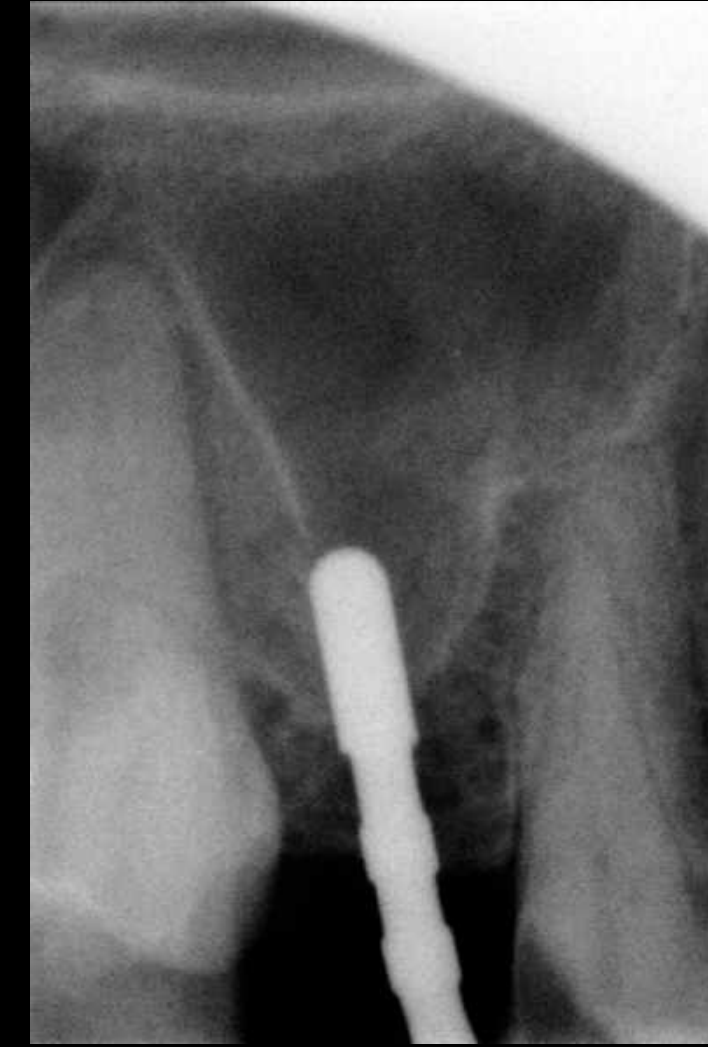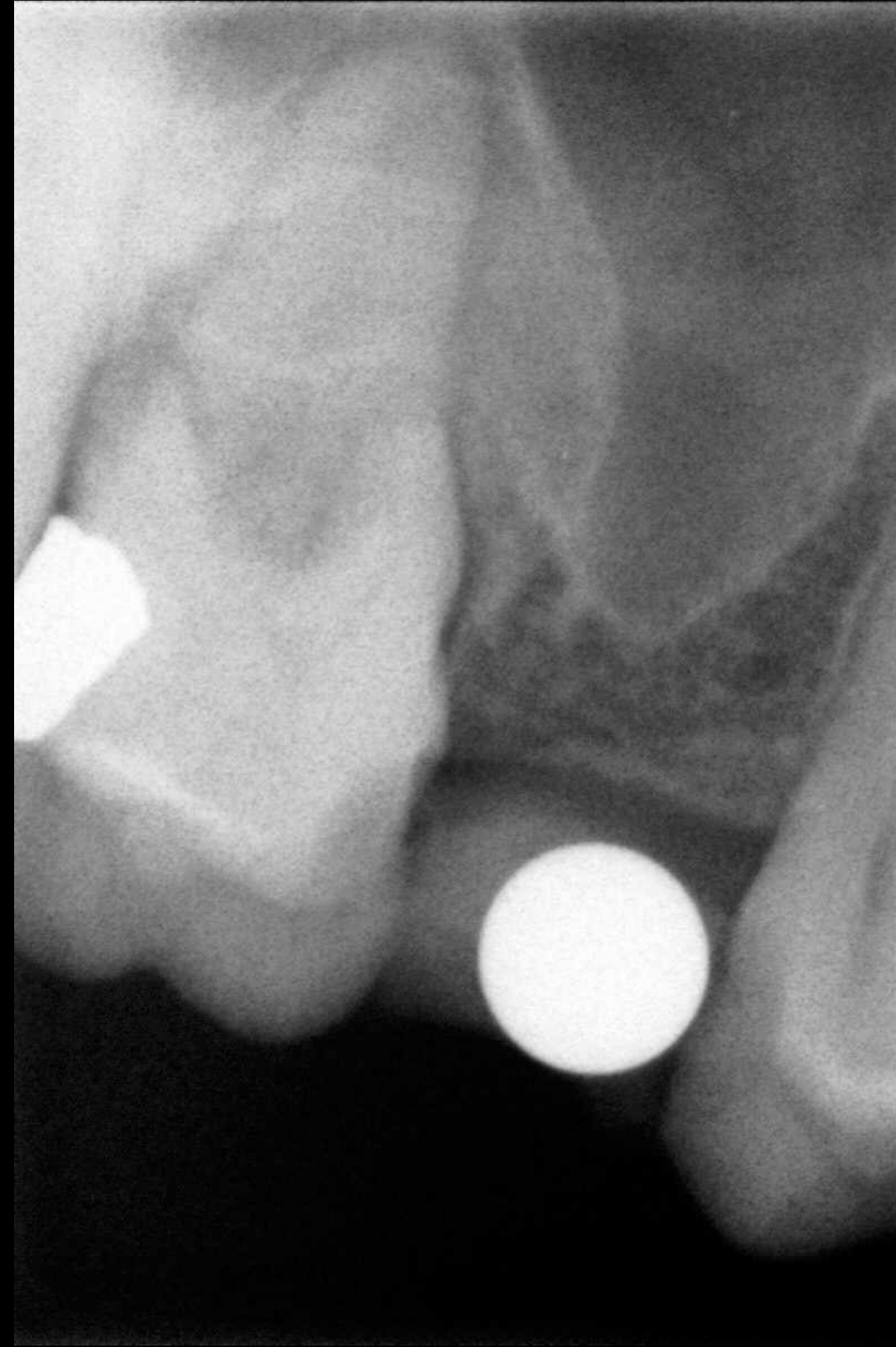Summers Modifiée



Re Modifiée par AUBAZAC et FILLION

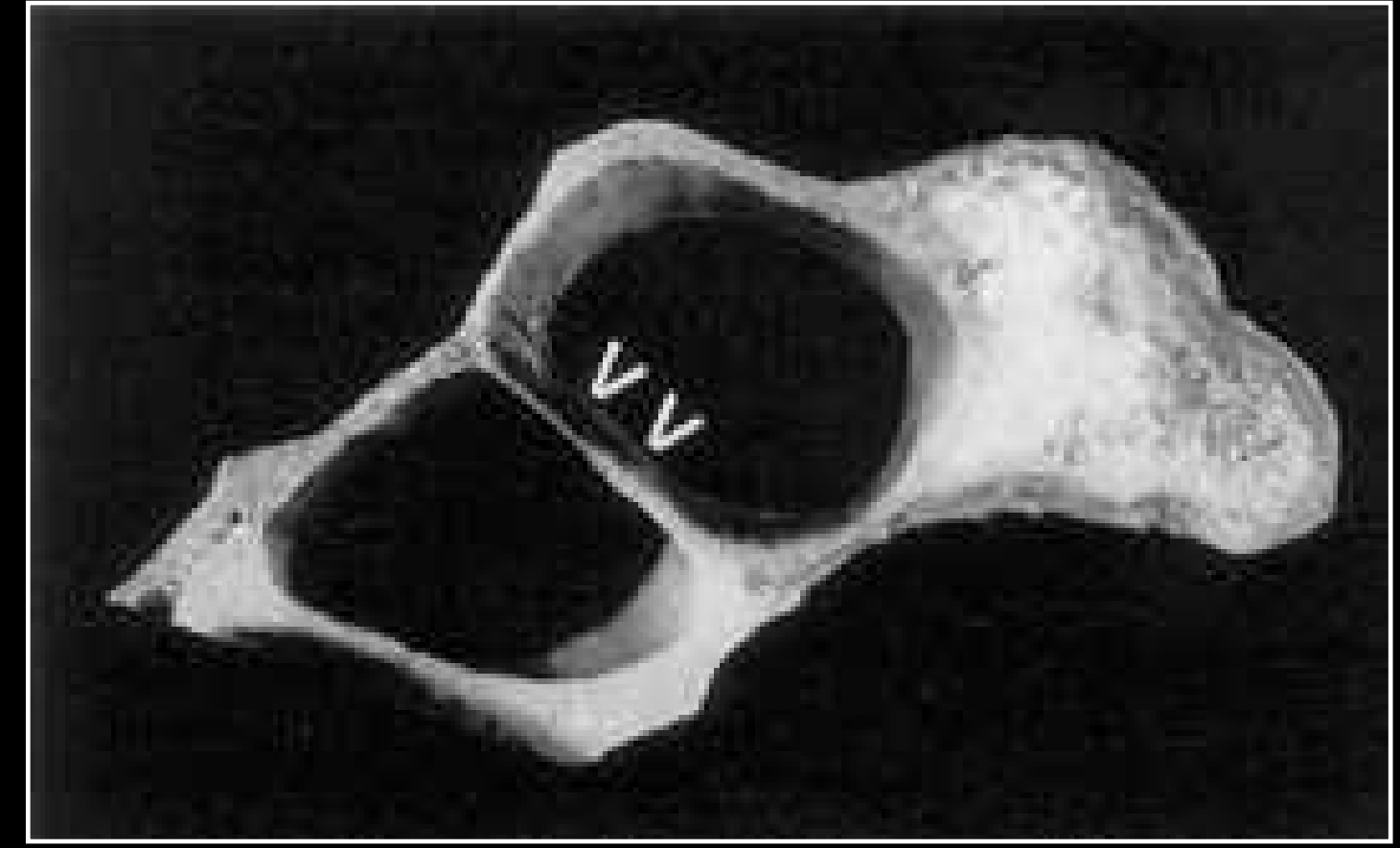
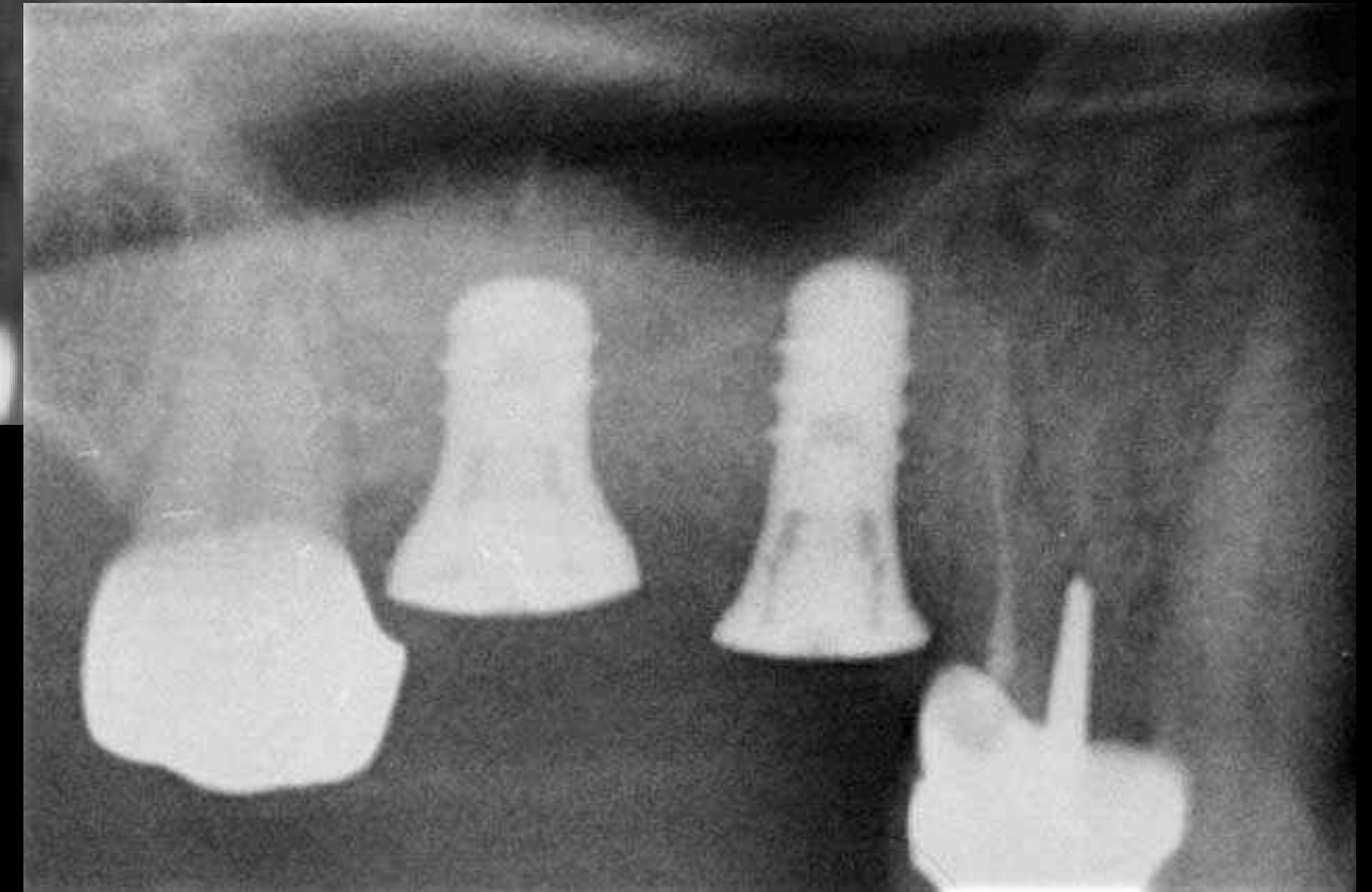
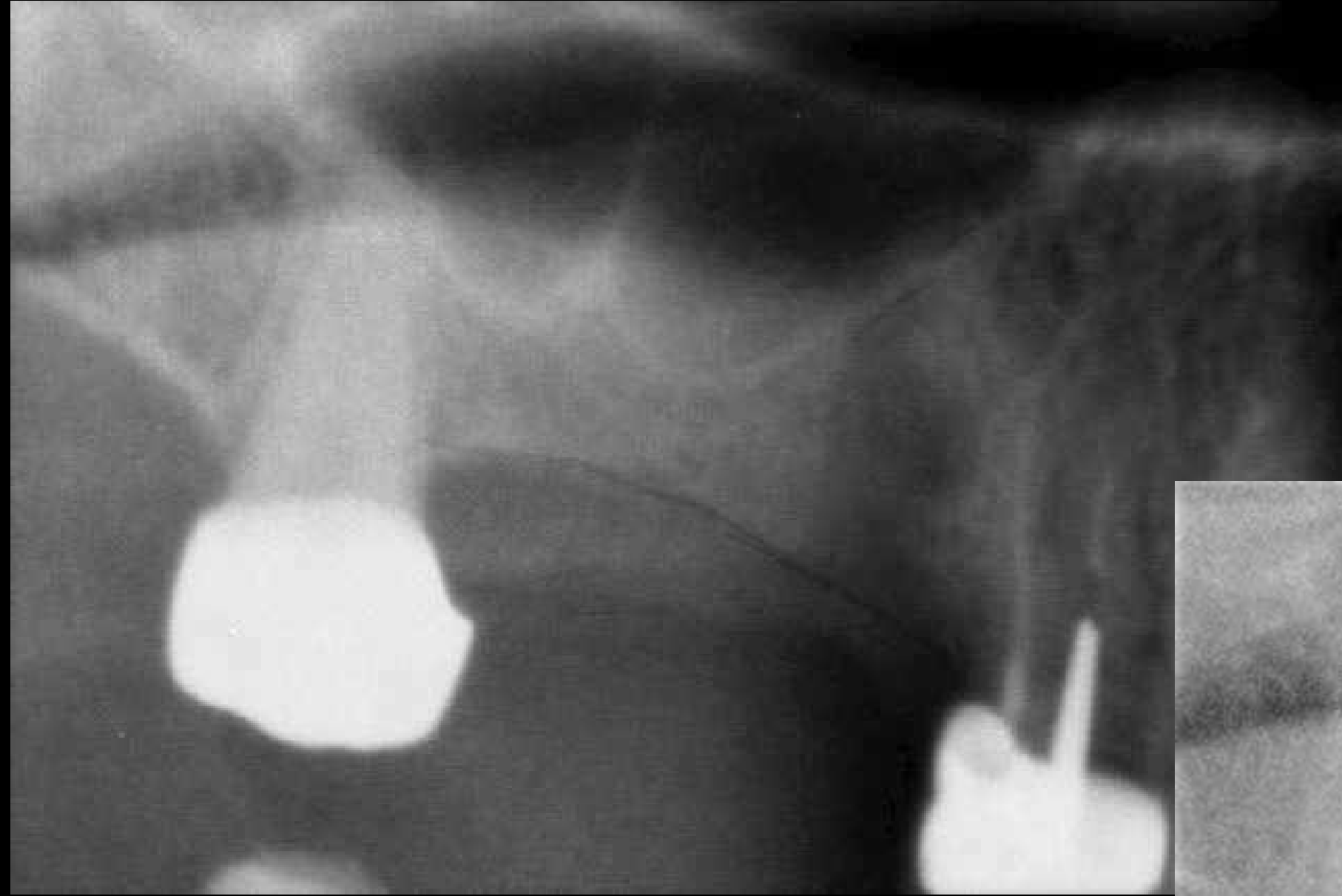
Approche Crestale

Summers Modifiée



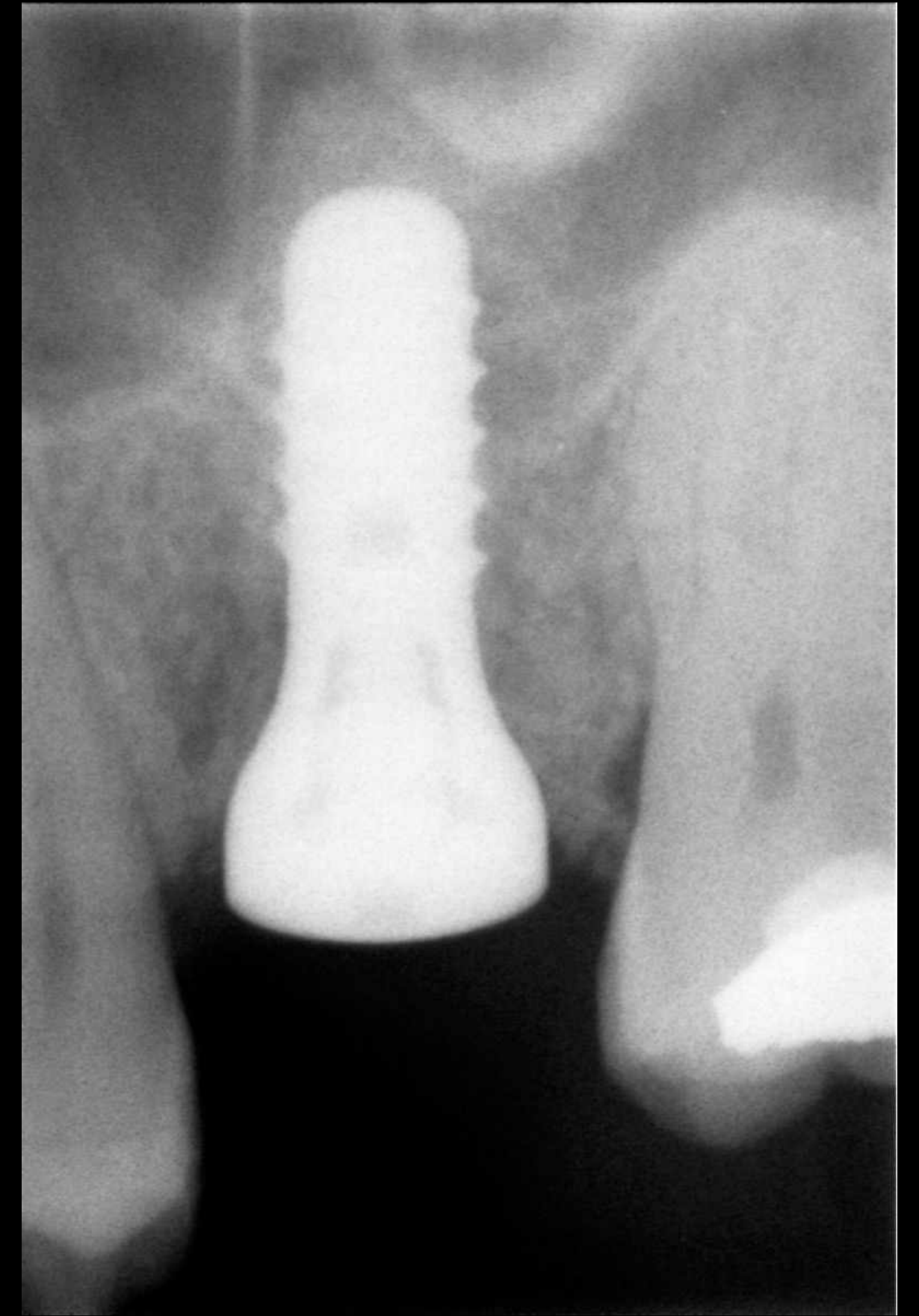
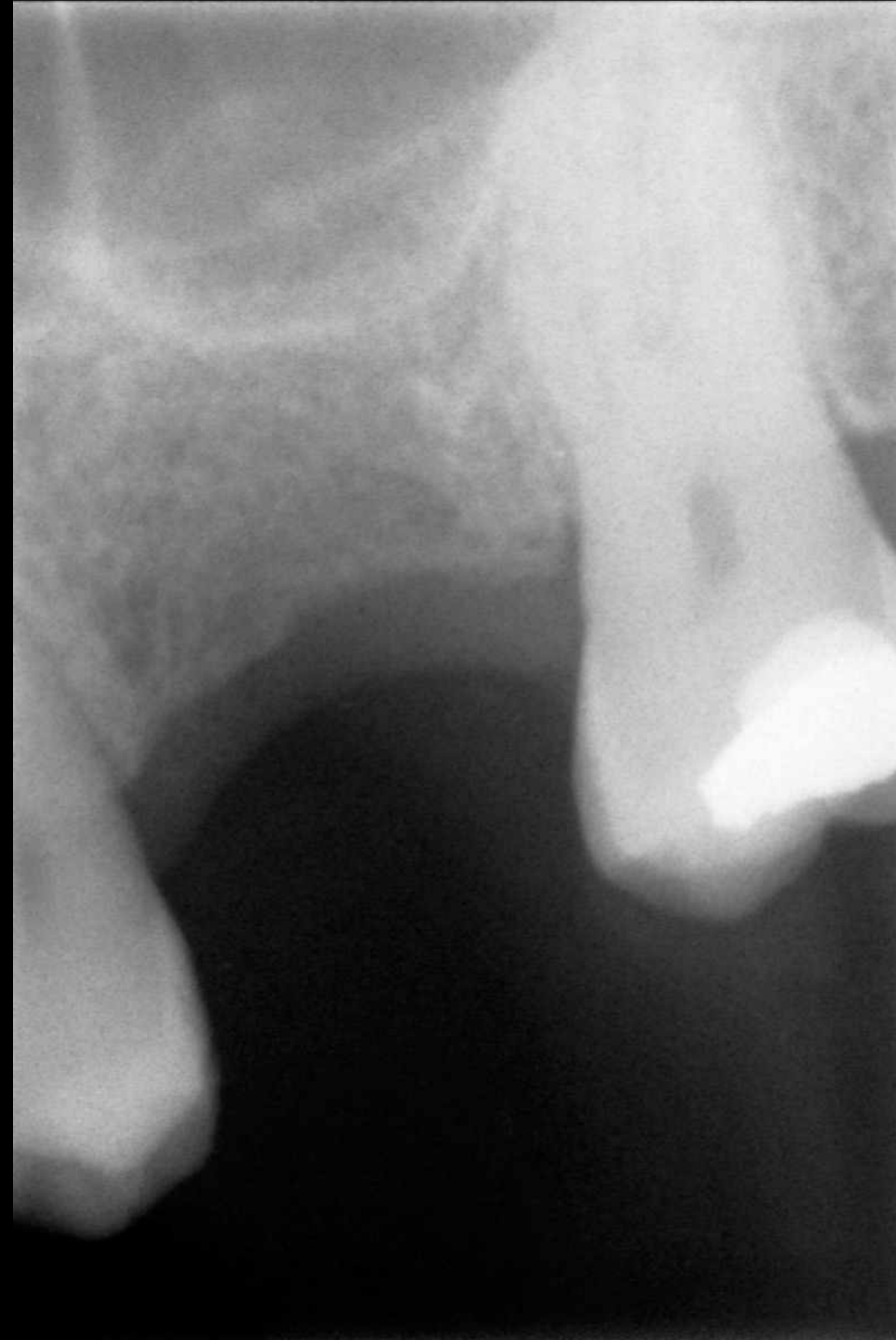Approche Crestale

Summers Modifiée



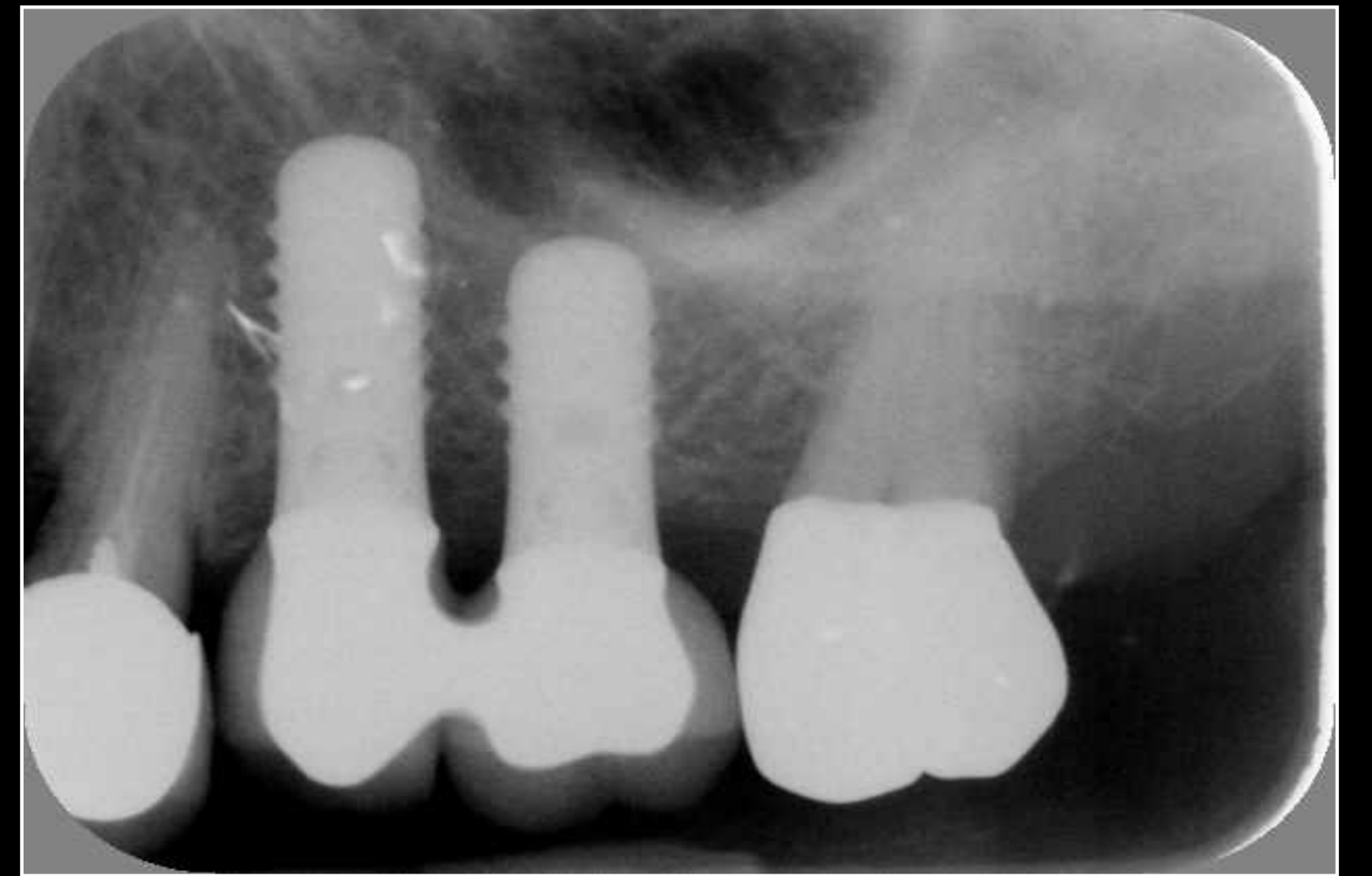
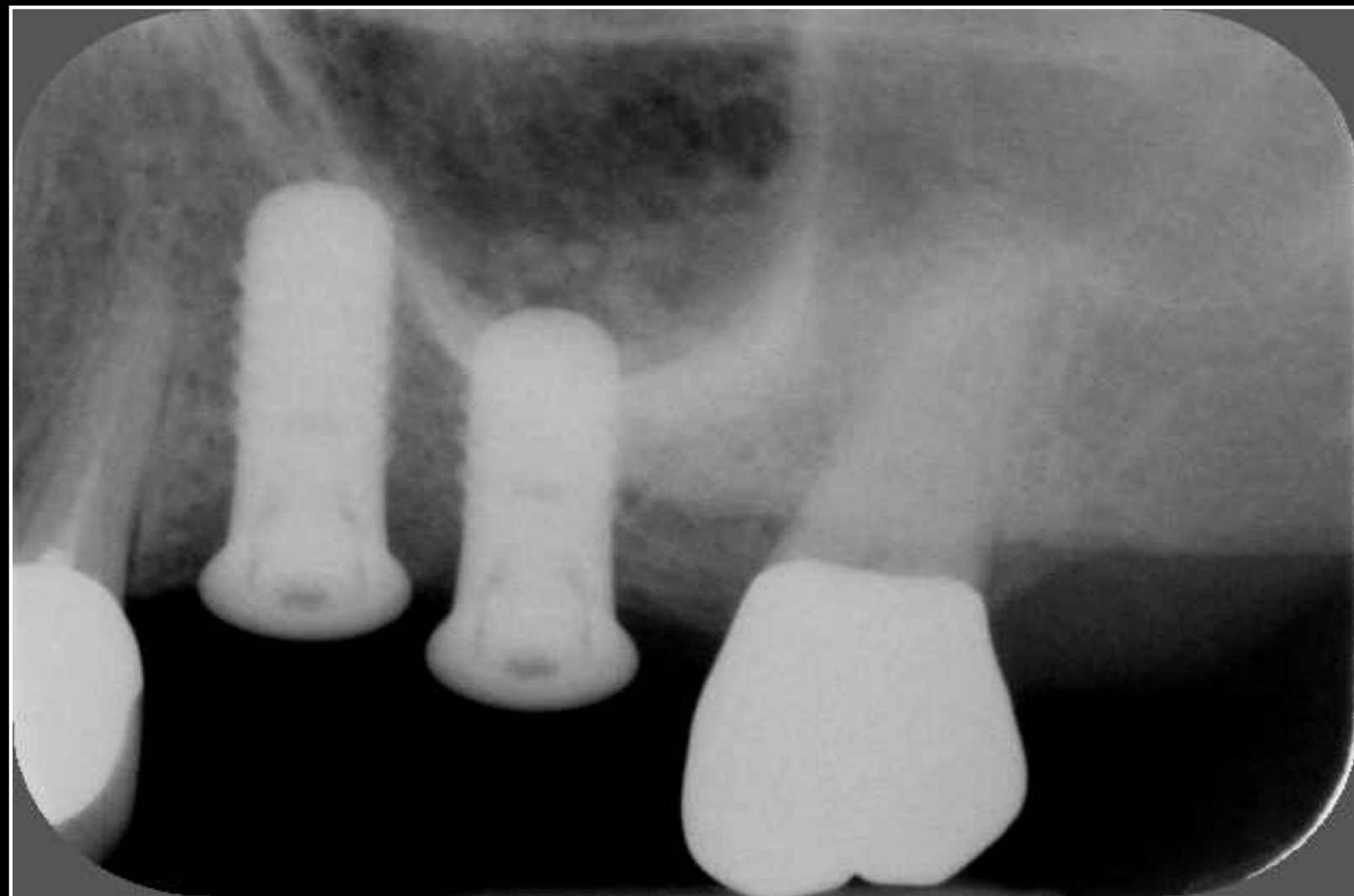
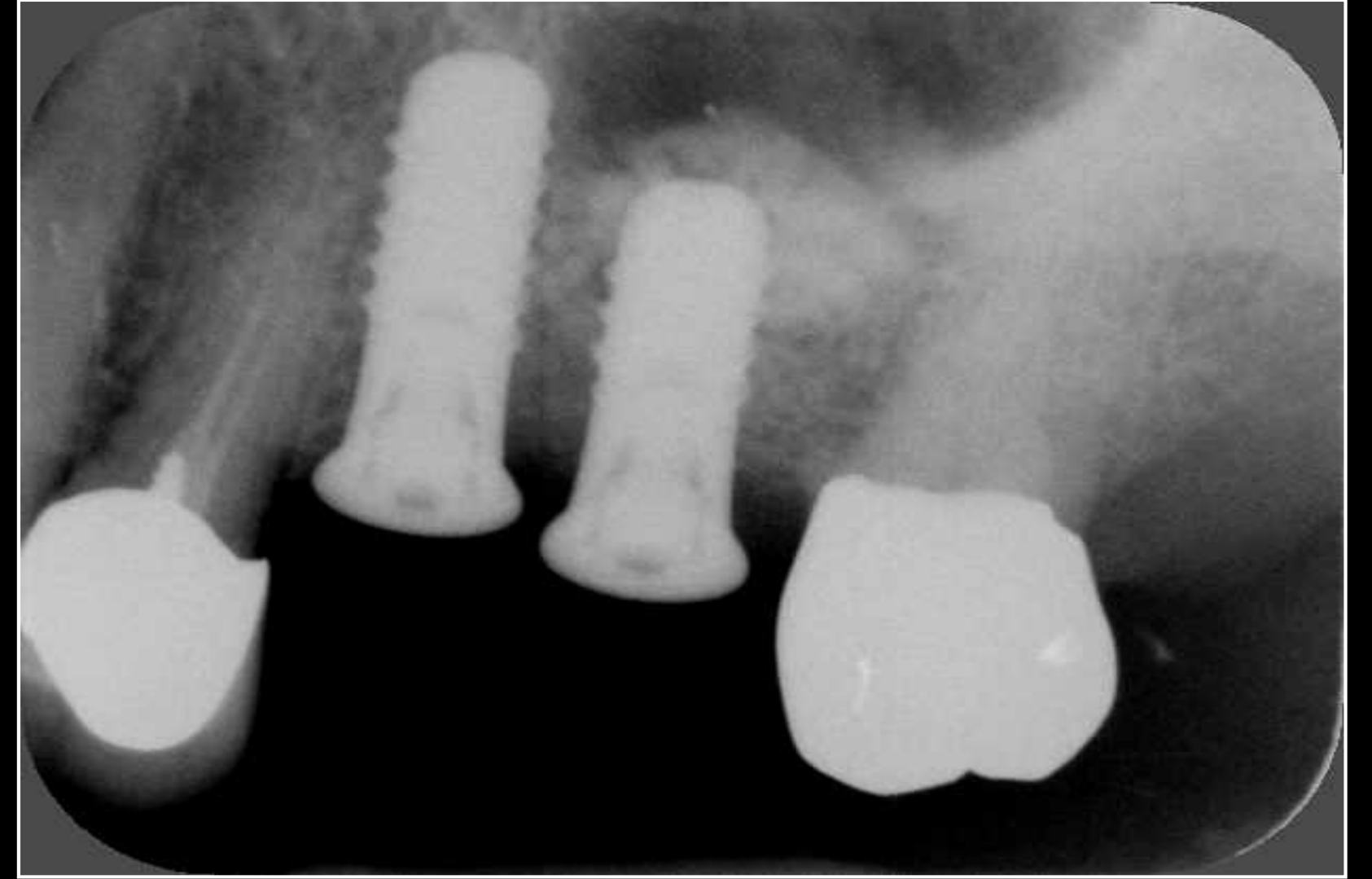
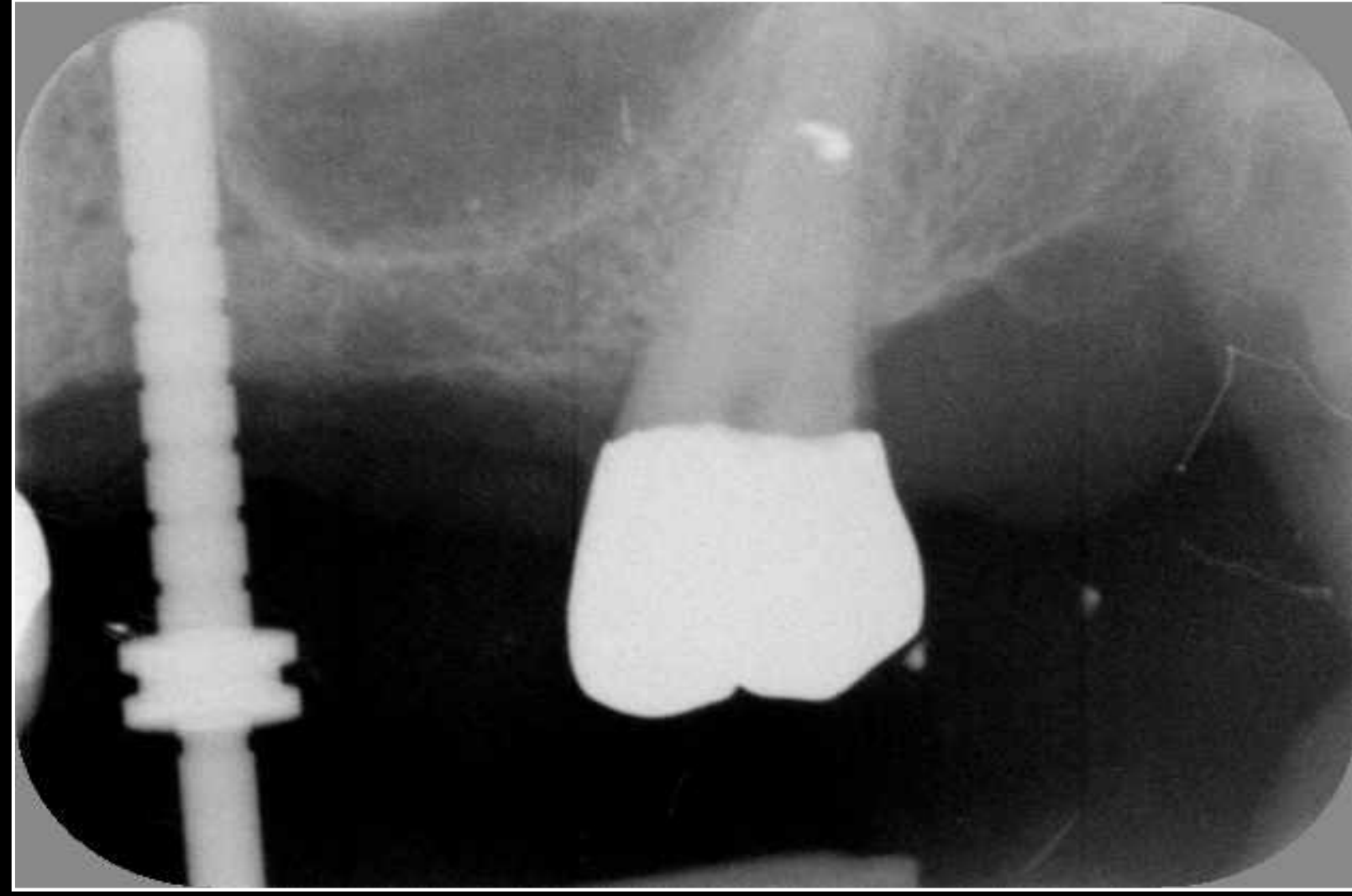
Approche Crestale

Summers Modifiée

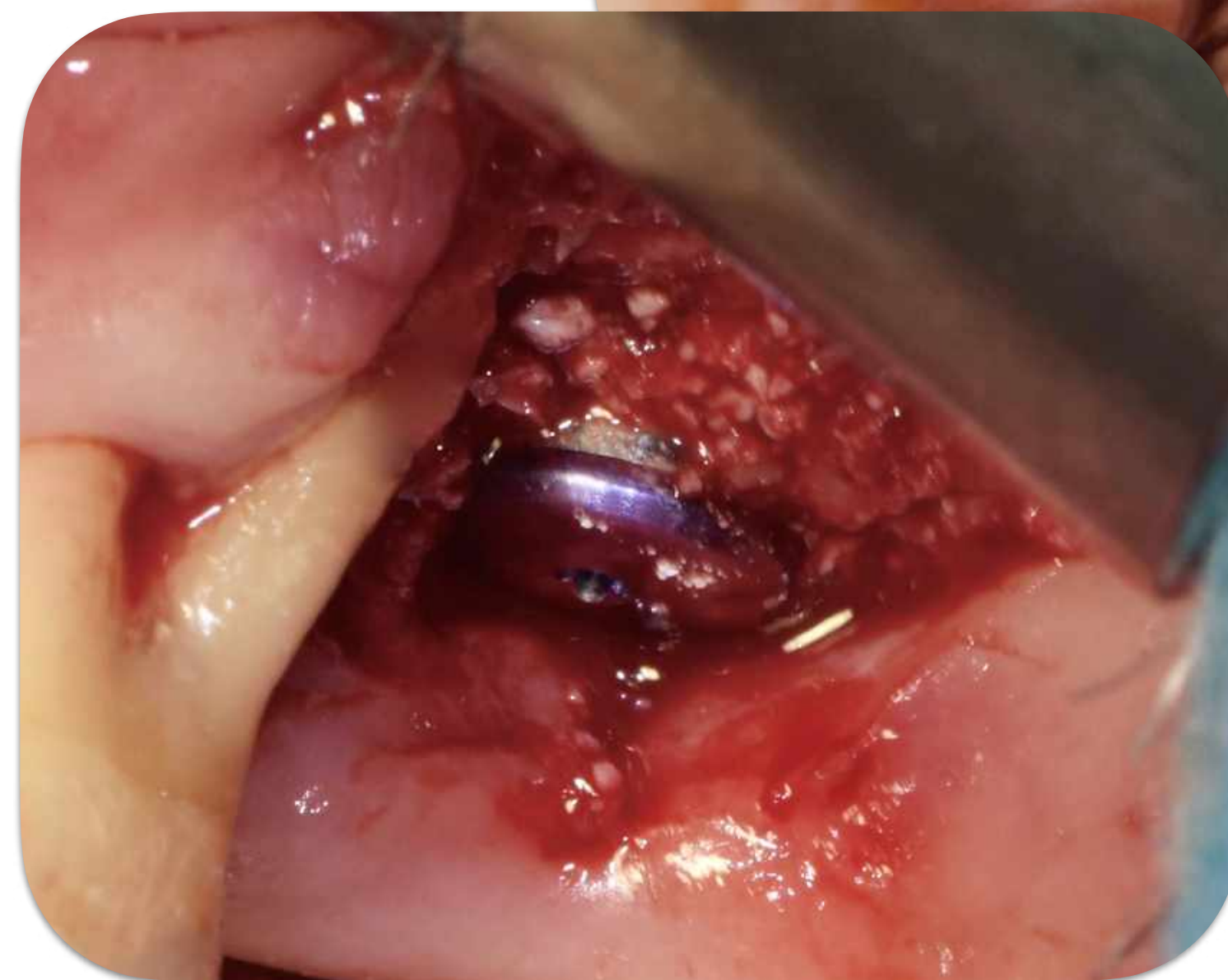
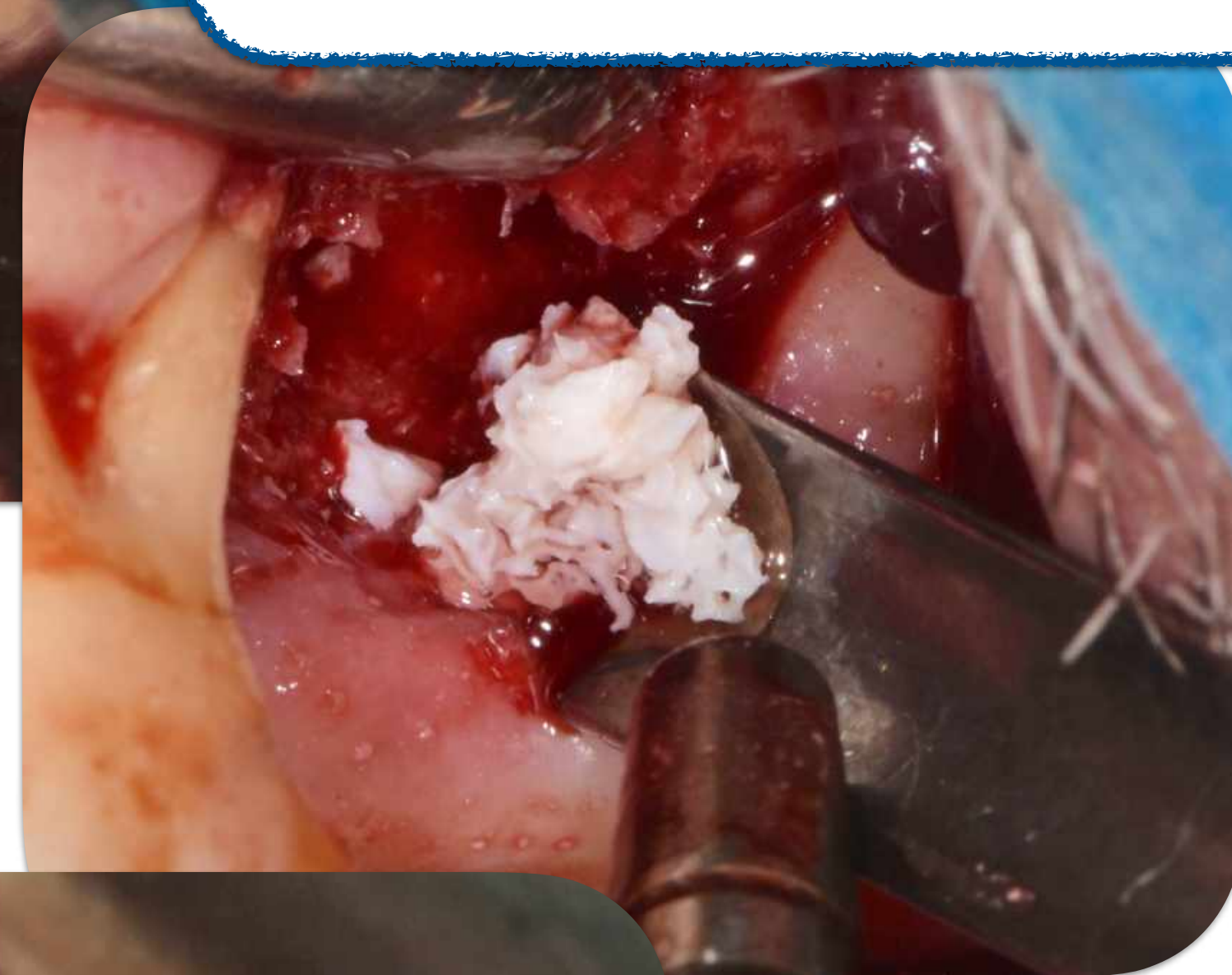
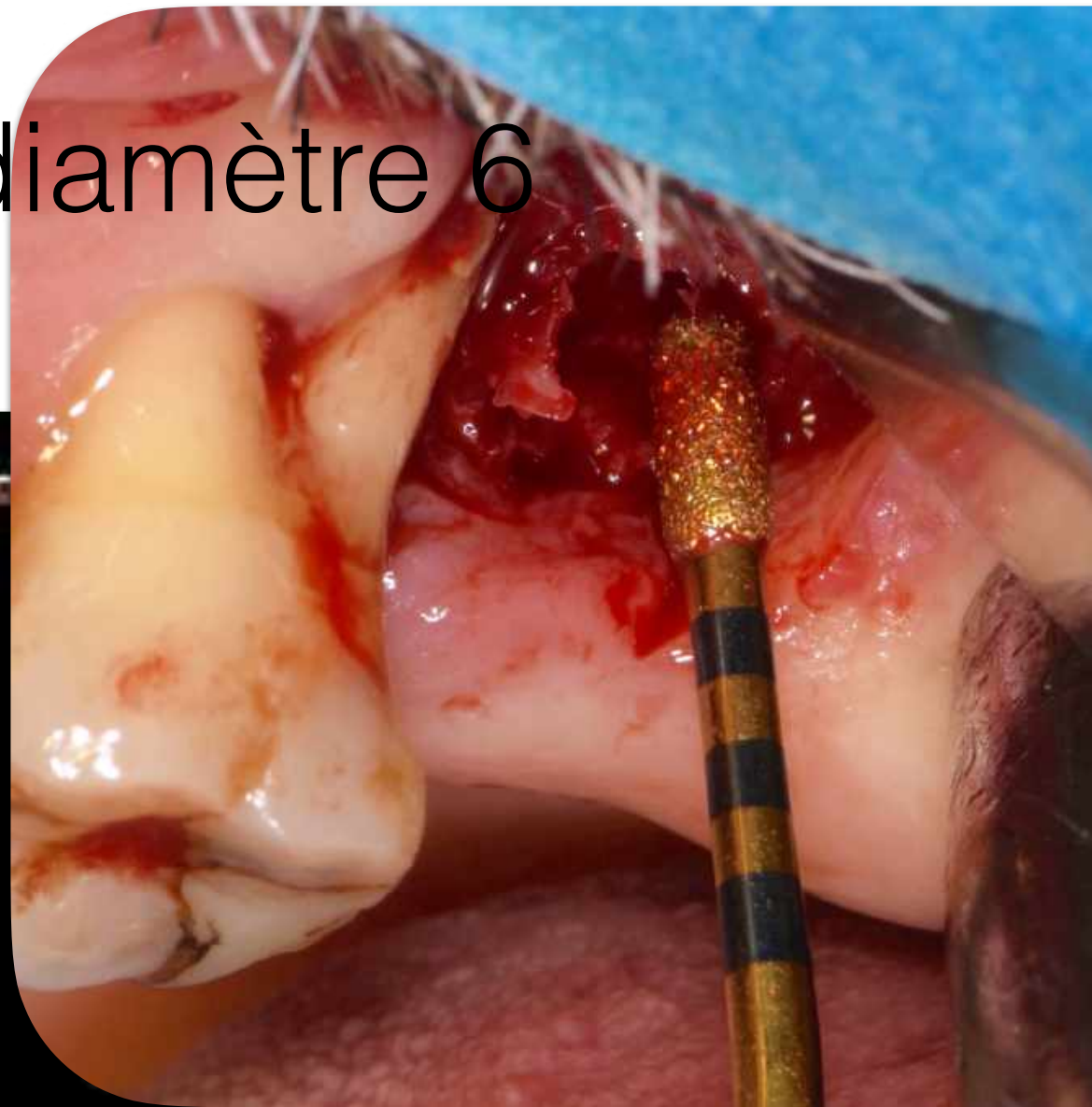
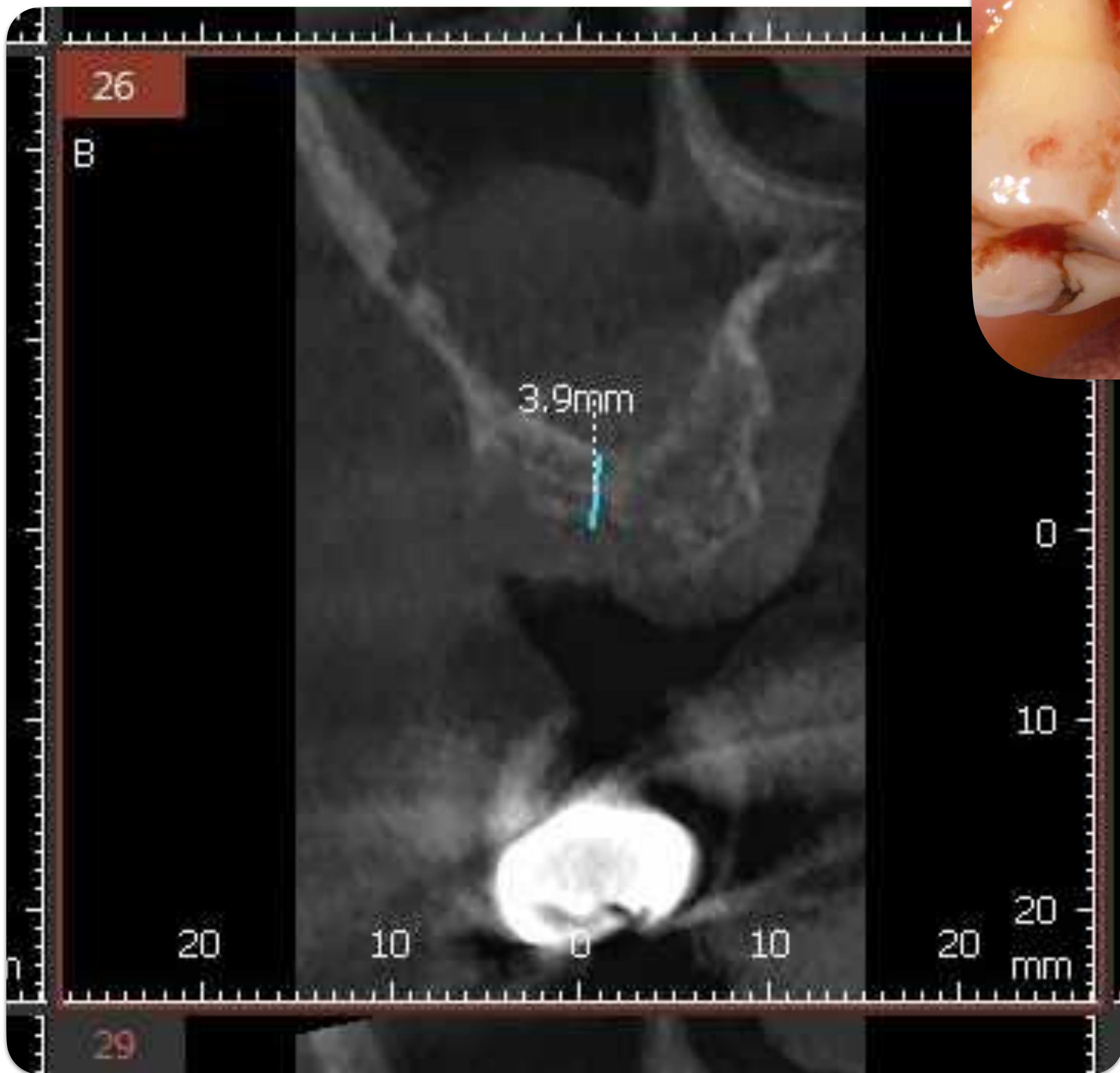
Approche Crestale

Summers Modifiée



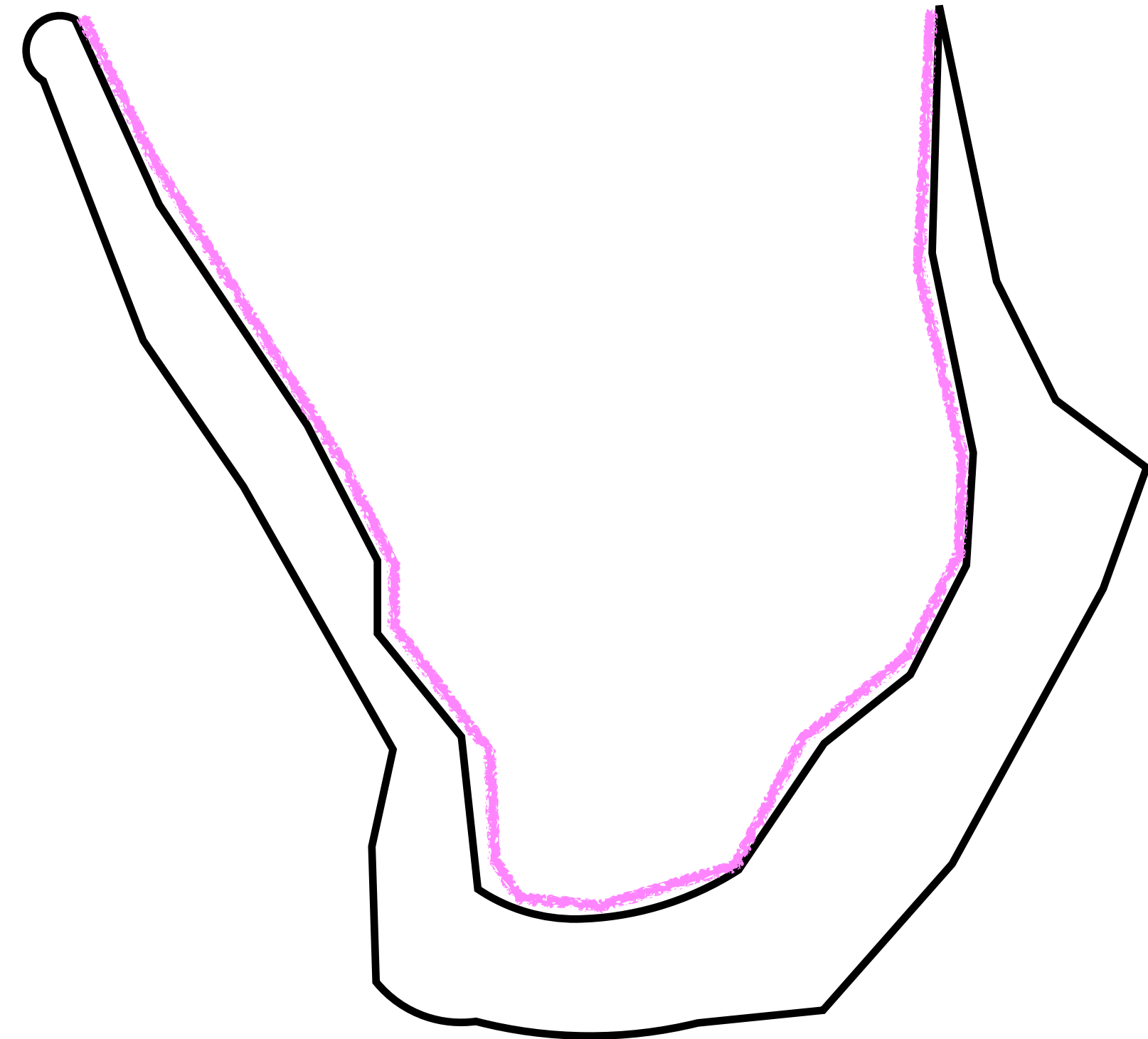
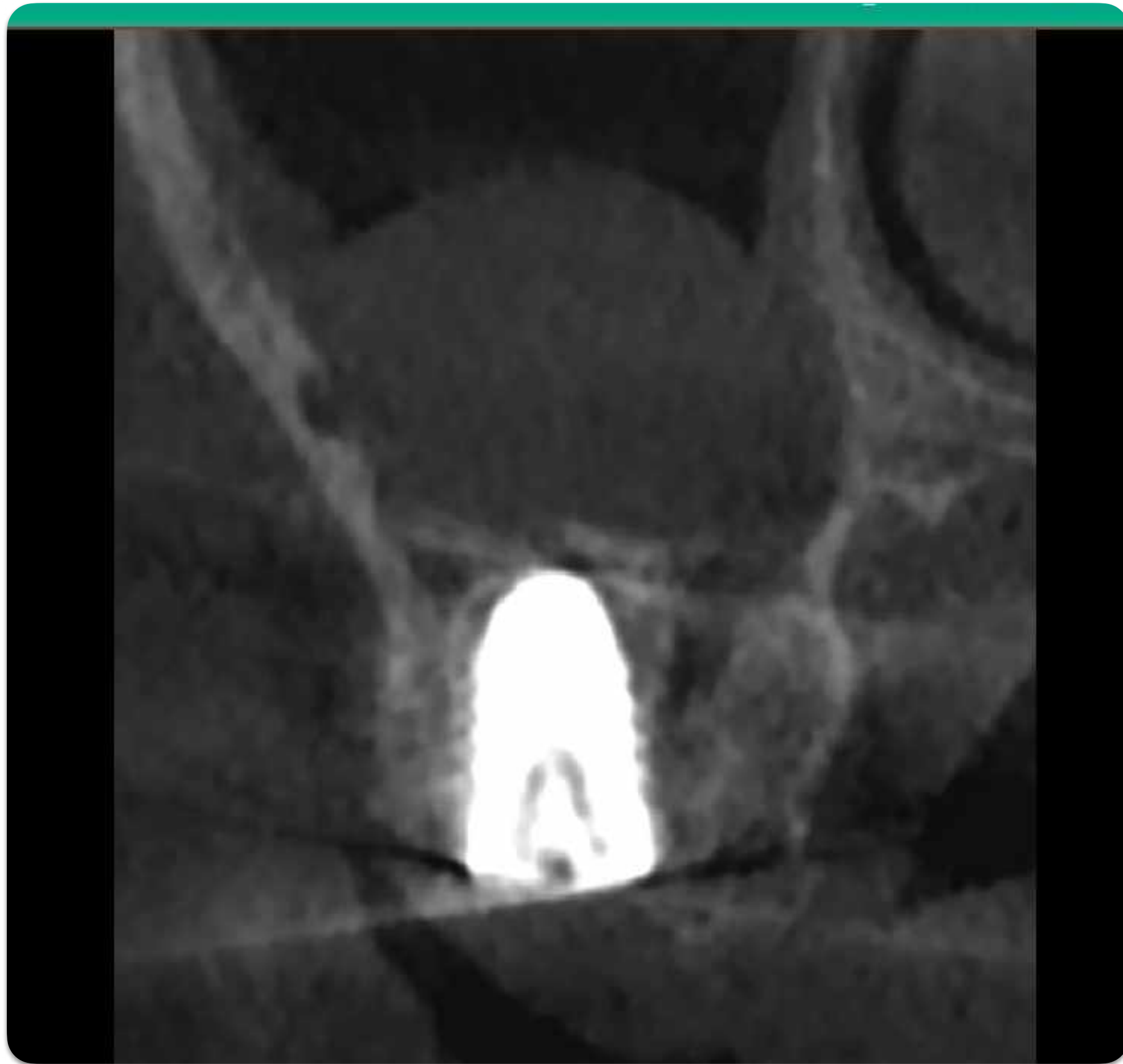Implants courts : Longueur 8 #diamètre 6



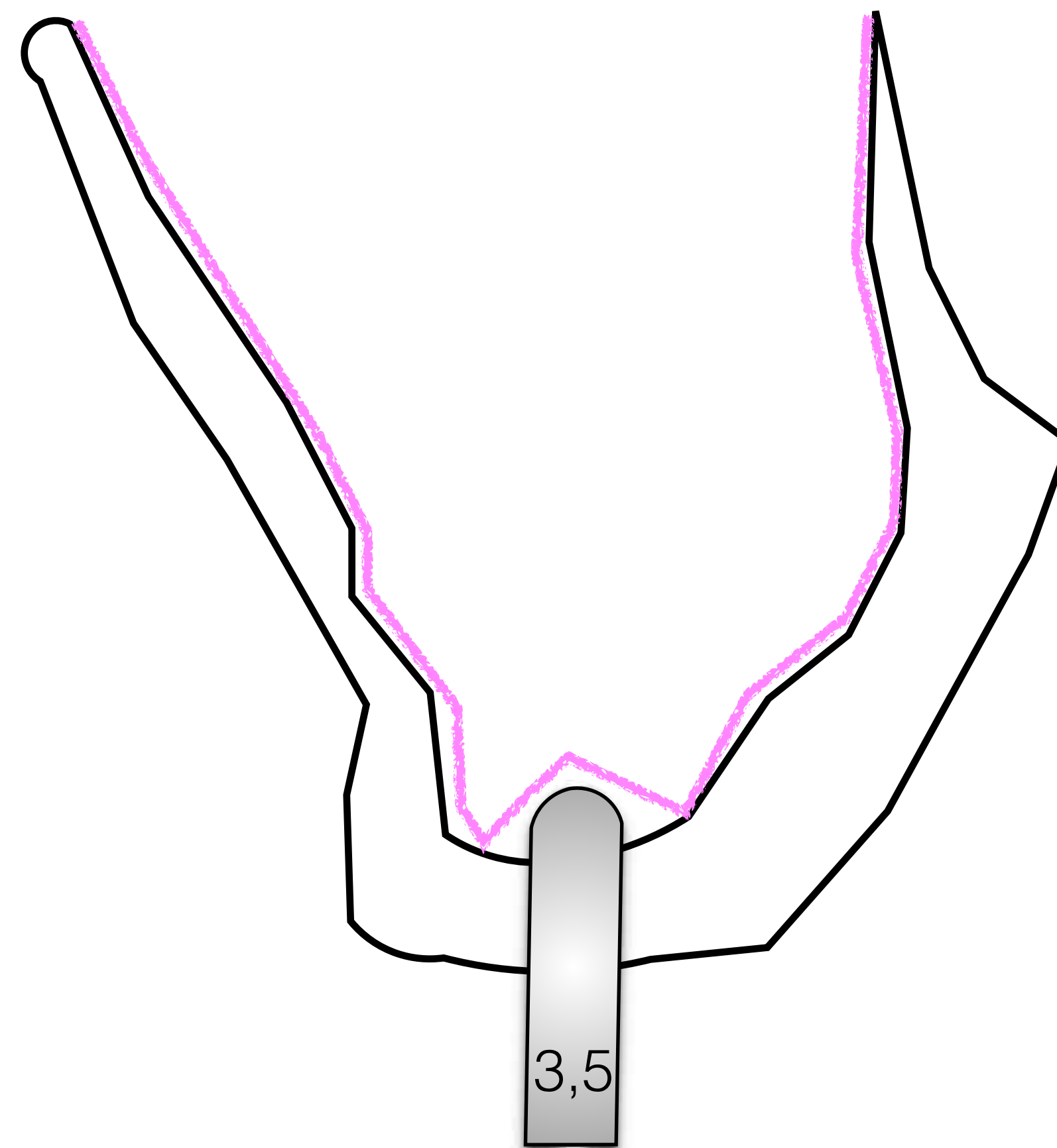
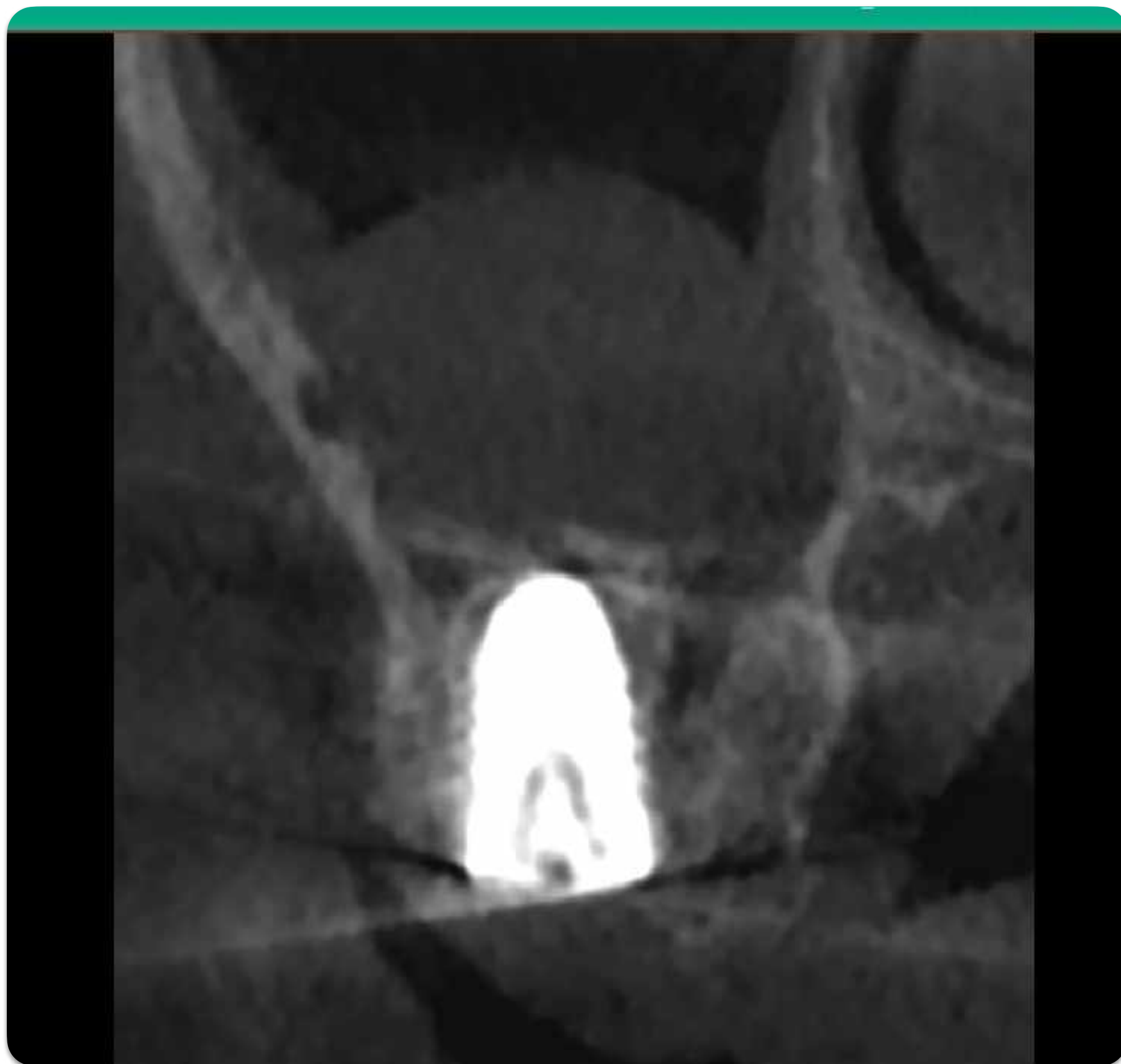Technique de Summers modifiée

#implications bio-mécaniques

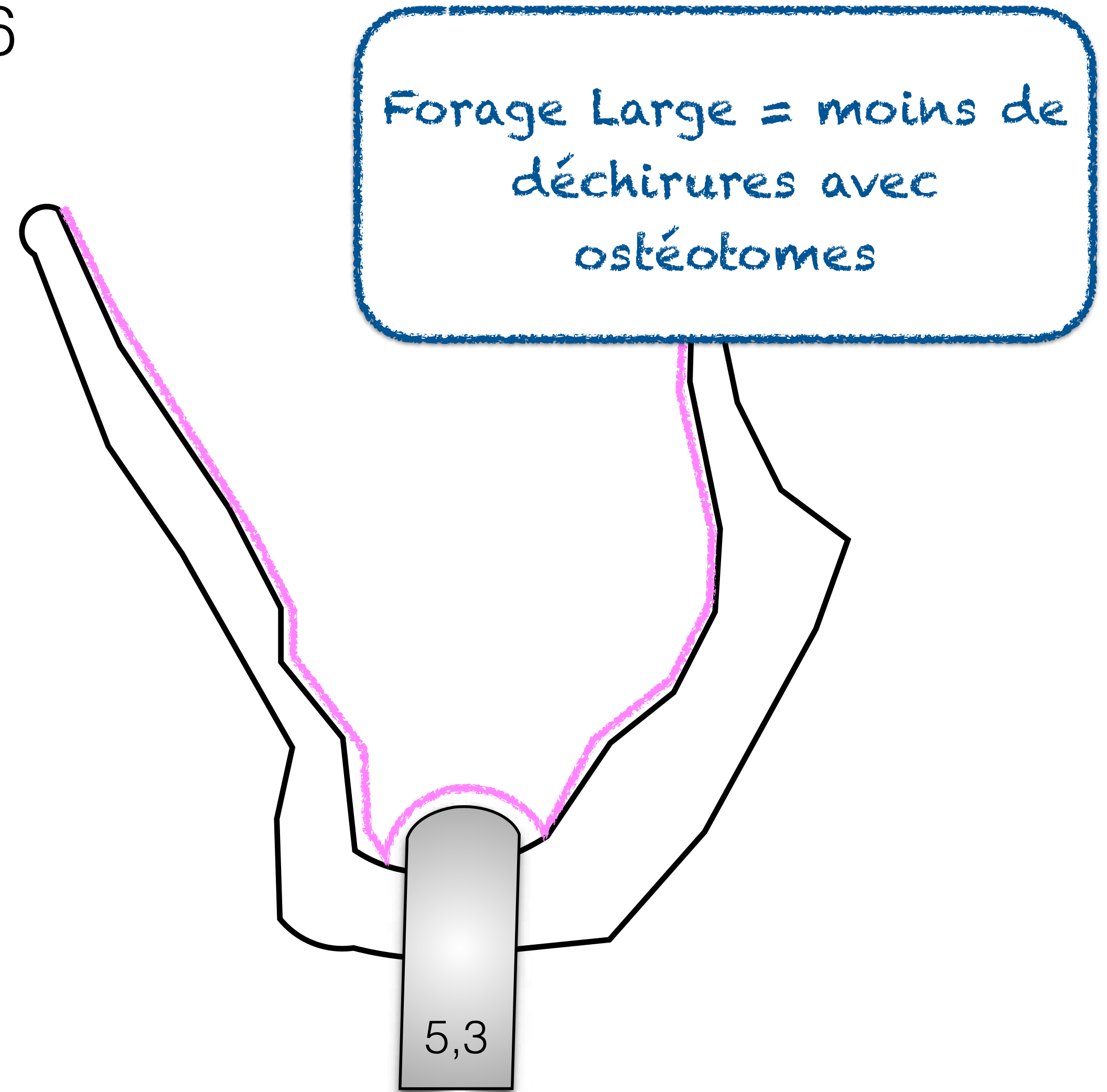
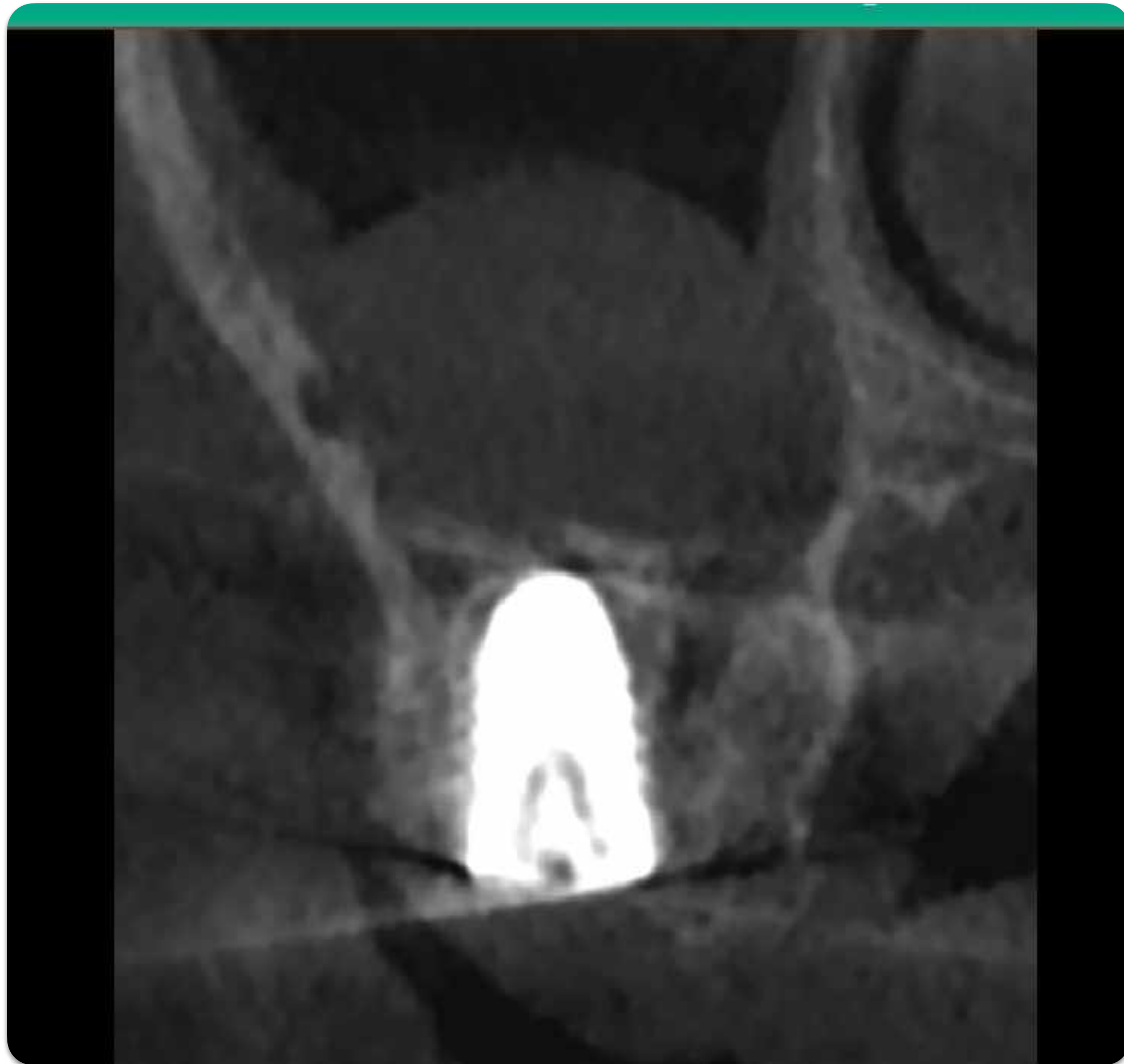Implants courts : Longueur 8 #diamètre 6



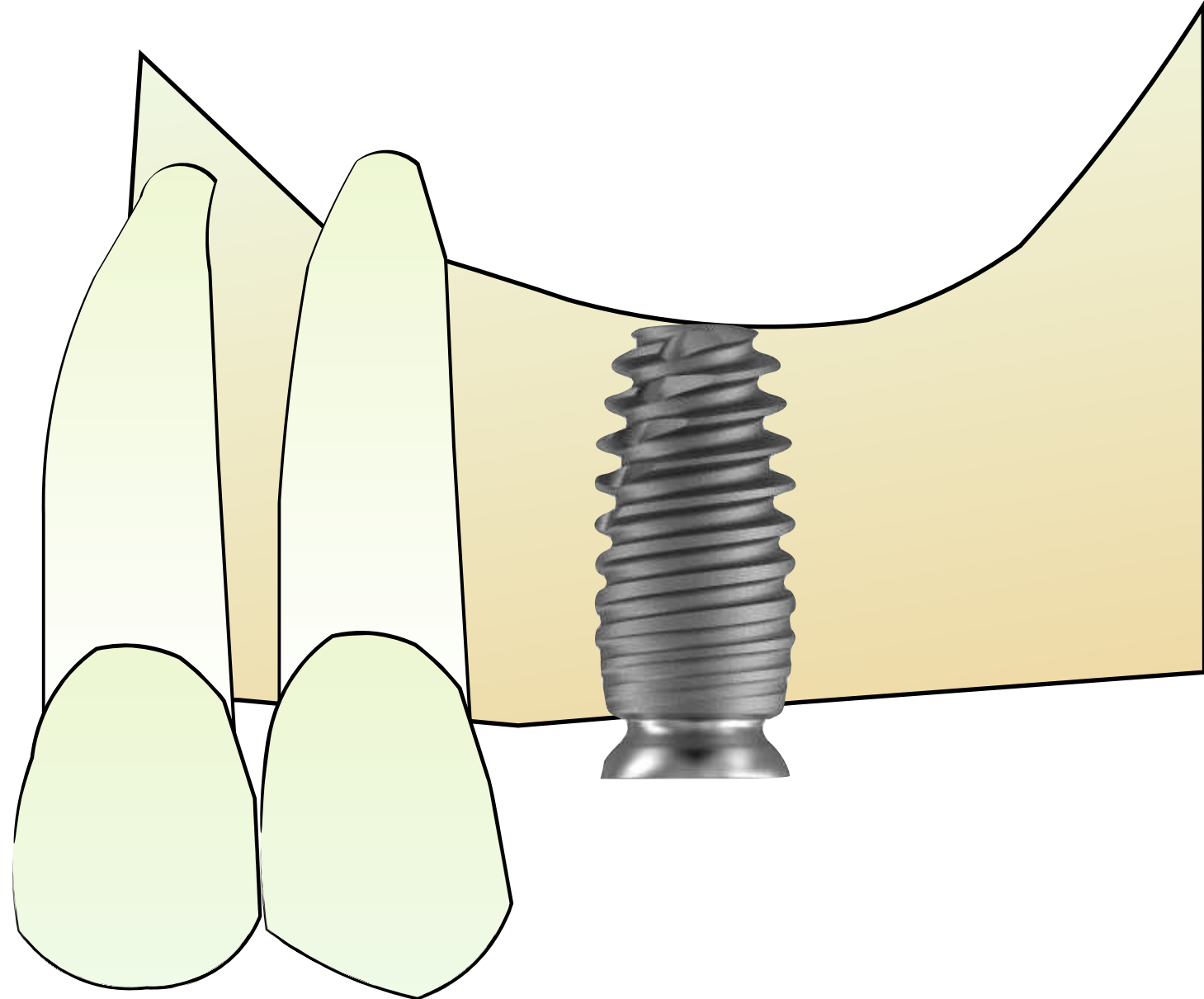
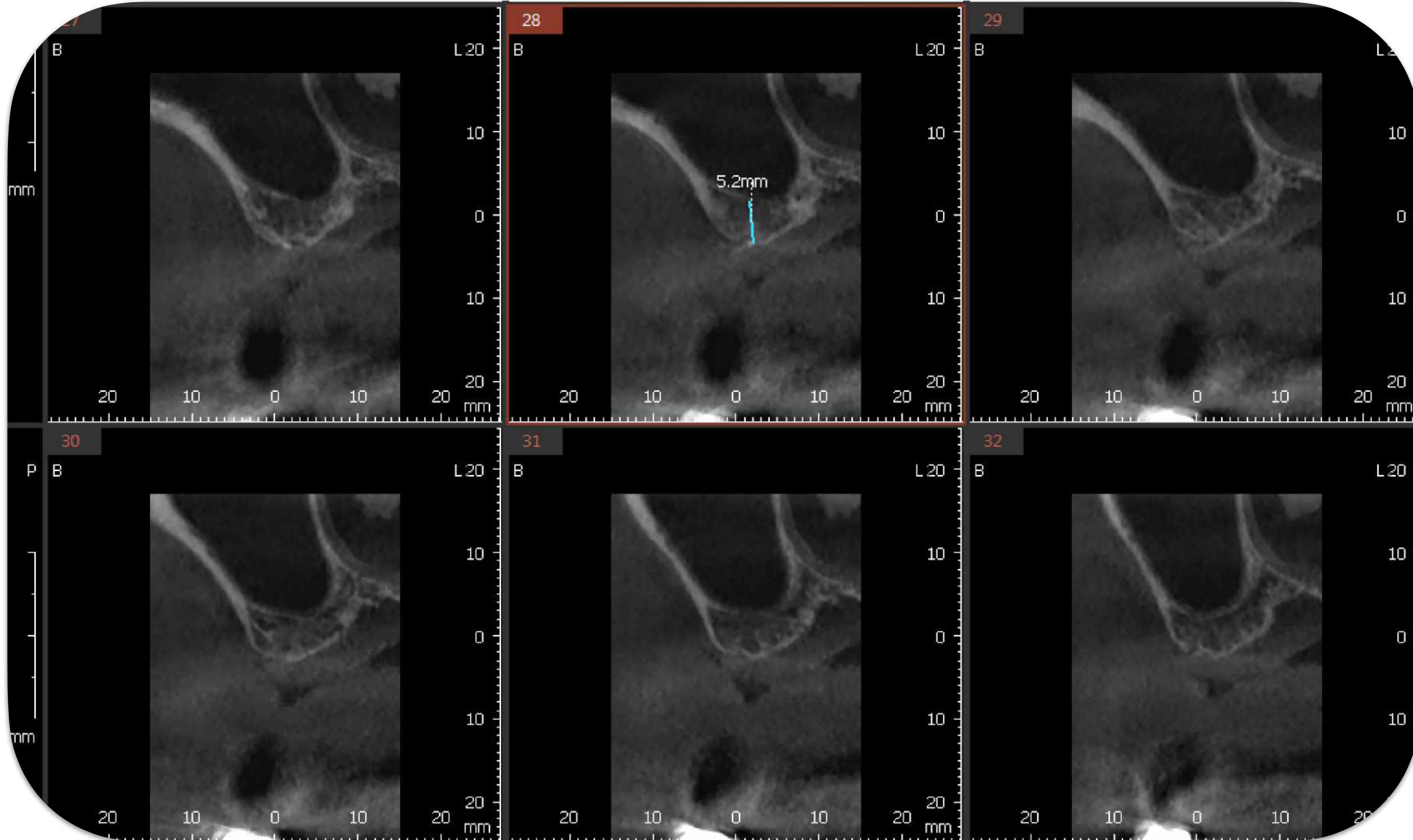
Implants courts : Longueur 8 #diamètre 6



Implants courts : Longueur 8 #diamètre 6

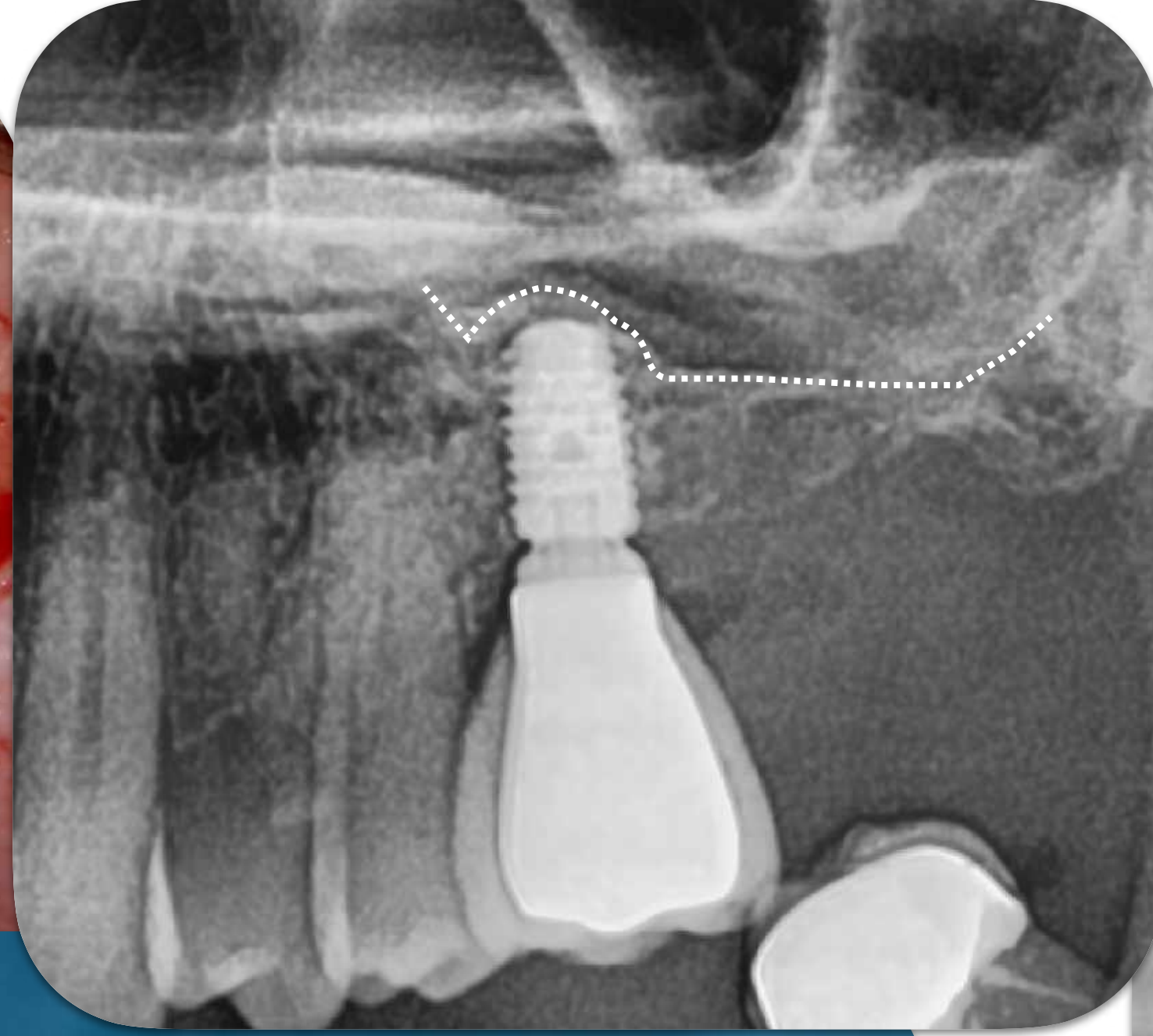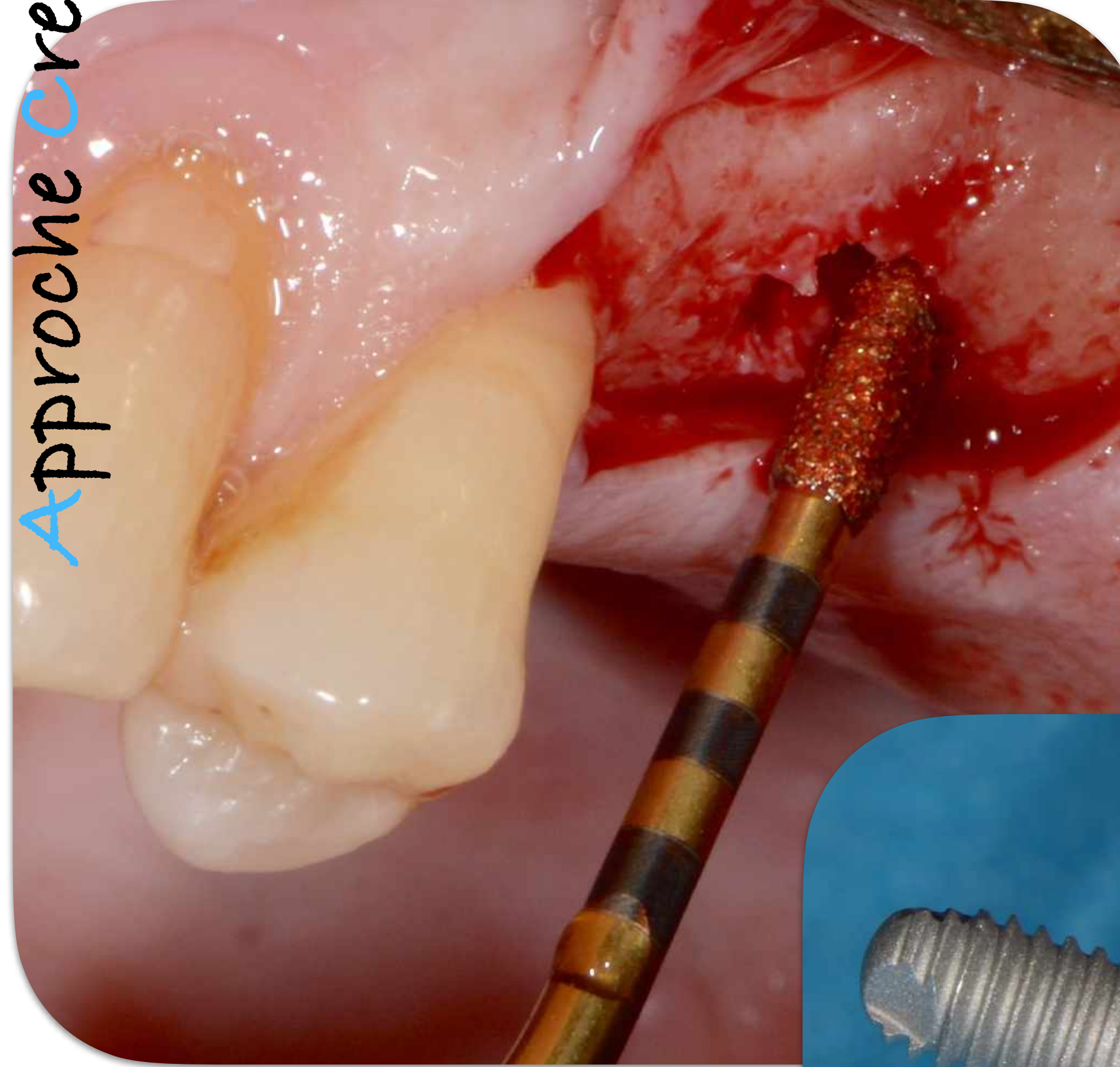


Col 1,5 : Pose d'implants courts et risques anatomiques = ne pas sur-enfouir l'implant !

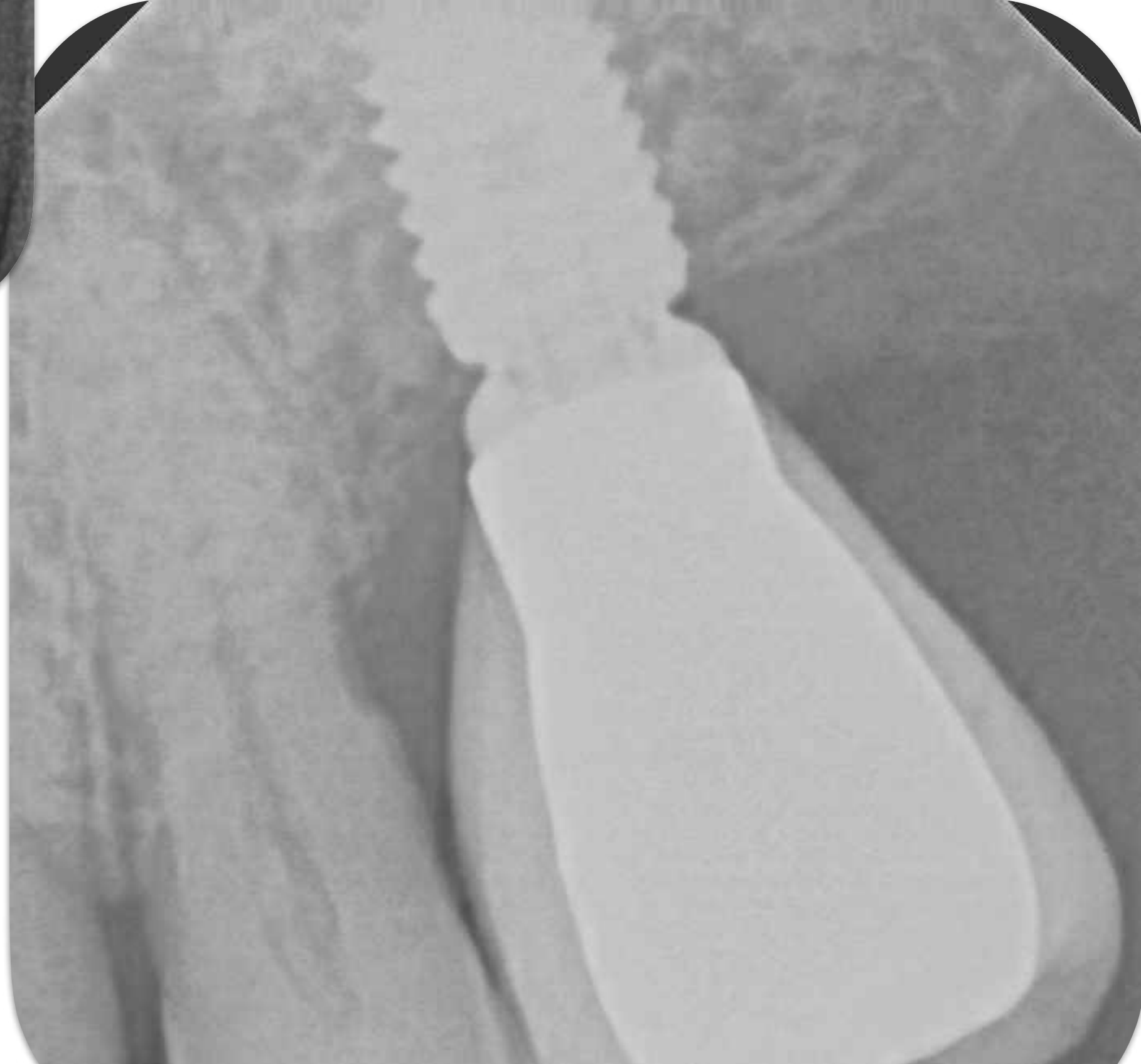
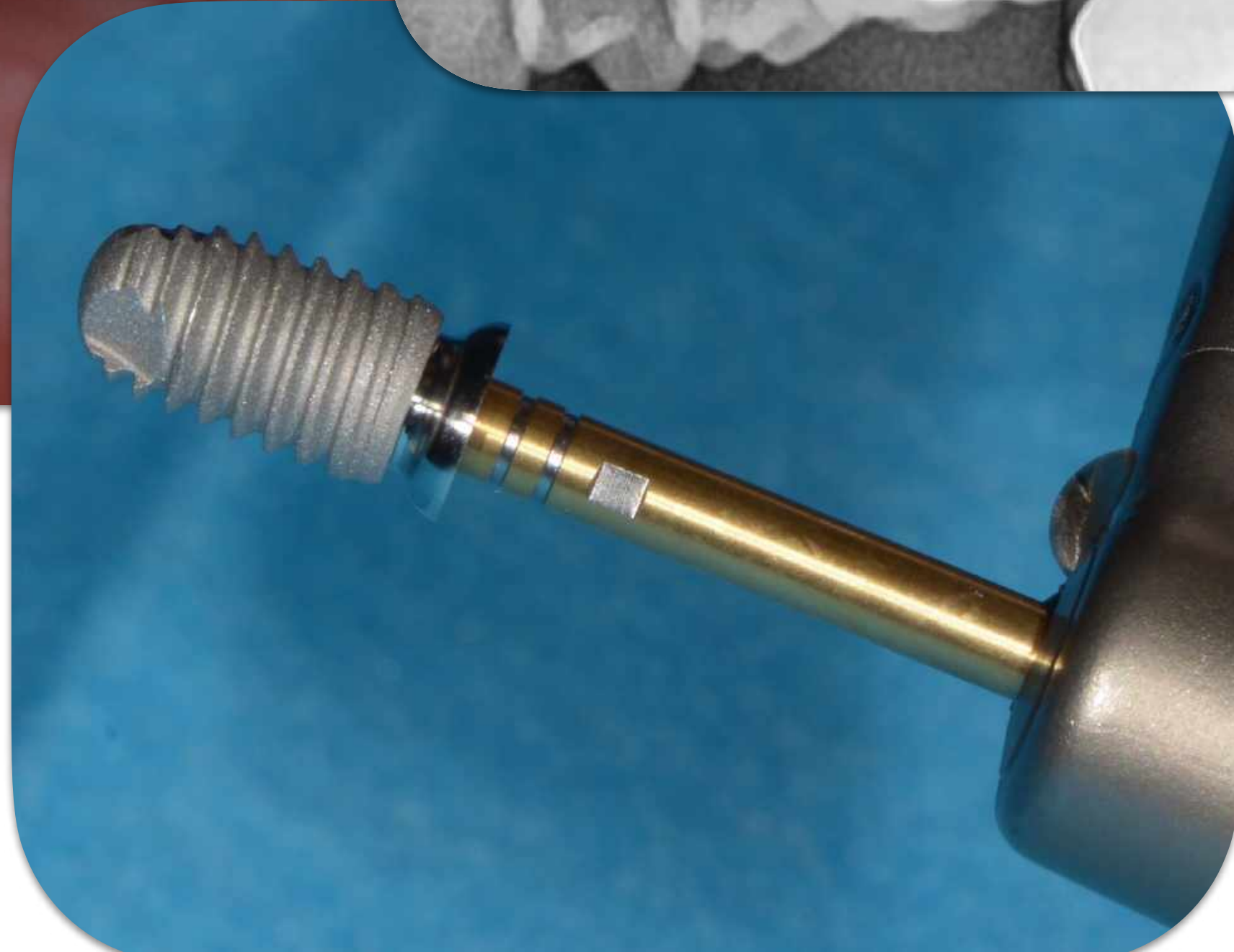
Implant L 8 Col R1,5

Col 1,5 : Pose d'implants courts et summers modifié

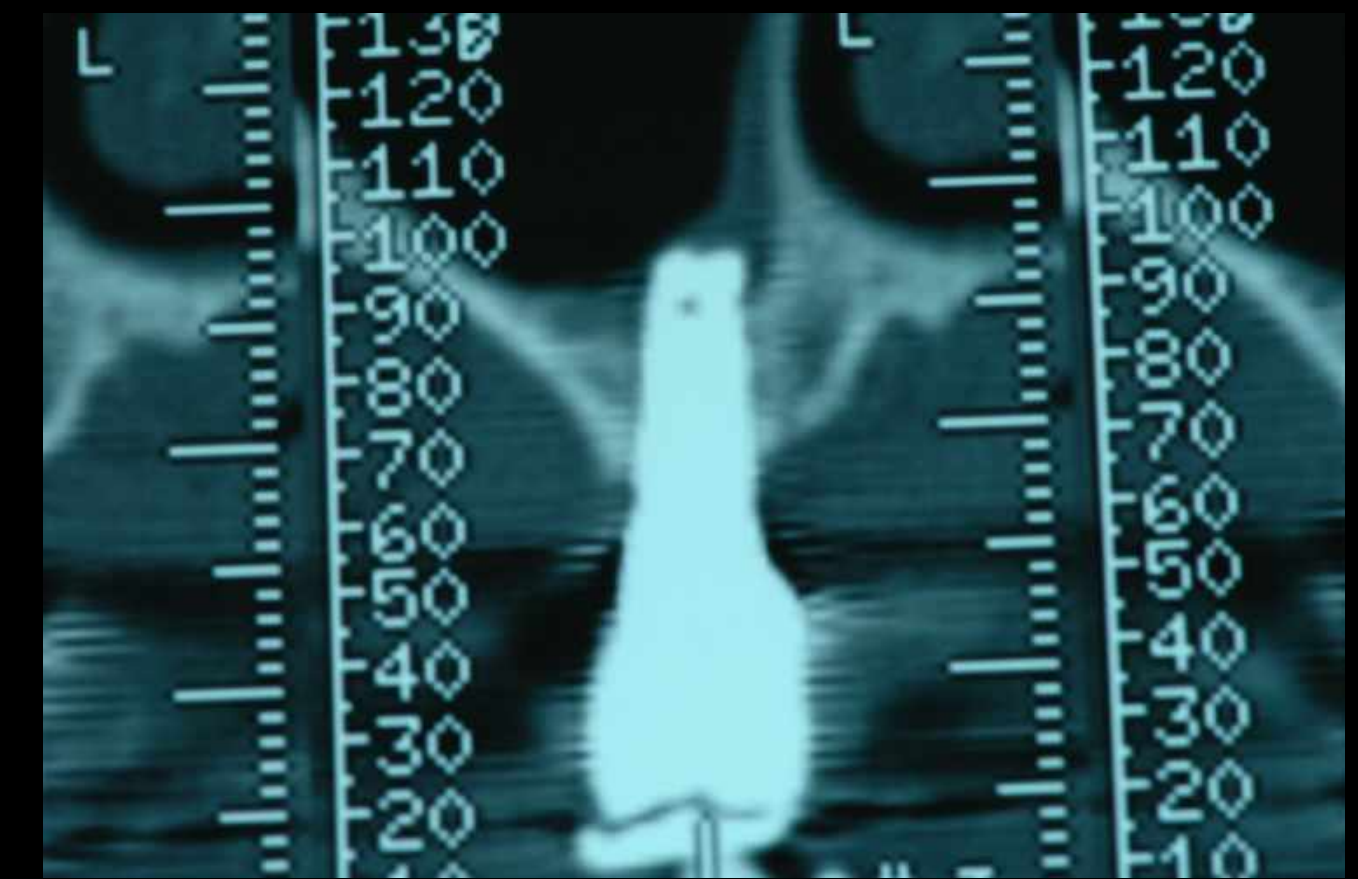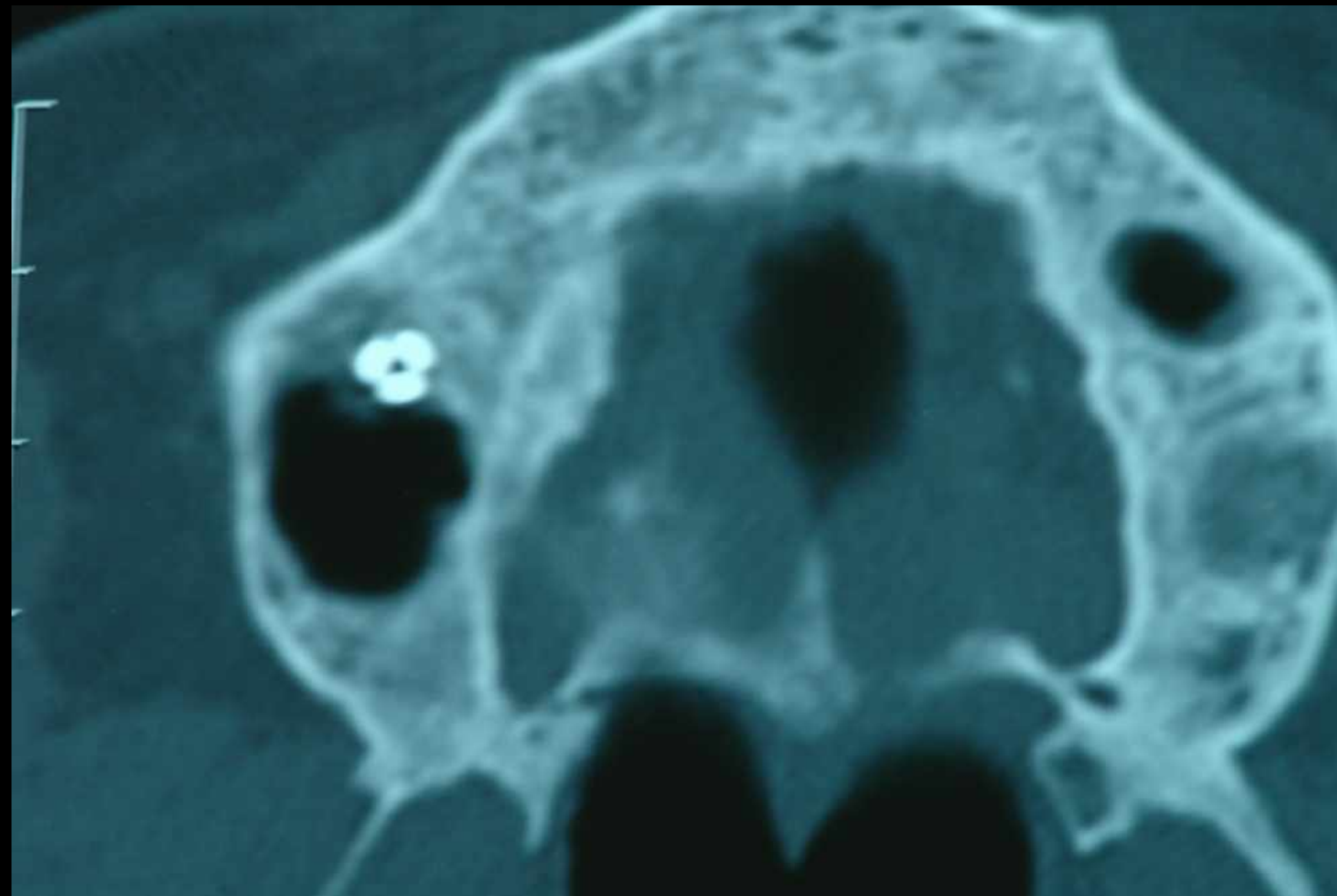

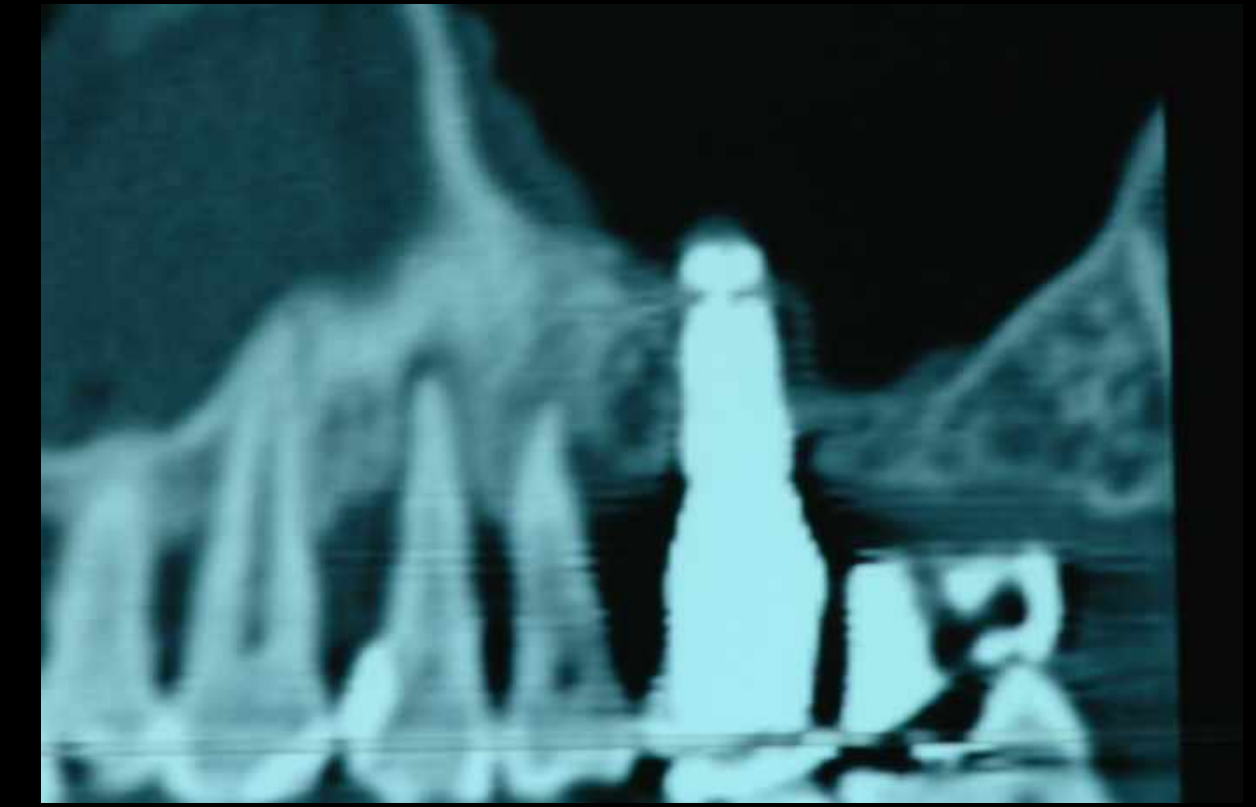
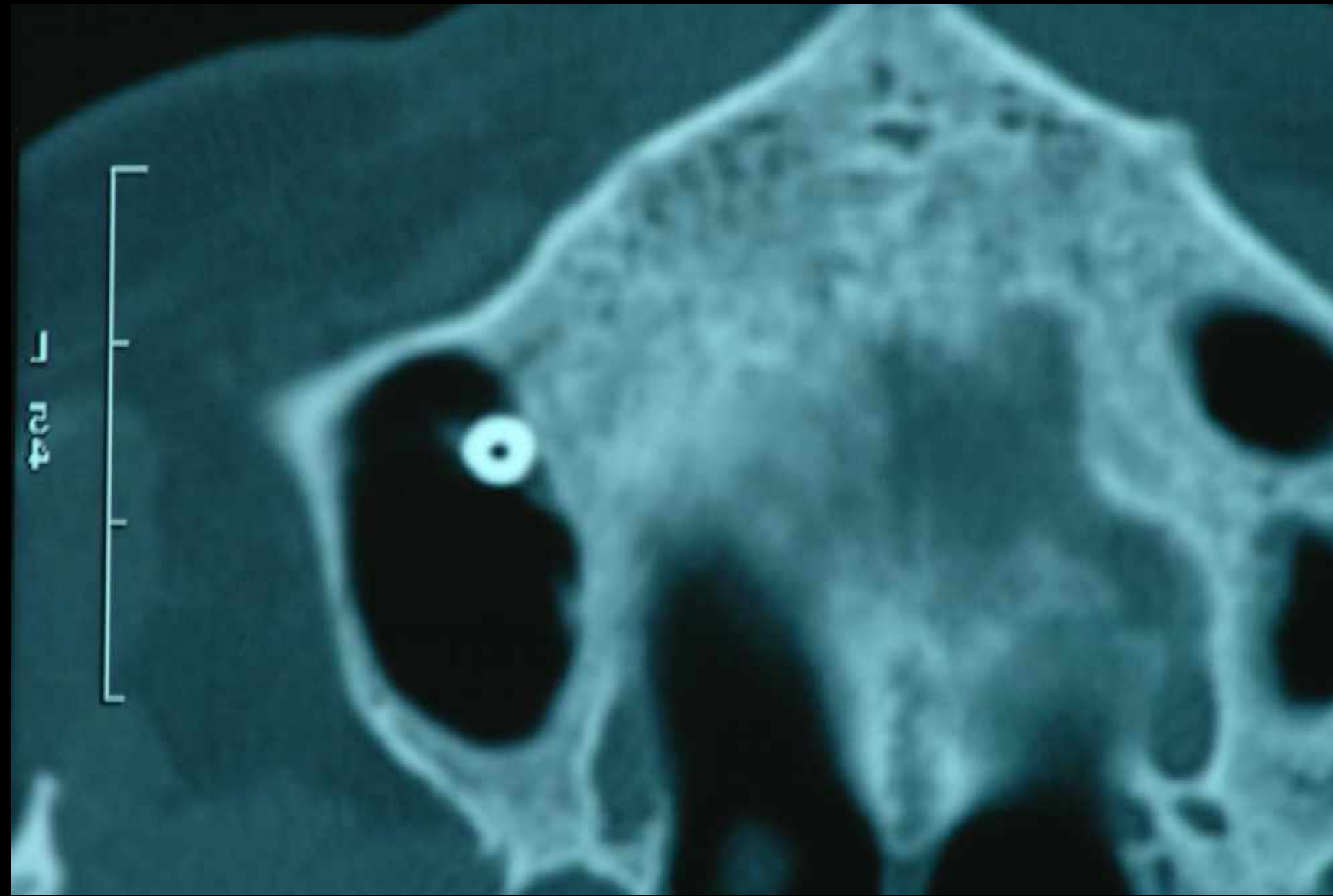t L 6,5 Col R1,5



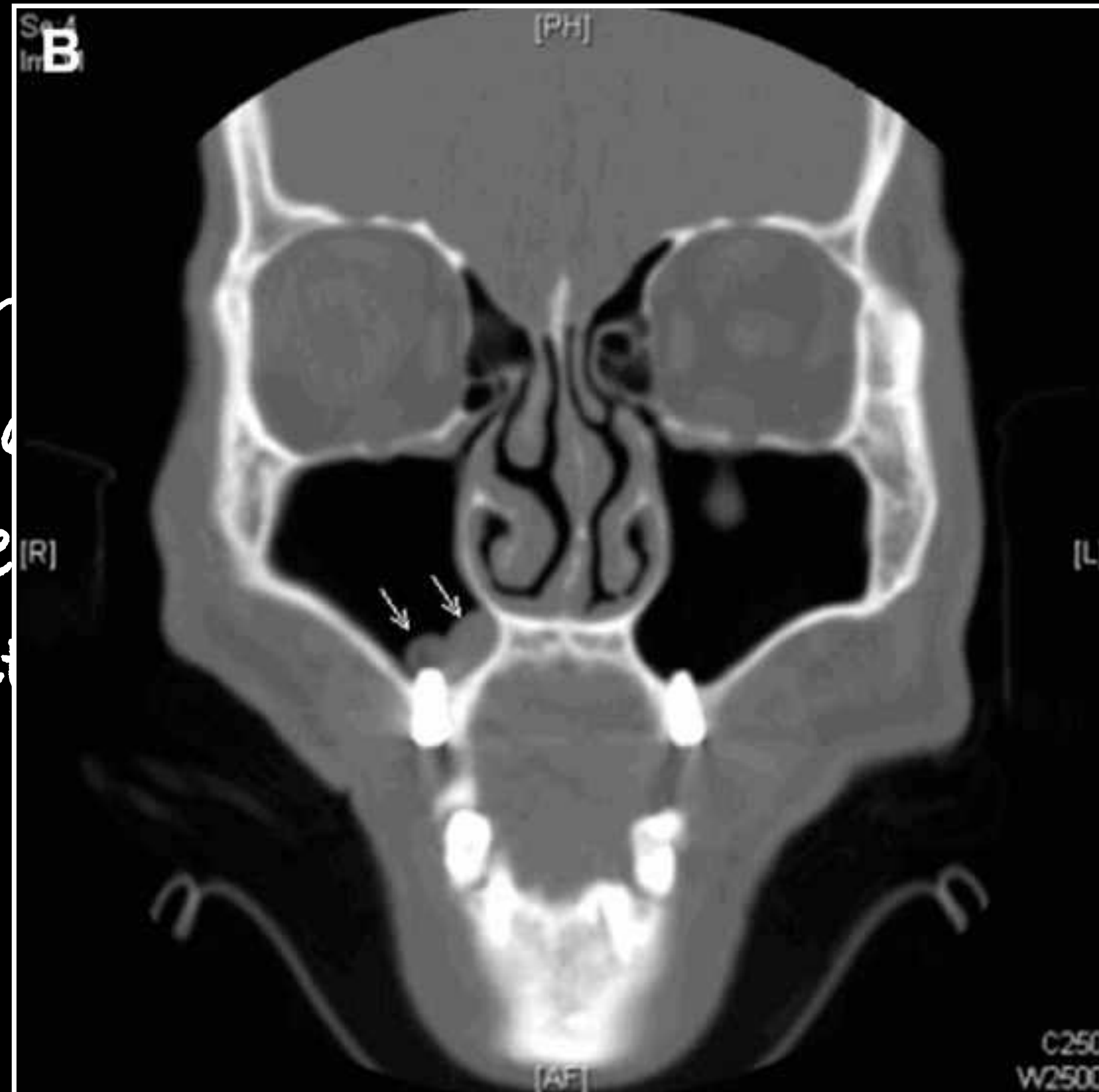
Approche Crestale

Les Limites



Complications post-opératoires et utilisation des ostéotomes

Etude retr
Dépasseme
14/23 implants



implants
4 à 7mm
use sinusienne

Jung JH, Choi BH, Jeong SM, Li J, Lee SH, Lee HJ. A retrospective study of the effects on sinus complications of exposing dental implants to the maxillary sinus cavity. Oral Surg Oral Med Oral Pathol Oral Radiol Endod. 2007 May;103(5):623-5. Epub 2007 Jan 25.

Complications post-opératoires et utilisation des ostéotomes

Etude sur le chien

Volet latéral pour éviter toute perfo

Dépassement de 4 et 8mm

Pas de substitut osseux ↔ technique de Summers

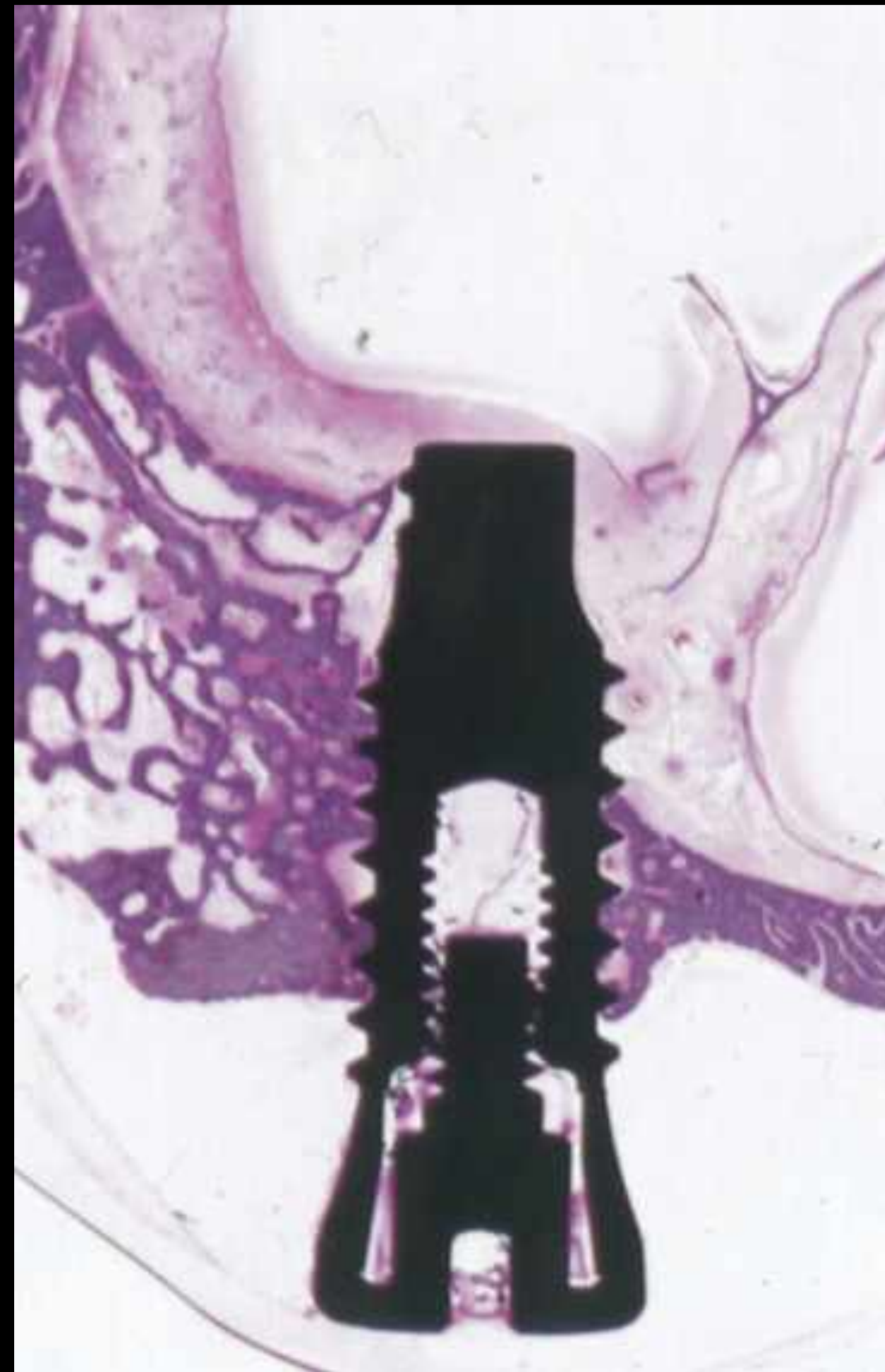
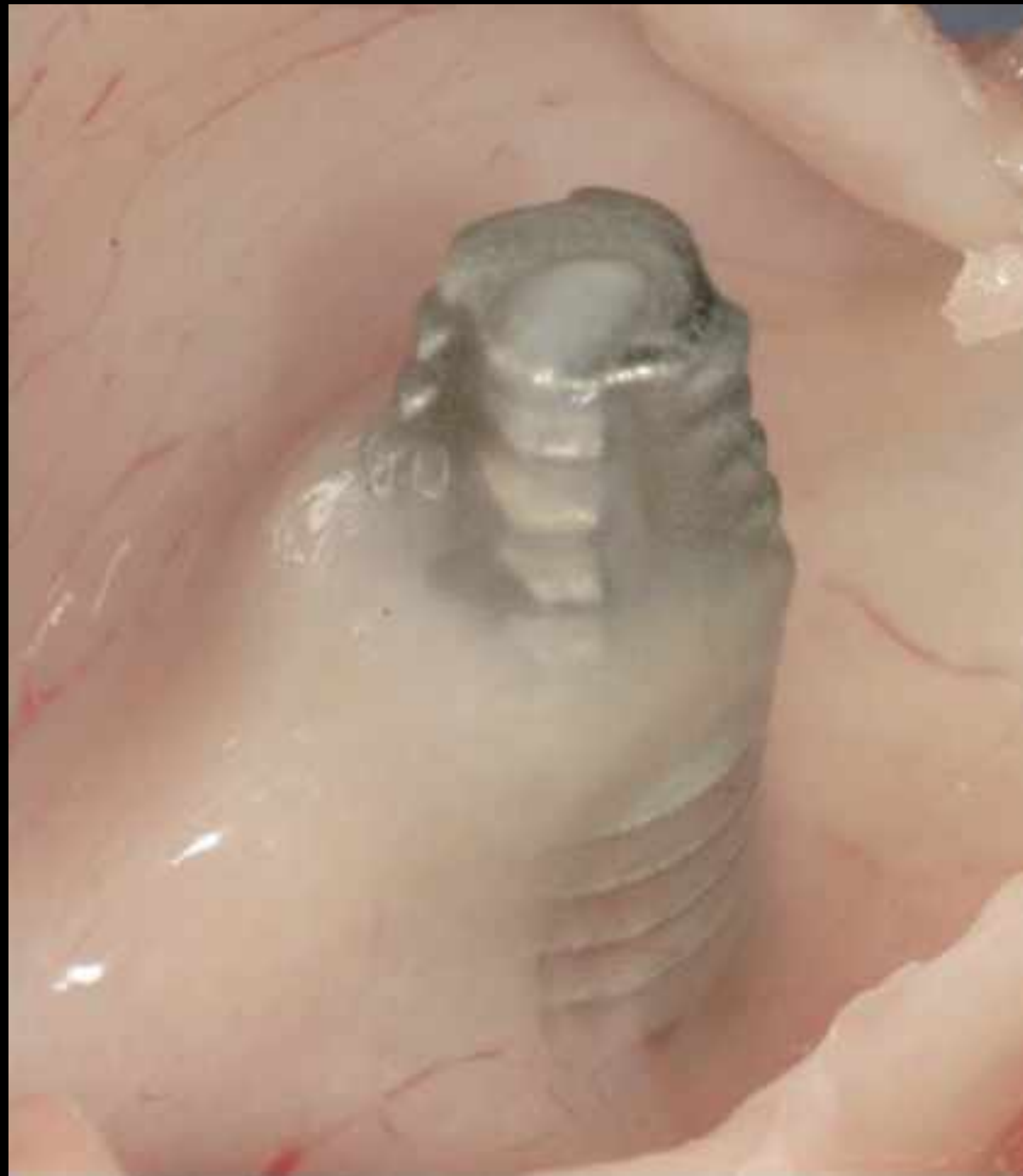hauteur d'os néoformé moyen = 3,3mm

Nombreuses perfo post-op sur dépassement 8mm

Pas de signe de sinusite

Sul SH, Choi BH, Li J, Jeong SM, Xuan F. Effects of sinus membrane elevation on bone formation around implants placed in the maxillary sinus cavity: An experimental study. Oral Surg Oral Med Oral Pathol Oral Radiol Endod. 2008 Feb 23 [Epub ahead of print]

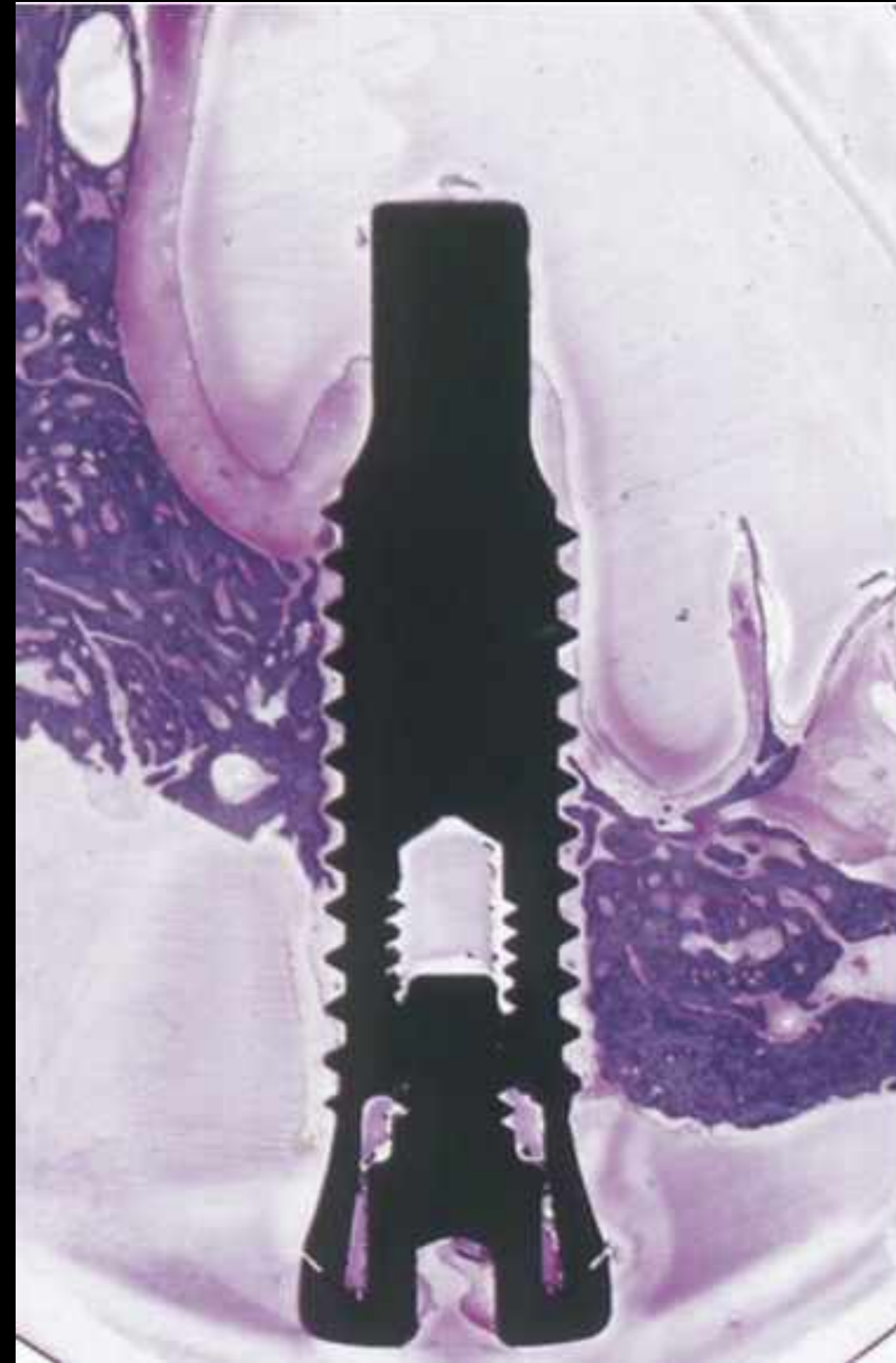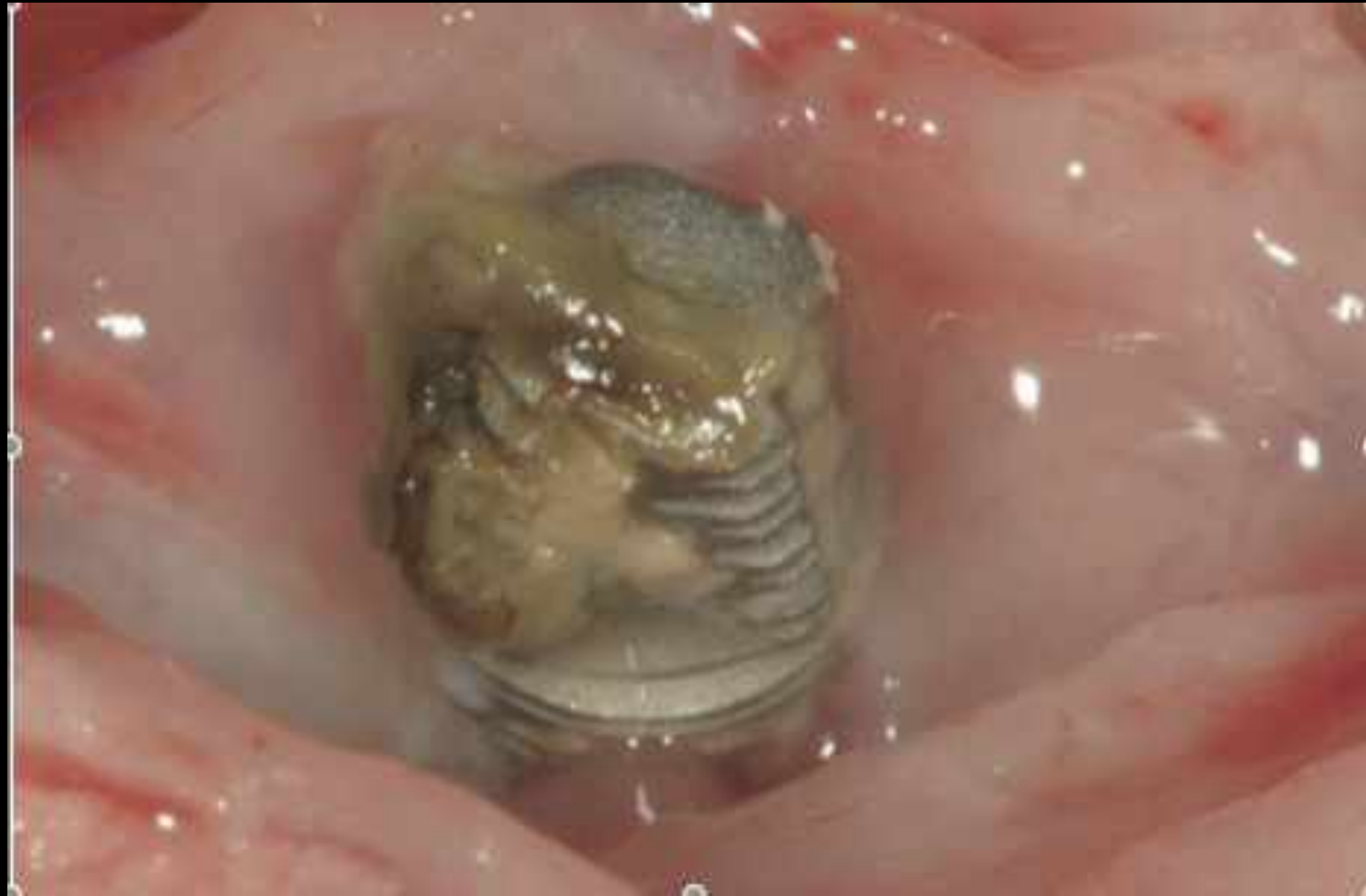Complications post-opératoires et utilisation des ostéotomes



H os néoformé
4mm maxí

Sul SH, Choi BH, Li J, Jeong SM, Xuan F. Effects of sinus membrane elevation on bone formation around implants placed in the maxillary sinus cavity: An experimental study. Oral Surg Oral Med Oral Pathol Oral Radiol Endod. 2008 Feb 23 [Epub ahead of print]

Complications post-opératoires et utilisation des ostéotomes





Membrane perforée
Rétention de débris
intrasinusiens

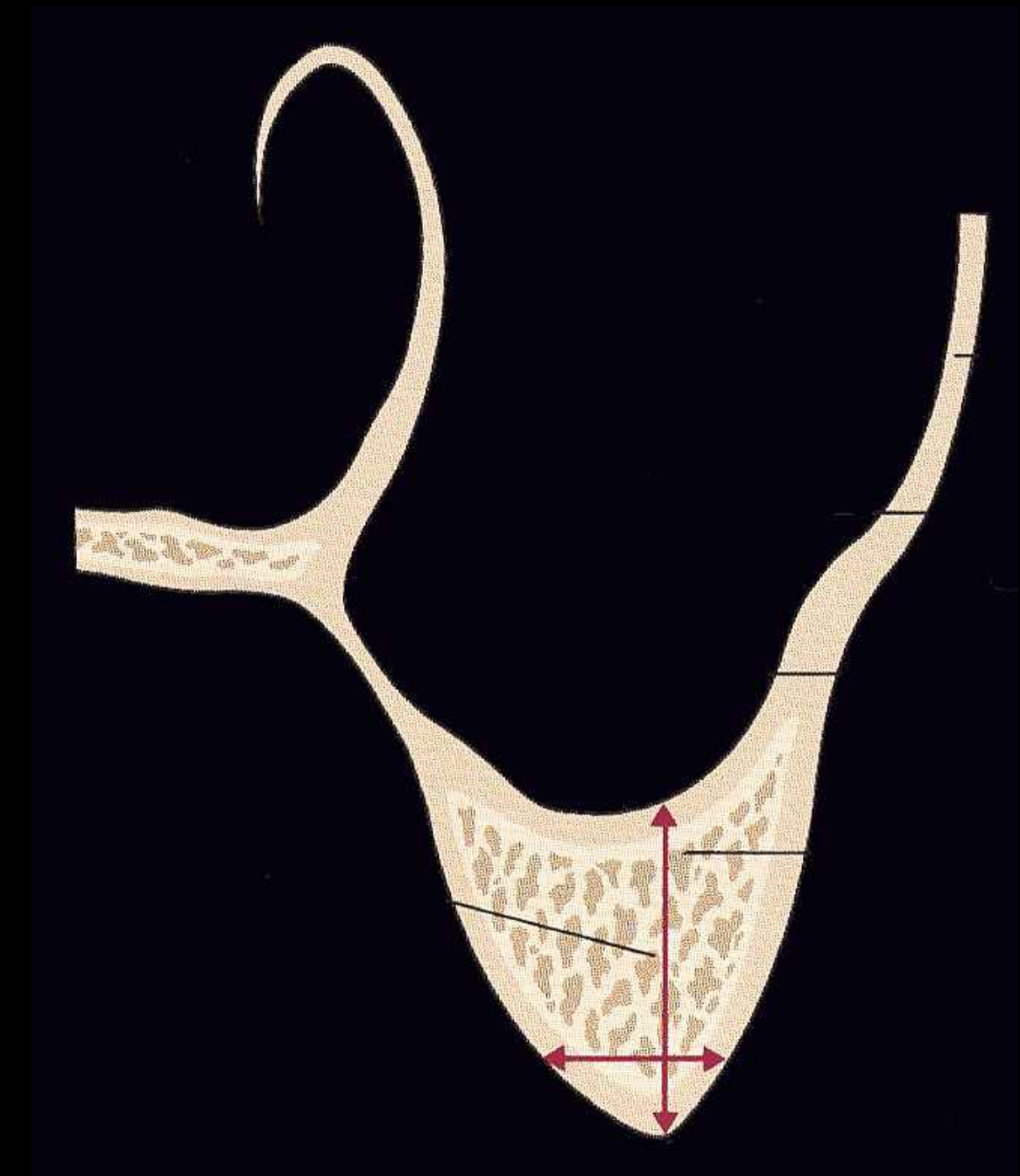
Sul SH, Choi BH, Li J, Jeong SM, Xuan F. Effects of sinus membrane elevation on bone formation around implants placed in the maxillary sinus cavity: An experimental study. Oral Surg Oral Med Oral Pathol Oral Radiol Endod. 2008 Feb 23 [Epub ahead of print]

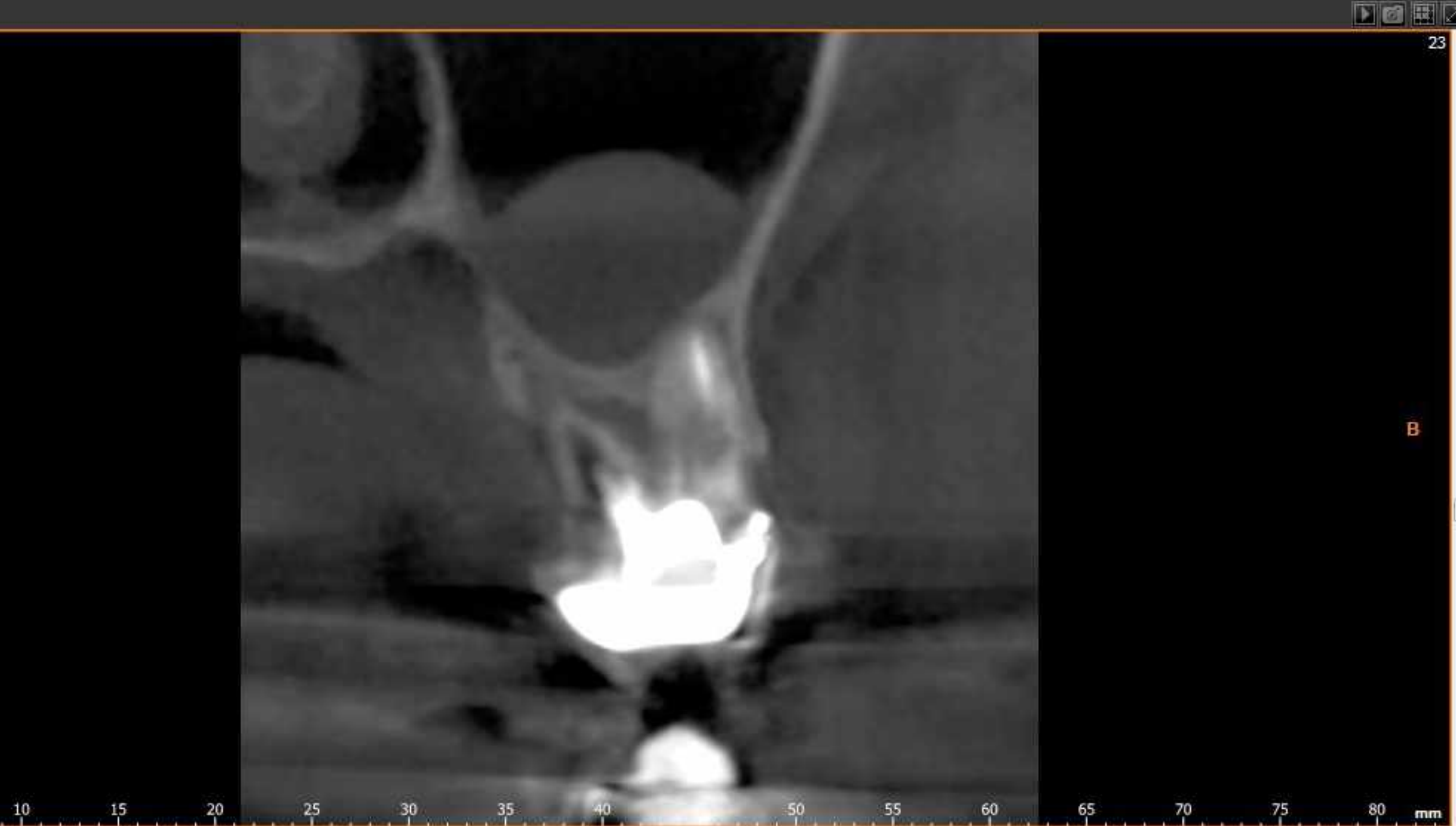
1 - GREFFE DU SINUS PAR ABORD CRESTAL

Placement d'implant pendant l'augmentation de crête

Etude de FUGAZZOTTO Paul J.O.M.I 2004

- 763 augmentations sinusiennes sur 168 mois
- 1522 implants 98,4% de succès sur 57,4 mois
- Il faut au moins 5 mm d'os pour un bon succès
- Forêt creux, ostéotomie
- Soit x la hauteur d'os sous-sinusien: la hauteur de l'implant = $2x - 2$
- $2x - 2$ suffisant  ostéotome + implant
- $2x - 2$ insuffisant  volet latéral + implant

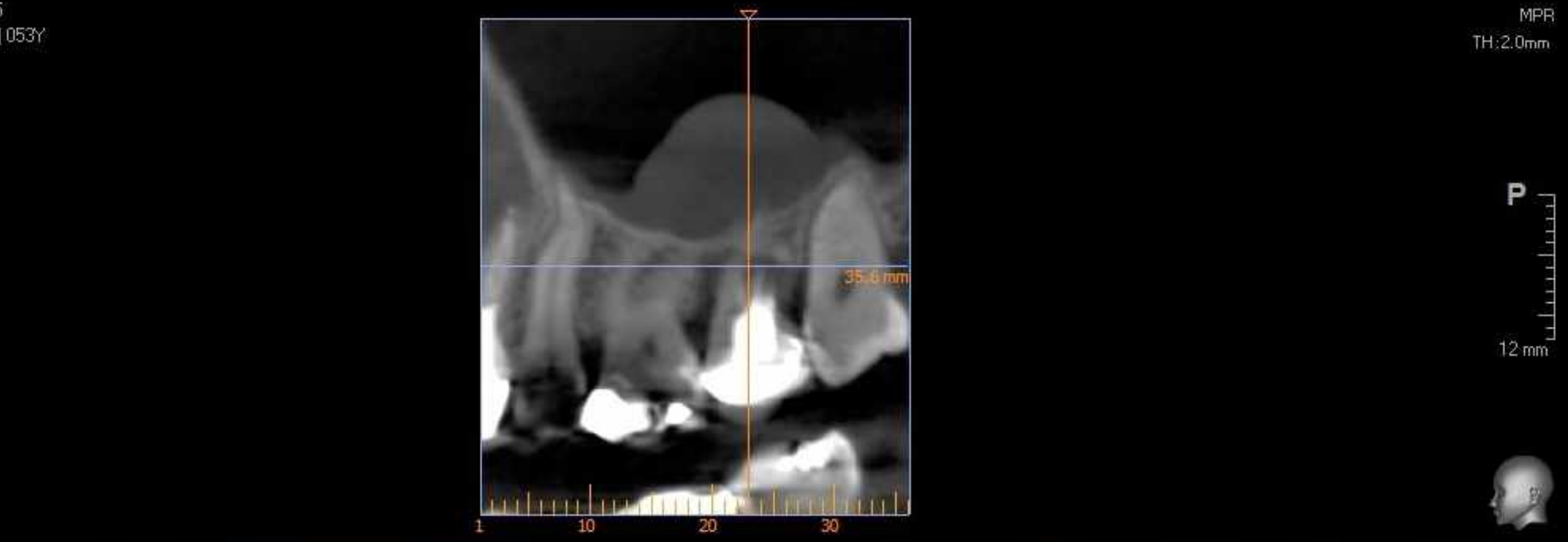
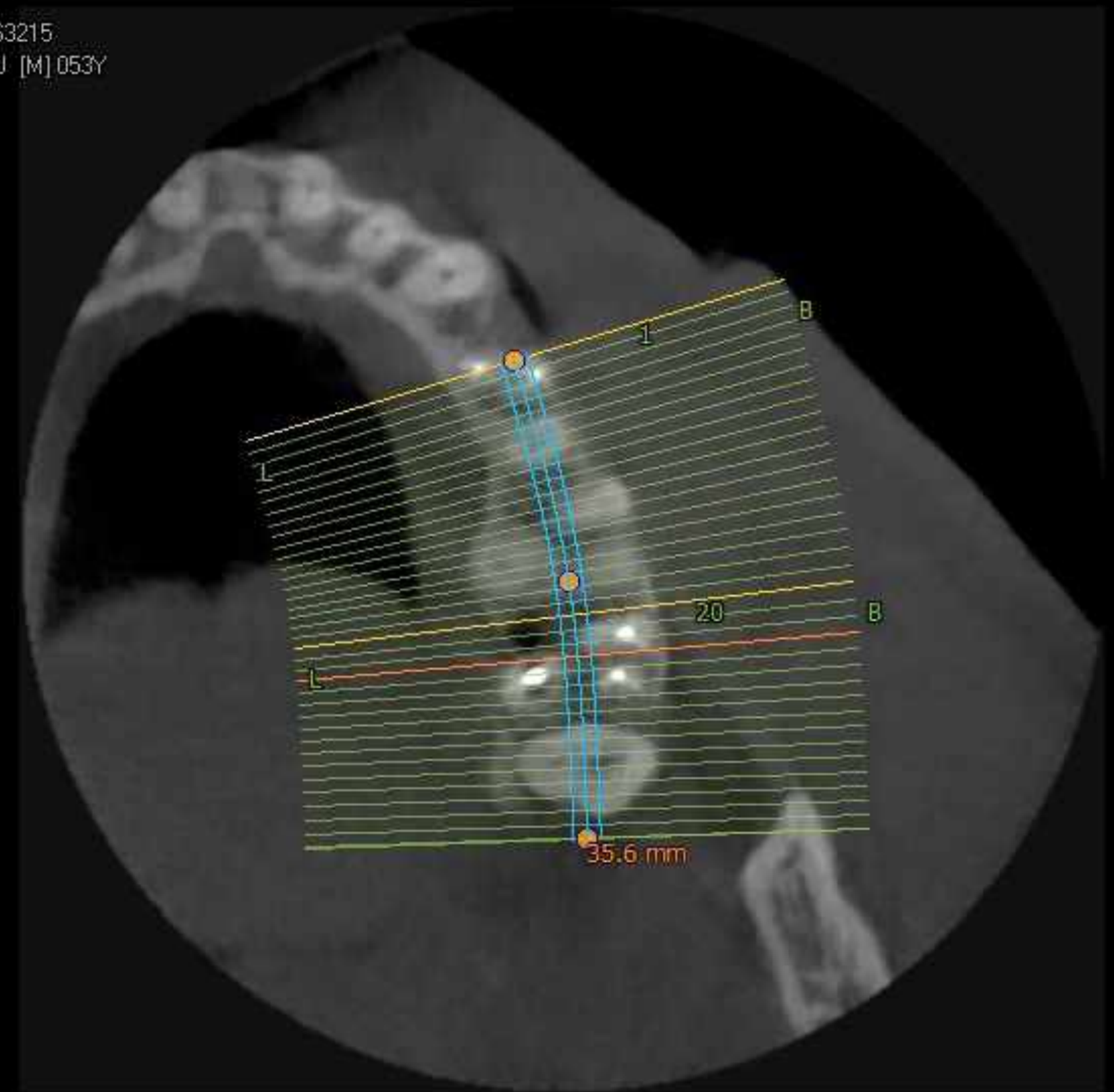




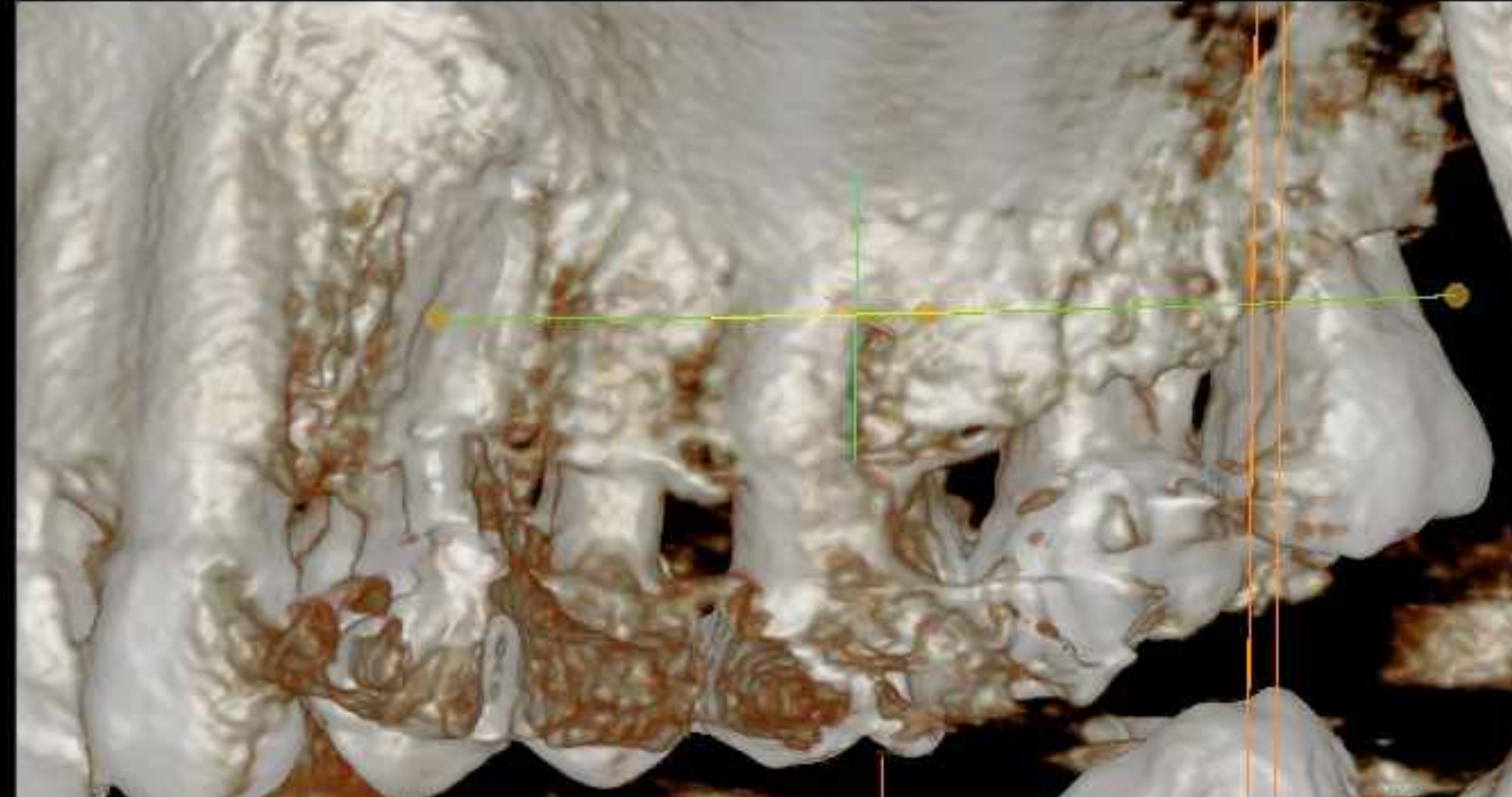Axial

ID : 20160111_163215
Vincent MICHEAU [M] 053Y
20160111
Series : 1

R



3D



MPR
TH:2.0mm

P

12 mm



MPR OBLIQUE 3DZOOM CURVE Mesure d'angle pour la vue 3D

Sectional

-5
-10
-15
-20
-25L
-30
-35
-40
-45

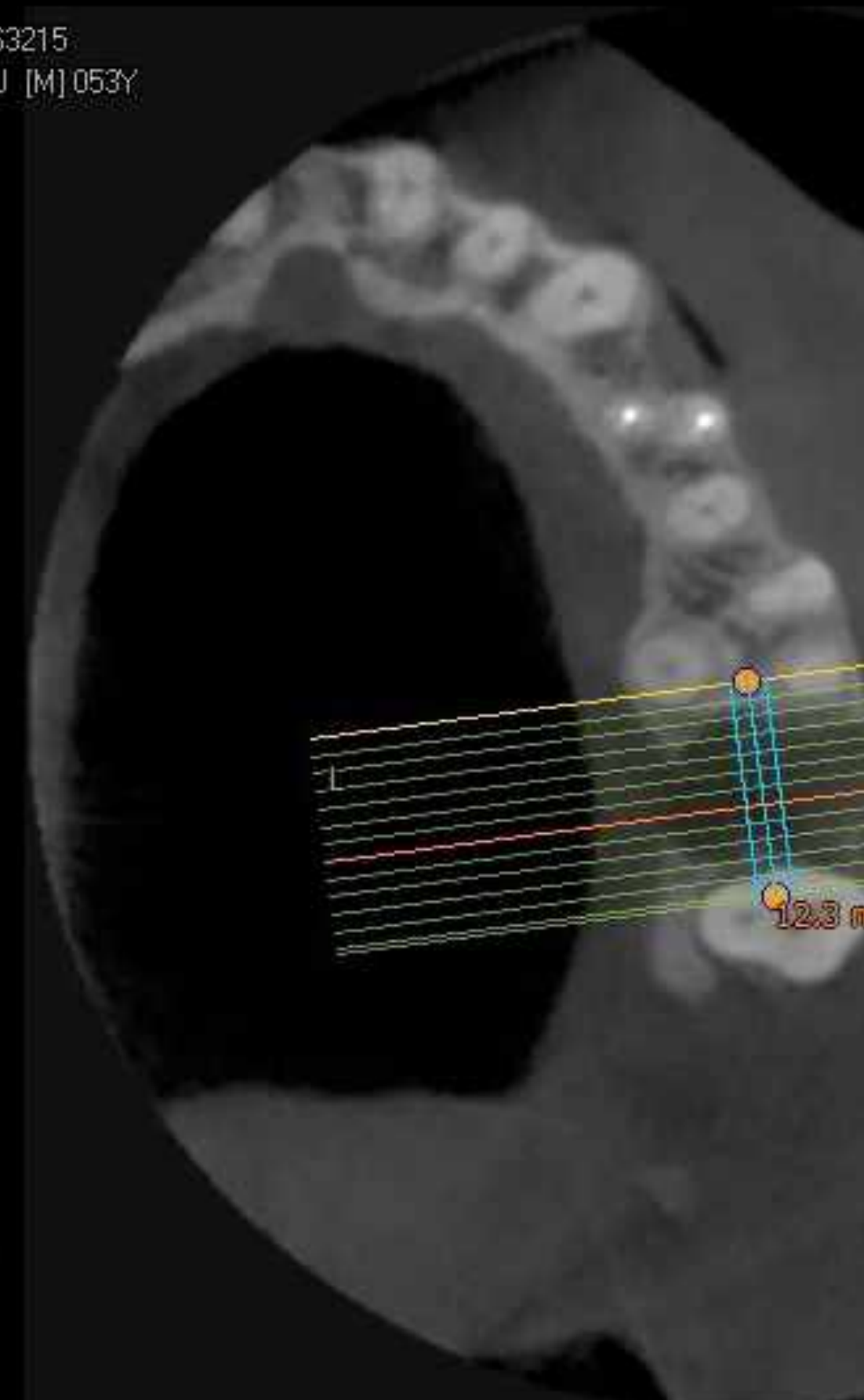


Axial

Z:100%

ID : 20160111_163215
Vincent MICHEAU [M] 053Y
20160302
Series : 1

R

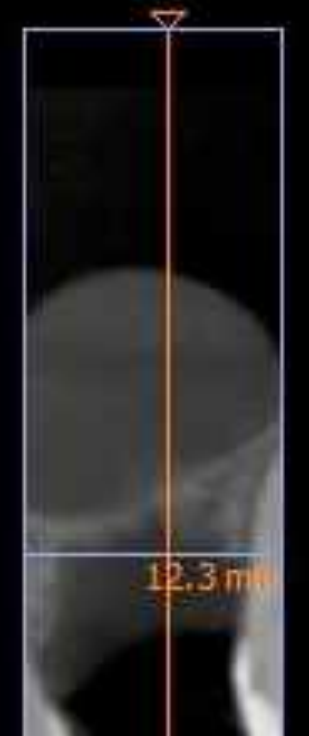


6.64 [dGy*cm^2]
5.9 [mA]
89 [kVp]
CT

5 10 15 20 25 30 35 40 45 50 55 60 65 70 75 80 85 90 95 100m

Panoramic


ID : 20160111_163215
Vincent MICHEAU [M] 053Y
20160302
Series : 1
Idx: 21



Z:73%

P

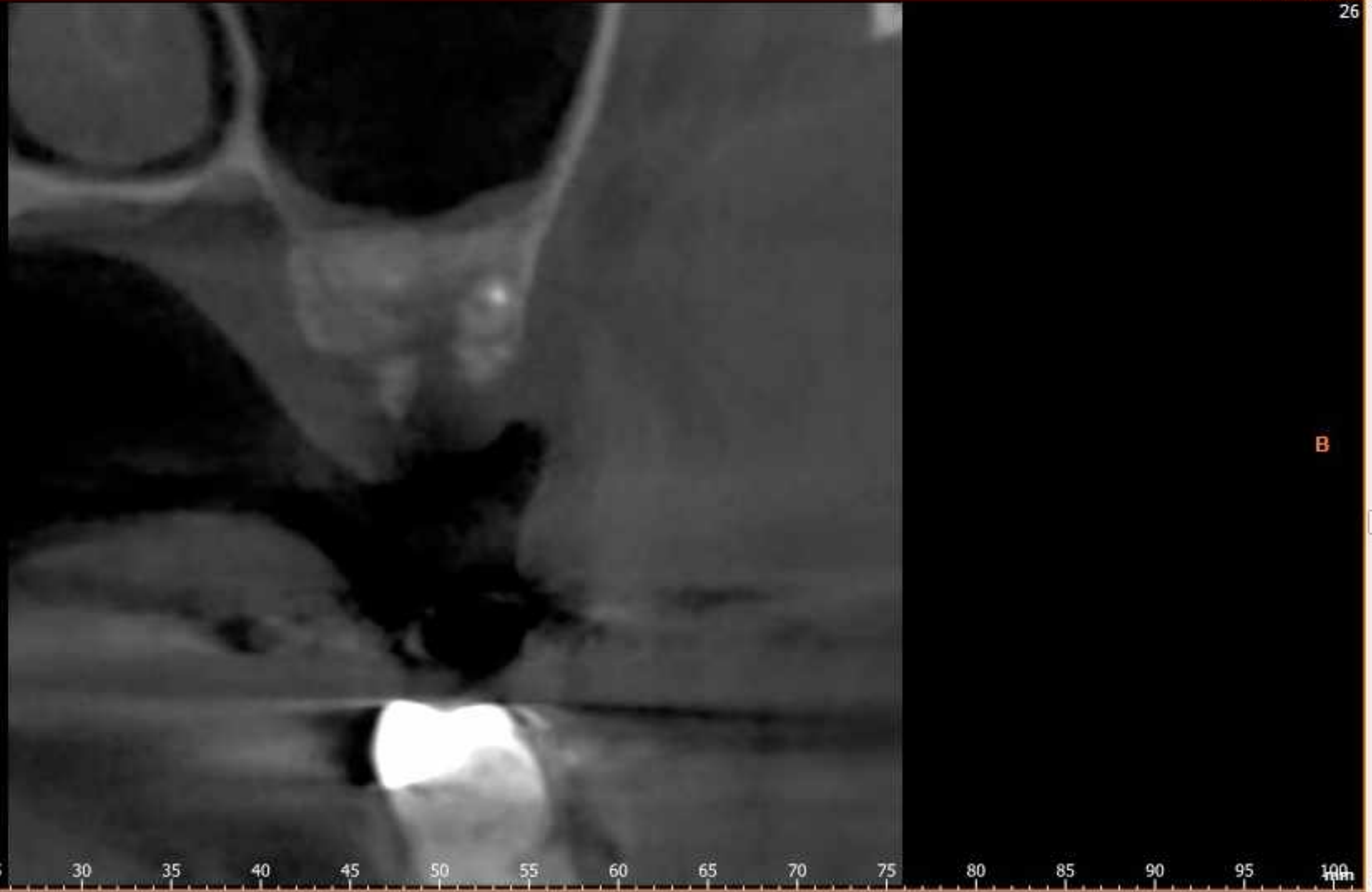
15 mm





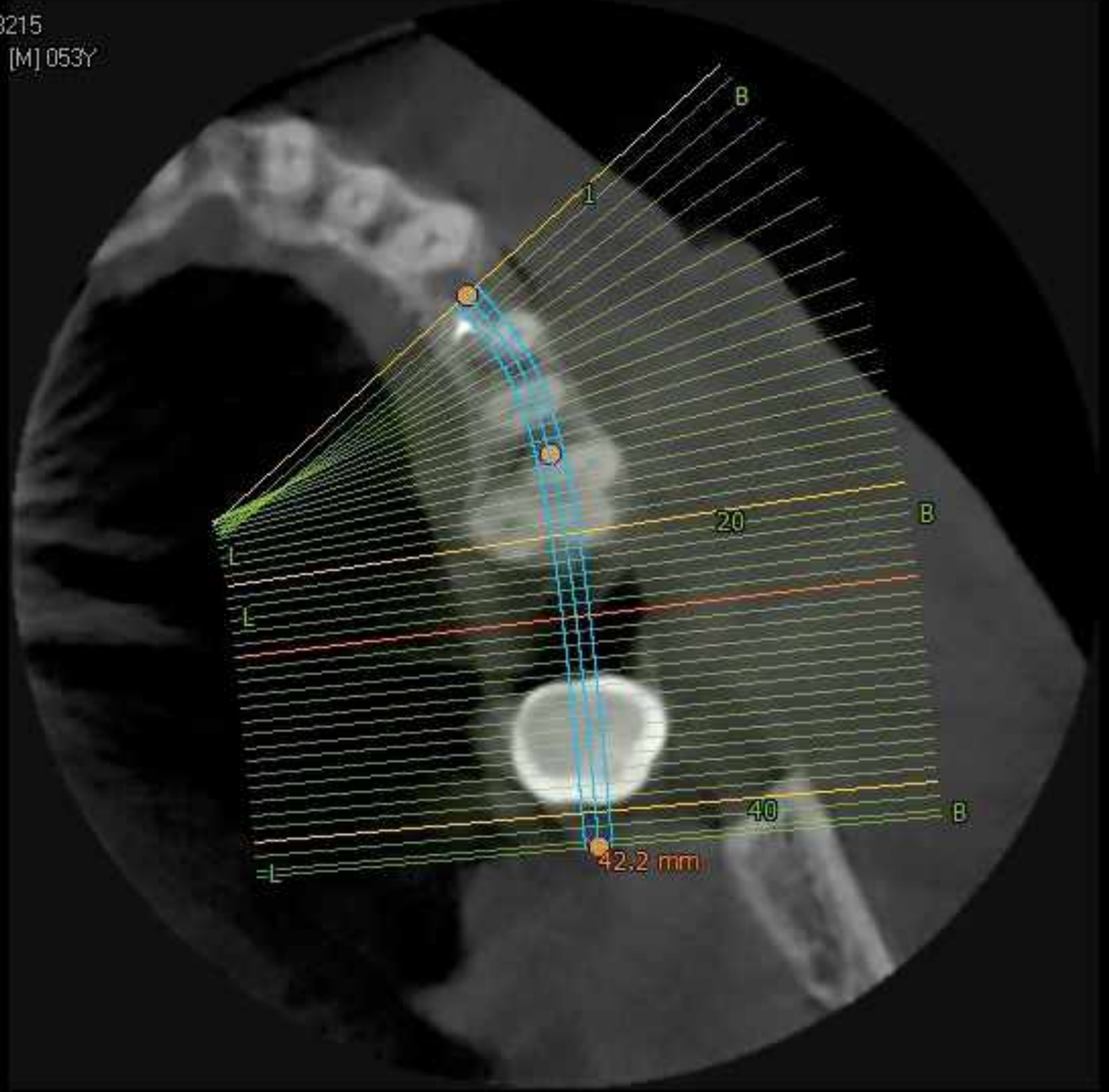
Axial

ID : 20160111_163215
Vincent MICHEAU [M] 053Y
20160601
Series : 1



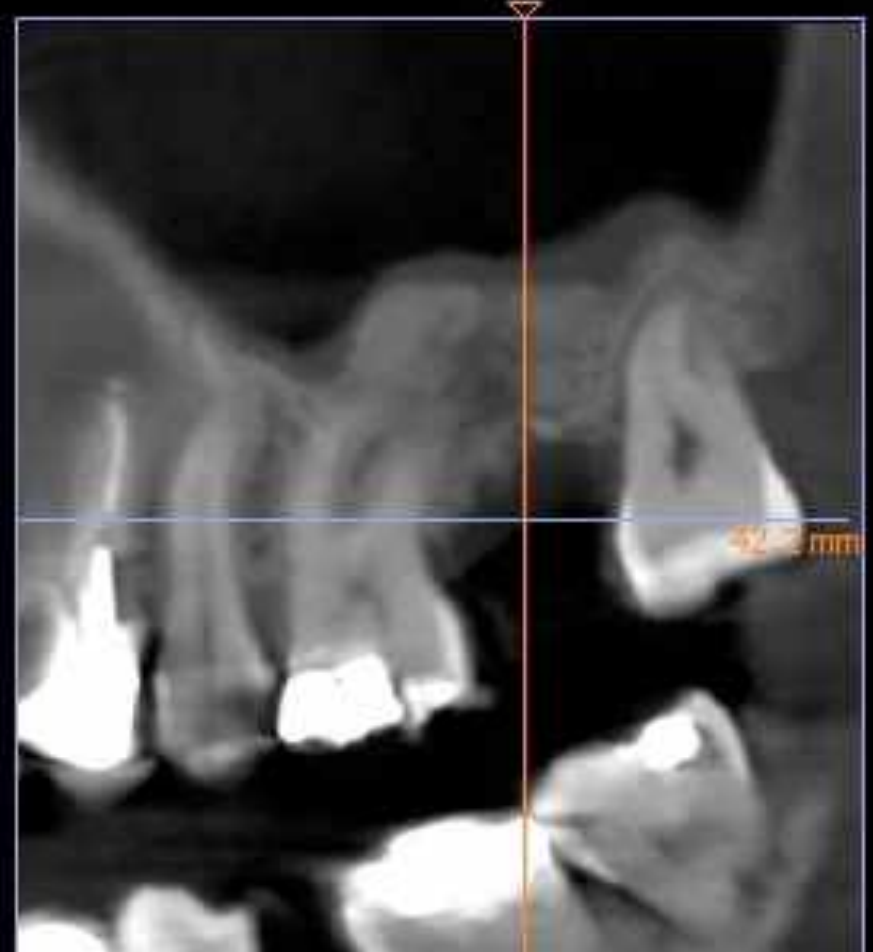20 25 30 35 40 45 50 55 60 65 70 75 80 85 90 95 100

R



6.64 [dGy*cm^2]
5.9 [mA]
89 [kVp]
CT

3D

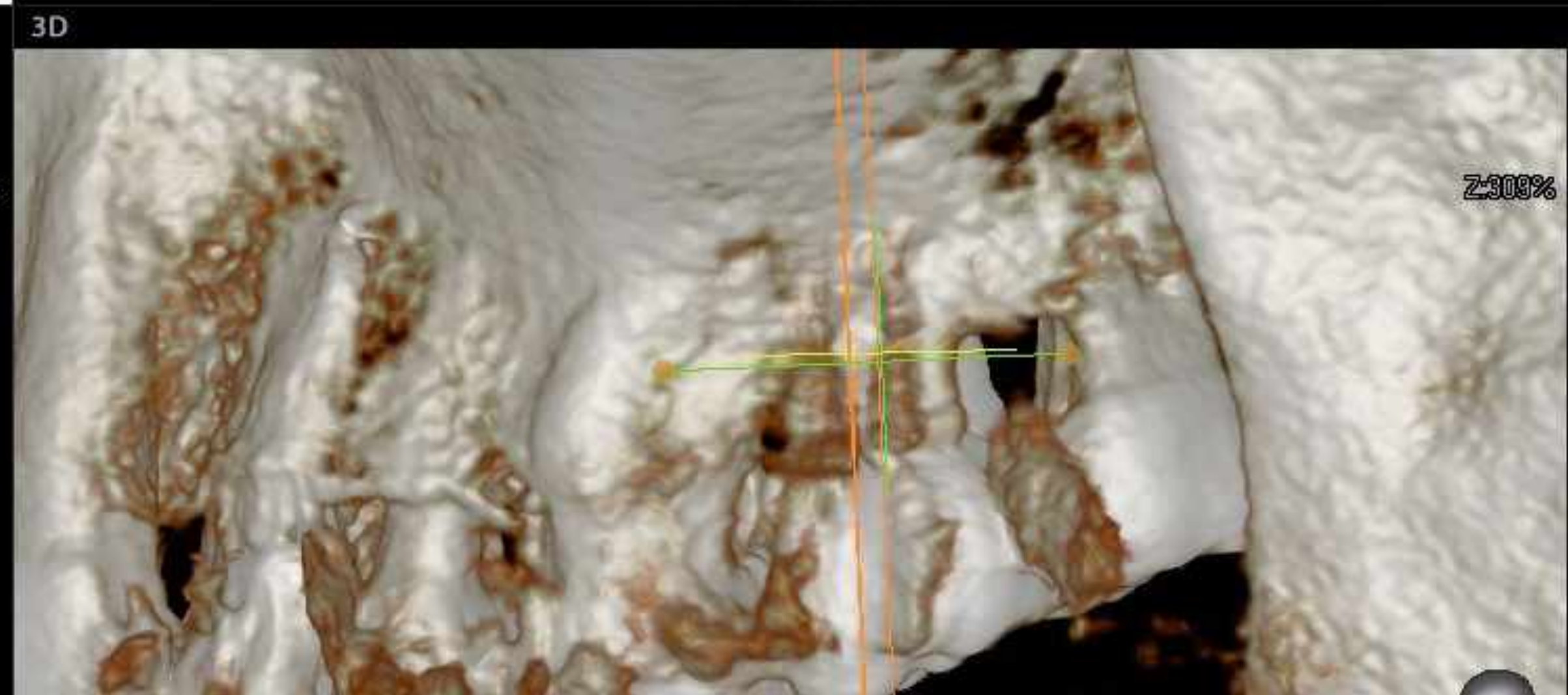
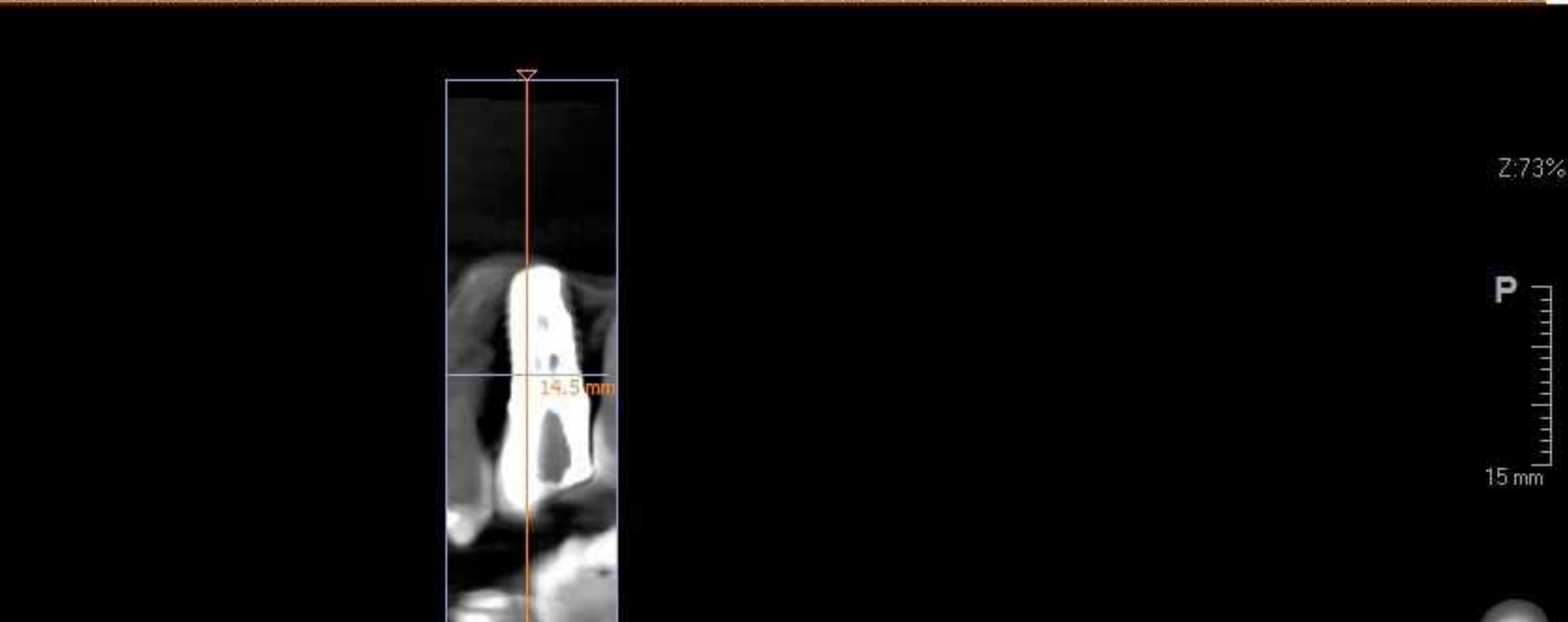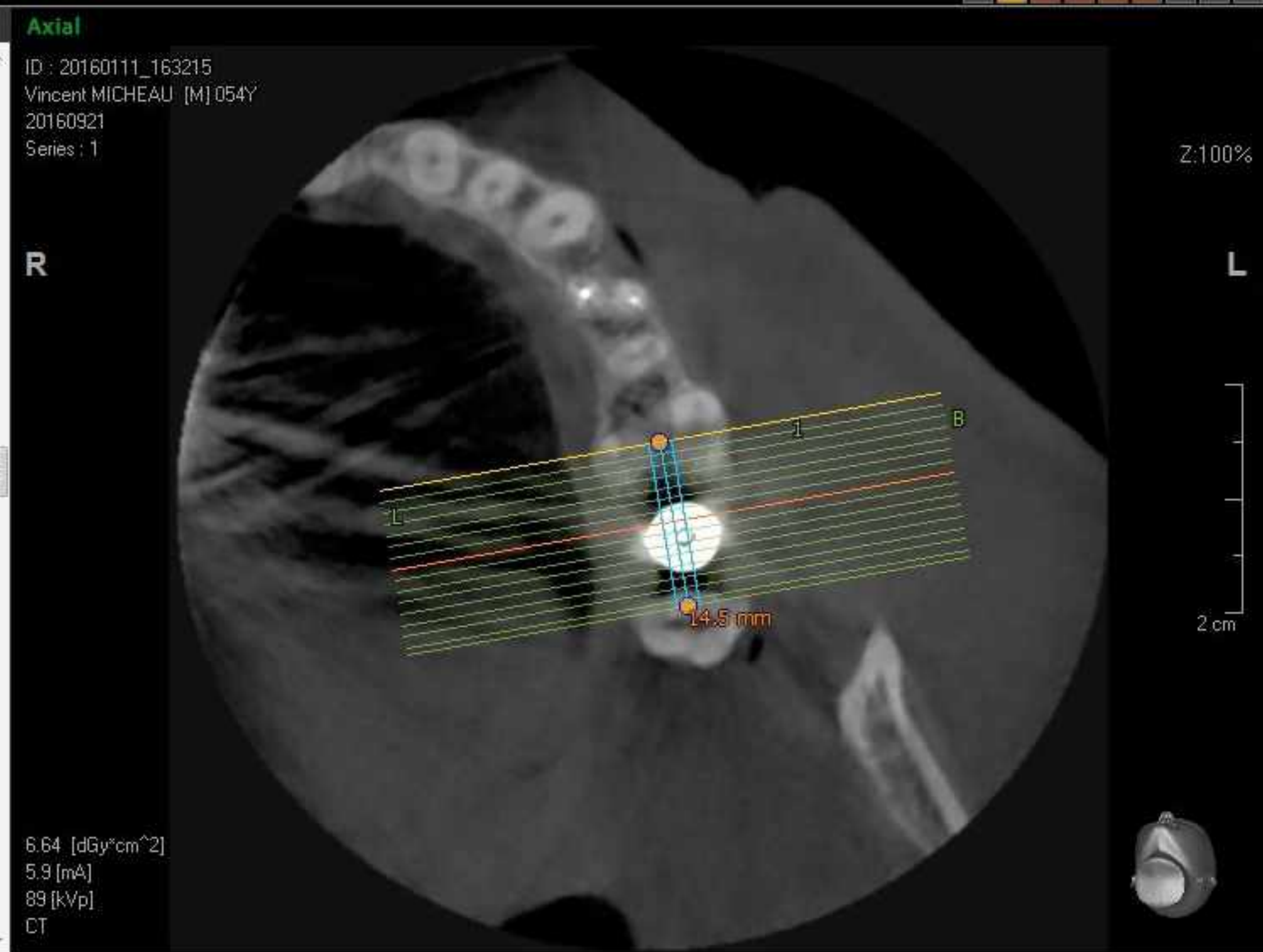
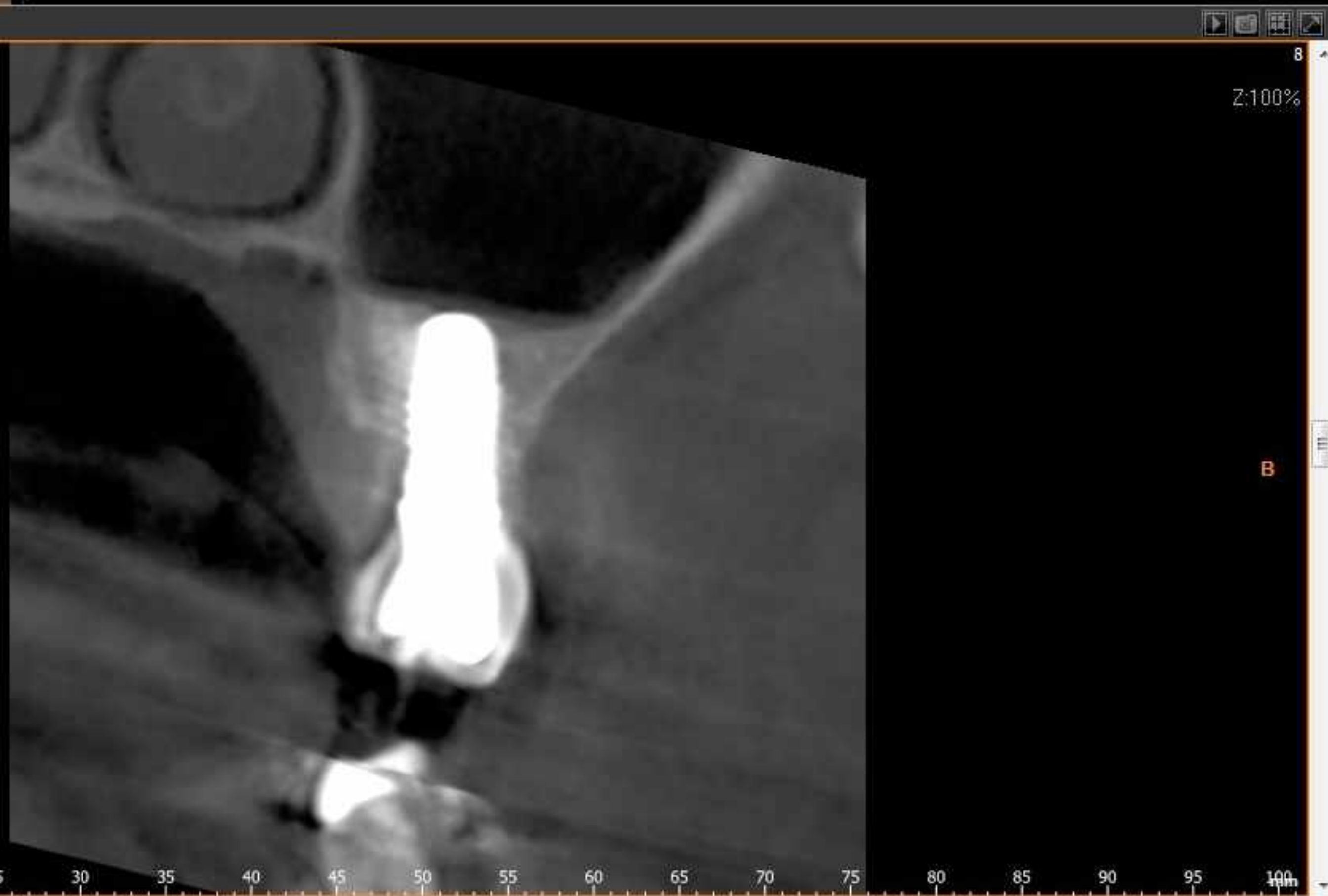


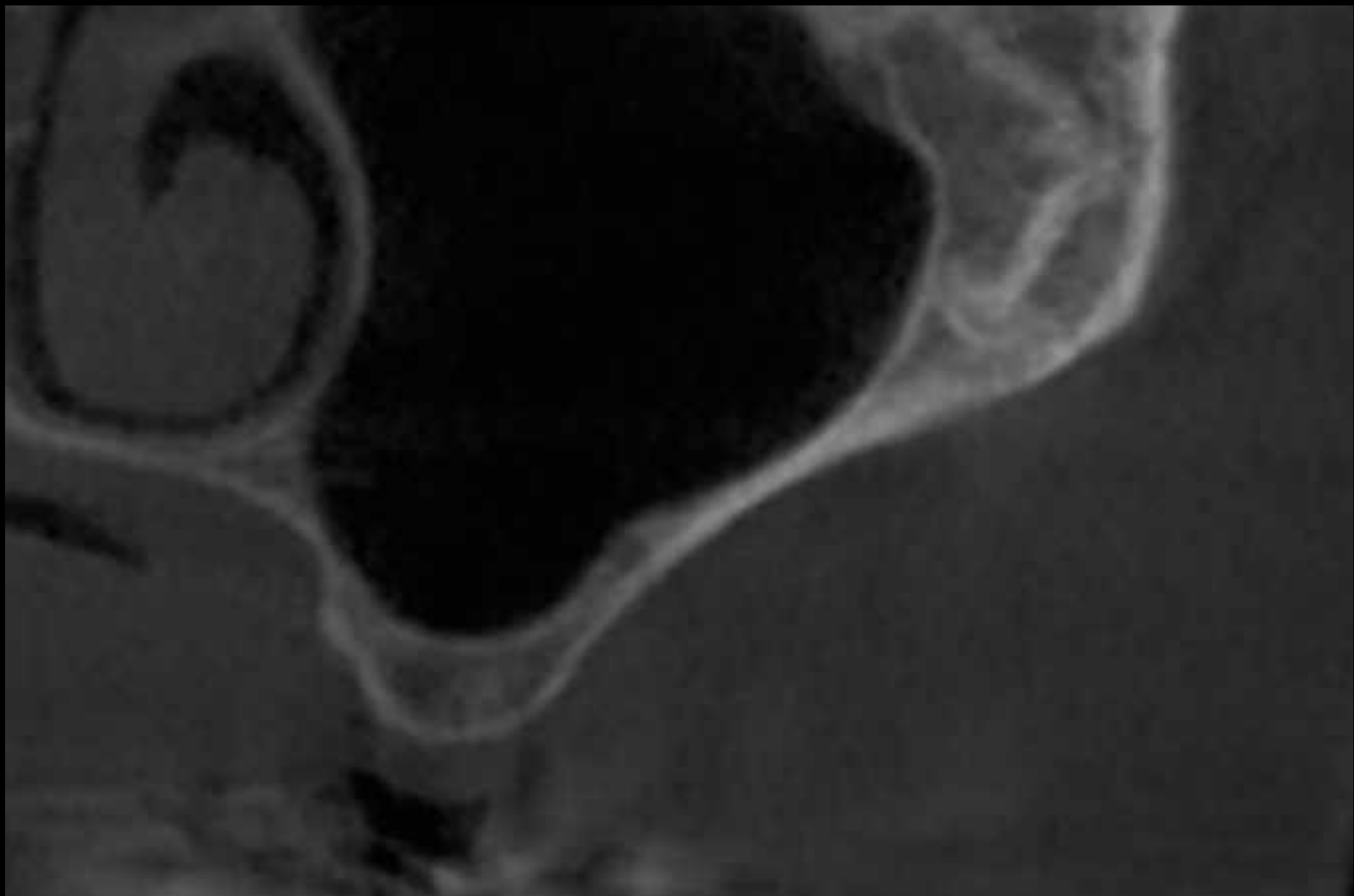
MPR
TH:2.0mm

P

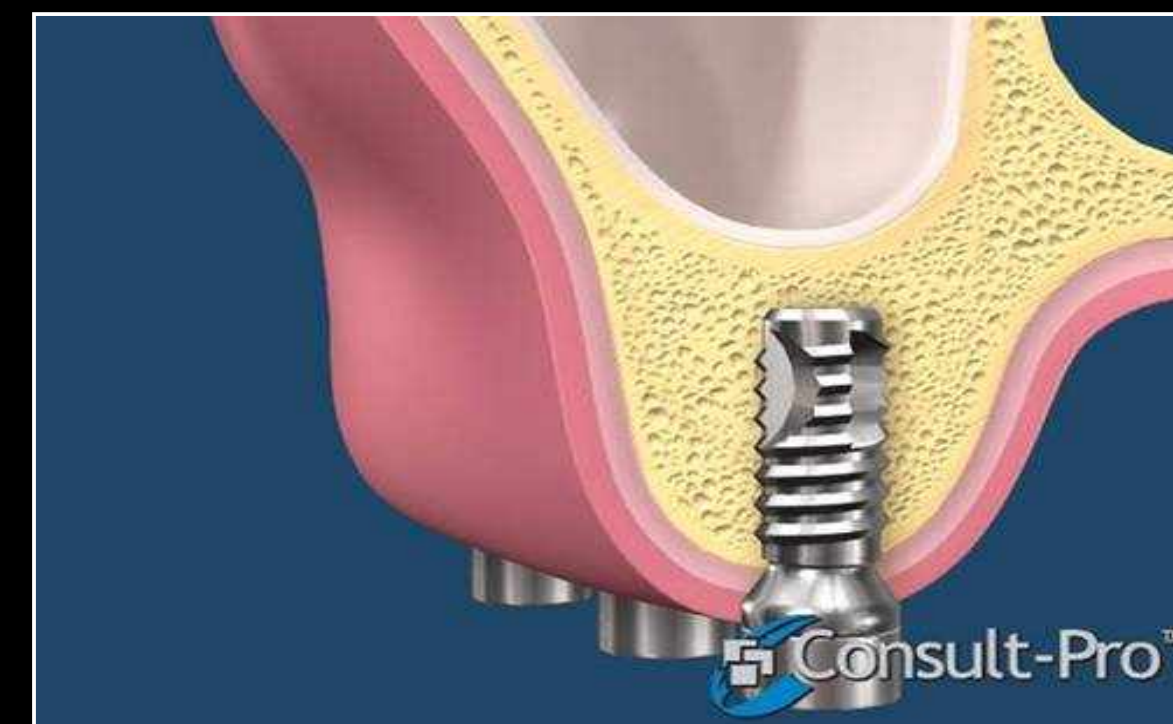
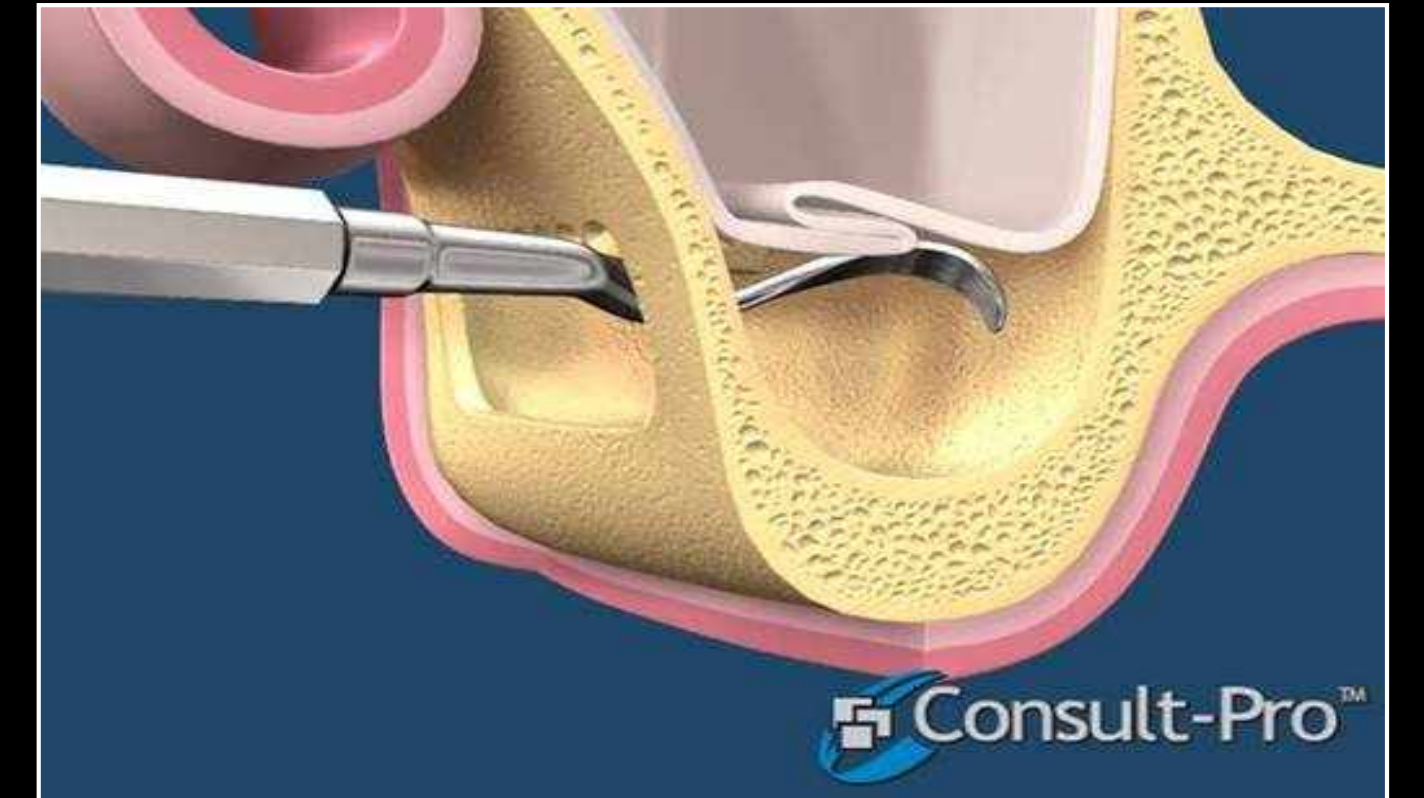
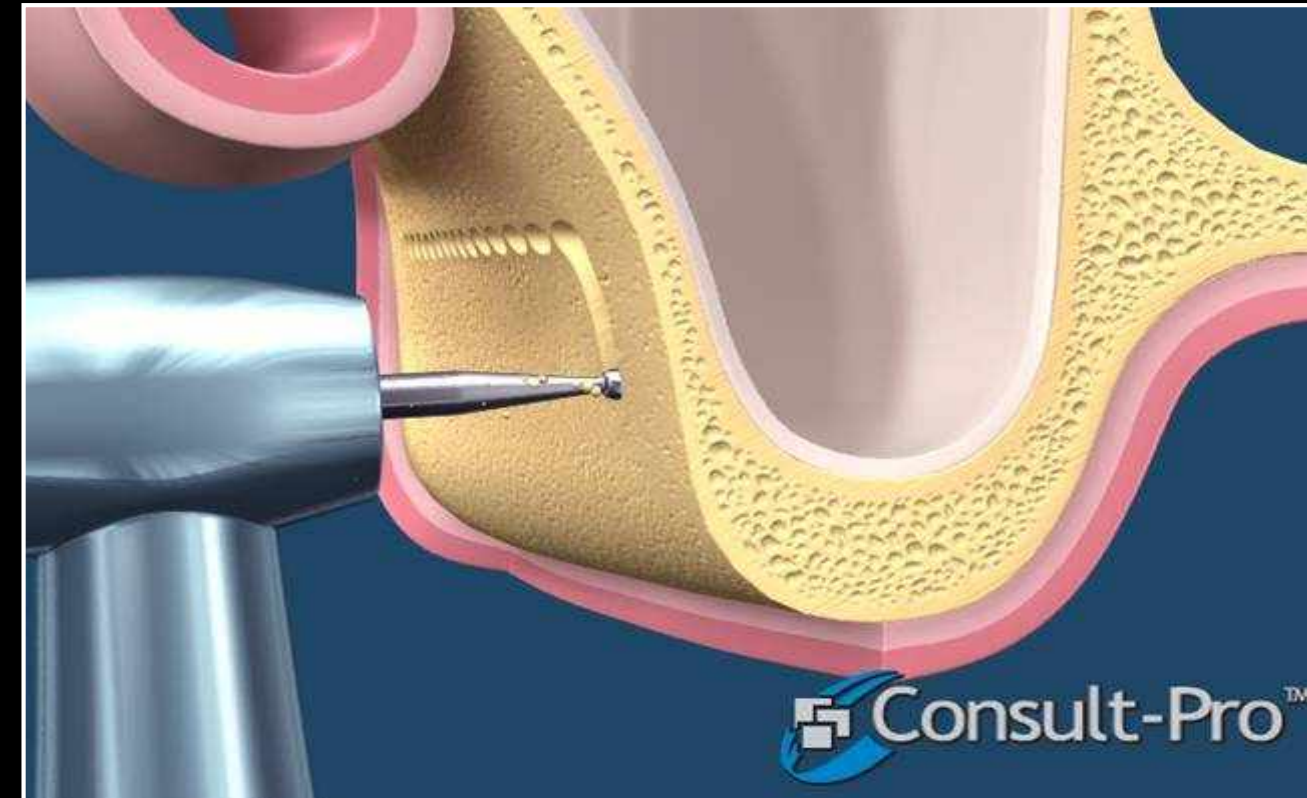
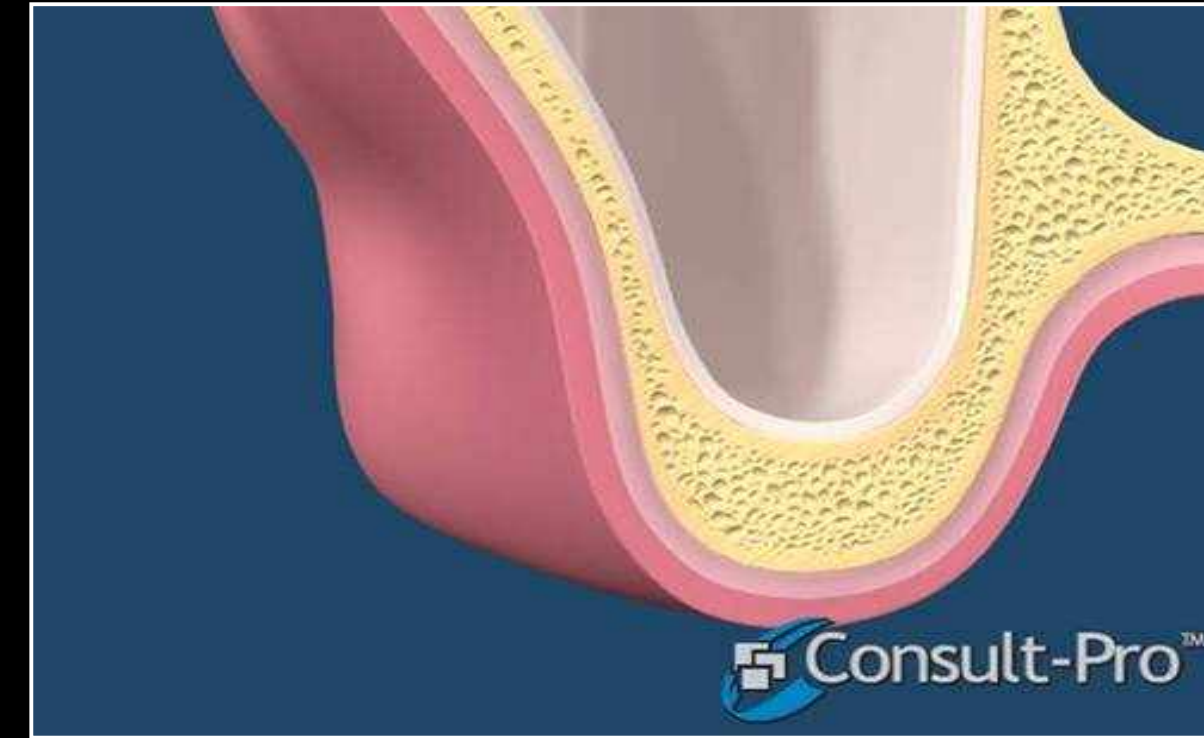
15 mm



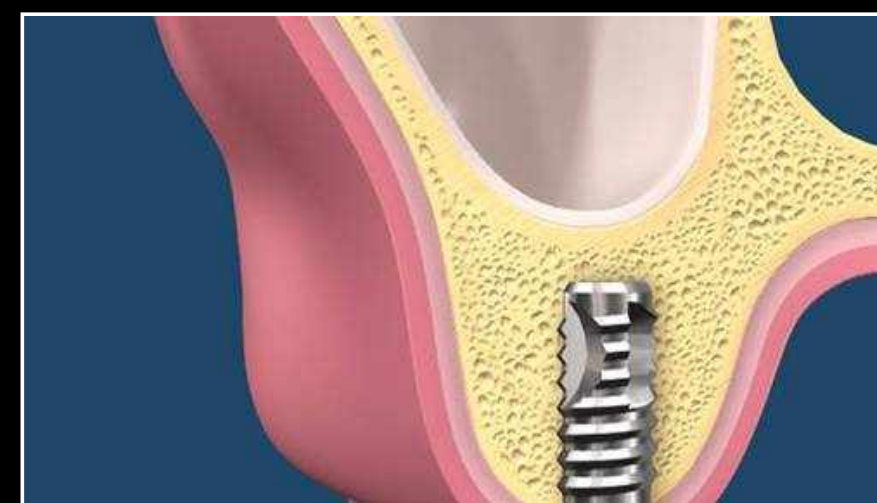
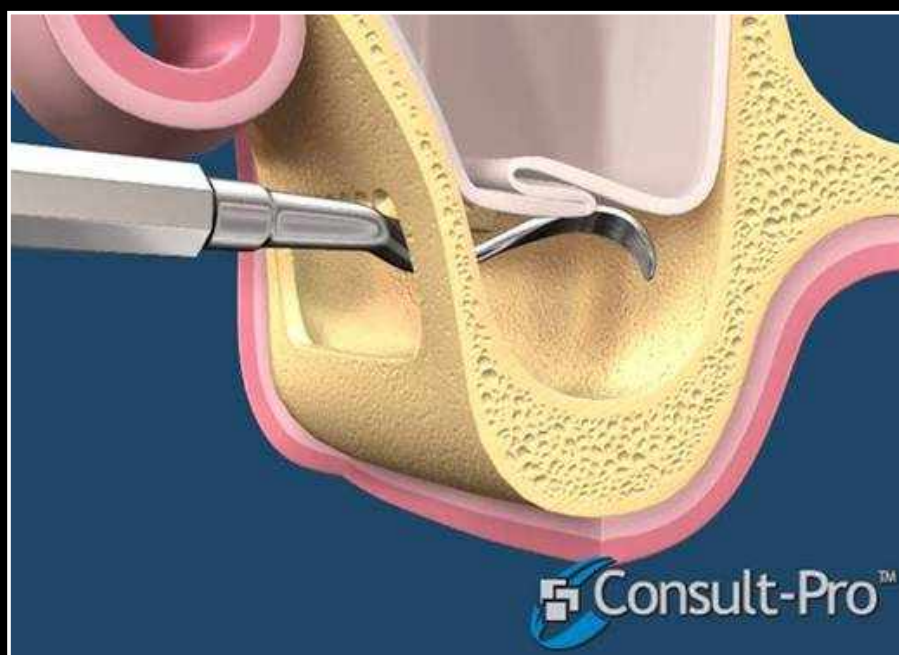
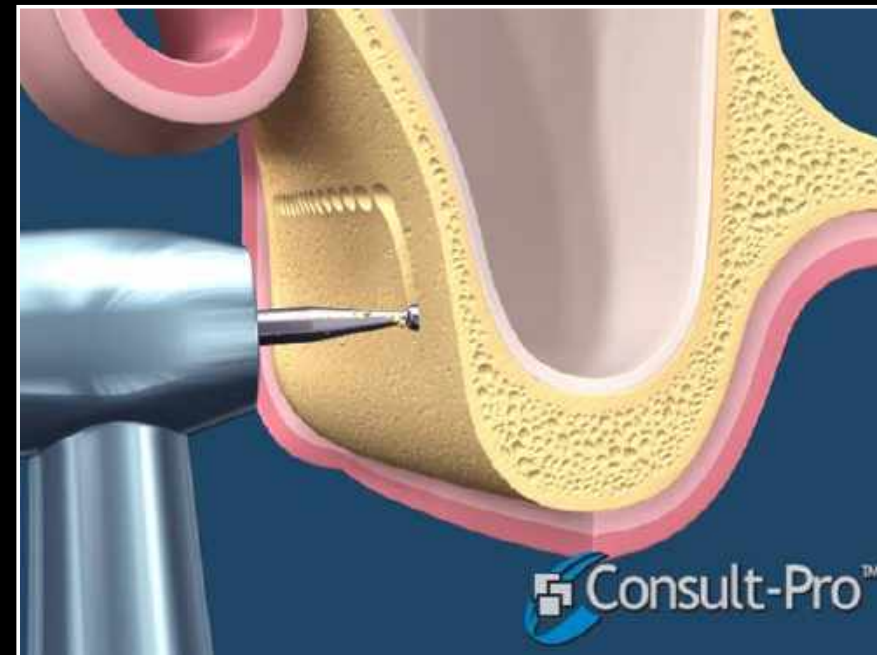
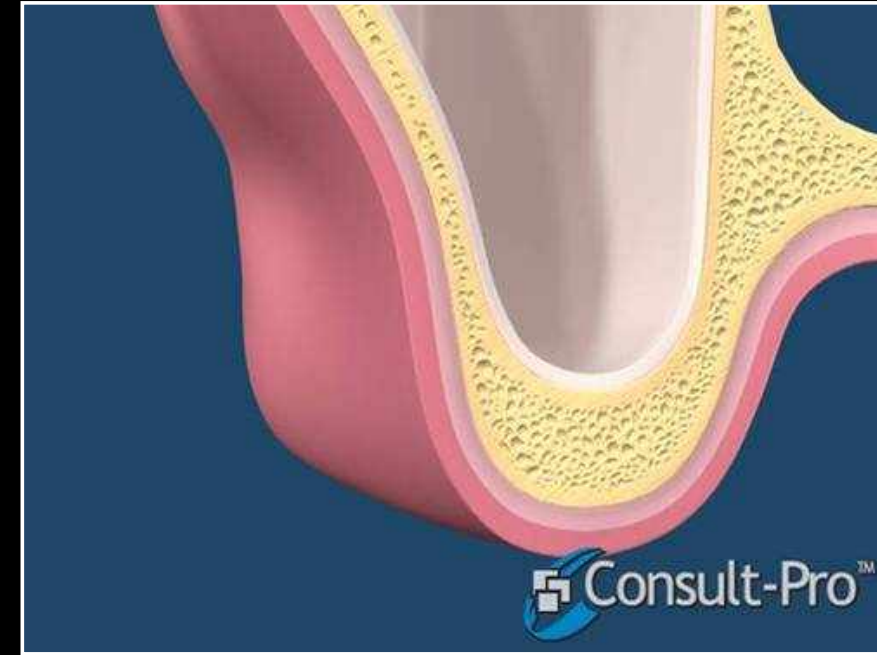




2 - GREFFE DU SINUS PAR VOILET LATERAL



2 - GREFFE DU SINUS PAR VOILET LATERAL



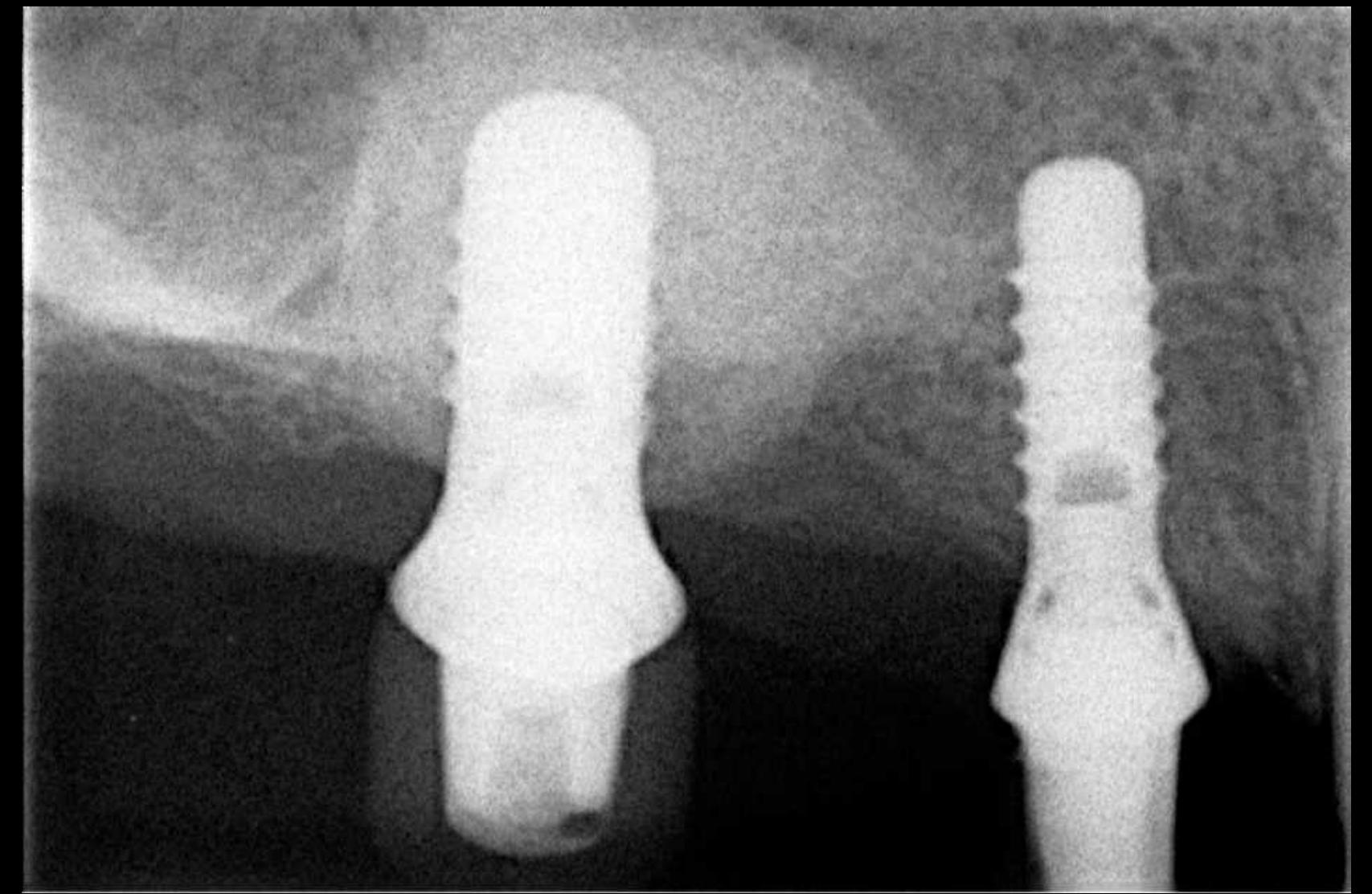
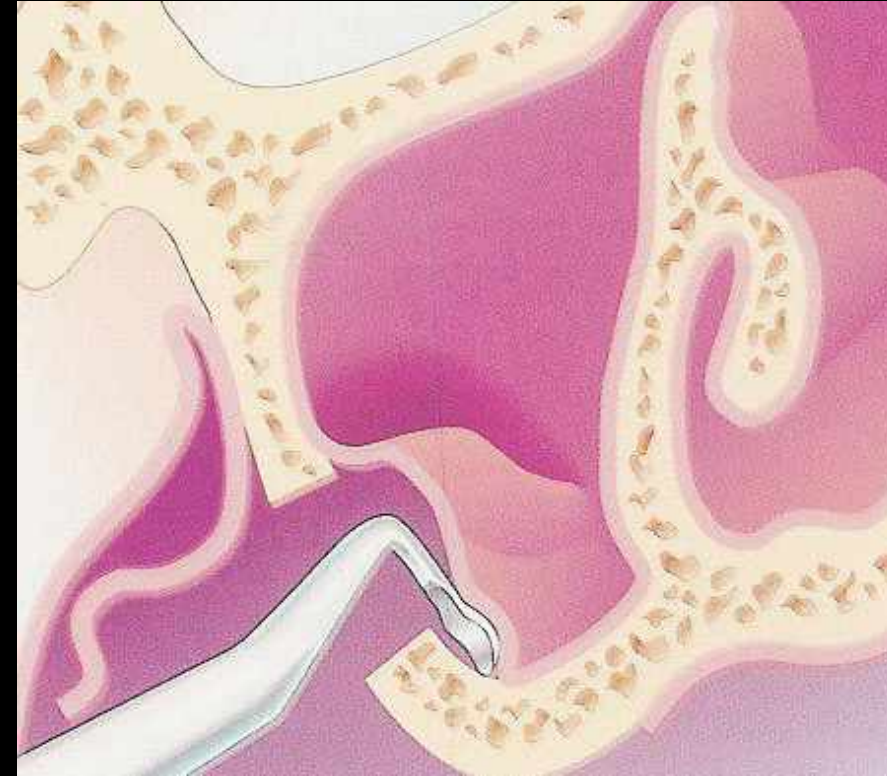
REVUE DE LA LITTERATURE

2158 SINUS LIFT

Résultats de 61,2% à 100%

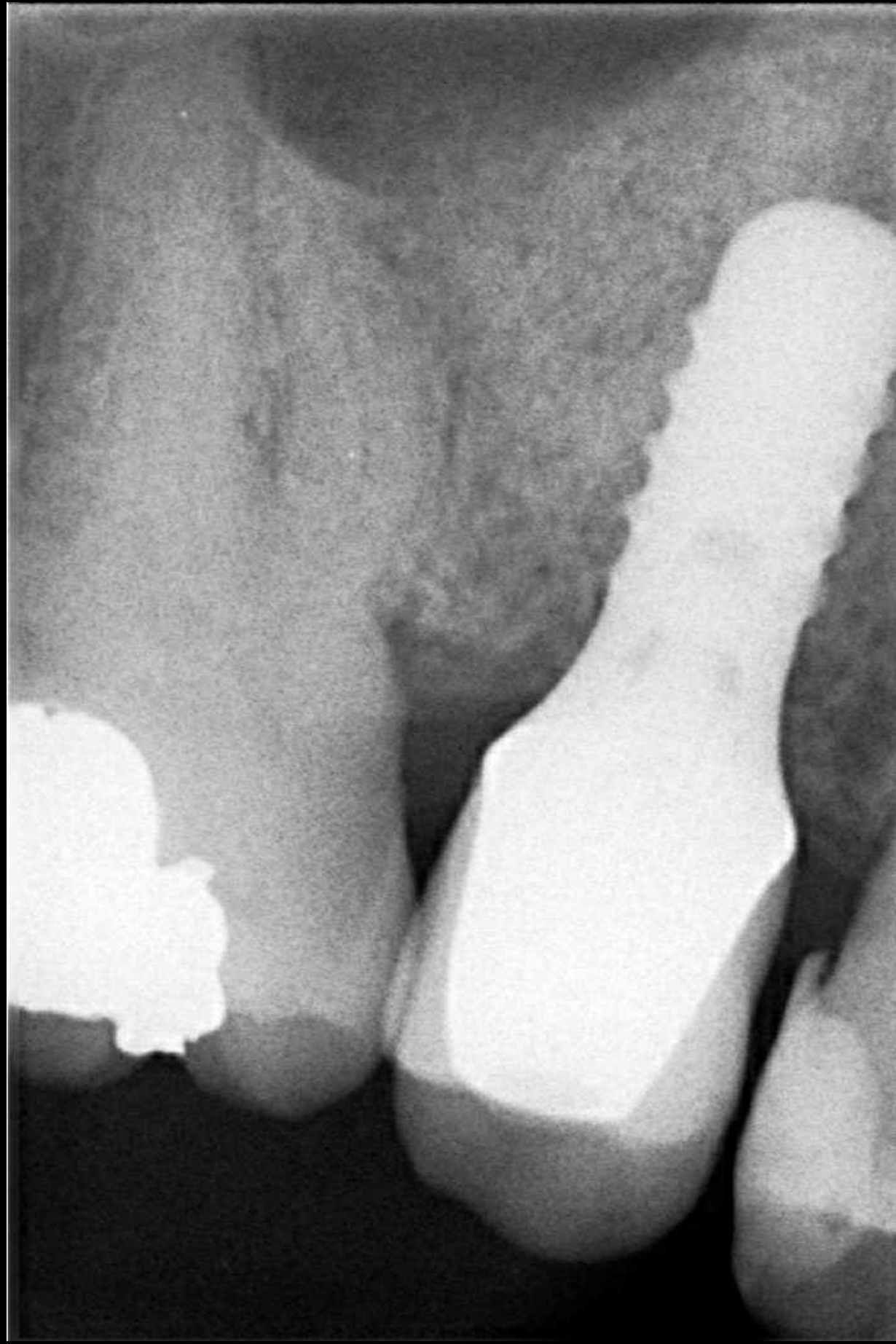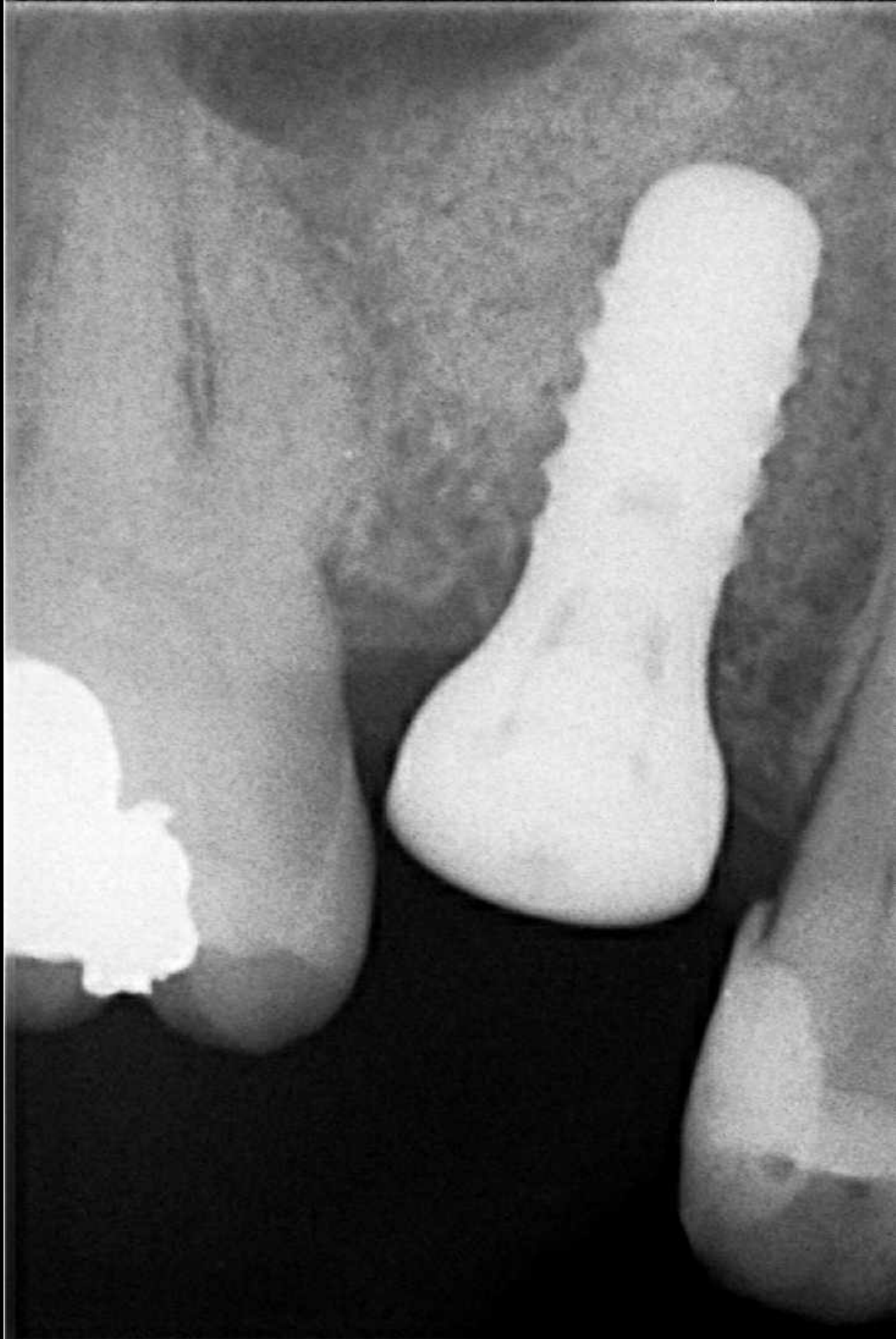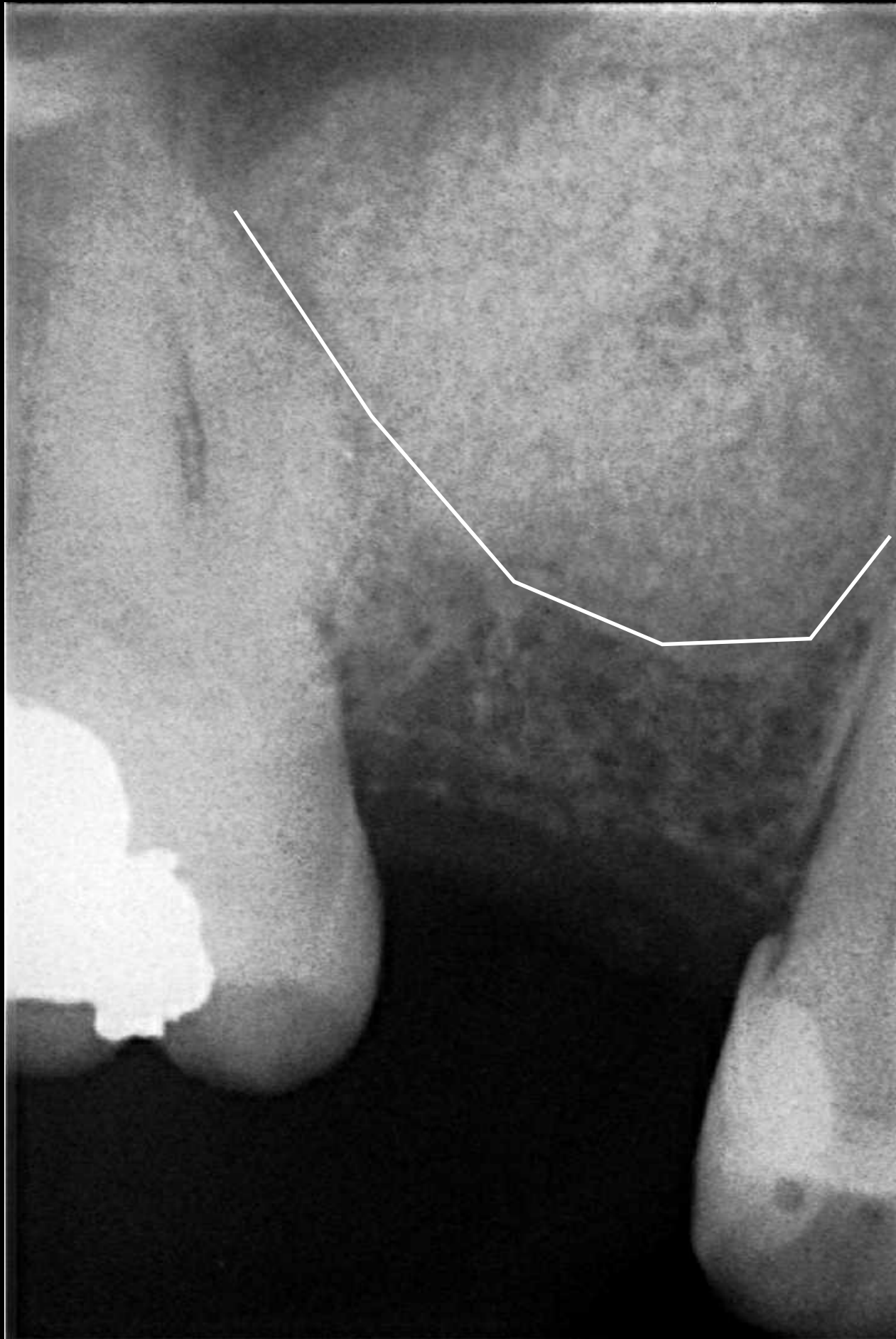
Comment améliorer ses résultats ?

2 - GREFFE DU SINUS PAR VOILET LATERAL

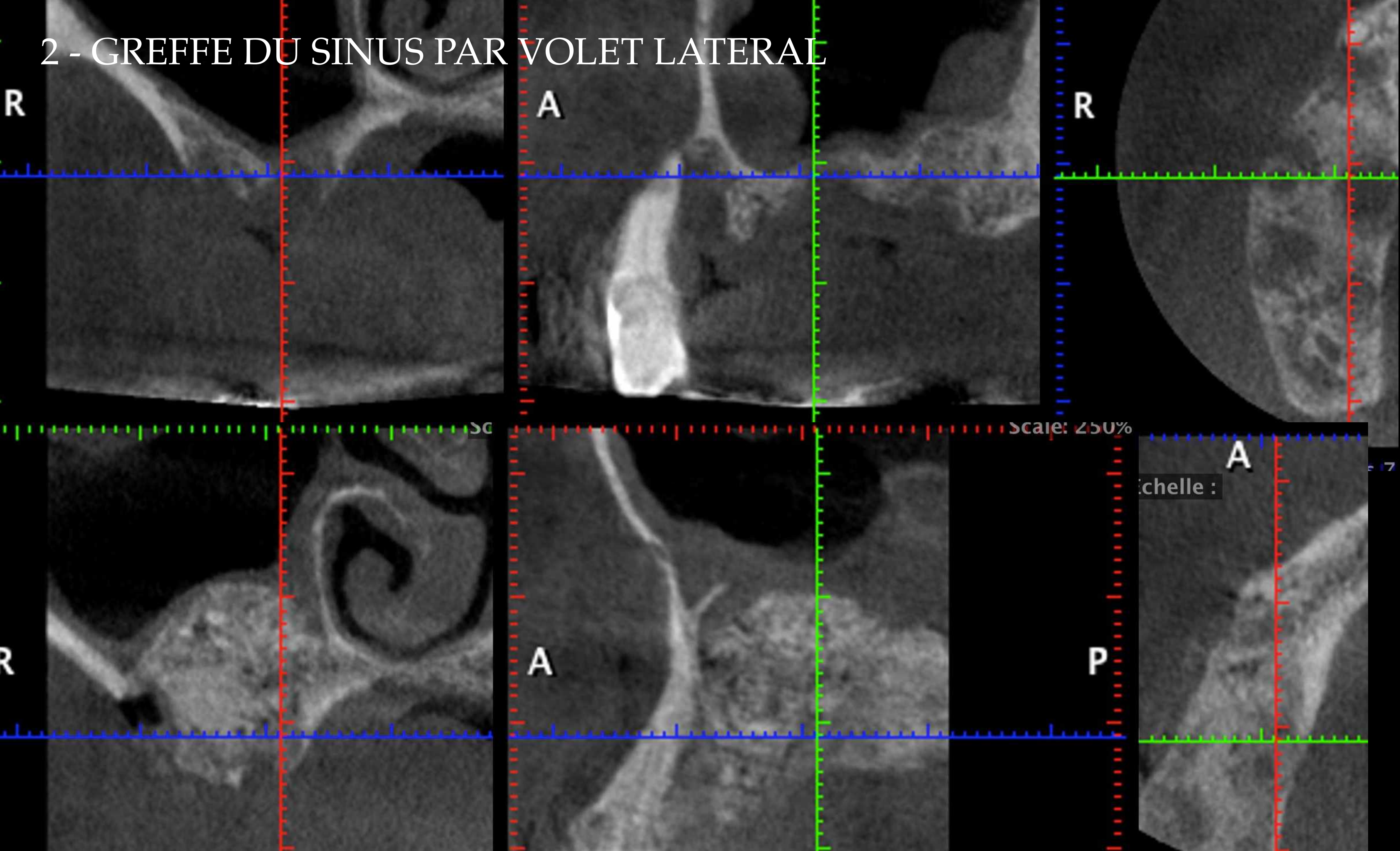


- Greffe du sinus anterieur afin de rétablir une occlusion à la 1ère molaire.
- Greffe pour obtenir un manchon osseux de 10 mm de haut pour la pose d'implant à surface rugueuse de 8 à 10 mm de long en diamètre large.
- Technique du volet latéral : Boyne et James 1980, Tatum 1986.

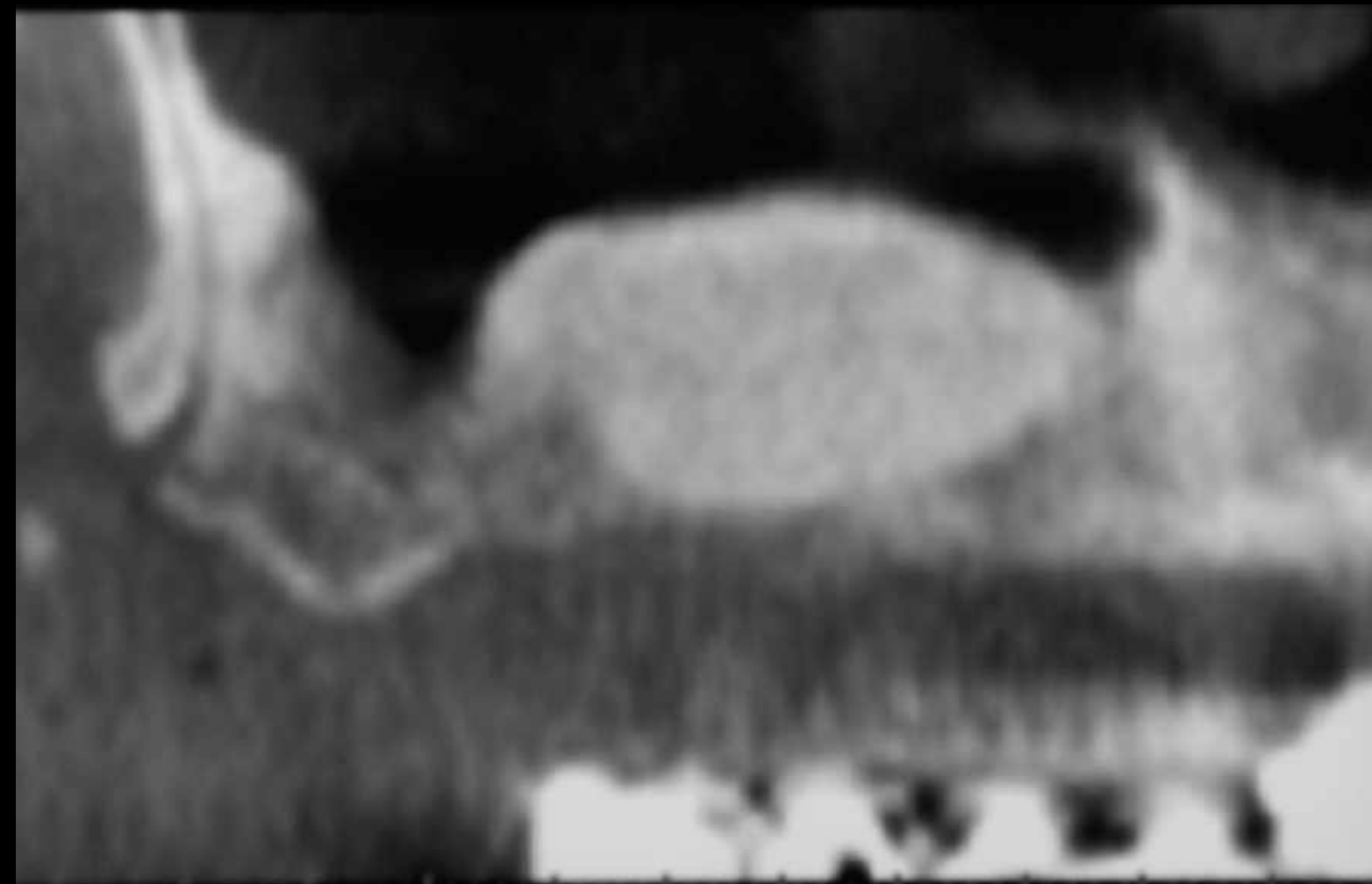
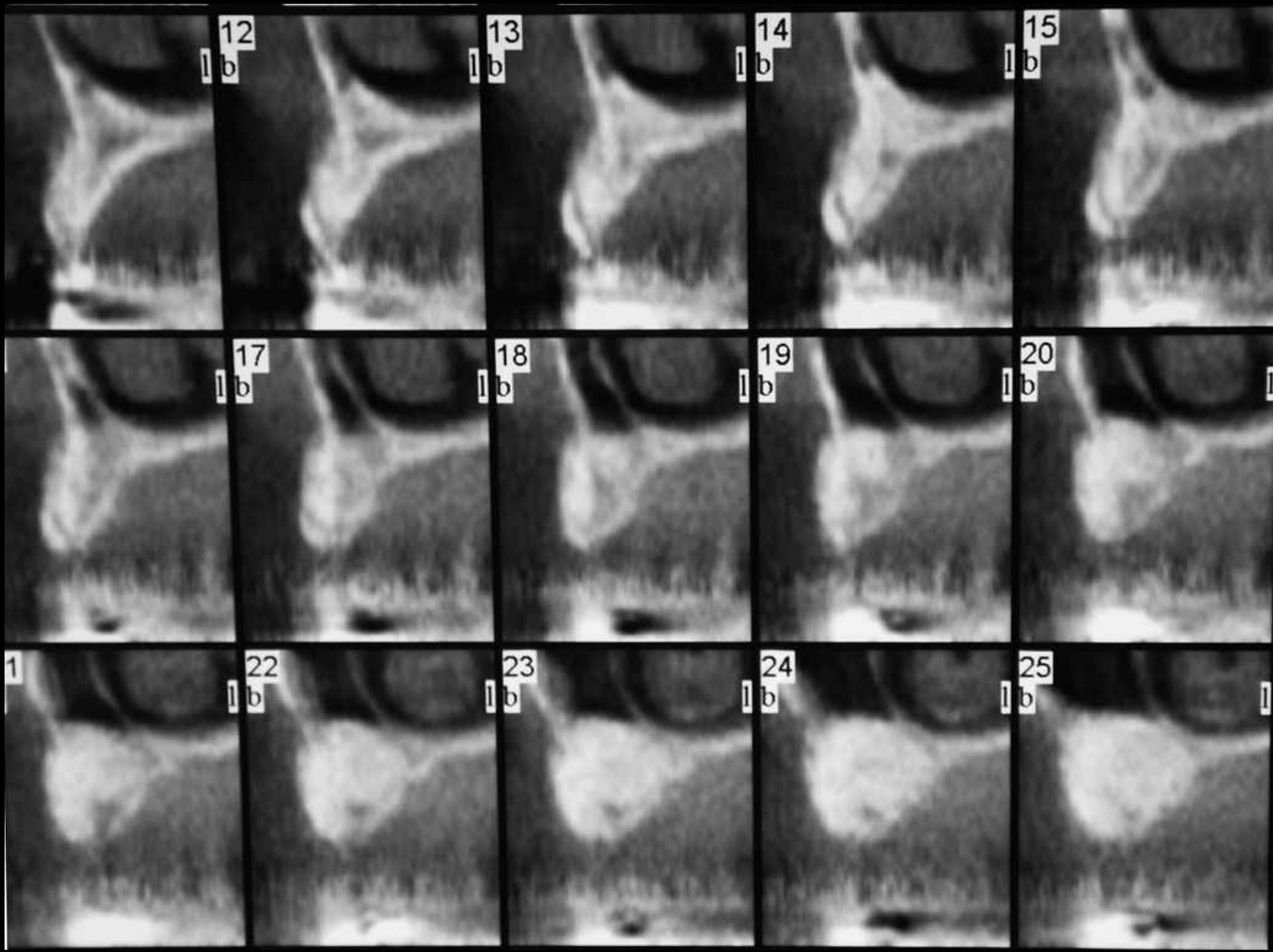
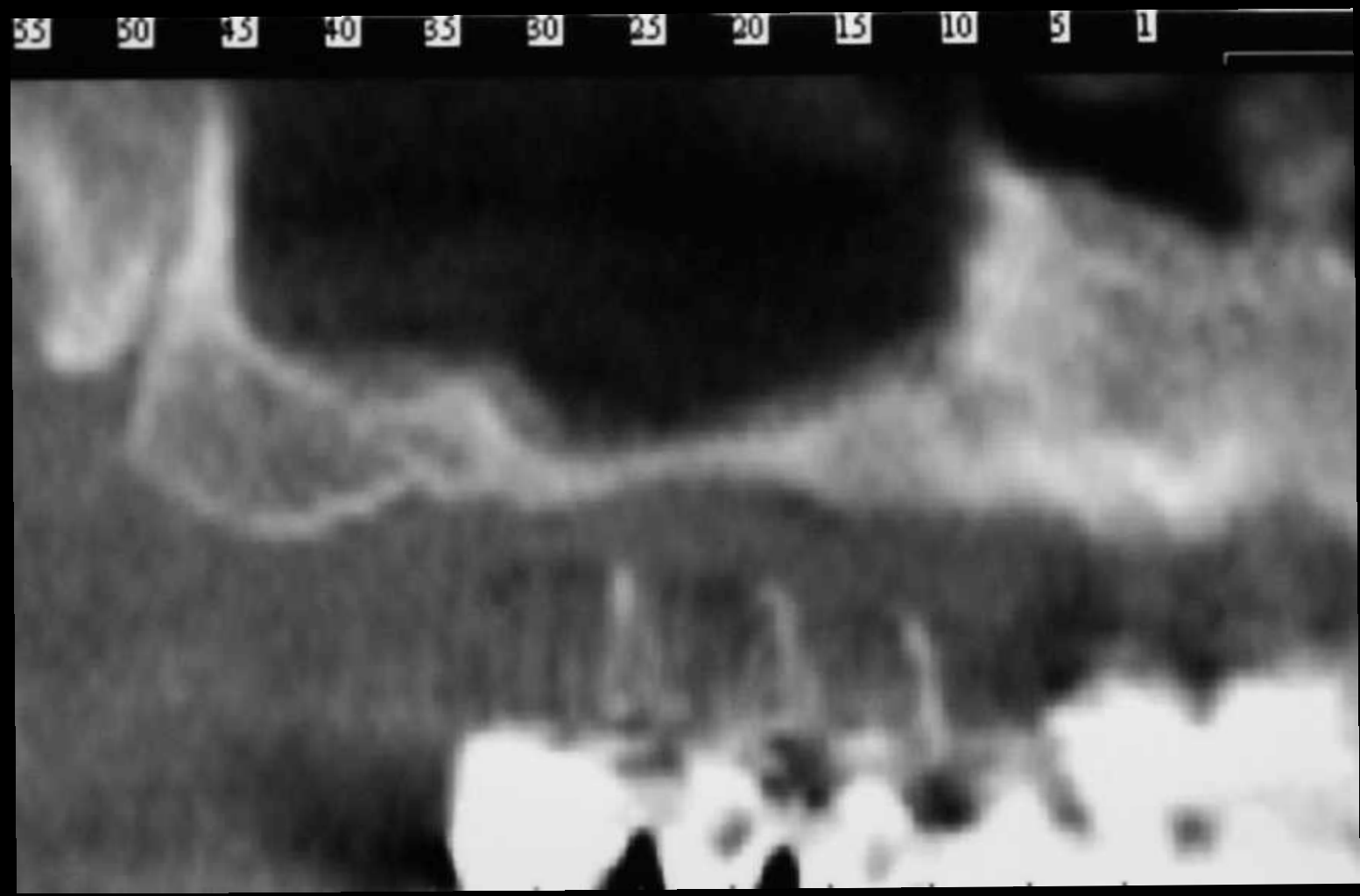
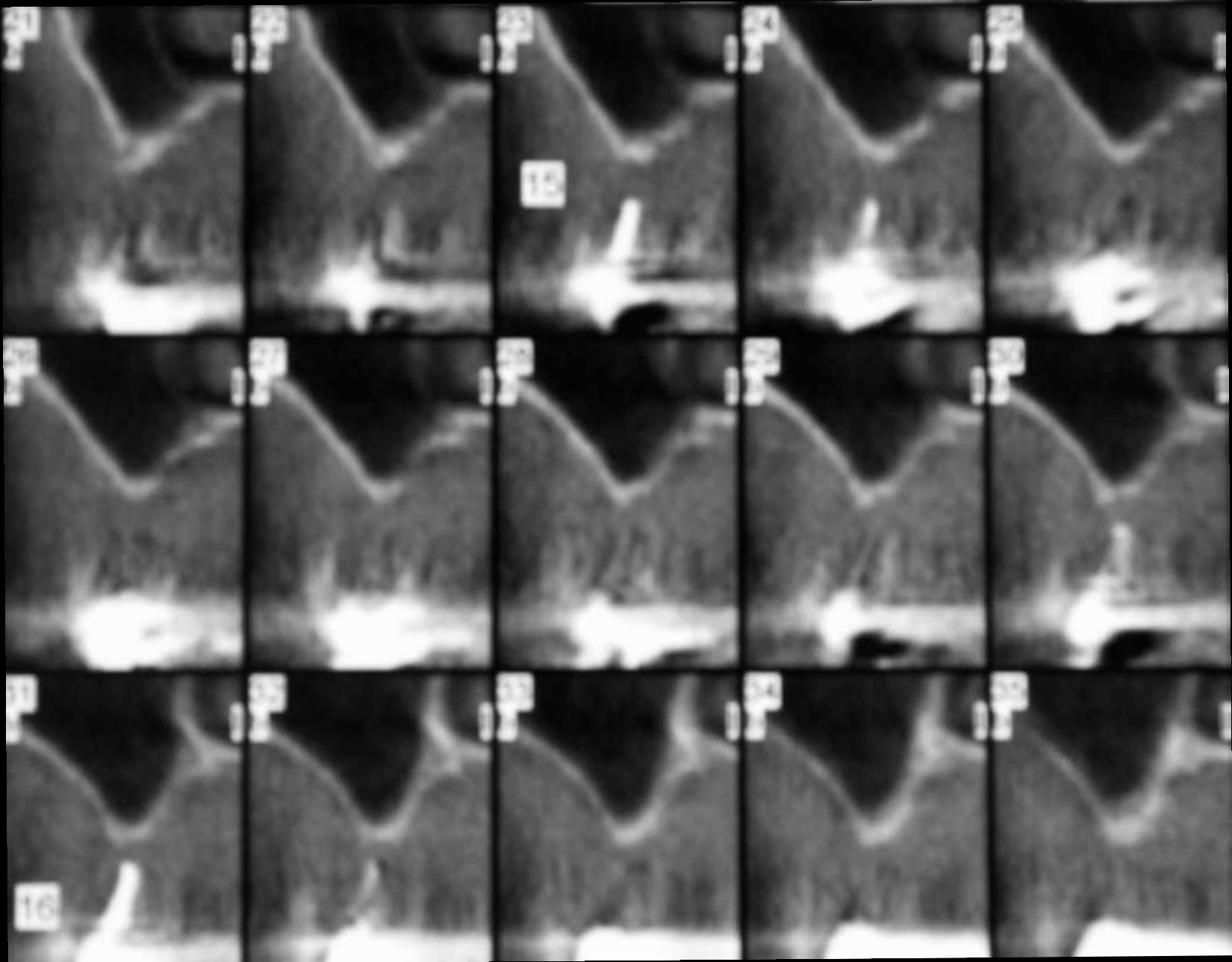
2 - GREFFE DU SINUS PAR VOILET LATERAL



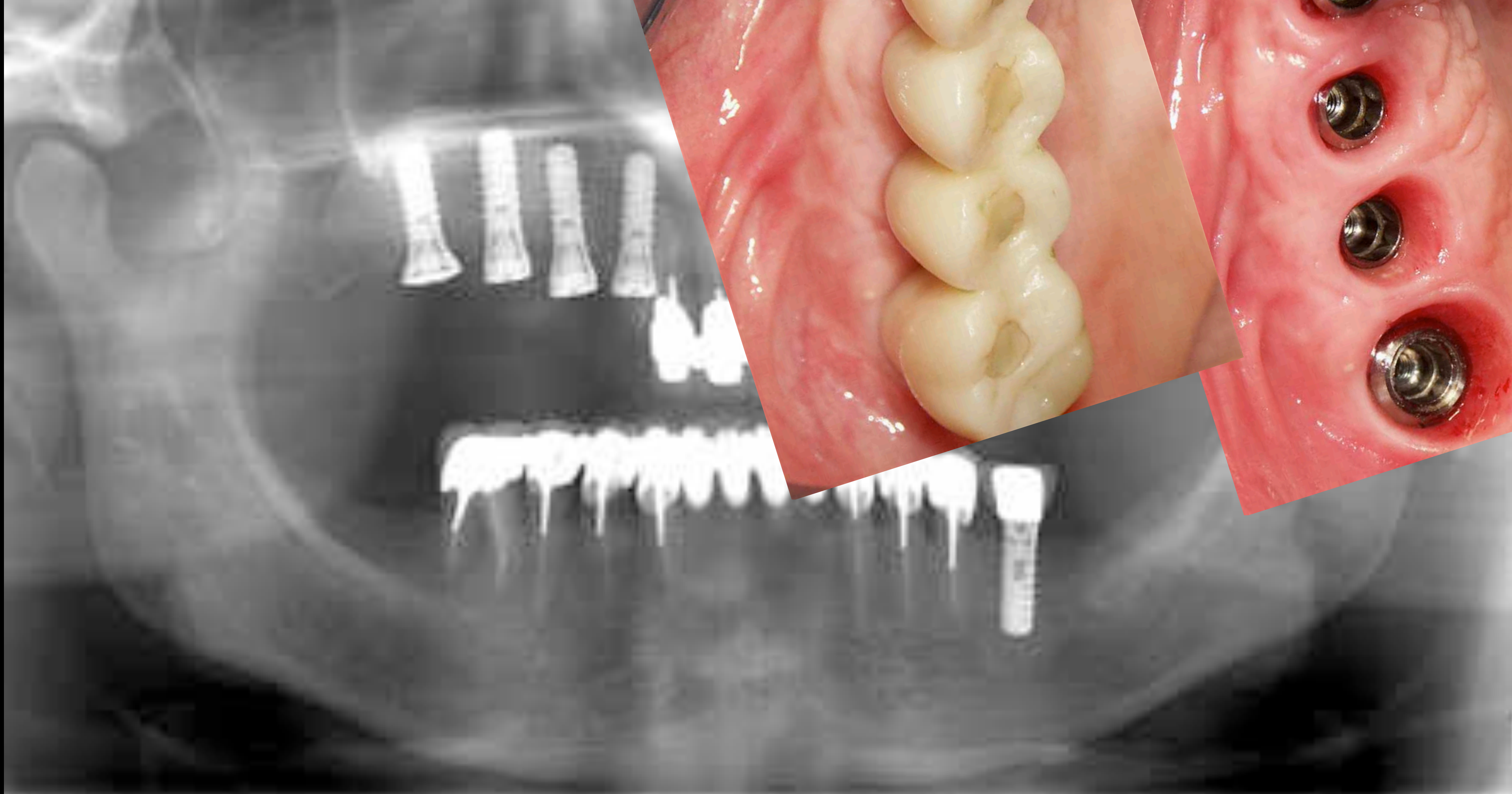
2 - GREFFE DU SINUS PAR VOILE LATERAL



2 - GREFFE DU SINUS PAR VOILE LATERAL



2 - GREFFE DU SINUS PAR VOILET LATERAL



2 - GREFFE DU SINUS PAR VOLET LATÉRAL

Lambeau

Manche de bistouri rond

Lame de bistouri 15c

Décolleur de Prichard- décolleur rugine de Mead

Ecarteur

Prélèvement osseux

Fraise de Lindemann - Fraise boule

ou piezosurgery

Pièce à main chirurgicale - moteur implantaire

Ciseaux à os - Pince gouge démultipliée.

Cupules

Élévation membrane

Curette de sinus (3)

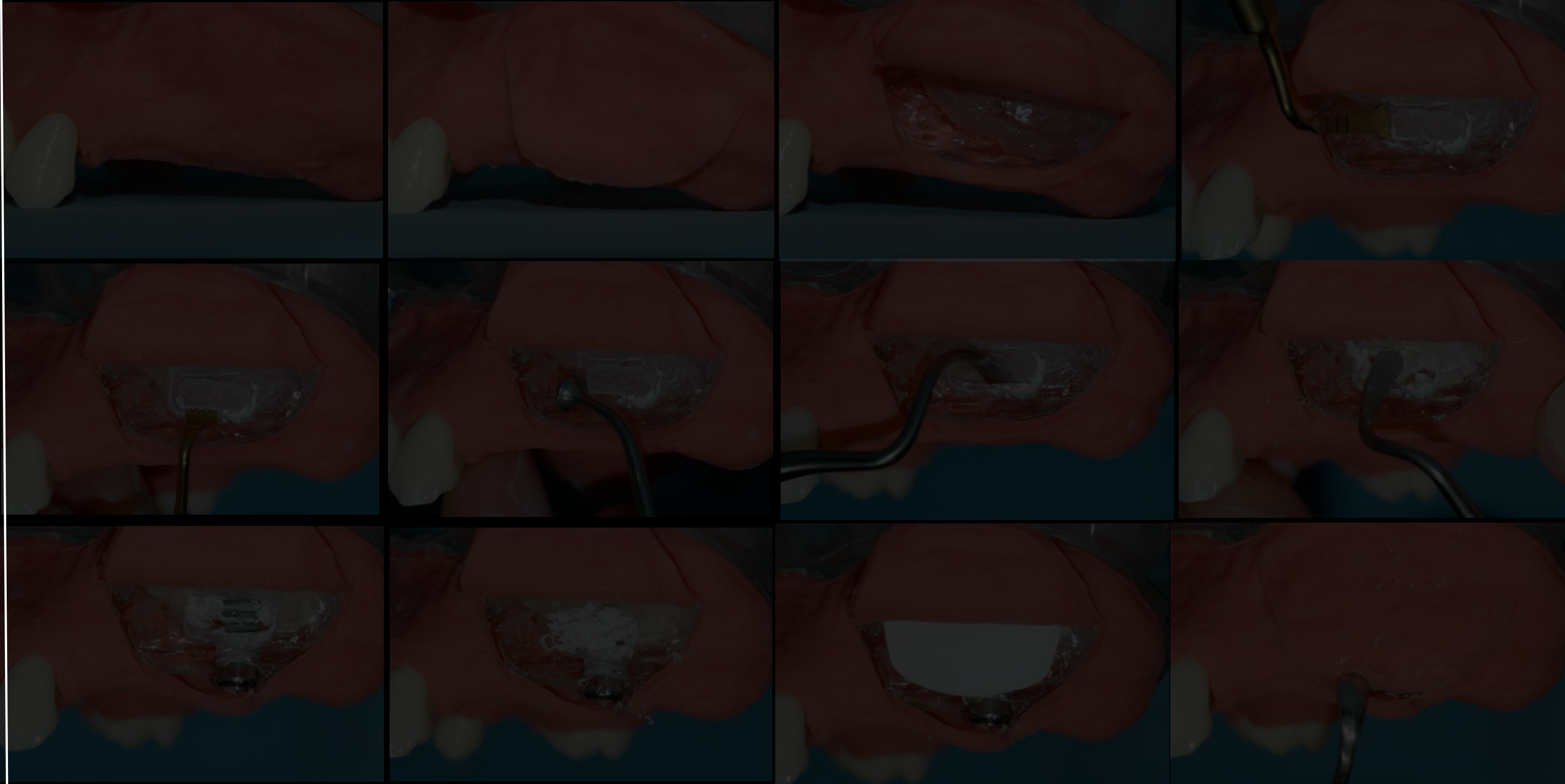Precelle à tissu

Porte aiguille de Castroviejo

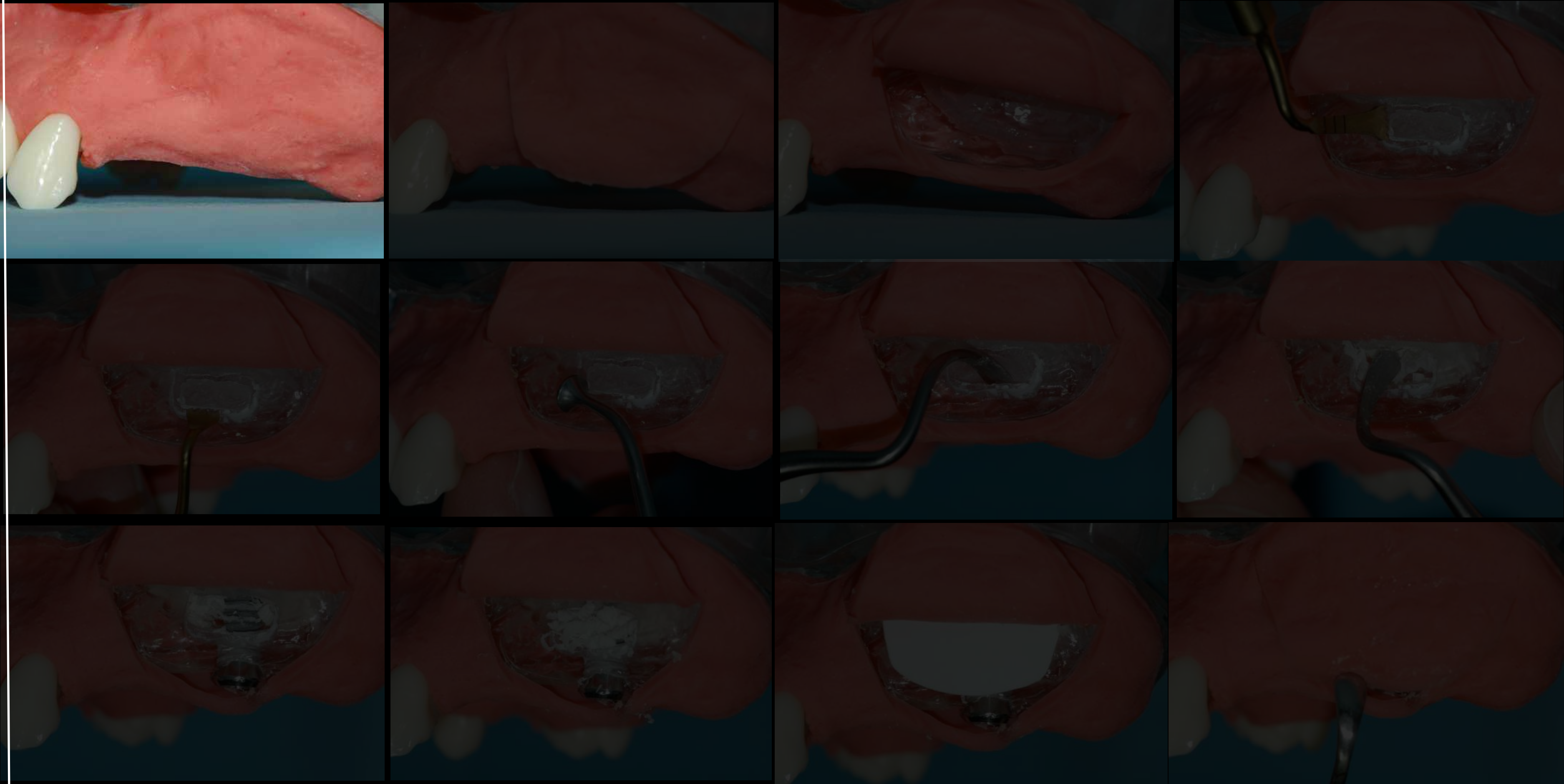Suture

Ciseaux à suture

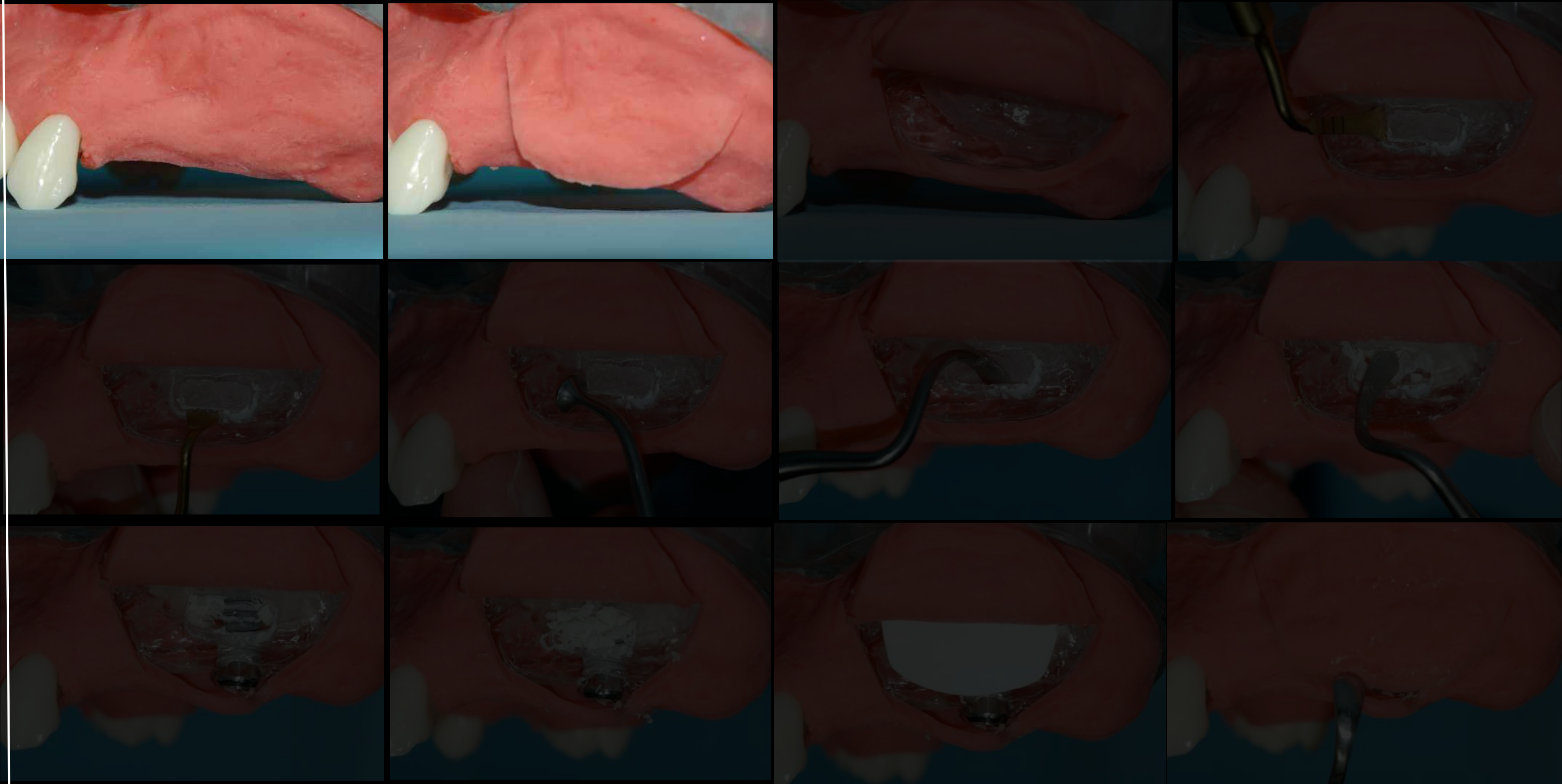
2 - GREFFE DU SINUS PAR VOILET LATERAL



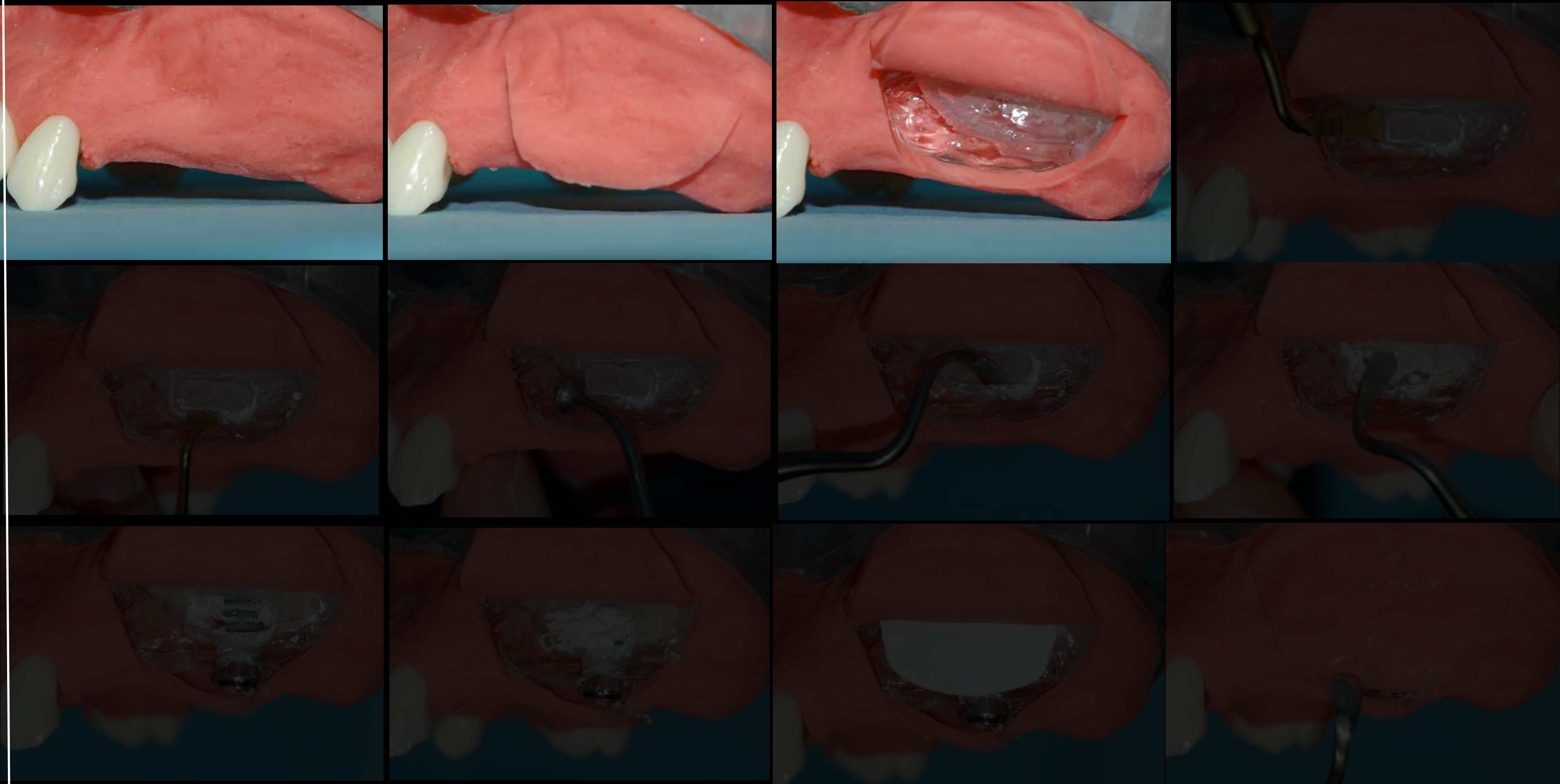
2 - GREFFE DU SINUS PAR VOILET LATERAL



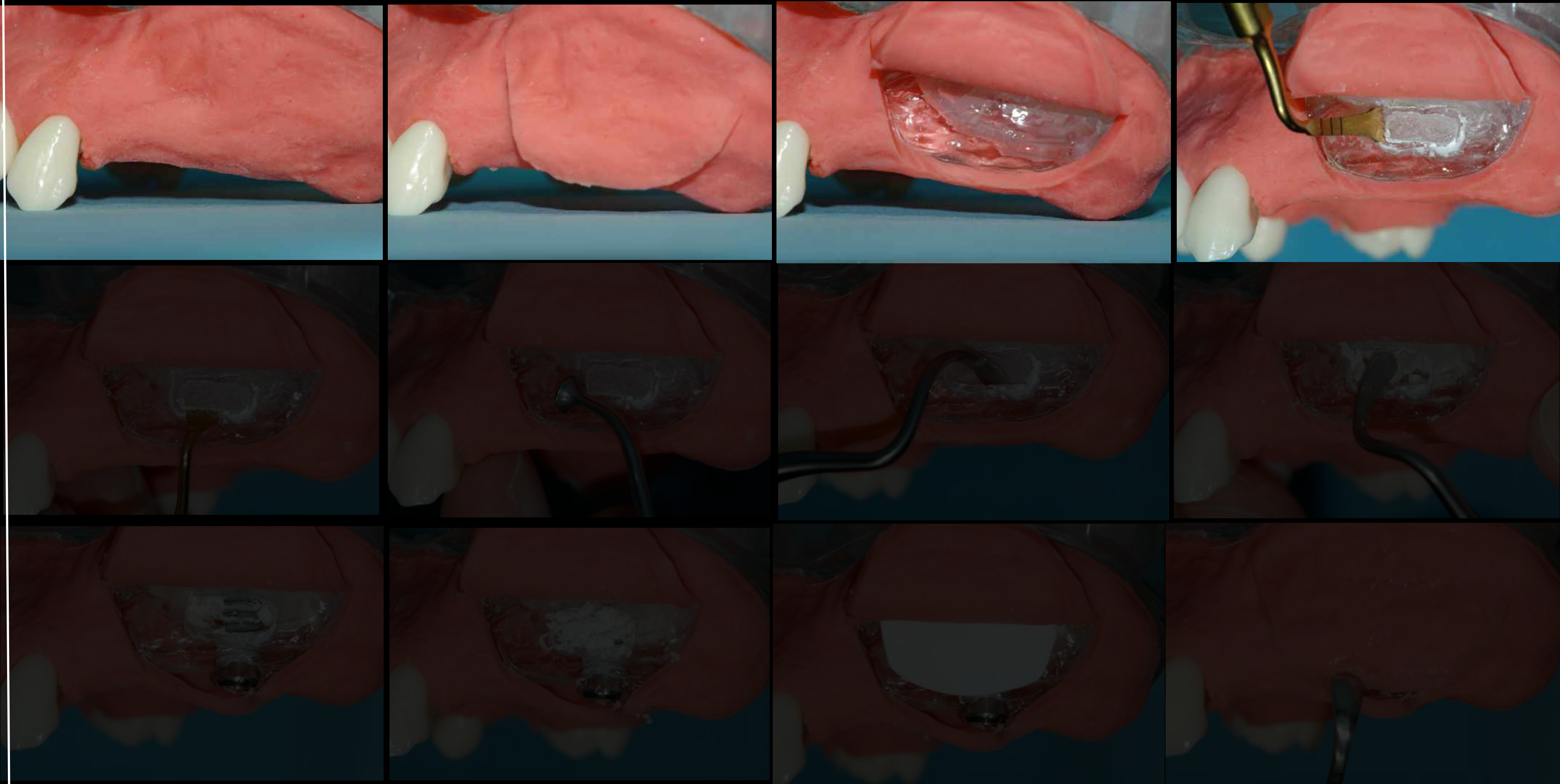
2 - GREFFE DU SINUS PAR VOILET LATERAL



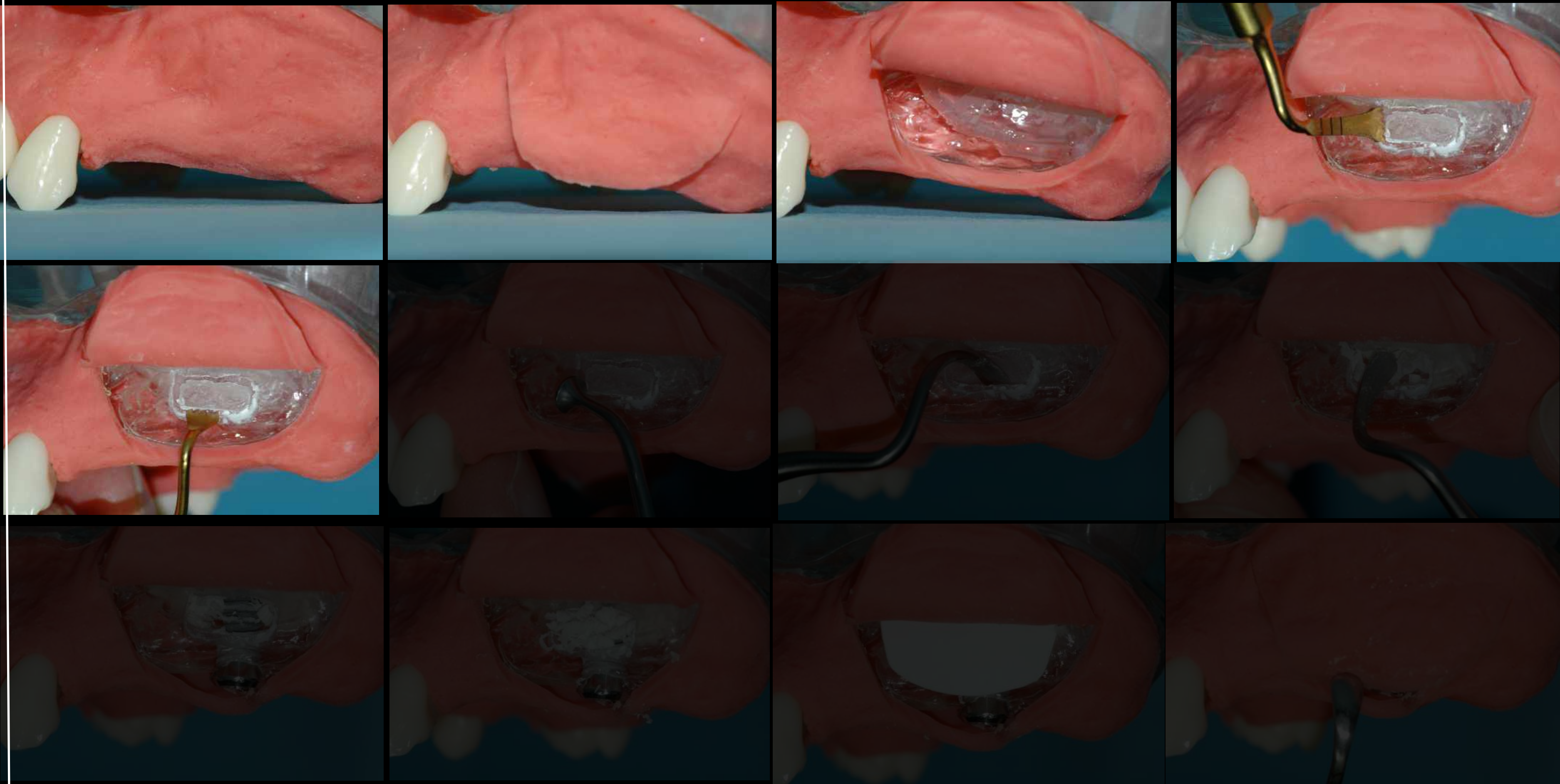
2 - GREFFE DU SINUS PAR VOILET LATERAL



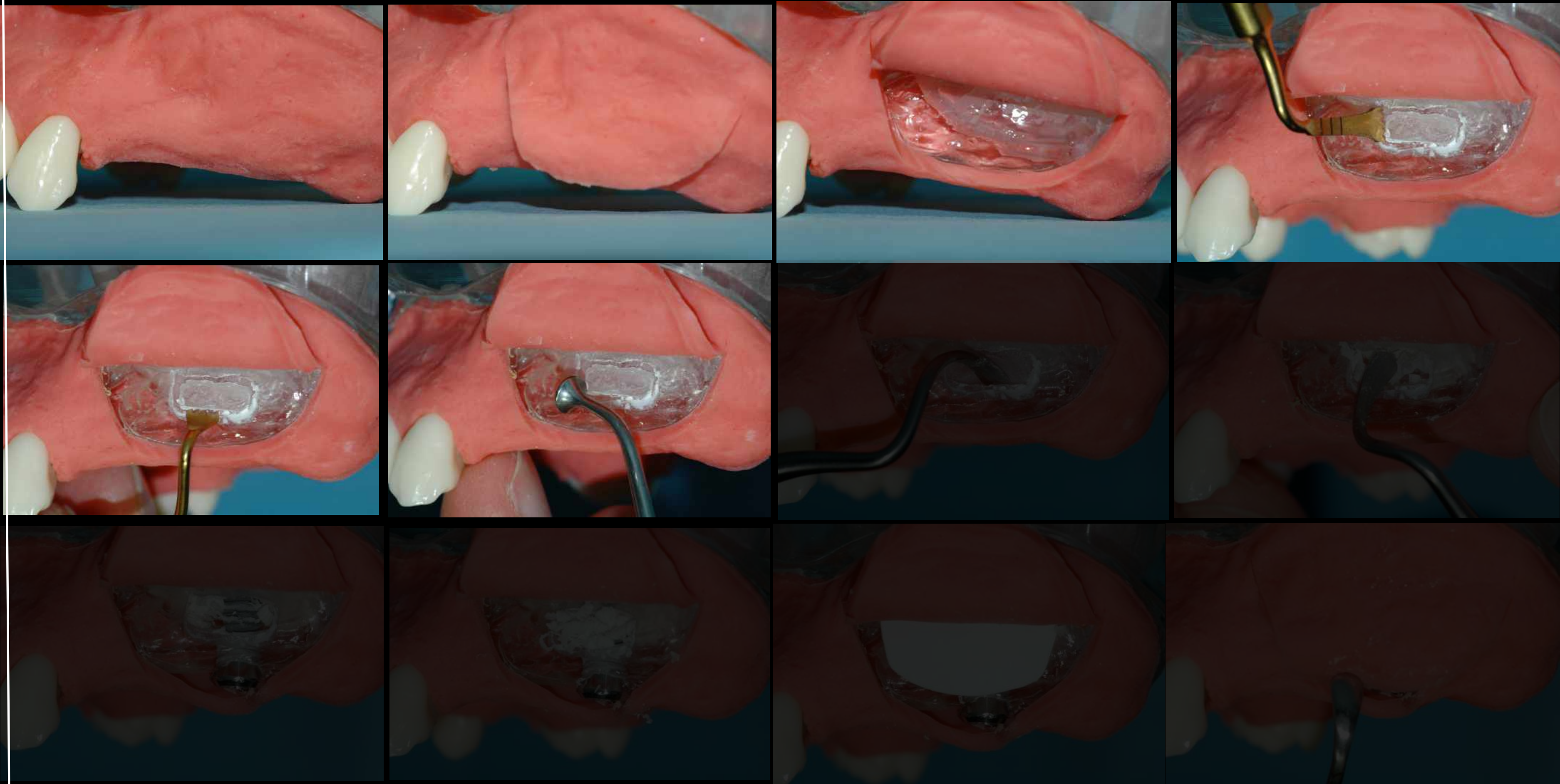
2 - GREFFE DU SINUS PAR VOILET LATERAL



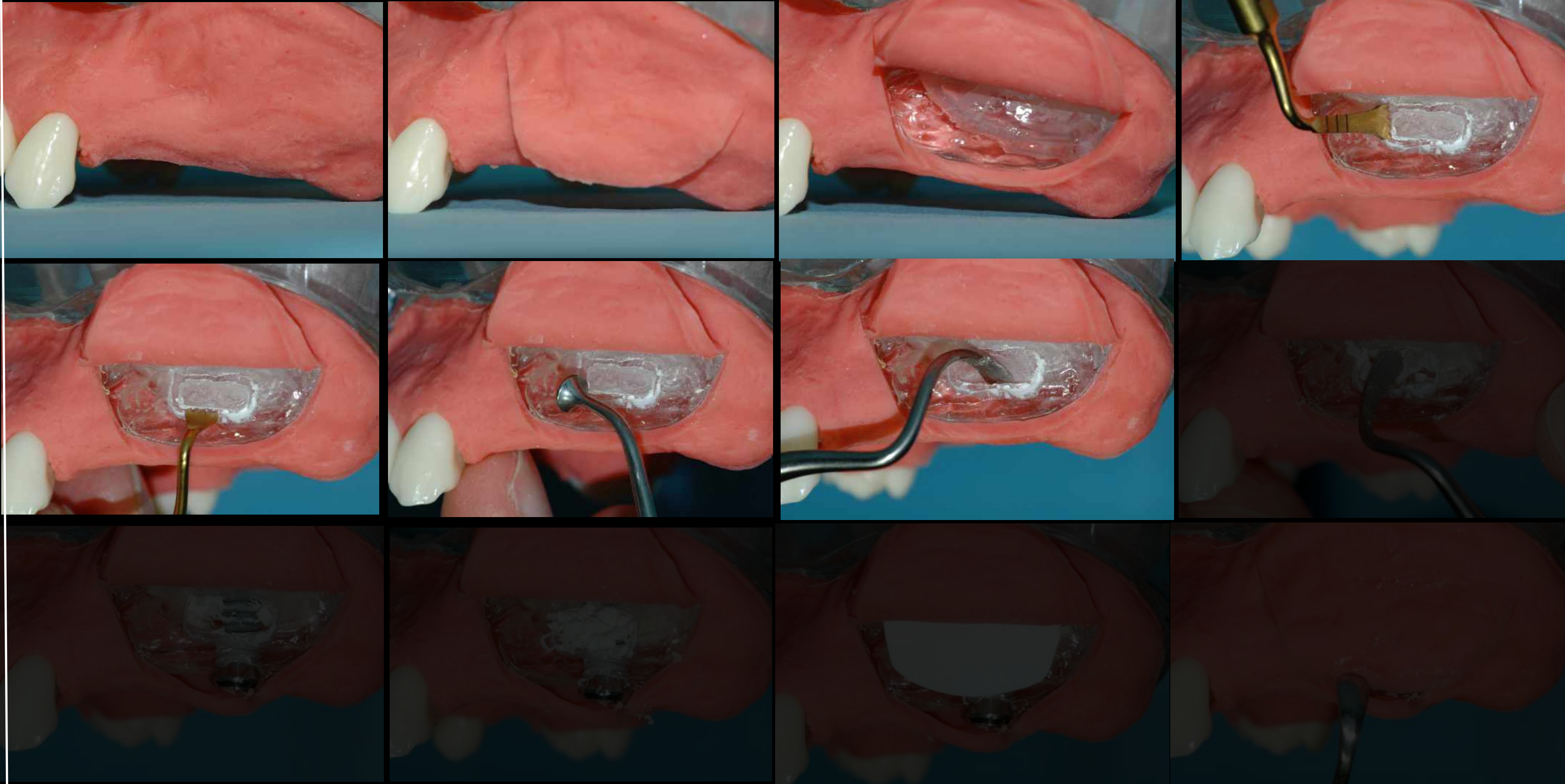
2 - GREFFE DU SINUS PAR VOILET LATERAL



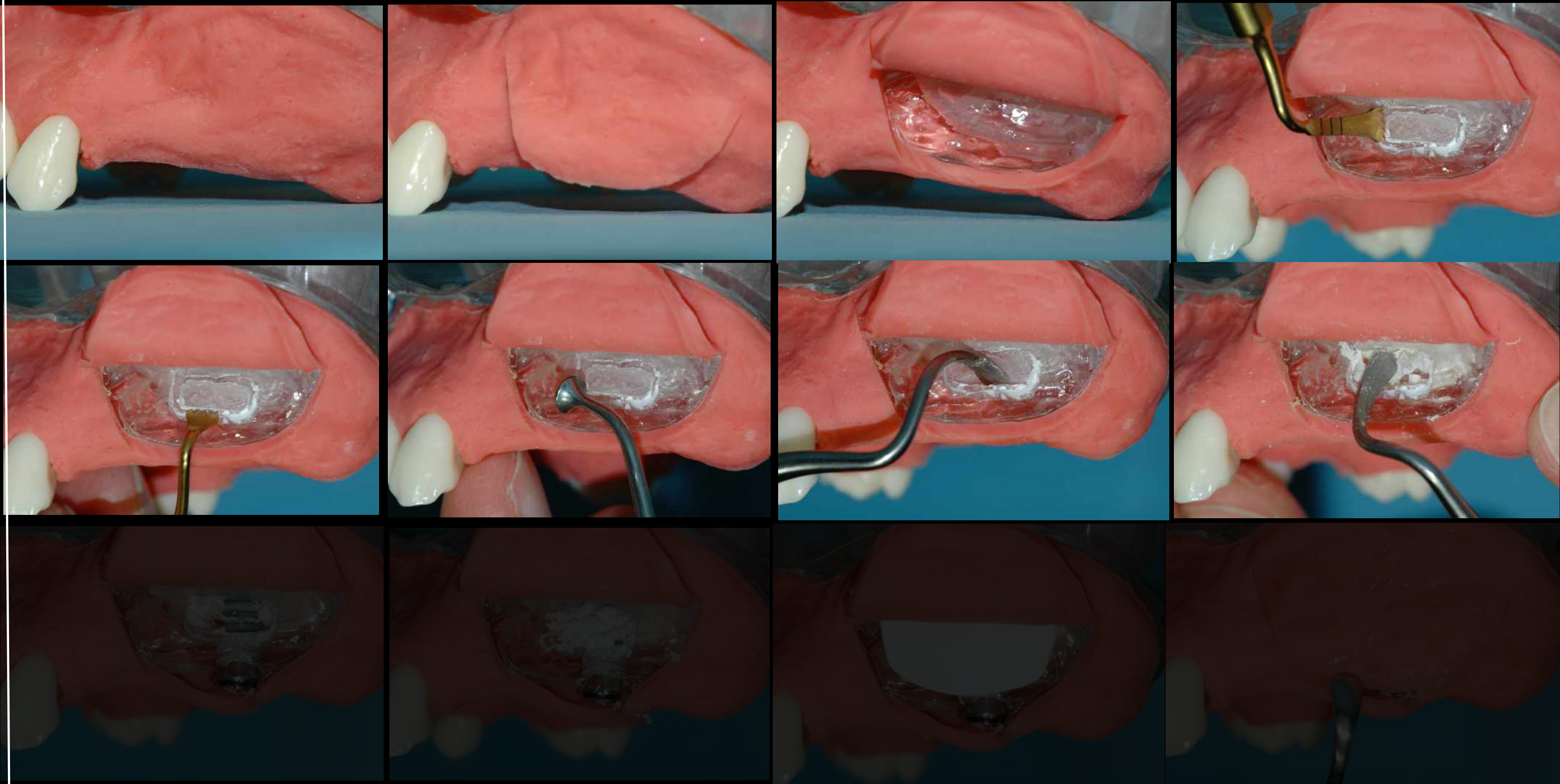
2 - GREFFE DU SINUS PAR VOILET LATERAL



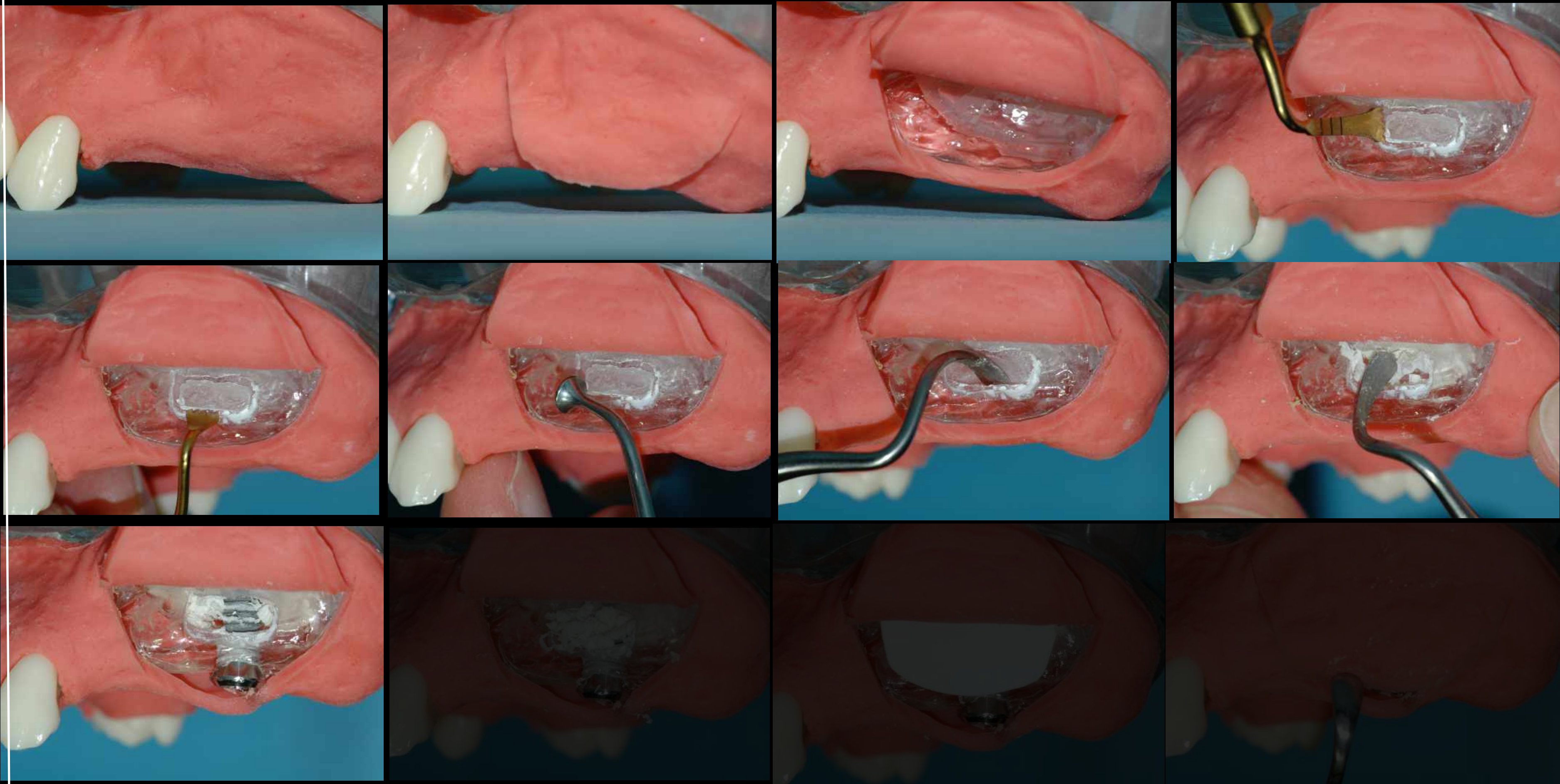
2 - GREFFE DU SINUS PAR VOILET LATERAL



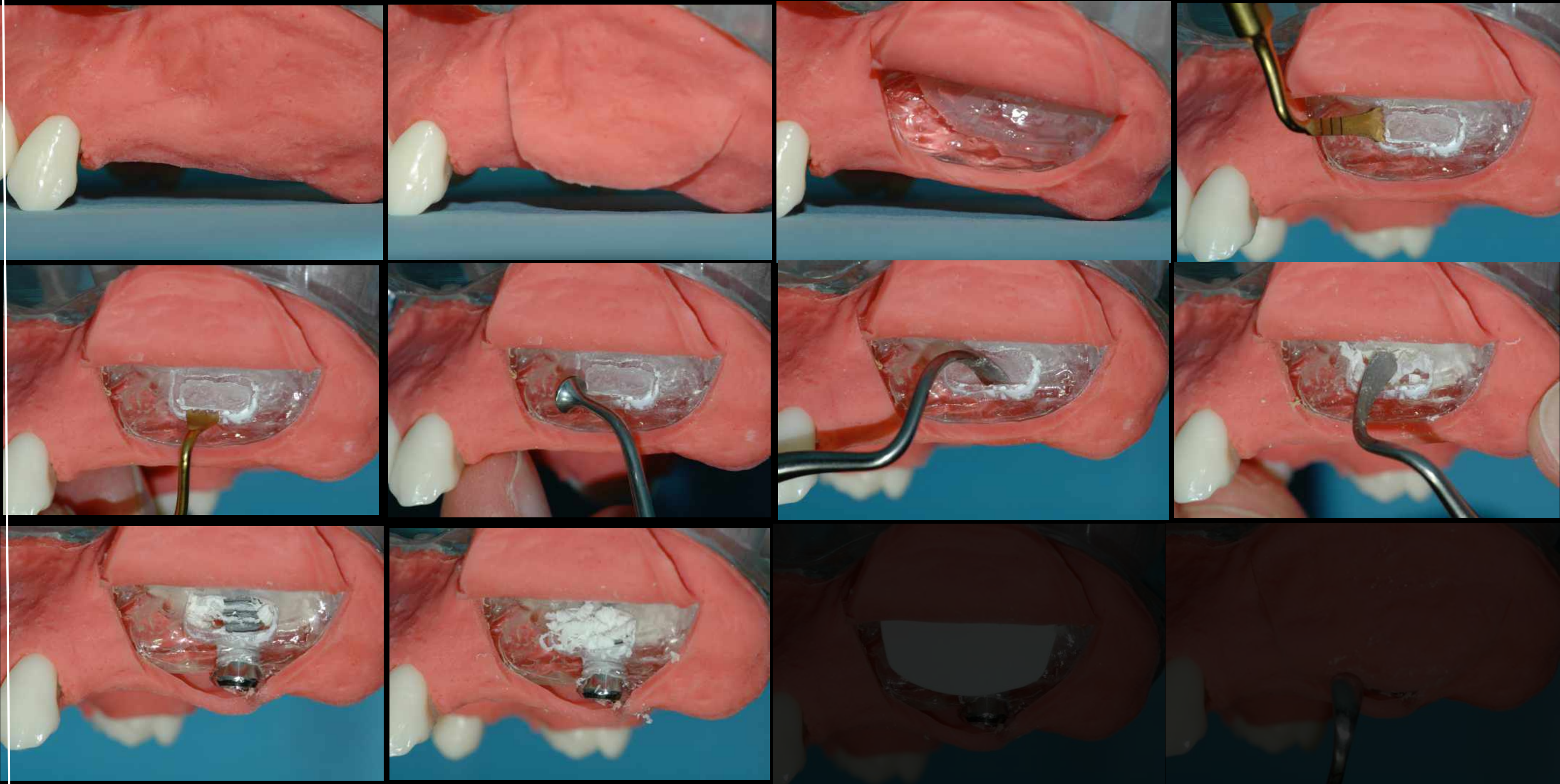
2 - GREFFE DU SINUS PAR VOILET LATERAL



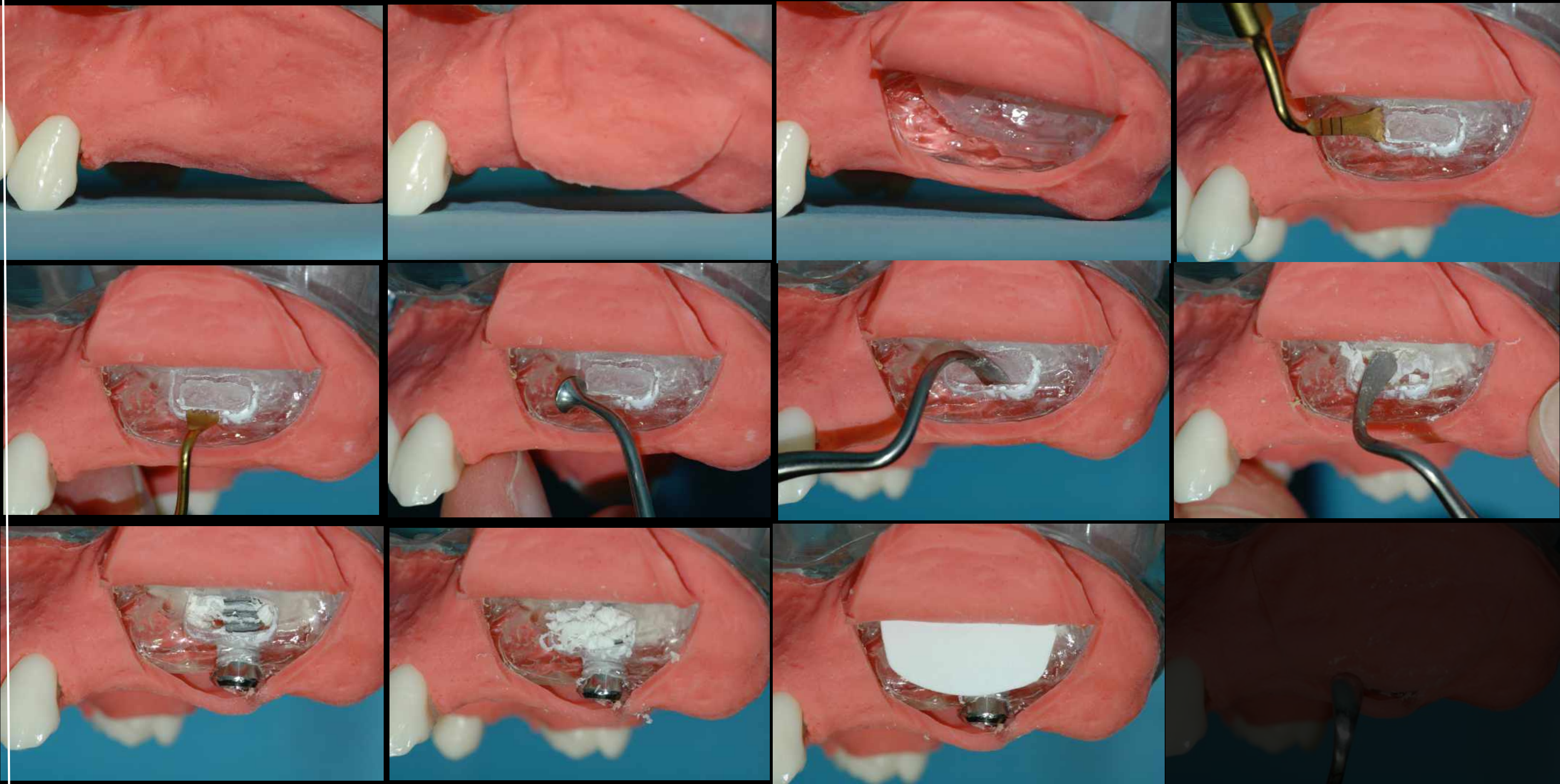
2 - GREFFE DU SINUS PAR VOILET LATERAL



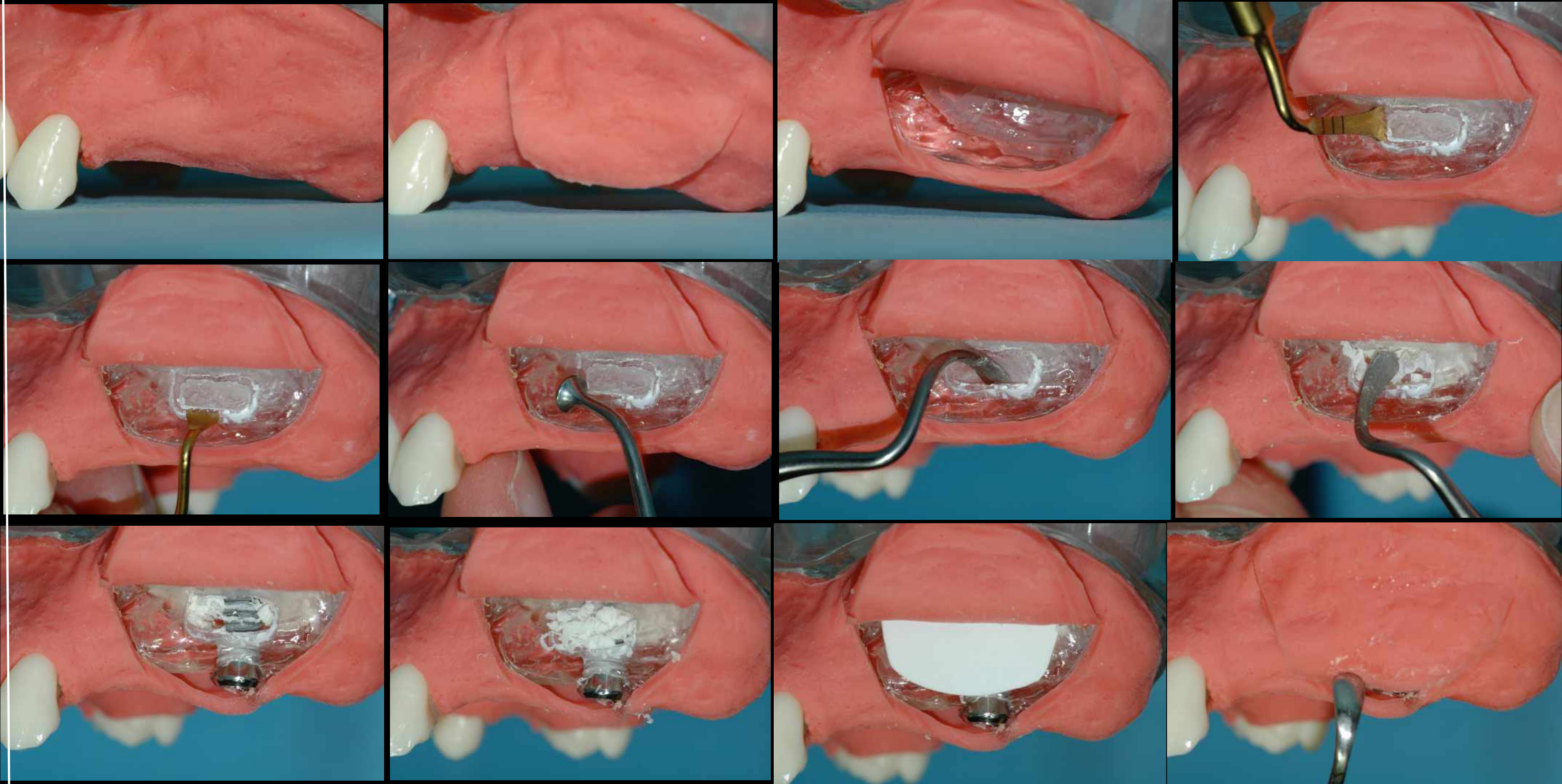
2 - GREFFE DU SINUS PAR VOILET LATERAL



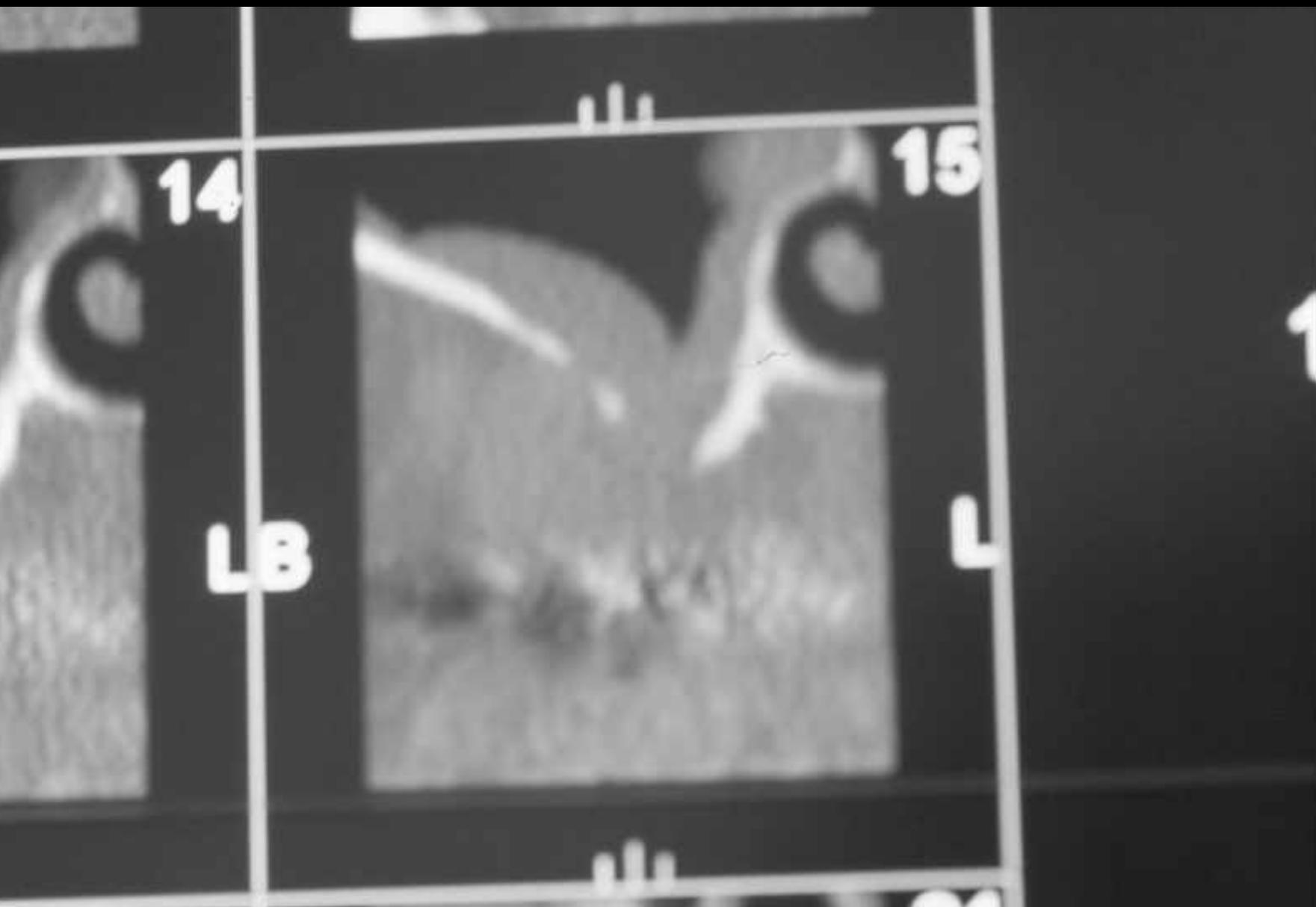2 - GREFFE DU SINUS PAR VOILET LATERAL



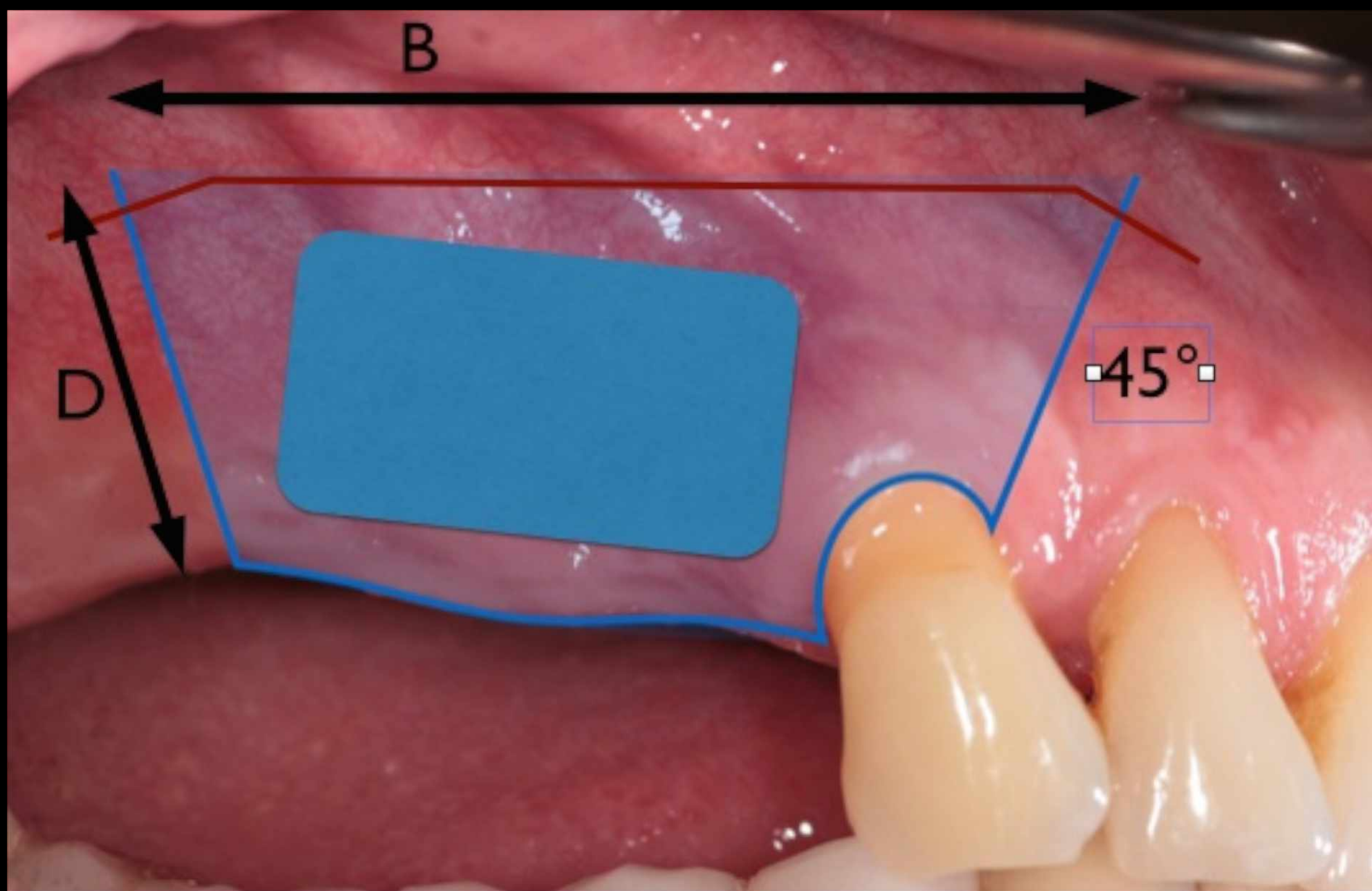
2 - GREFFE DU SINUS PAR VOILET LATERAL



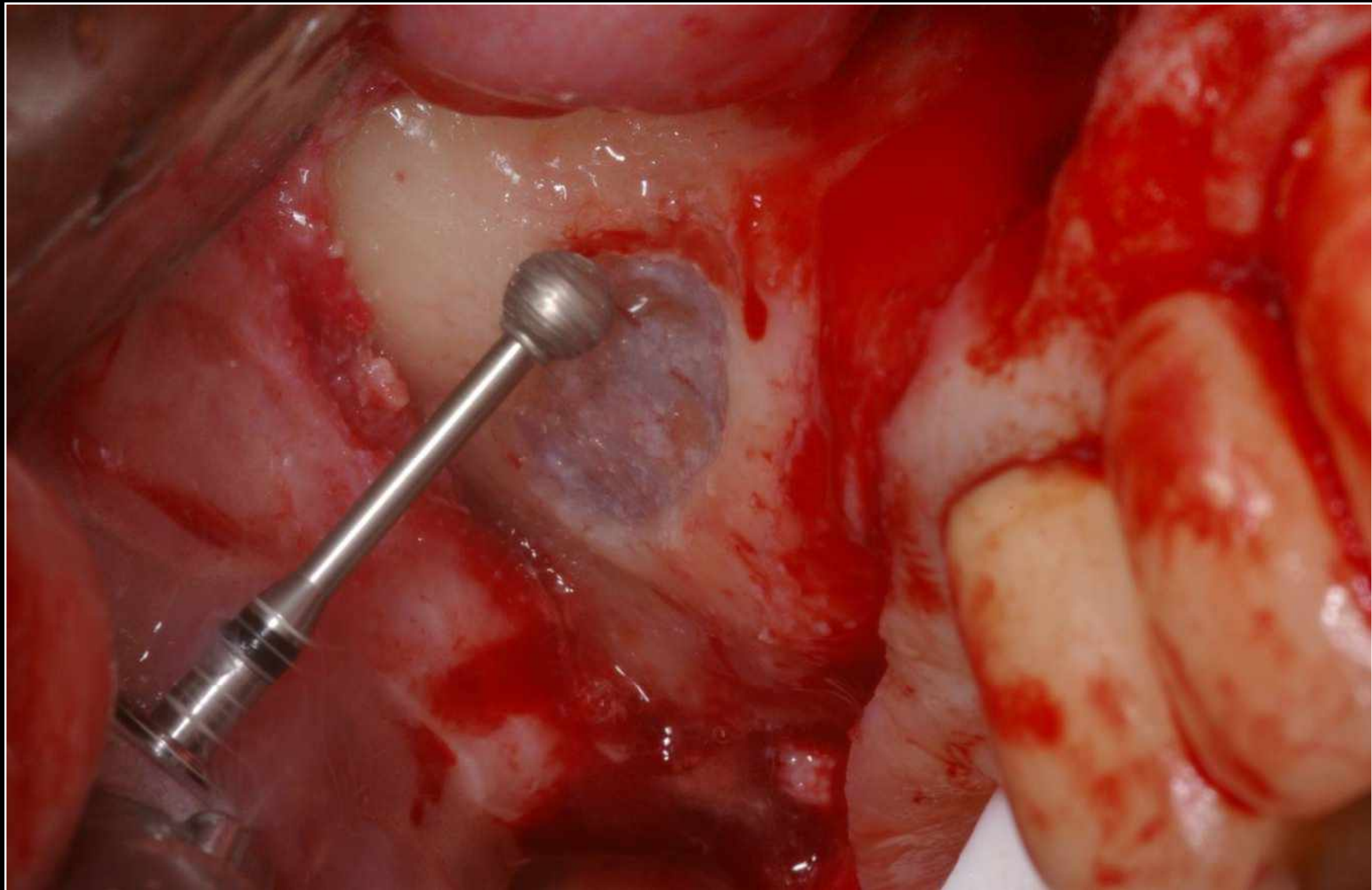
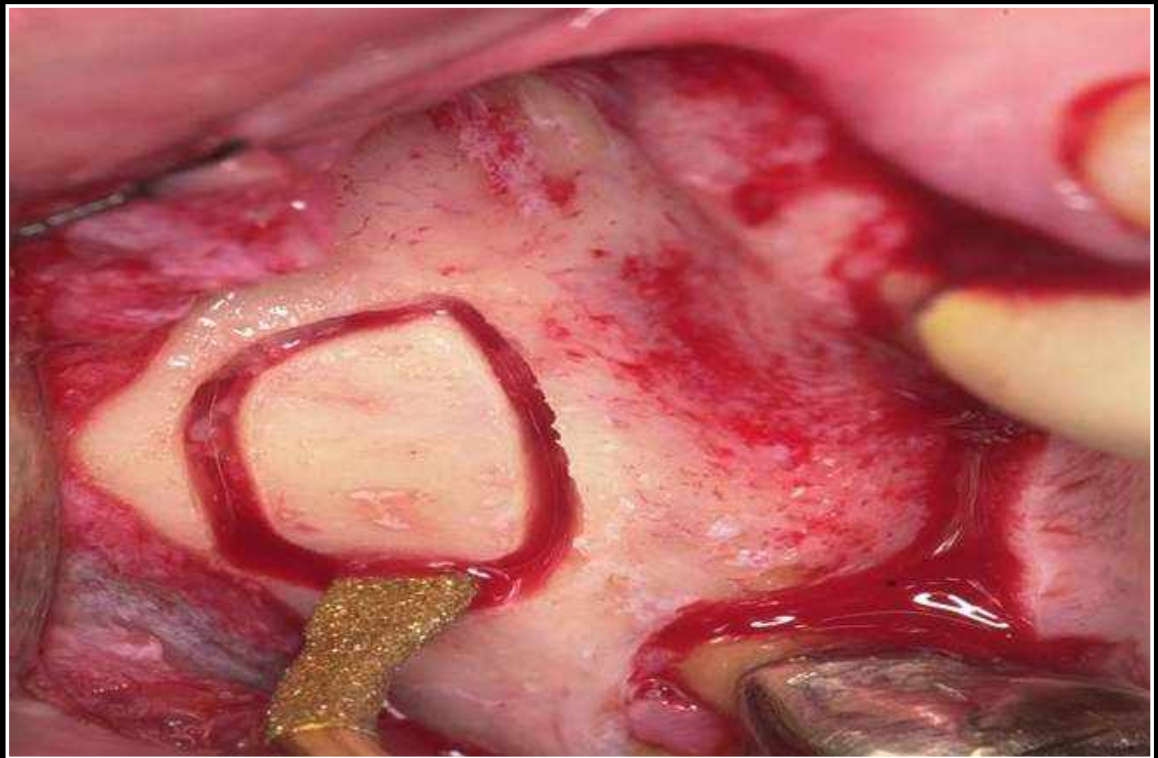

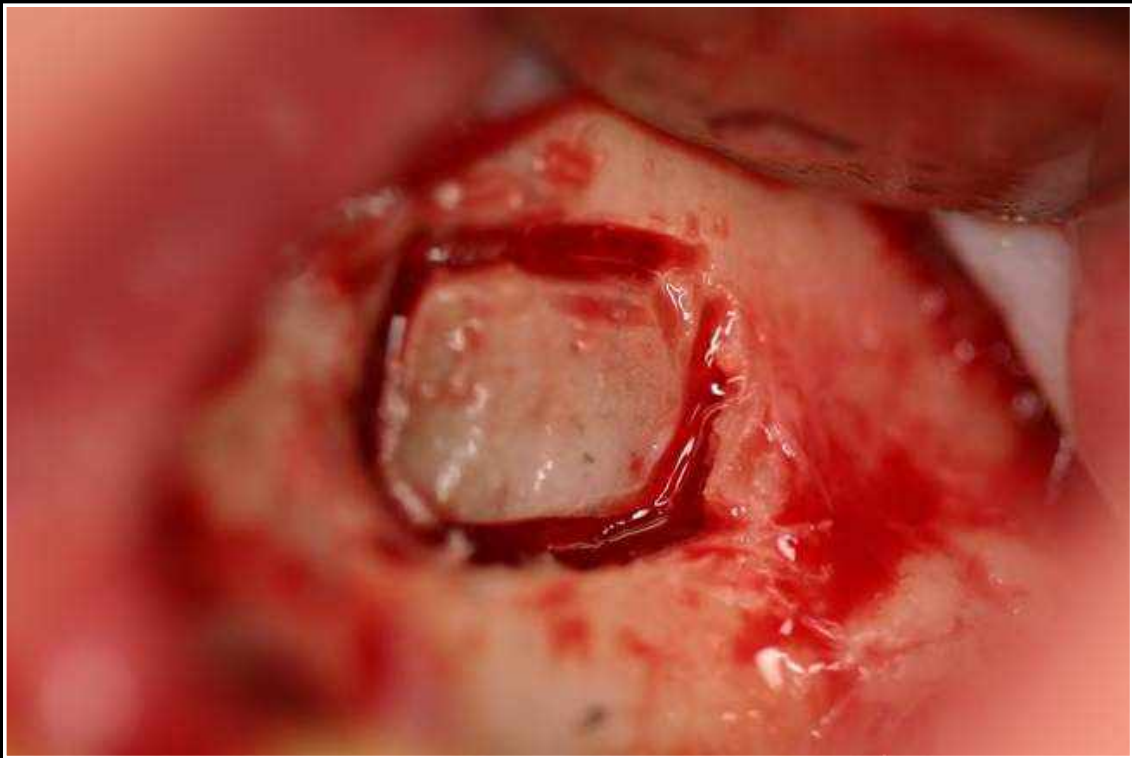
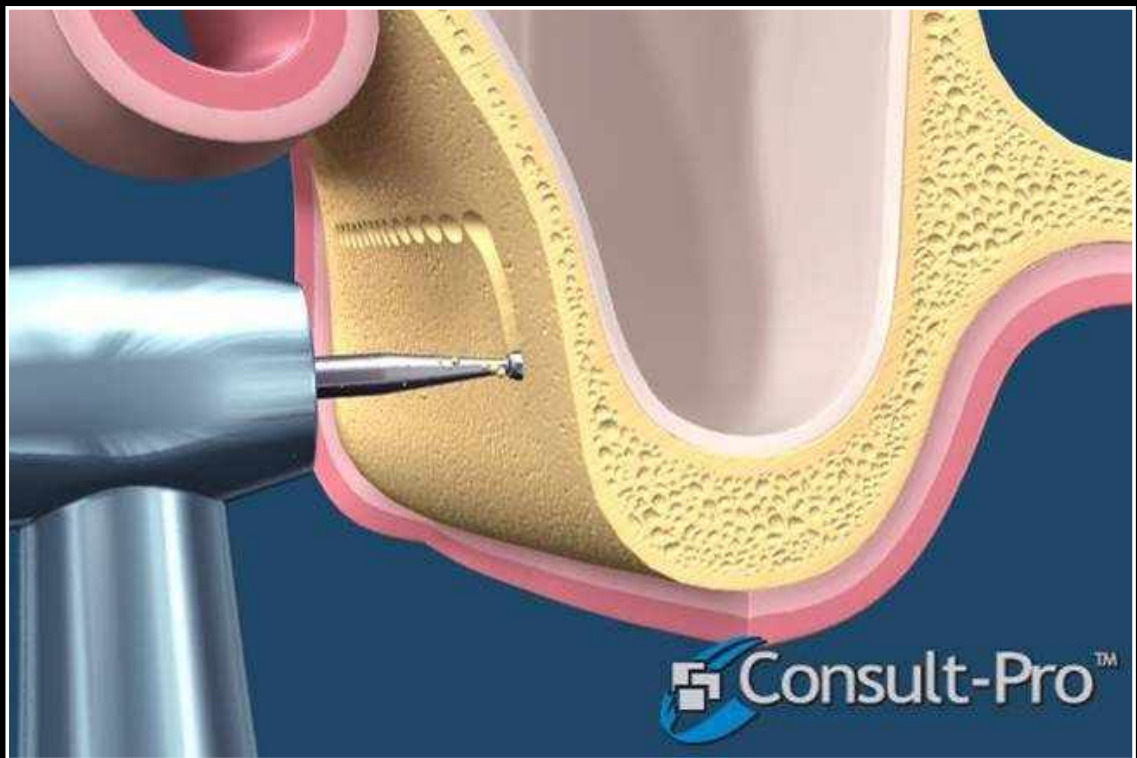
INCISION



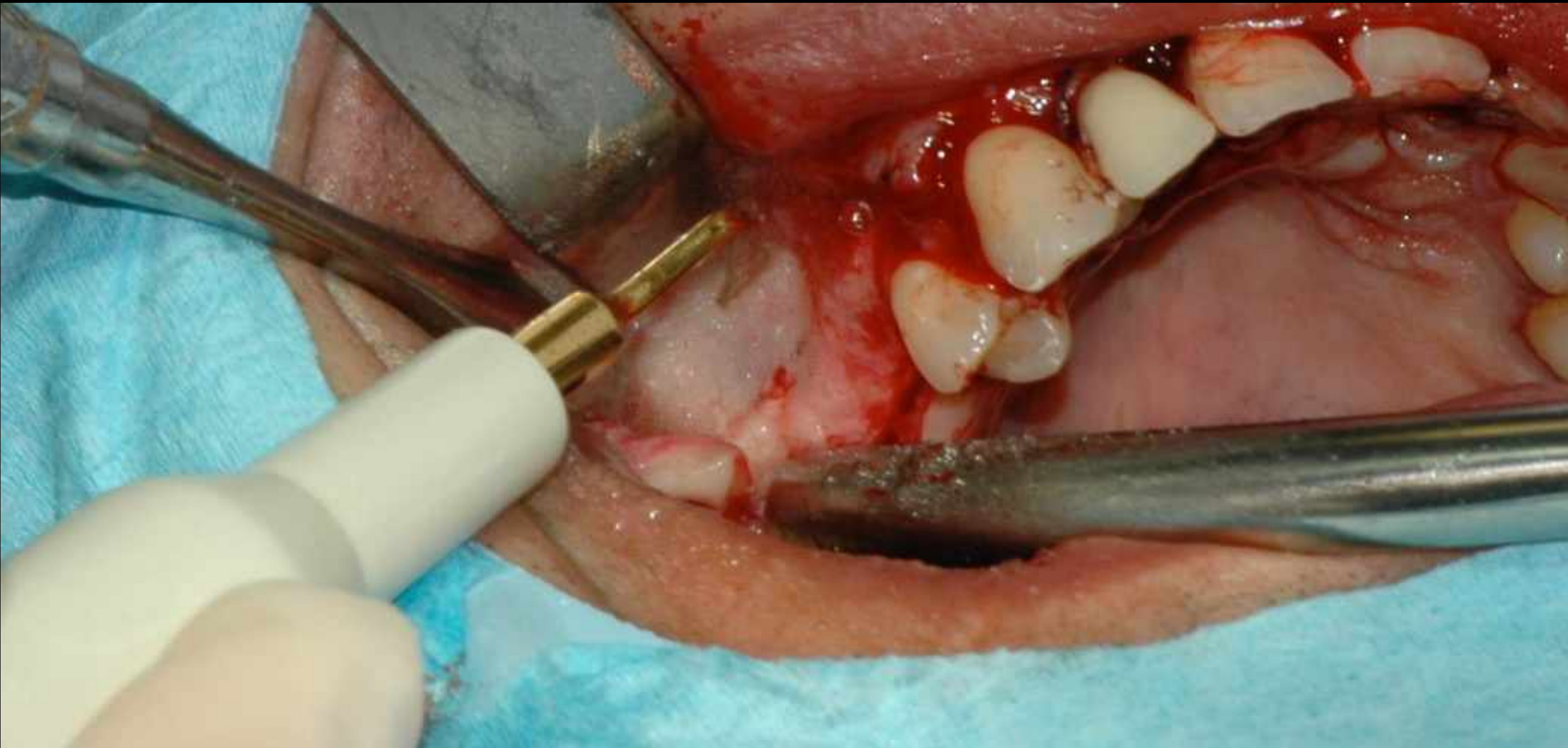
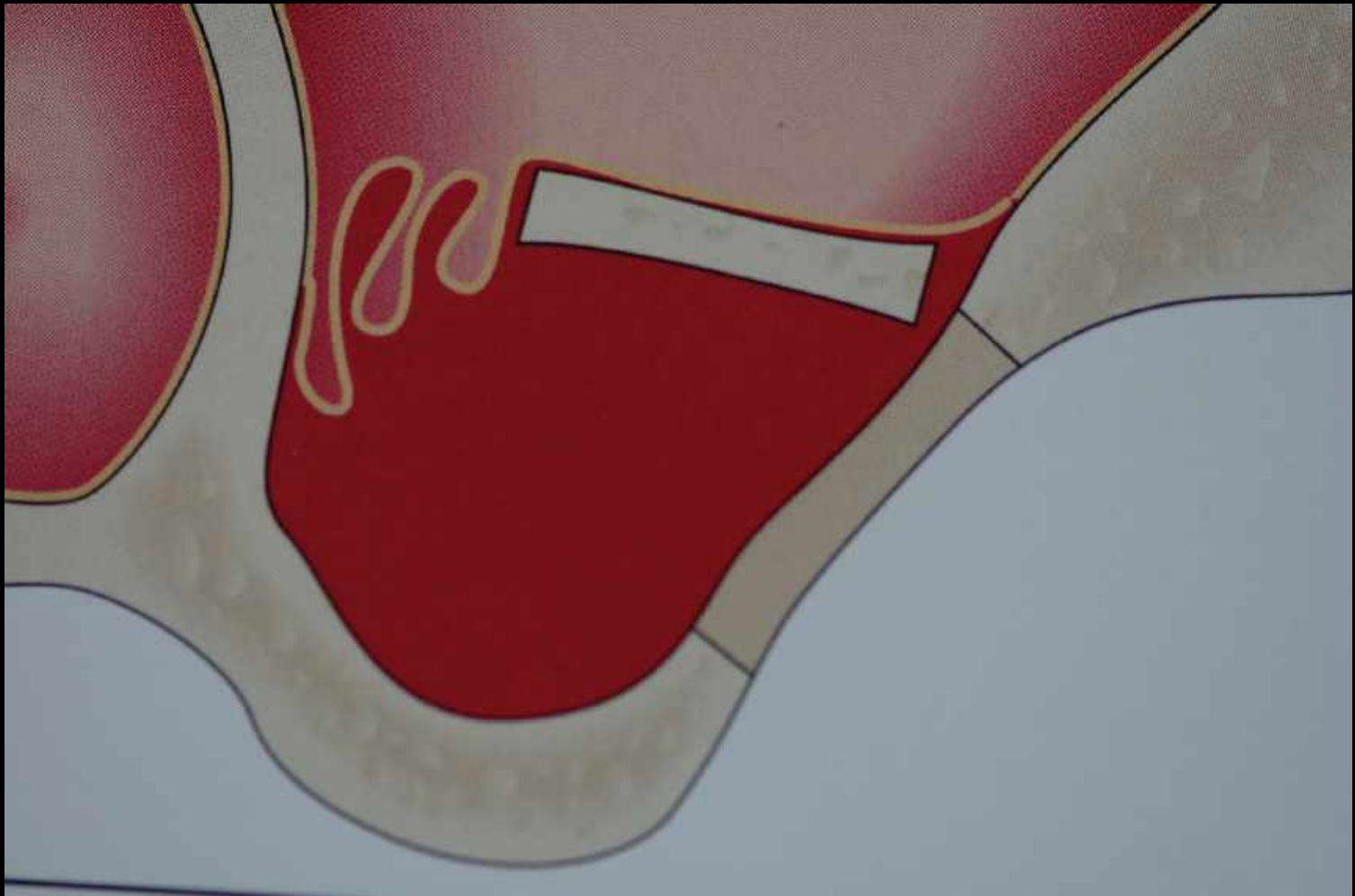
- Pleine épaisseur crestale ou décalée en palatin
- A distance du volet
- Attention si perforation après extraction
risque de communication avec la lame sur la crête
- Fraise comme un pinceau ou piezochirurgie



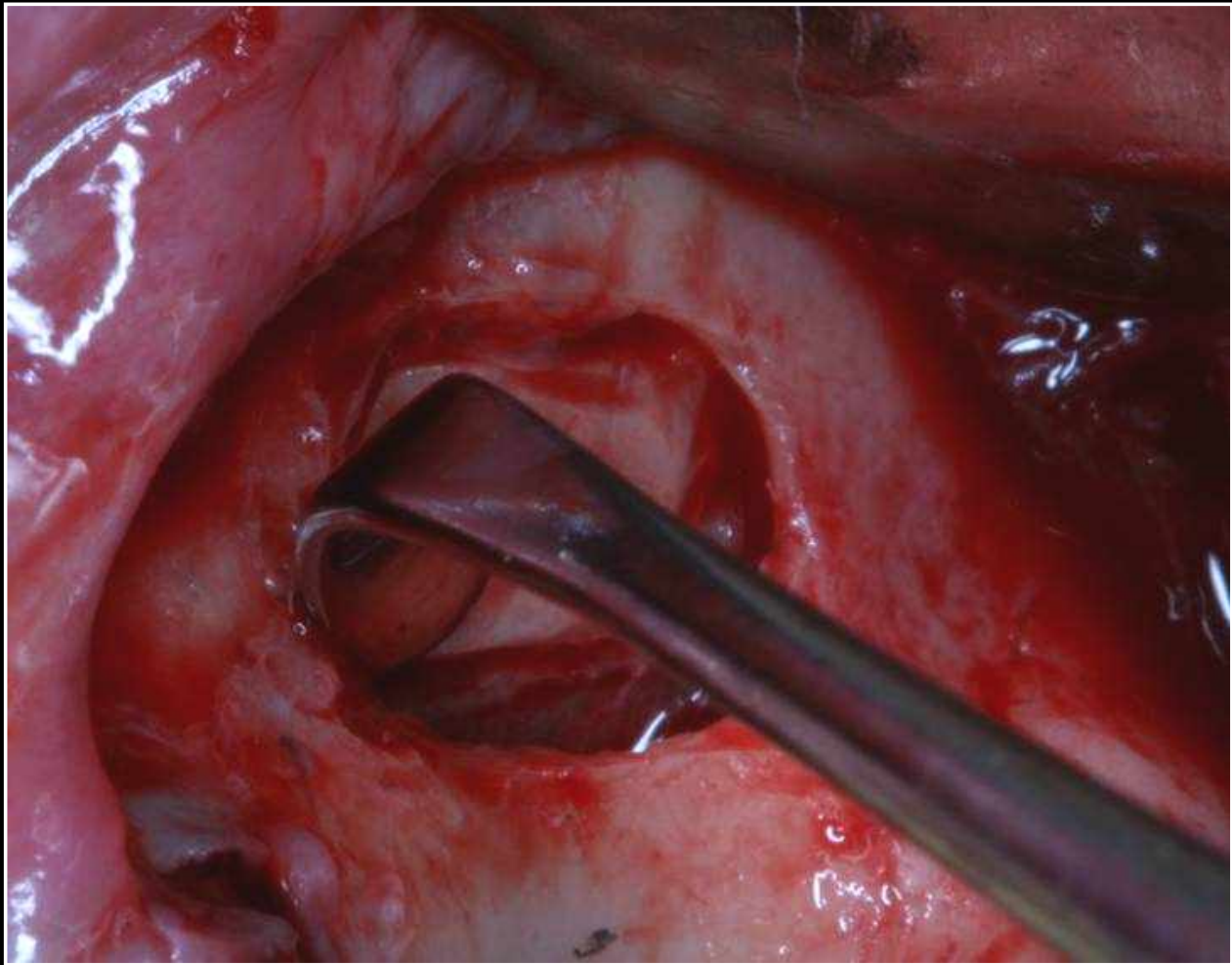
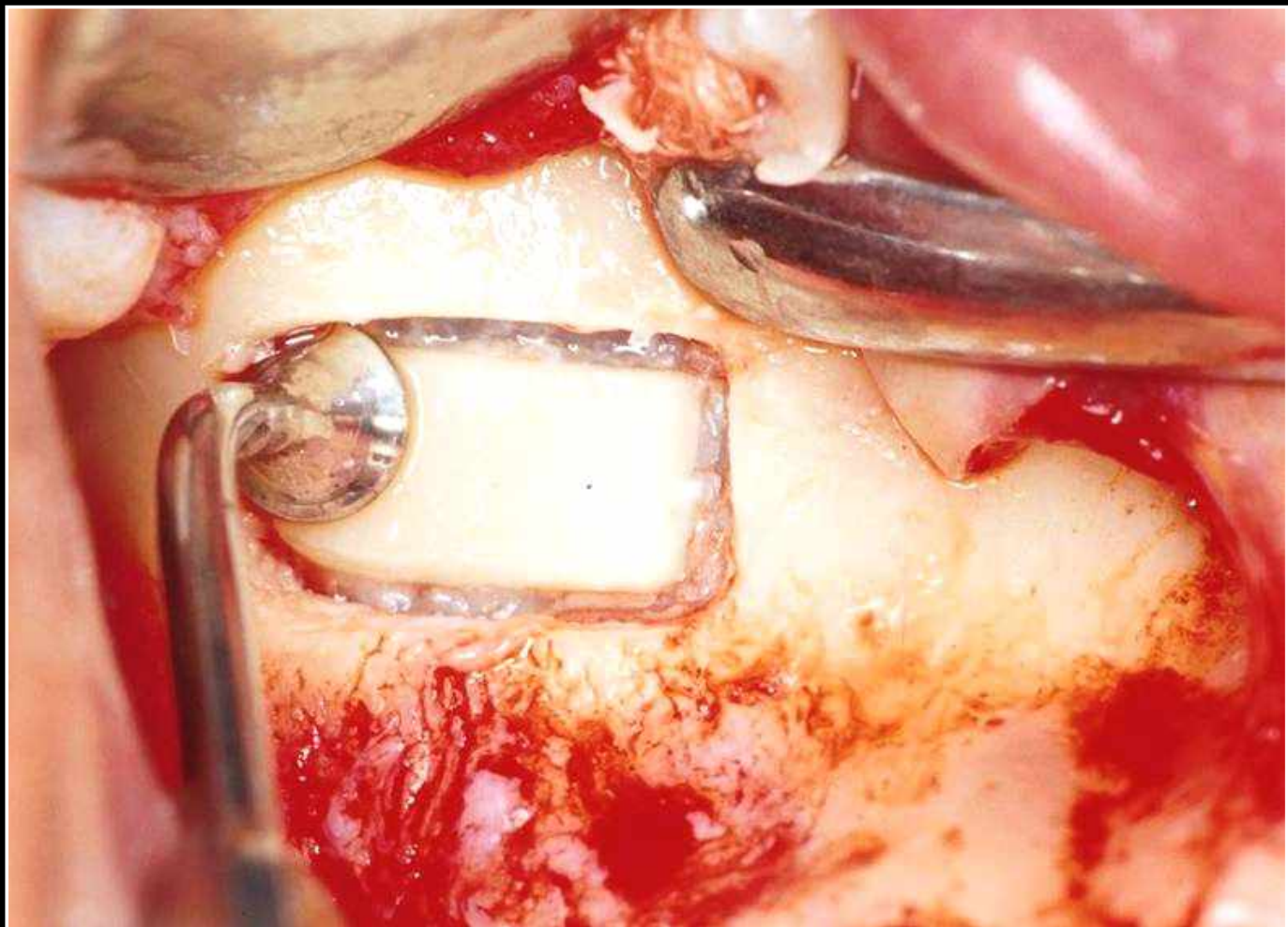
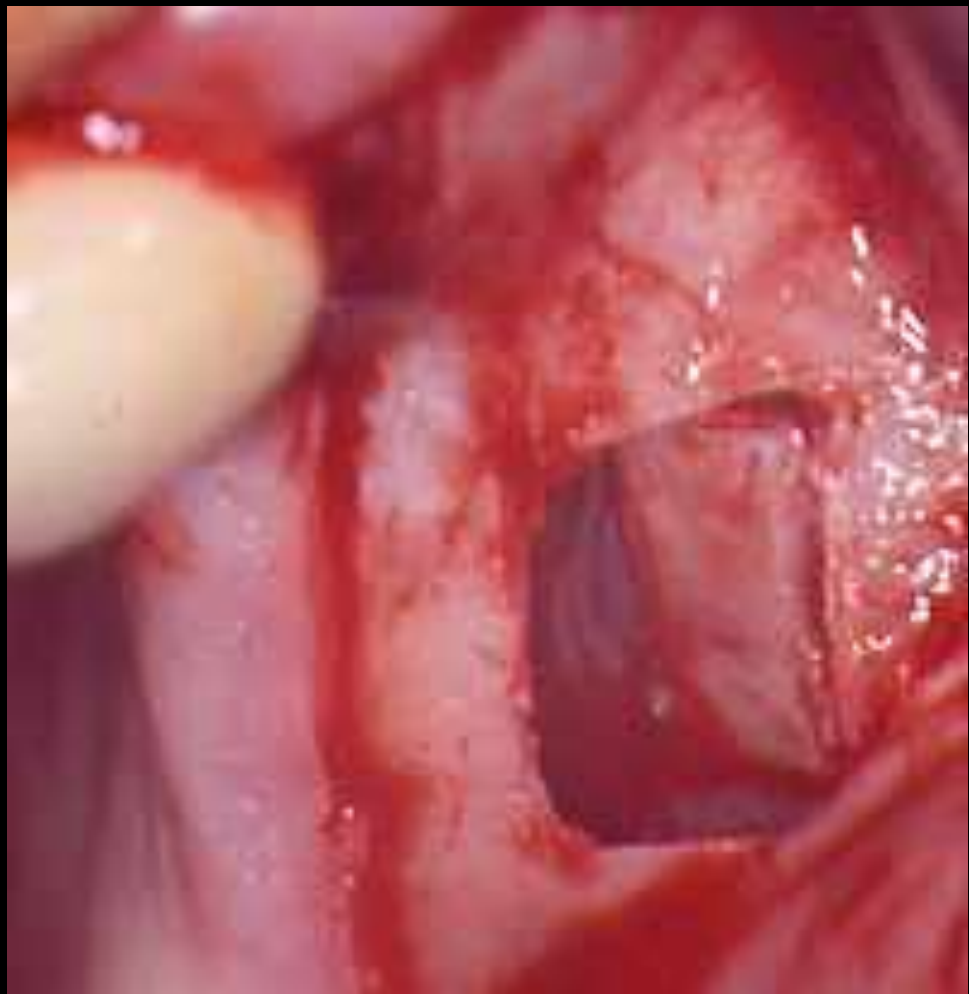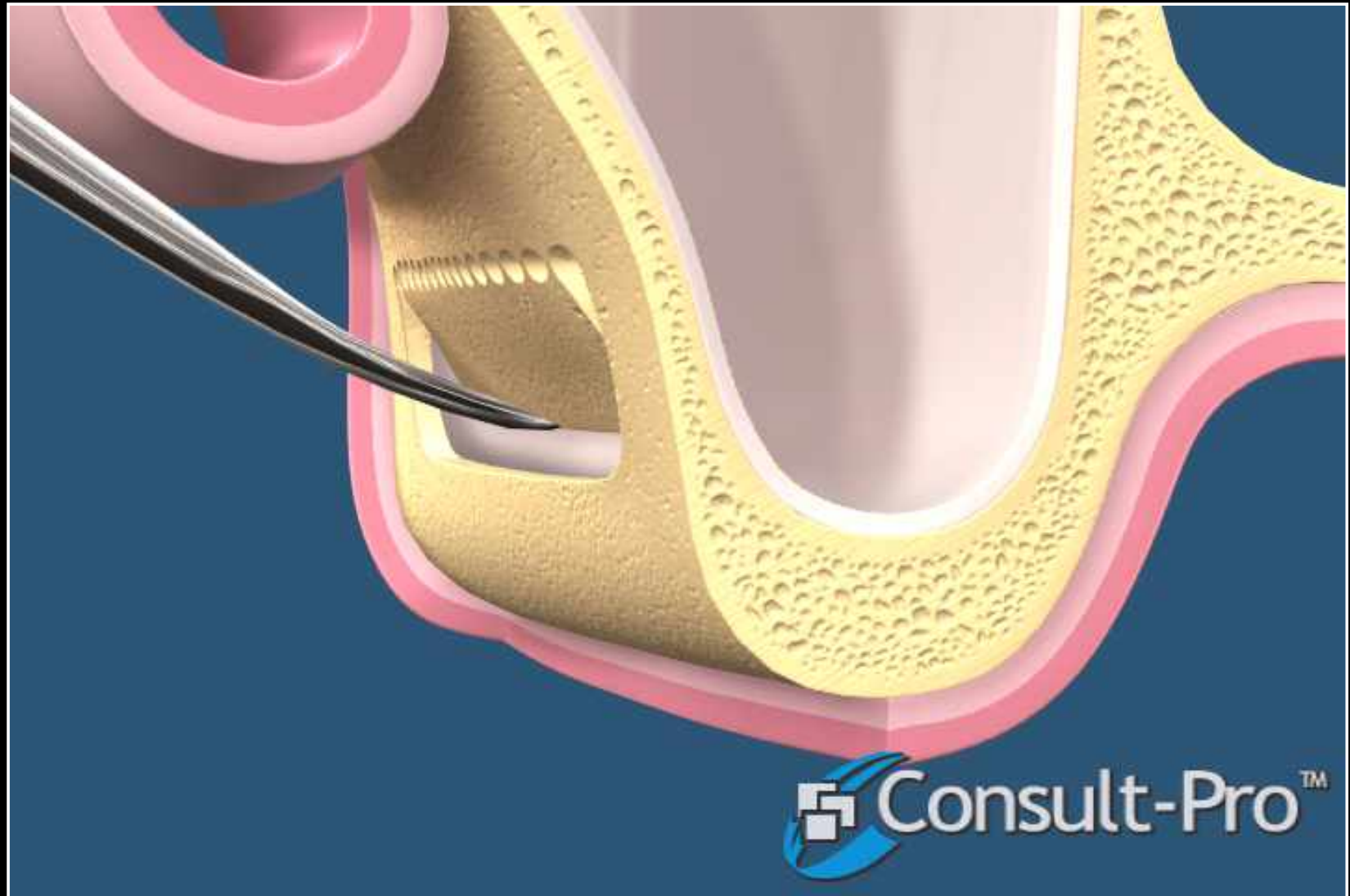
2 - GREFFE DU SINUS PAR VOILET LATERAL



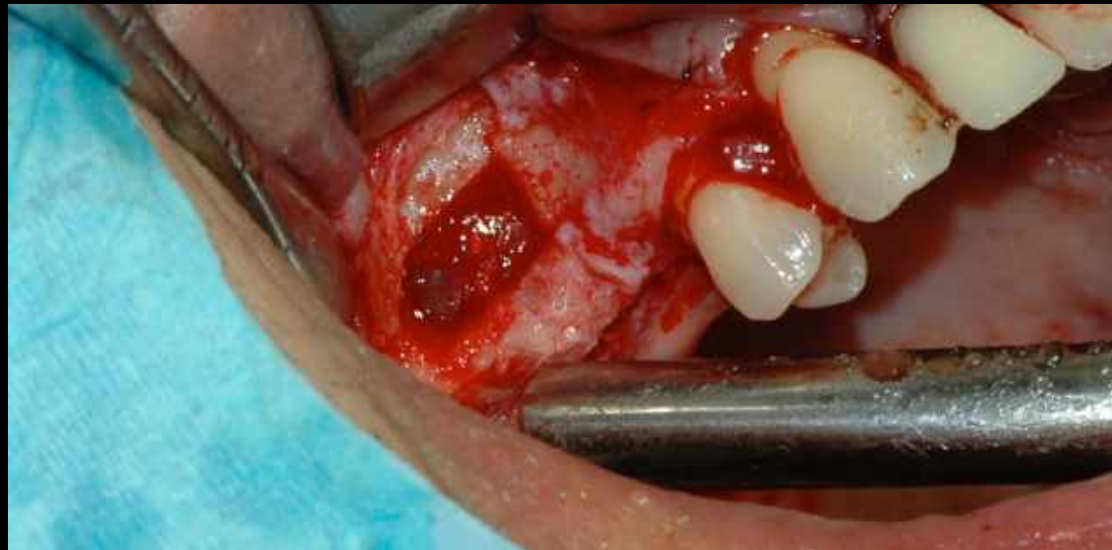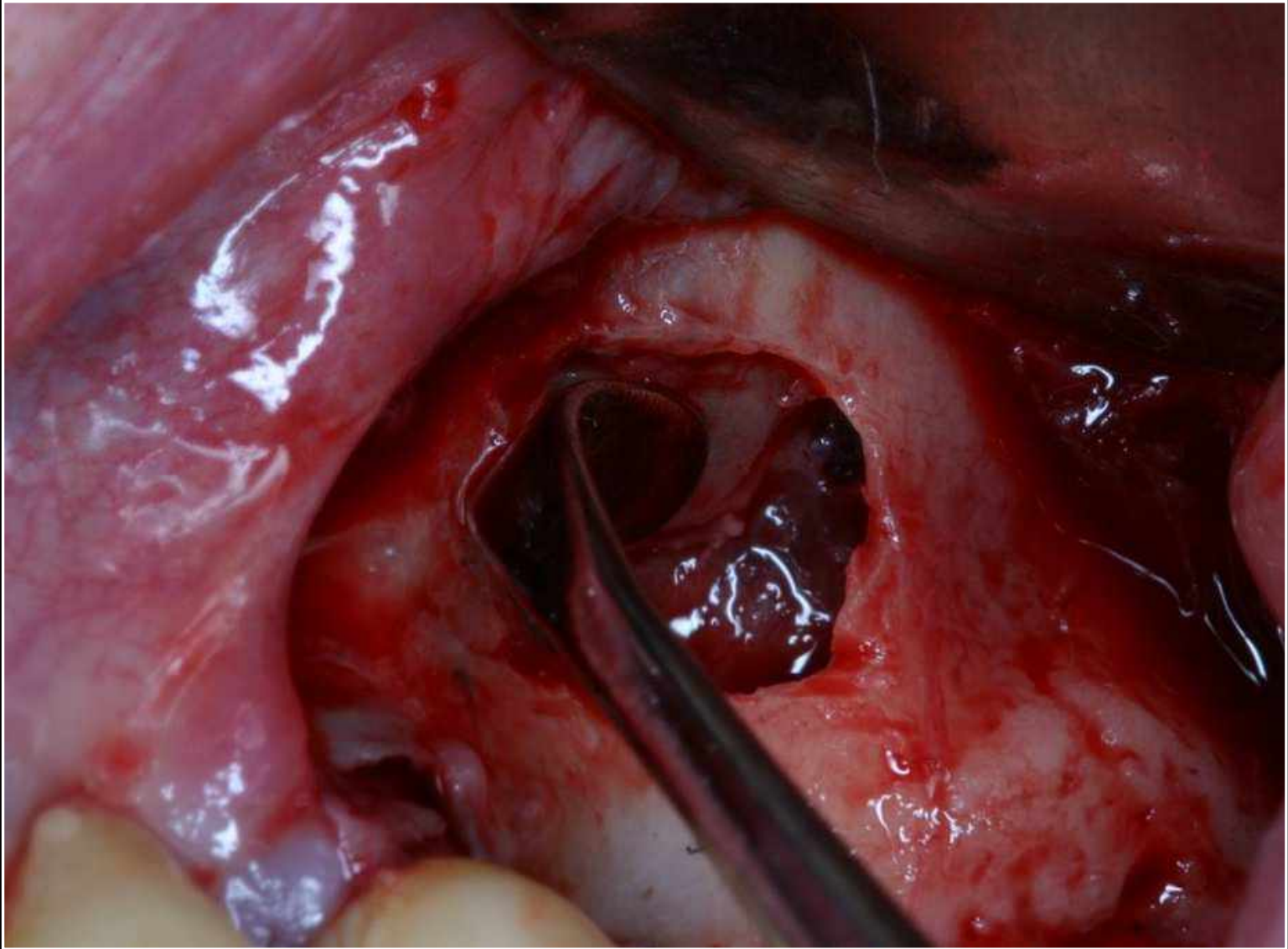
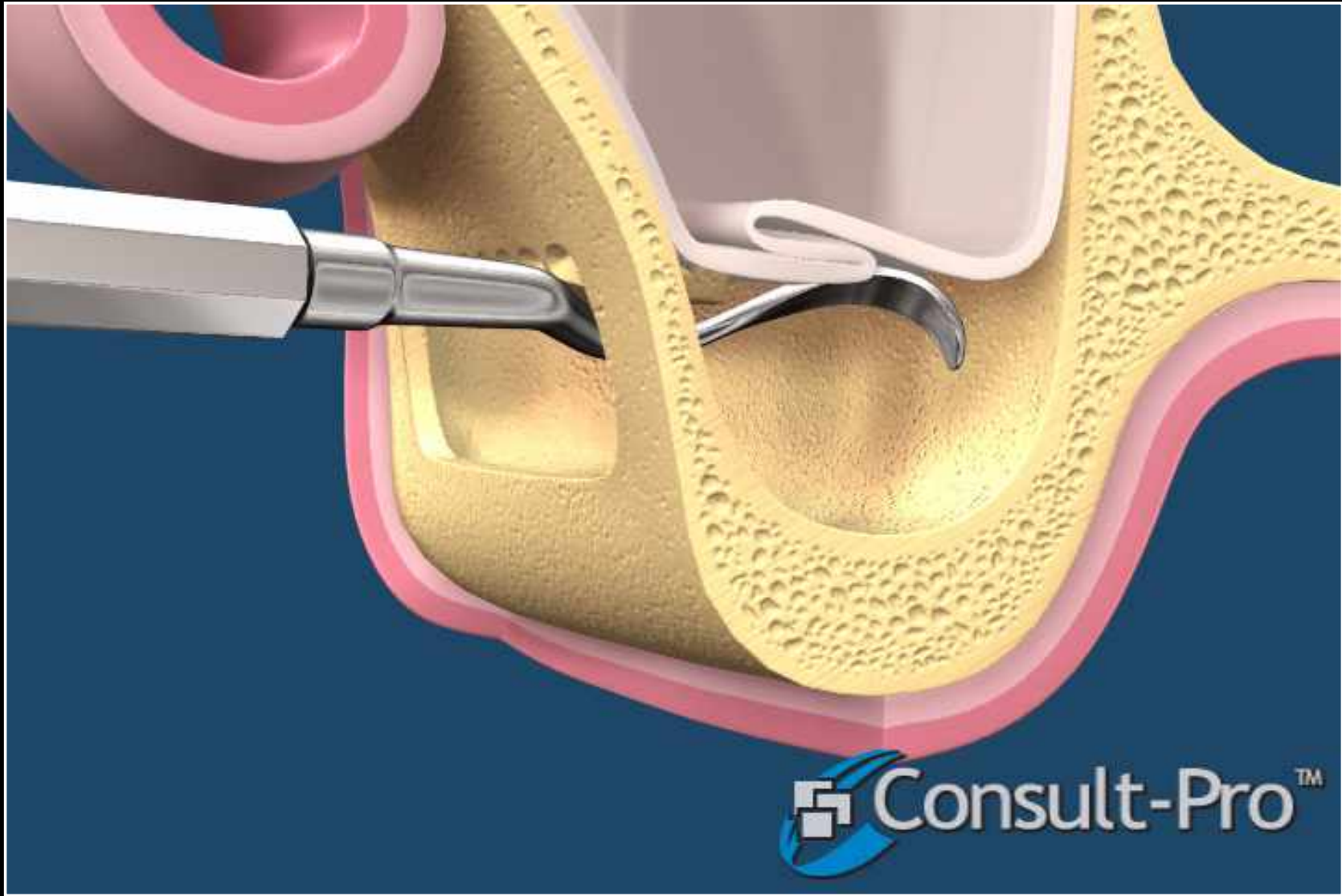
2 - GREFFE DU SINUS PAR VOILET LATERAL

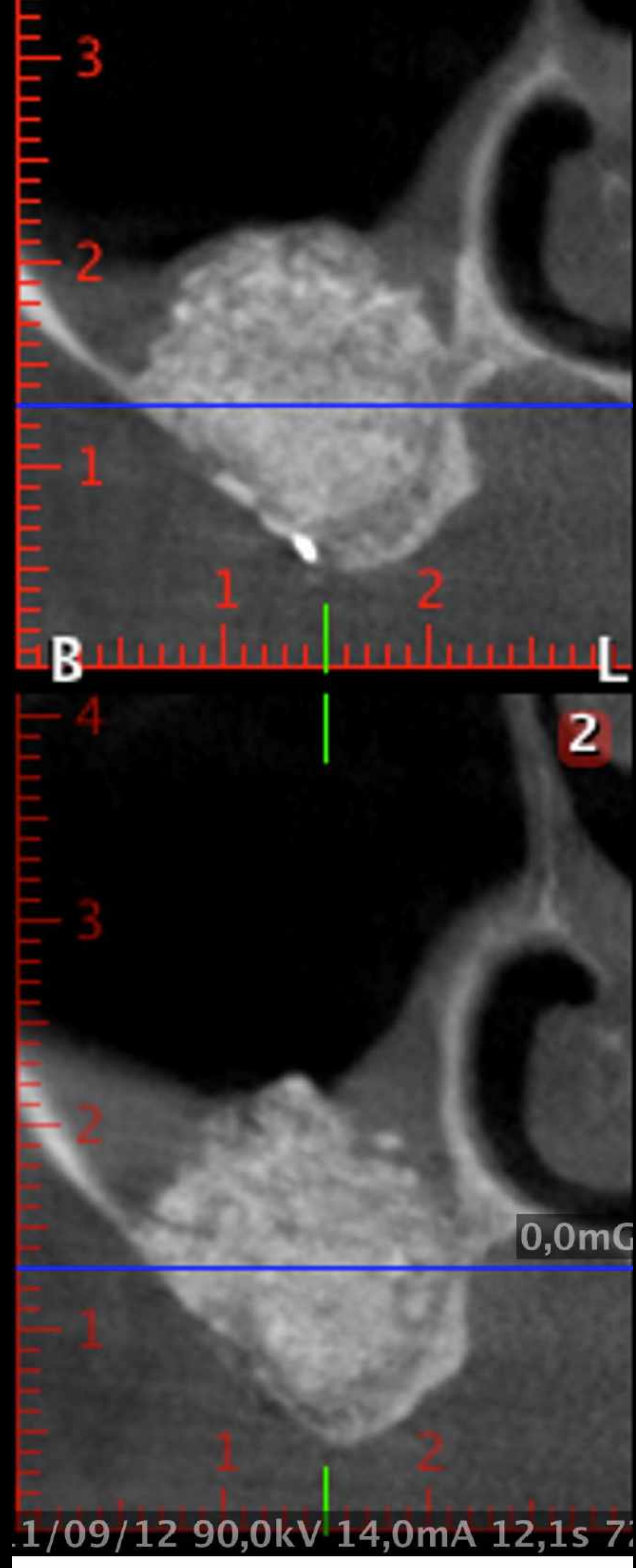
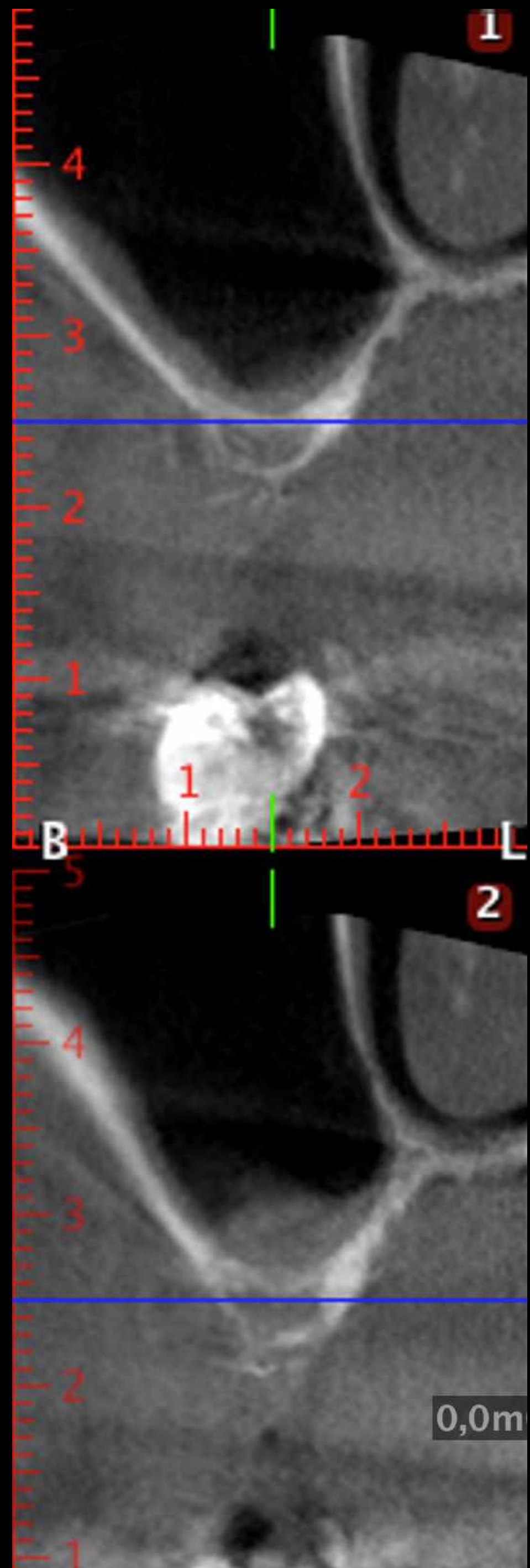


2 - GREFFE DU SINUS PAR VOILET LATERAL

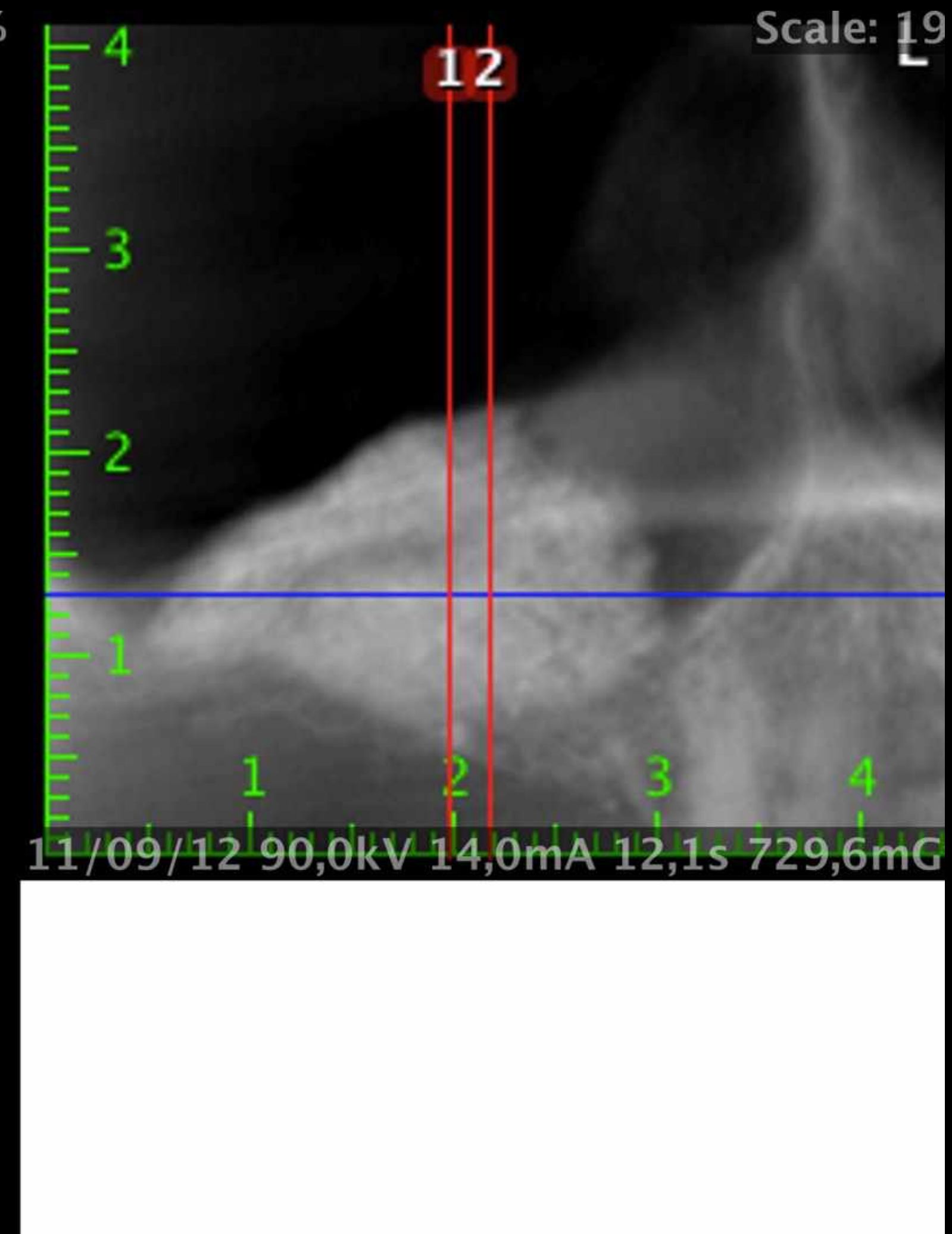
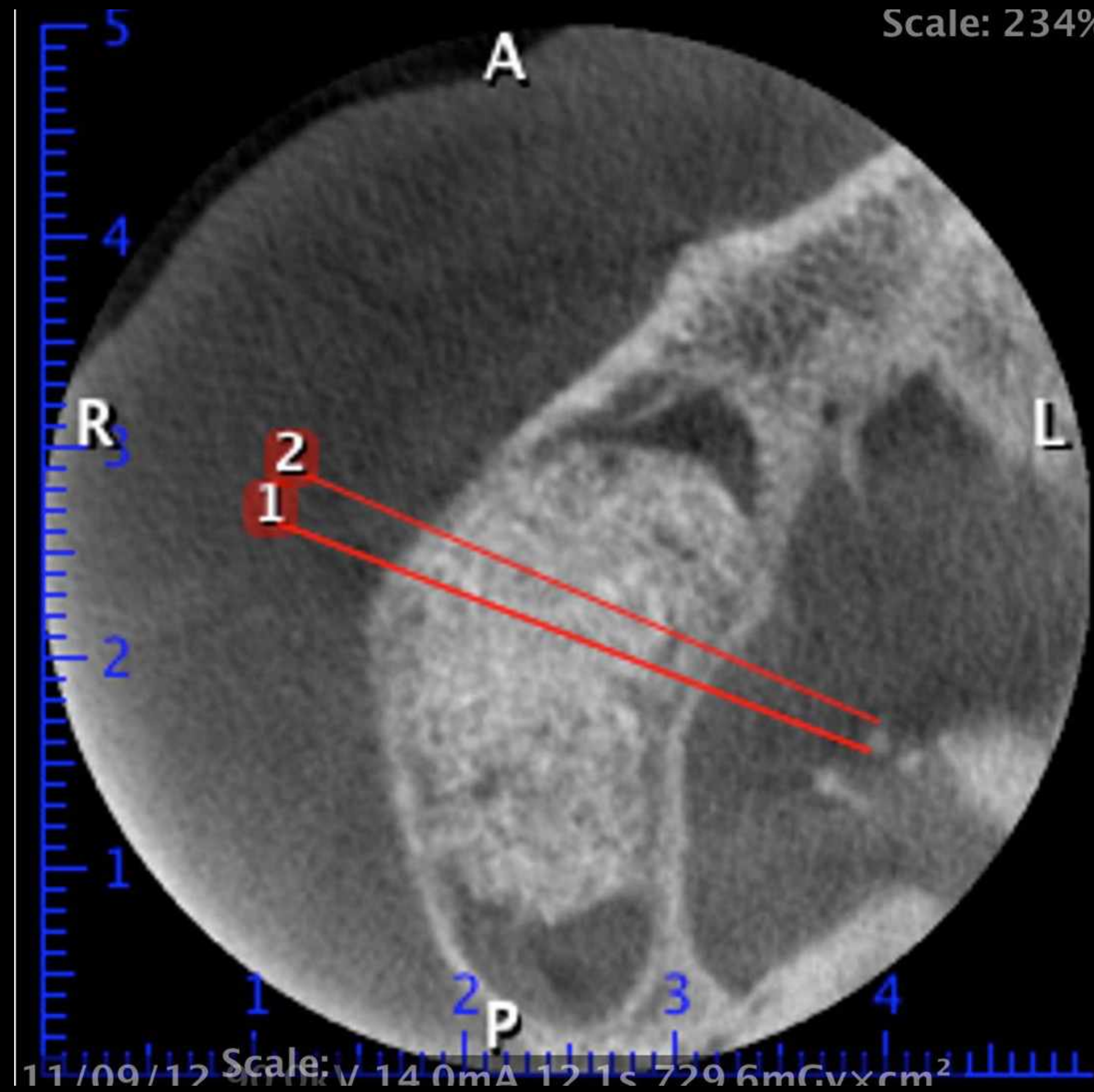


2 - GREFFE DU SINUS PAR VOILET LATERAL

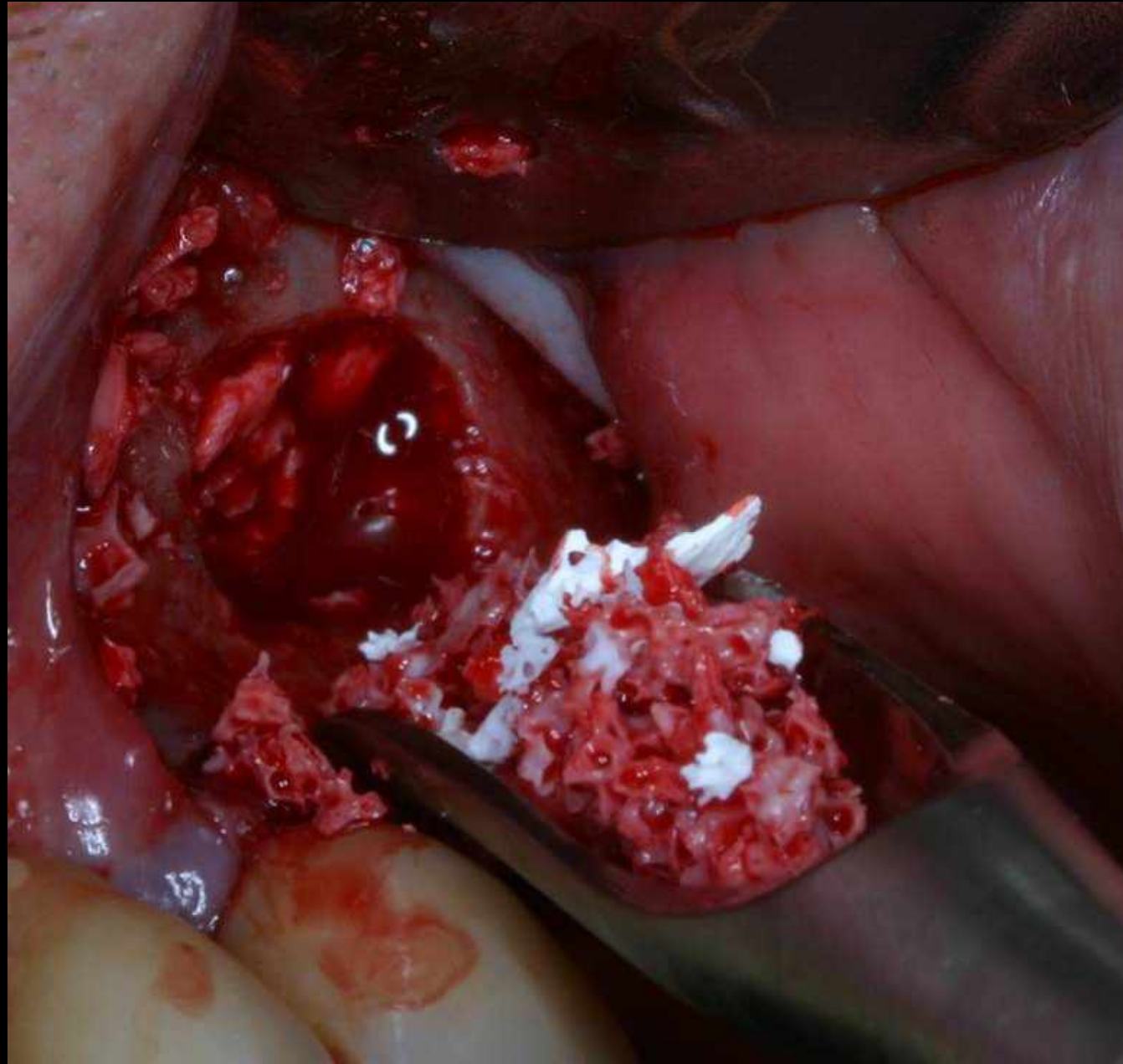
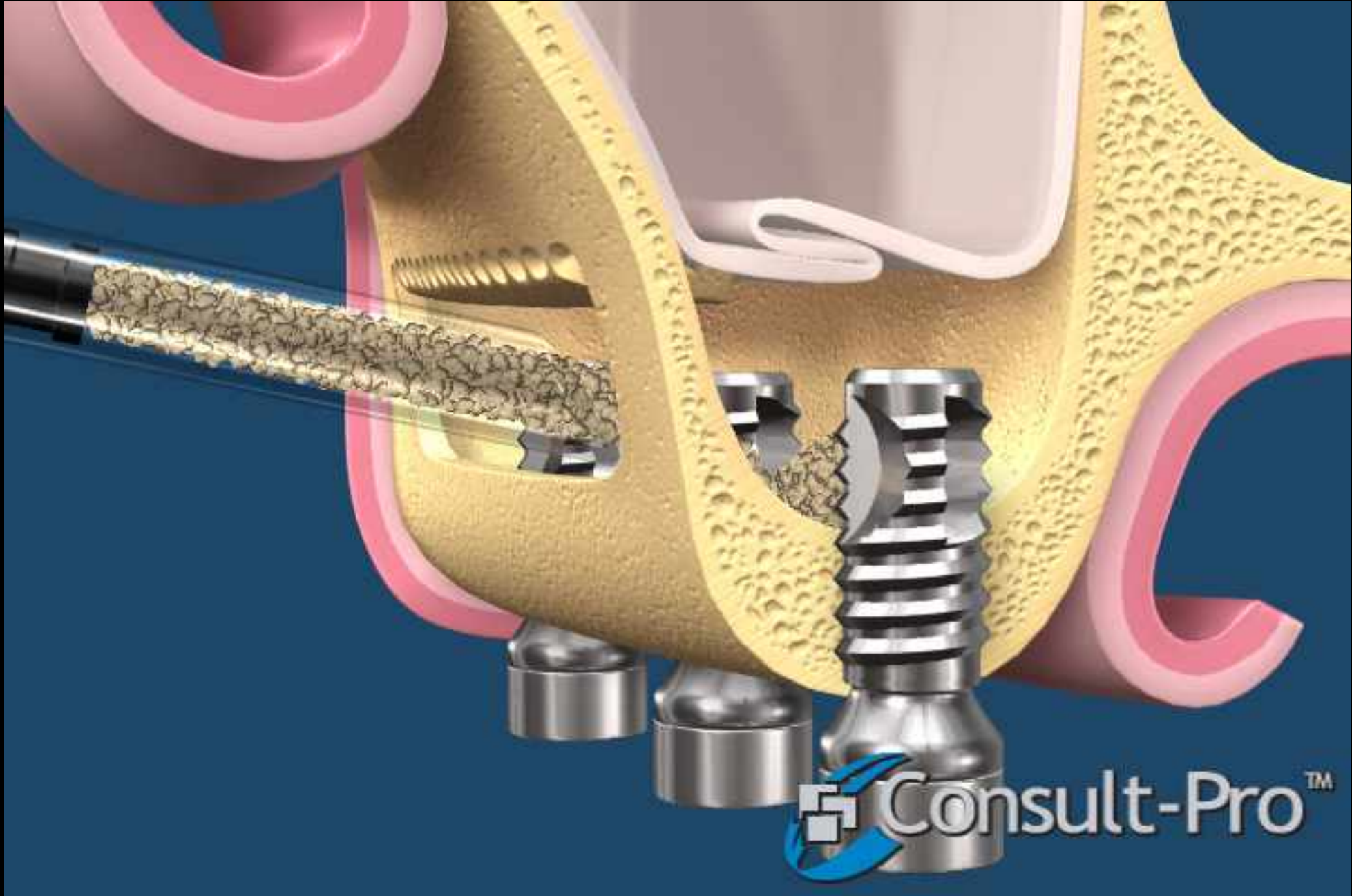




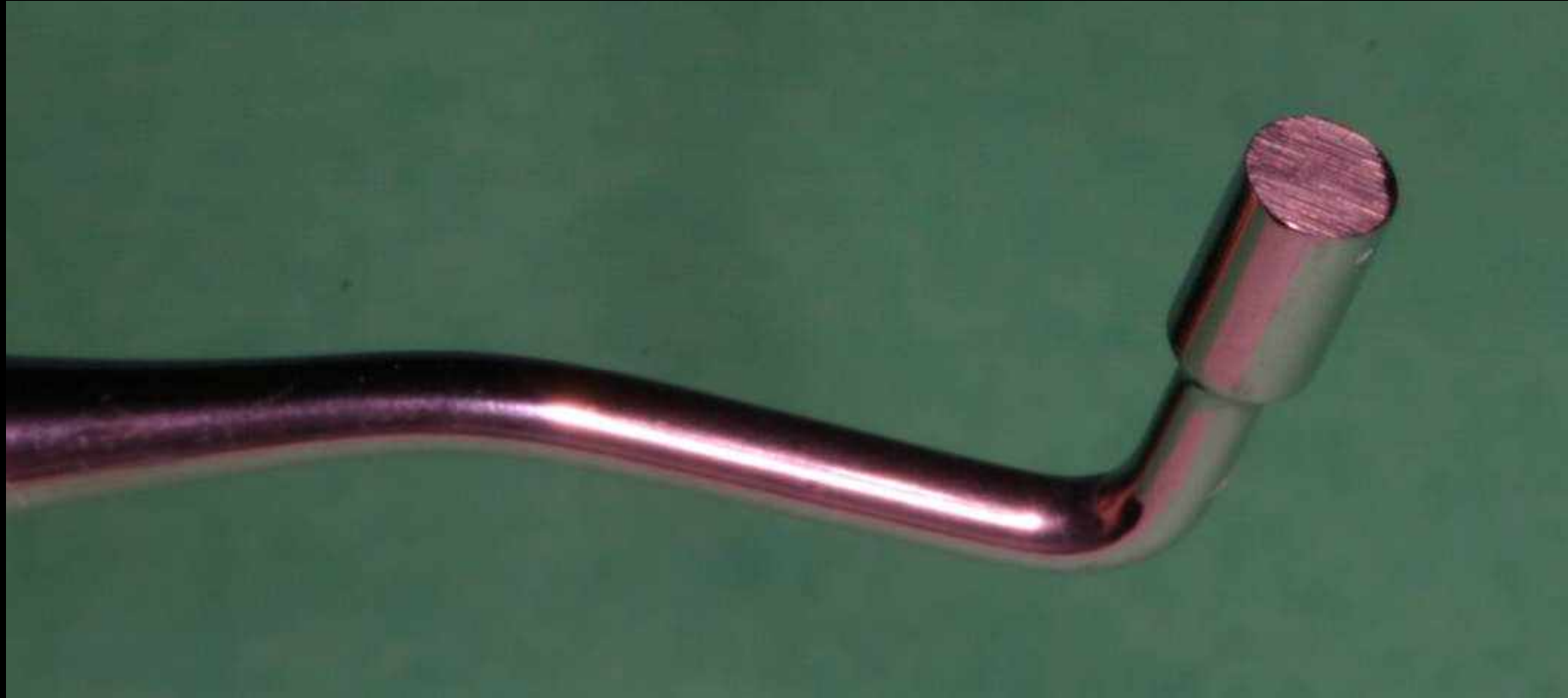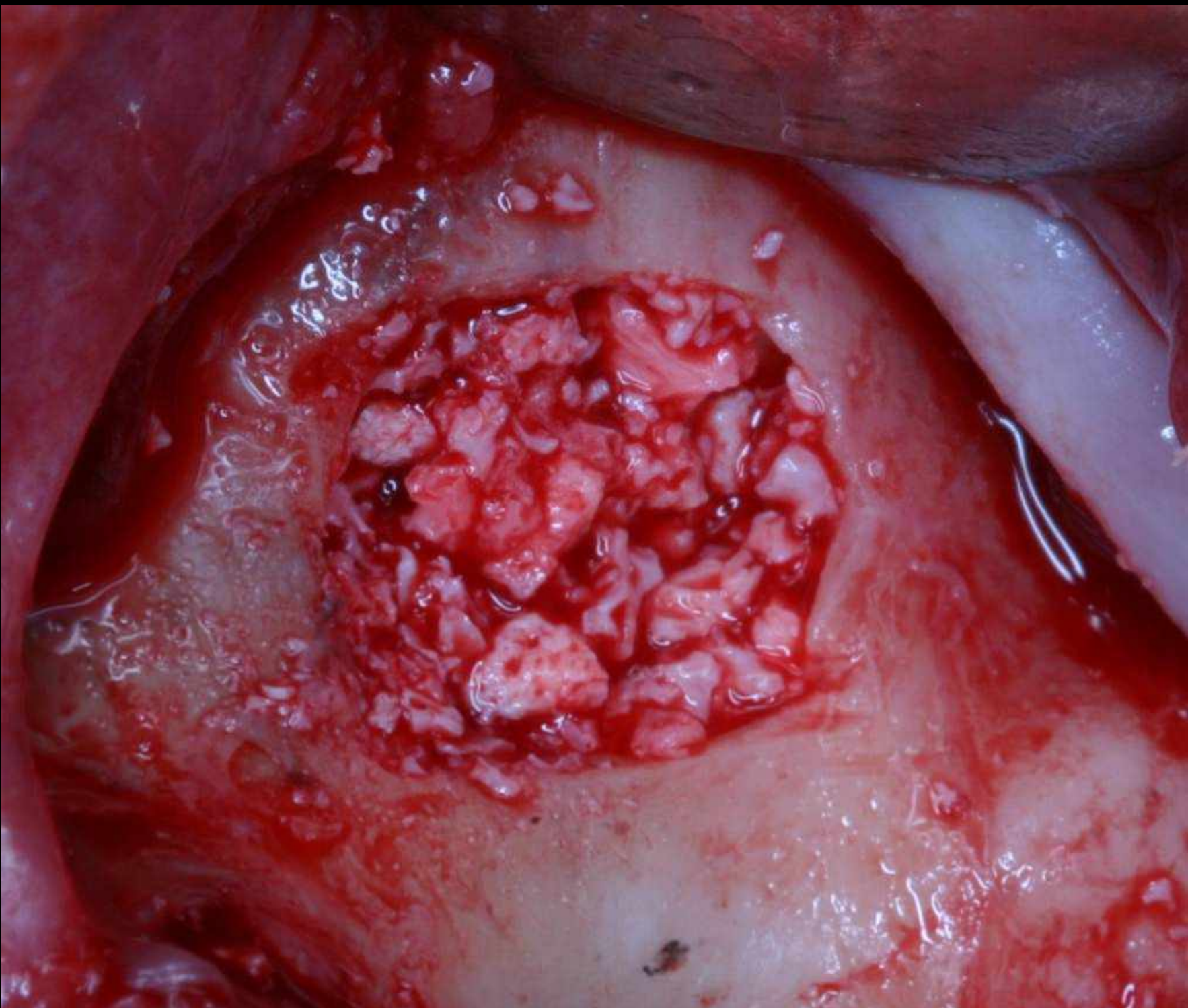
2 - GREFFE DU SINUS PAR VOILE LATERAL



2 - GREFFE DU SINUS PAR VOILET LATERAL

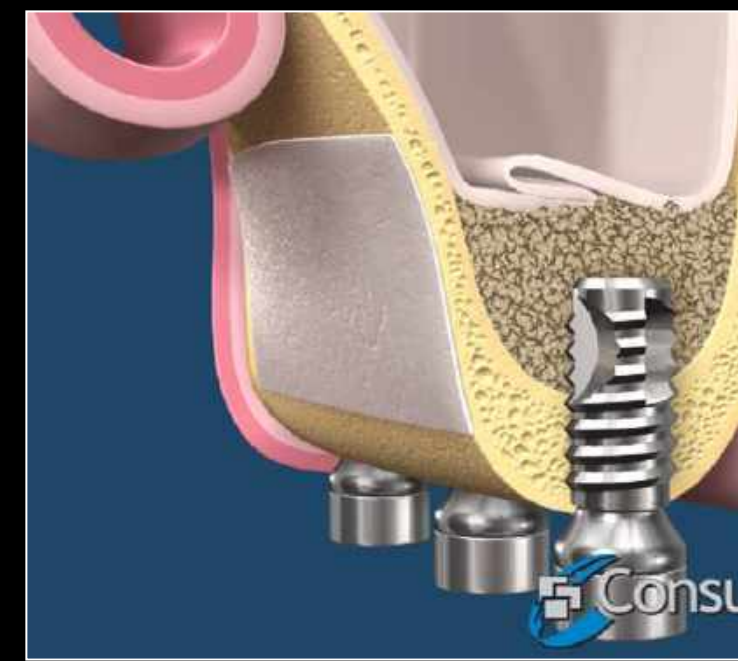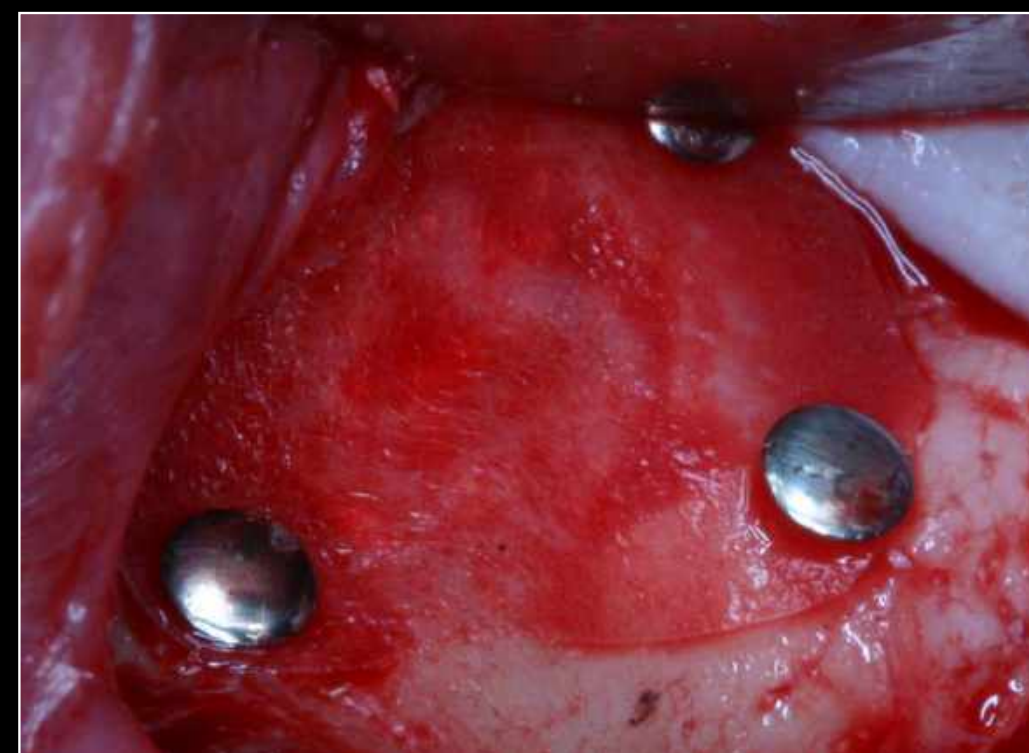

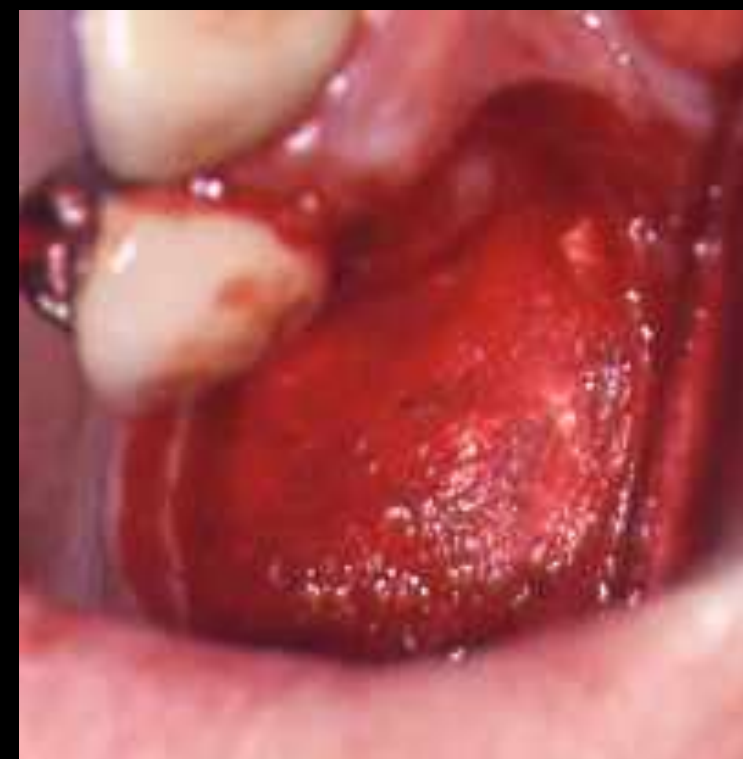
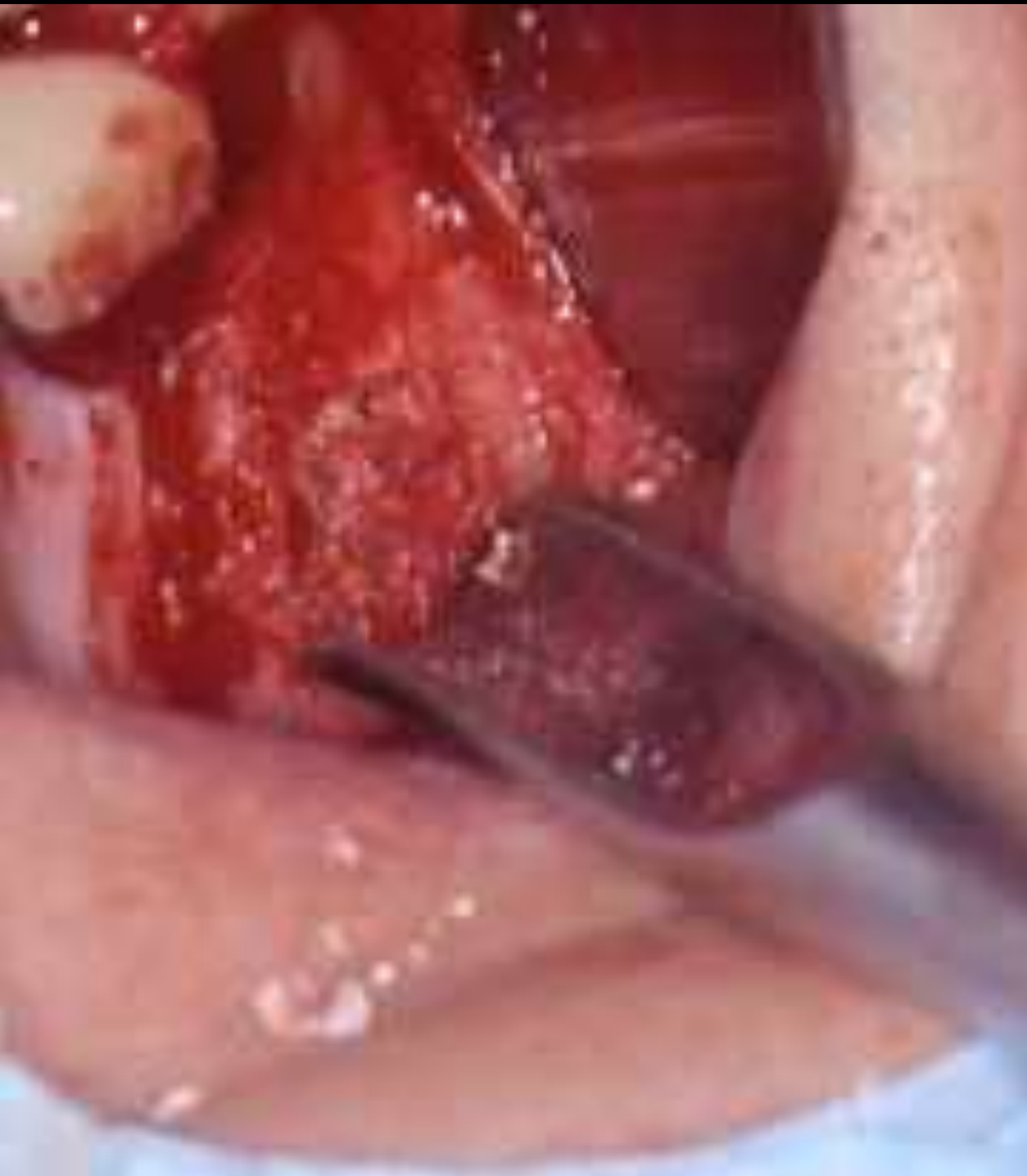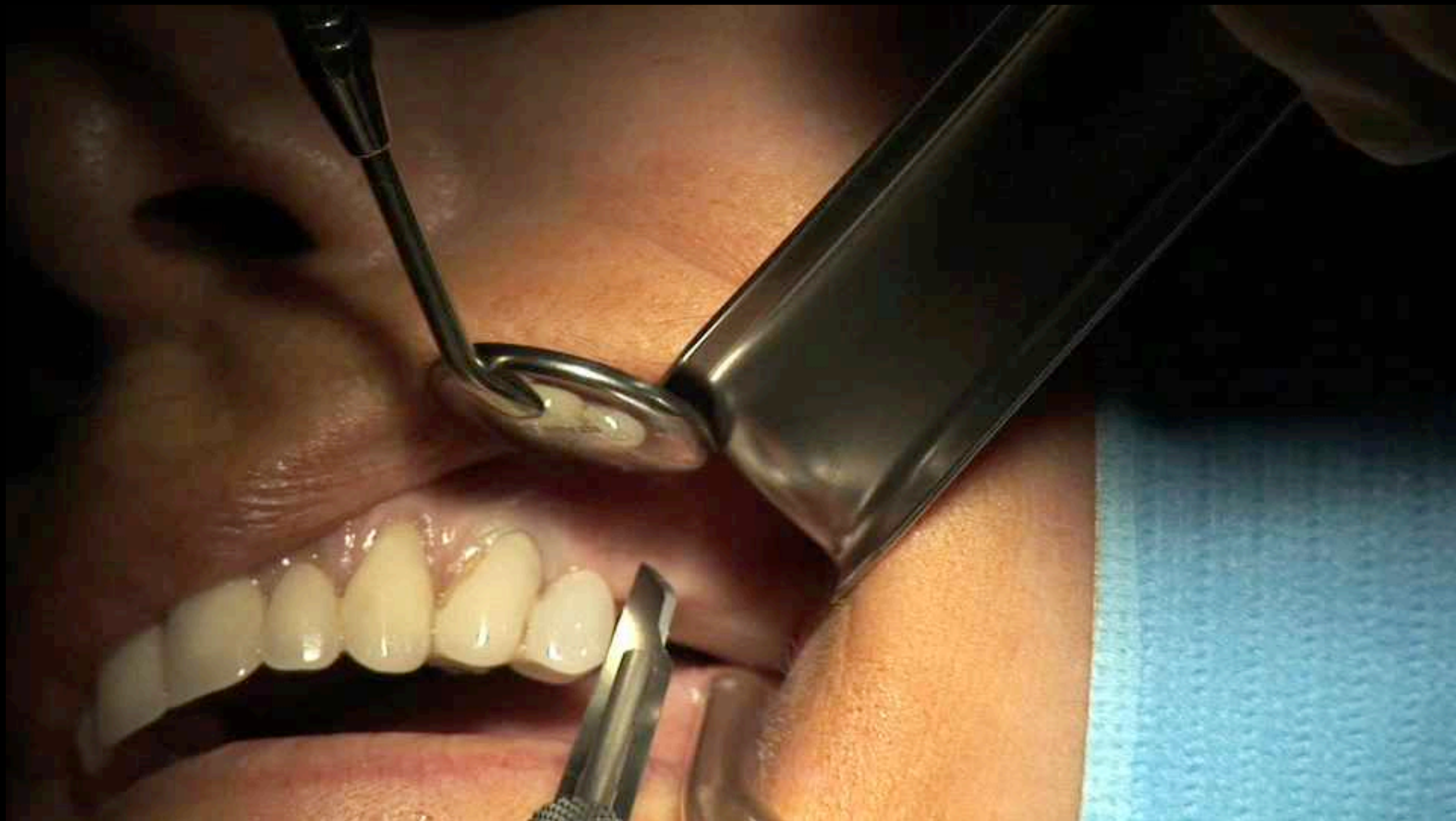2 - GREFFE DU SINUS PAR VOILET LATERAL



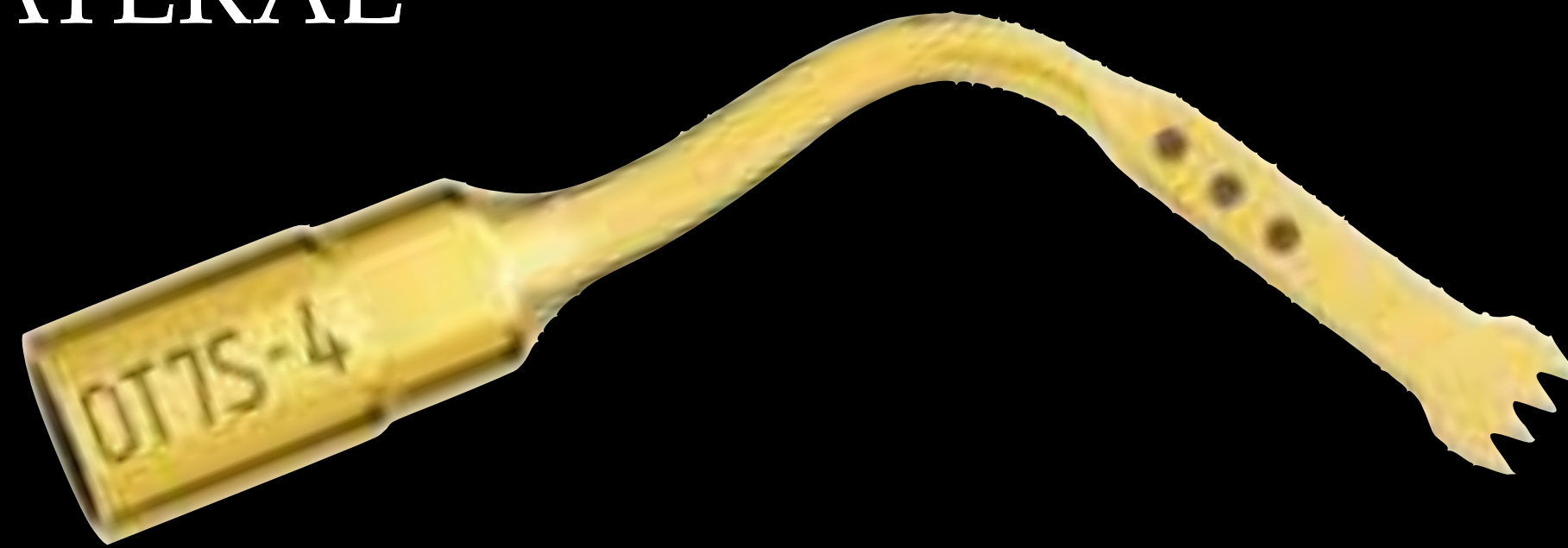2 - GREFFE DU SINUS PAR VOILET LATERAL

- on amène en moyenne un volume de 5 à 6 ml
- la pression de l'air dans le sinus peut comprimer la xenogreffe
- pas d'affection du fonctionnement sinusien et de sa physiologie





2 - GREFFE DU SINUS PAR VOILET LATERAL



Etude sur 13 patients avec greffe bilatérale

-Temps nécessaire pour l'ostéotomie:

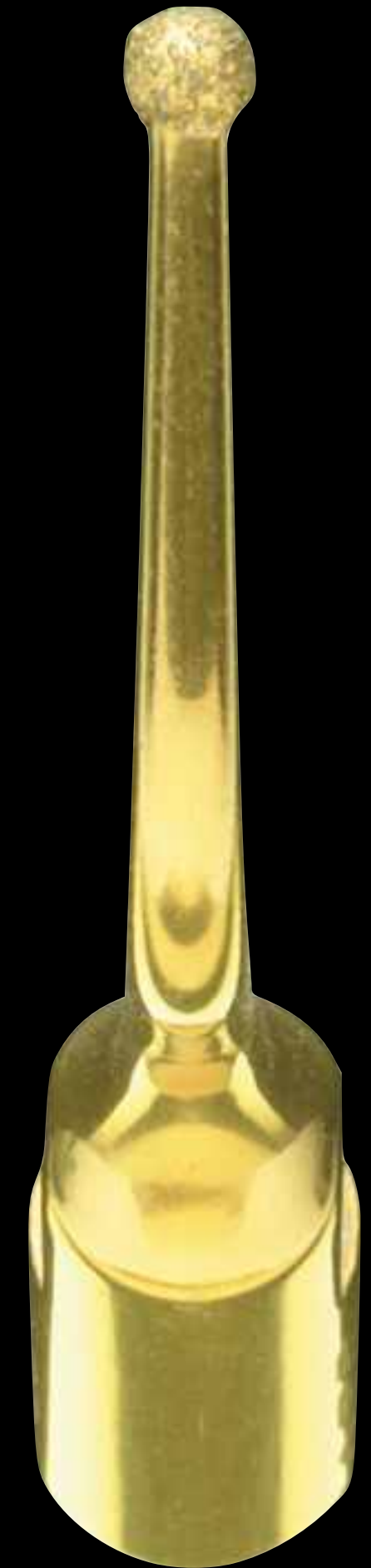-12,6min

-15,3min

-Perforation de la membrane dans

-30% des cas

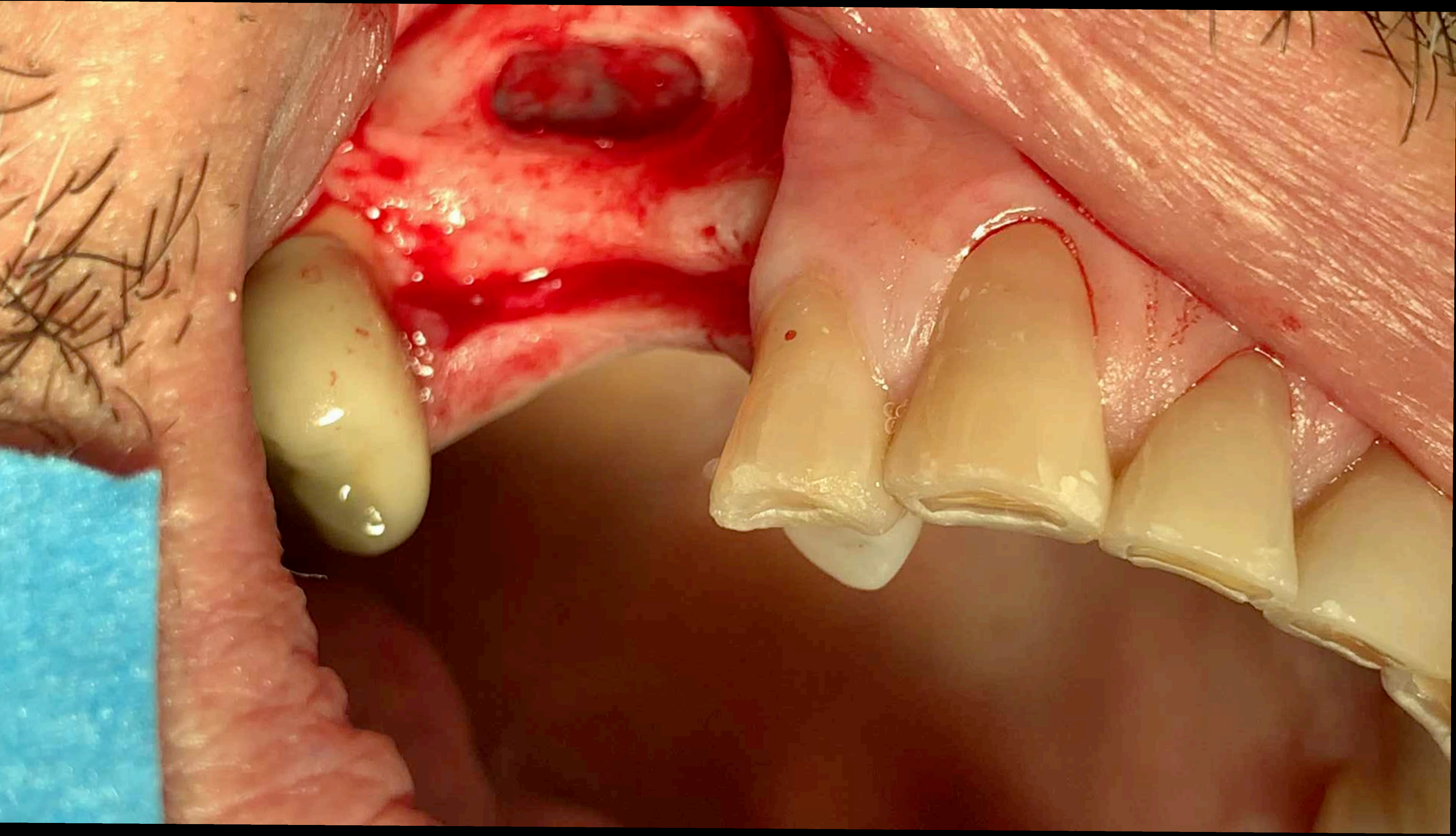
-23% des cas



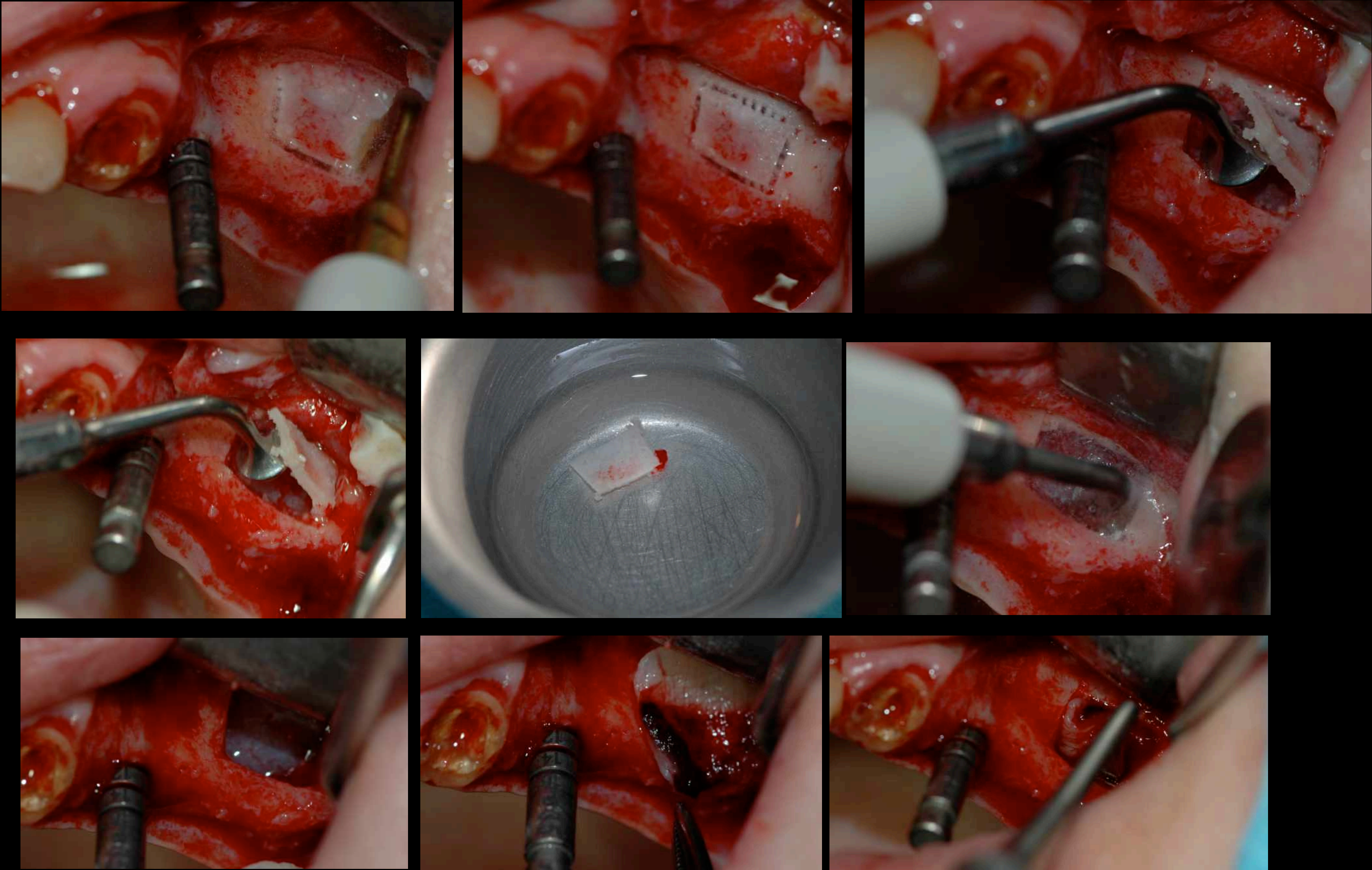
Clinical oral implants research 19;2008:511-515 Osteotomy and membrane elevation during the maxillary sinus augmentation procedure.

A.Barane,S.Santini,S.Marconcini

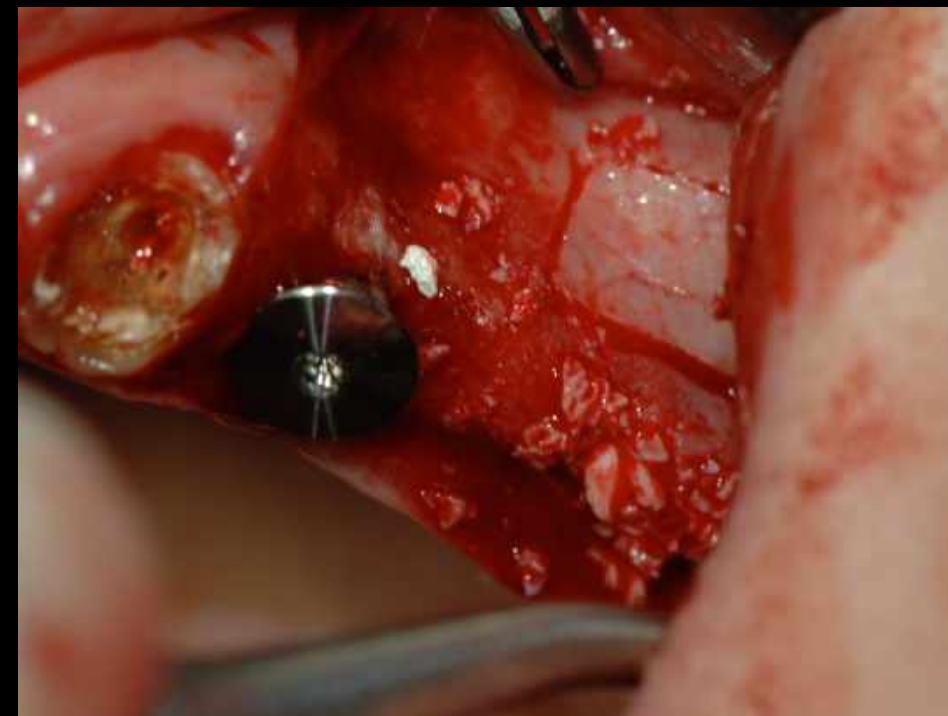
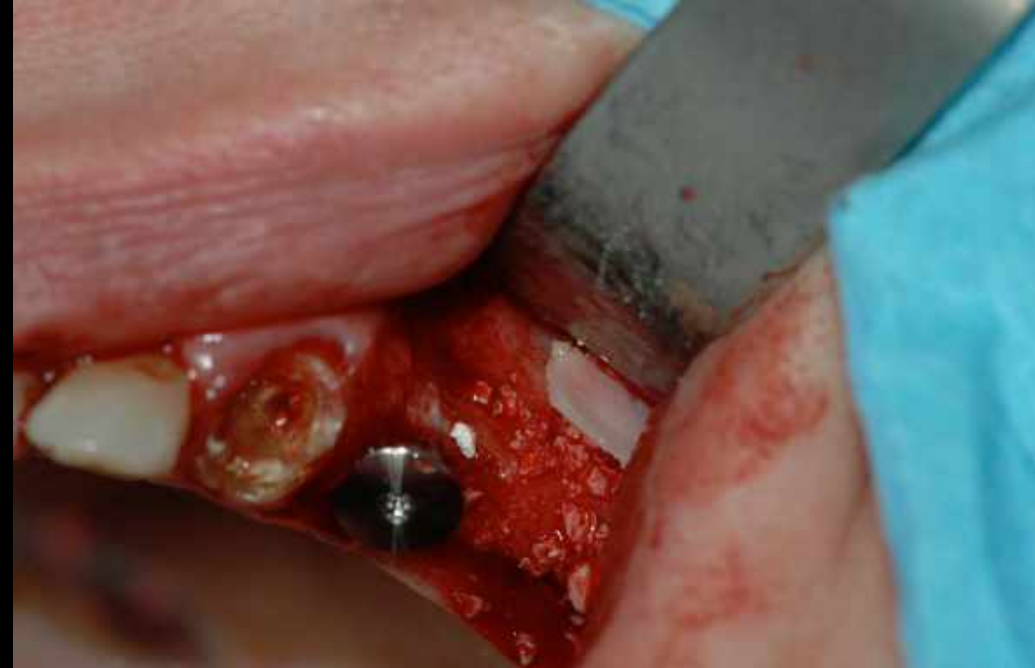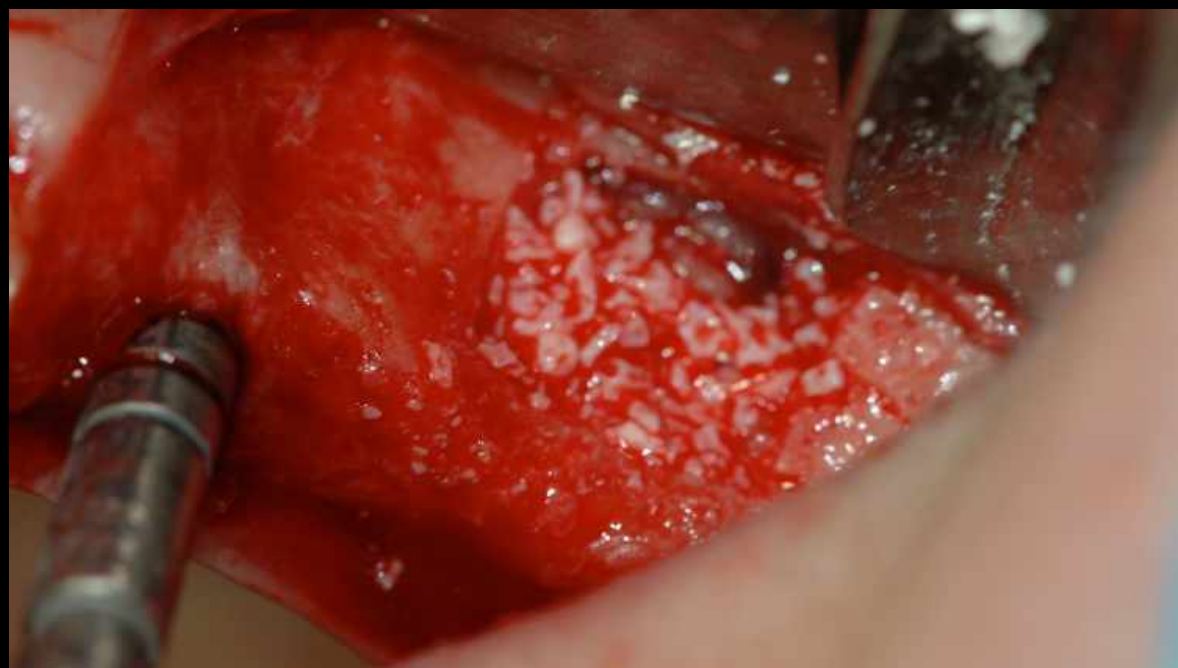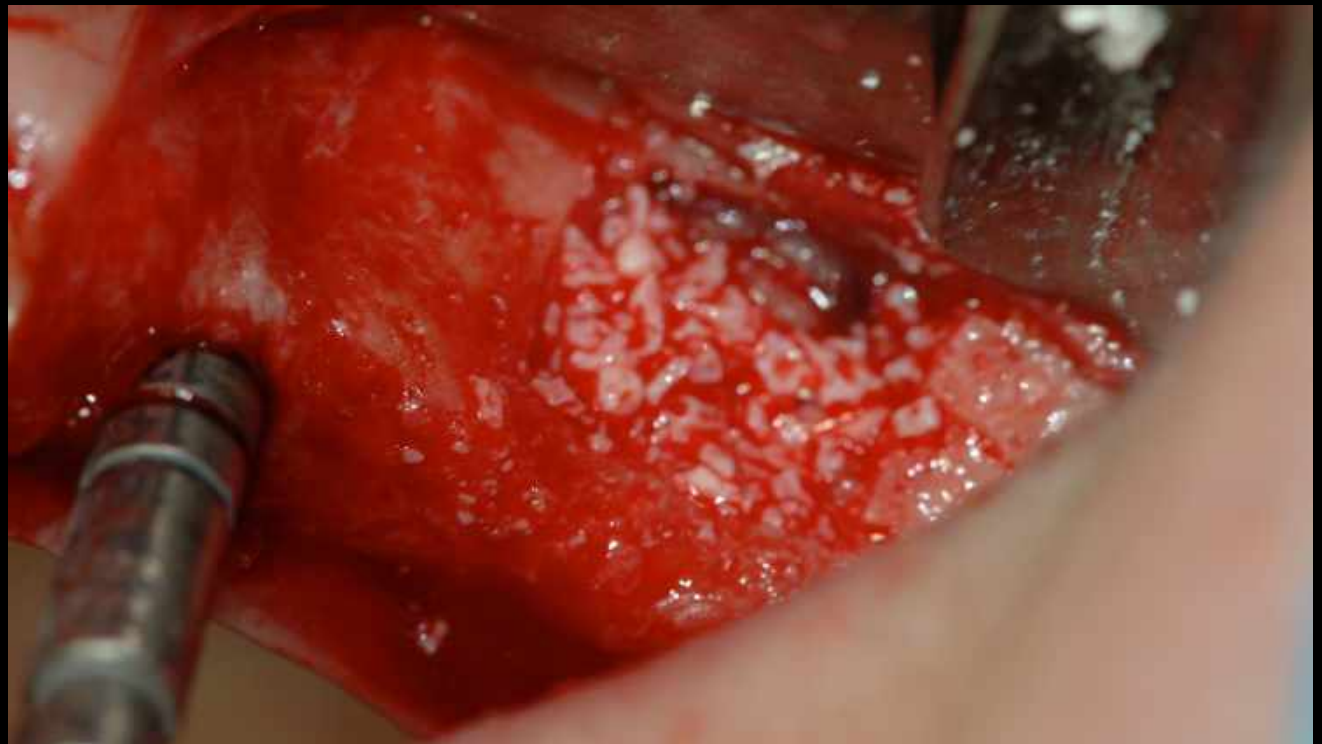
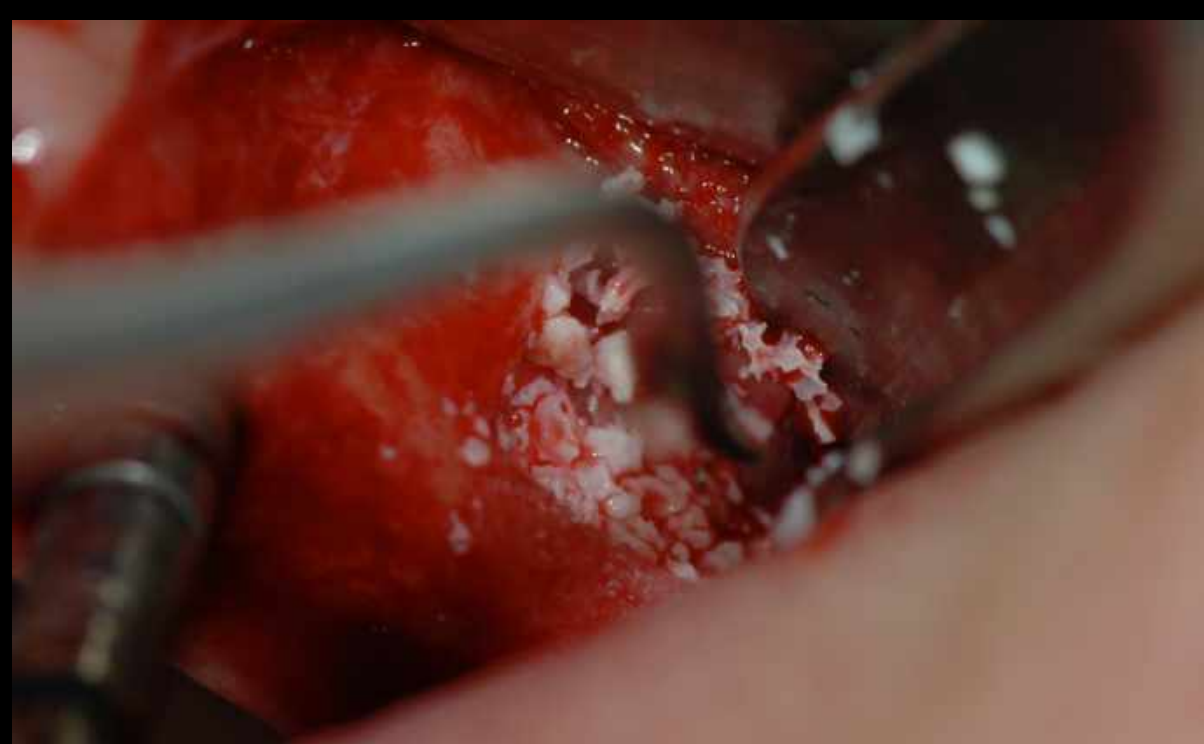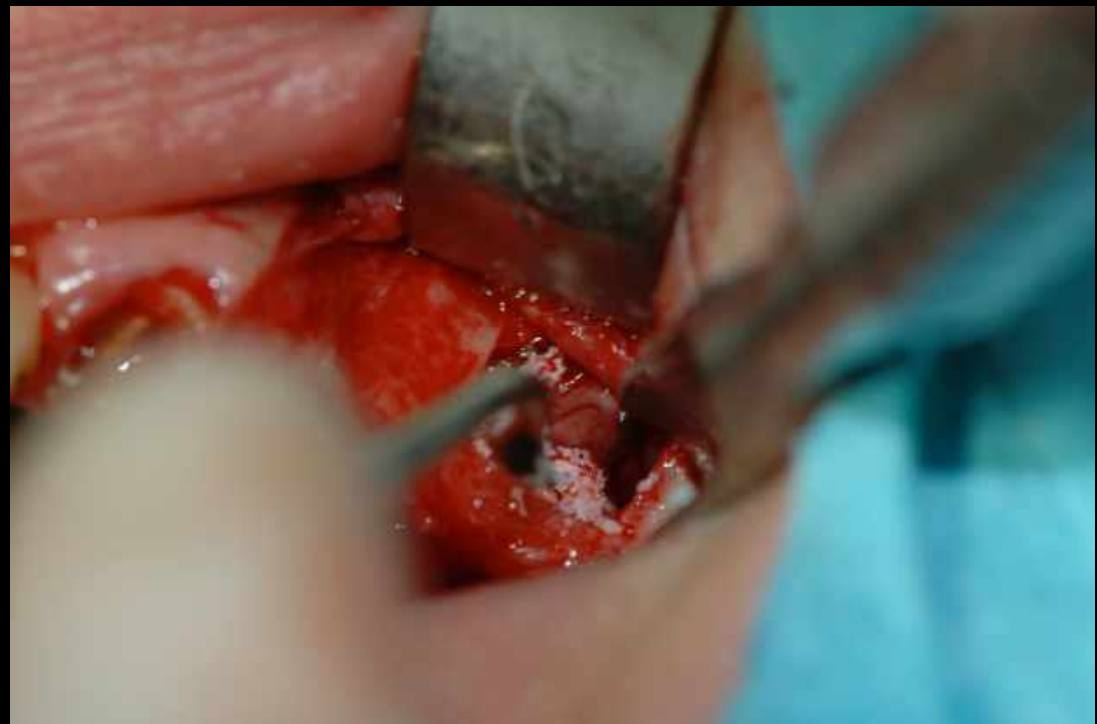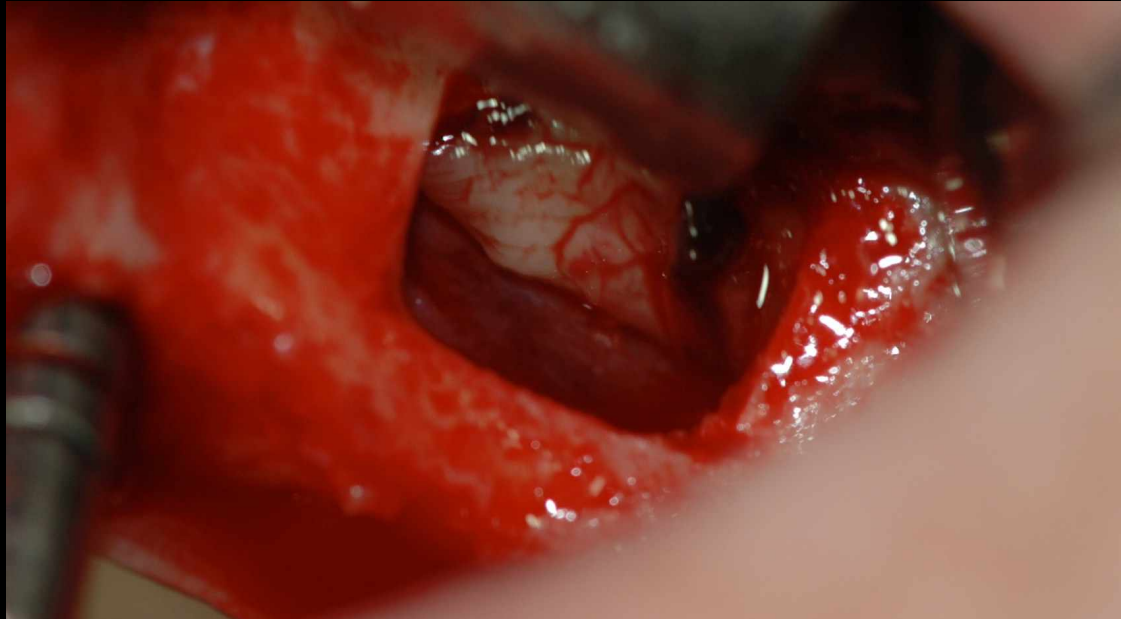
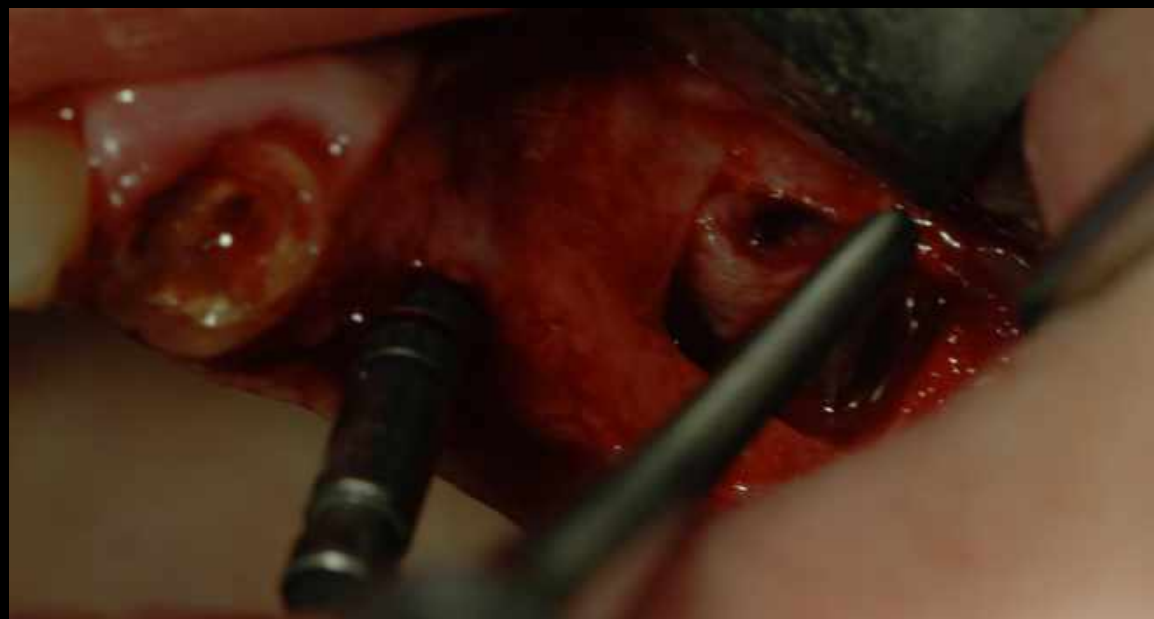2 - GREFFE DU SINUS PAR VOILET LATERAL



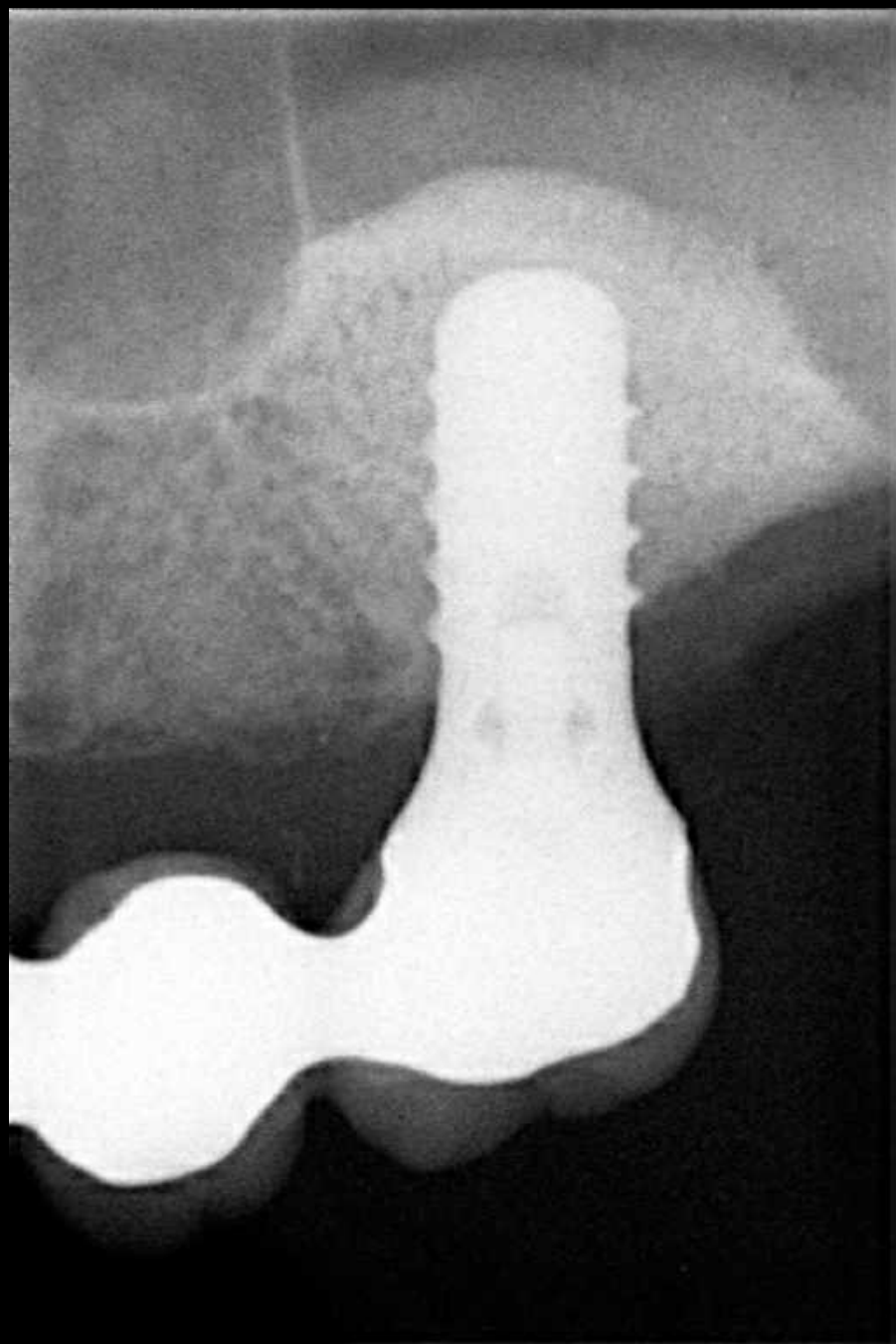
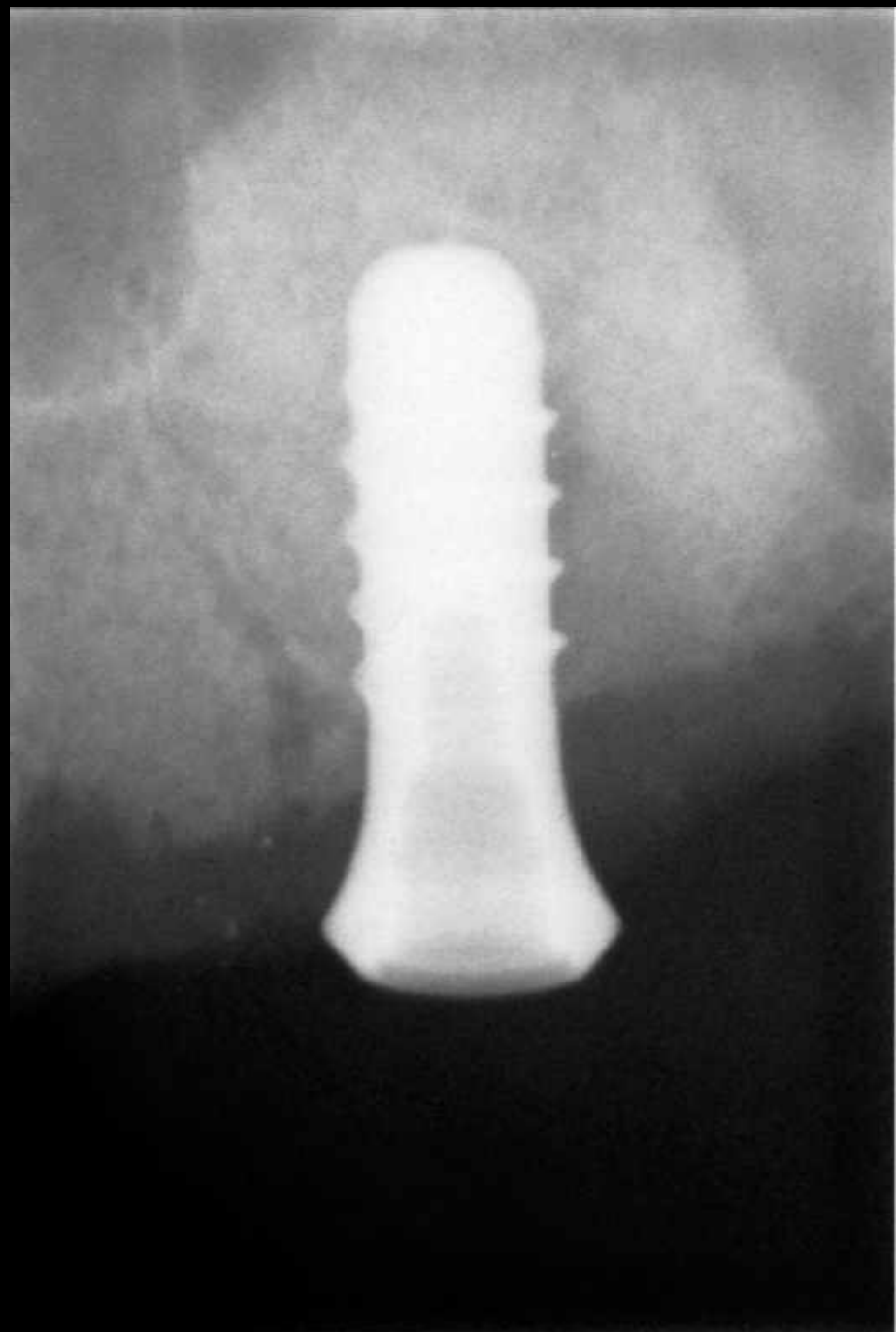
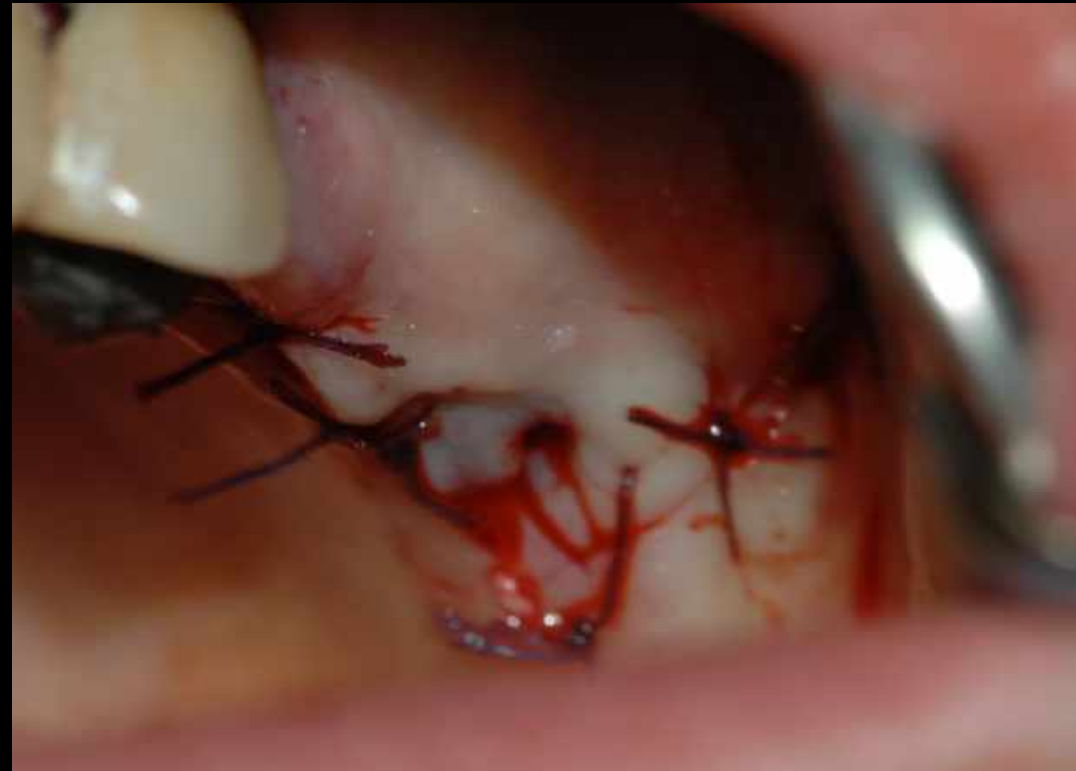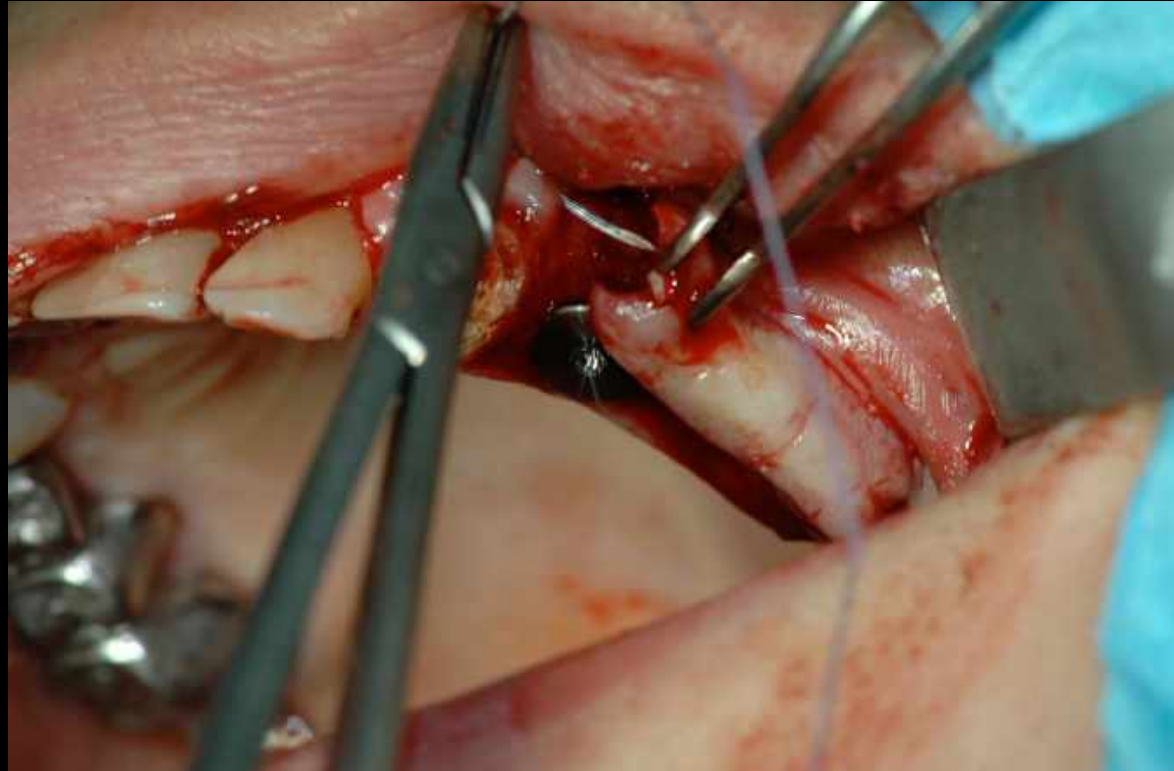
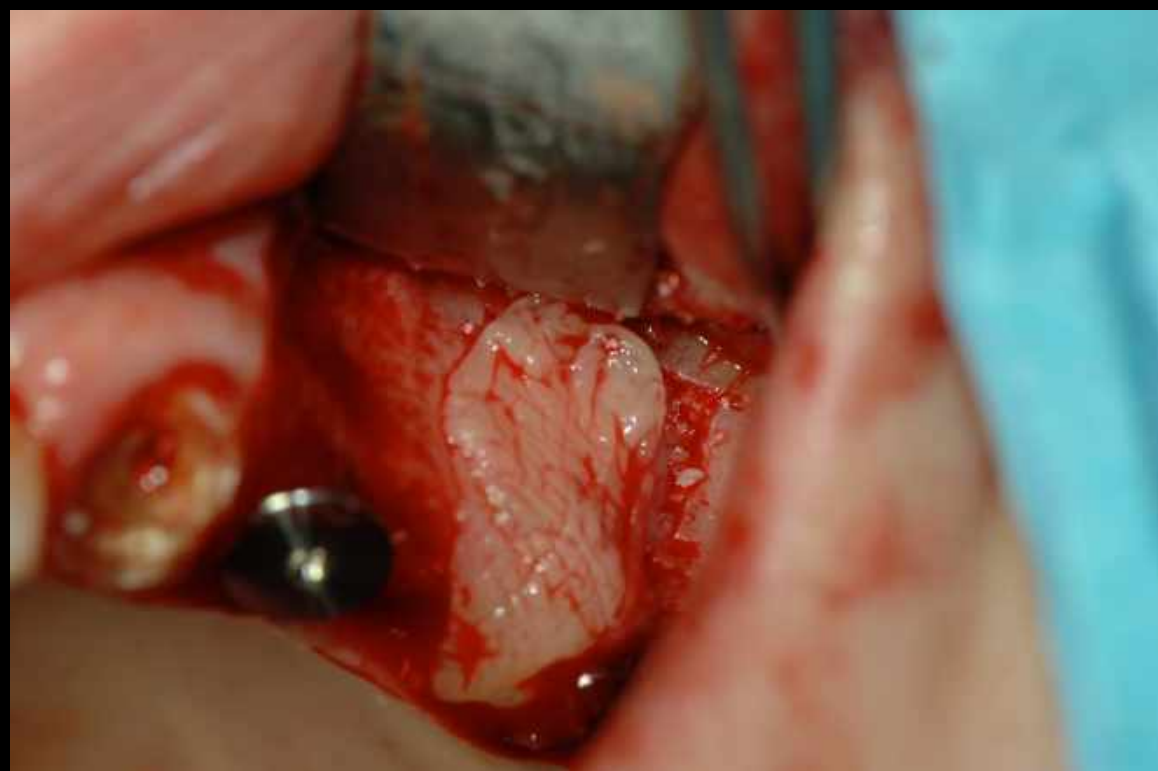
2 - GREFFE DU SINUS PAR VOILET LATERAL



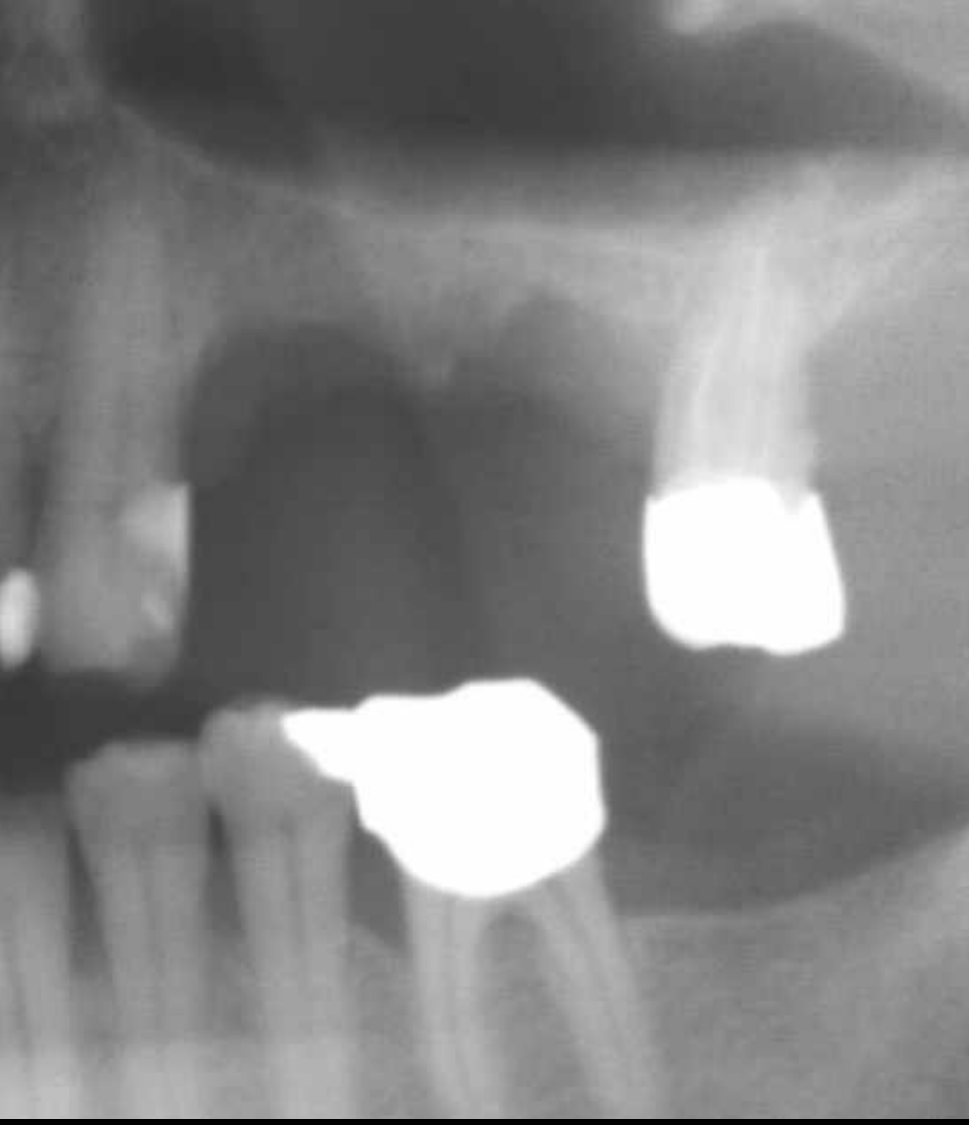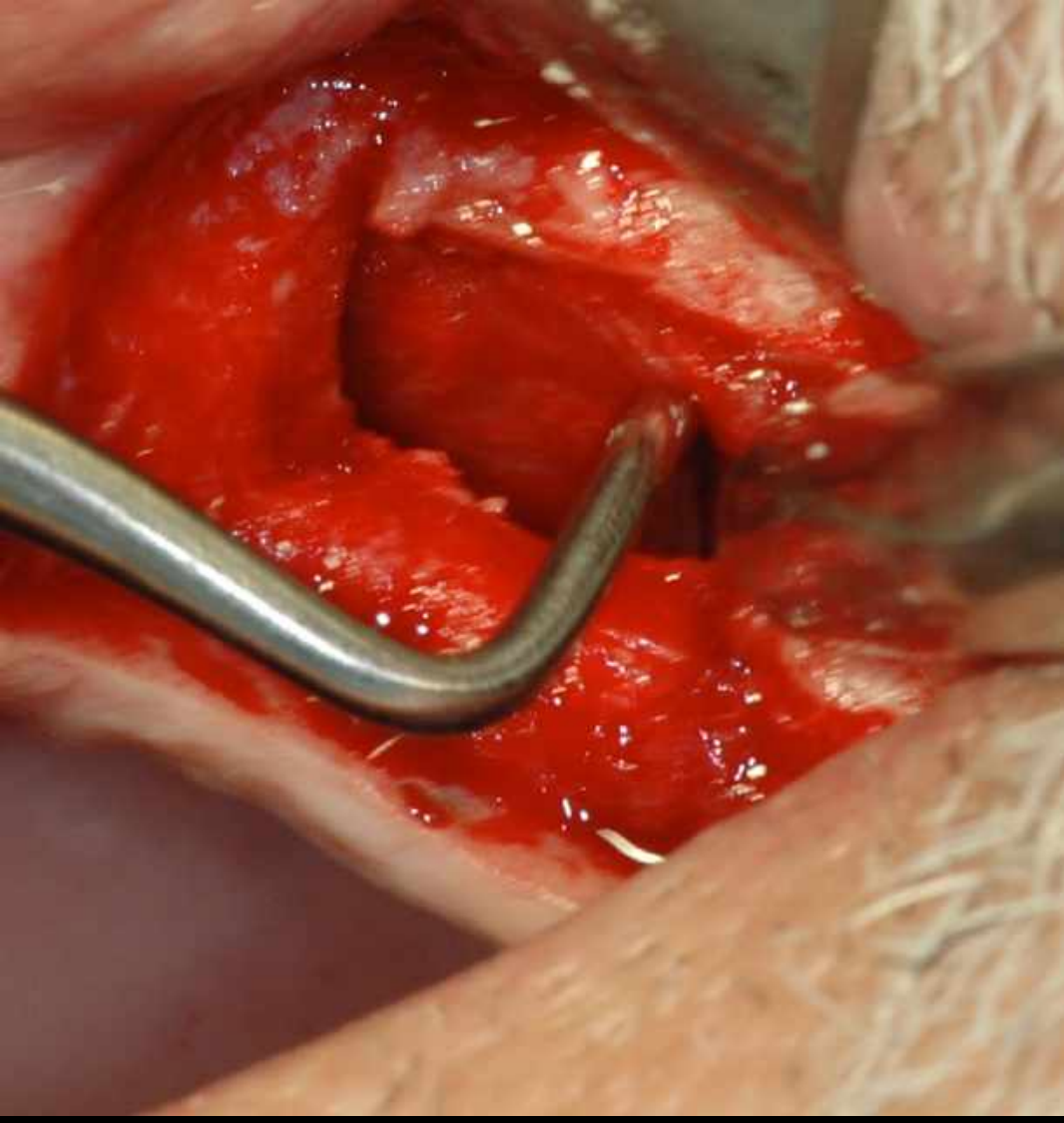
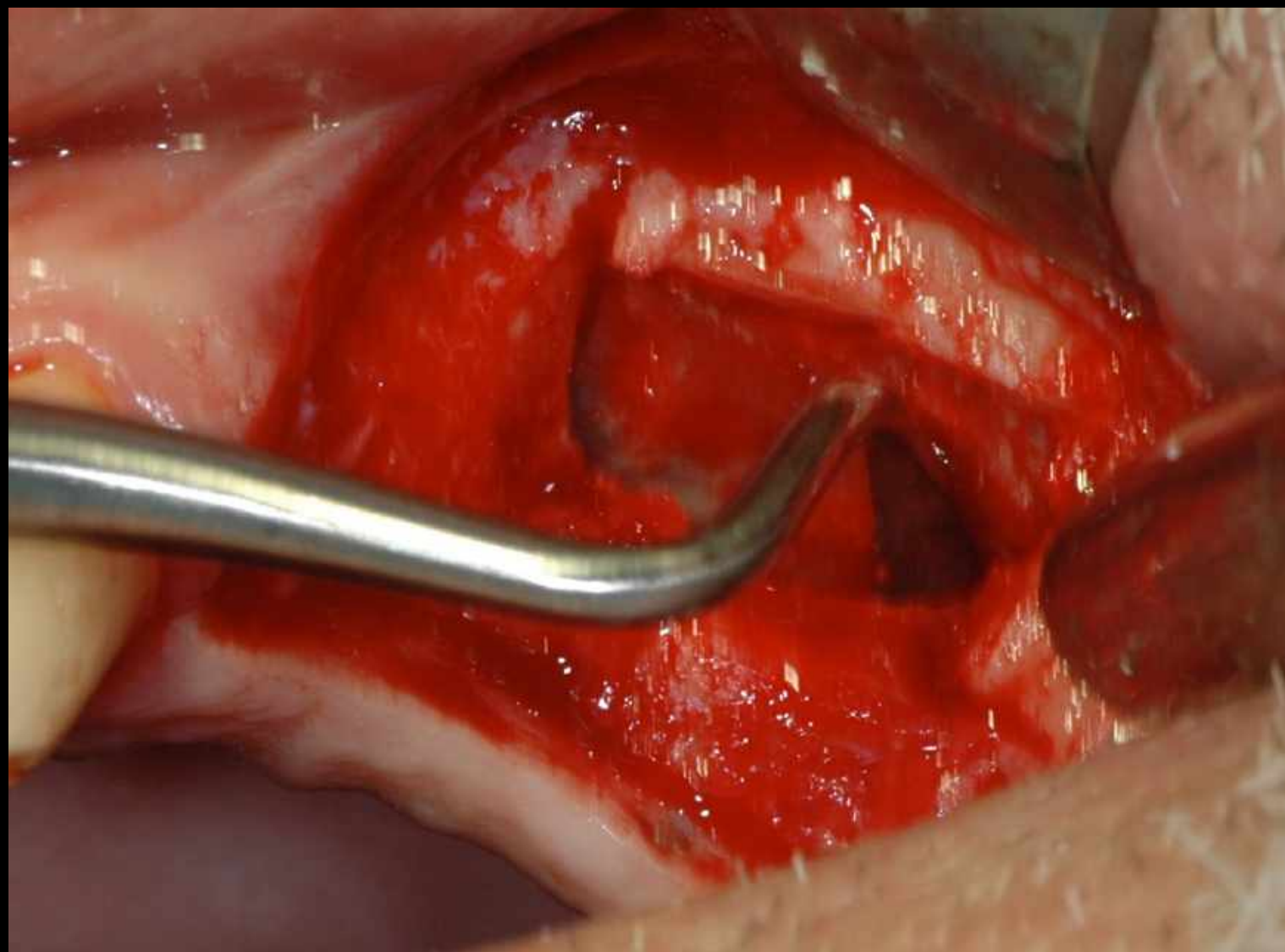
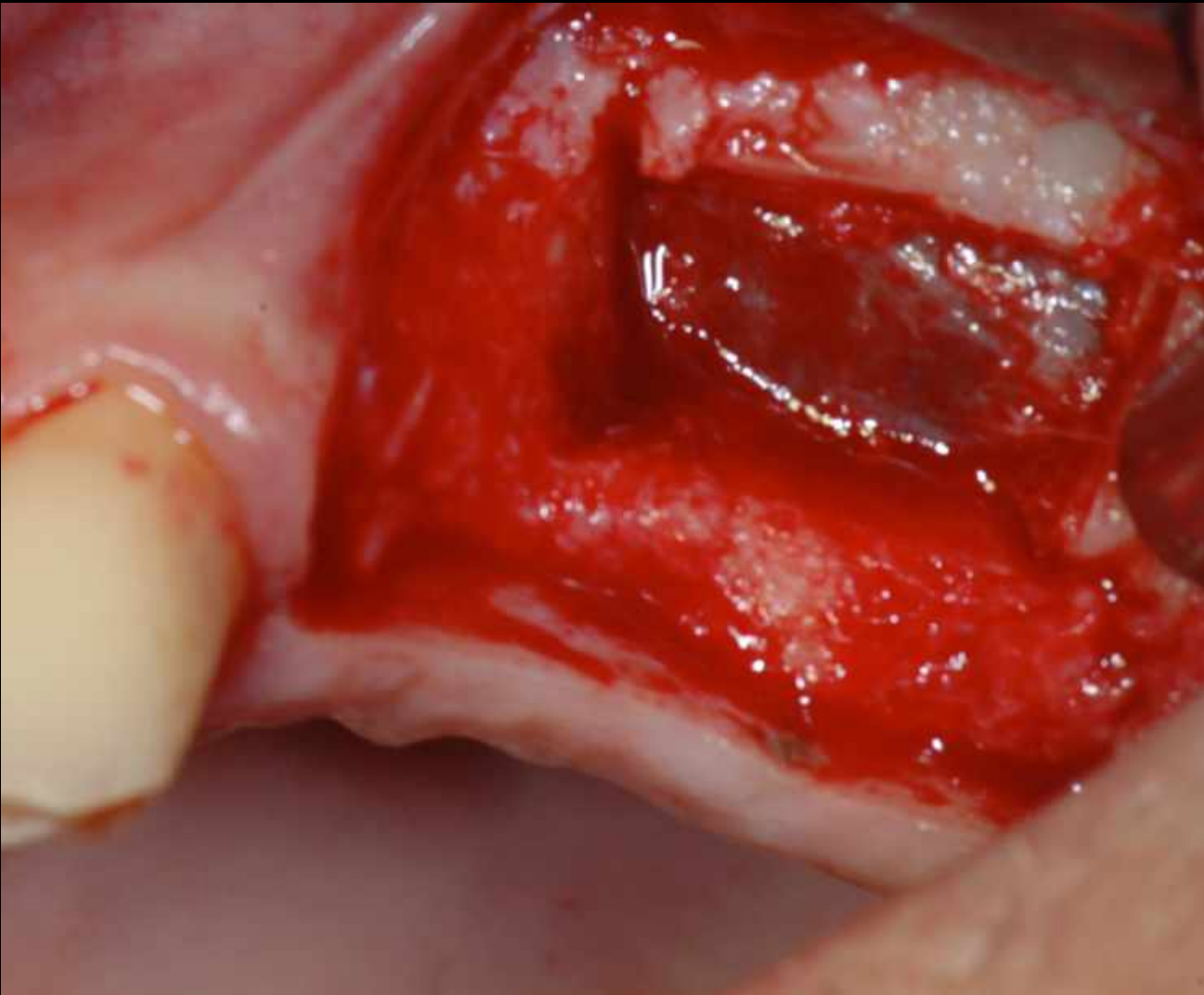
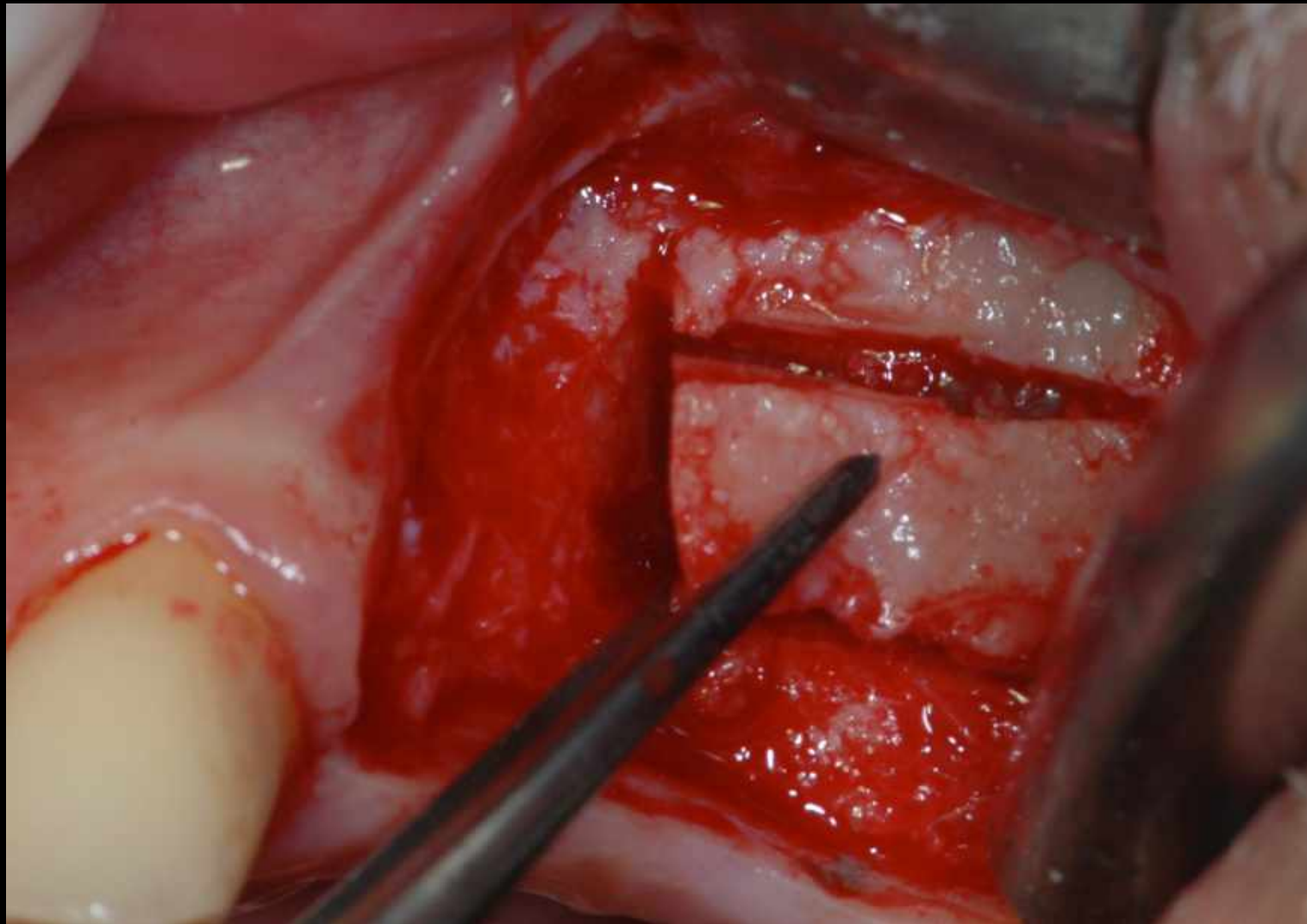
2 - GREFFE DU SINUS PAR VOILET LATERAL



2 - GREFFE DU SINUS PAR VOILET LATERAL

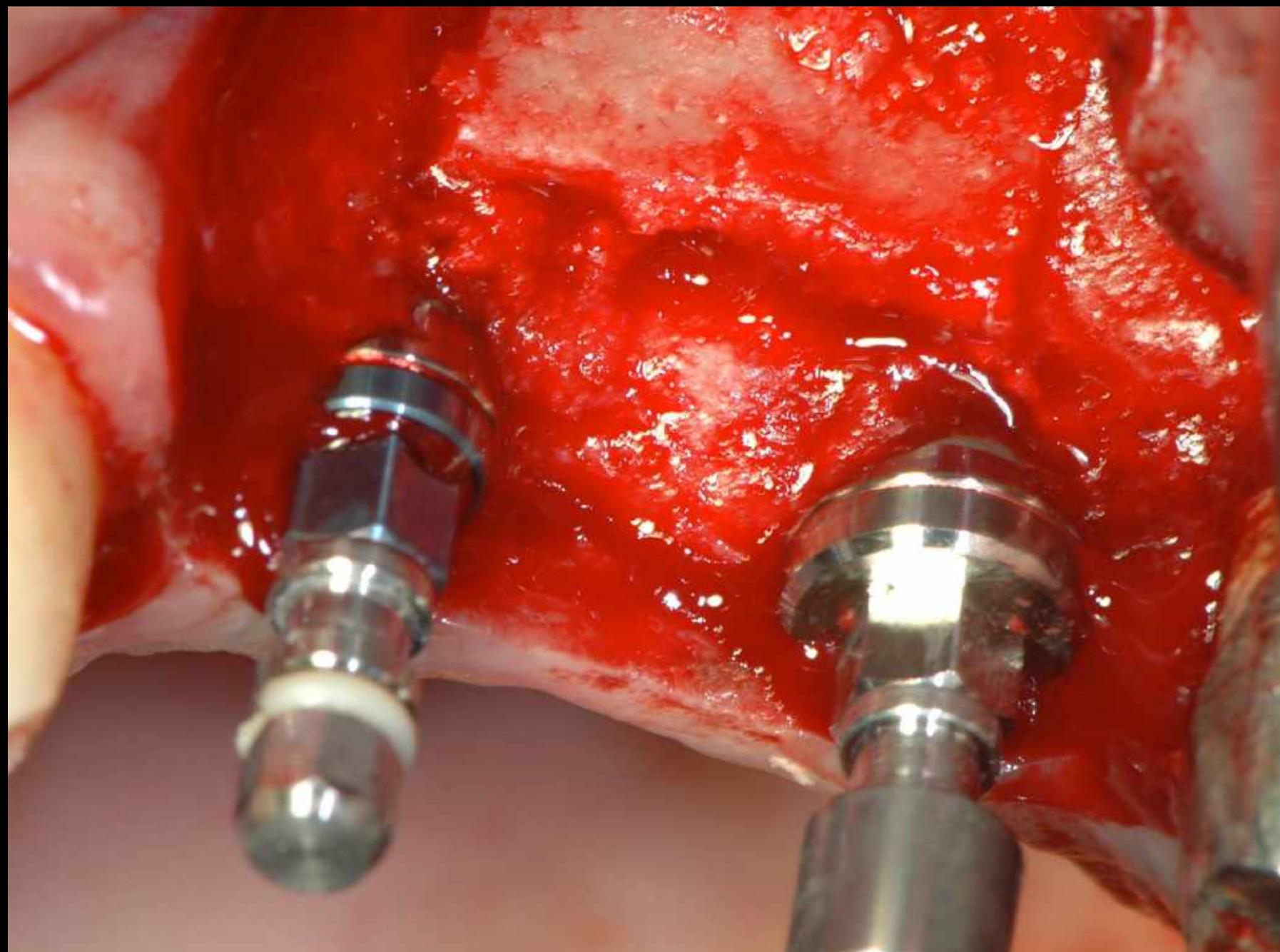
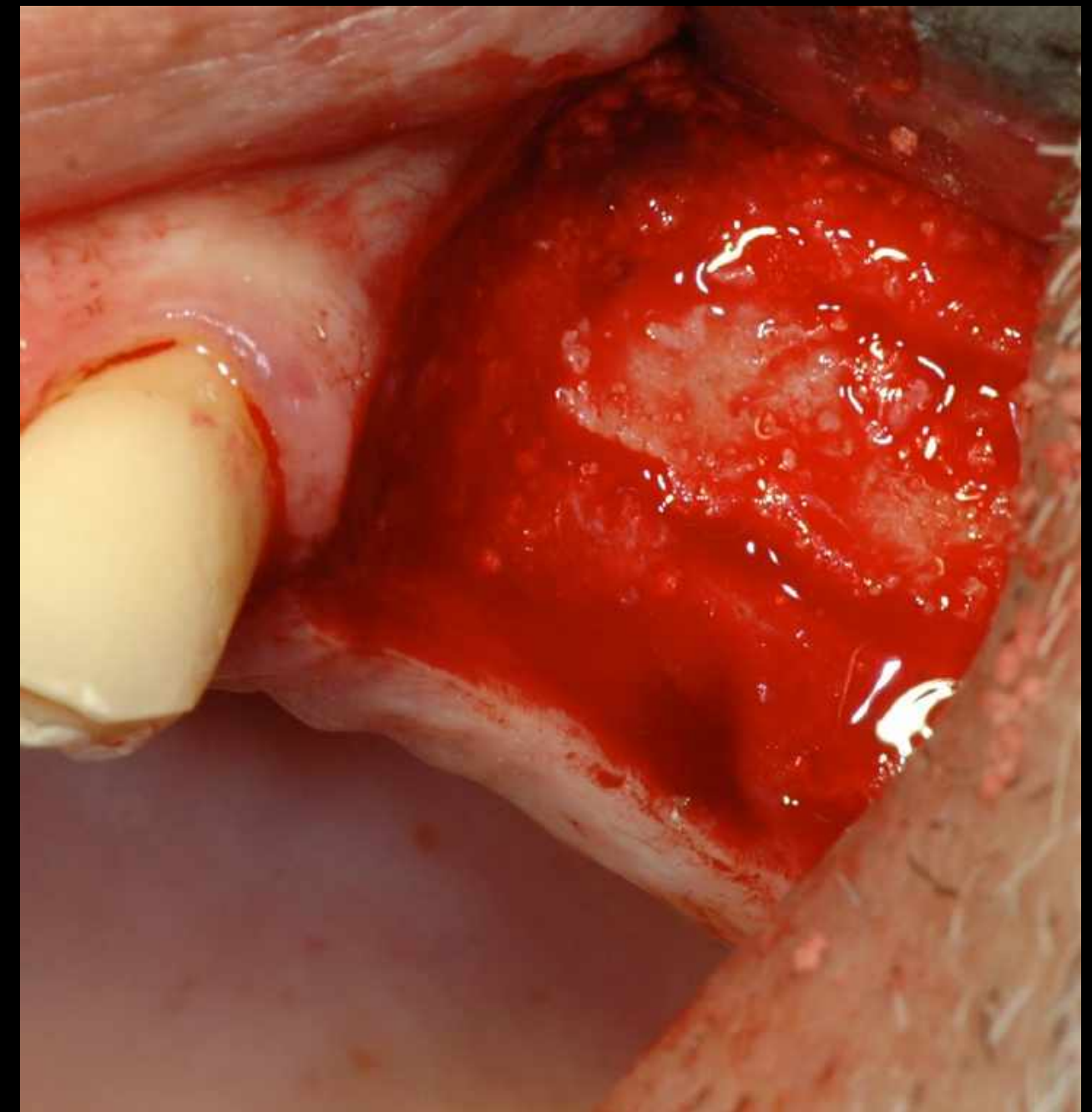
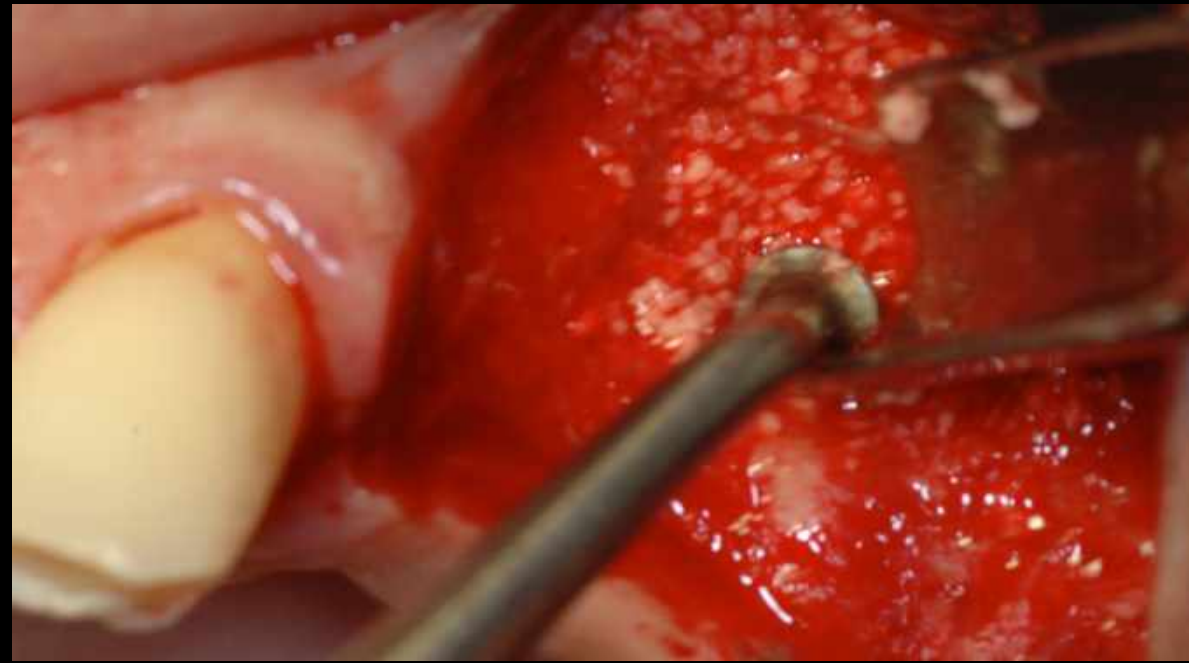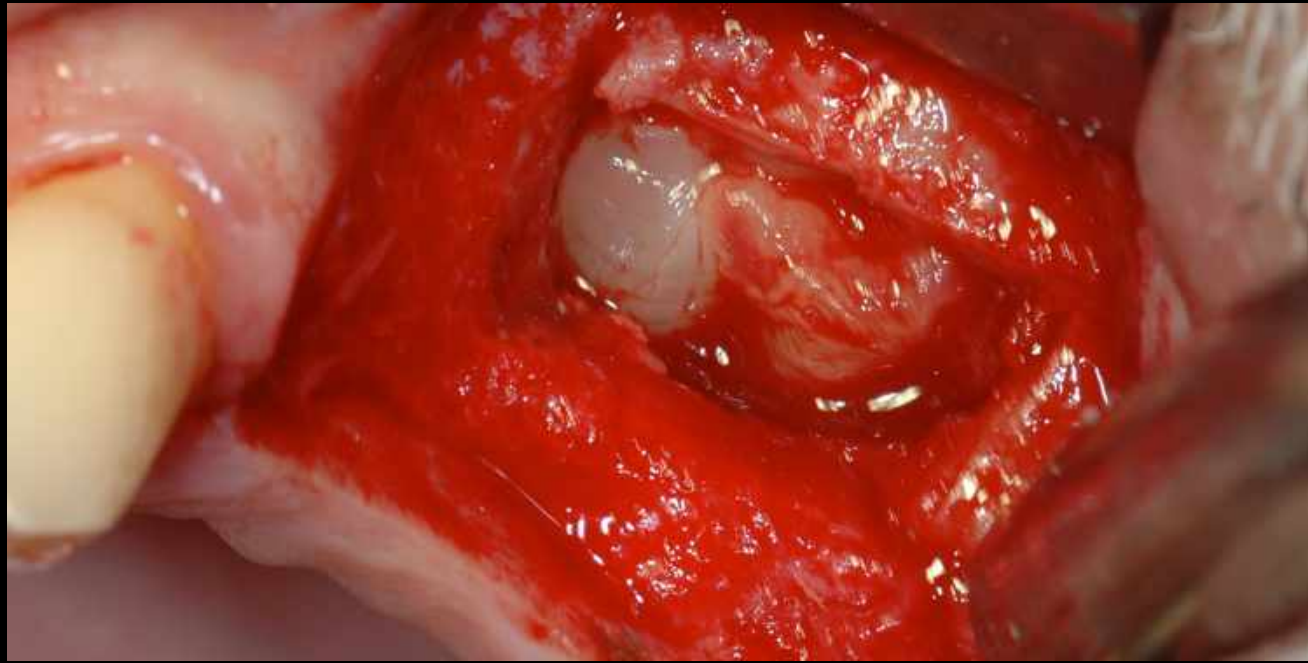


2 - GREFFE DU SINUS PAR VOILET LATERAL



Volet Latéral

Volet Basculé

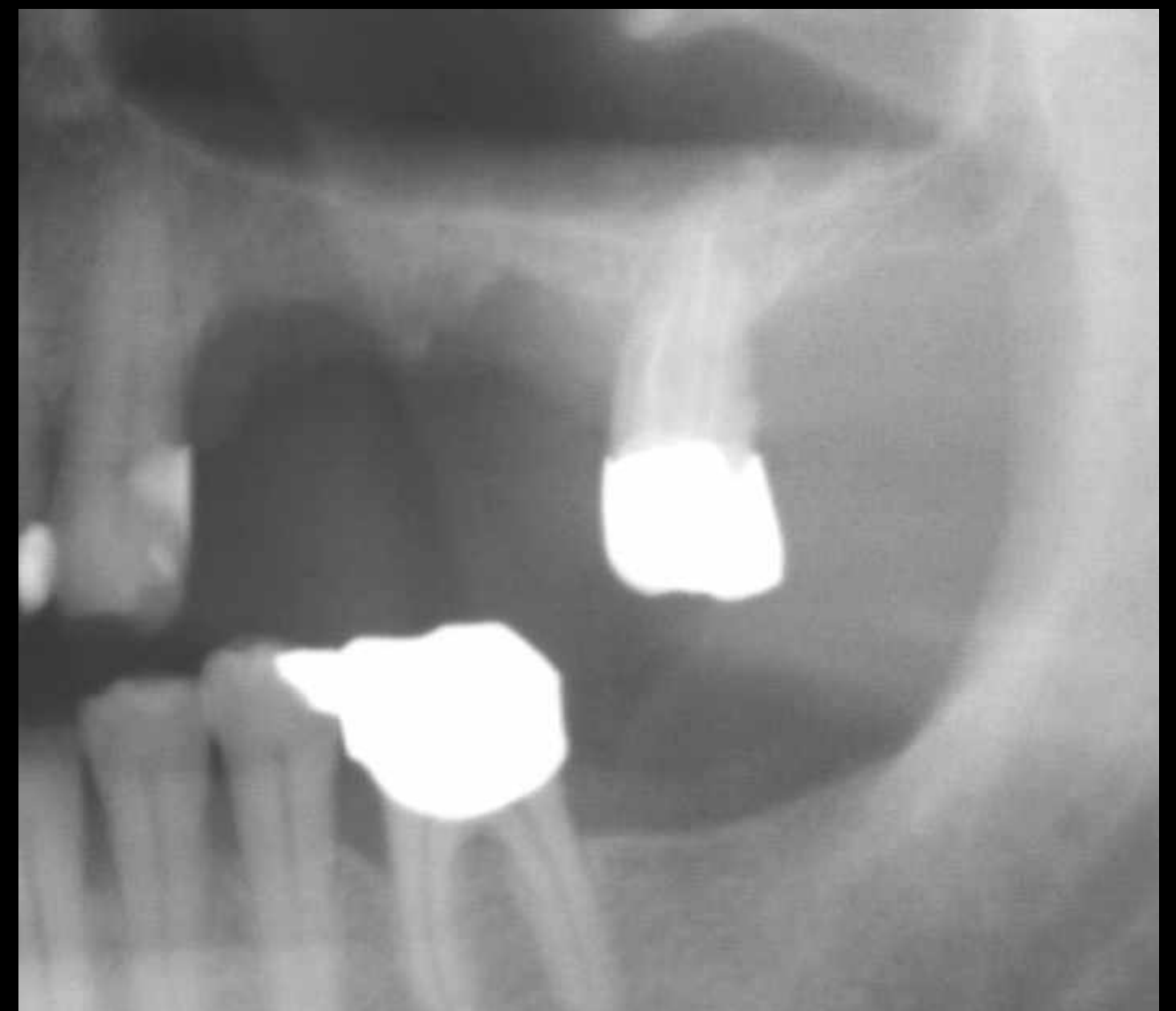
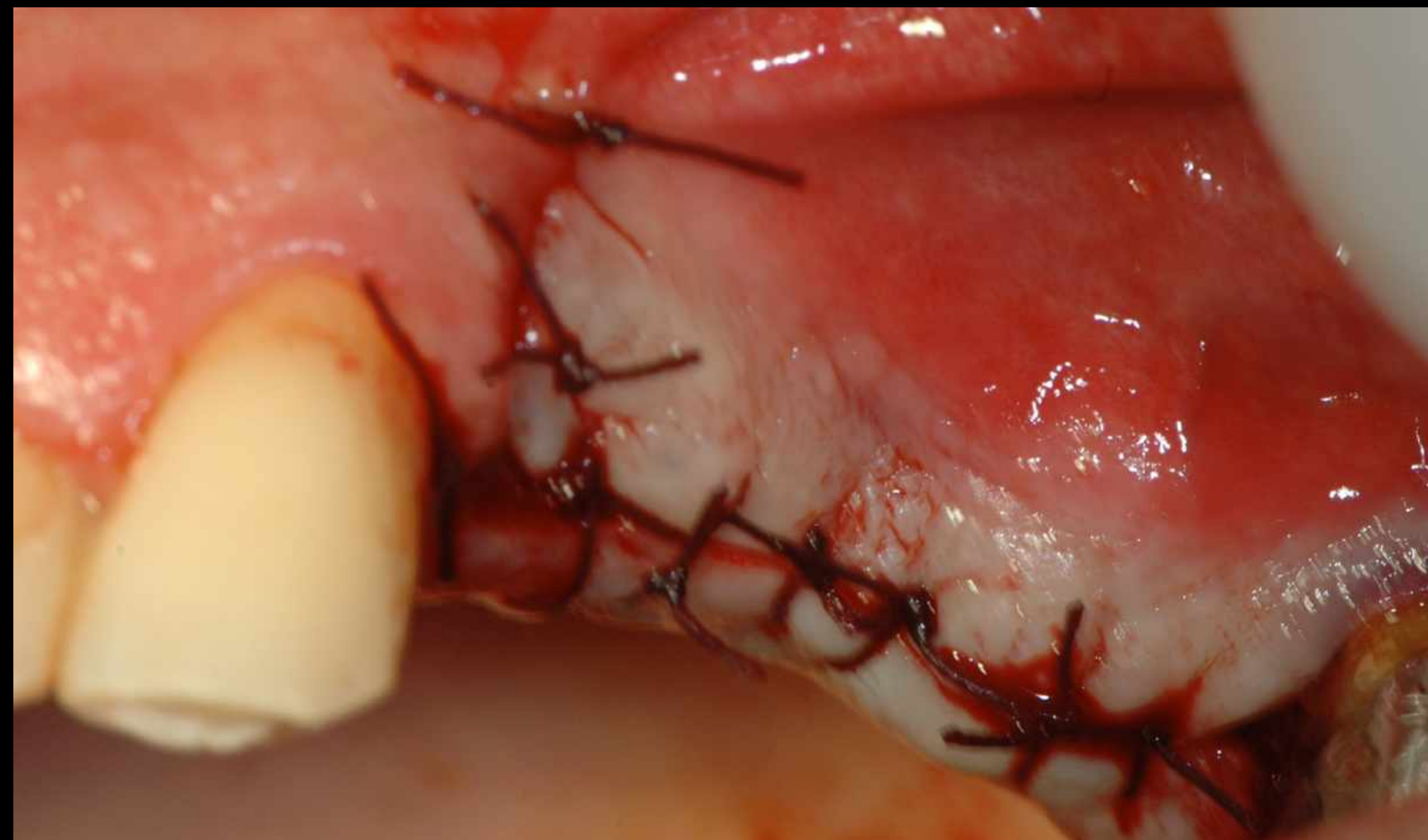
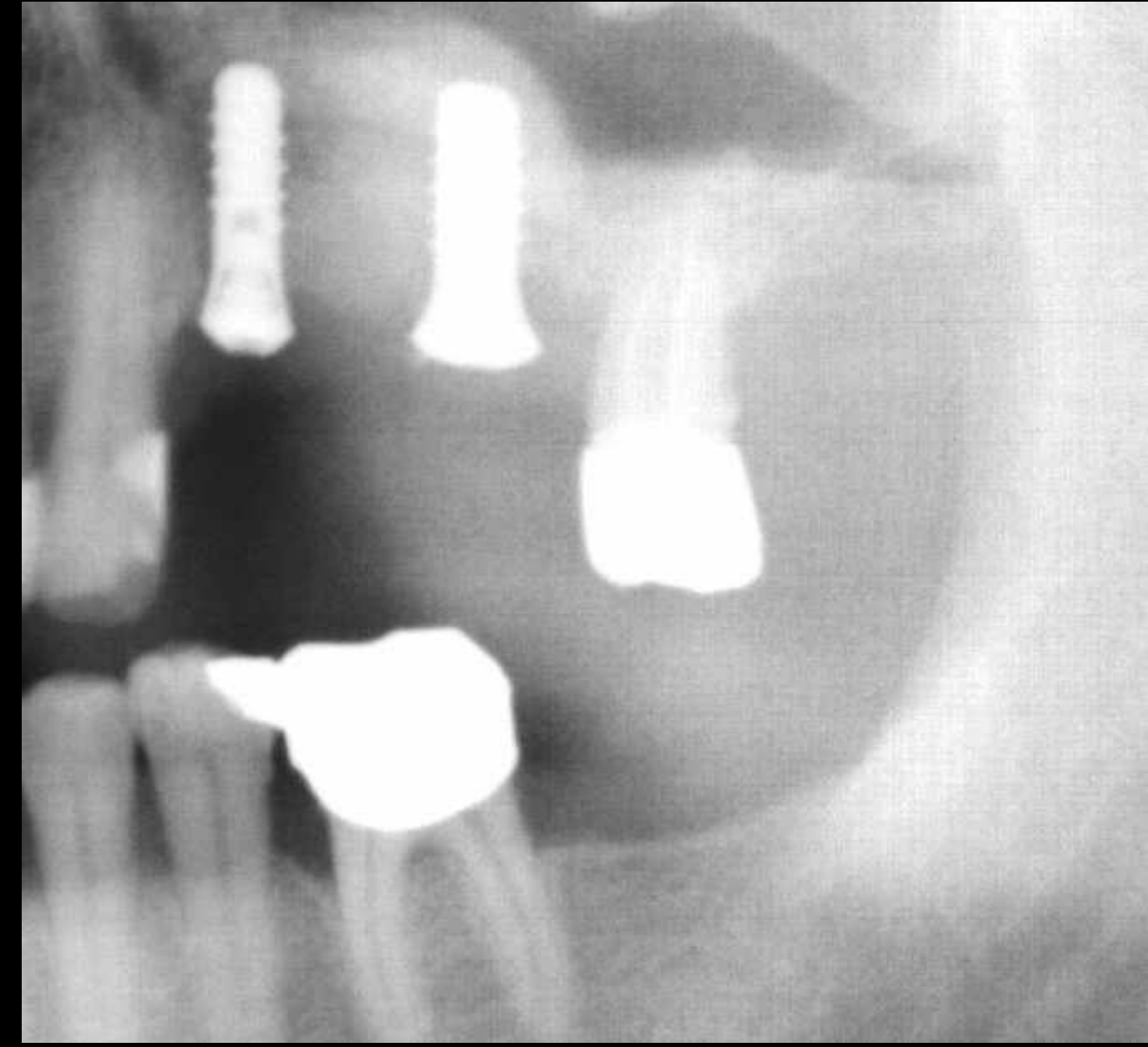
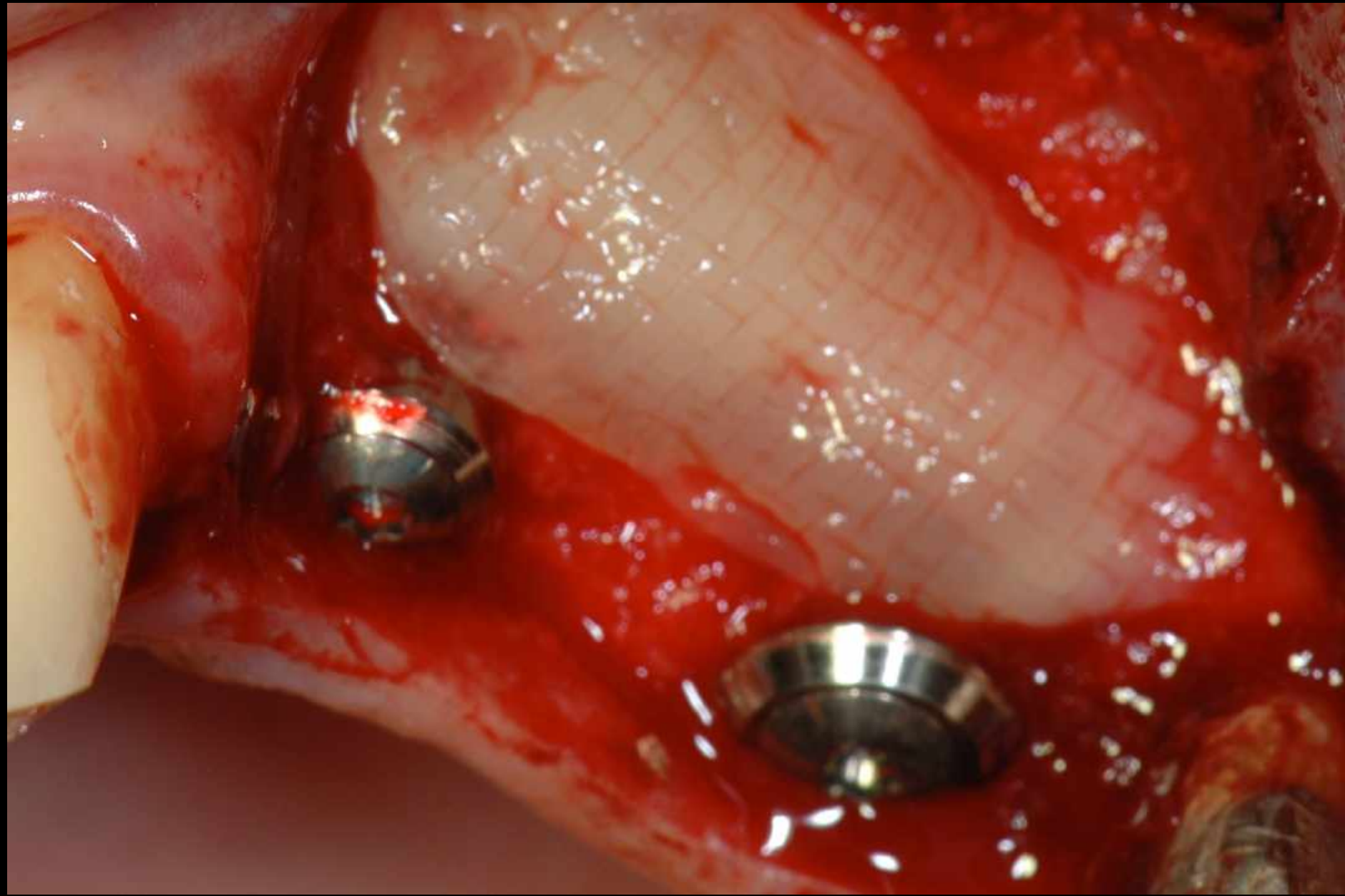


Indication :

Muqueuse fine
Sinus profond
Pas de cloison

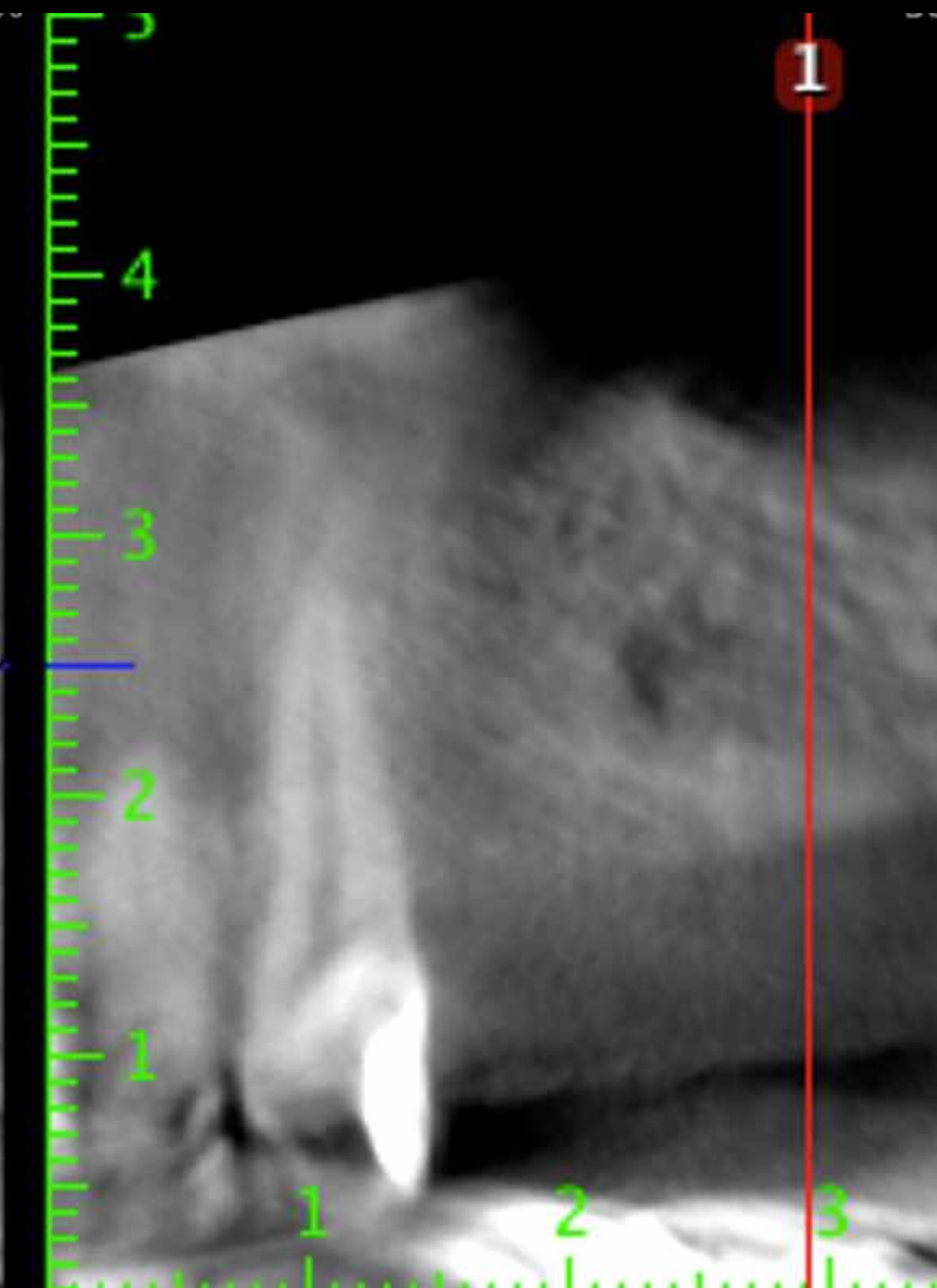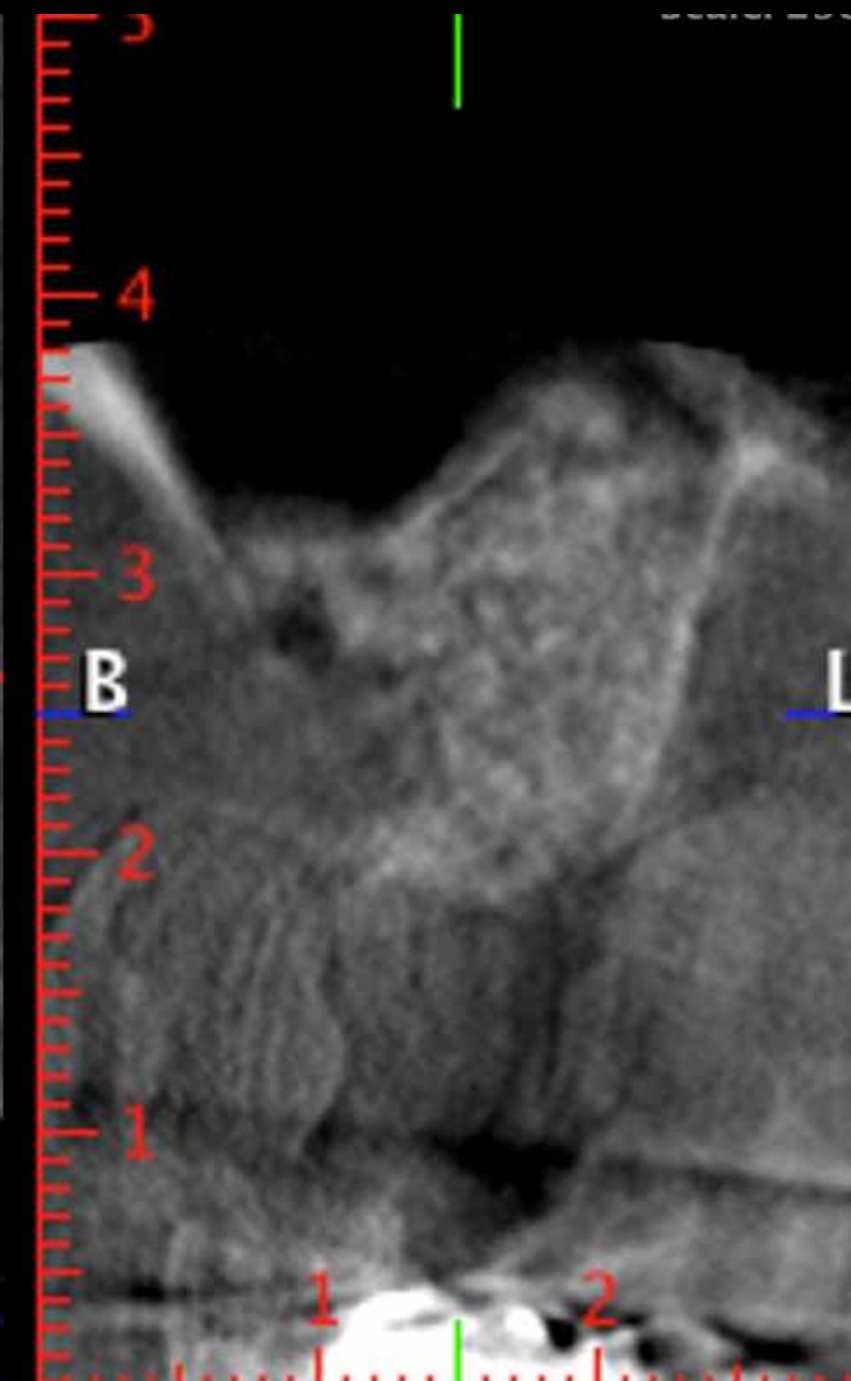
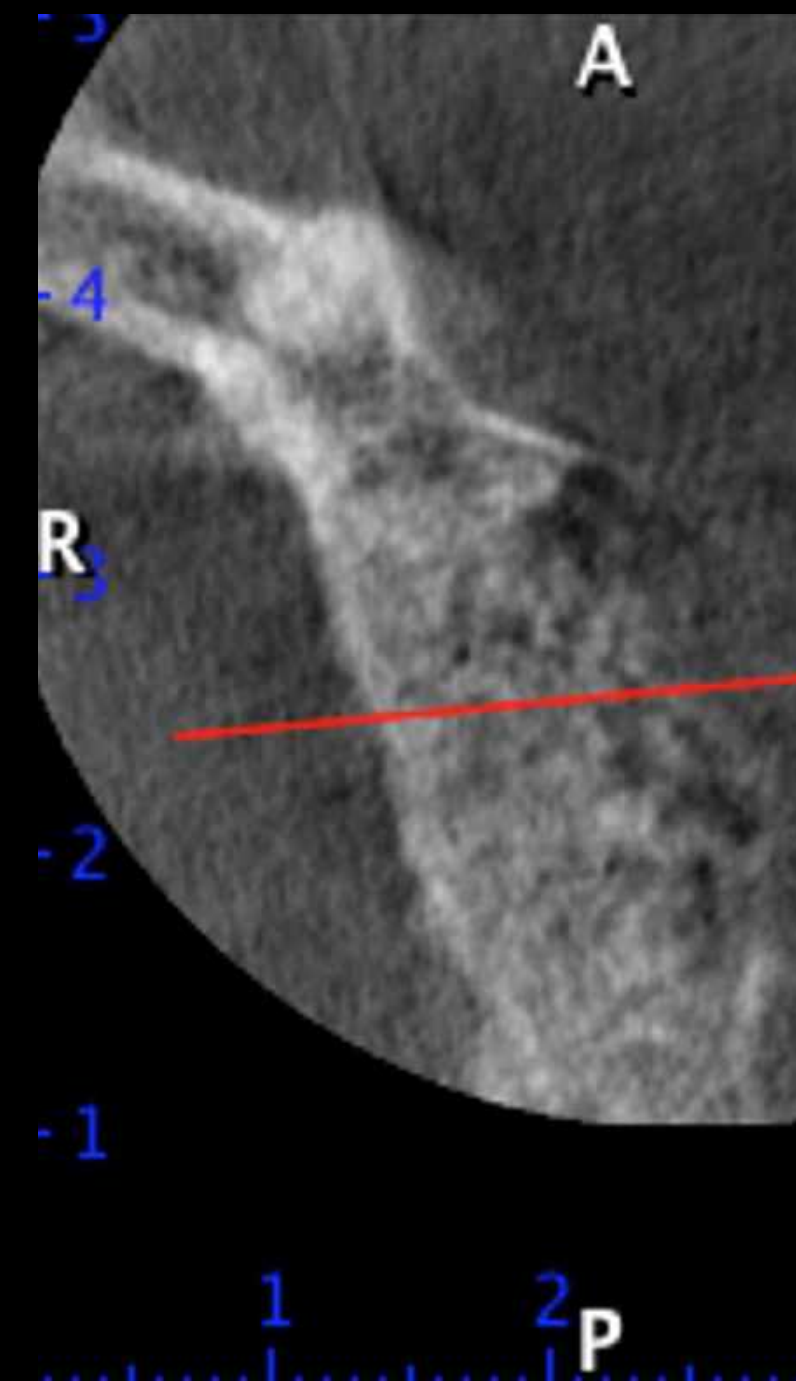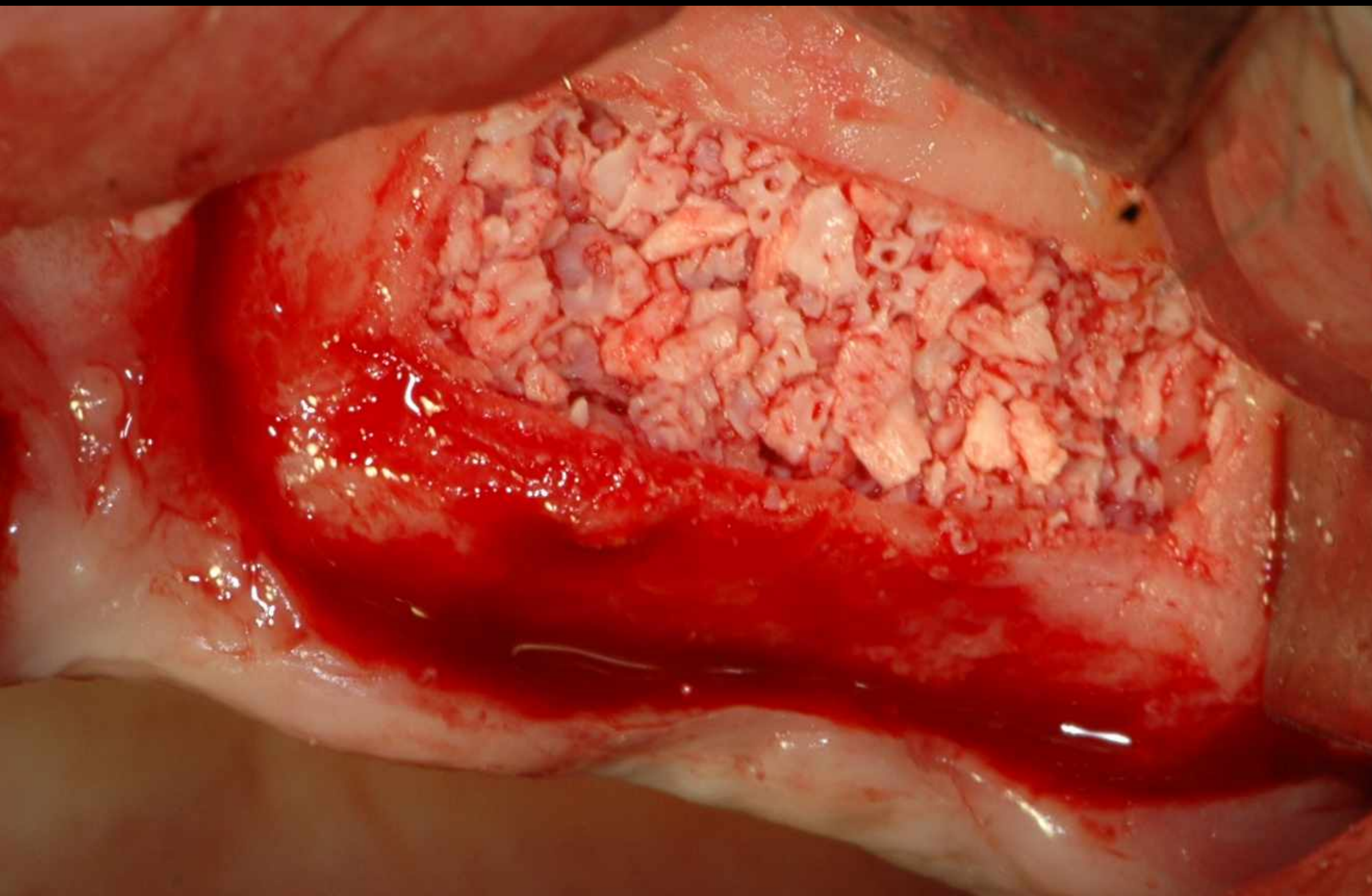
Volet Latéral

Volet Basculé



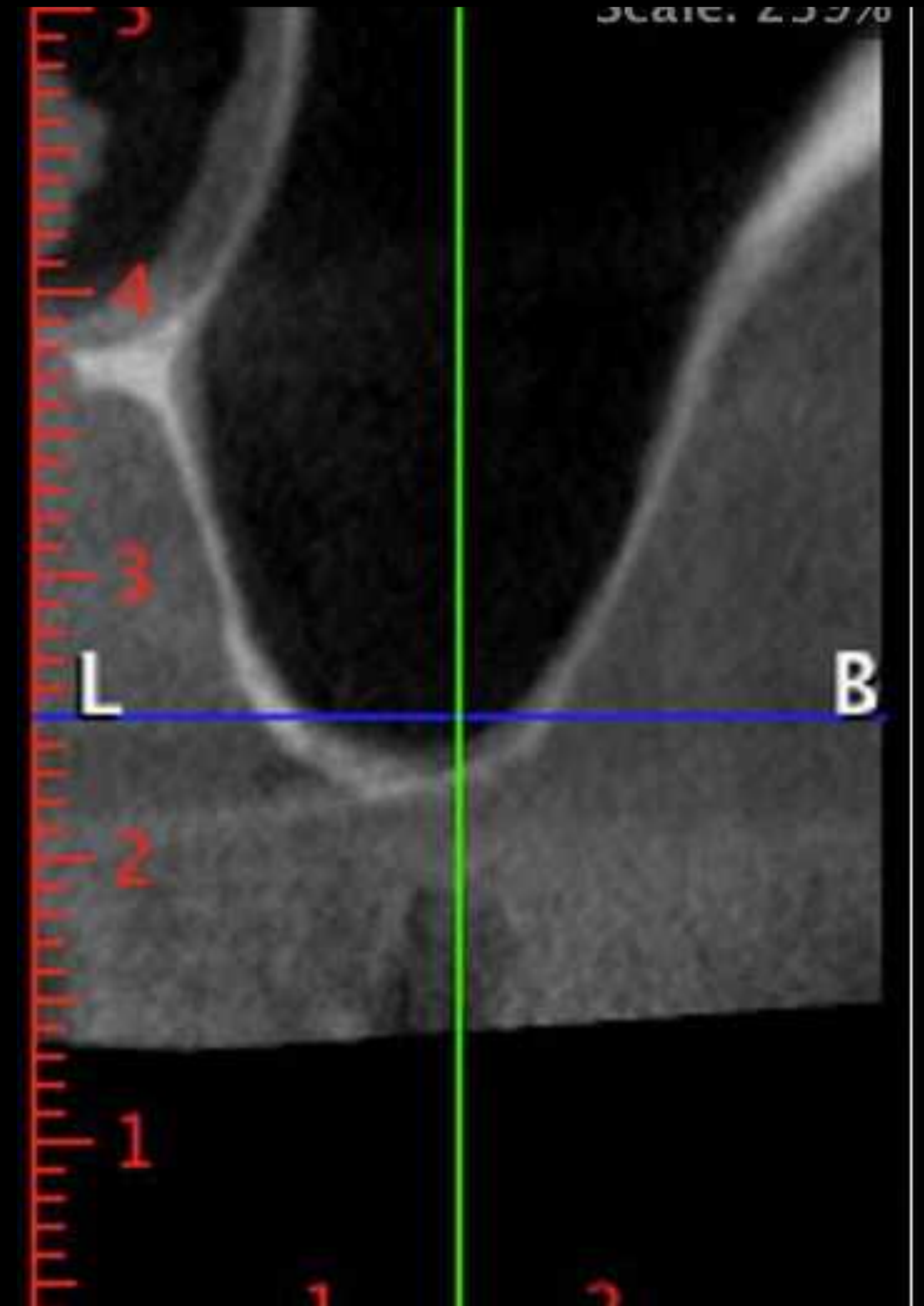
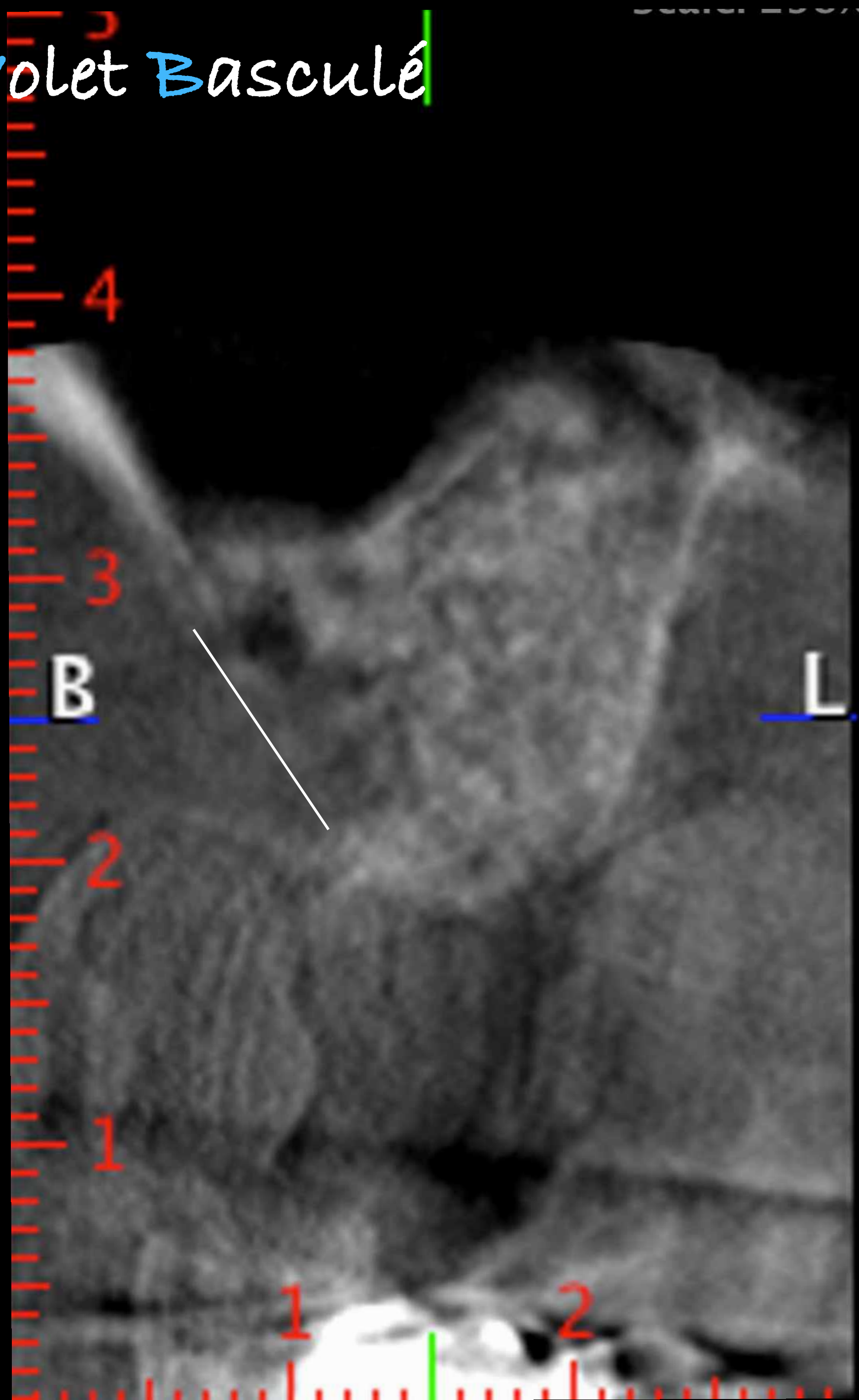


volet Basculé



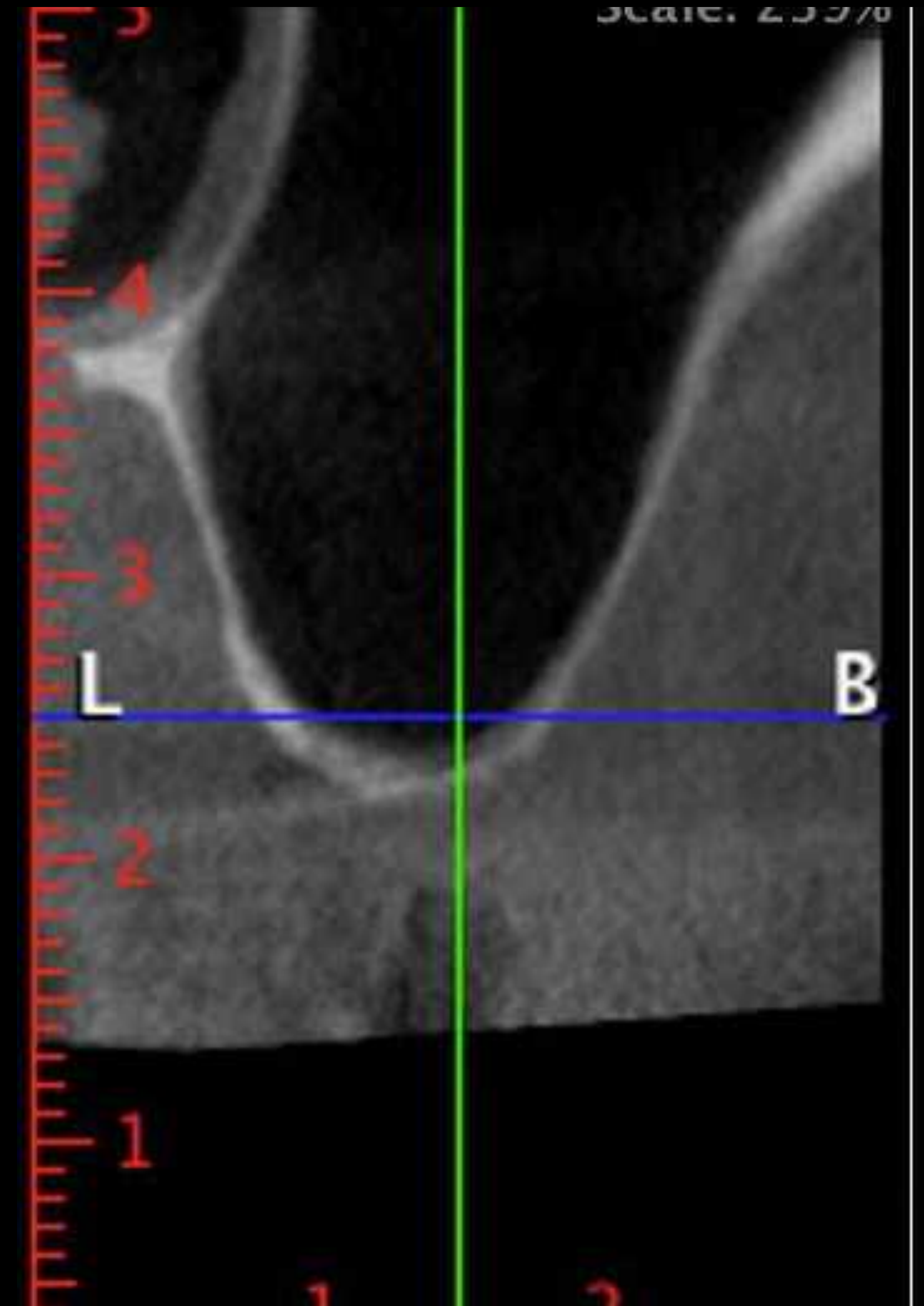
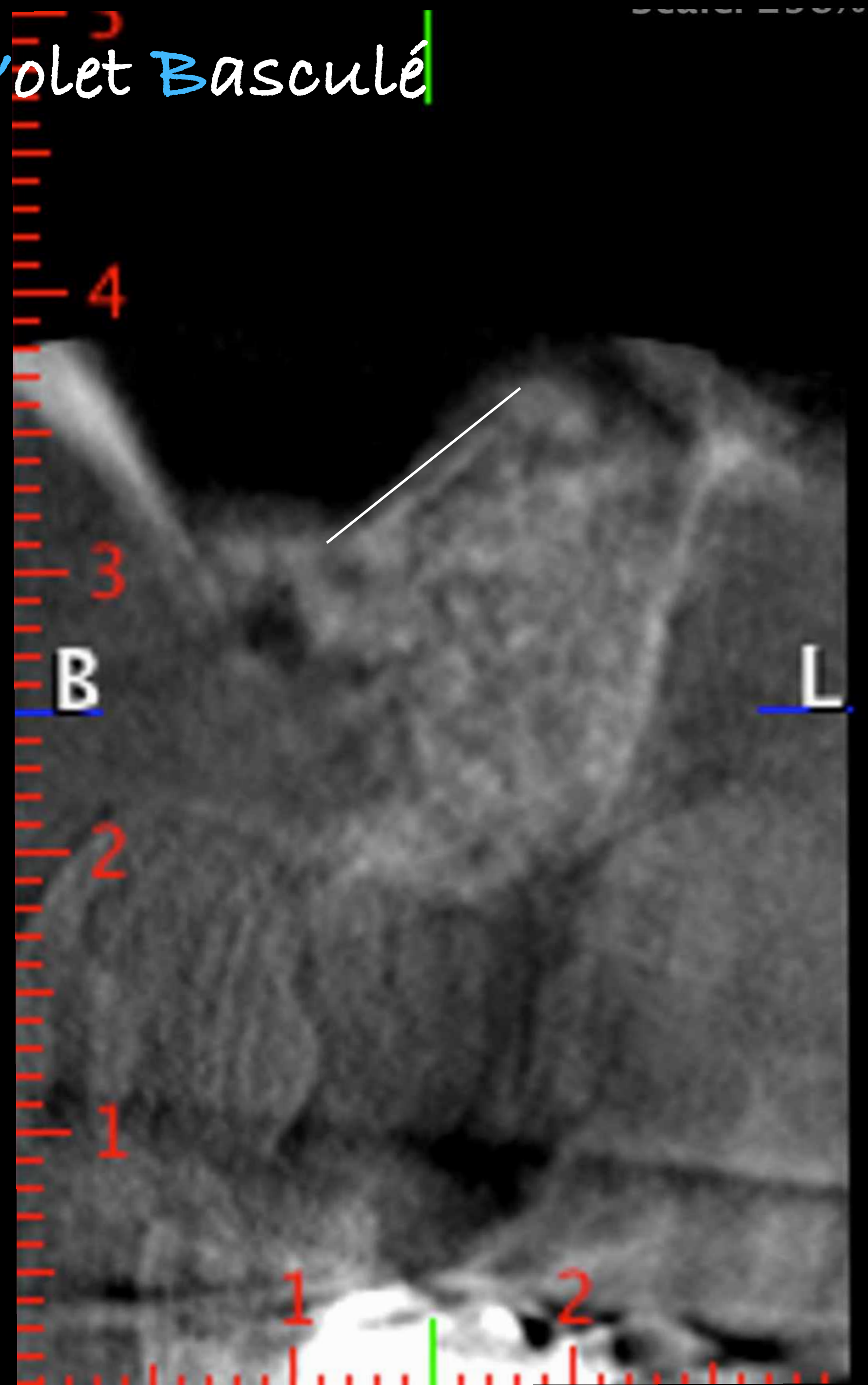
Volet Latéral

Volet Basculé

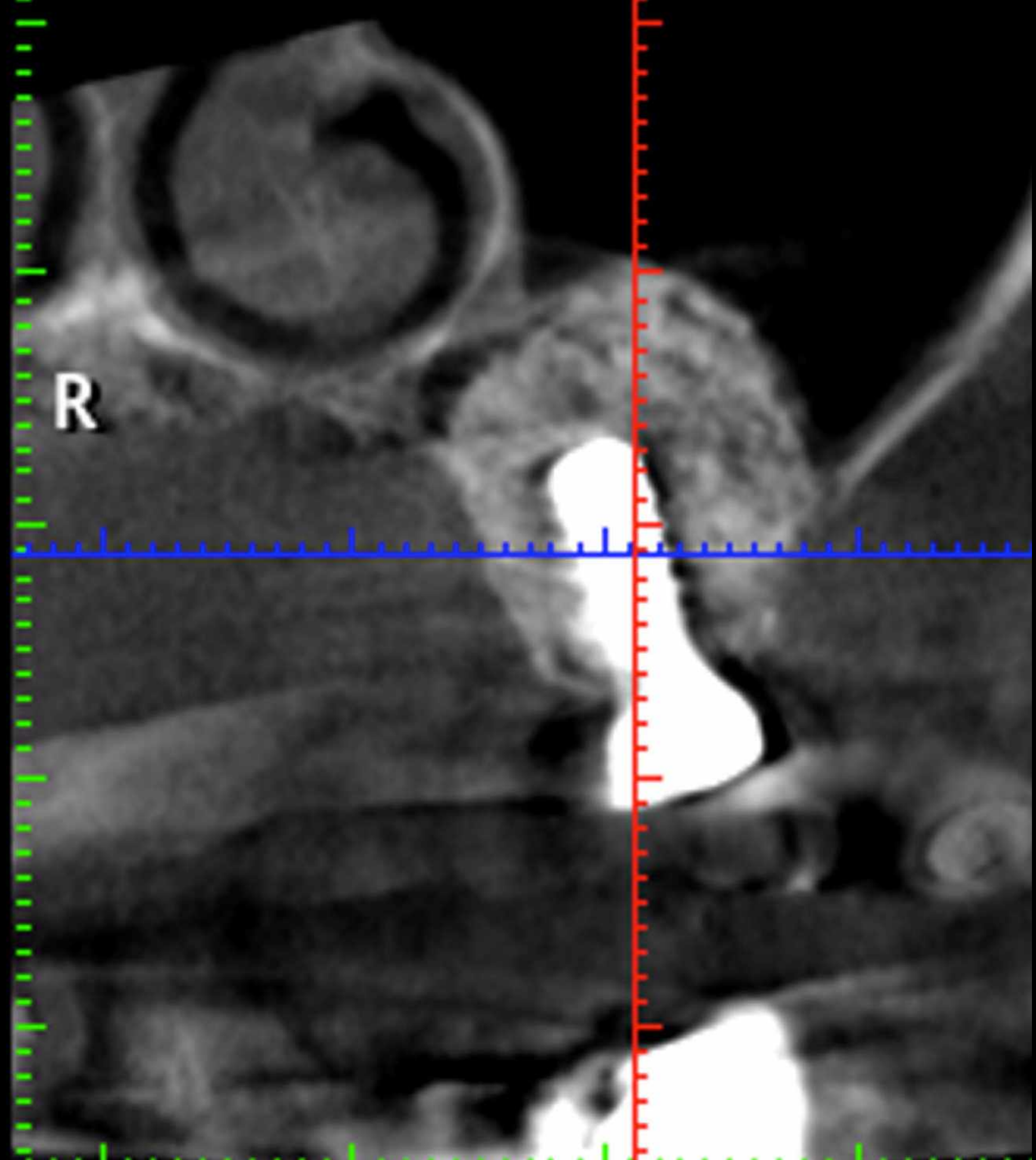
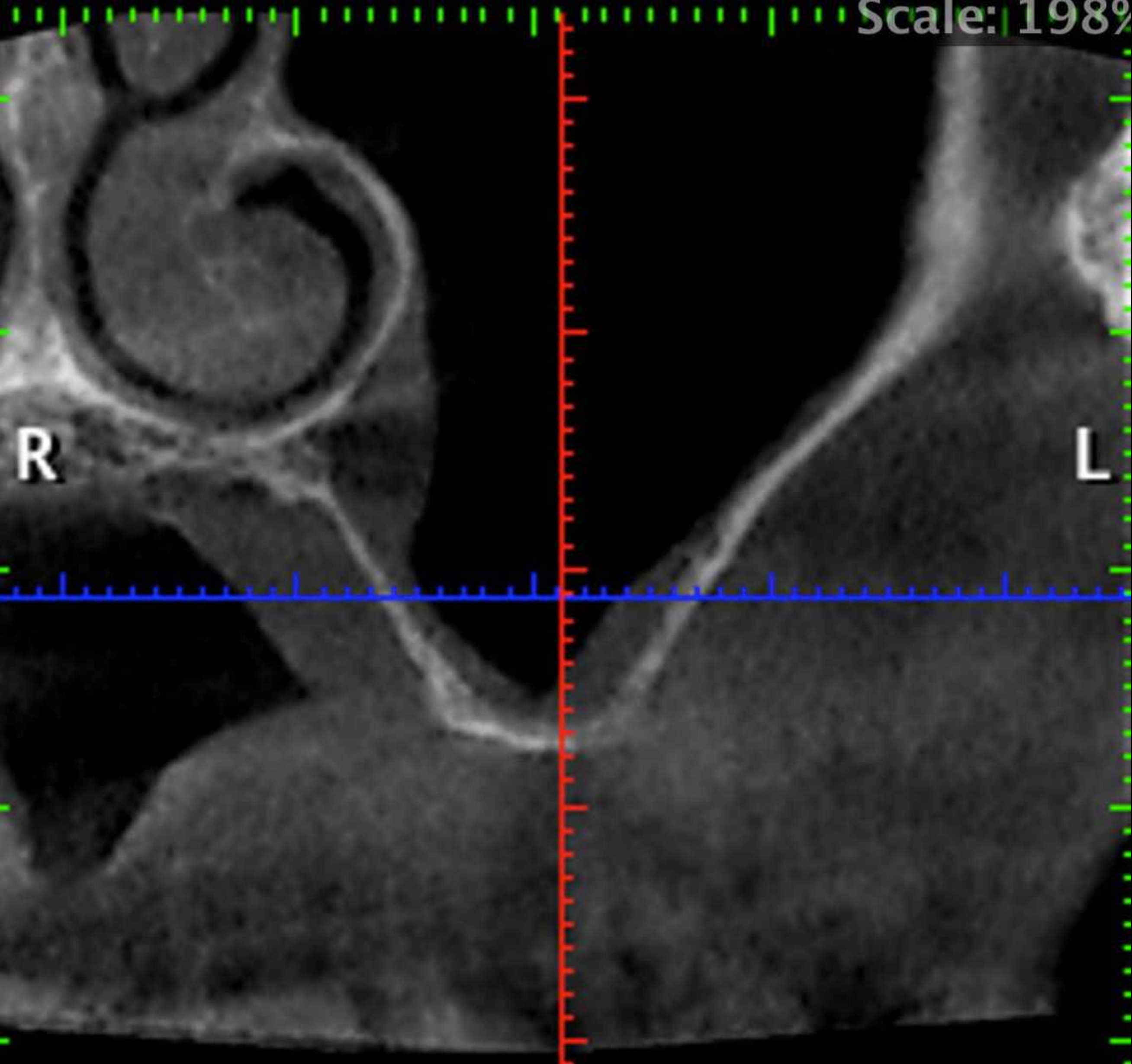


Volet Latéral

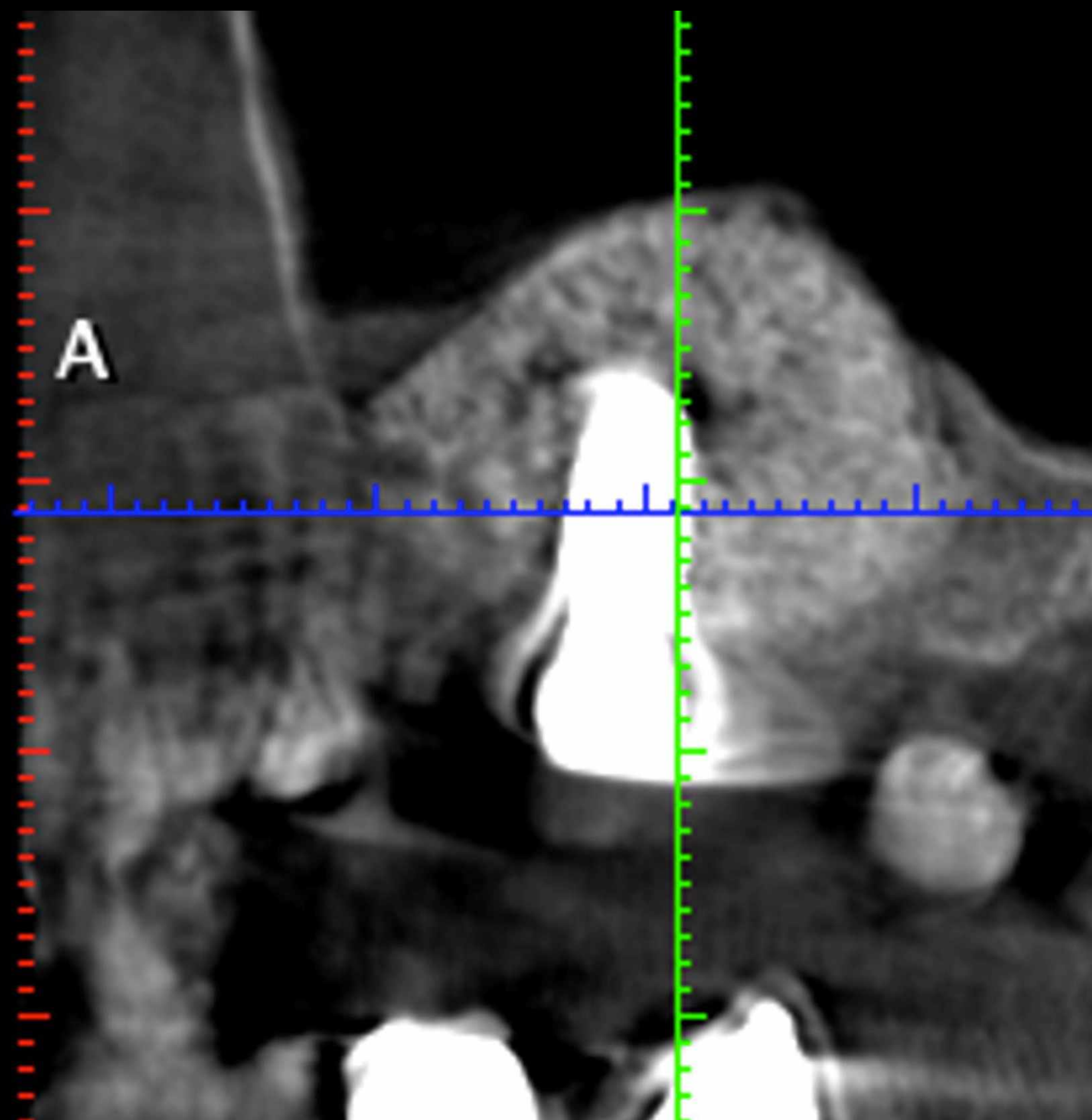
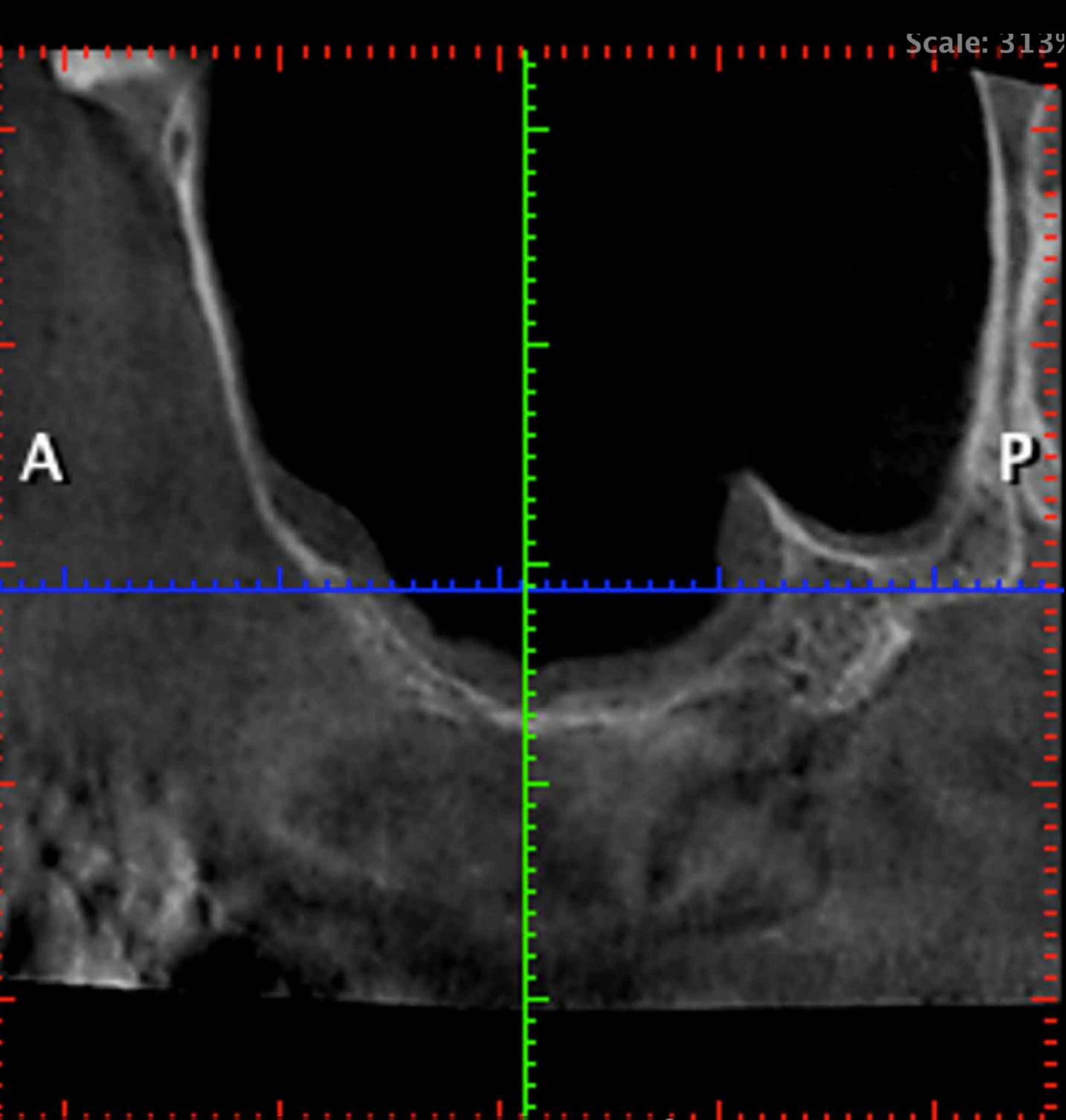
Volet Basculé



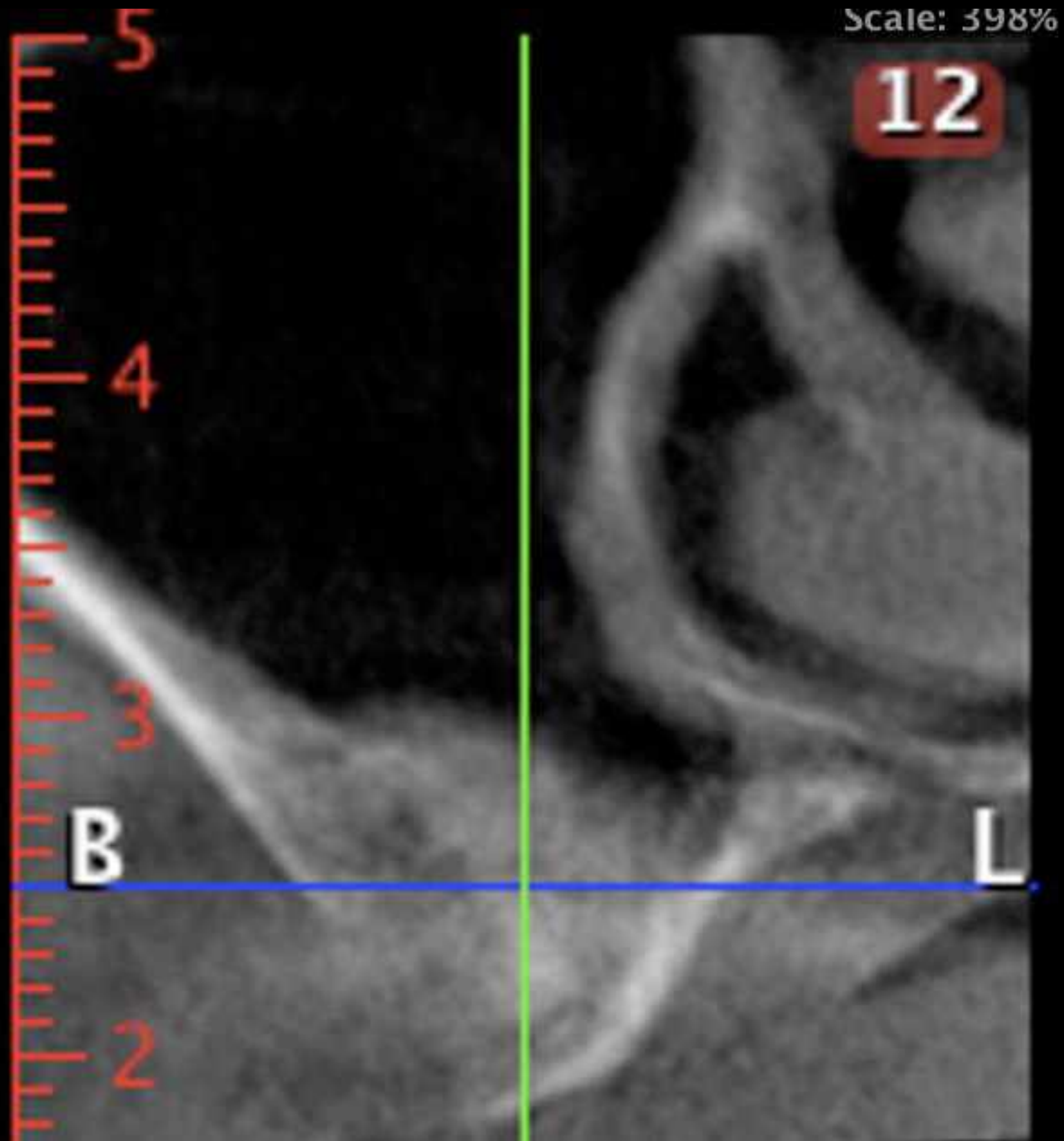Scale: 198%

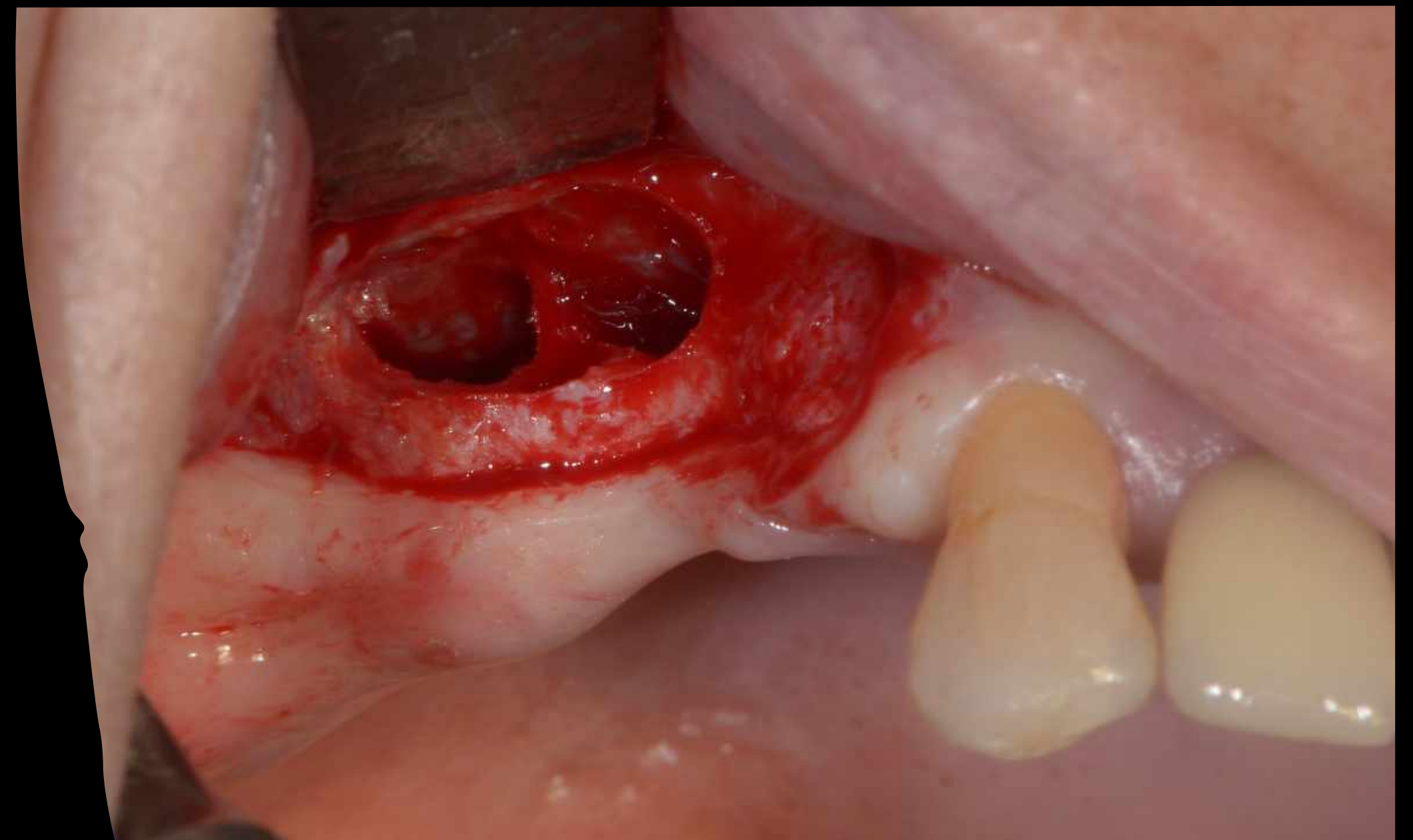
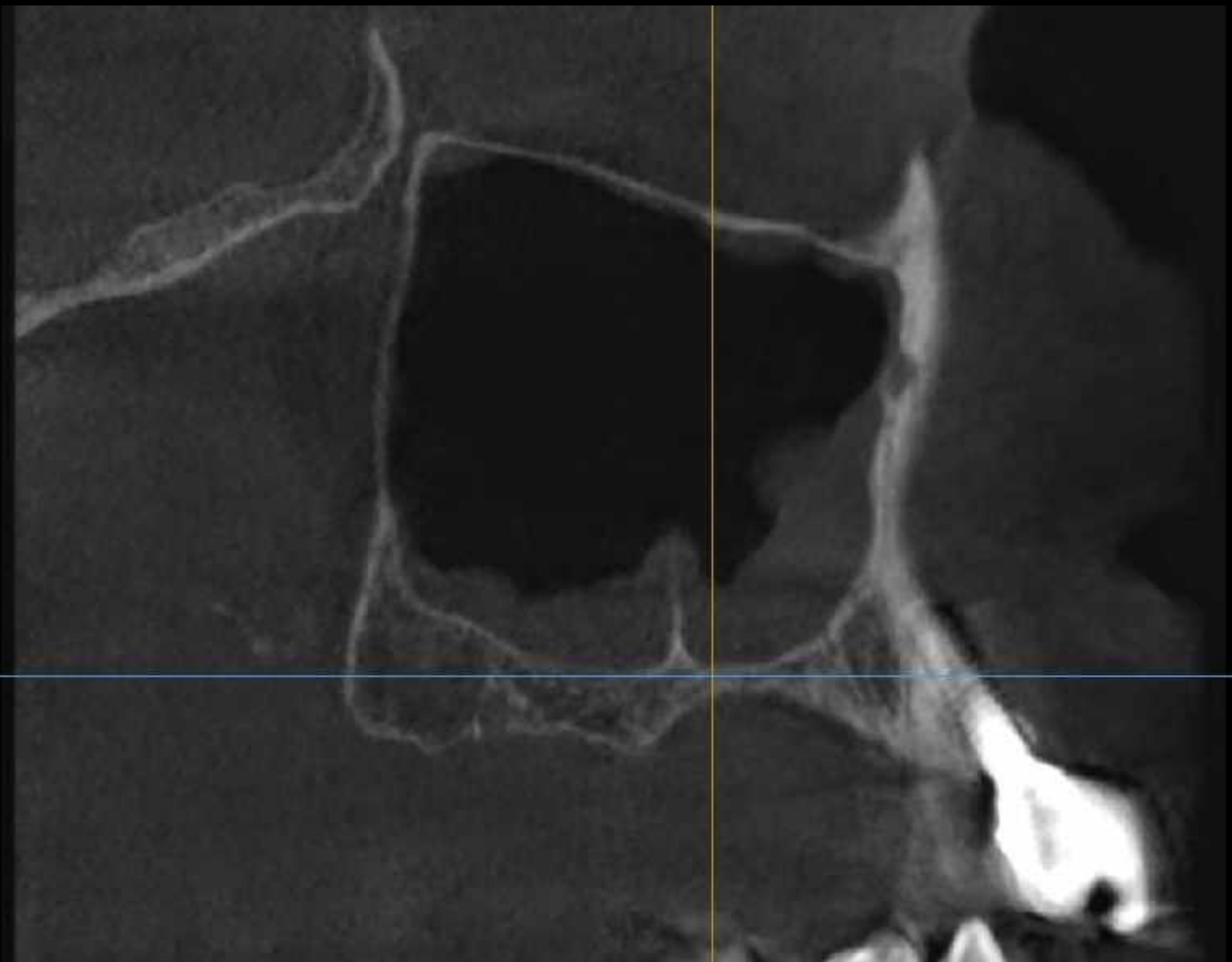
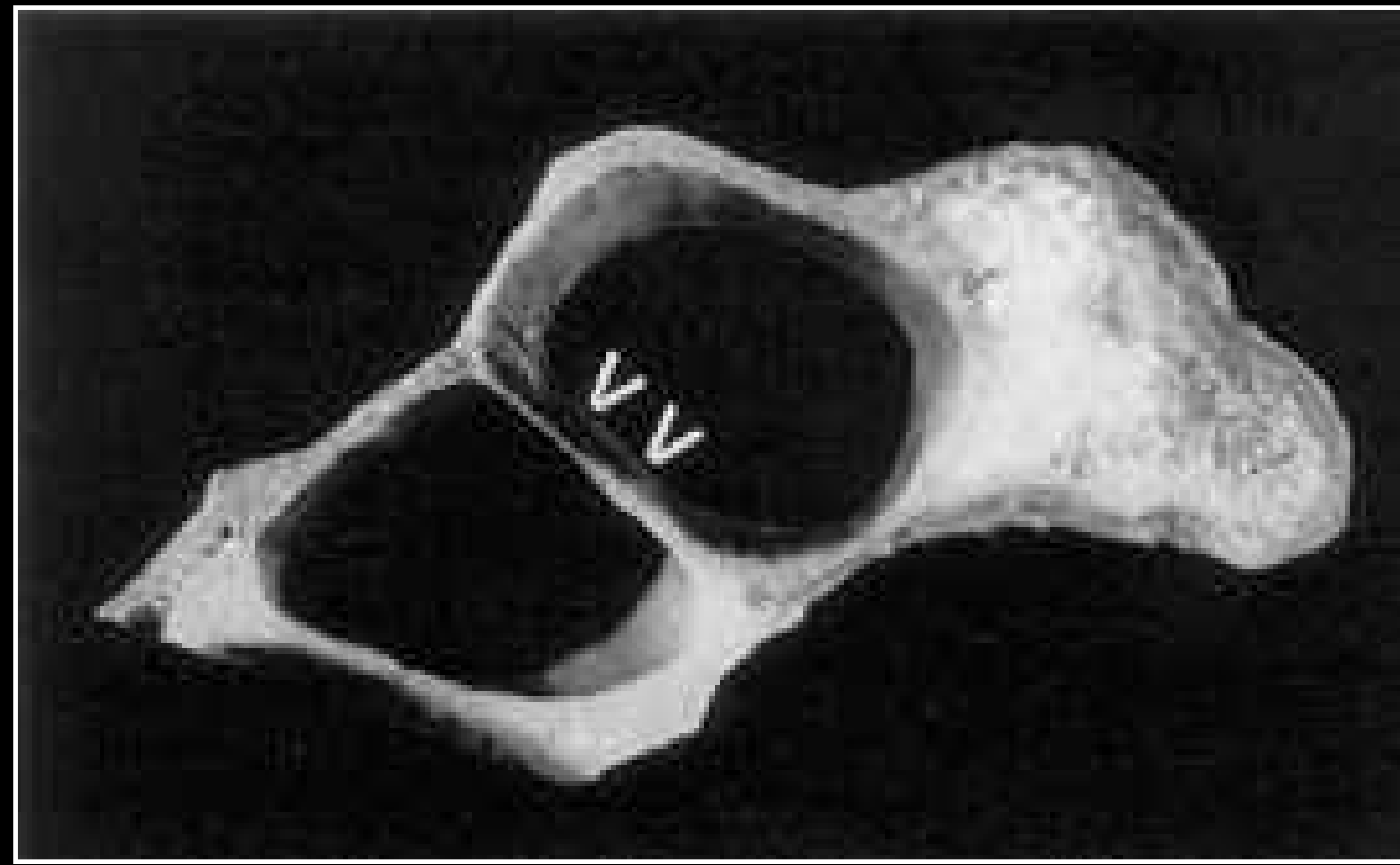


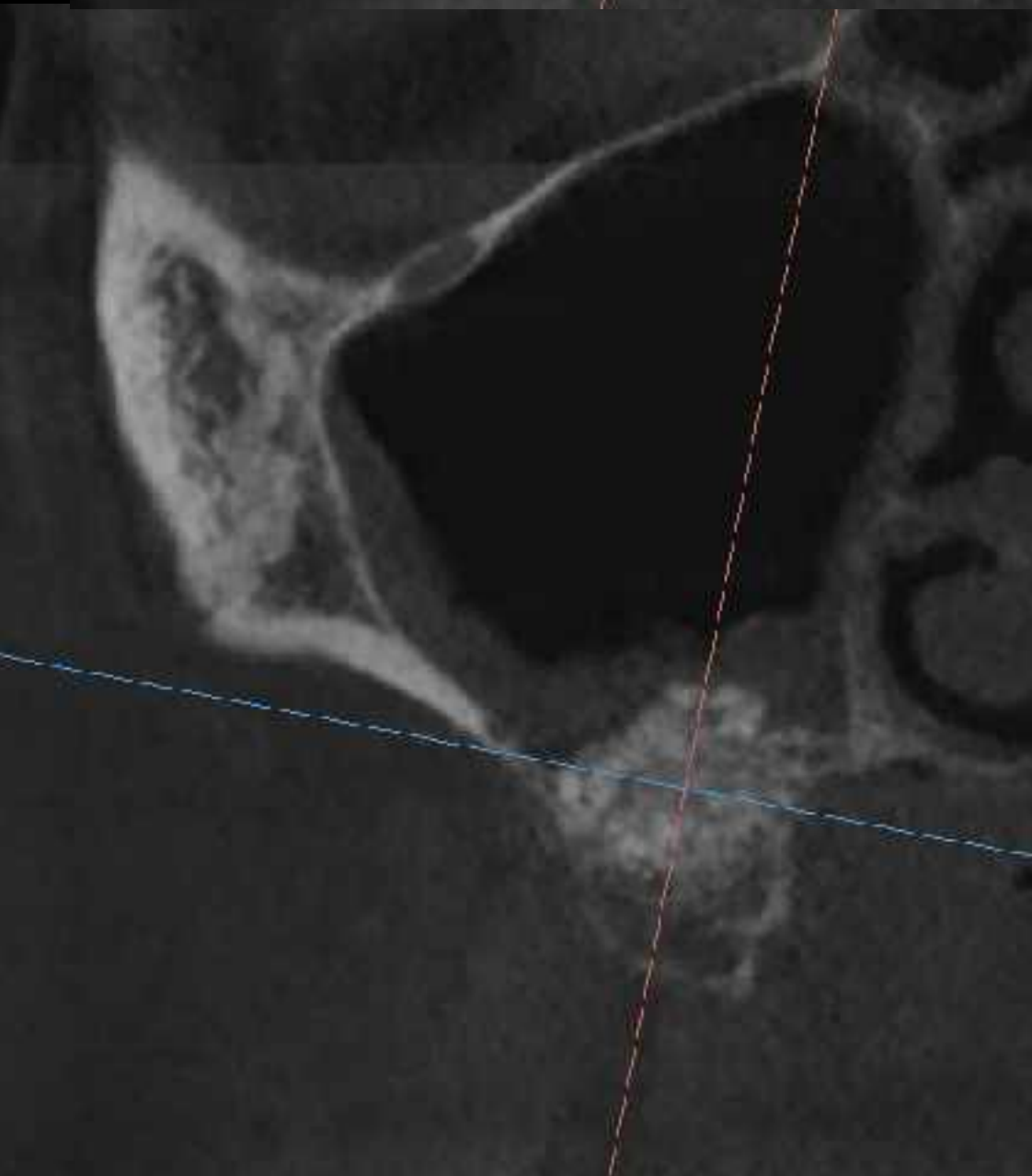
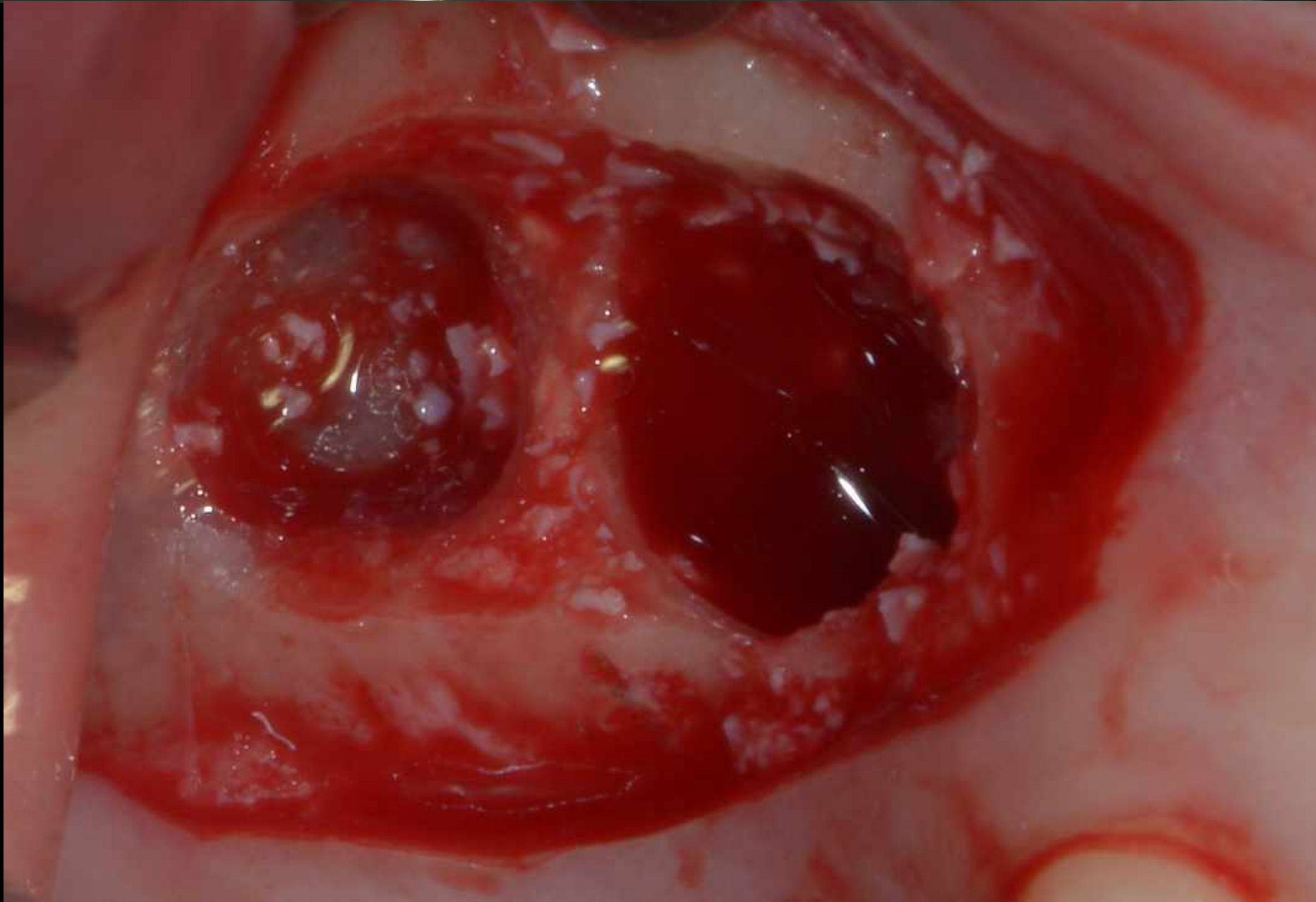
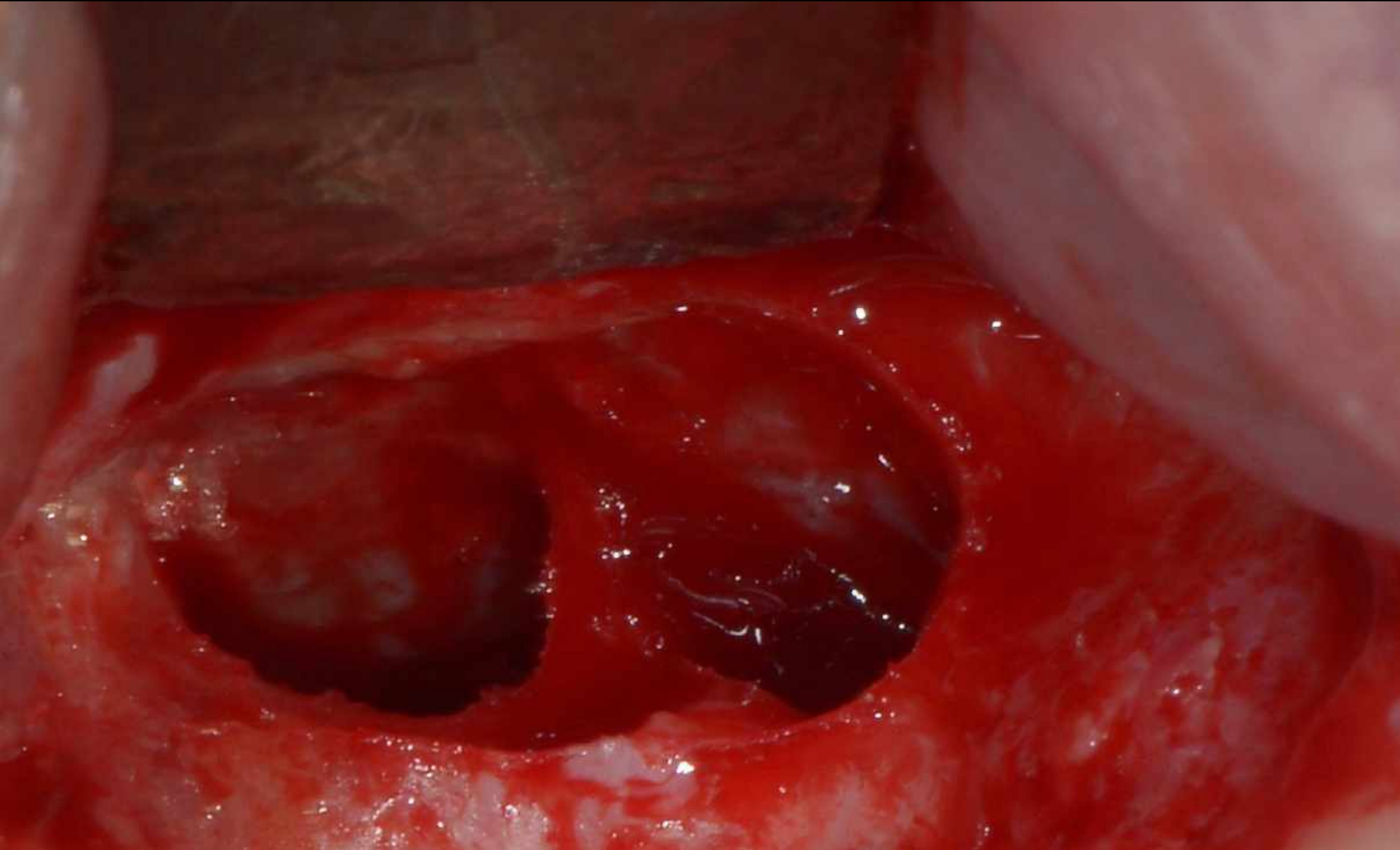
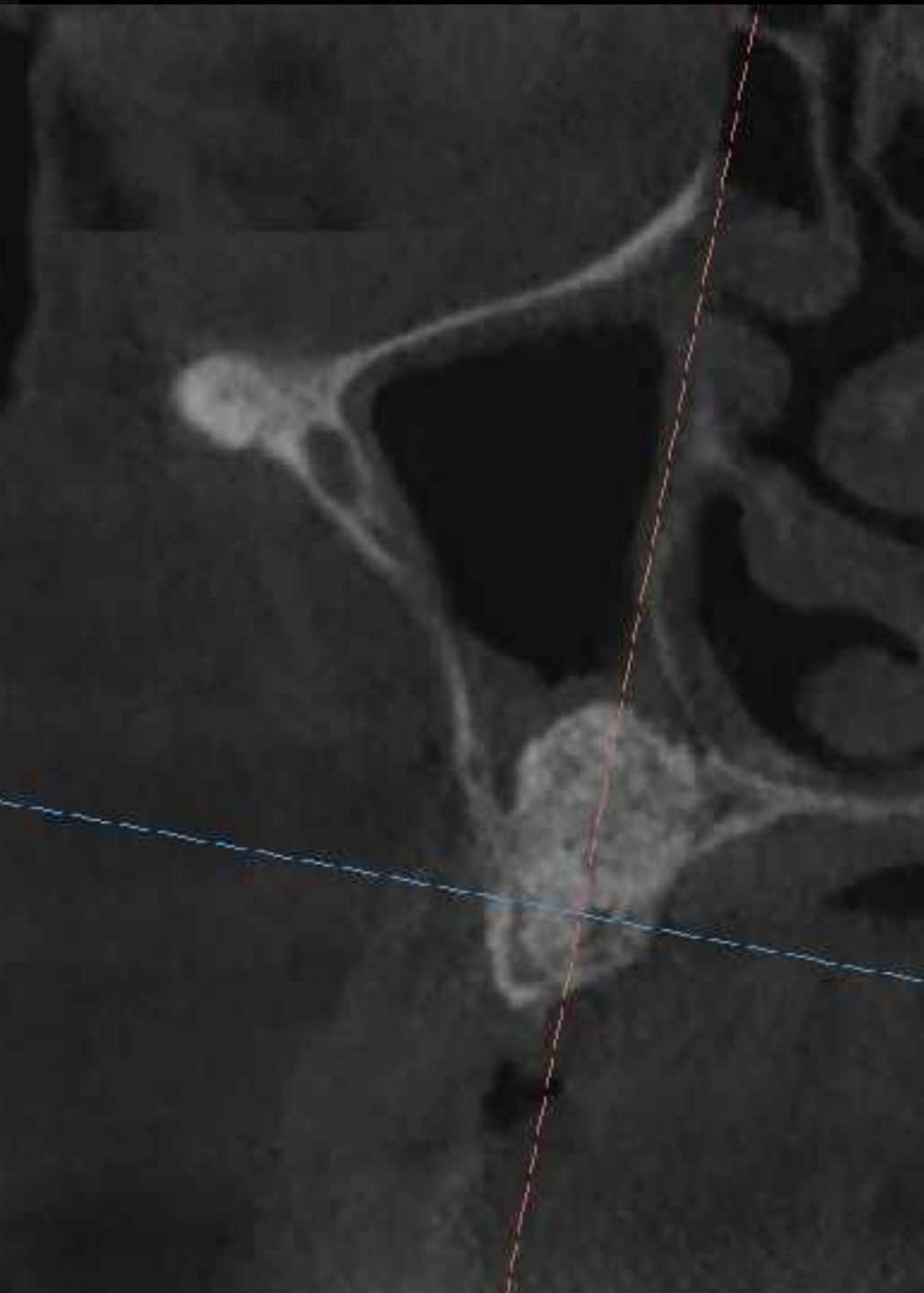
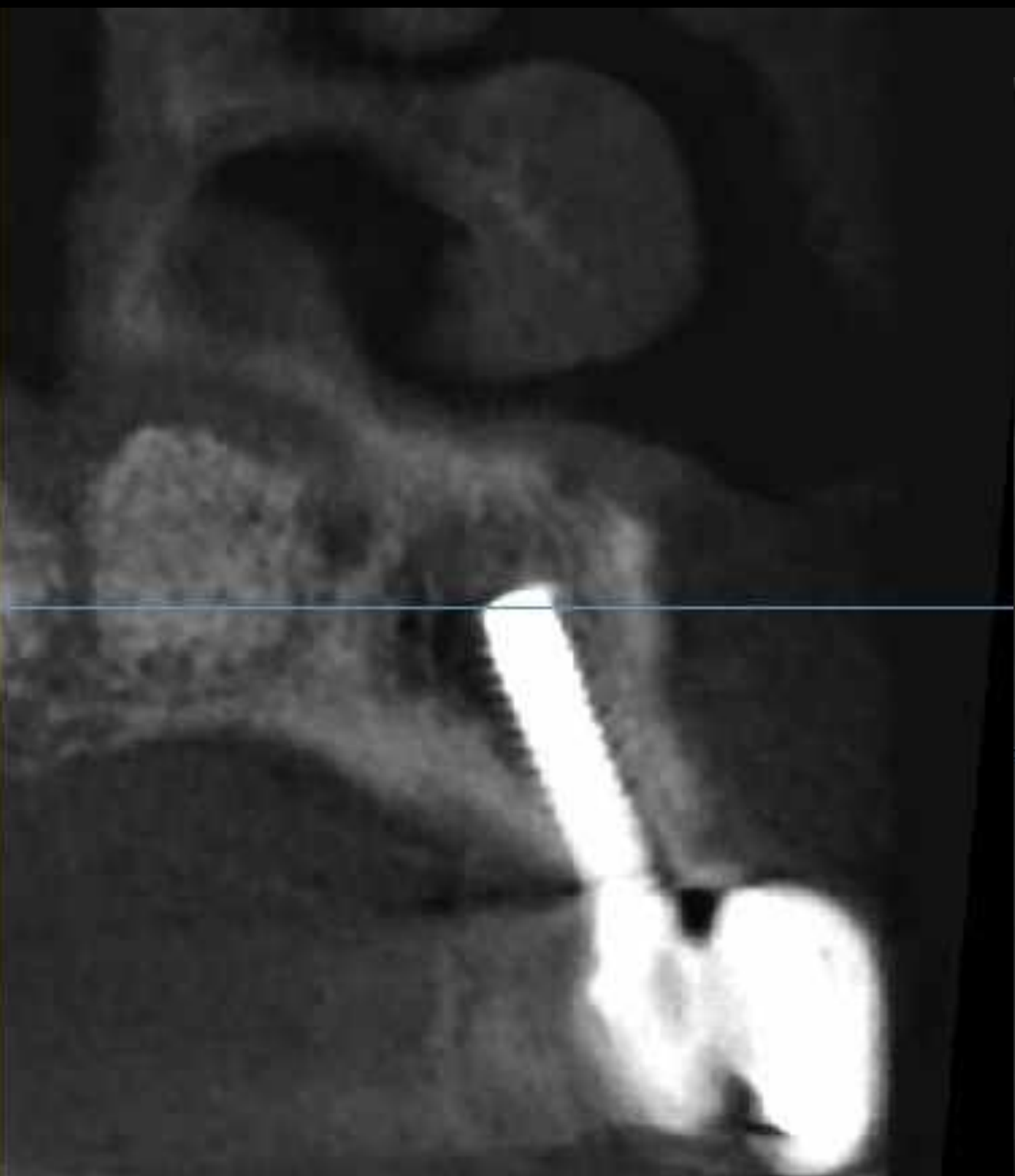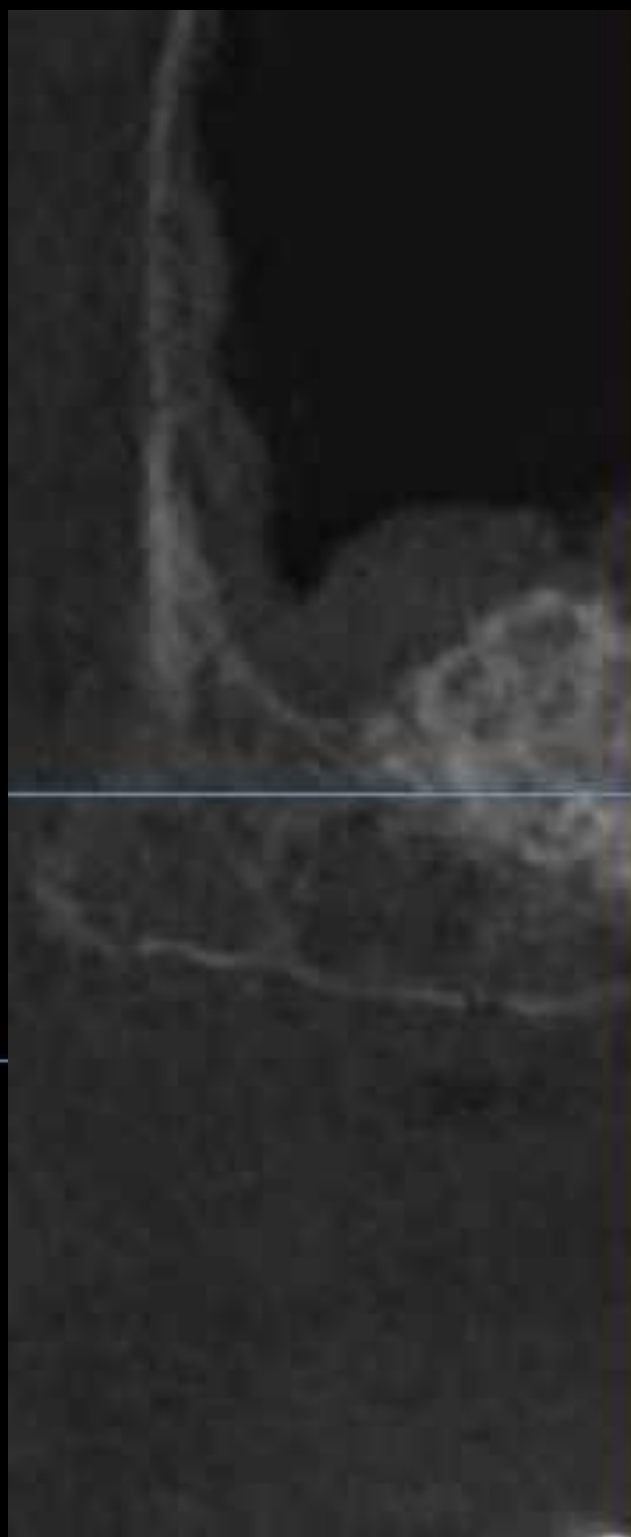
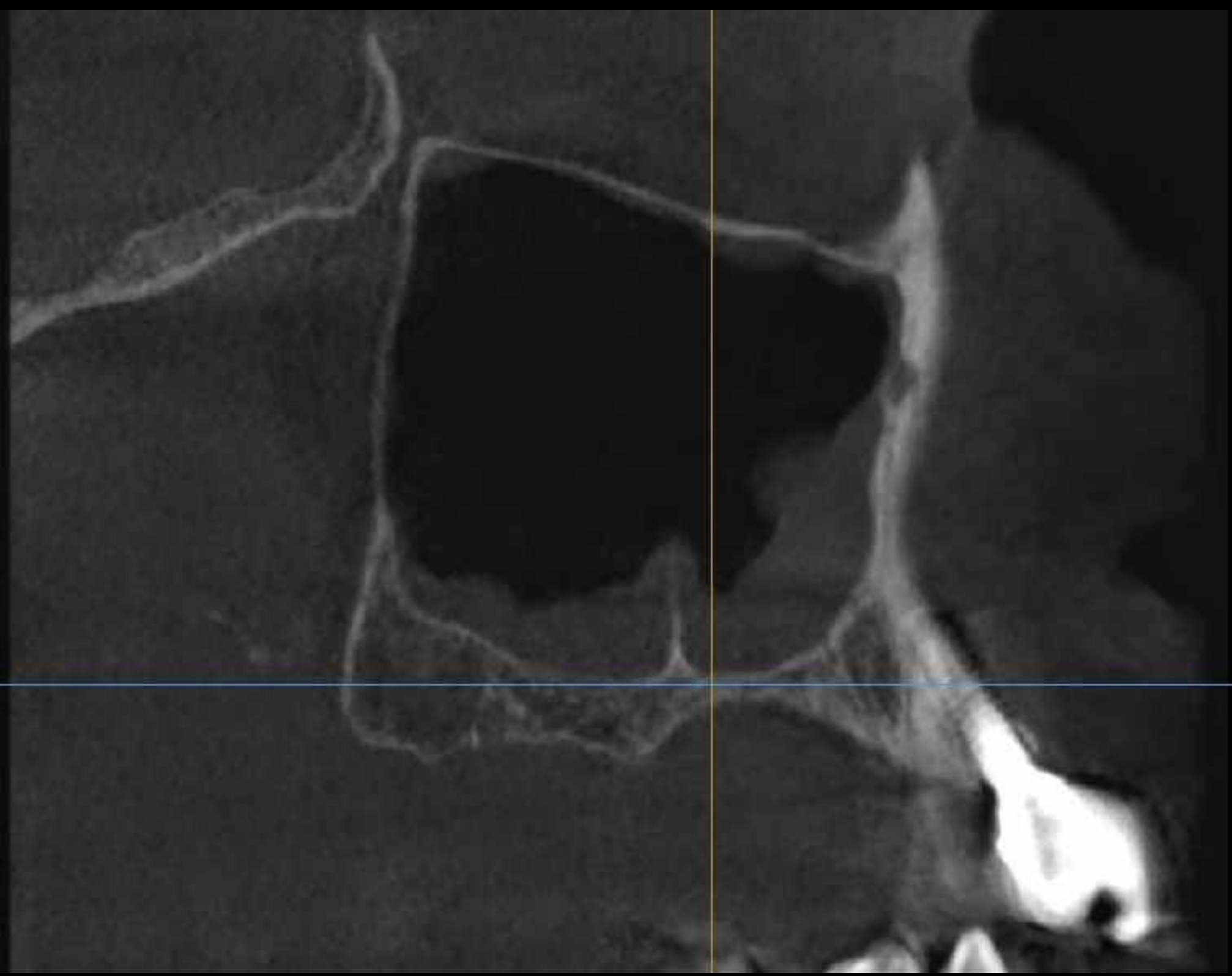
Scale: 313%



2 - GREFFE DU SINUS PAR VOILET LATERAL





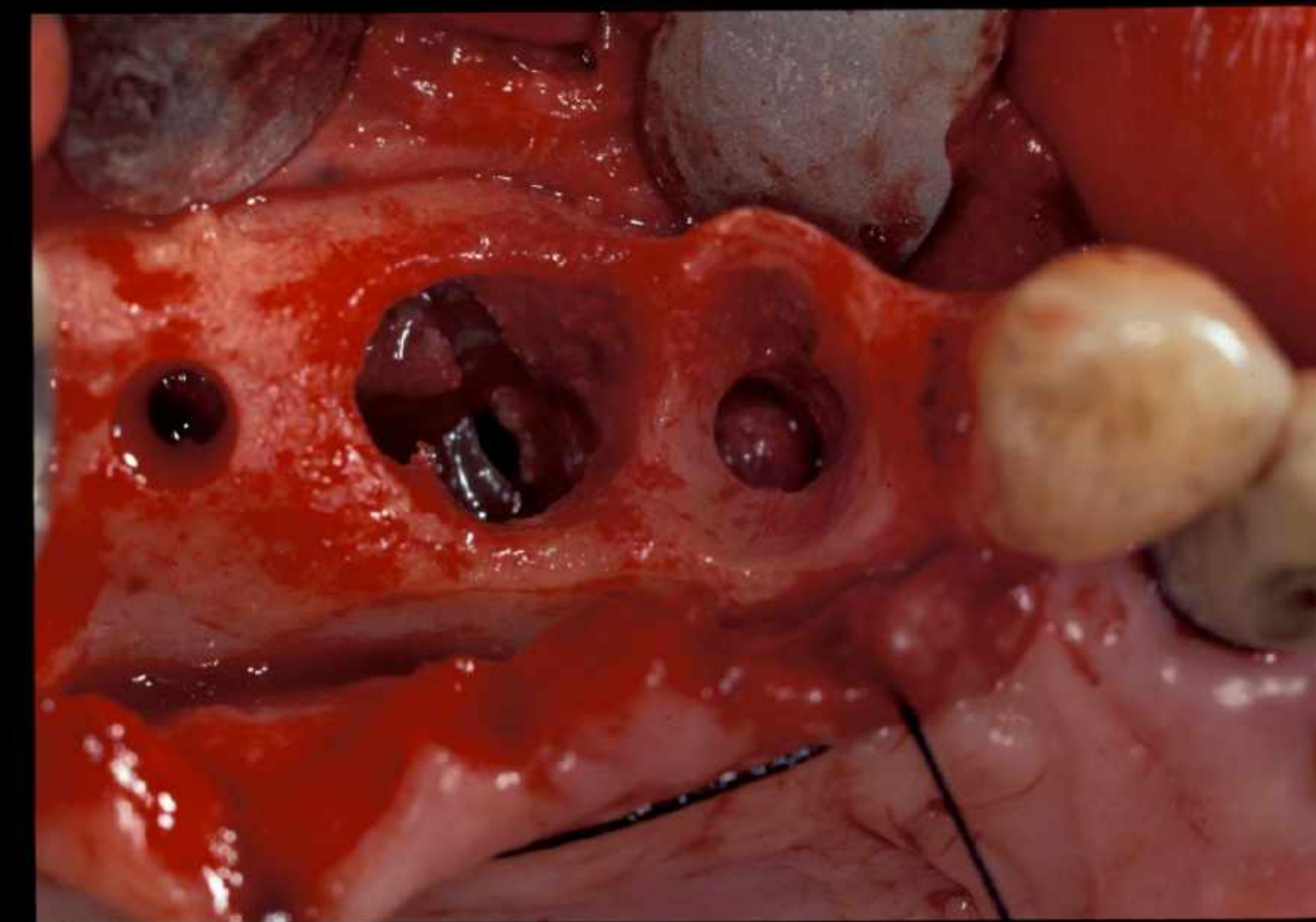
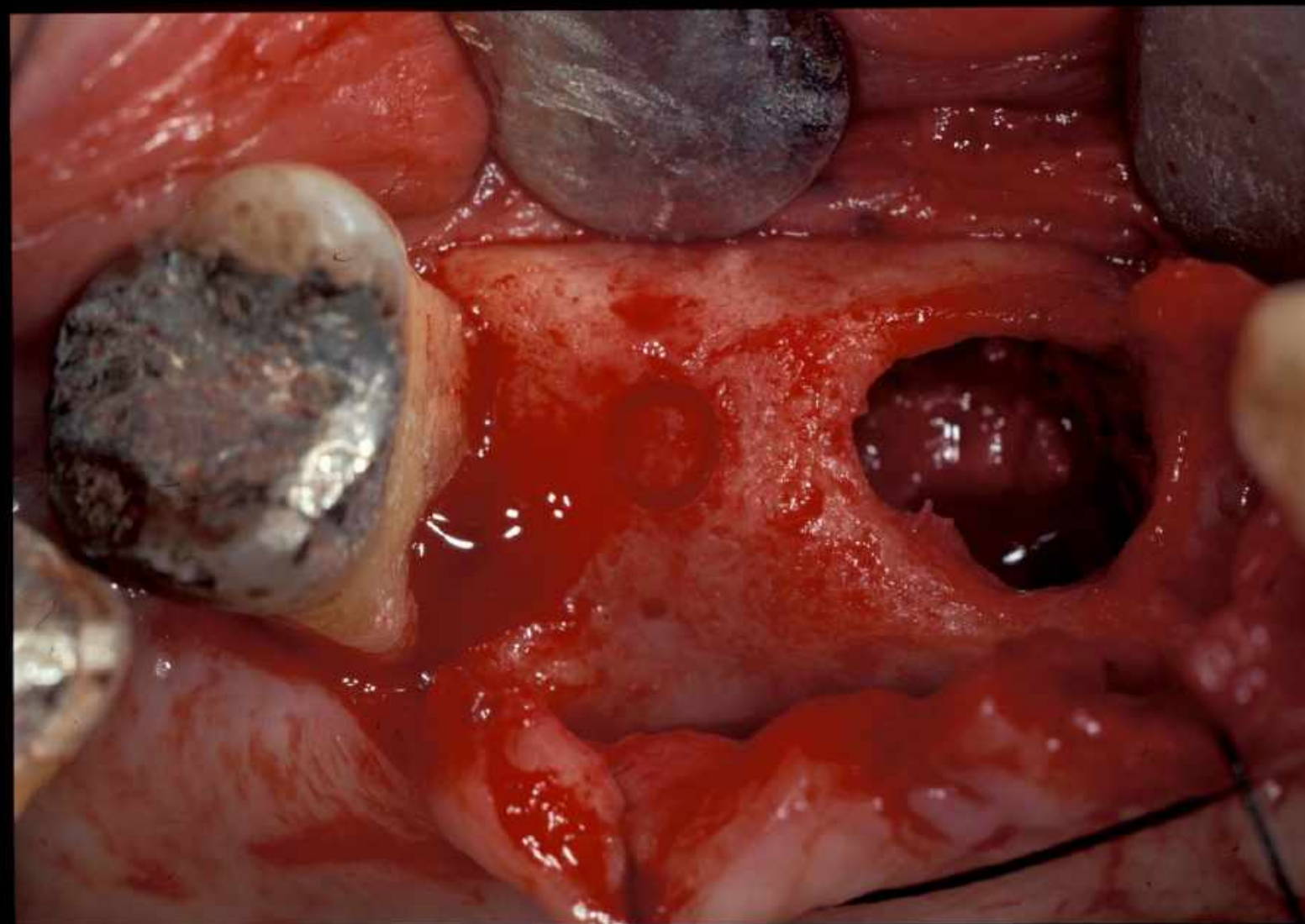
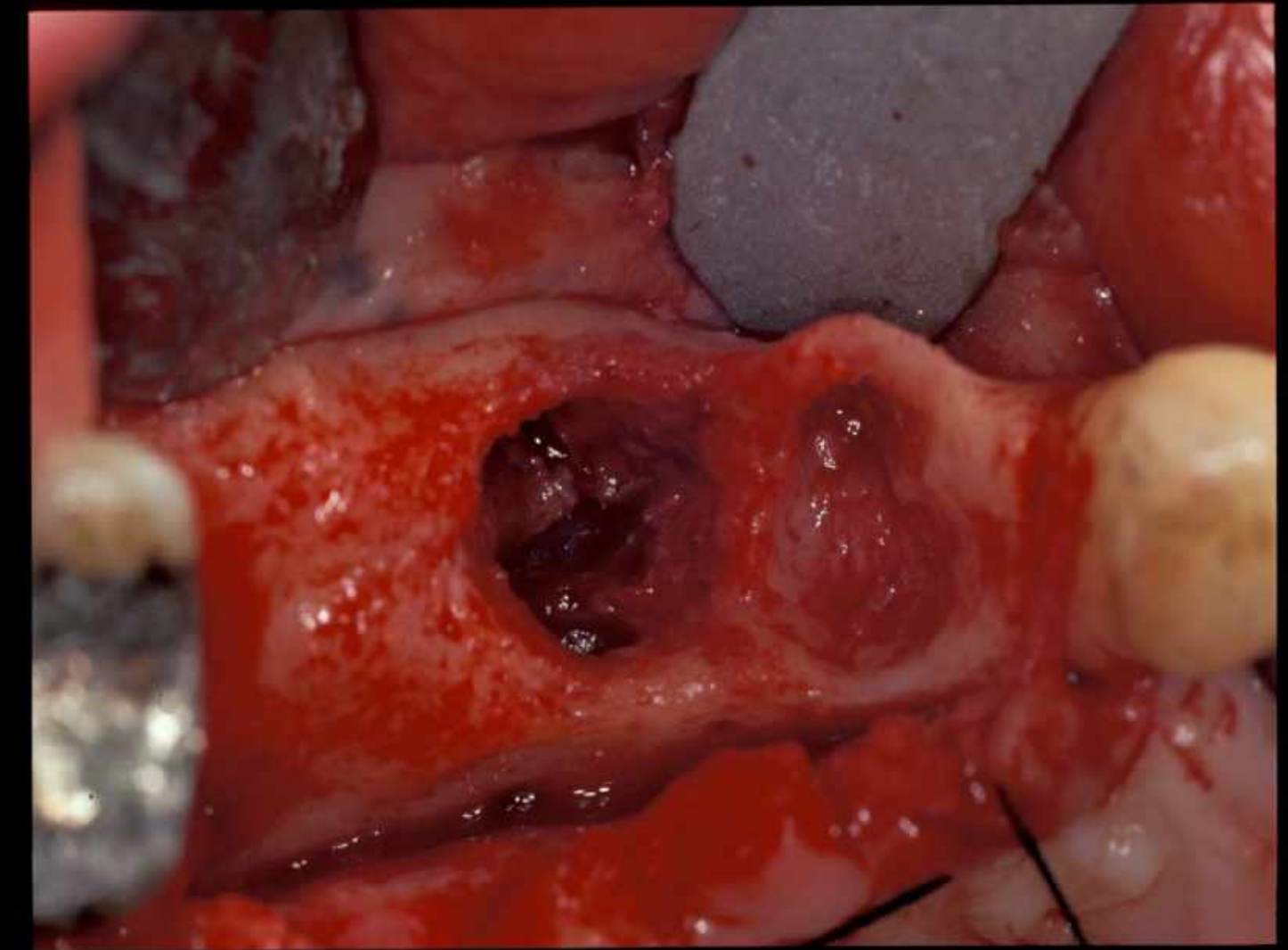
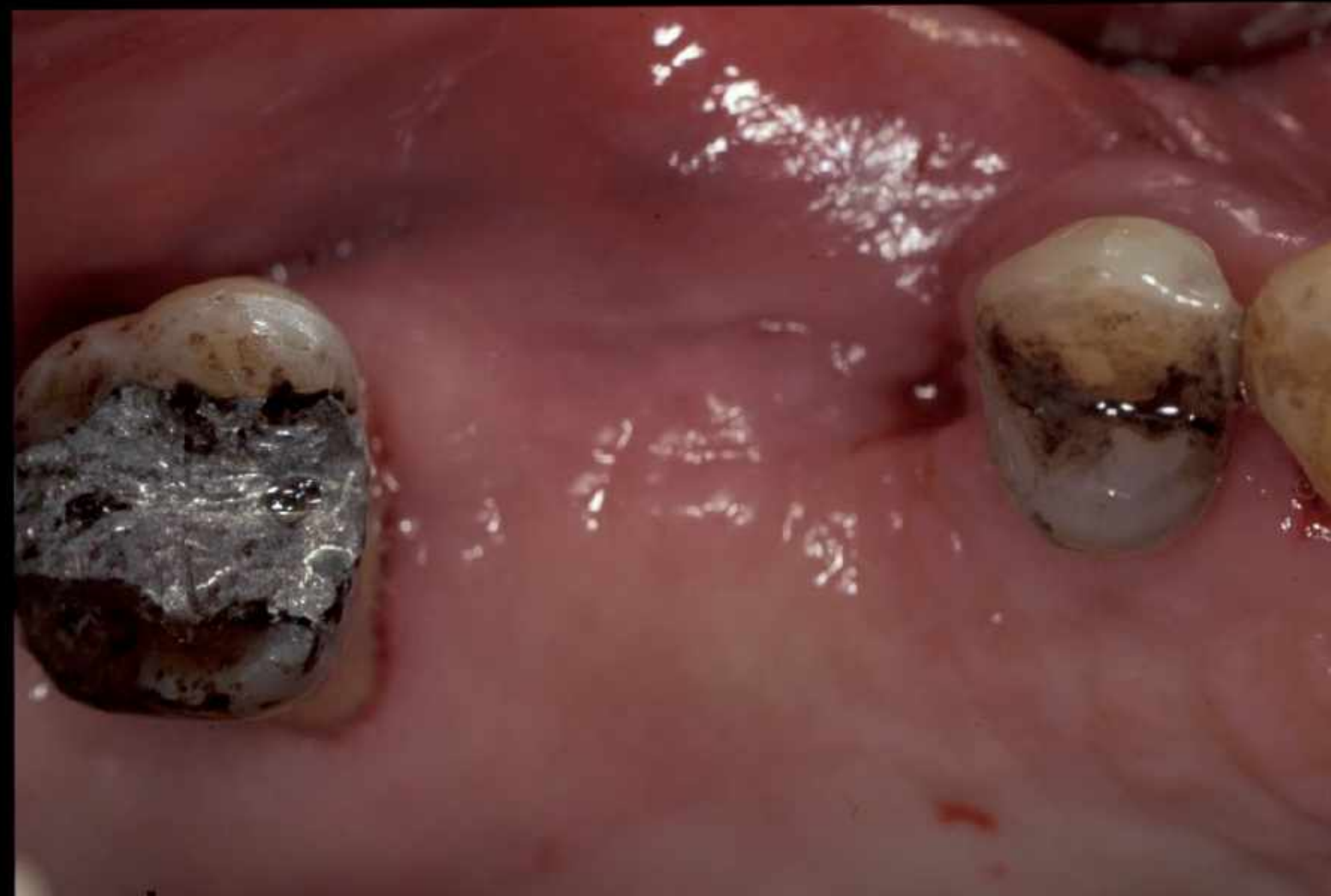

Volet Latéral

Voie Crestale élargie

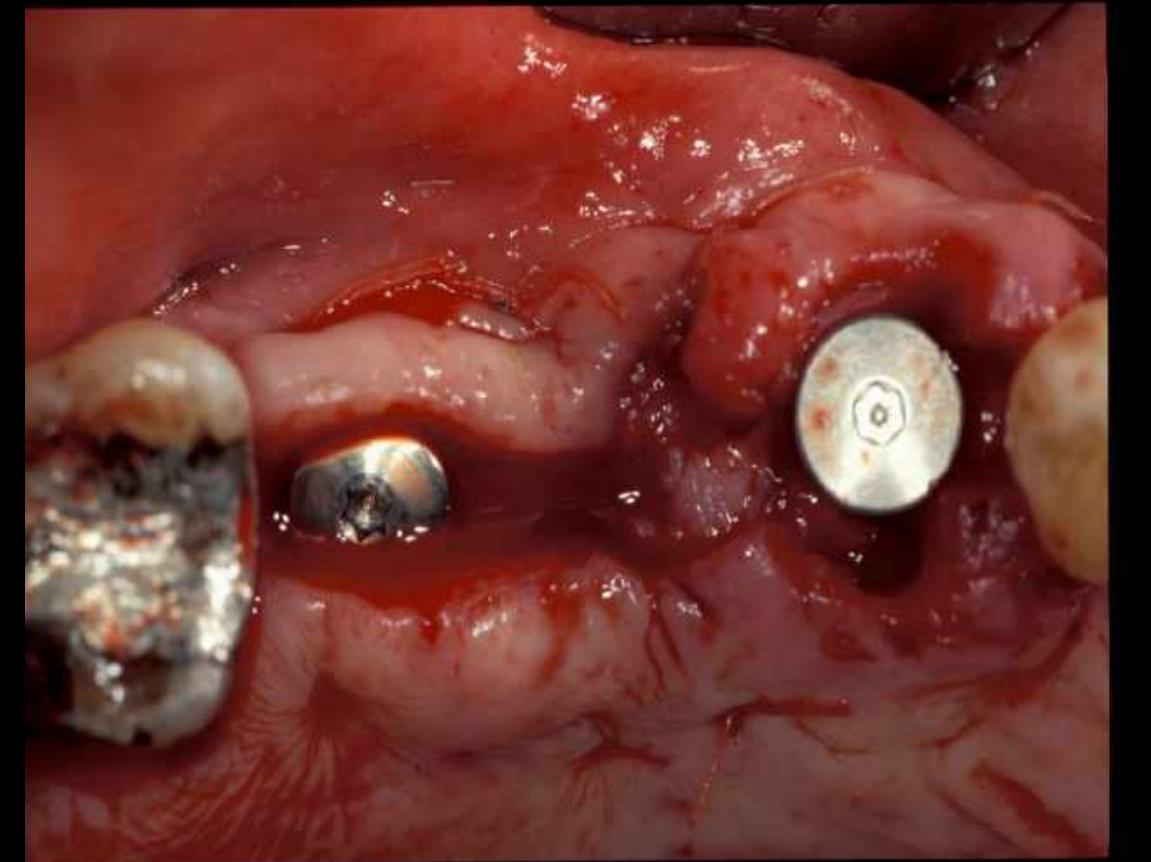
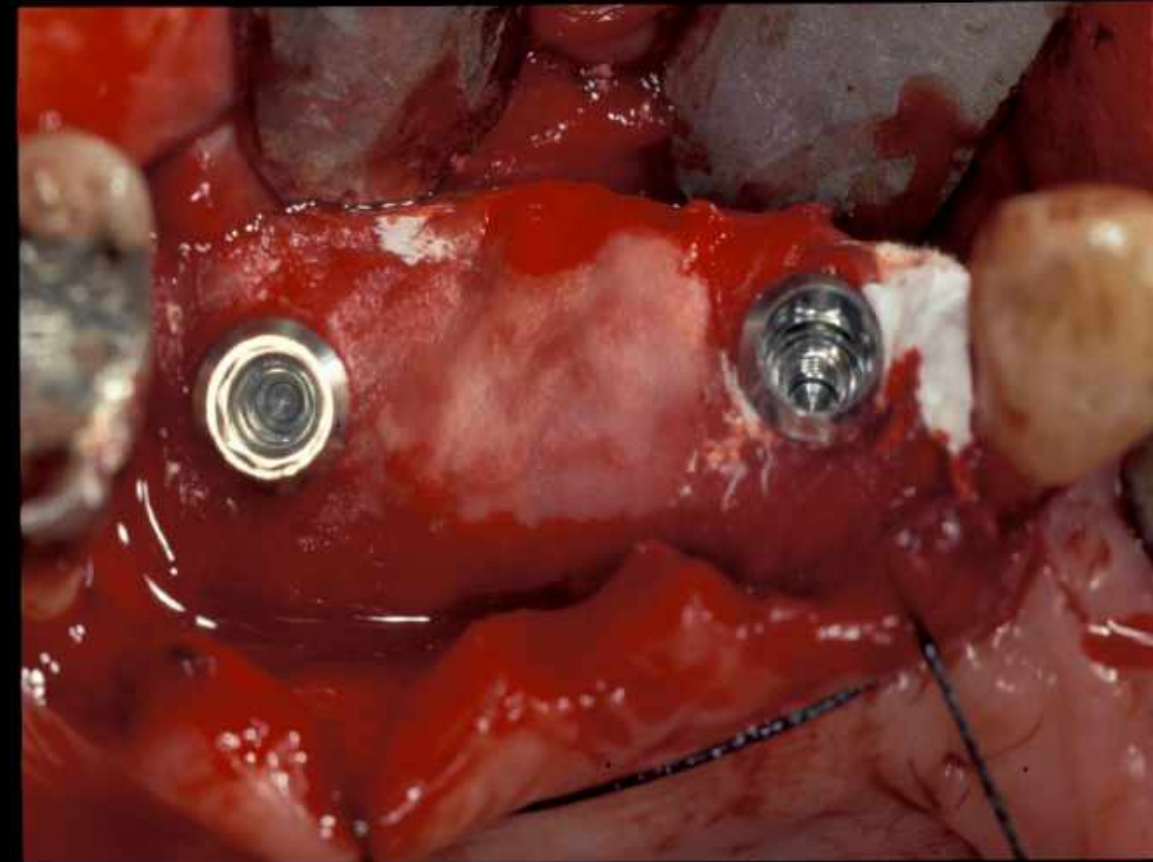
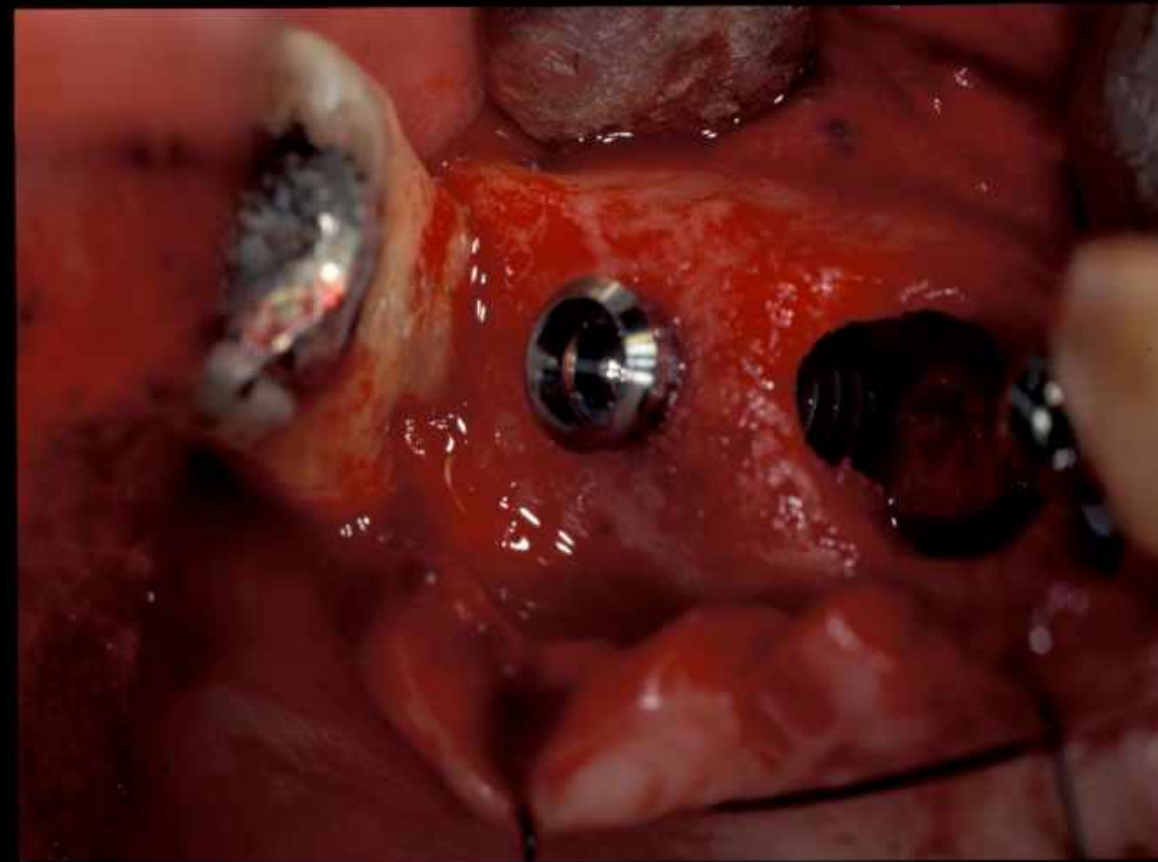
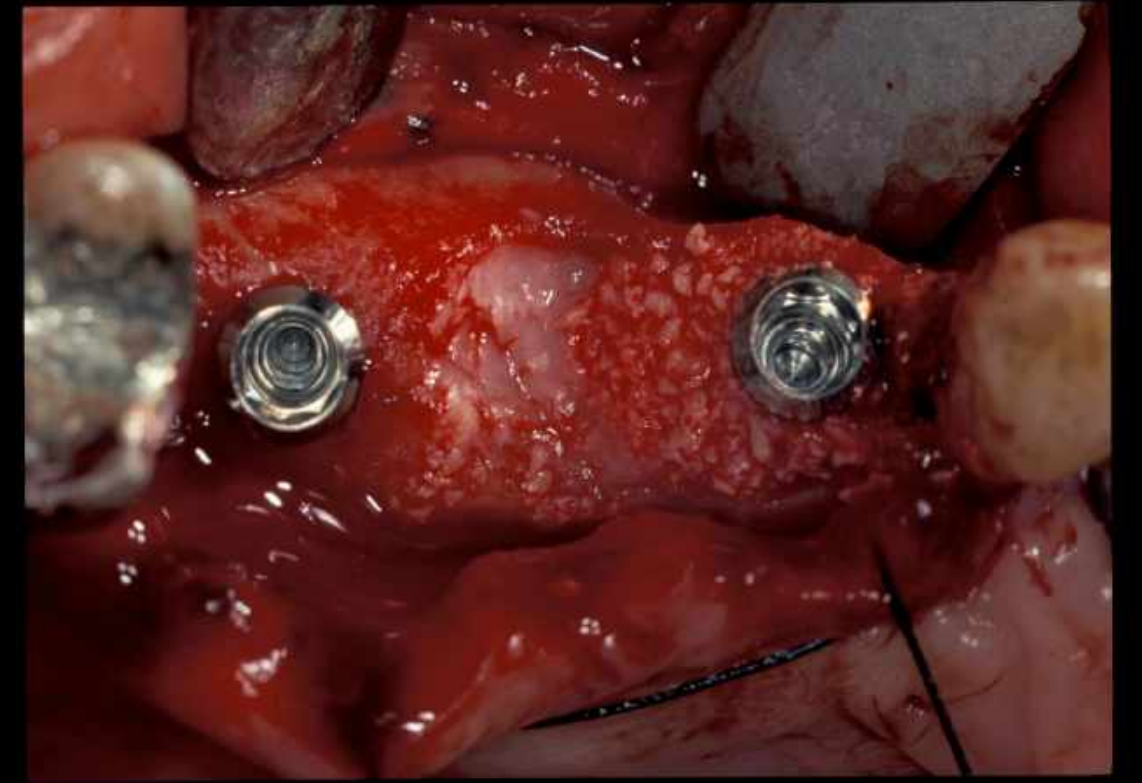
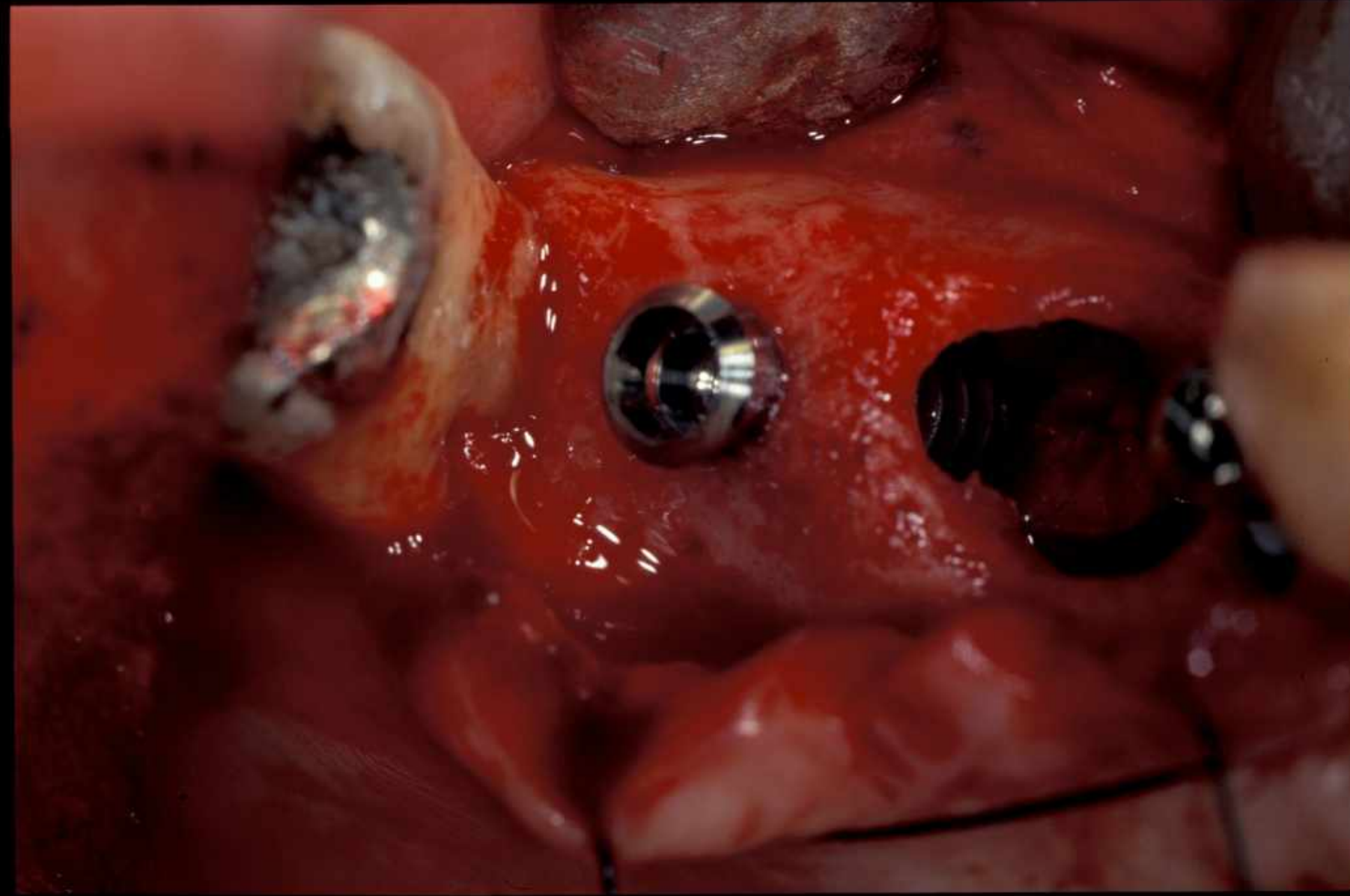
Indication :

Crête très large
Site d'extraction
muqueuse épaisse
association ostéotomes



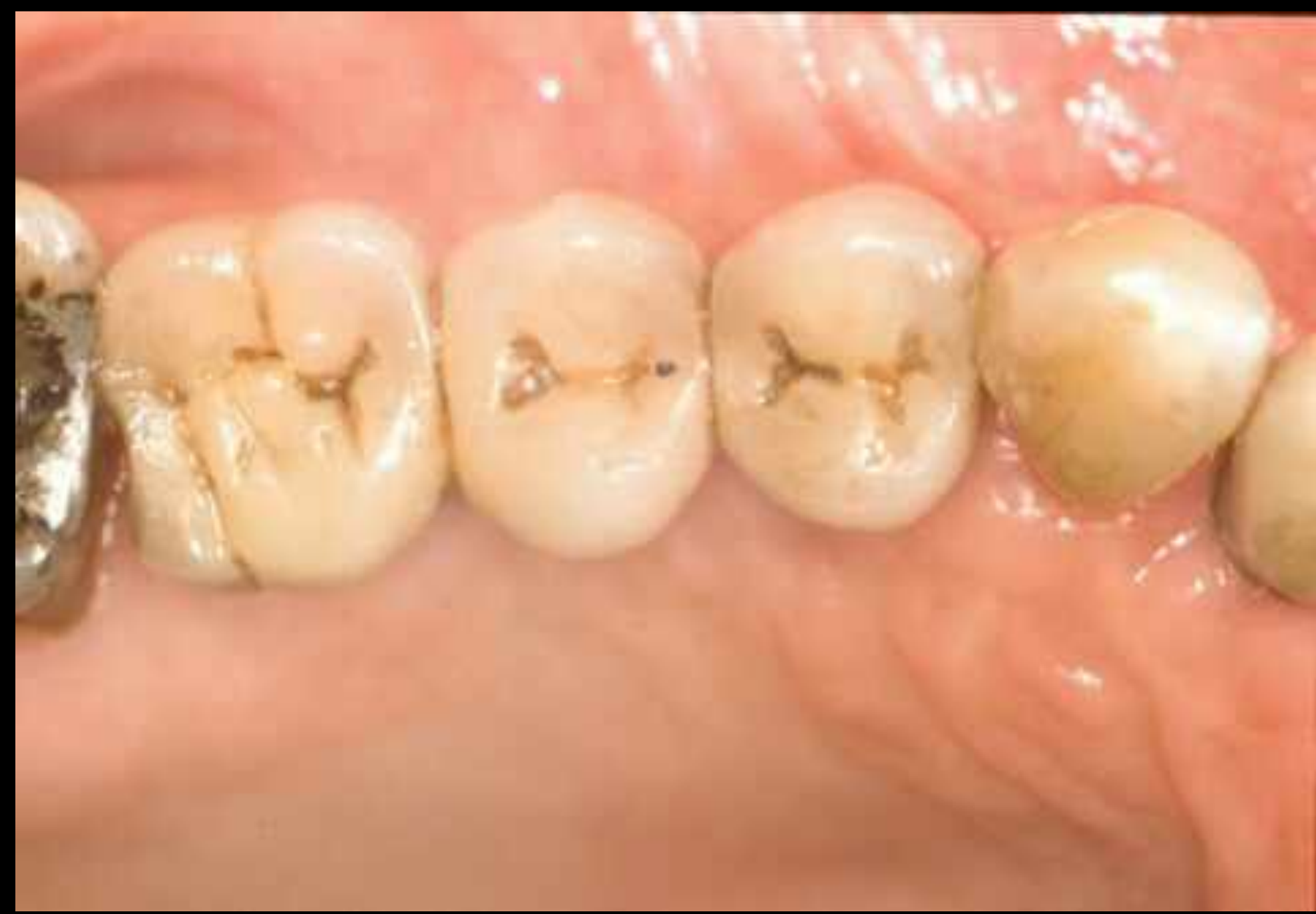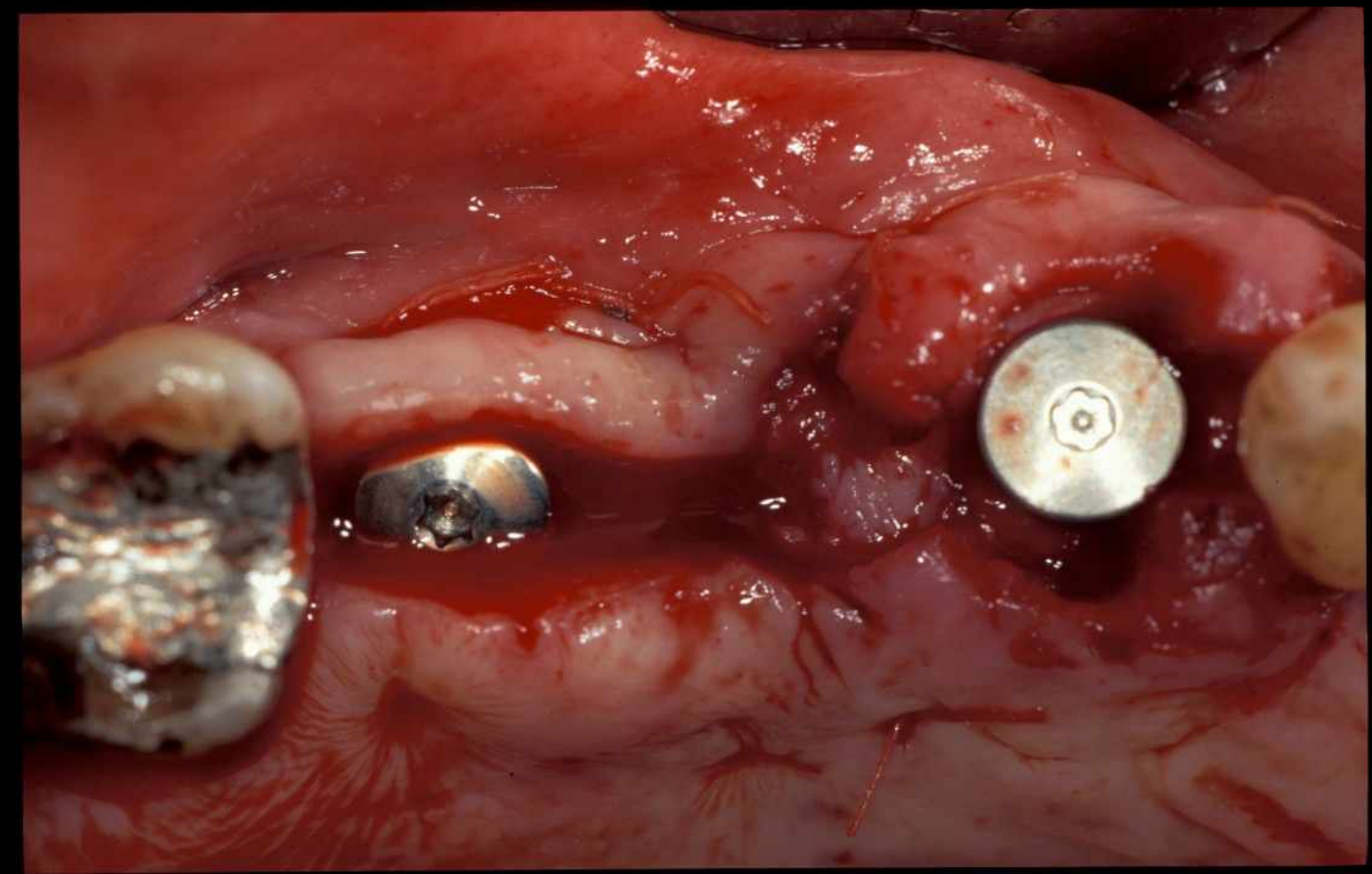
Volet Latéral

Voie Crestale élargie



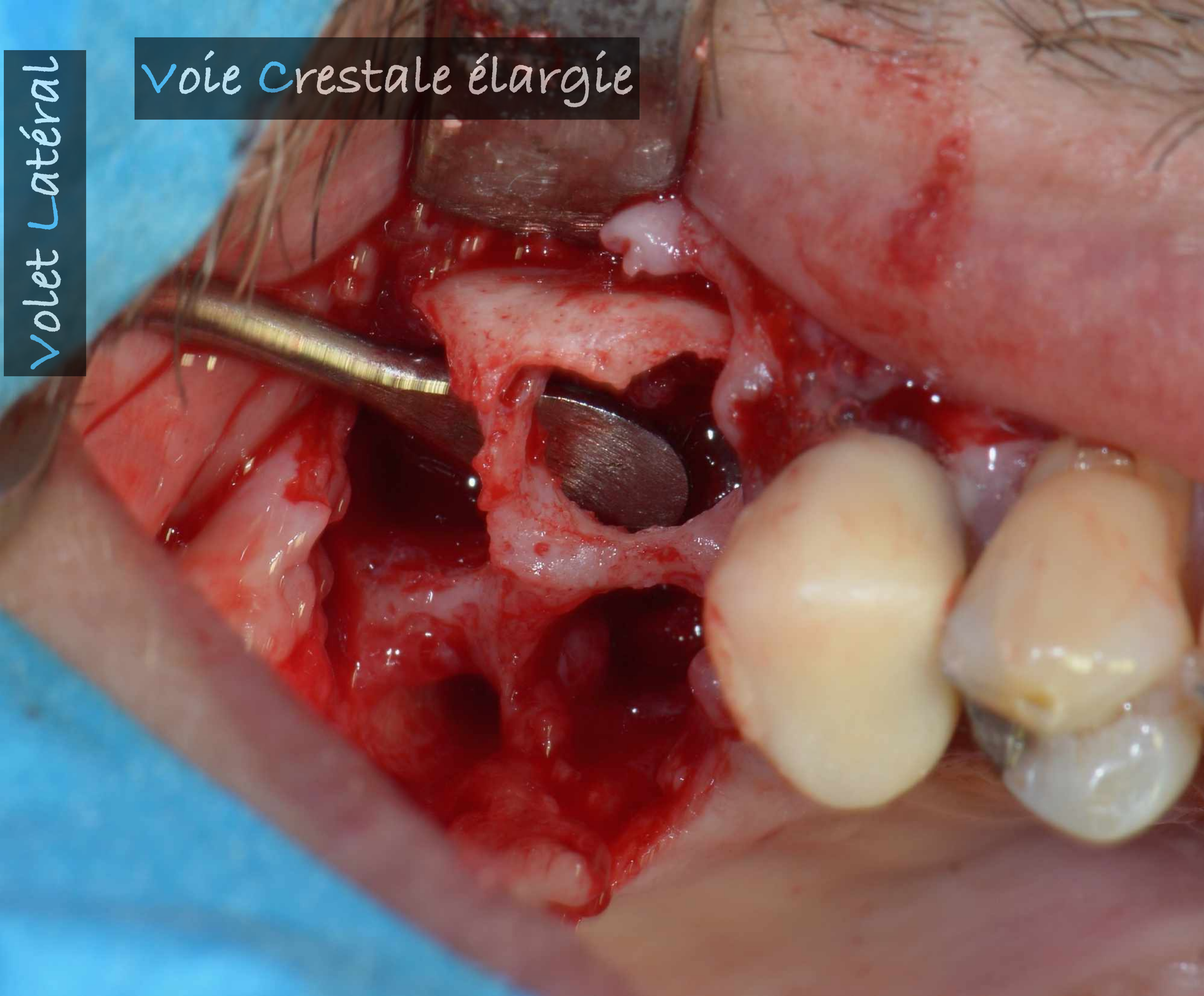Volet Latéral

Voie Crestale élargie



Volet Latéral

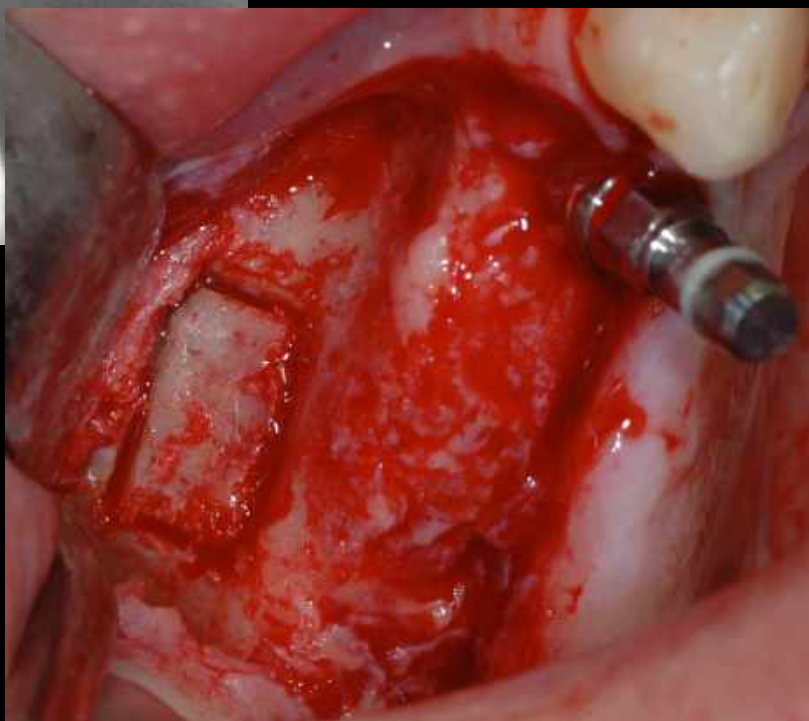
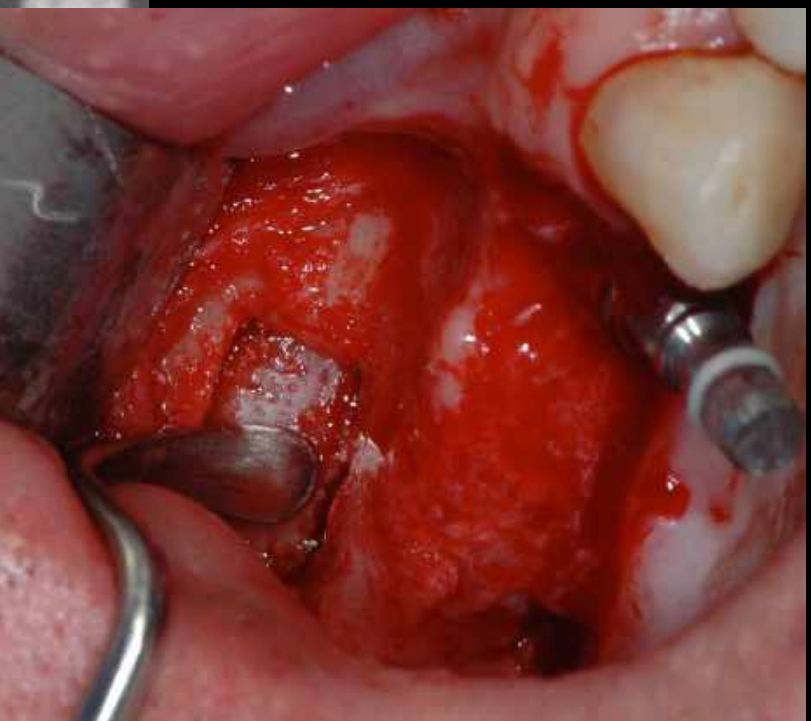
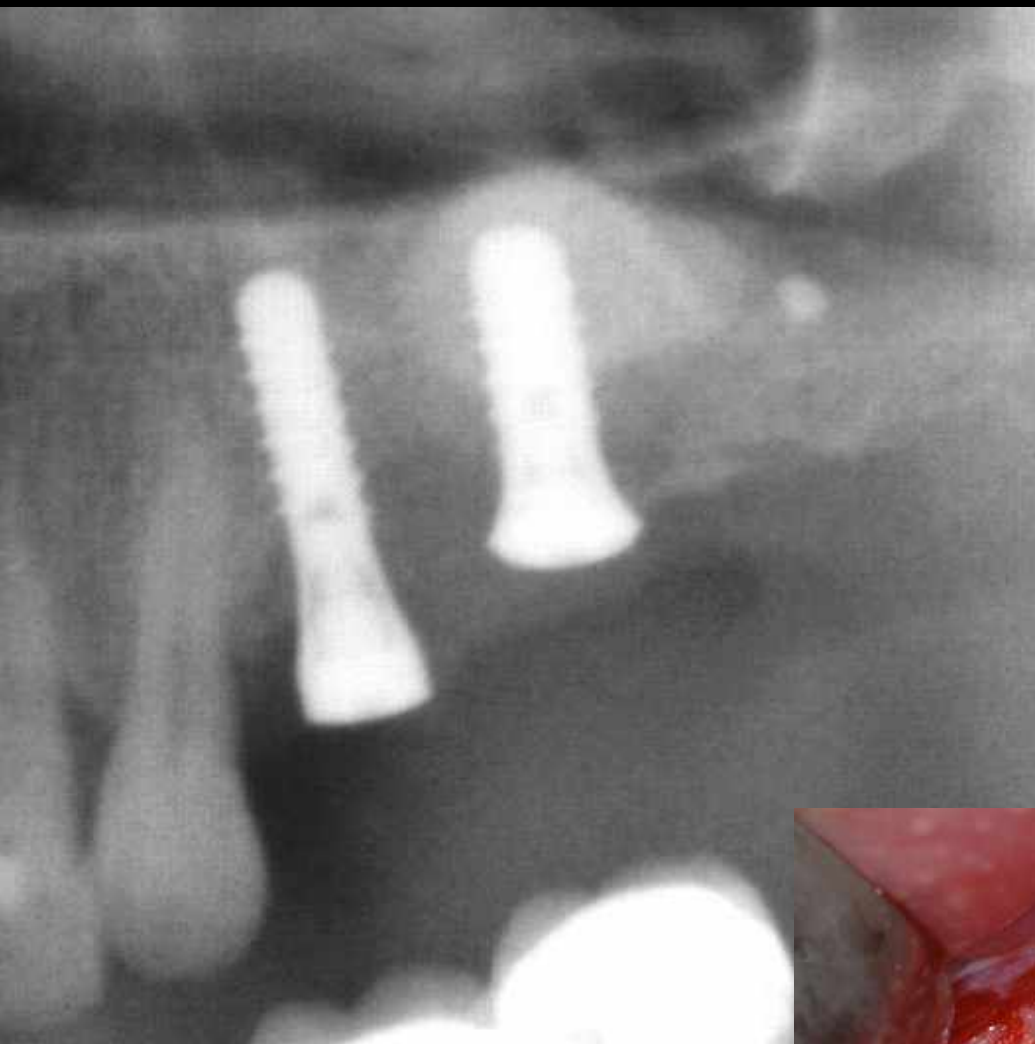
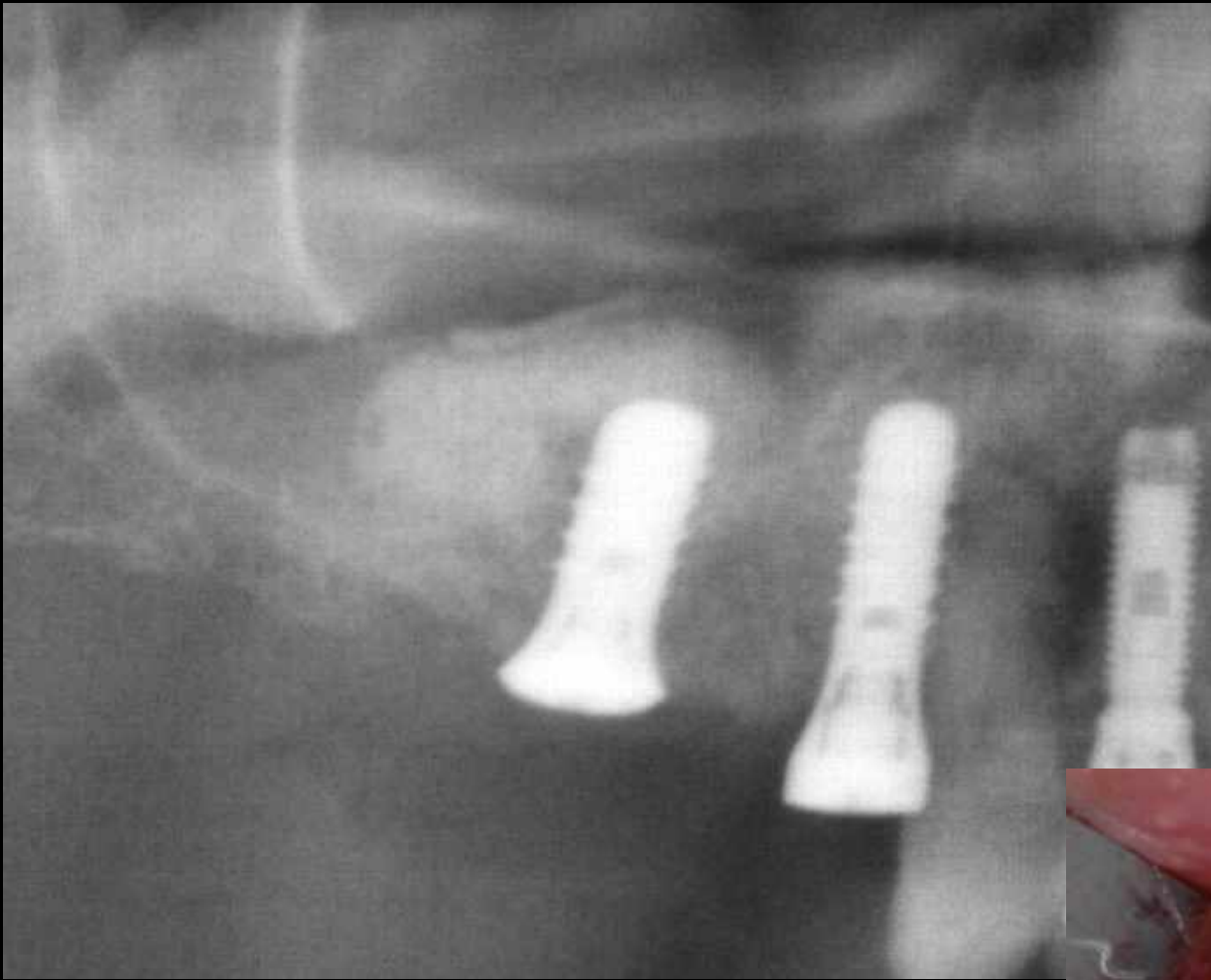
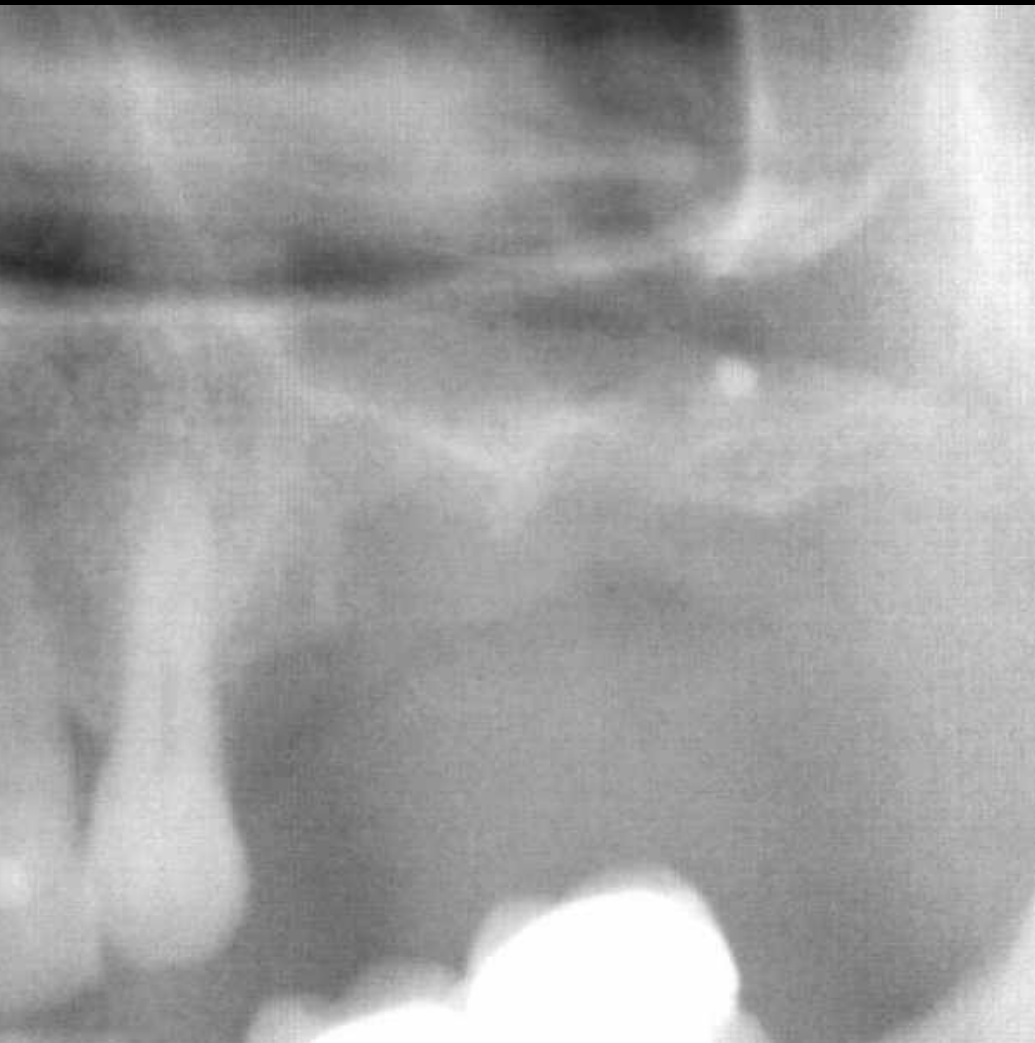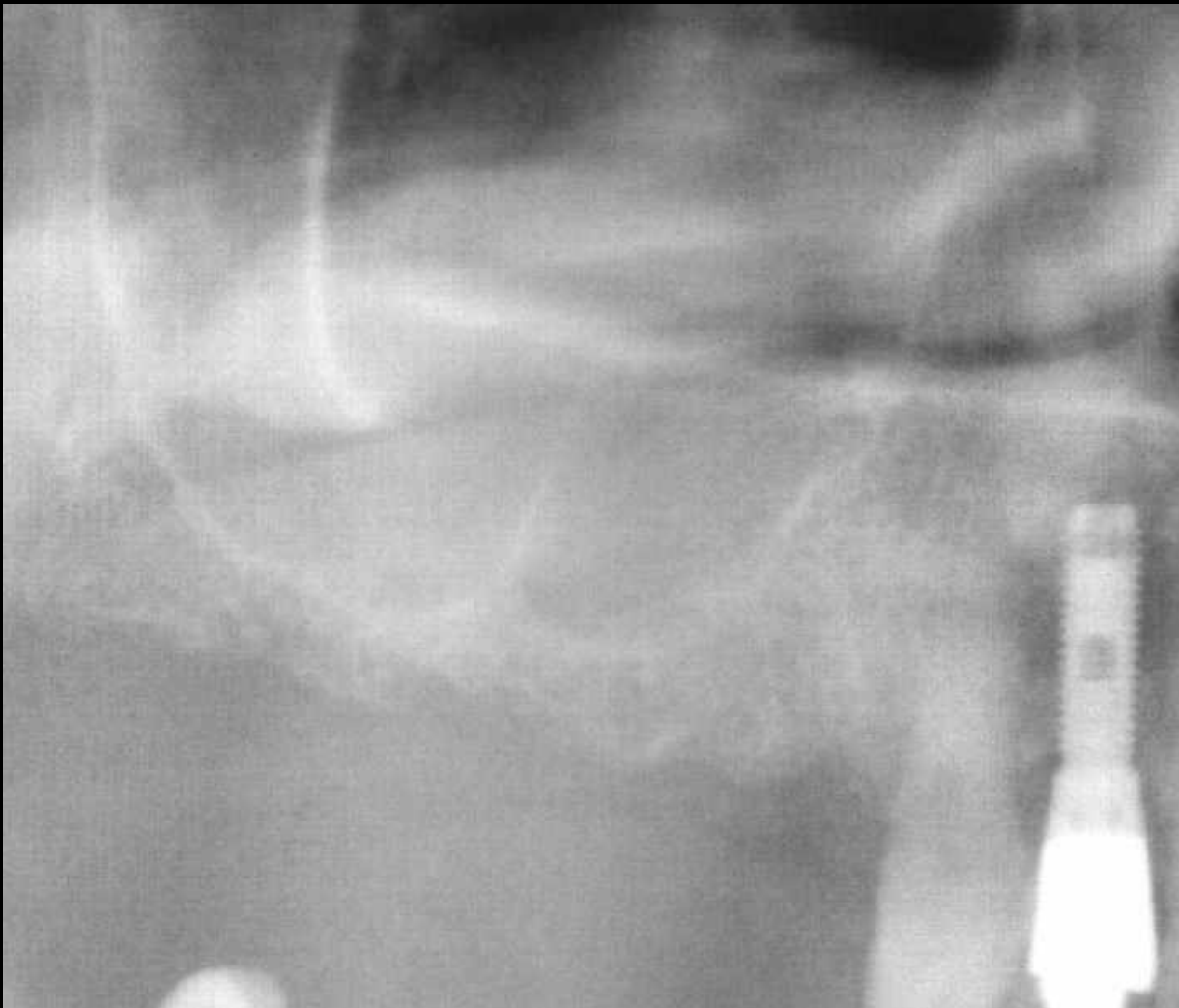
Voie Crestale élargie



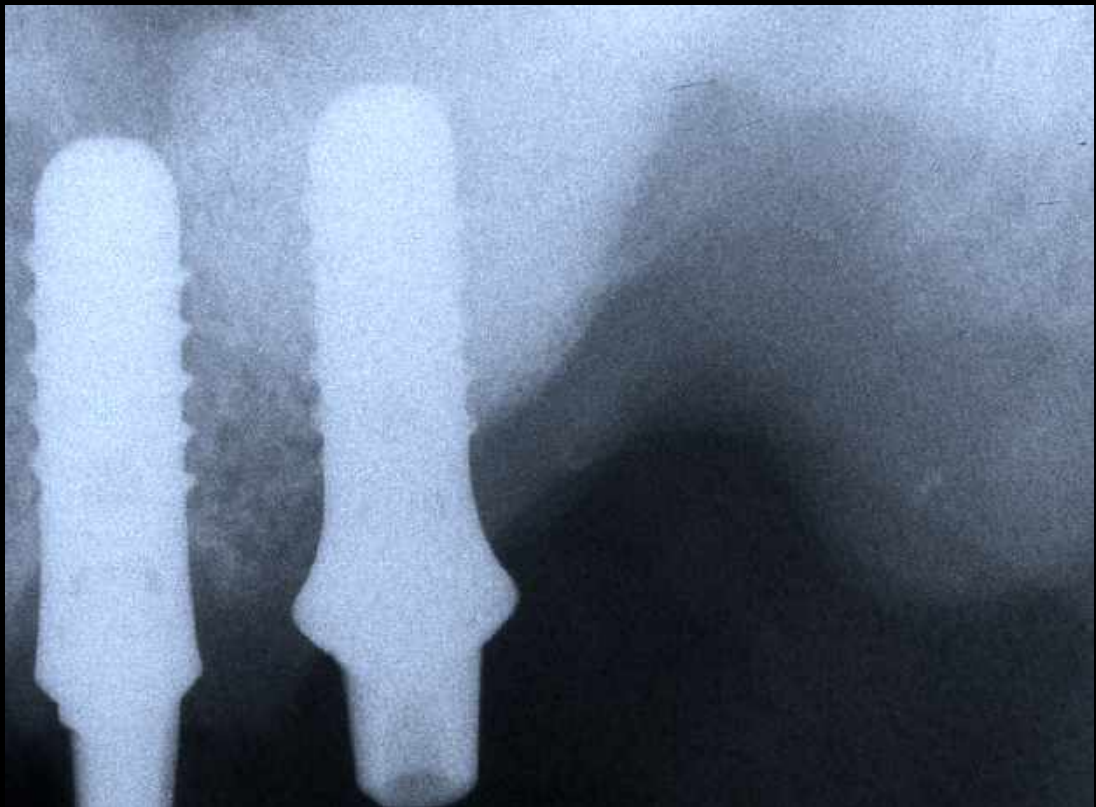
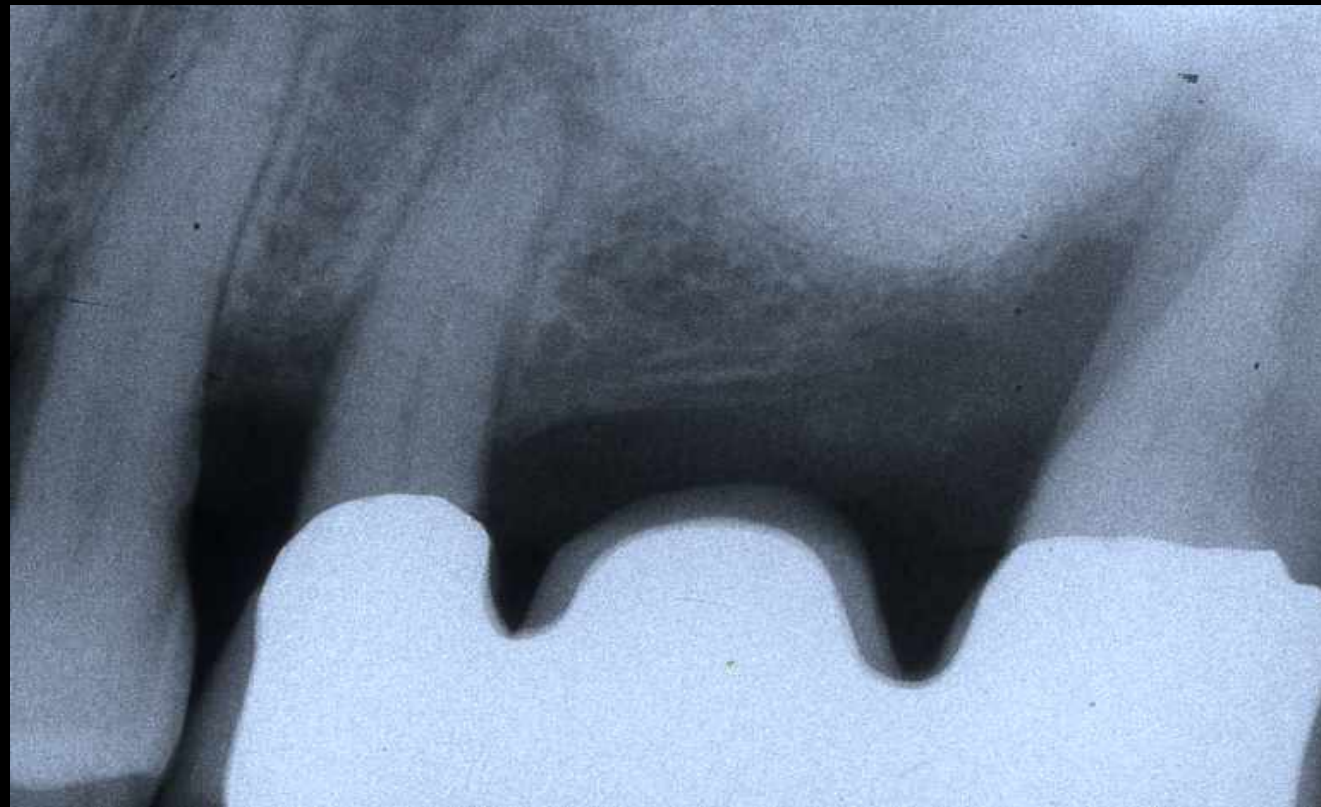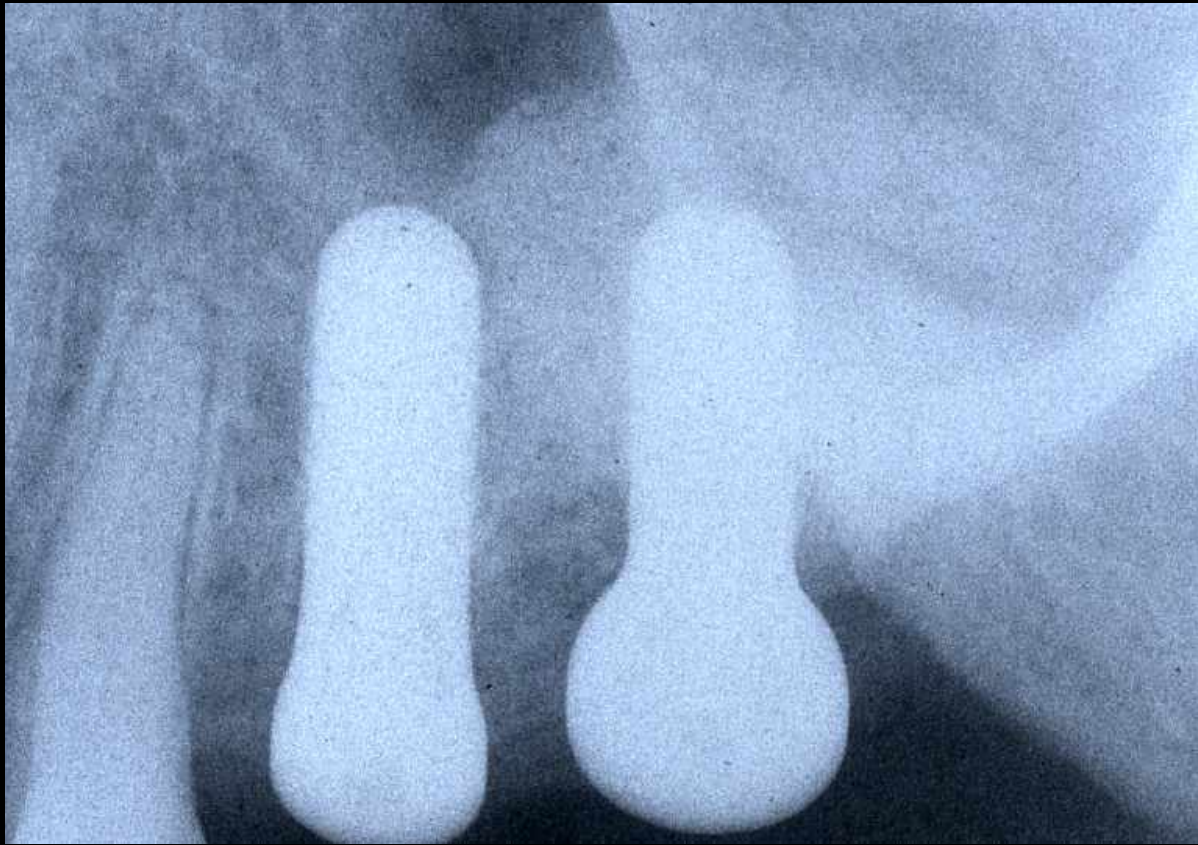
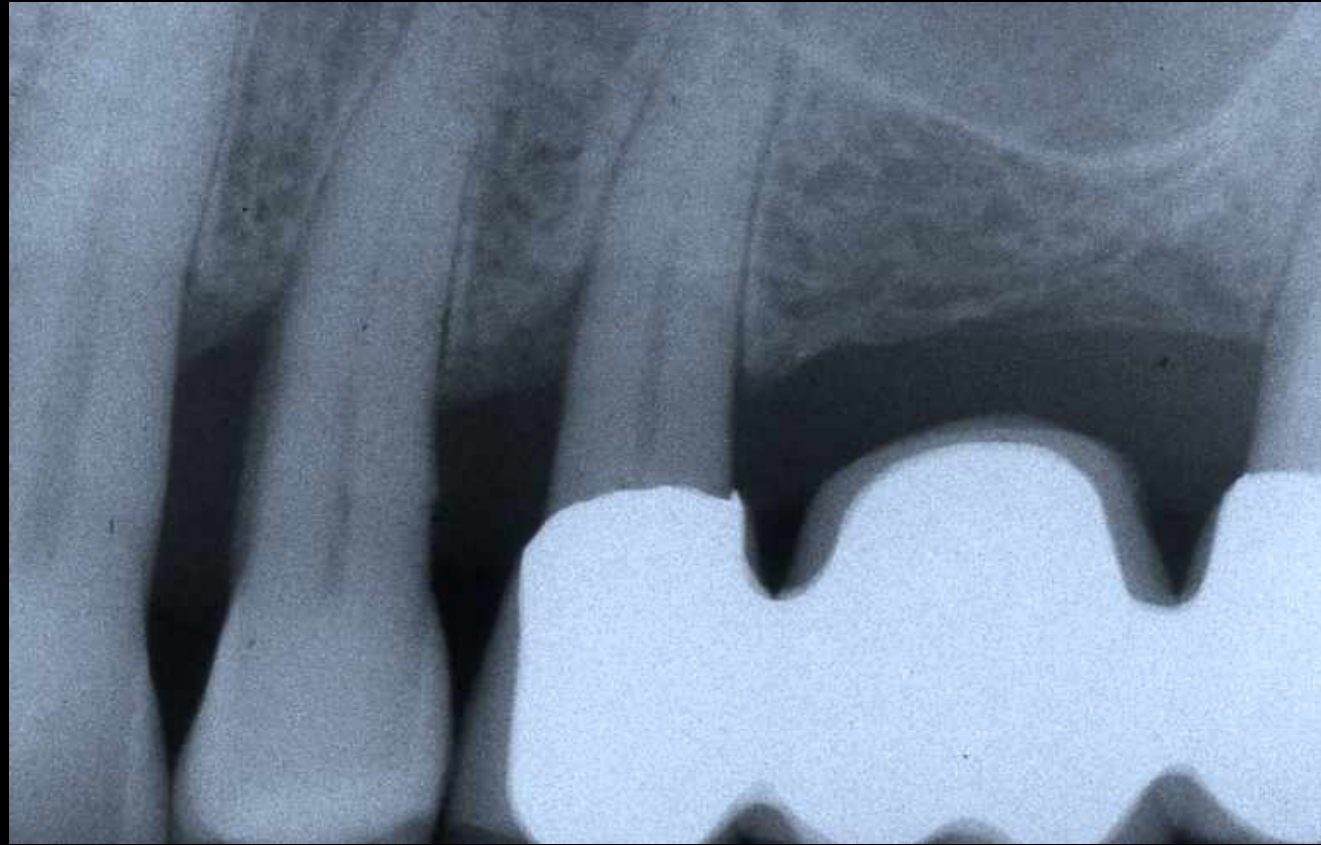Extraction +
Lésions apicales

Elevation par voie latérale
+
Alvéolaire

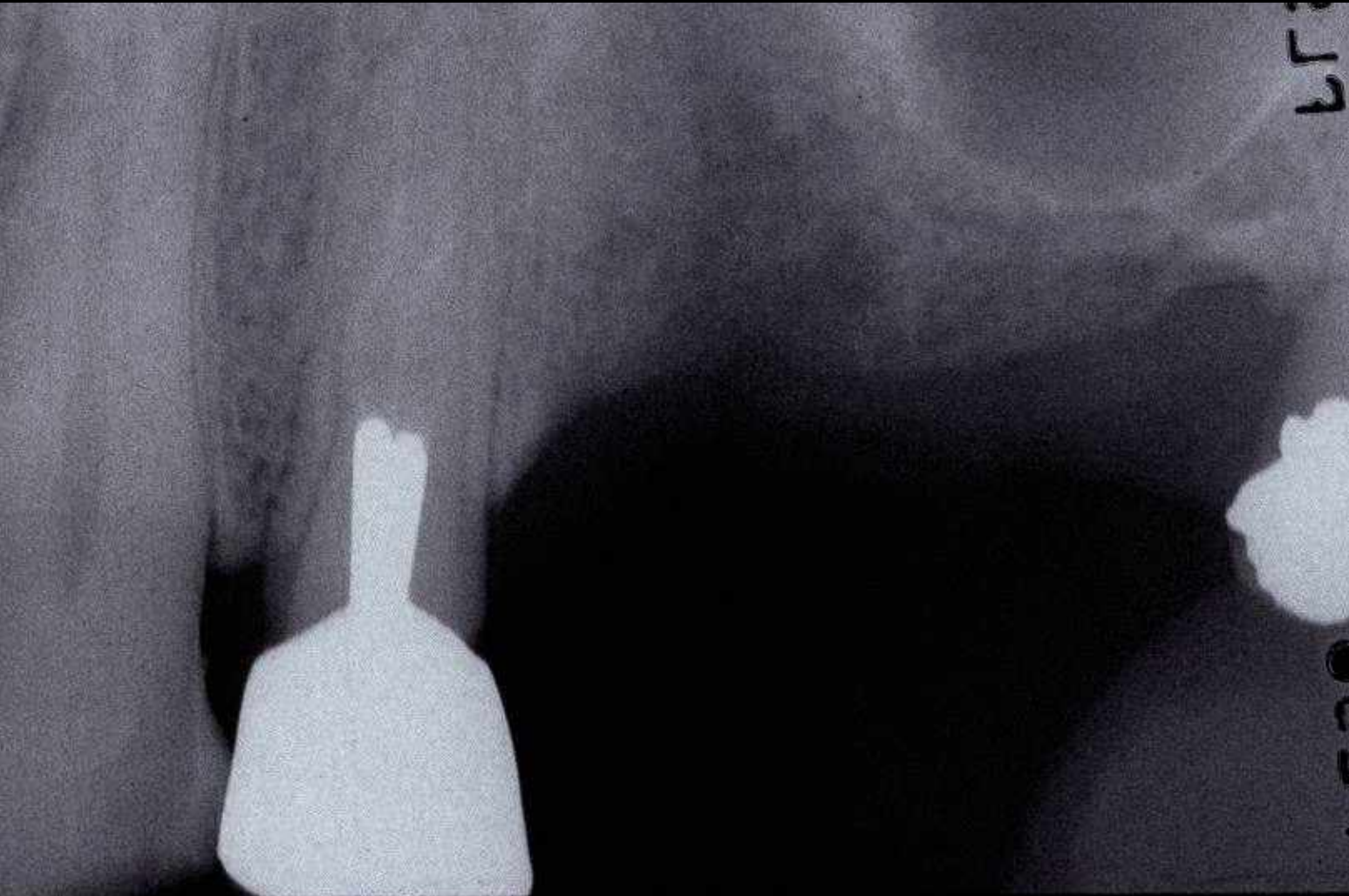
2 - GREFFE DU SINUS PAR VOILET LATERAL



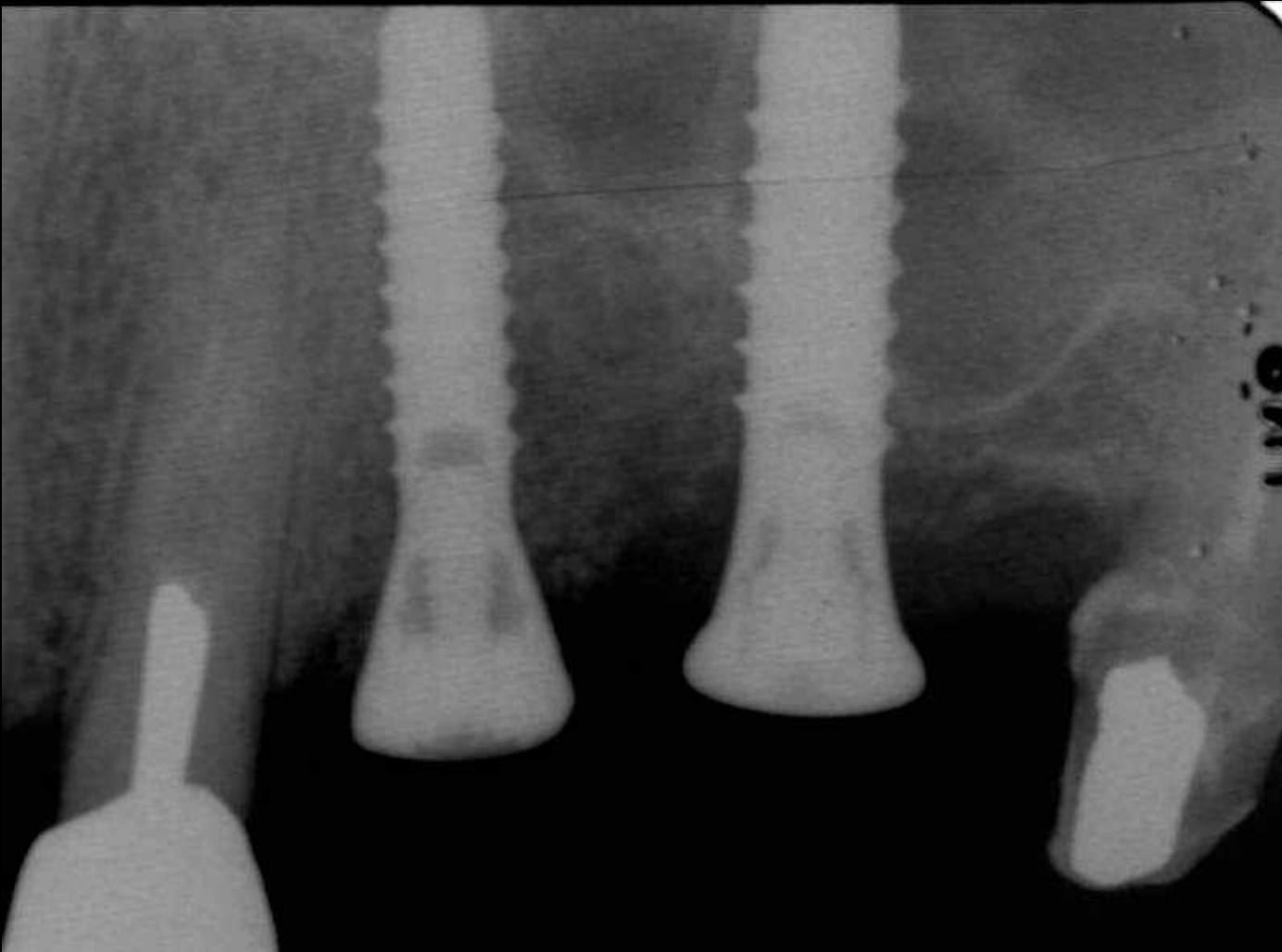
2 - GREFFE DU SINUS PAR VOILET LATERAL



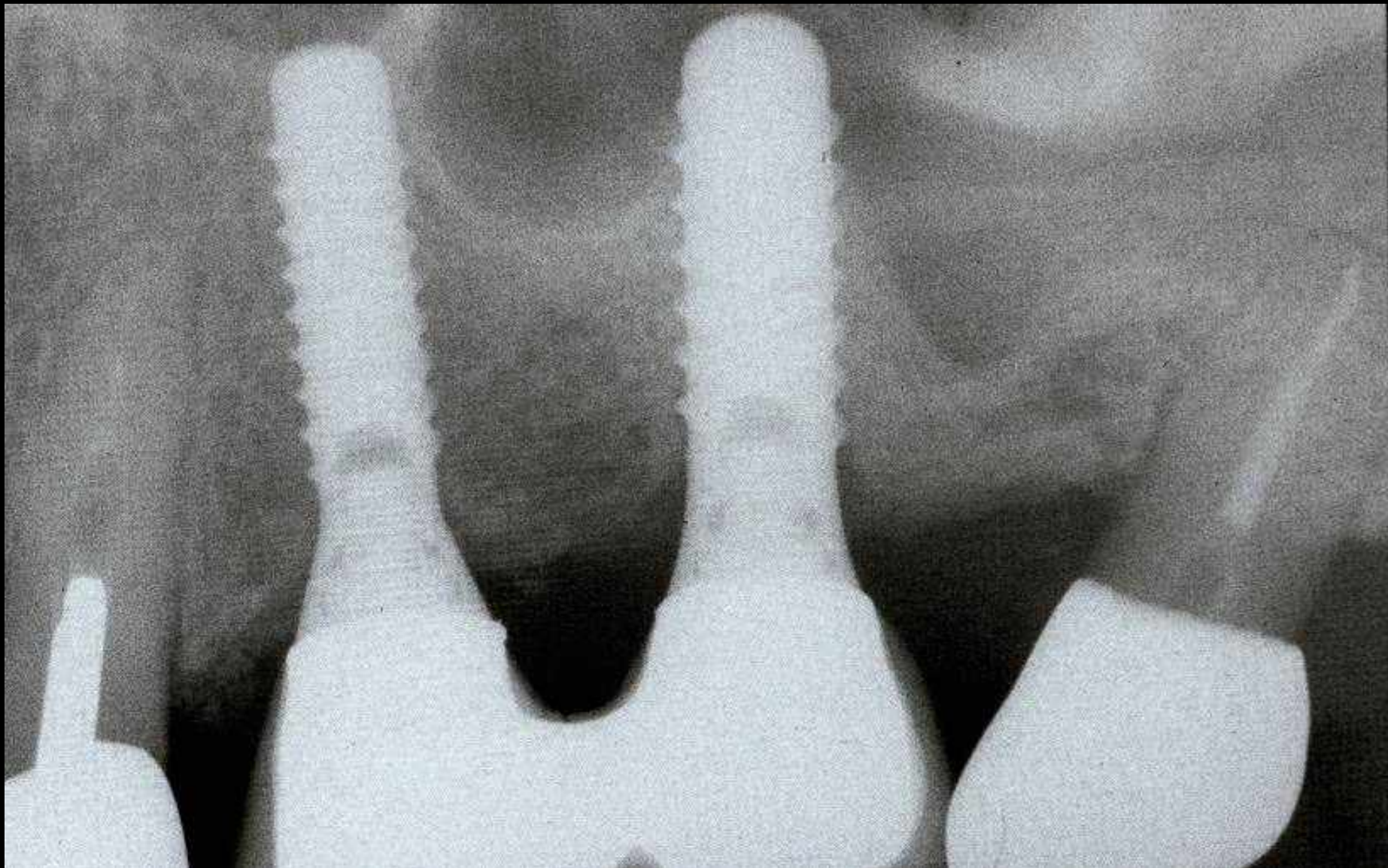
2 - GREFFE DU SINUS PAR VOILET LATERAL



Pré op

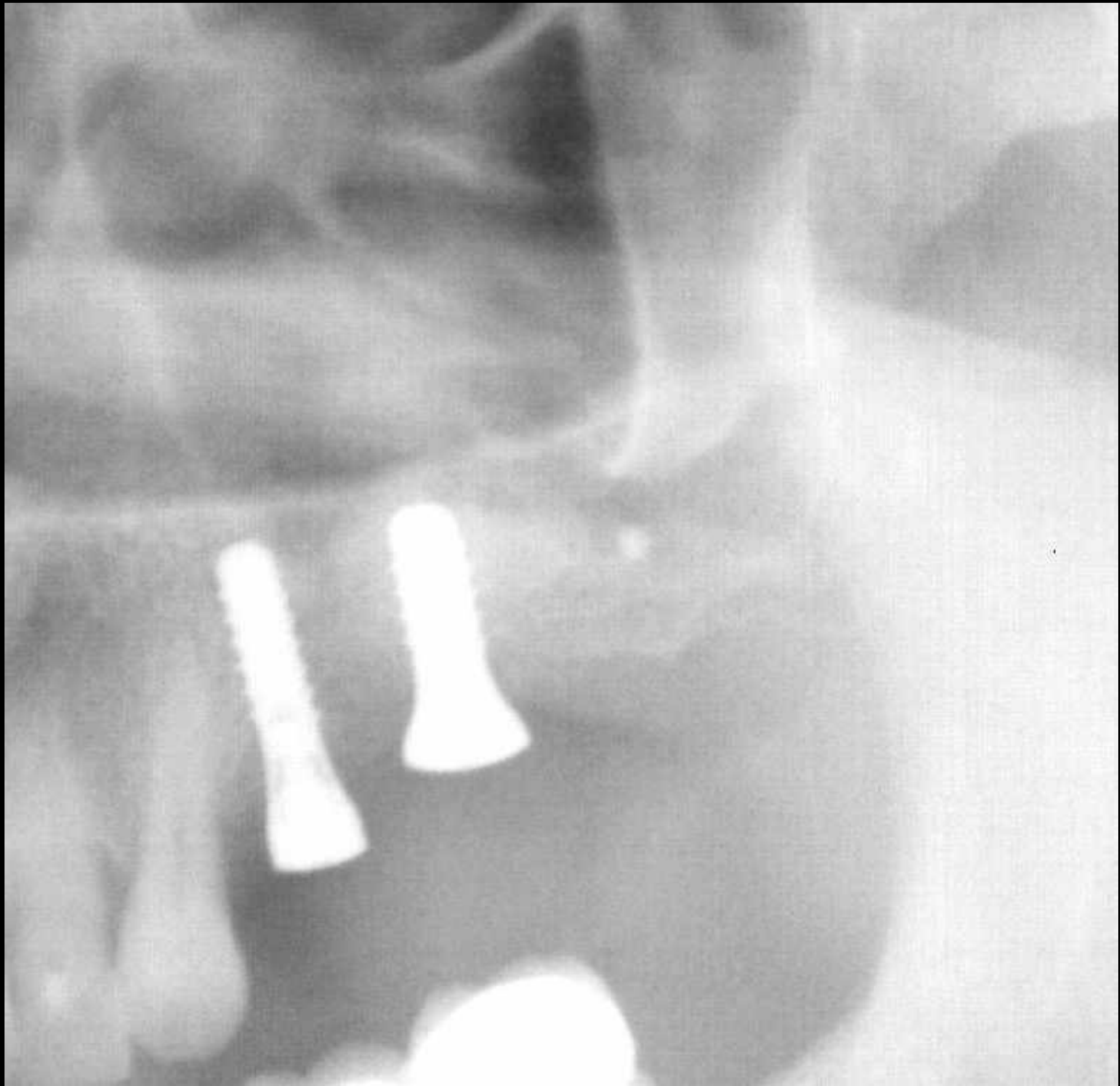
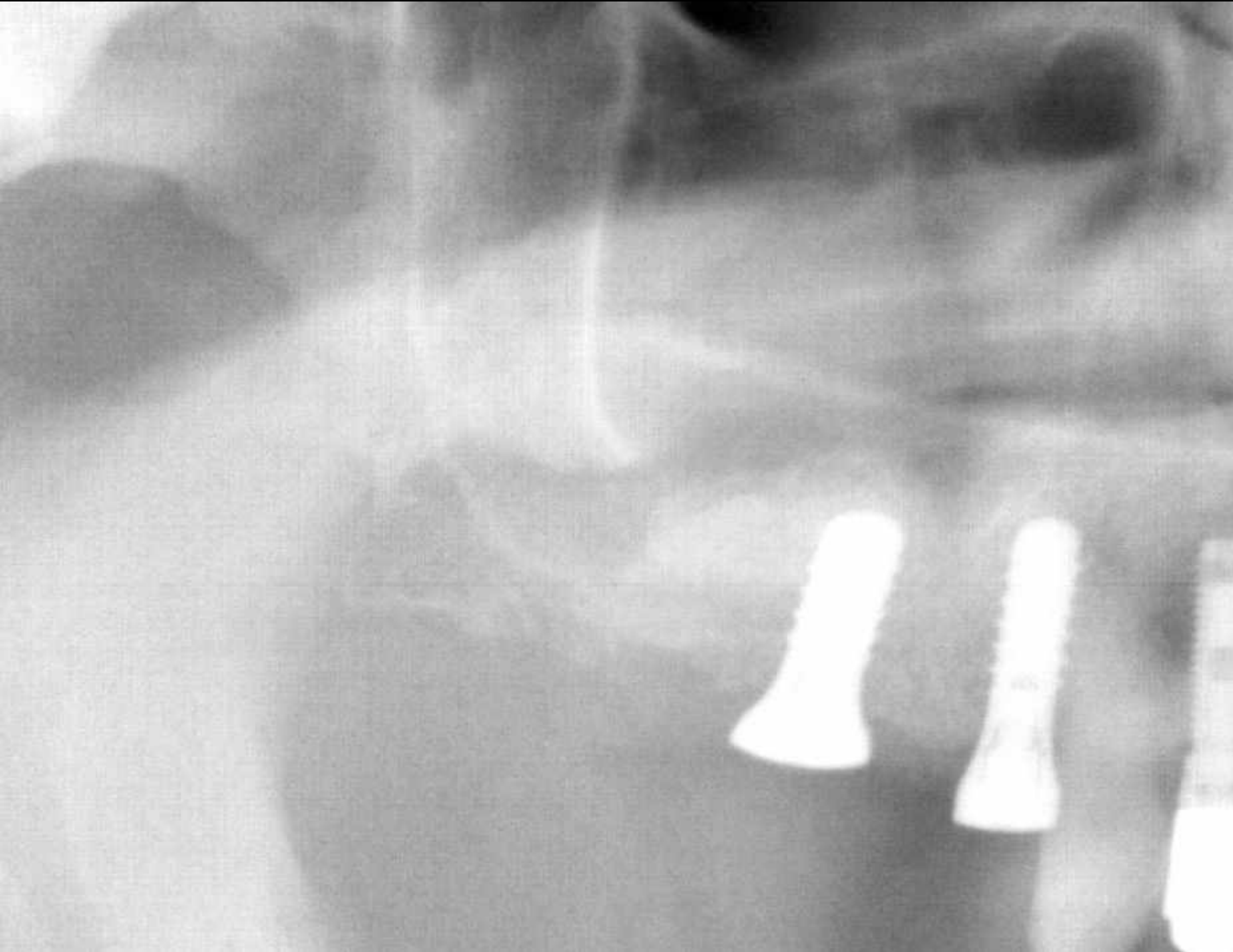


Post op

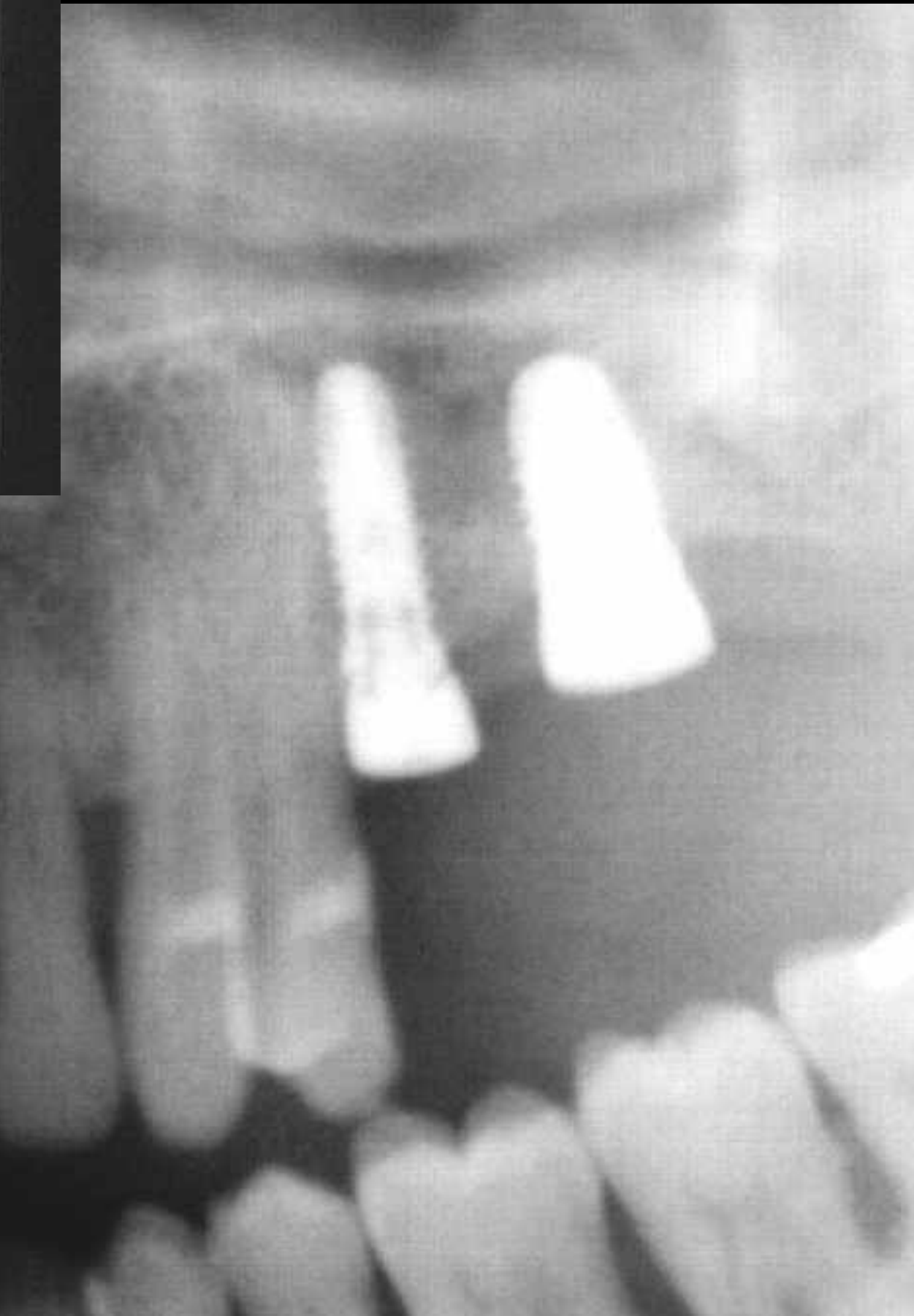
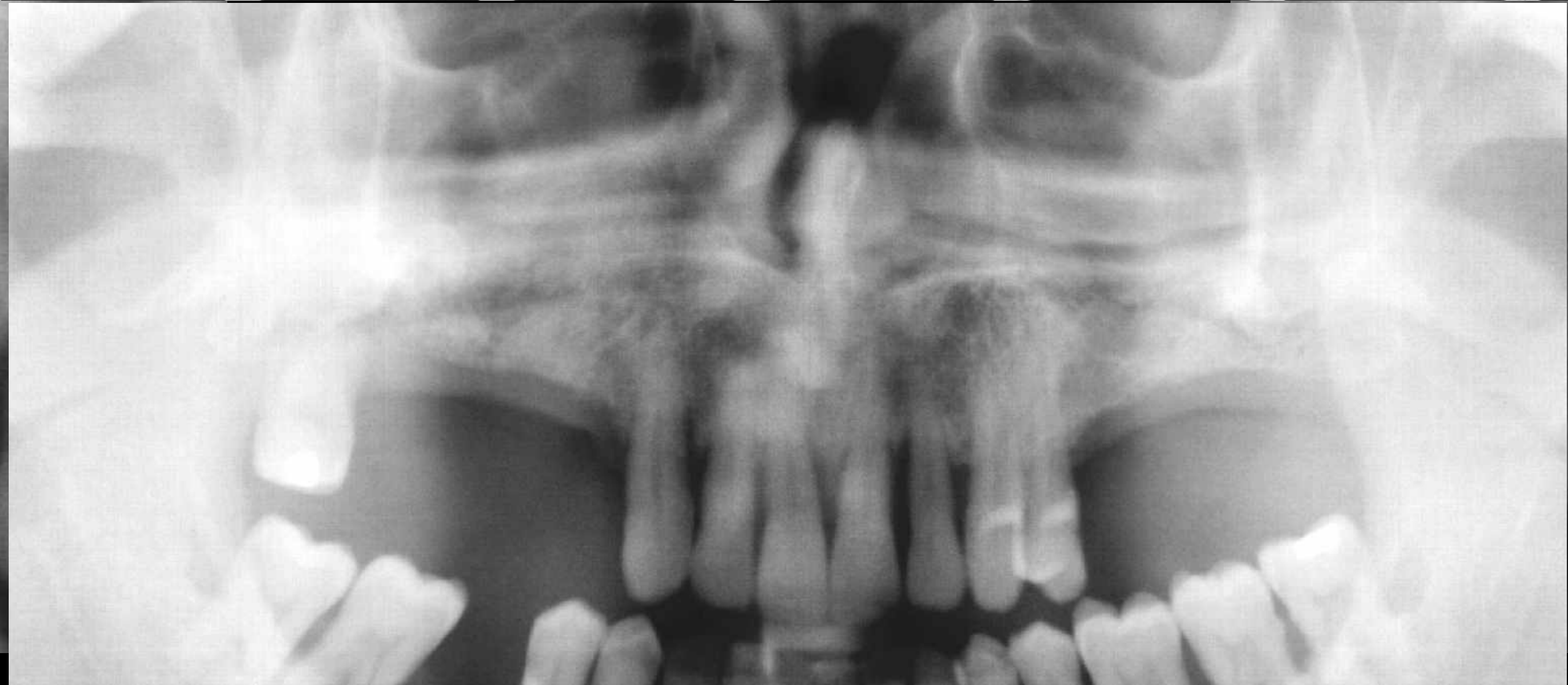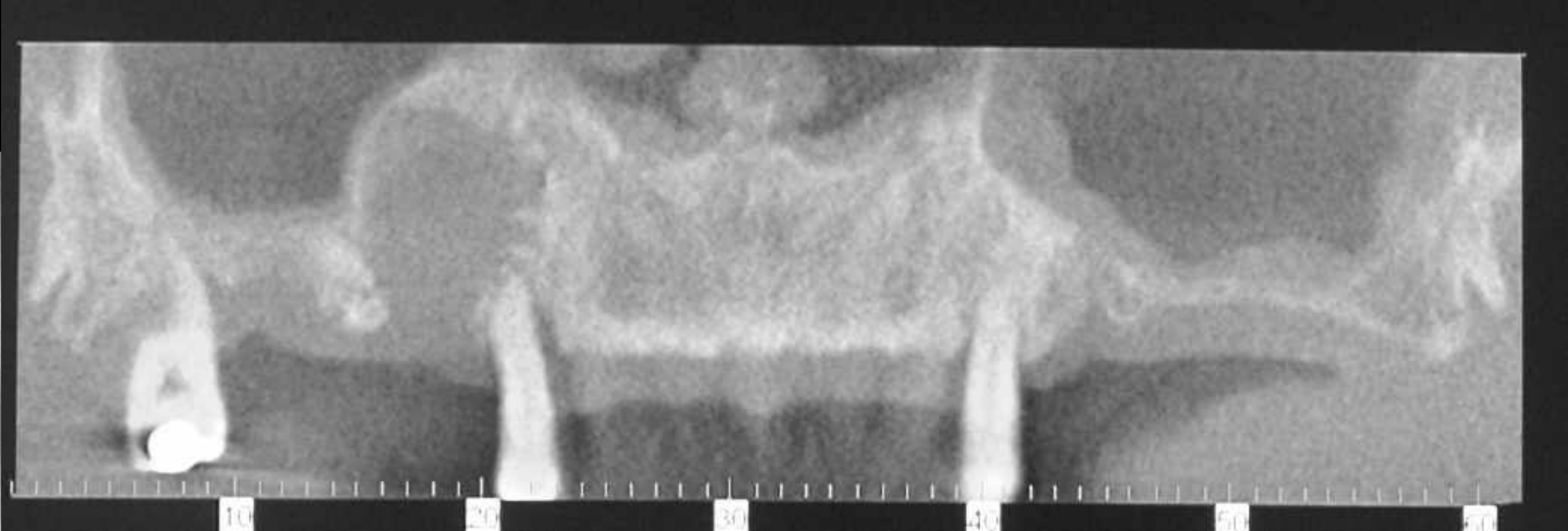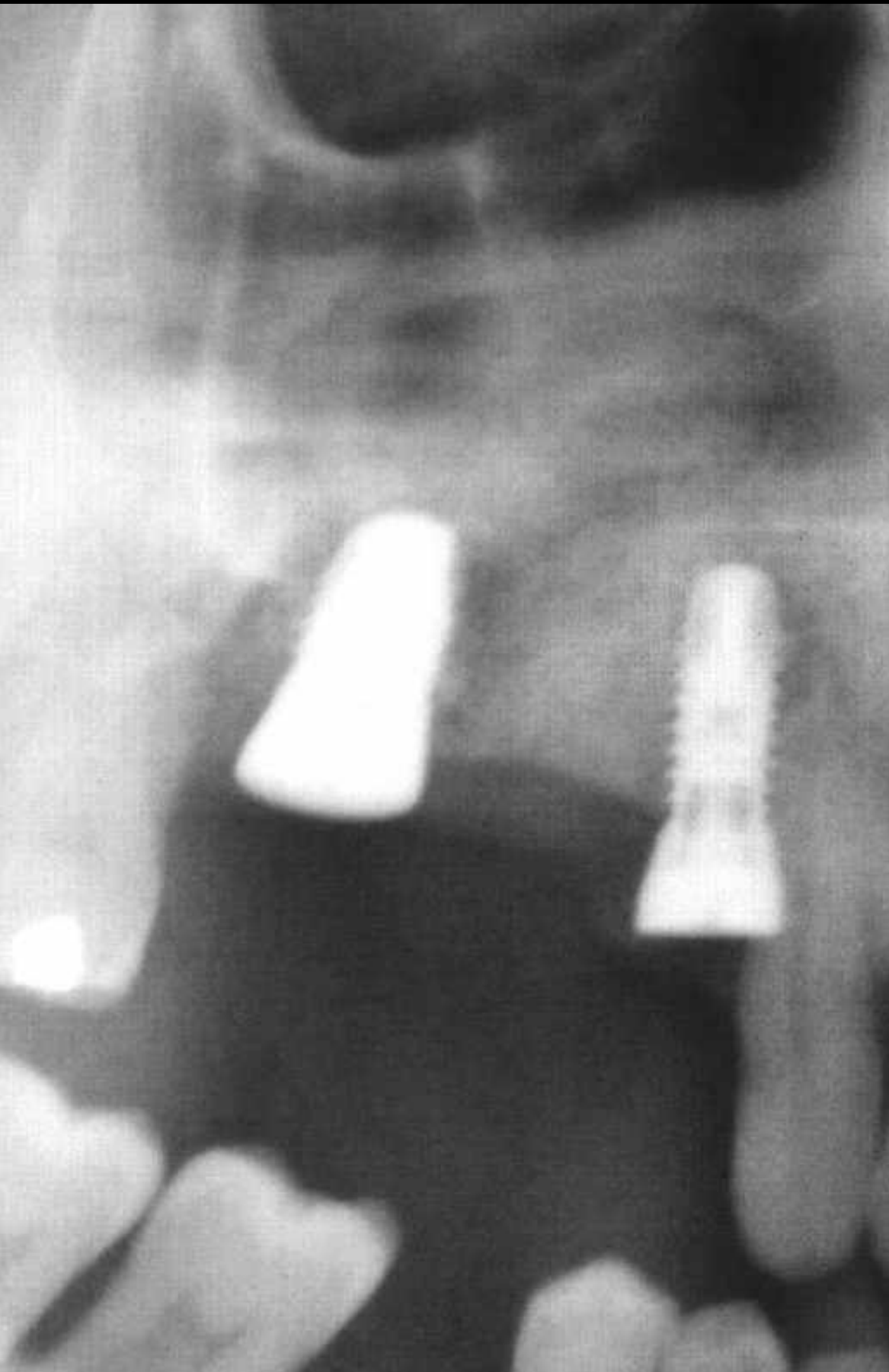


10 ans

2 - GREFFE DU SINUS PAR VOILET LATERAL



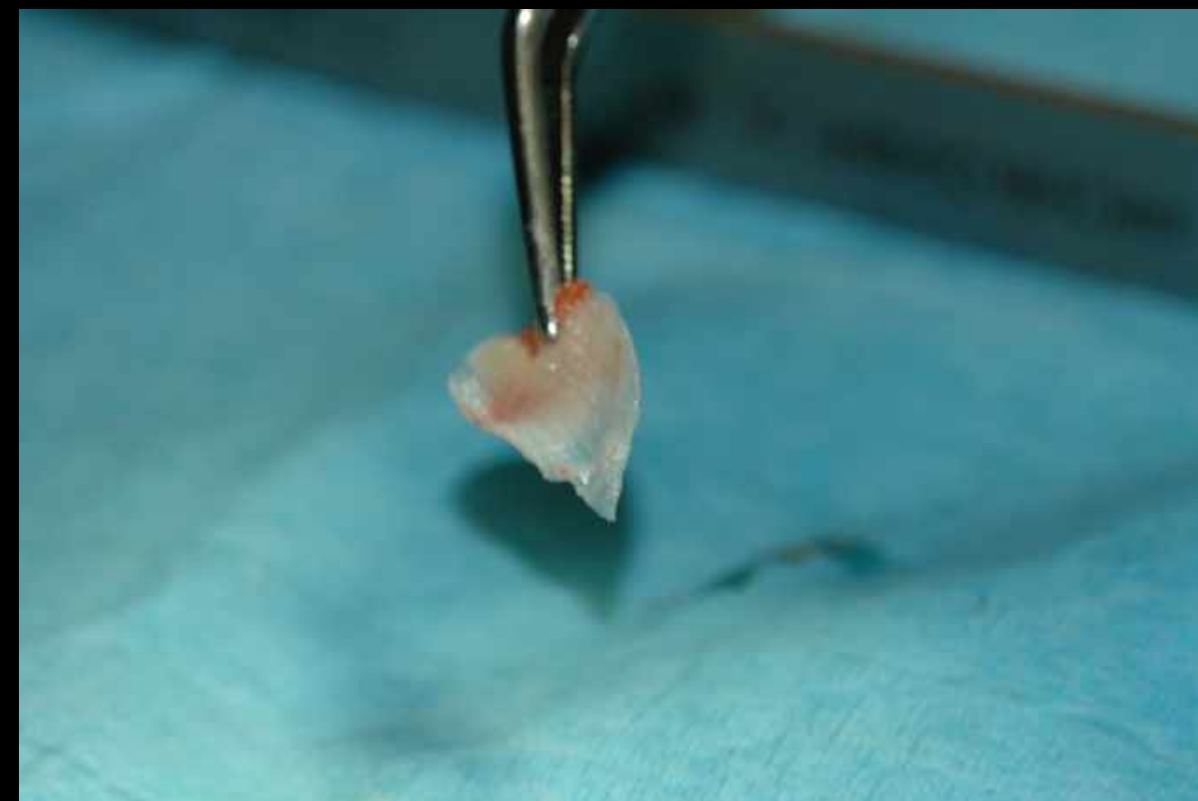
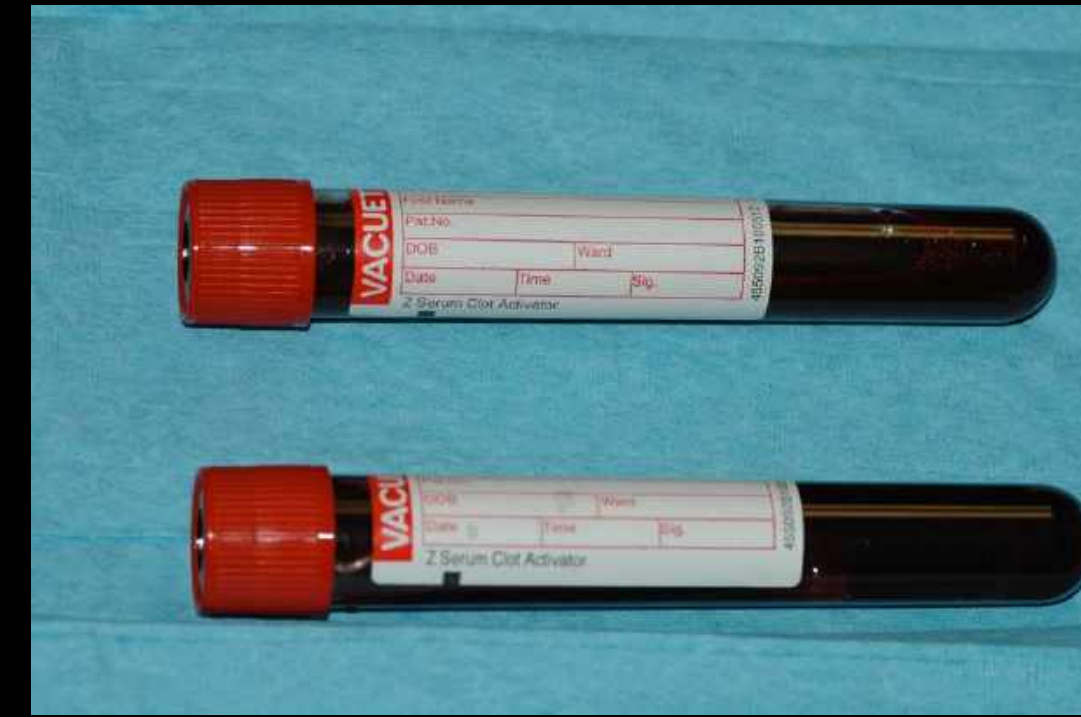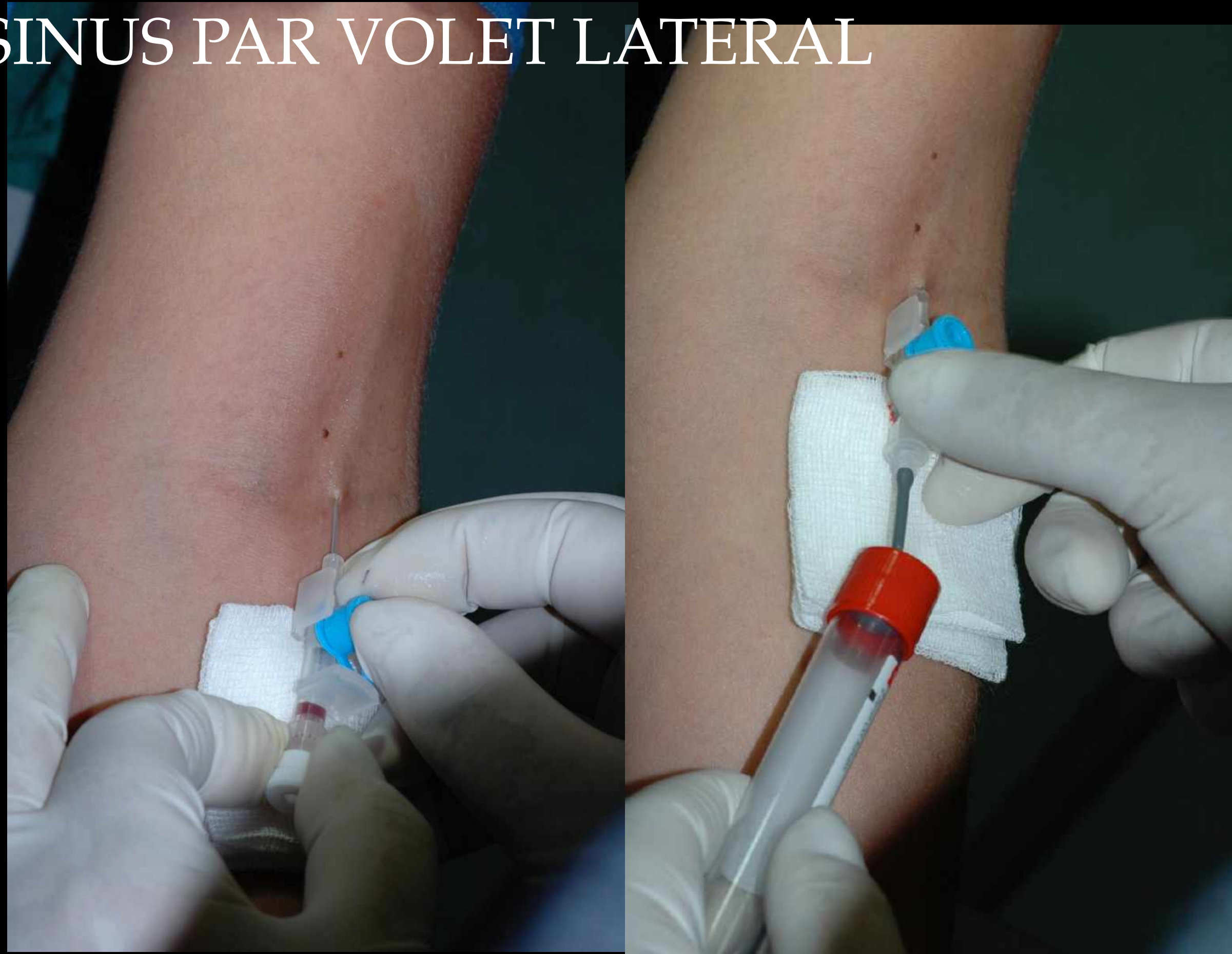
2 - GREFFE DU SINUS PAR VOILET LATERAL



Temps de Régénération

- ETUDE DE HALLMAN M ET NORDINT J
PERIODONTOL 2004
- L'os médullaire se reforme à la vitesse de 1mm
par mois
- Il faut en moyenne 8 mois pour vasculariser
une xenogreffe

2 - GREFFE DU SINUS PAR VOILET LATERAL



12mn à 1500t/mn

2 - GREFFE DU SINUS PAR VOILE LATÉRAL

Conservation des greffons

LE SERUM →

LE PRF →

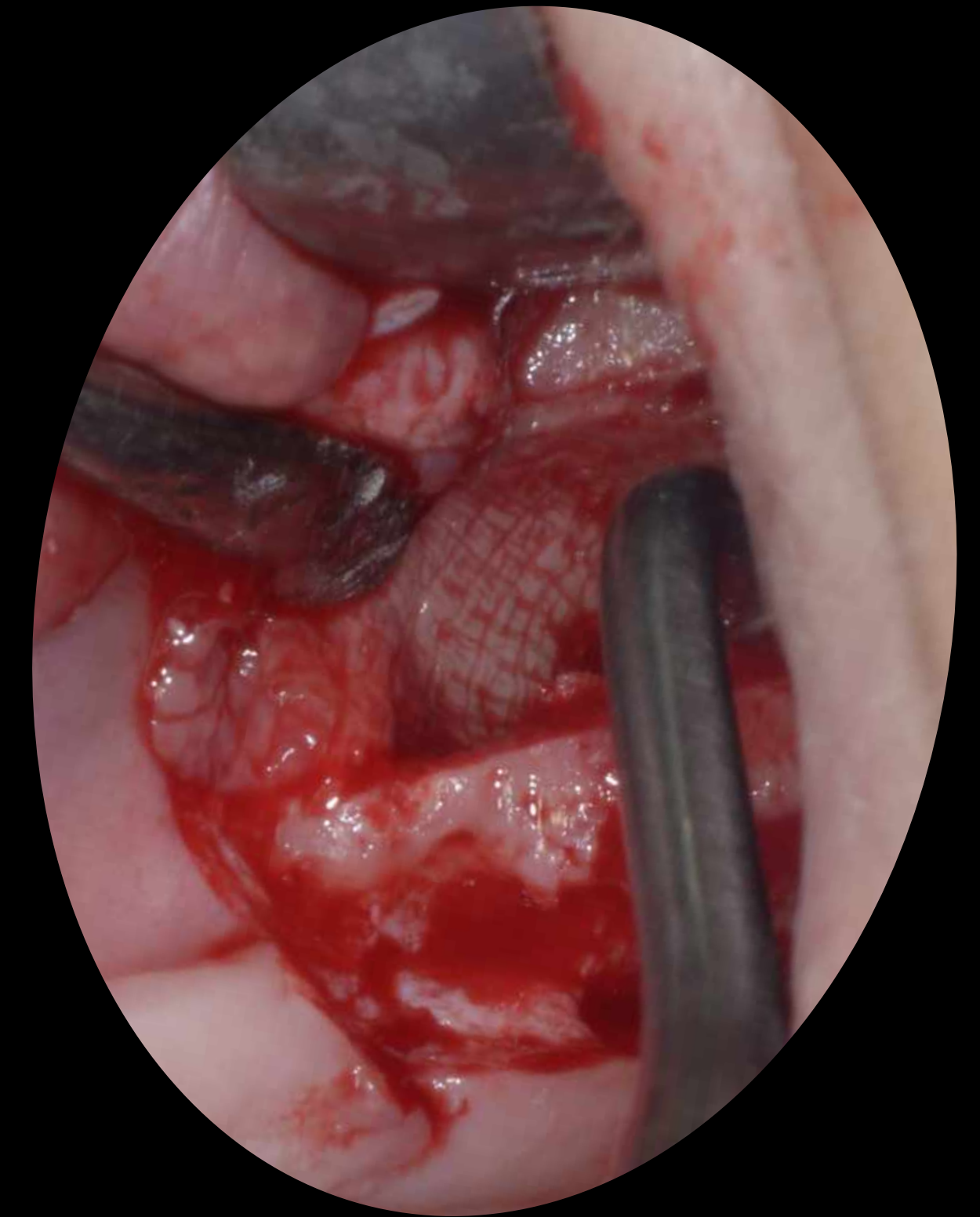PLAQUETTES & GLOBULES BLANCS

LES GLOBULES ROUGES

2 - GREFFE DU SINUS PAR VOILE LATÉRAL


La majorité des facteurs de croissance sont contenus dans les plaquettes

PRF: Platelet Rich Fibrin




Caillot de fibrine


INTERET DU P.R.F



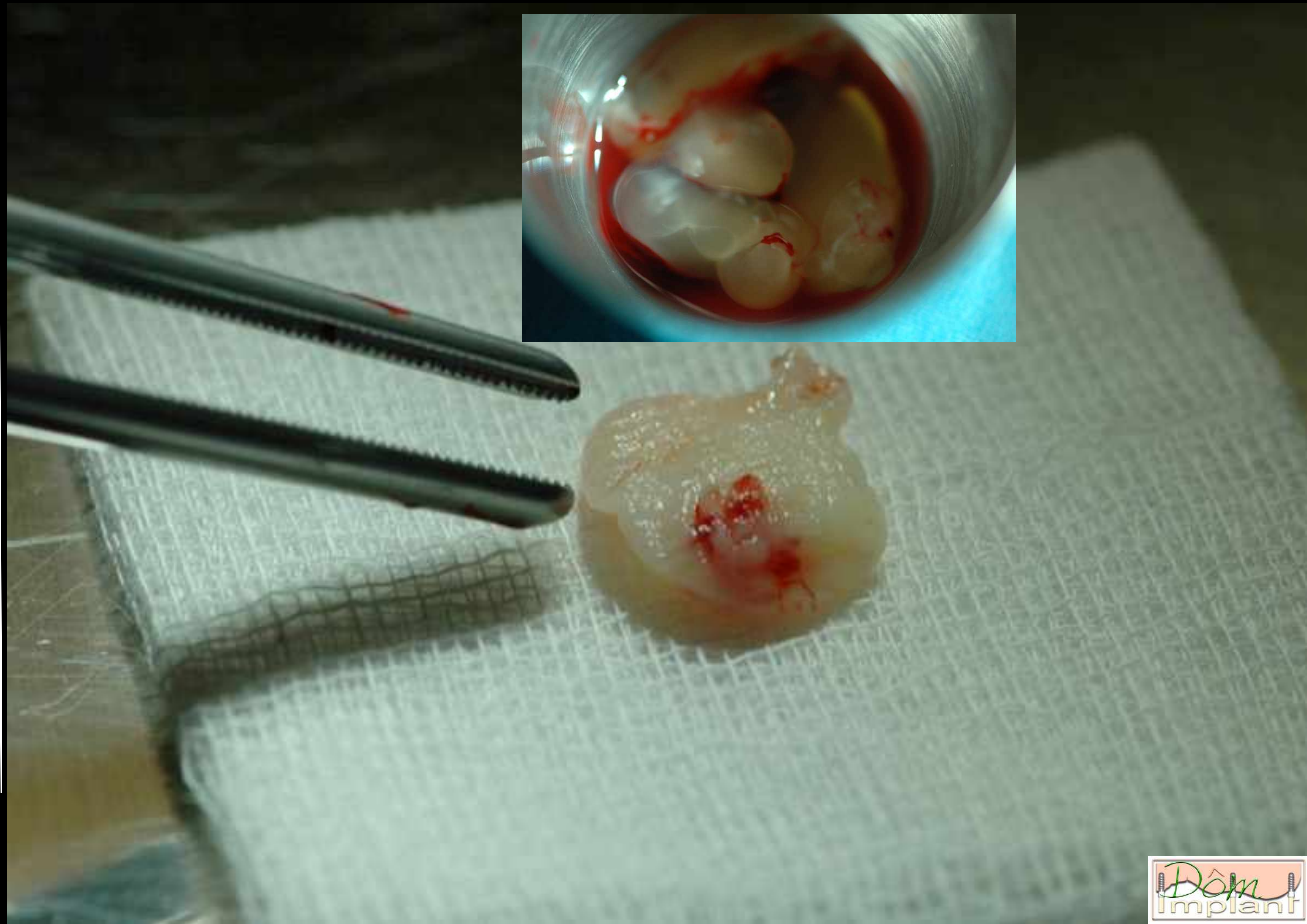
ROLE MECANIQUE IMPORTANT
mêlé au greffon sert de liant biologique



FAVORISE LES MIGRATIONS CELLULAIRES
notamment les cellules souches mésenchymateuses



BENEFIQUE POUR LA MATURATION DU GREFFON
Aspect immunitaire



2 - GREFFE DU SINUS PAR VOILE LATÉRAL

Comparaison de la densité osseuse par analyse
histomorphométrique

Effect of plaquet-rich plasma with autogenous bone graft for
maxillary sinus augmentation in a rabbit model

Butterfield KJ, Bennett J, Gronowicz G, Adams D

Int j periodontics restorative dent 2003 oct23:427-37

Apport du PRF en comblement

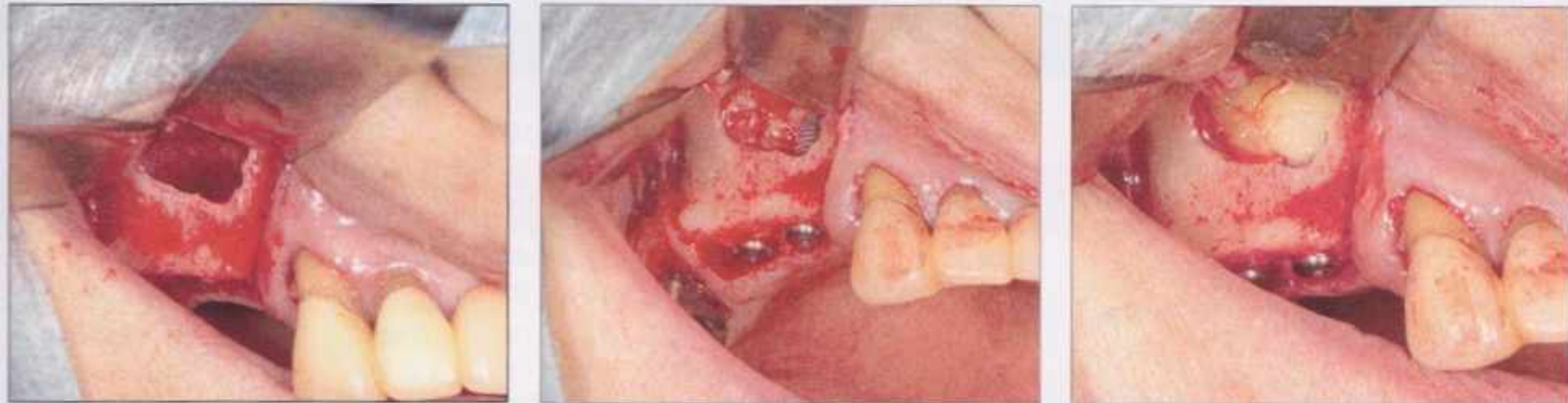9 volets latéraux + 17 implants

Hauteur d'os résiduel : 4,3mm +/- 1mm

Hauteur après chir : 11,8mm +/- 1,67

100% de succès **6 mois** après chirurgie

Fig 2 Intraoral photographs of patient no. 3 during surgery.



Tajima N, Ohba S, Sawase T, Asahina I. Evaluation of sinus floor augmentation with simultaneous implant placement using platelet-rich fibrin as sole grafting material. *Int J Oral Maxillofac Implants*. 2013 Jan-Feb;28(1):77-83.

Apport du PRF **seul** en comblement

Group 1 = Os résiduel $>4\text{mm}$

Group 2 = Os résiduel $<4\text{mm}$

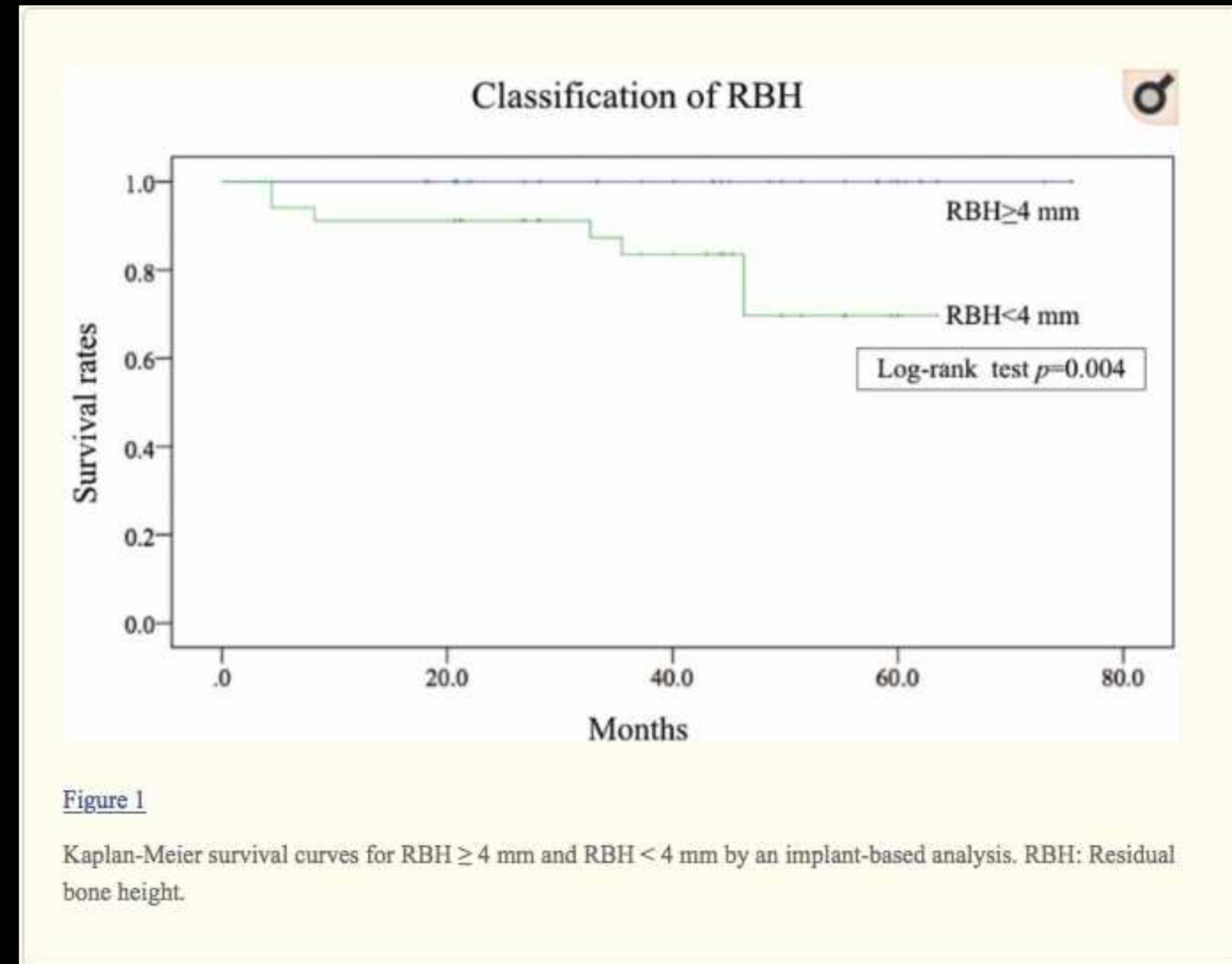
Résultats à **7 ans**

Taux de survie 85,5% :

100% Group 1

69% Group 2

Intérêt du PRF seul très discutable si
Os résiduel $< 4\text{mm}$



Aoki N and coll. Sinus floor elevation with platelet-rich fibrin alone: A Clinical retrospective study of 1-7 years. J Clin Exp Dent. 2018 Oct 1;10(10):e984-e991.

Risque médicamenteux Anti-coagulants / Bisphosphonates

Anti-coagulant = Risque hémorragique

Attention à la position du l'a.Antrale

Bien expliquer les consignes

Donner son 06...

Bisphosphonate = Risque de BP-ONJ

Risque théorique. Sur une revue de 50 études aucune nécrose

Expliquer le risque théorique au patient

Attention aux médicaments associées : AIS, MTX, anti TNF-alpha

et facteurs de risque : Diabète, Tabac

Walter C, Al-Nawas B, Wolff T, Schiegnitz E, Grötz KA. Dental implants in patients treated with antiresorptive medication - a systematic literature review. Int J Implant Dent. 2016 Dec;2(1):9. Epub 2016 Apr 4.

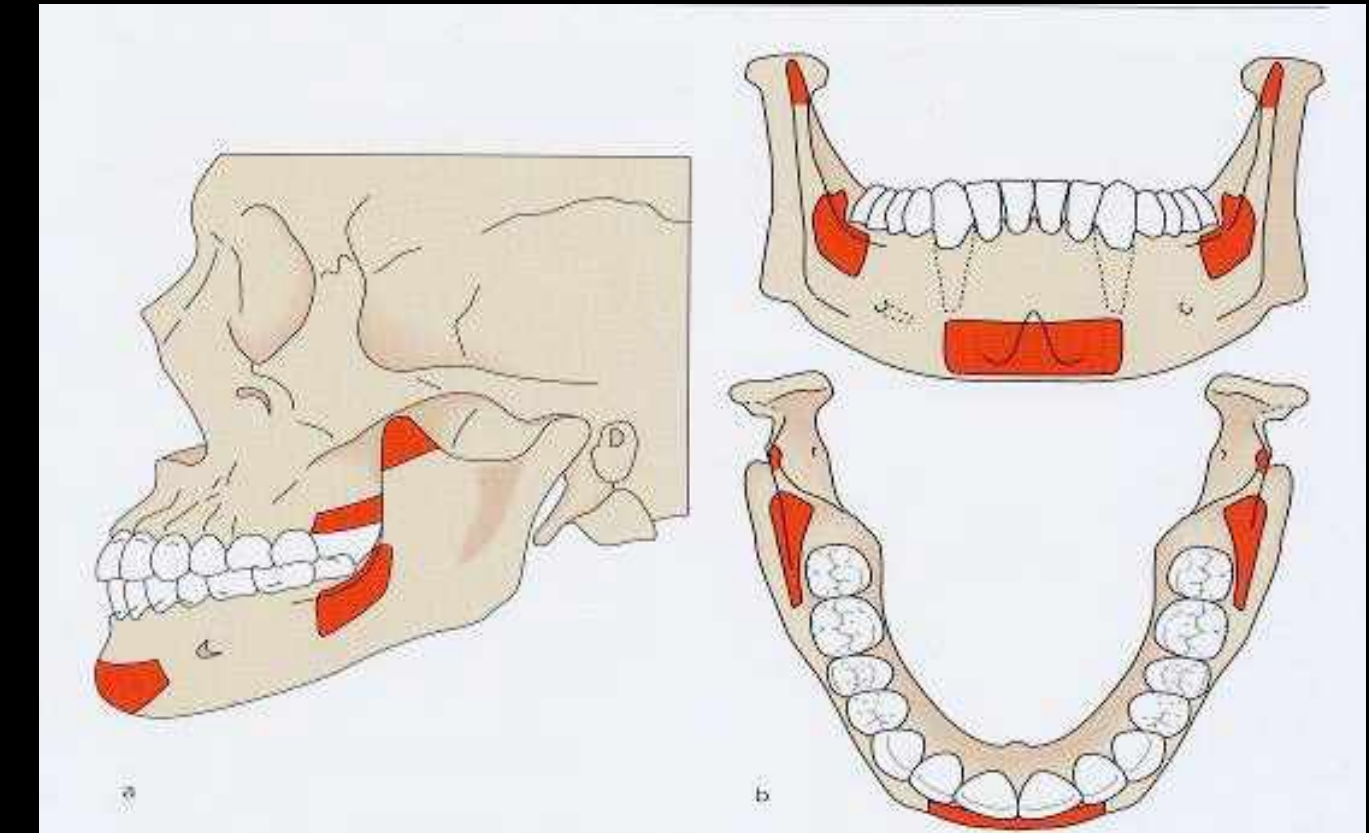
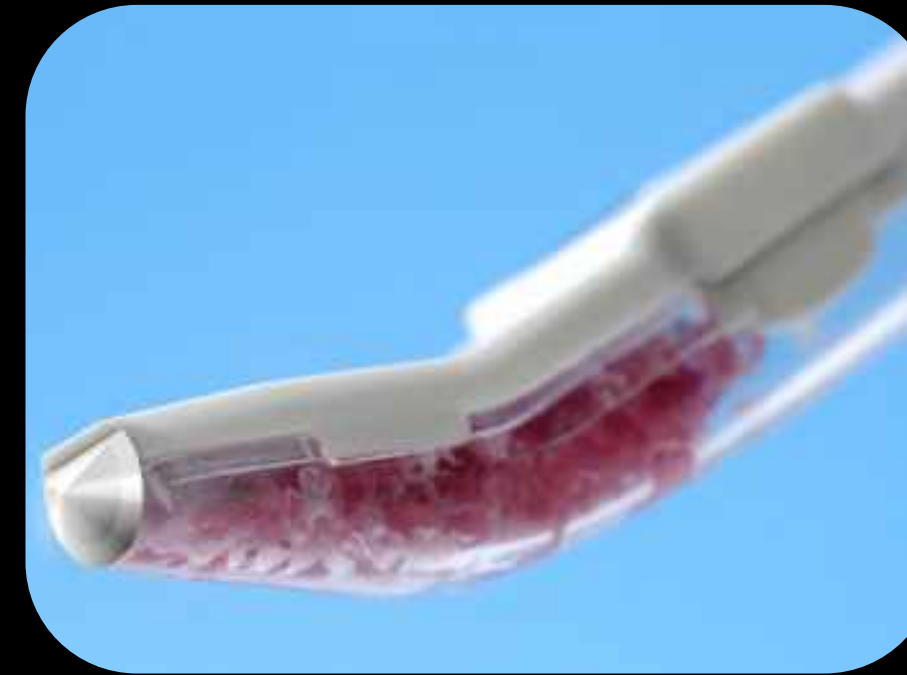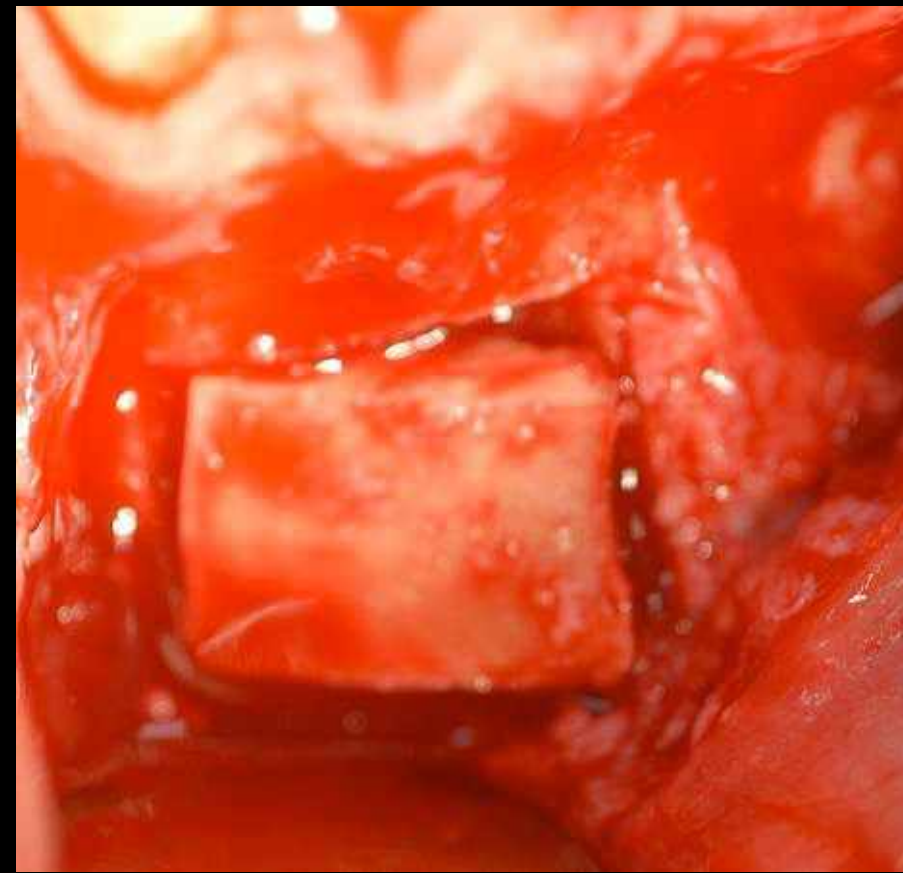
2 - GREFFE DU SINUS PAR VOLET LATERAL

Quel matériaux ?

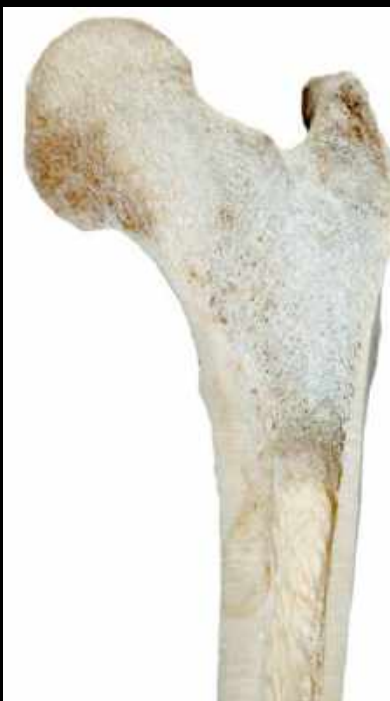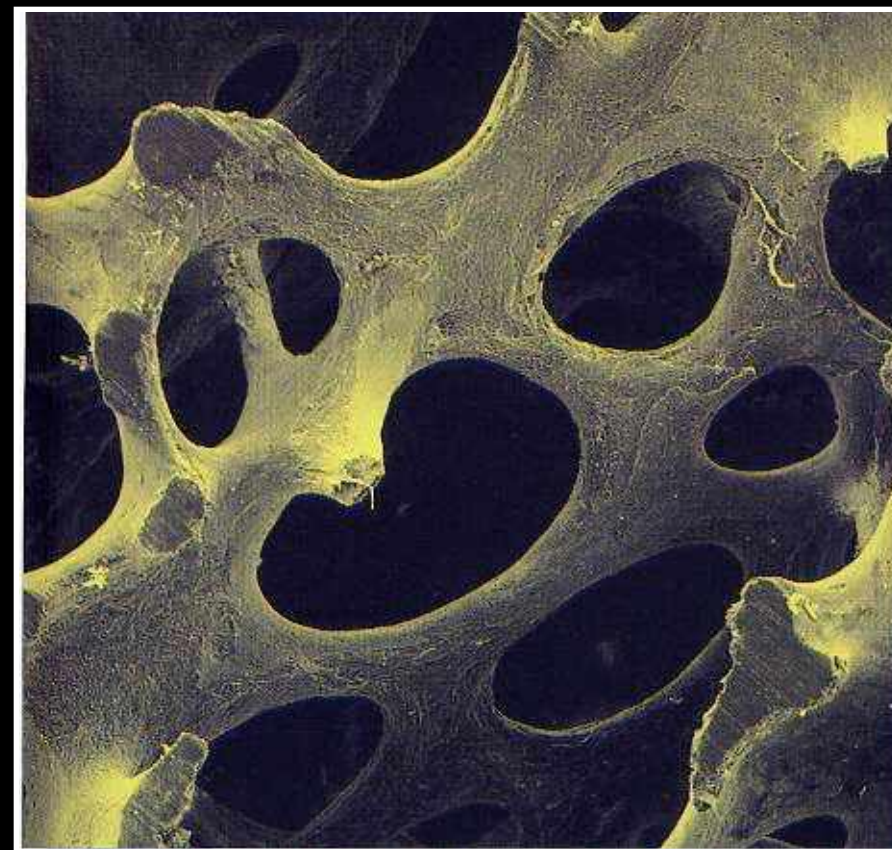
Pr Stephen WALLACE

- Bloc iliaque+surface usinée 78,8%
- Os particulé +surface usinée 90,0%
- Bloc iliaque + surface rugueuse 89,5%
- Os particulé +surface rugueuse 94,6%
- 100% autogène : 87,7%
- mélange autogène substitut osseux : 94,9%
- 100% substitut osseux (Bio-Oss) : 96,2%

Les greffes d'os : Autogènes



Allogreffes

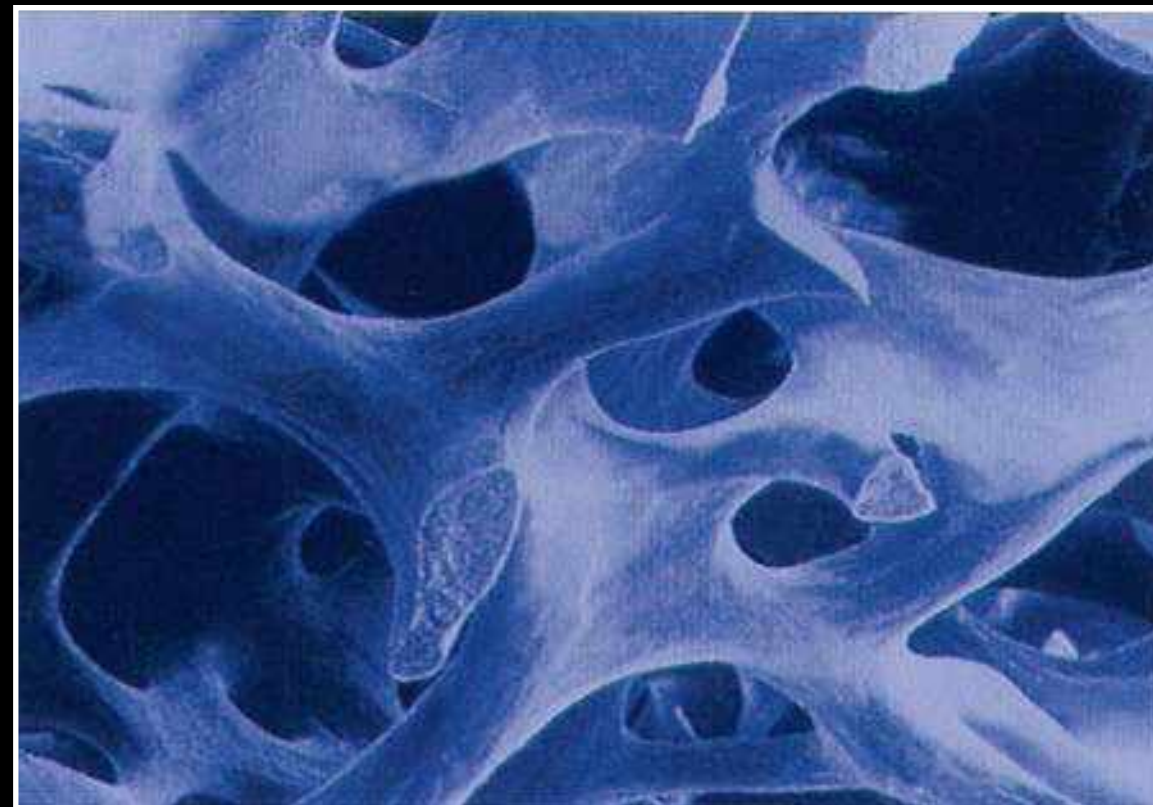


Hétérogreffes

Alloplastic
(synthetic)
Ca/P ceramics, polymers, metals etc.



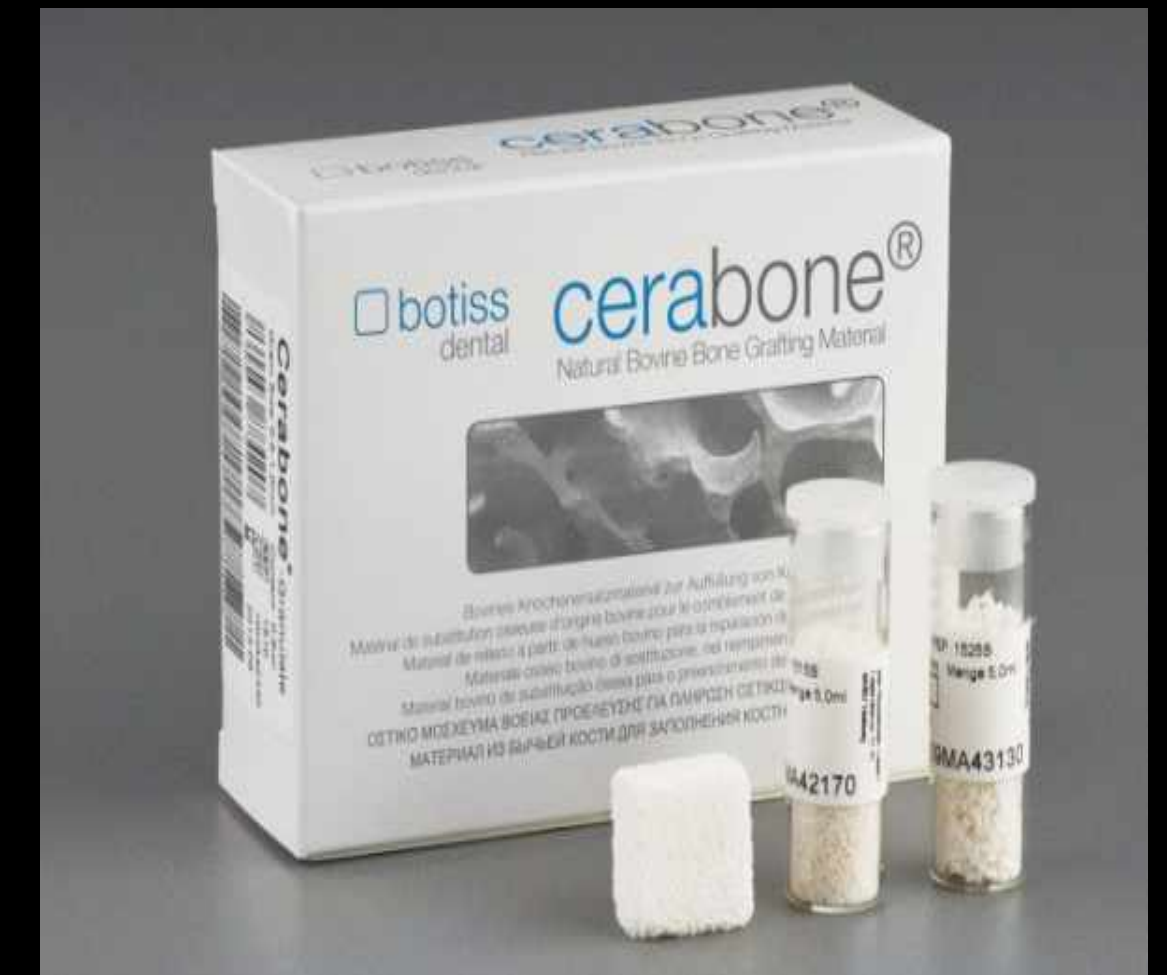Xénogreffes



Bio-Oss® Collagen
Bio-Gide® Perio
Information destinée aux professionnels - Parodontologie

An illustration of a dental procedure. A gloved hand is using a surgical instrument to place a white, porous bone graft material into a prepared site in the jawbone. The background shows a cross-section of teeth and the underlying bone structure.

*Système de régénération
des tissus parodontaux*



2 - GREFFE DU SINUS PAR VOILET LATERAL

Quel matériau ?

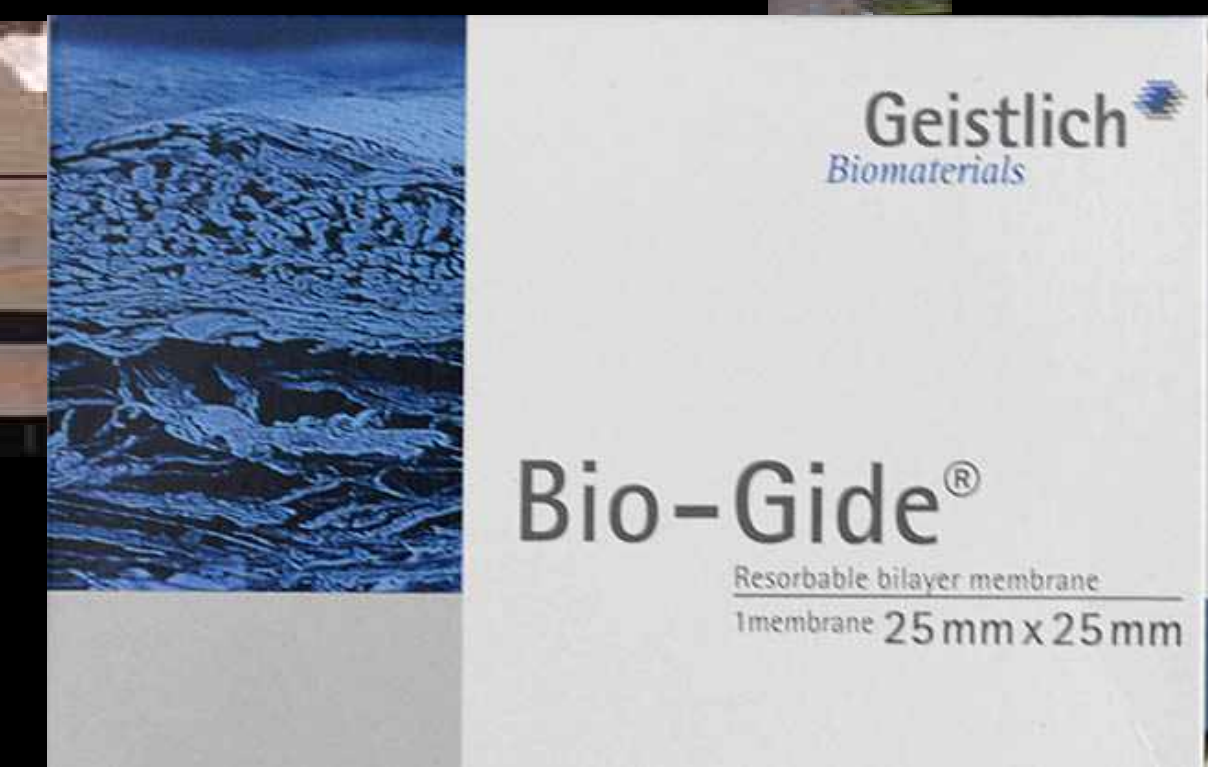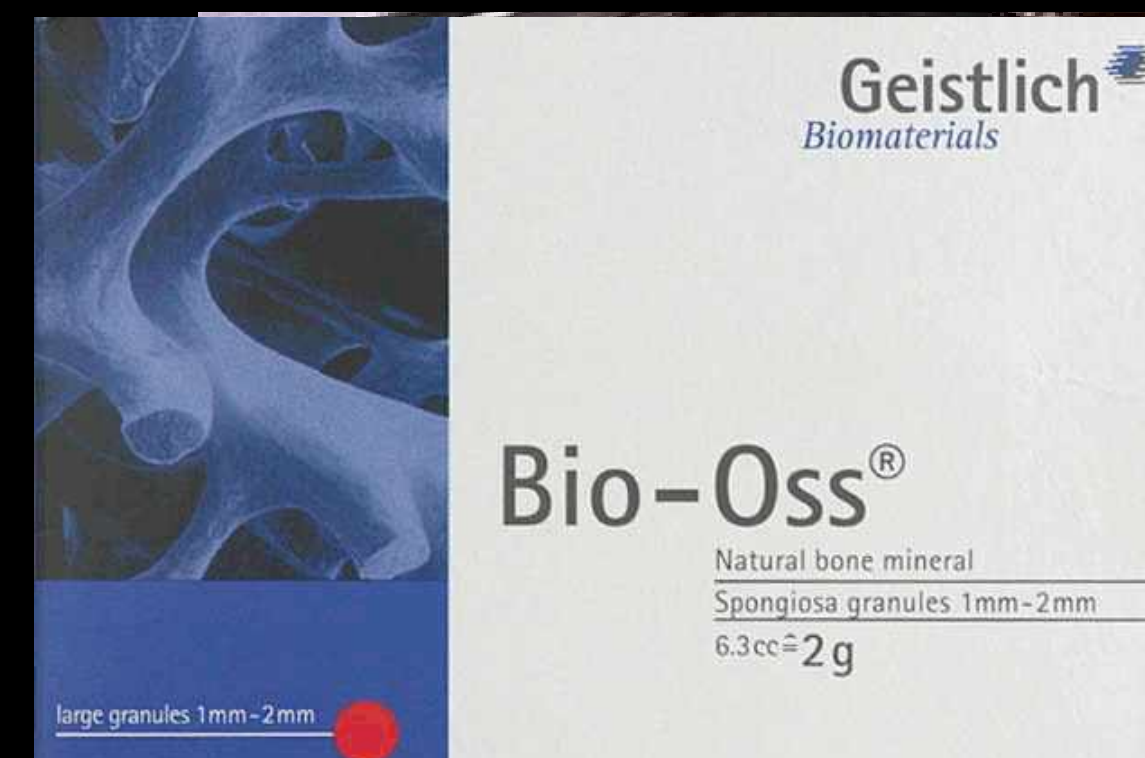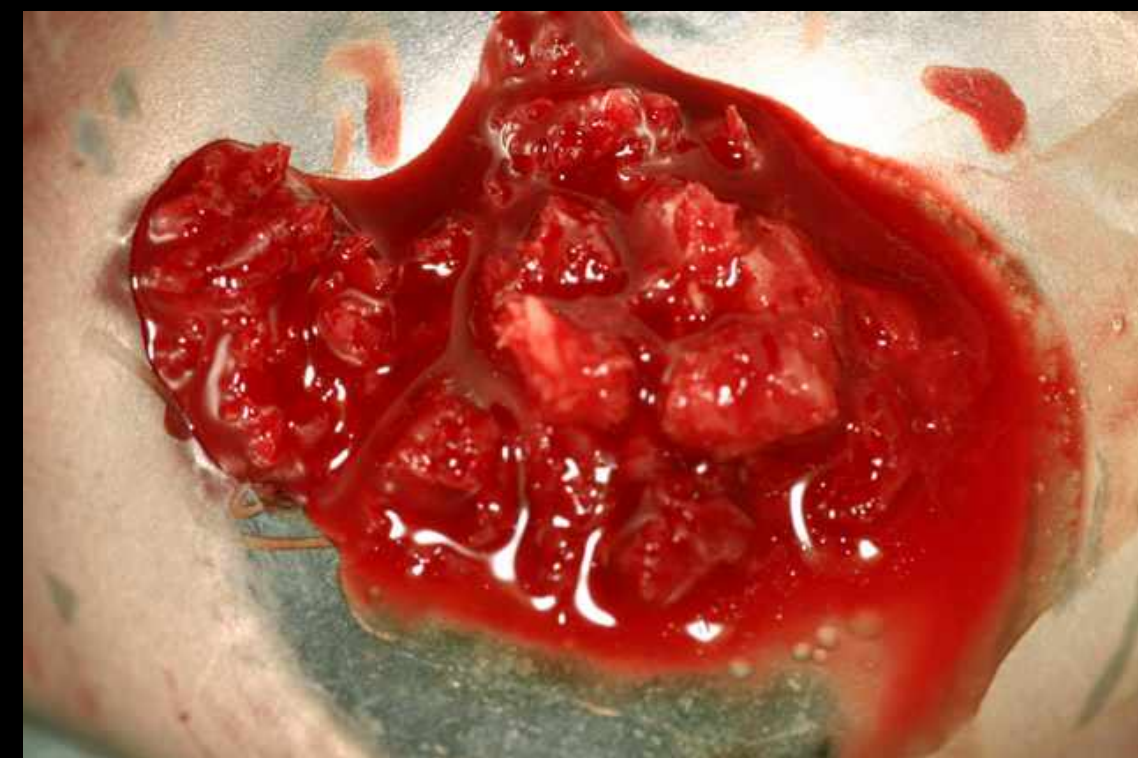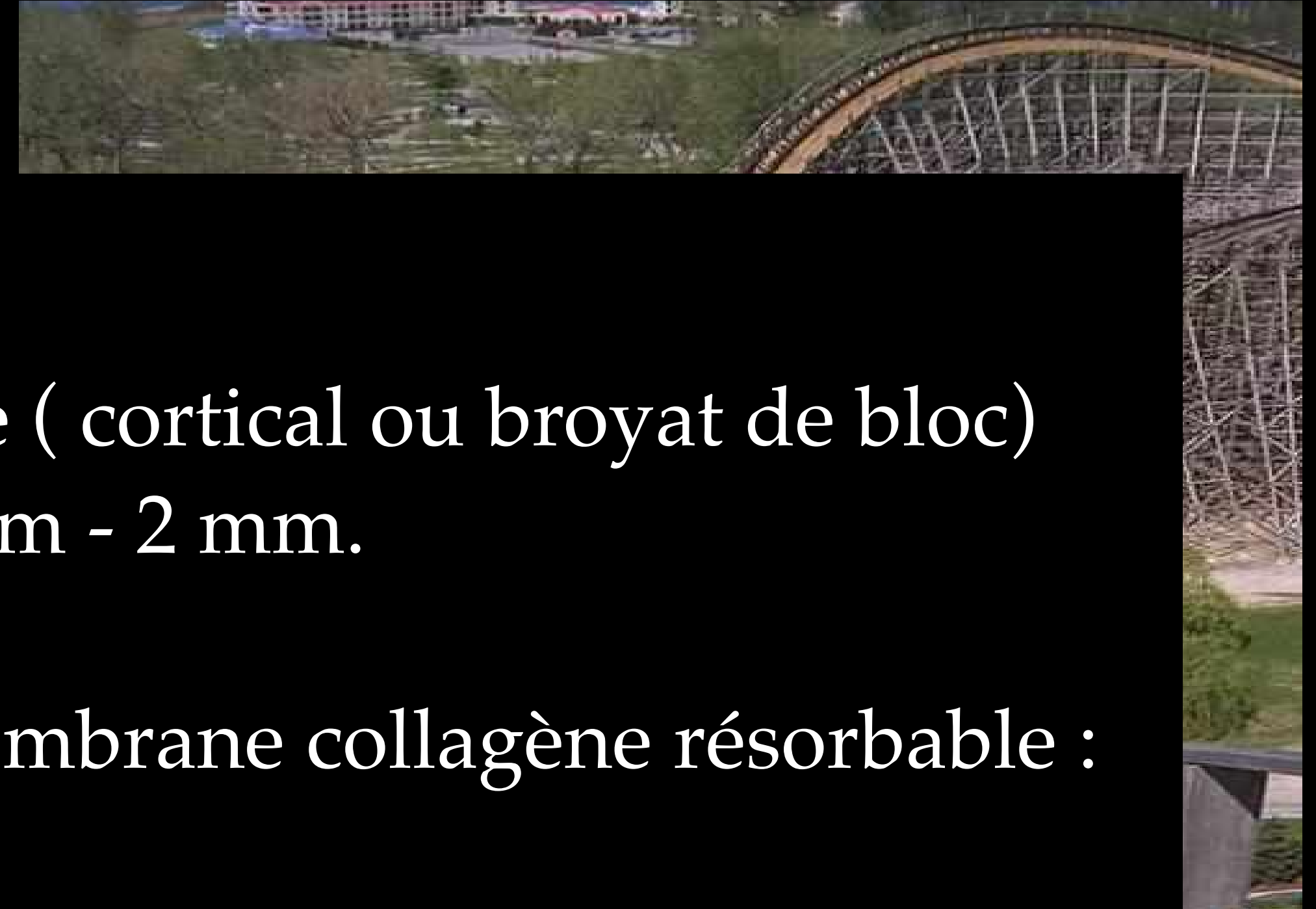
Mélange de :

Copeau d'os autogène (cortical ou broyat de bloc)

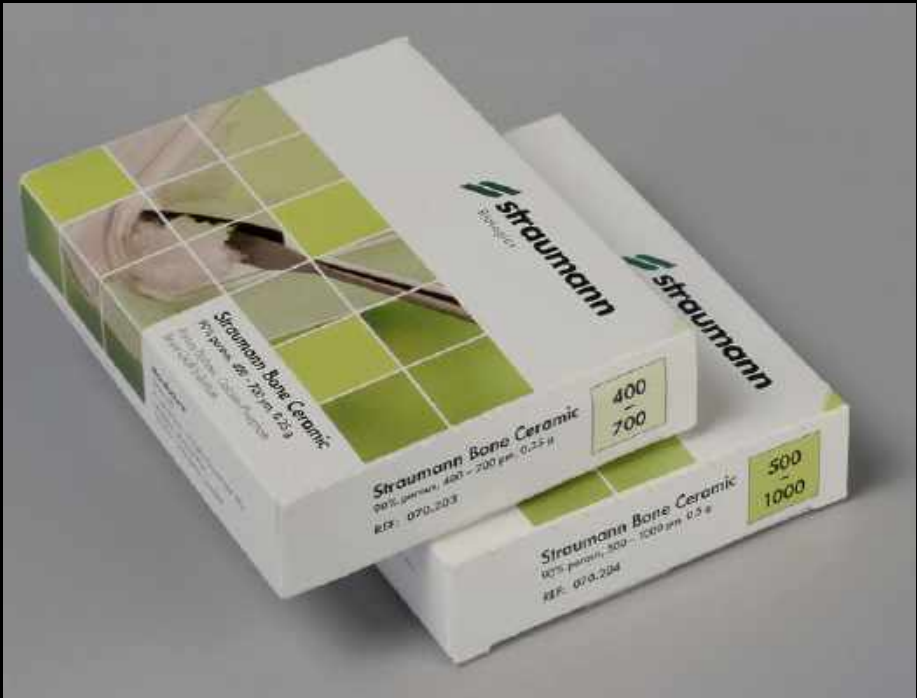
Bio - Oss (HA) de 1mm - 2 mm.

Recouvert par une membrane collagène résorbable :

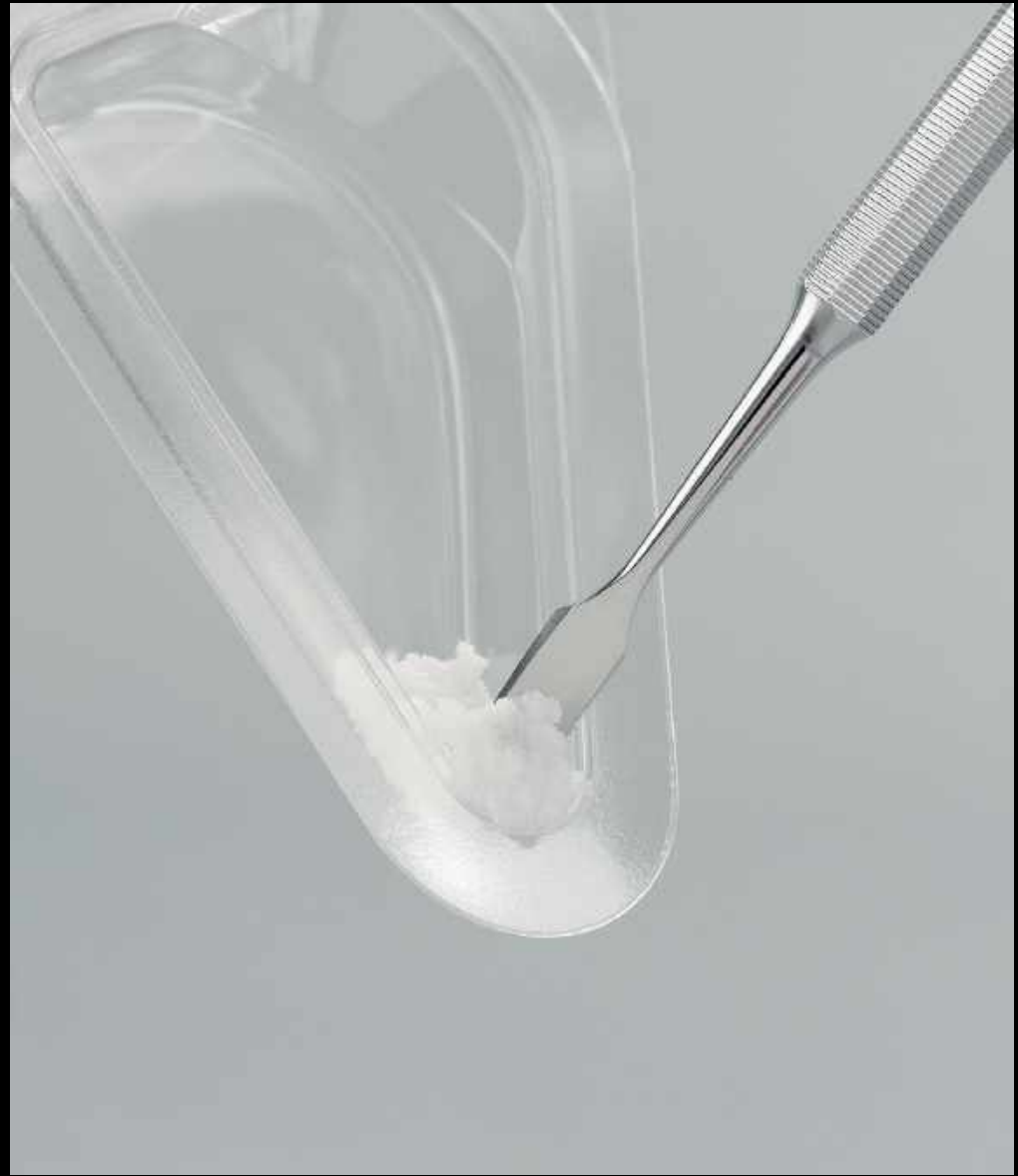Bio - Gide



2 - GREFFE DU SINUS PAR VOILET LATERAL

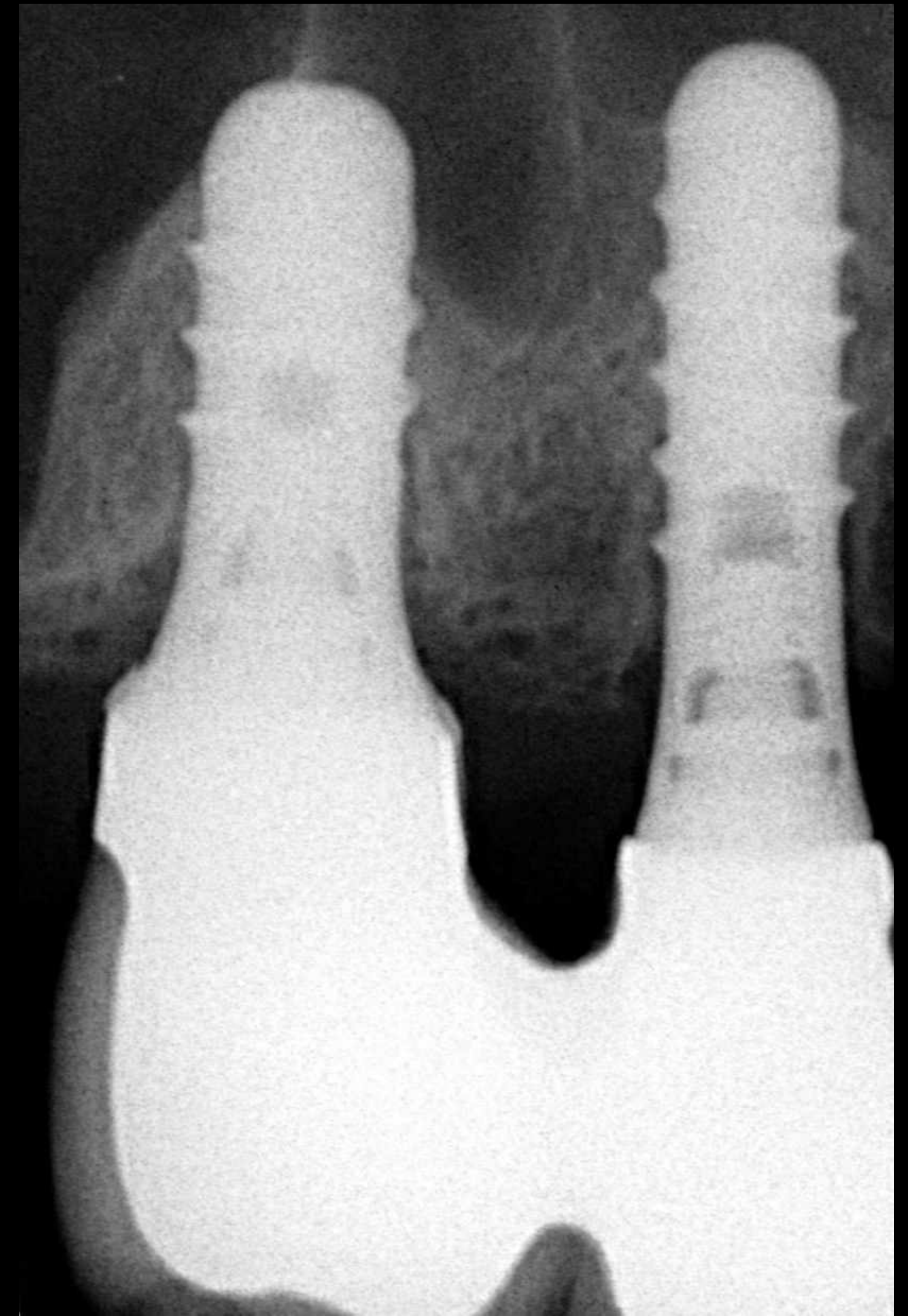
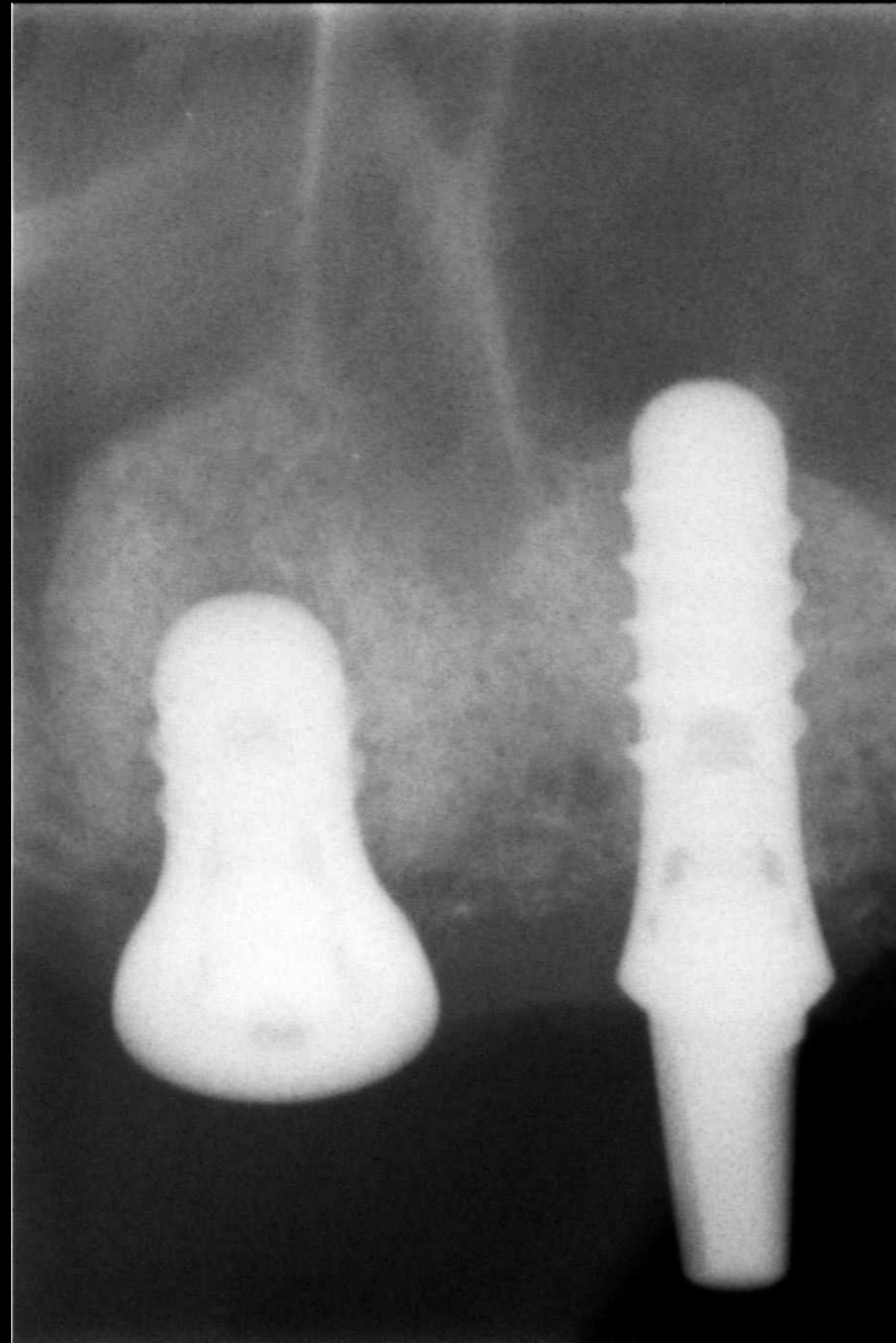


Quel Biomateriau ?

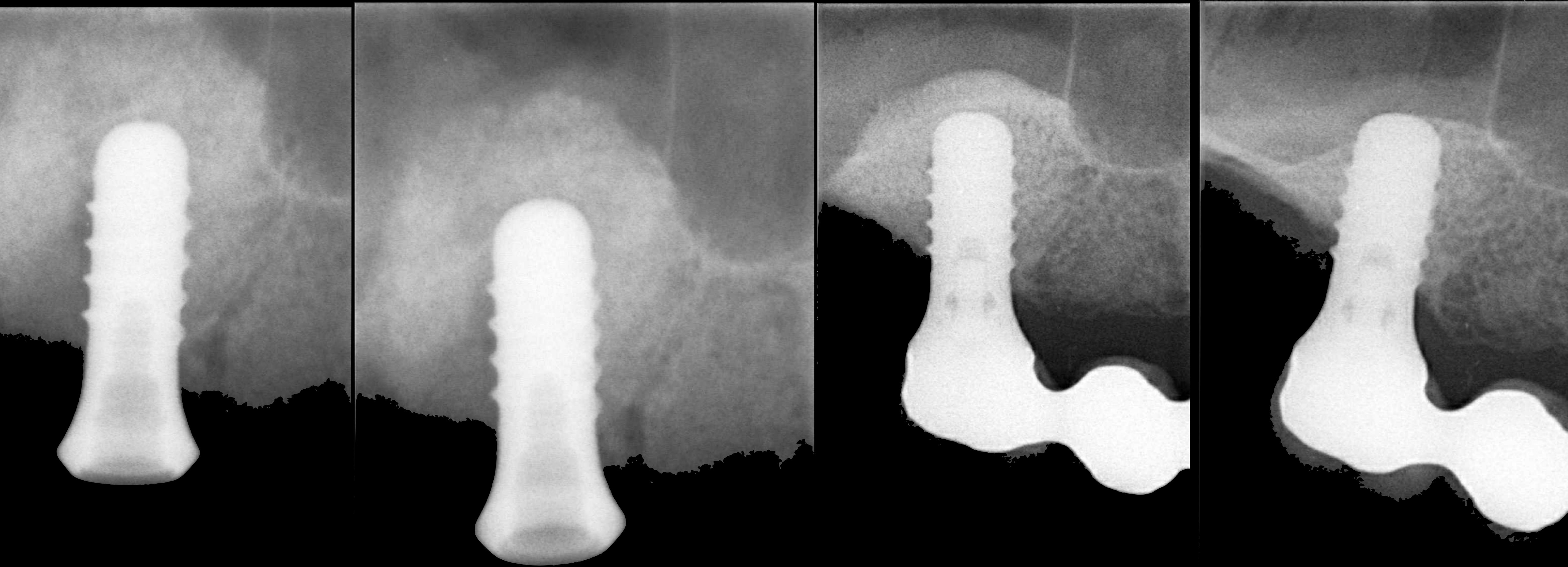


2 - GREFFE DU SINUS PAR VOILET LATERAL

1 - GREFFE DU SINUS PAR ABORD CRESTAL



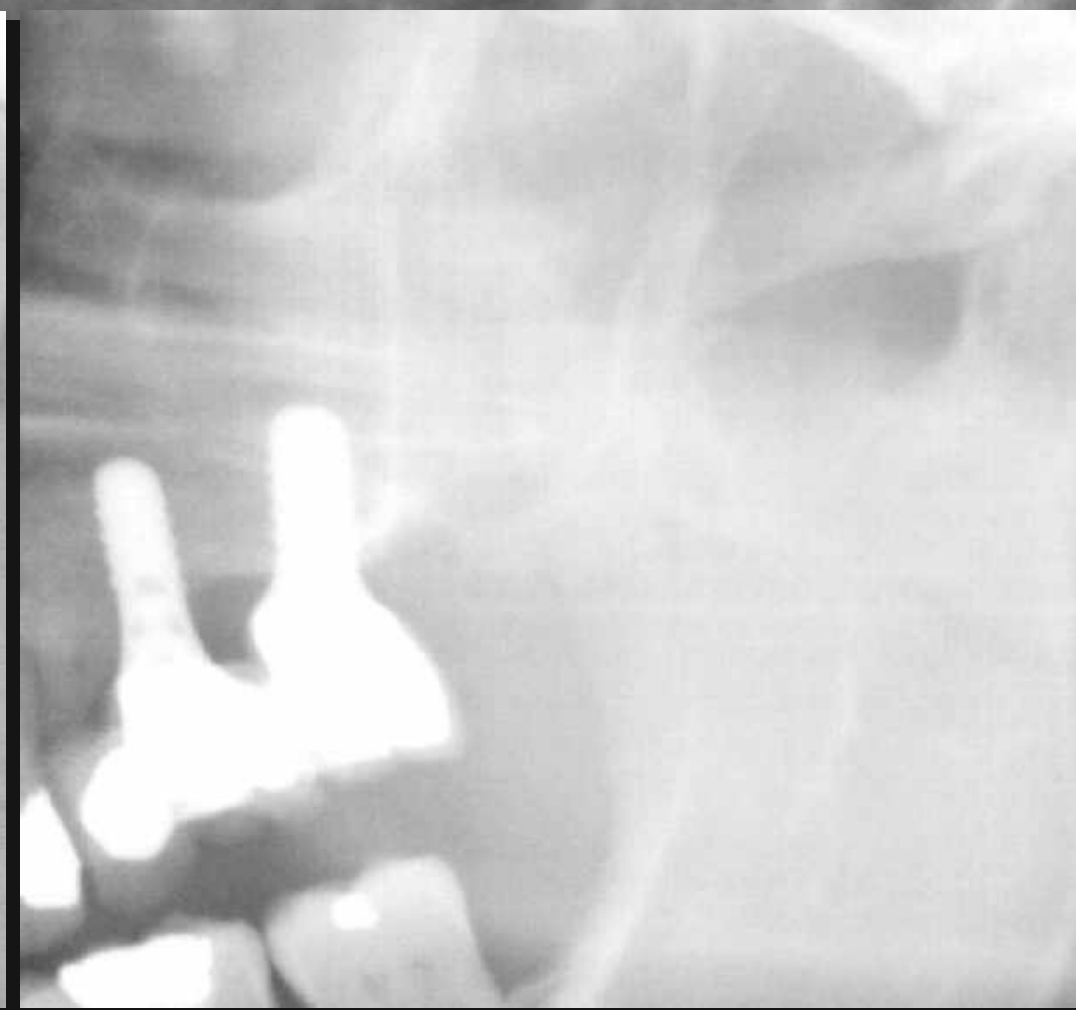
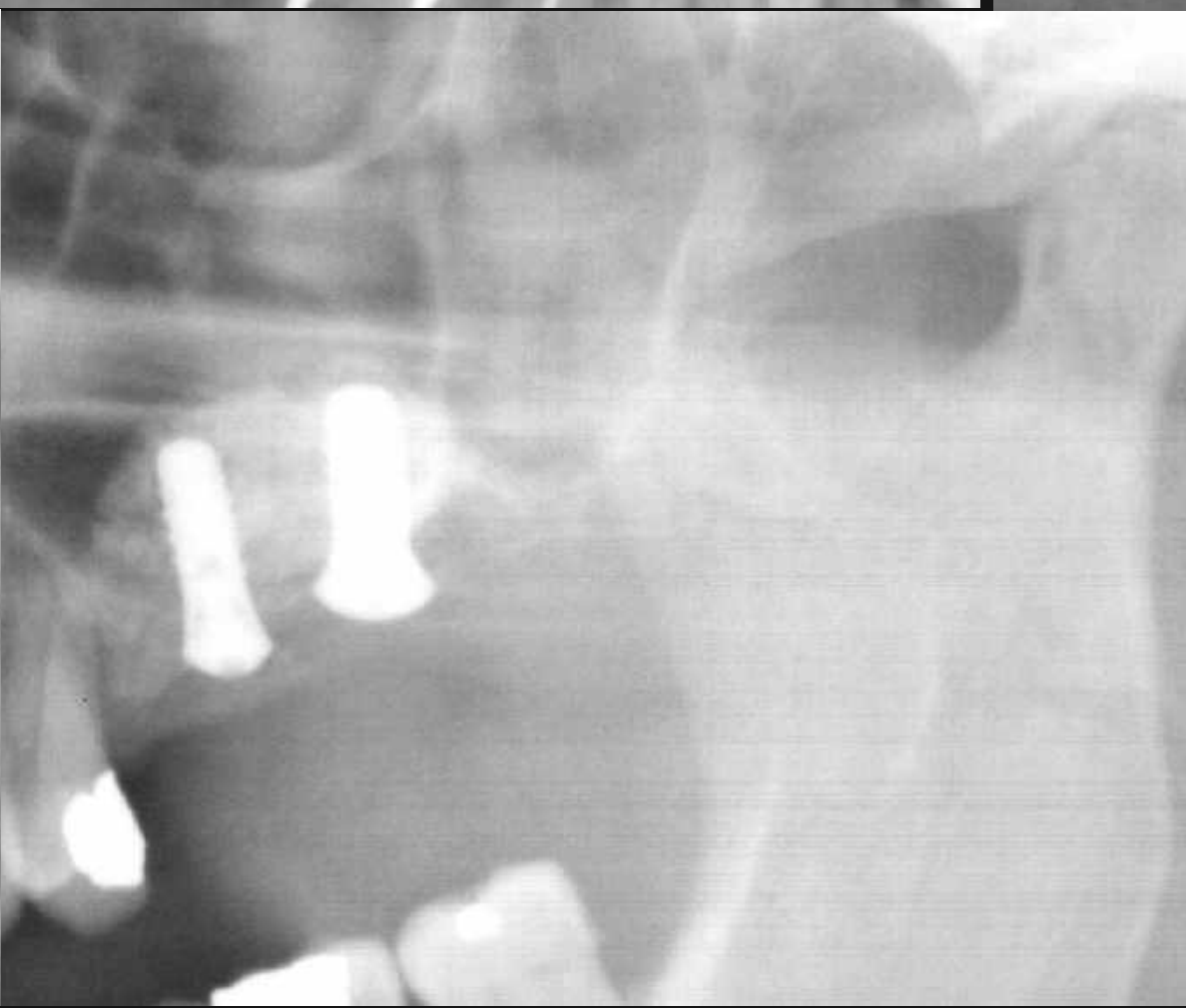
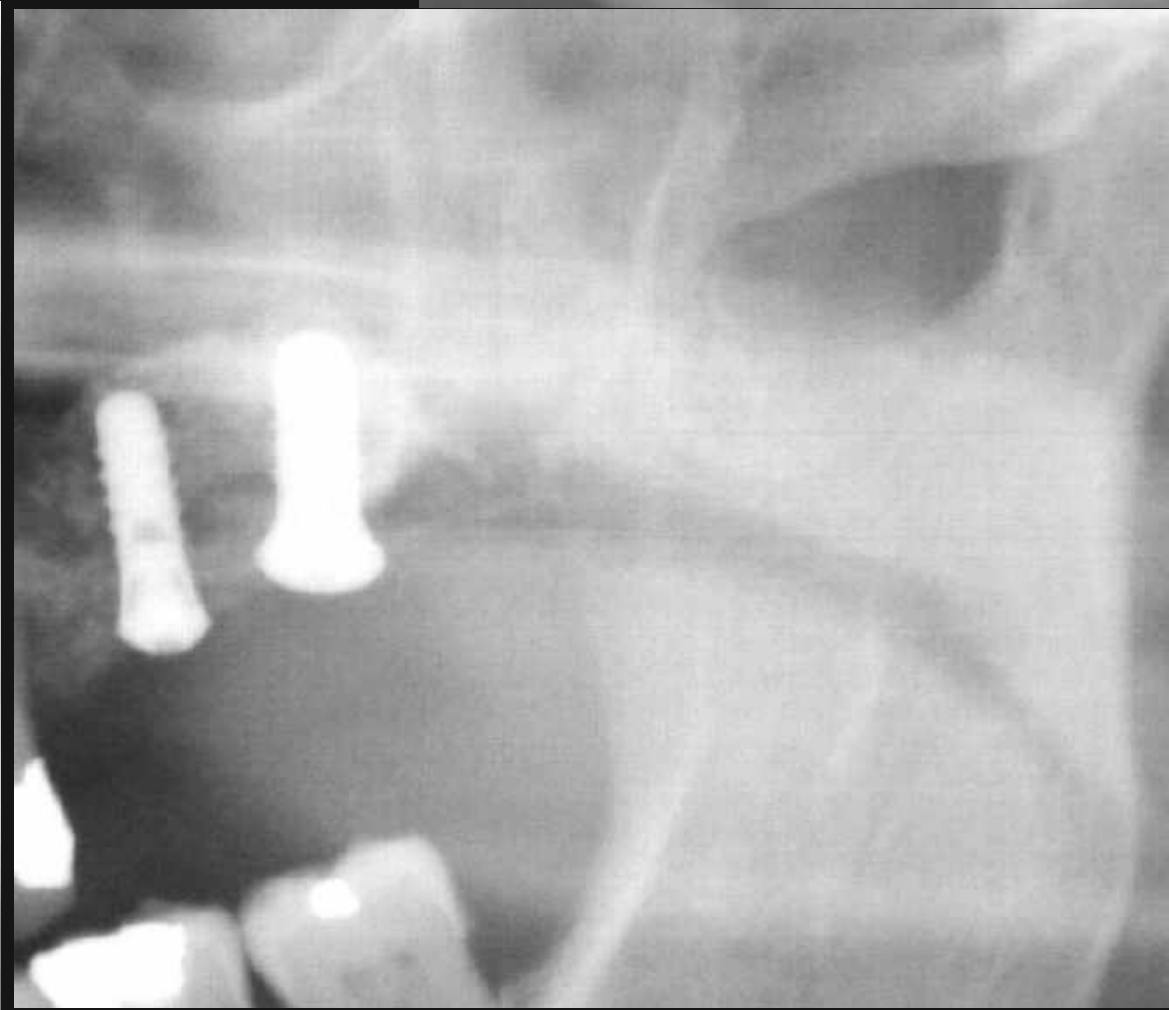
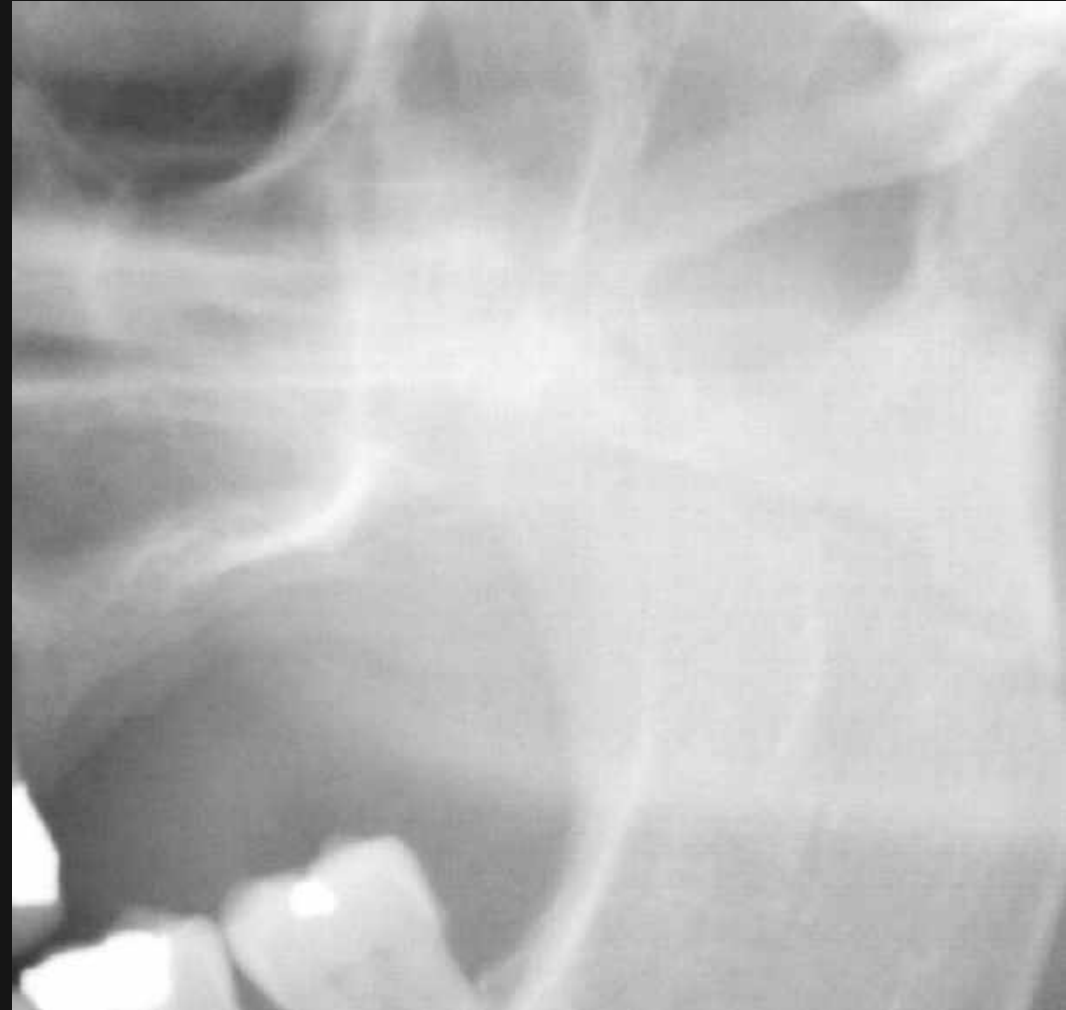
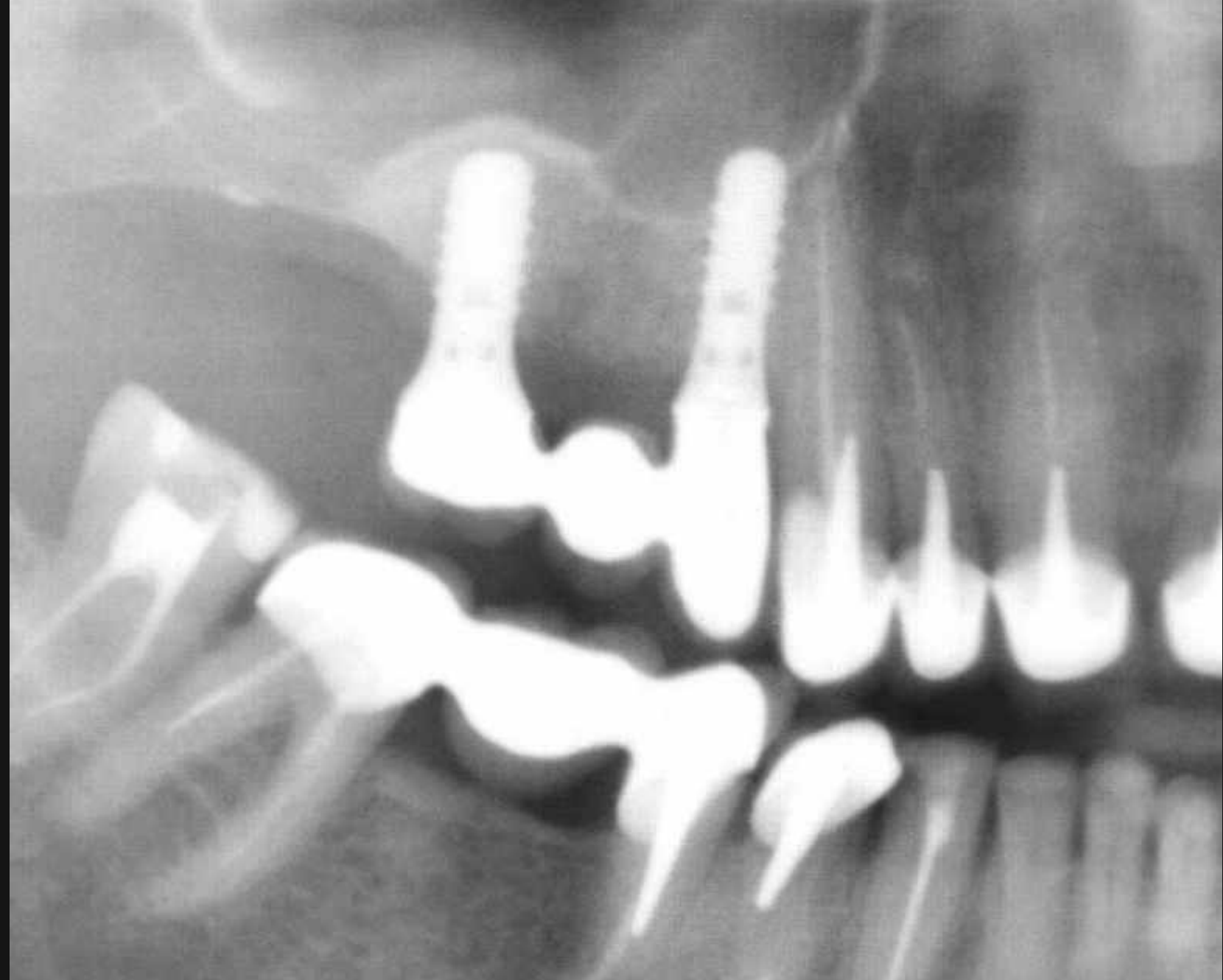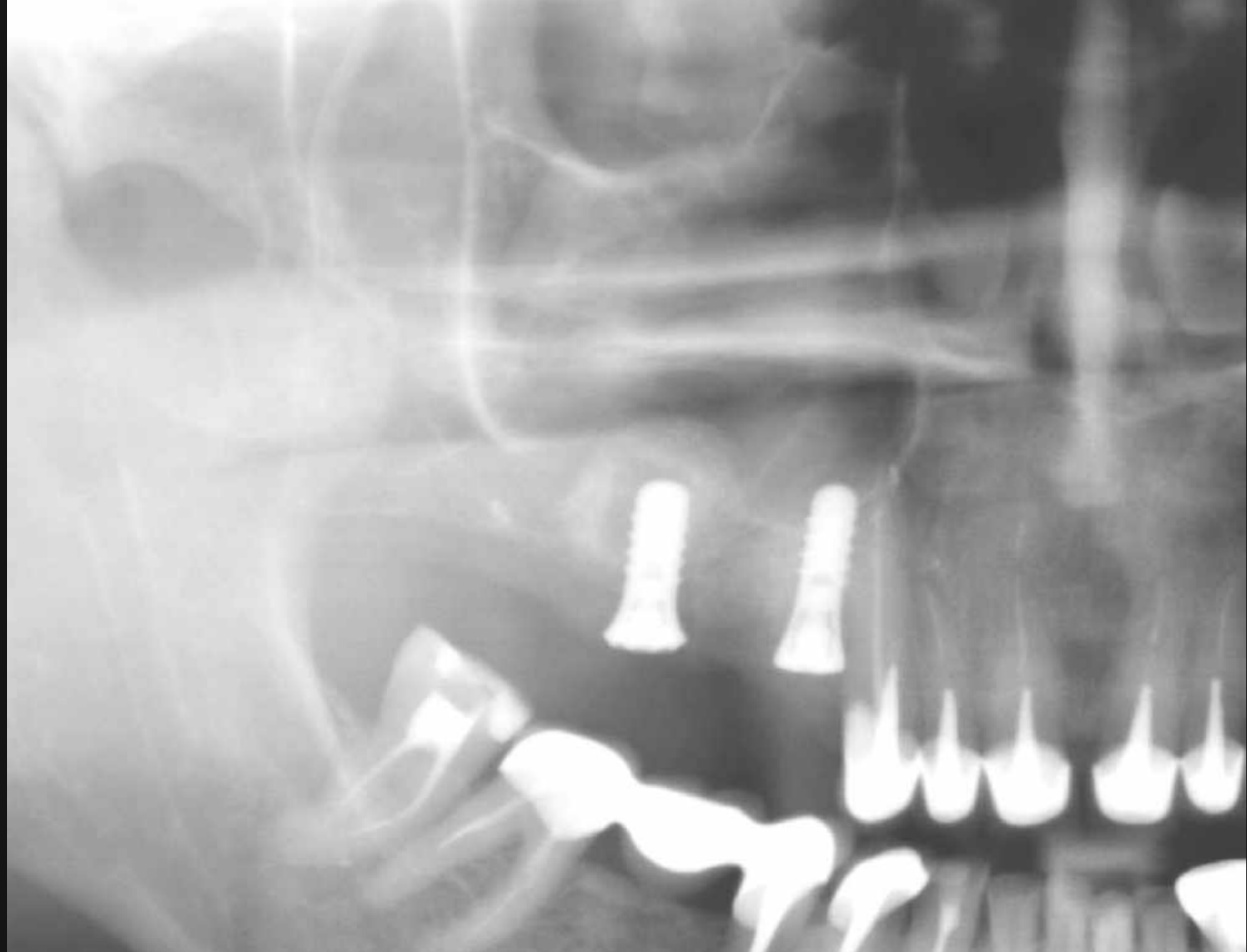
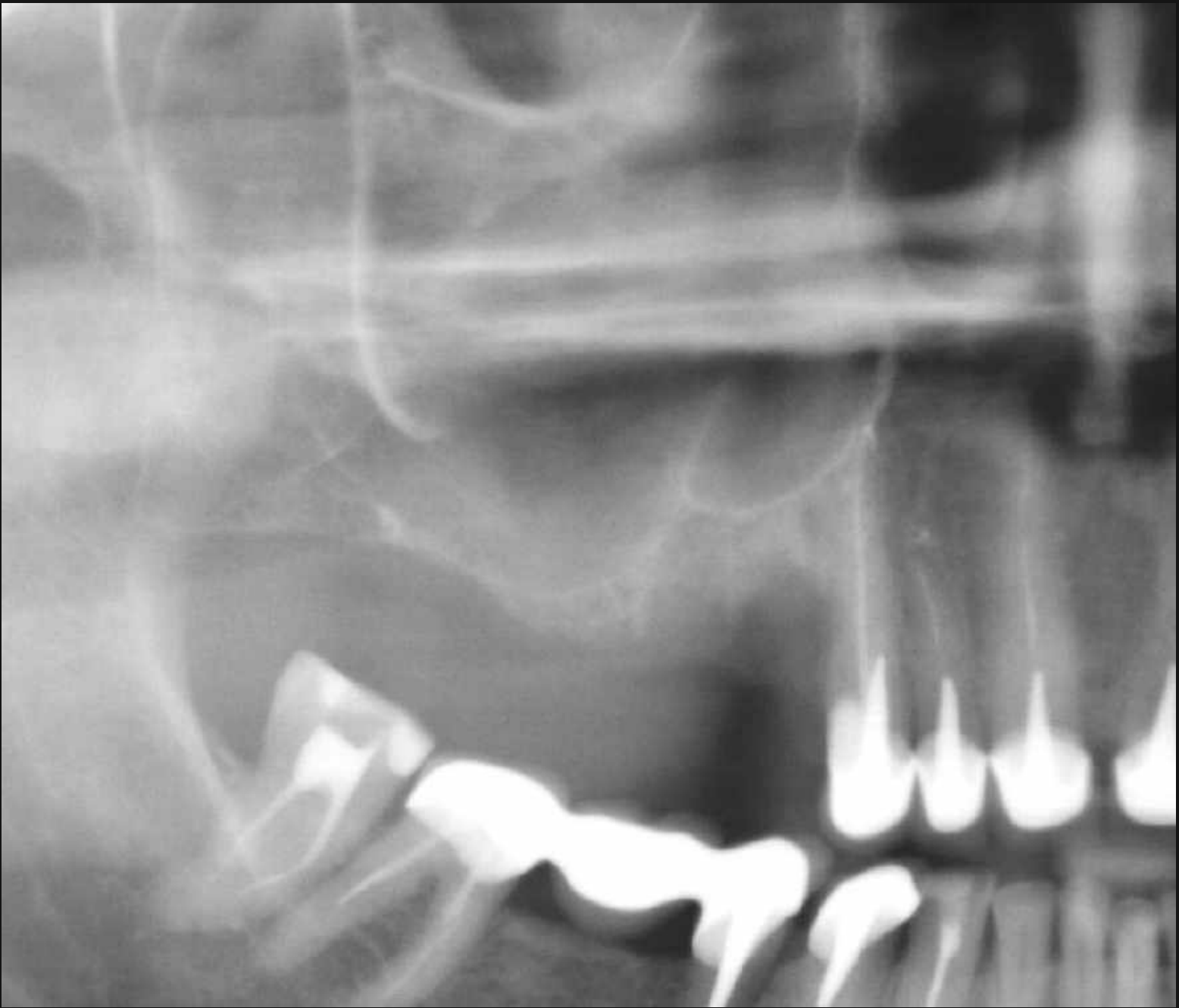
2 - GREFFE DU SINUS PAR VOILET LATERAL

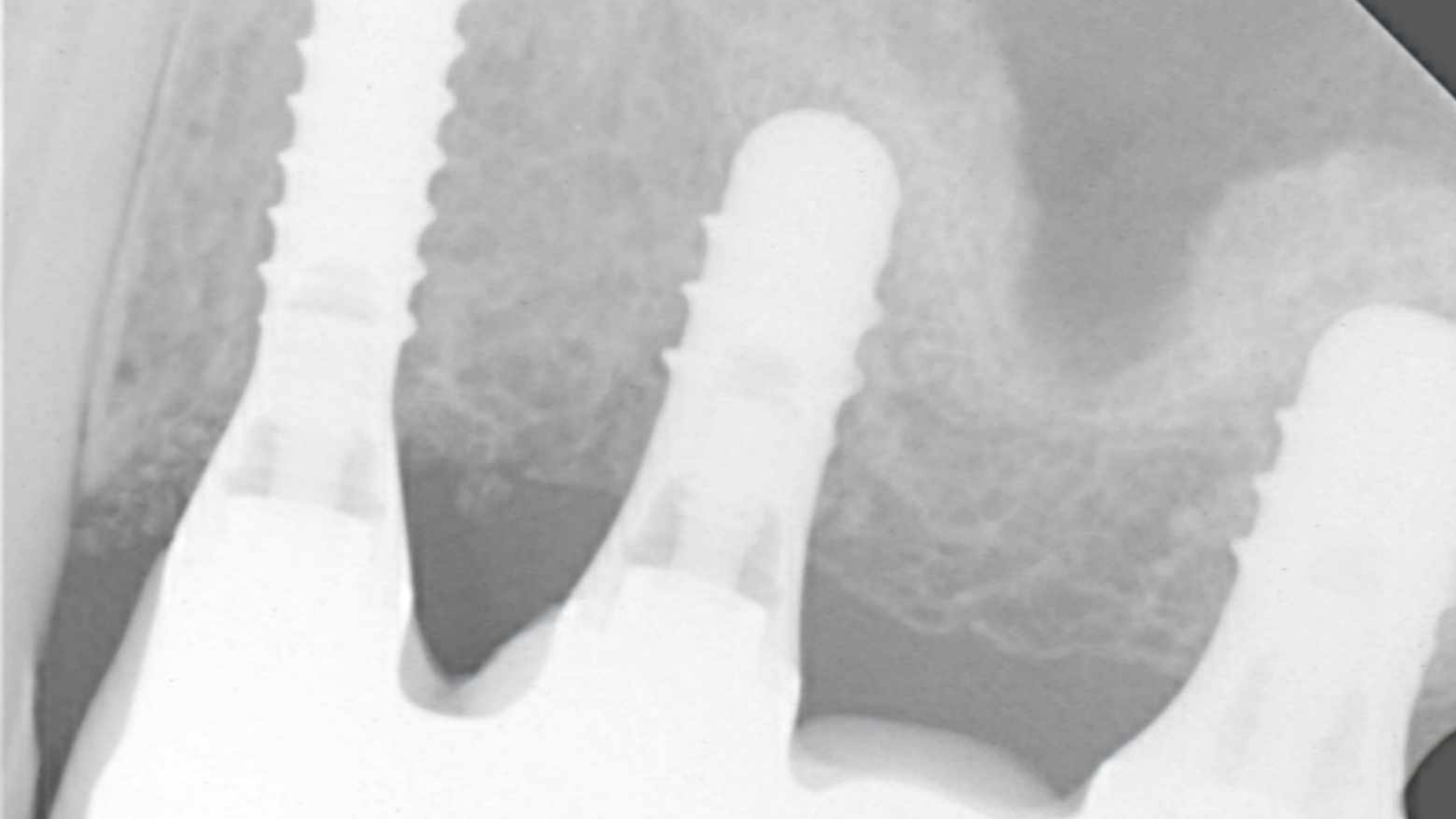


12 ans de maturation d'une greffe

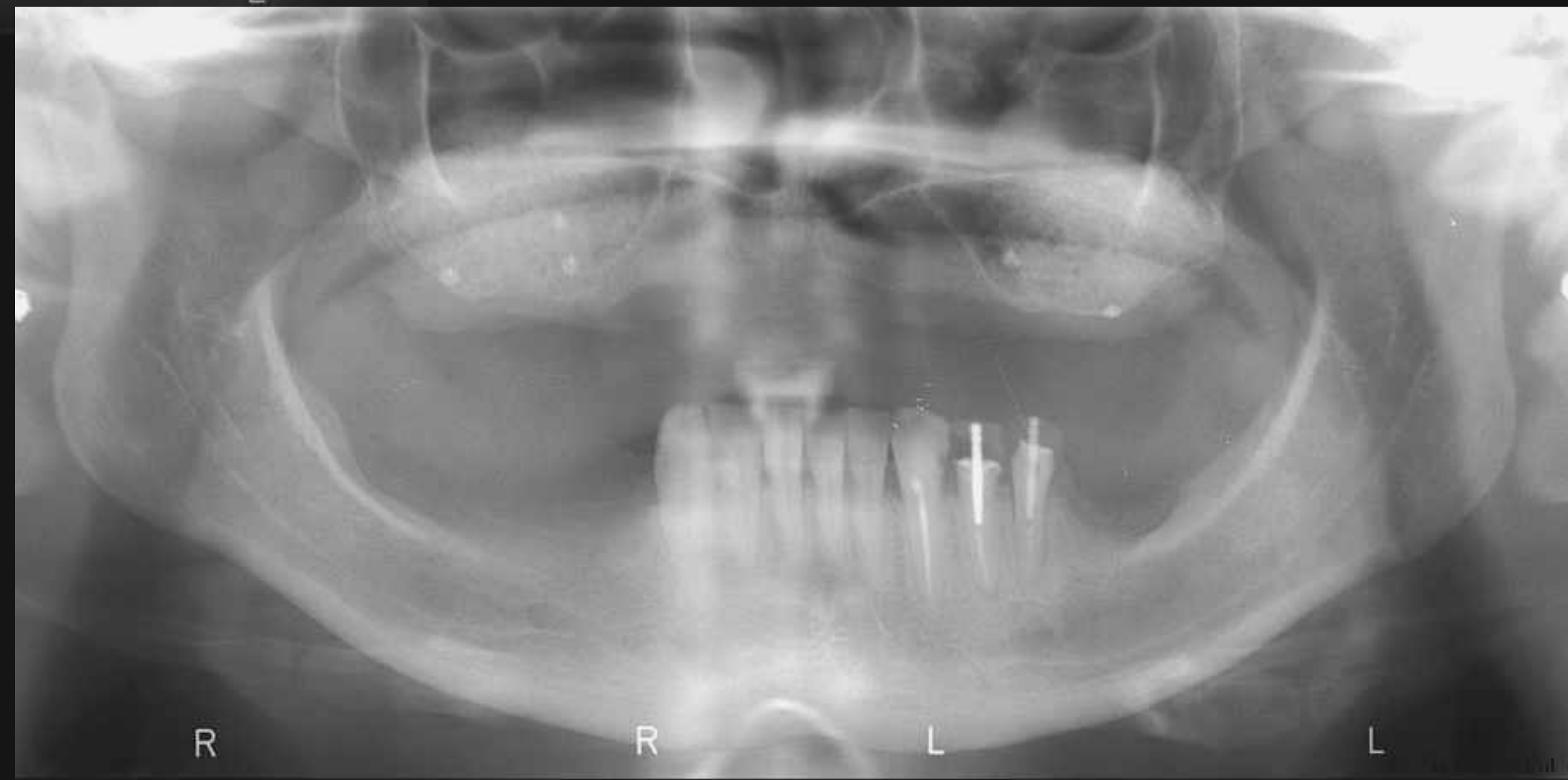
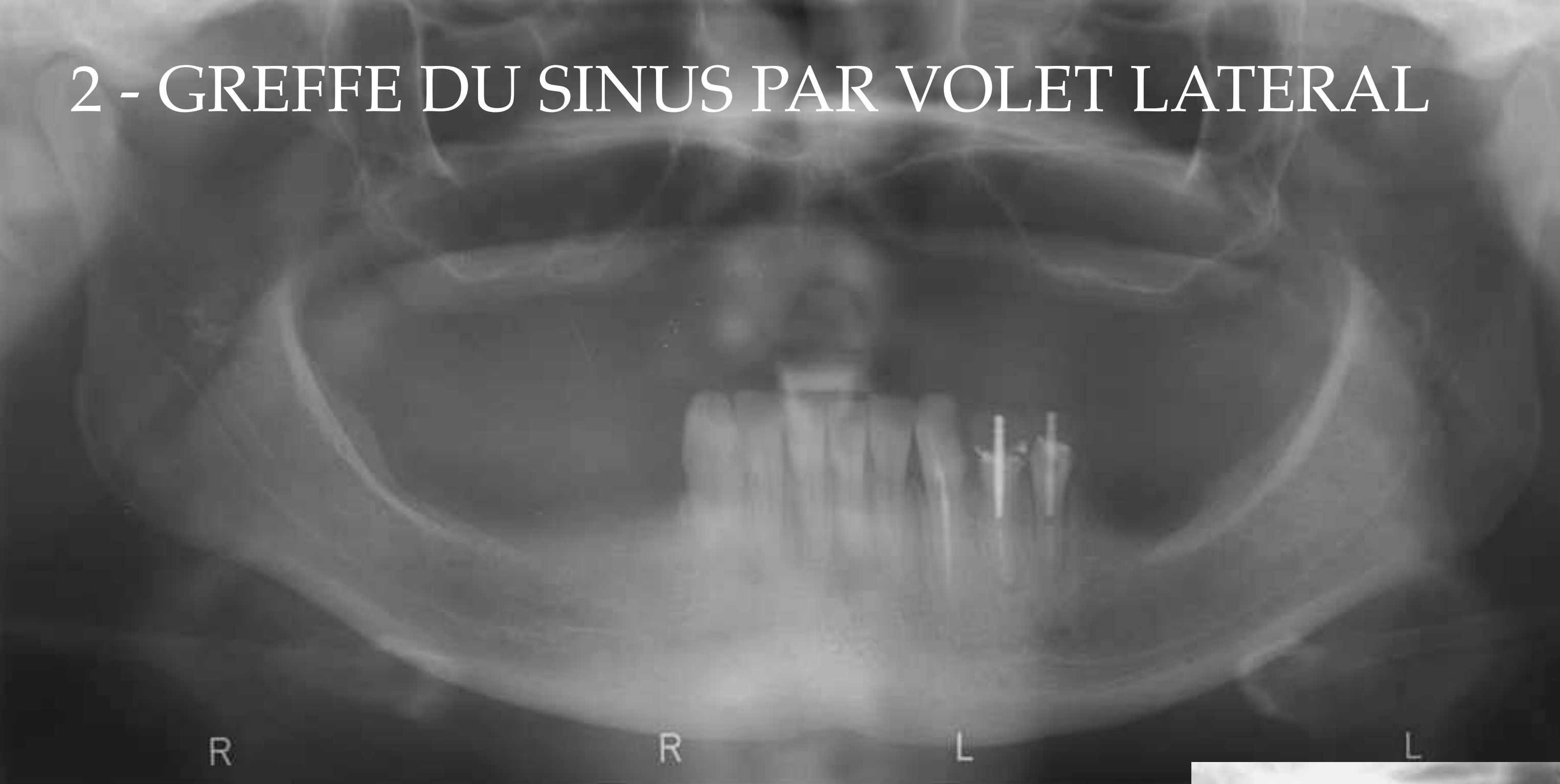


2 - GREFFE DU SINUS PAR VOILET LATERAL

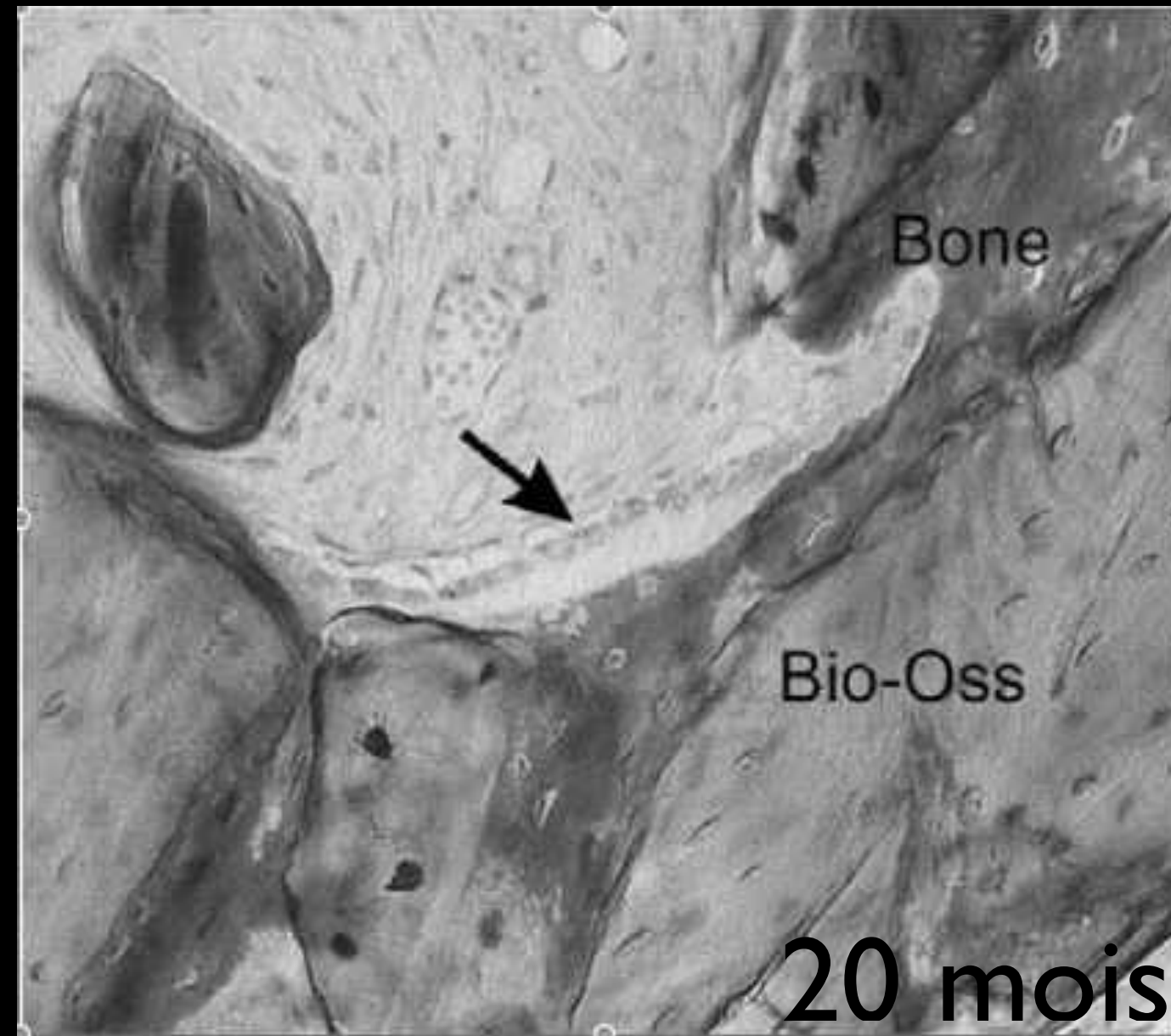




2 - GREFFE DU SINUS PAR VOILET LATERAL



Que devient le biomatériau dans le sinus ?



Patiente inclus dans étude
prospective

à 20 mois : prélèvement trephine
+ histo

à 7 ans : Fracture d'un implant
+ histo

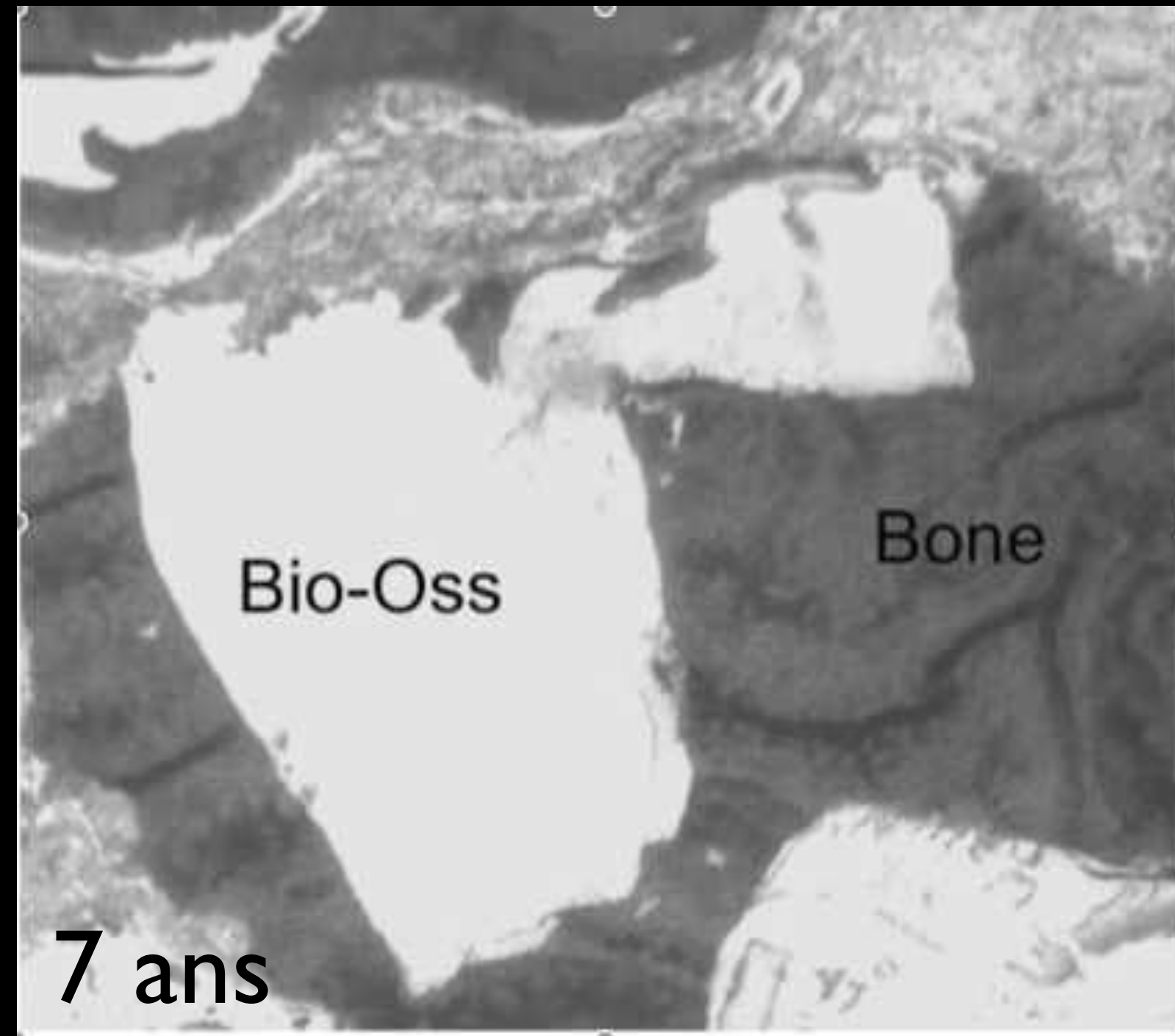
GX40

Os néoformé au contact du Bio-Oss

Nbx ostéoblastes


Orsini G, Scarano A, Degidi M, Caputi S, Iezzi G, Piattelli A. Histological and ultrastructural evaluation of bone around Bio-Oss particles in sinus augmentation.

Oral Dis. 2007 Nov;13(6):586-93.



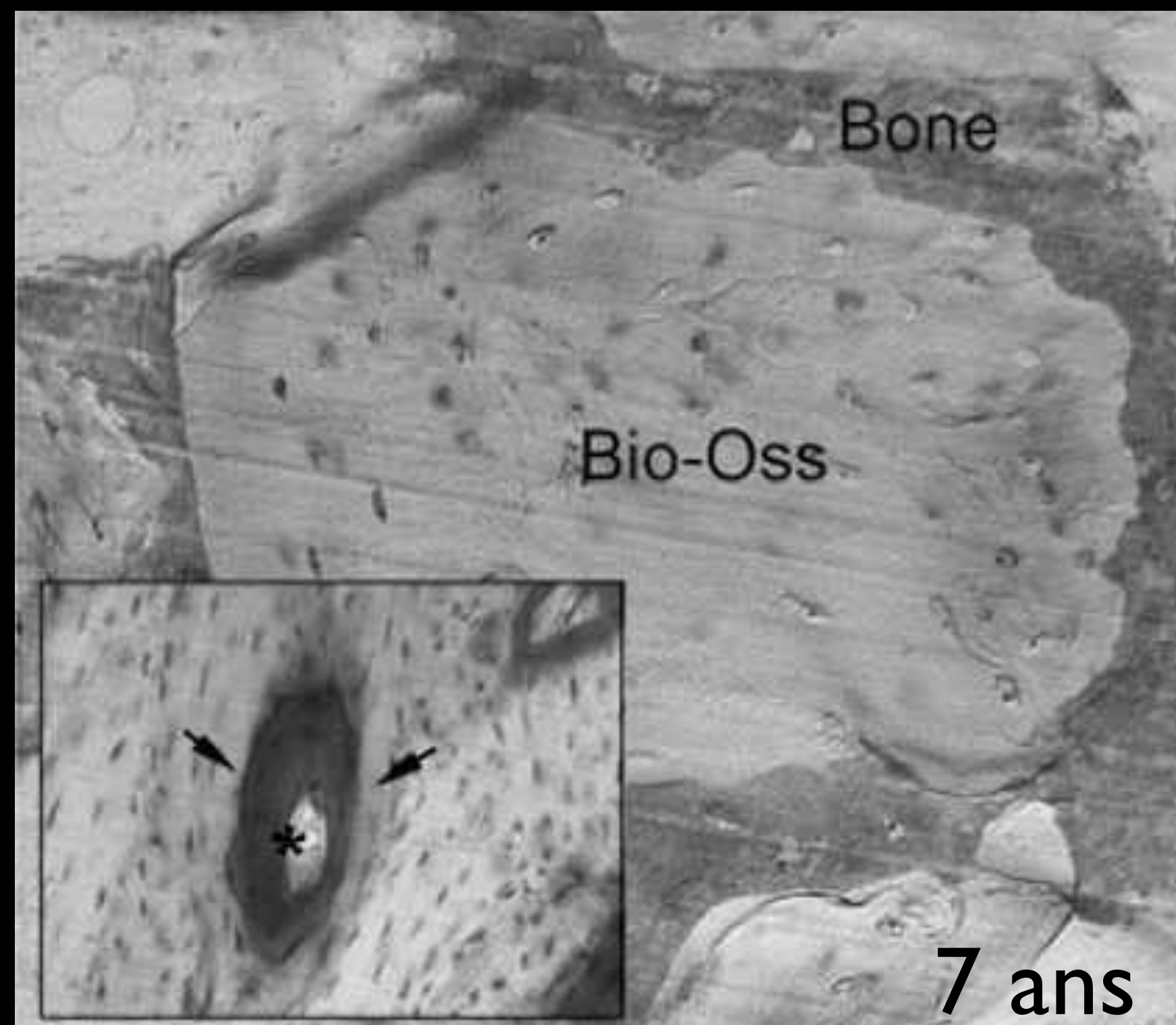
GX10
Contact étroit entre os et Bio-Oss
Particule Bio-Oss de petite taille :
Résorption de la xénogreffe

Orsini G, Scarano A, Degidi M, Caputi S, Iezzi G, Piattelli A. Histological and ultrastructural evaluation of bone around Bio-Oss particles in sinus augmentation.
Oral Dis. 2007 Nov;13(6):586-93.



TEM
Ostéoblaste produisant T. ostéoïde
à 20 mois

Orsini G, Scarano A, Degidi M, Caputi S, Iezzi G, Piattelli A. Histological and ultrastructural evaluation of bone around Bio-Oss particles in sinus augmentation.
Oral Dis. 2007 Nov;13(6):586-93.



7 ans :

Contact étroit entre Bio-Oss
et Os

Canaux de Havers et
néo-vascularisation

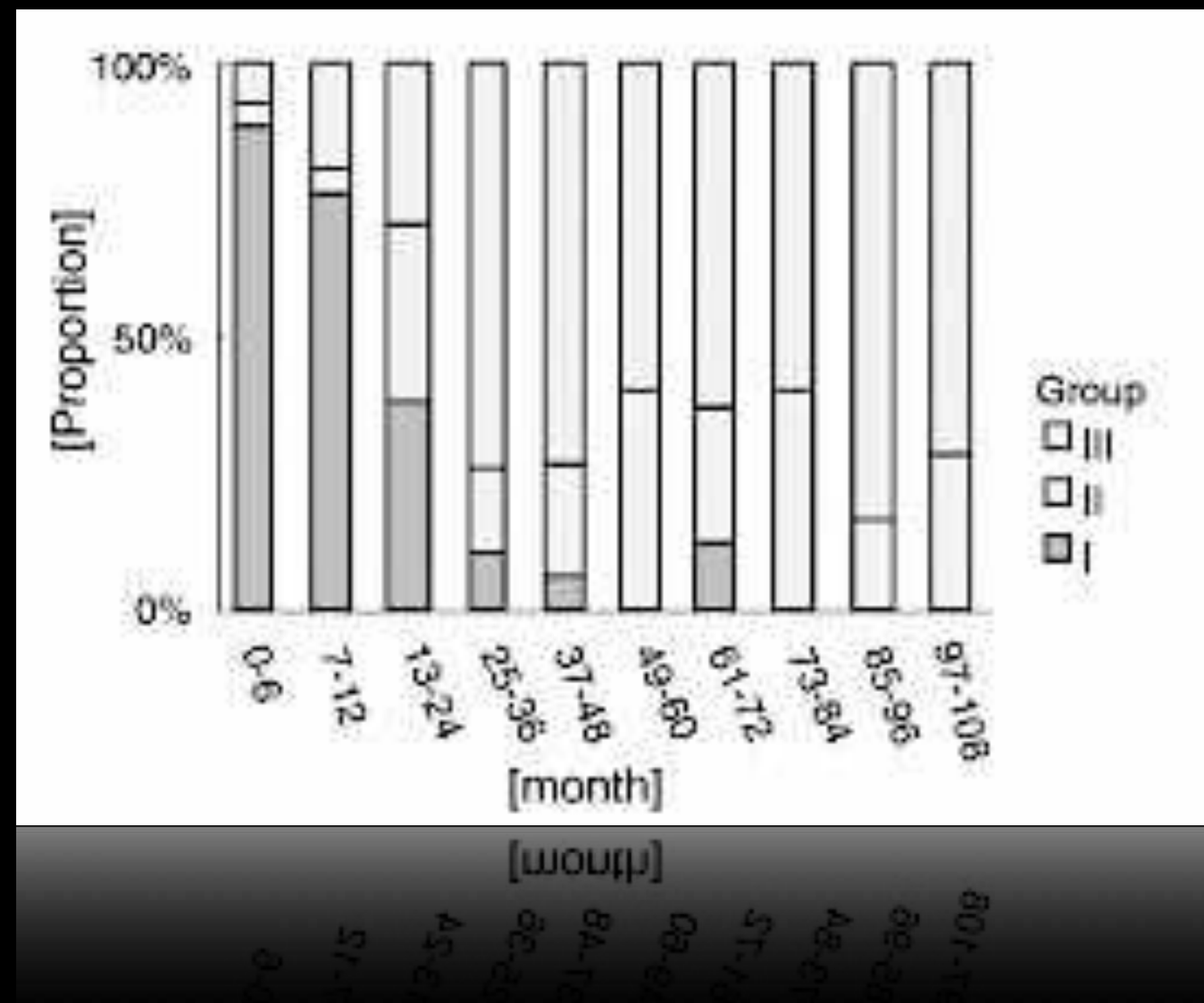
Orsini G, Scarano A, Degidi M, Caputi S, Iezzi G, Piattelli A. Histological and ultrastructural evaluation of bone around Bio-Oss particles in sinus augmentation.

Oral Dis. 2007 Nov;13(6):586-93.

2 - GREFFE DU SINUS PAR VOILET LATERAL

Hatano N., Shimizu Y, Ooya K. Aclinical long-term radiographic evaluation of graft height changes after maxillary sinus floor augmentation with 2:1 autogenous bone/ xenograft mixture and simultaneous placement of dental implants. *Clin. Oral Impl. Res.* 15: 2004; 339-345

Re-pneumatisation du sinus durant les deux ou trois premières années après la greffe



191 patients suivi sur dix ans après une procédure de greffe du sinus

2 - GREFFE DU SINUS PAR VOLET LATERAL

Chiapasco M, Zaniboni M, Boisco M. Augmentation procedures for the rehabilitation of deficient edentulous ridges with oral implants. *Clin. Oral Impl. Res.* 17 (suppl 2), 2006; 136-159

L'utilisation de matériau non résorbable ou à résorption lente permet de prévenir ce phénomène . Avec l'os autogène une mixture de HA permet de limiter cette re-pneumatisation en limitant le risque de résorption osseuse.

Tidwell et Al 1992 ; Chiapasco & Ronchi 1994 ; Neyt et al 1997 ; Mayfield et al 2001 ; Hallman et al 2002, Halmann & Zetterqvist 2004; Hallman & Nordin 2004

2 - GREFFE DU SINUS PAR VOLET LATERAL



Membrane résorbable.

Wallace SS, Froum SJ, Cho SC, Elian N, Monteiro D, Kim BS, Tarnow DP.

Sinus augmentation utilizing anorganic bovine bone (Bio-Oss) with absorbable and nonabsorbable membranes placed over the lateral window: histomorphometric and clinical analyses.

Int J Periodontics Restorative Dent. 2005 Dec;25(6):551-9.

51 patients - 64 greffes de sinus - Pose différée de 135 implants.

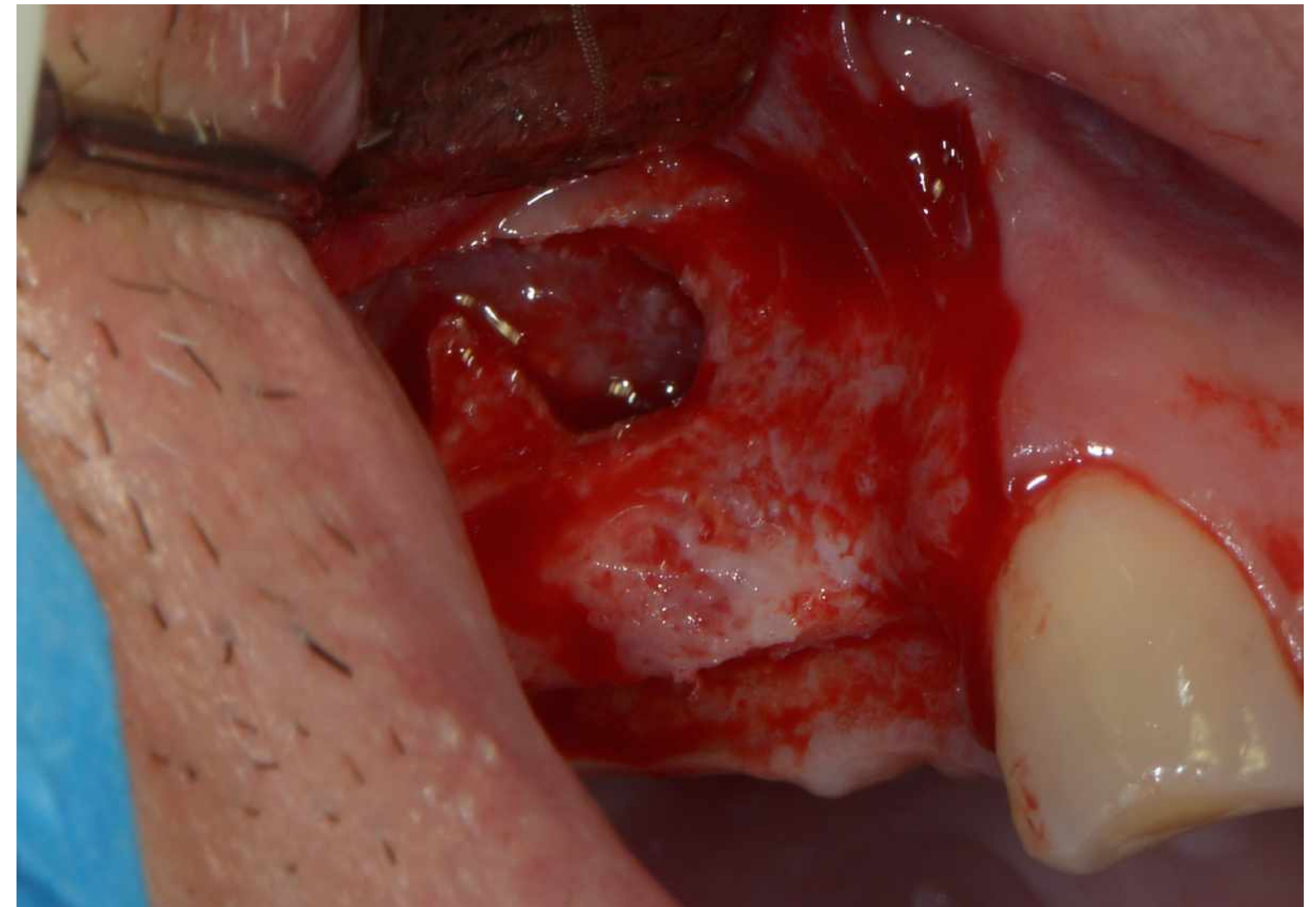
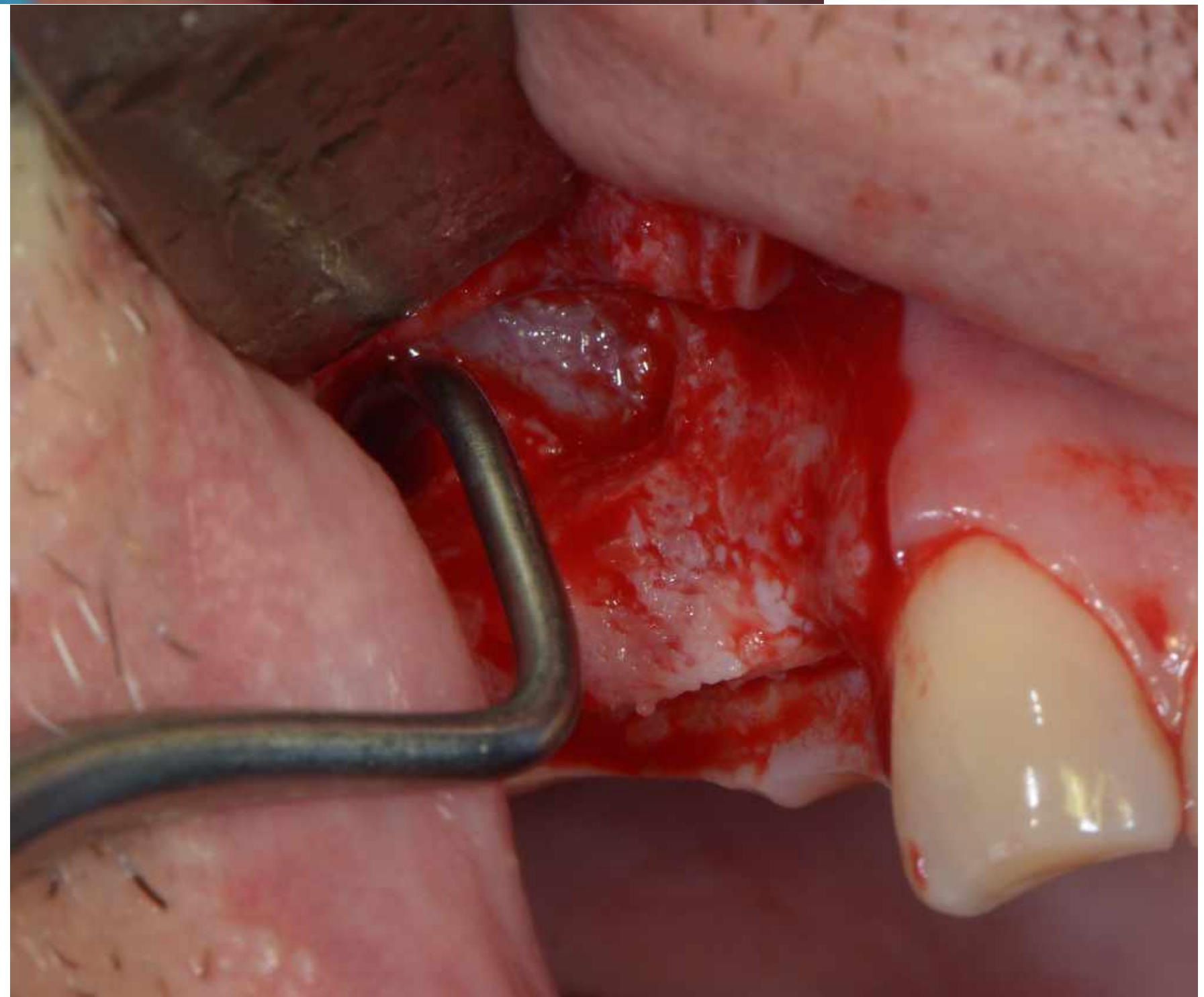
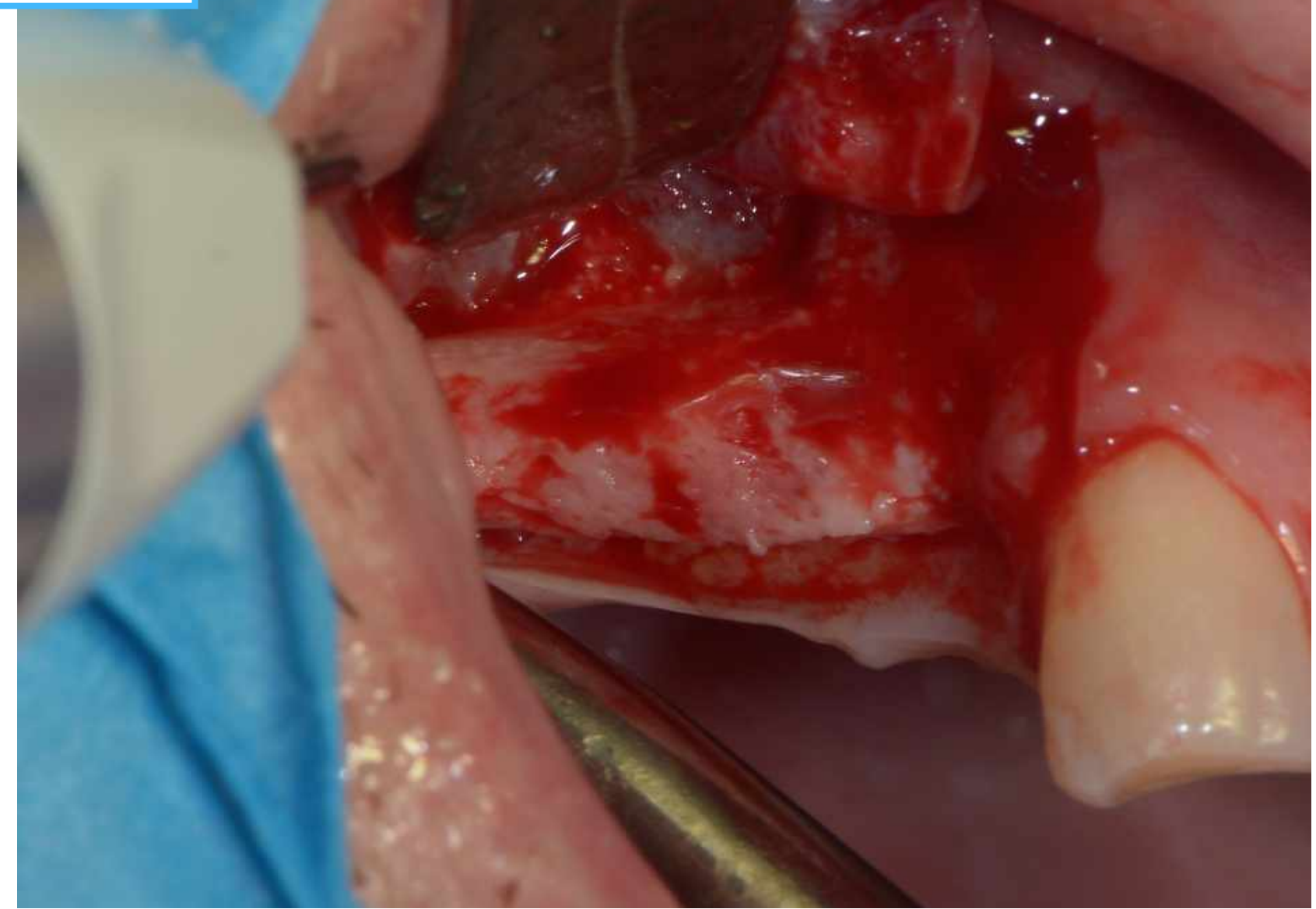
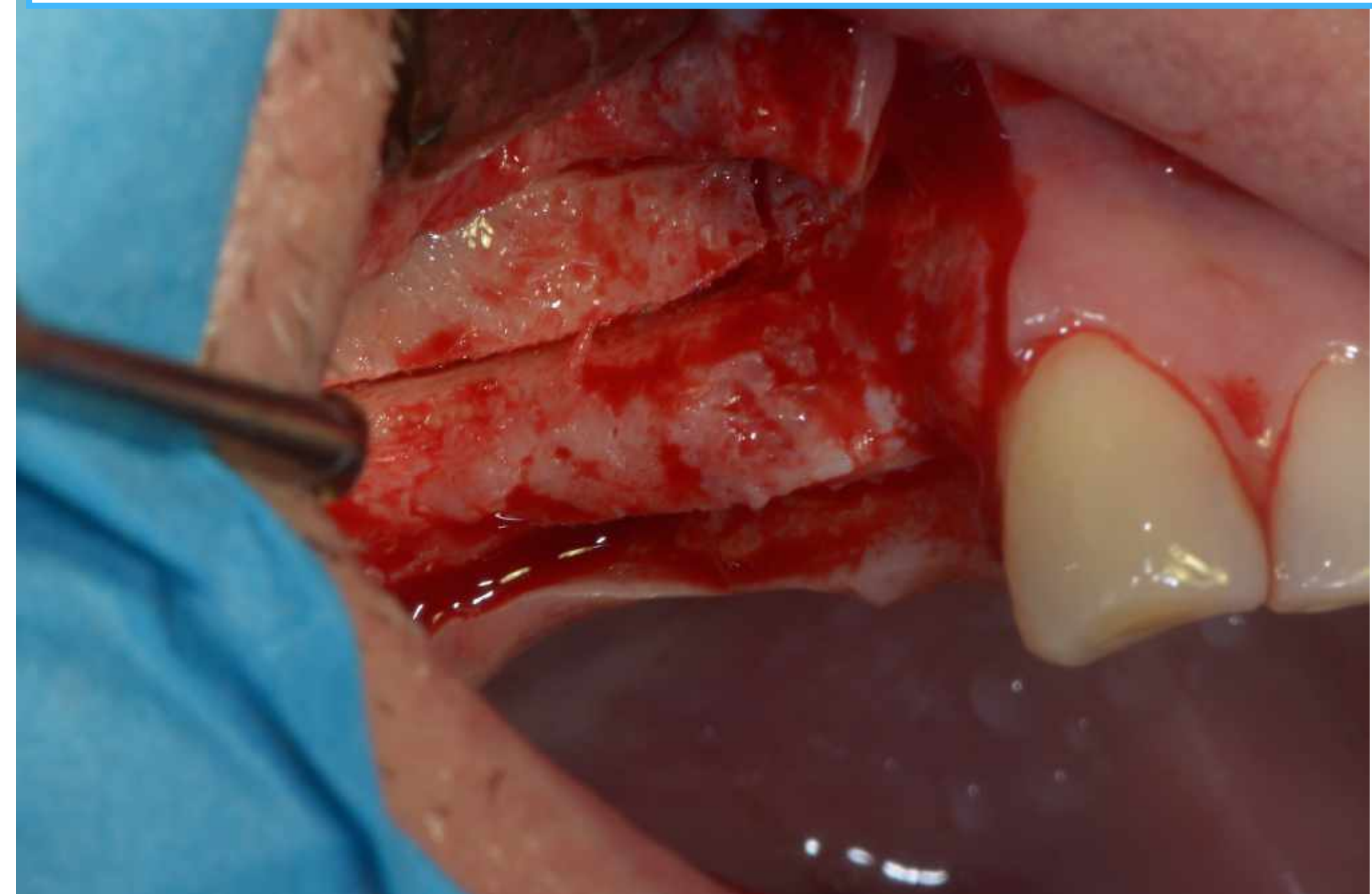
Prélèvement 6 à 10 mois après la greffe .

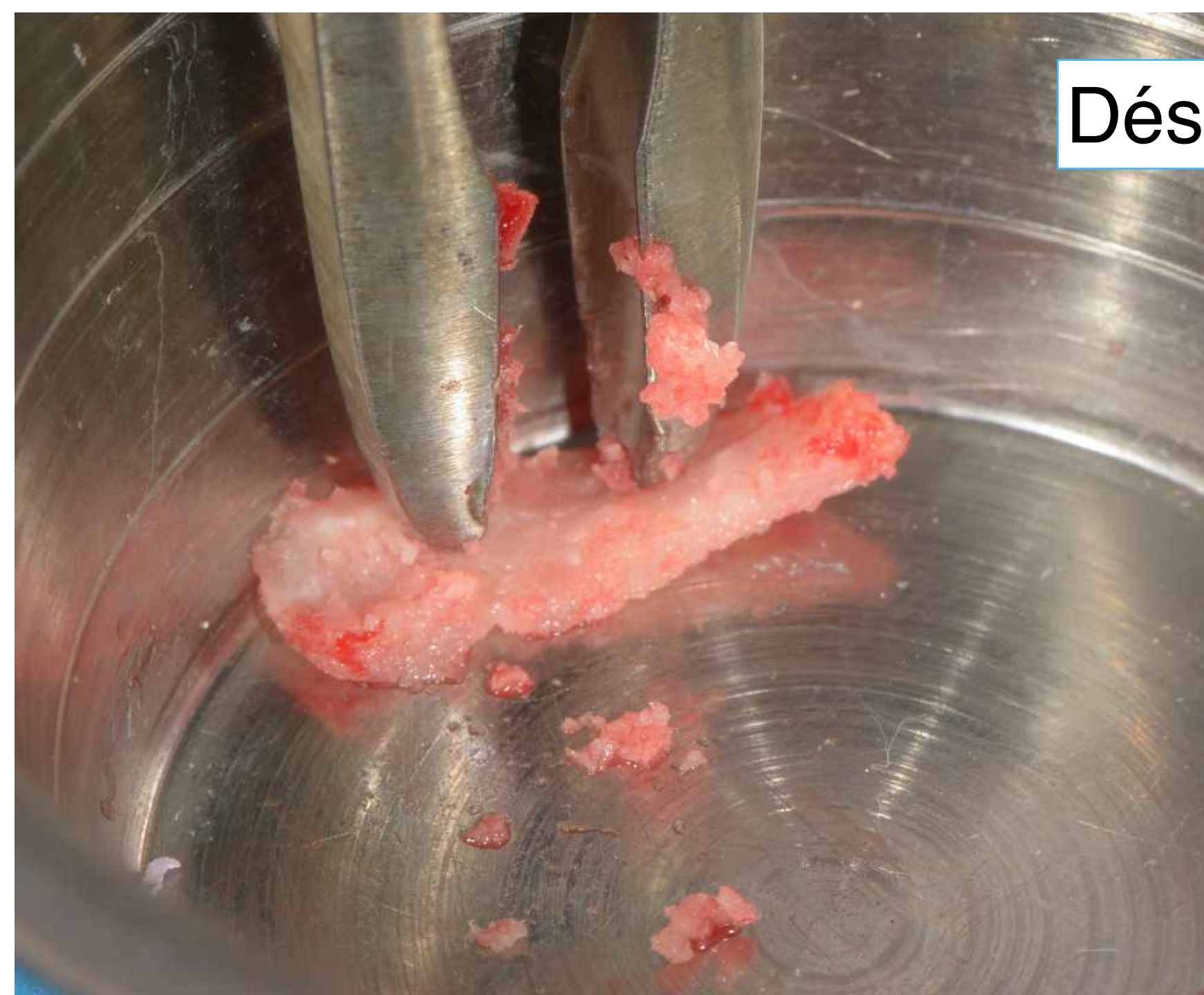
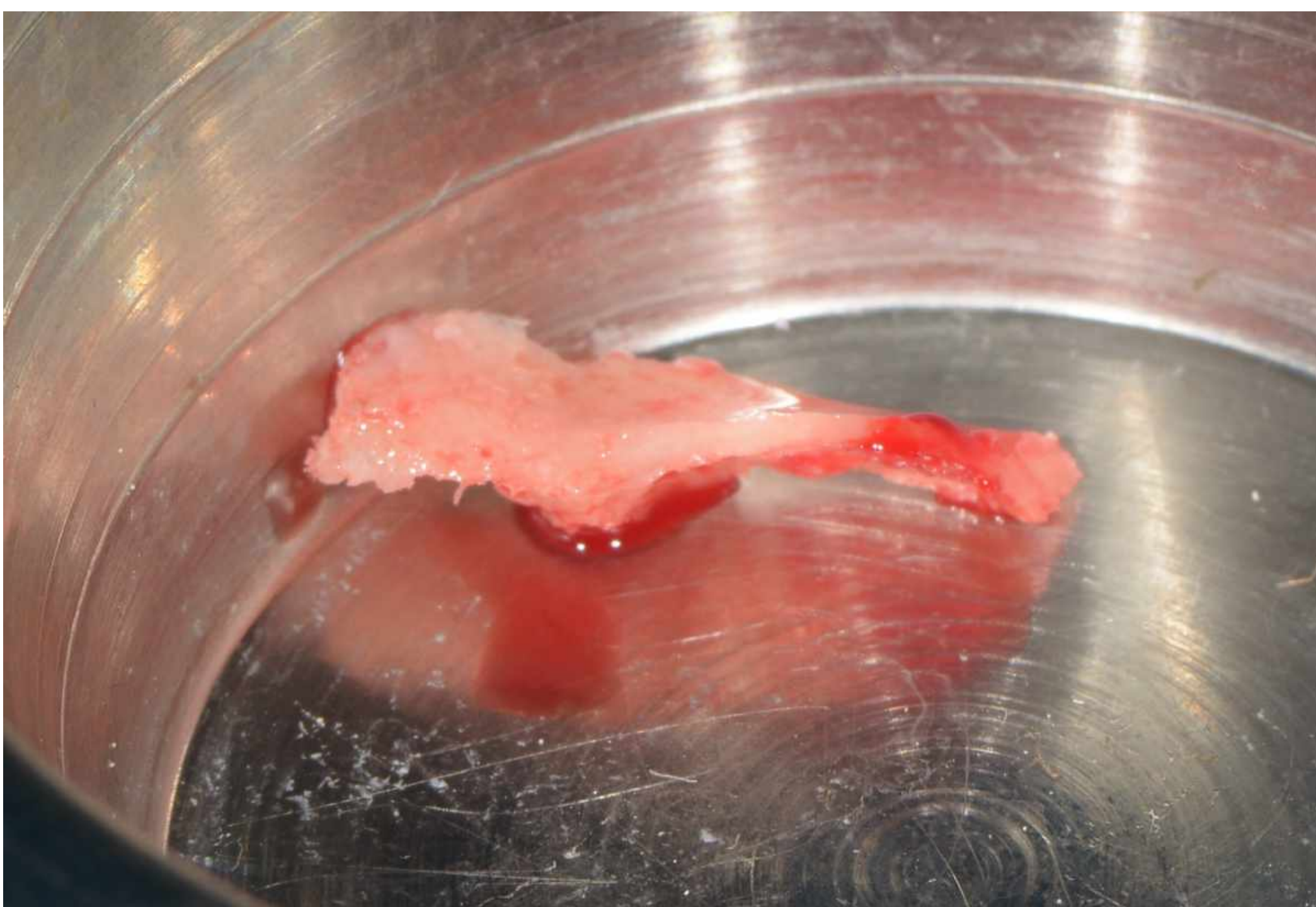21 sinus avec PTFE-e	16,9% d'os vital
37 sinus avec BioGide	17,6 % d'os vital
6 sans membrane	12,1 % d'os vital

POUR ALLER PLUS LOIN !

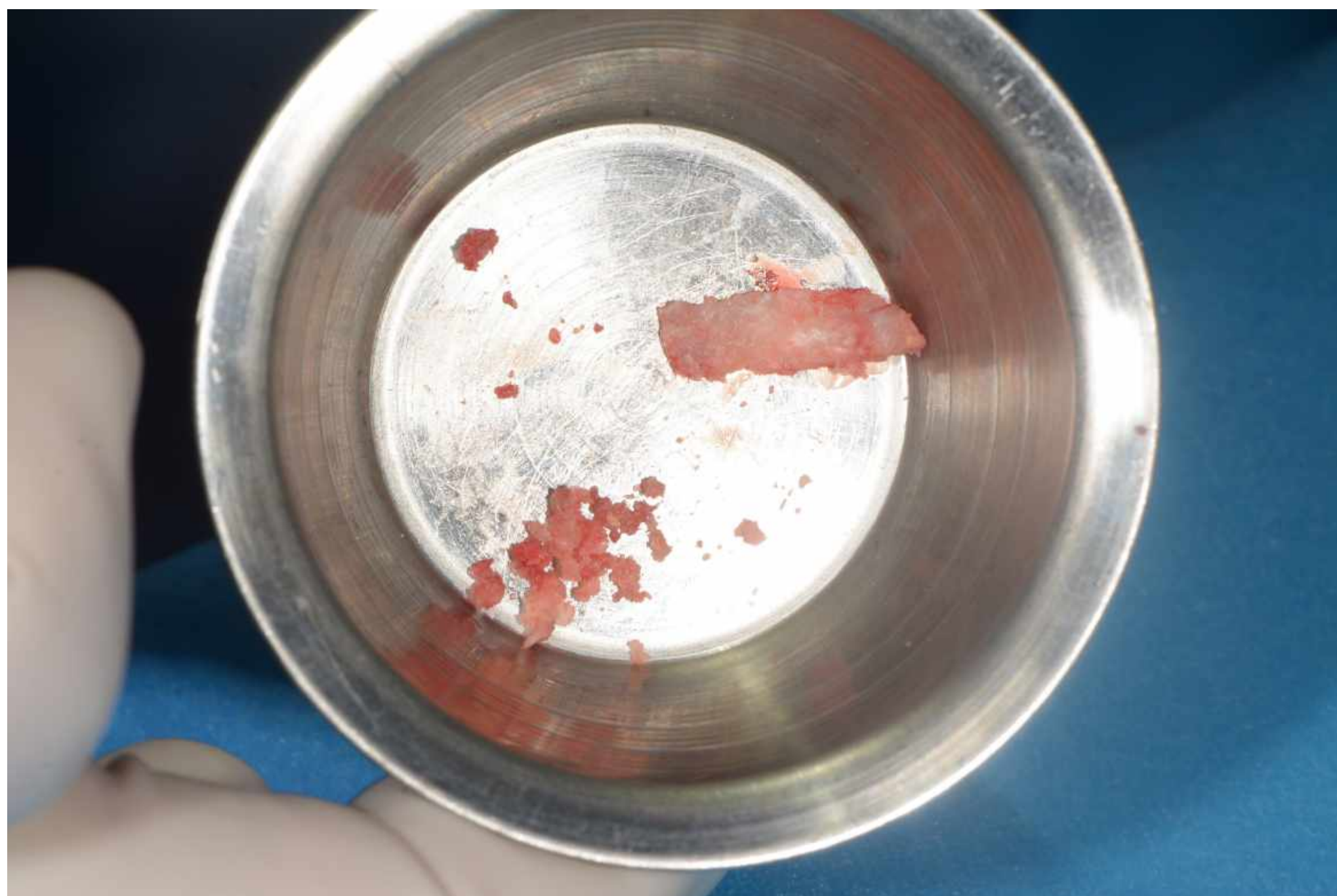Sinus Lift + cloison + Augmentation horizontale

Technique du volet remplacé

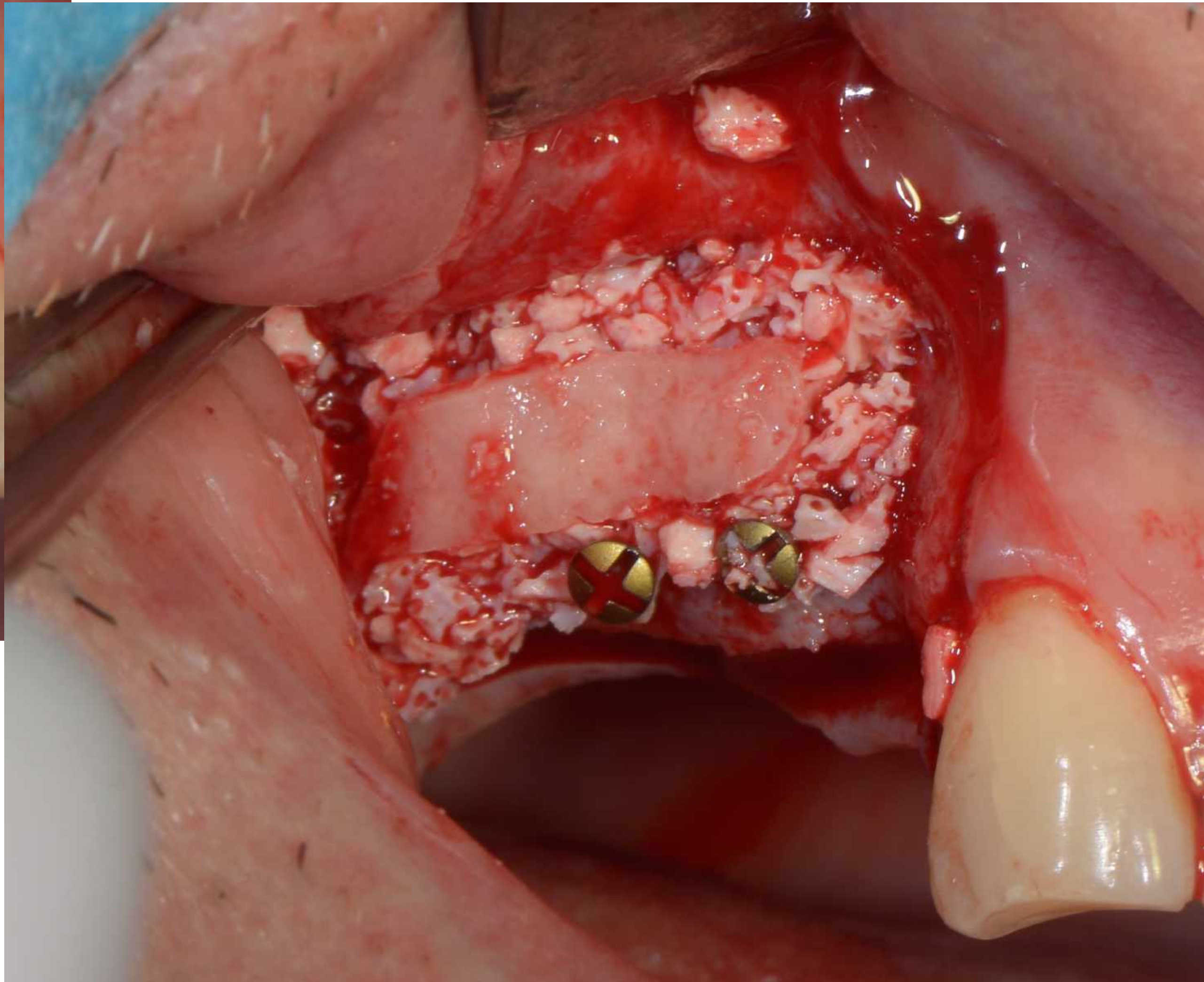
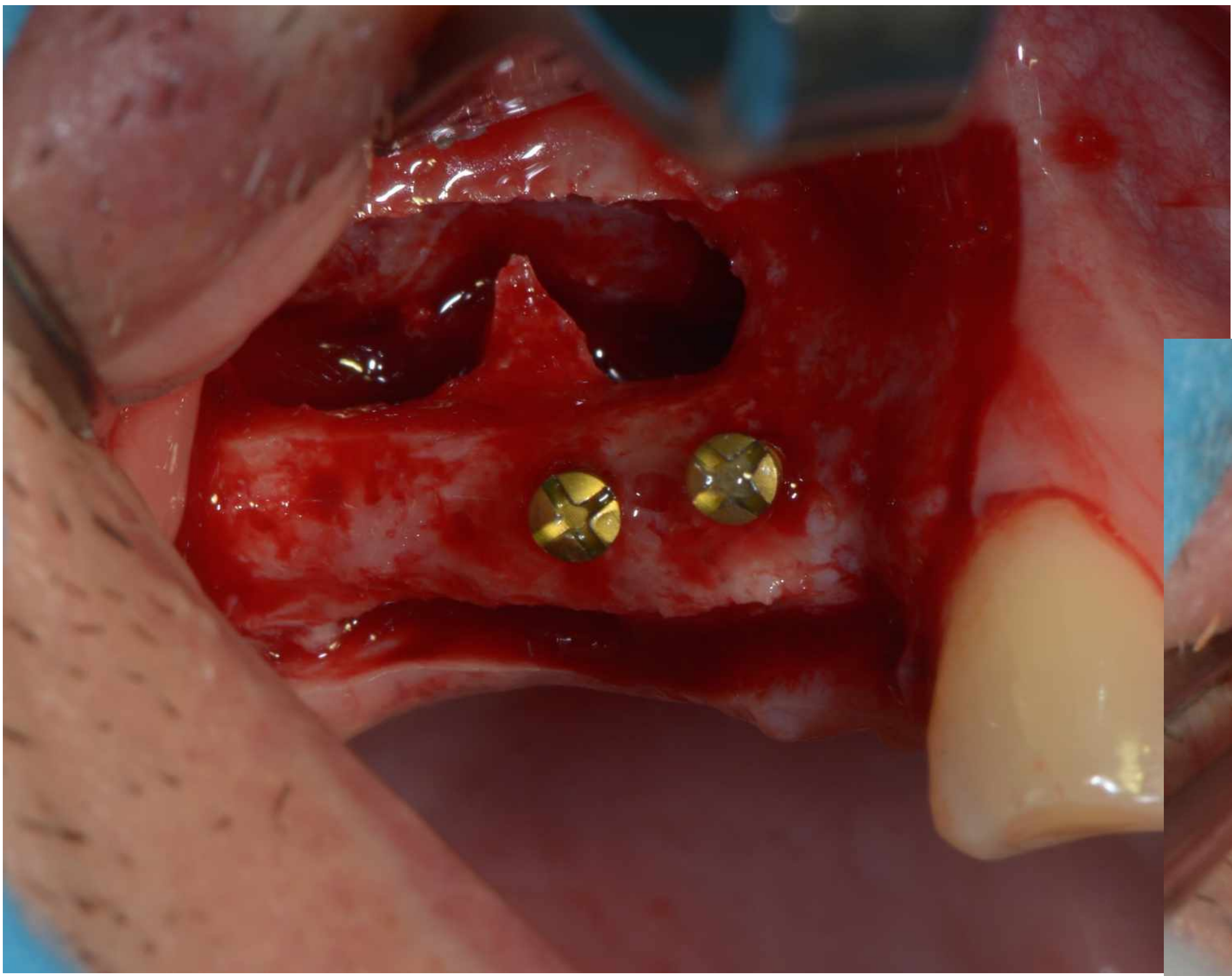


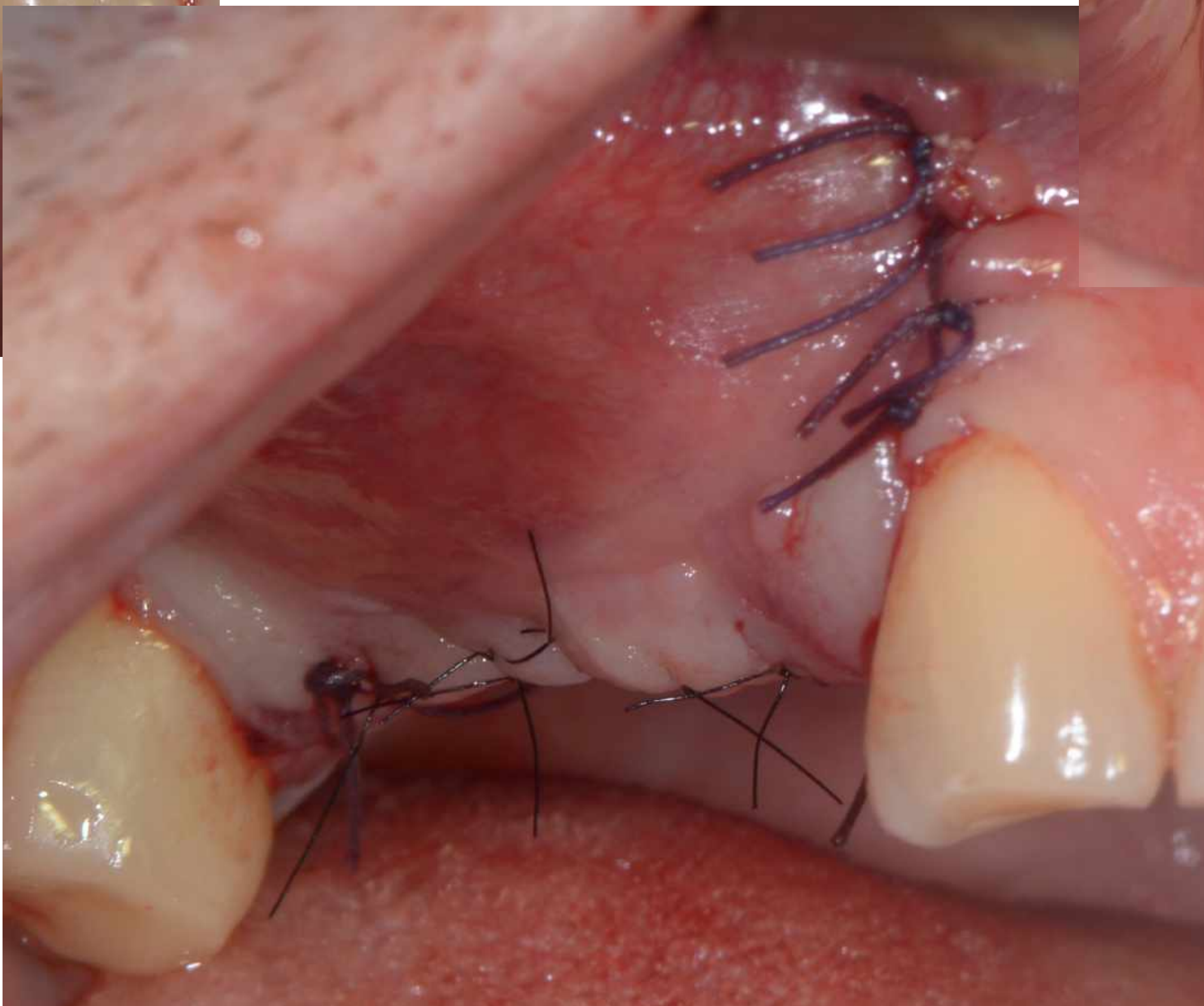
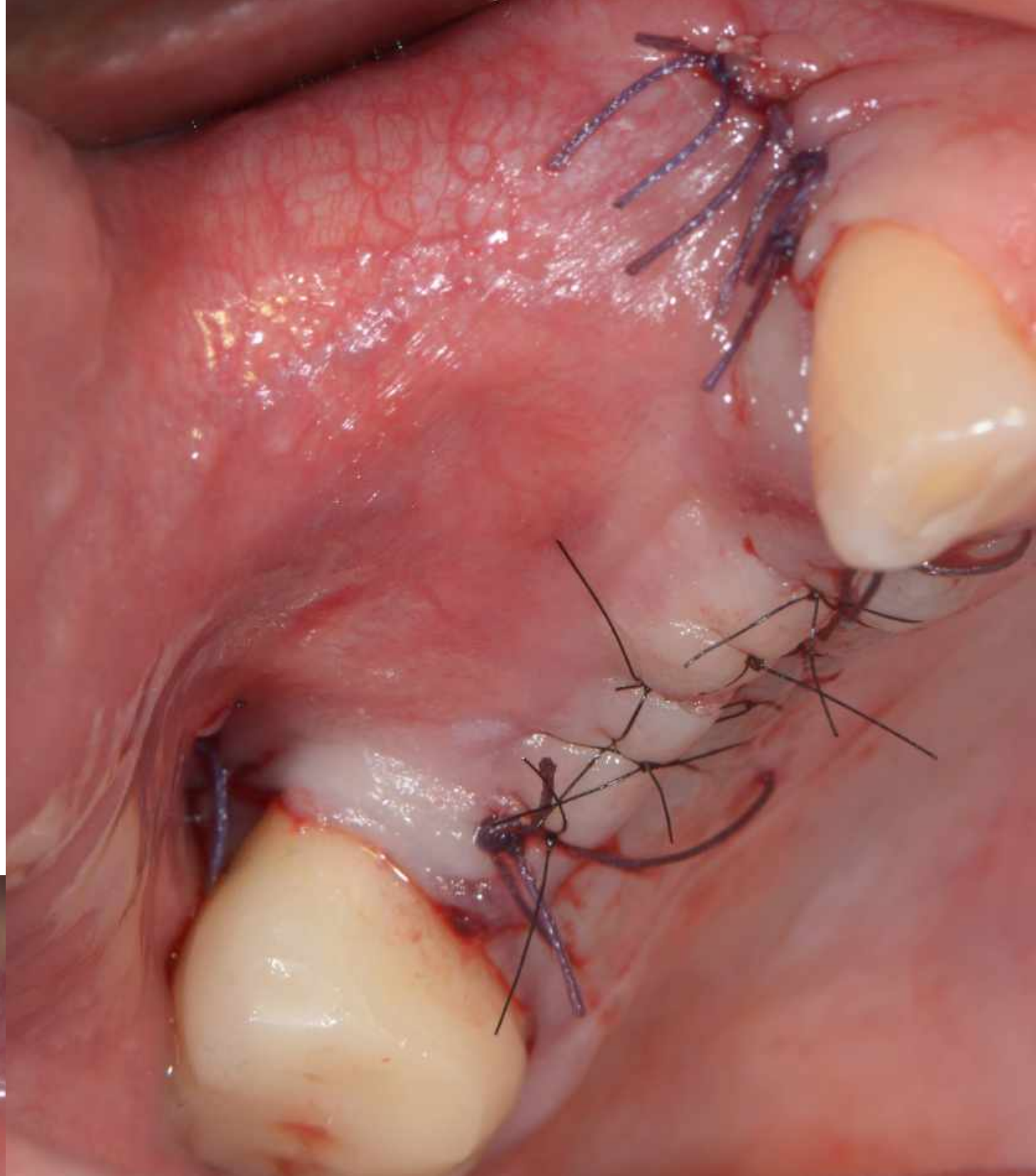
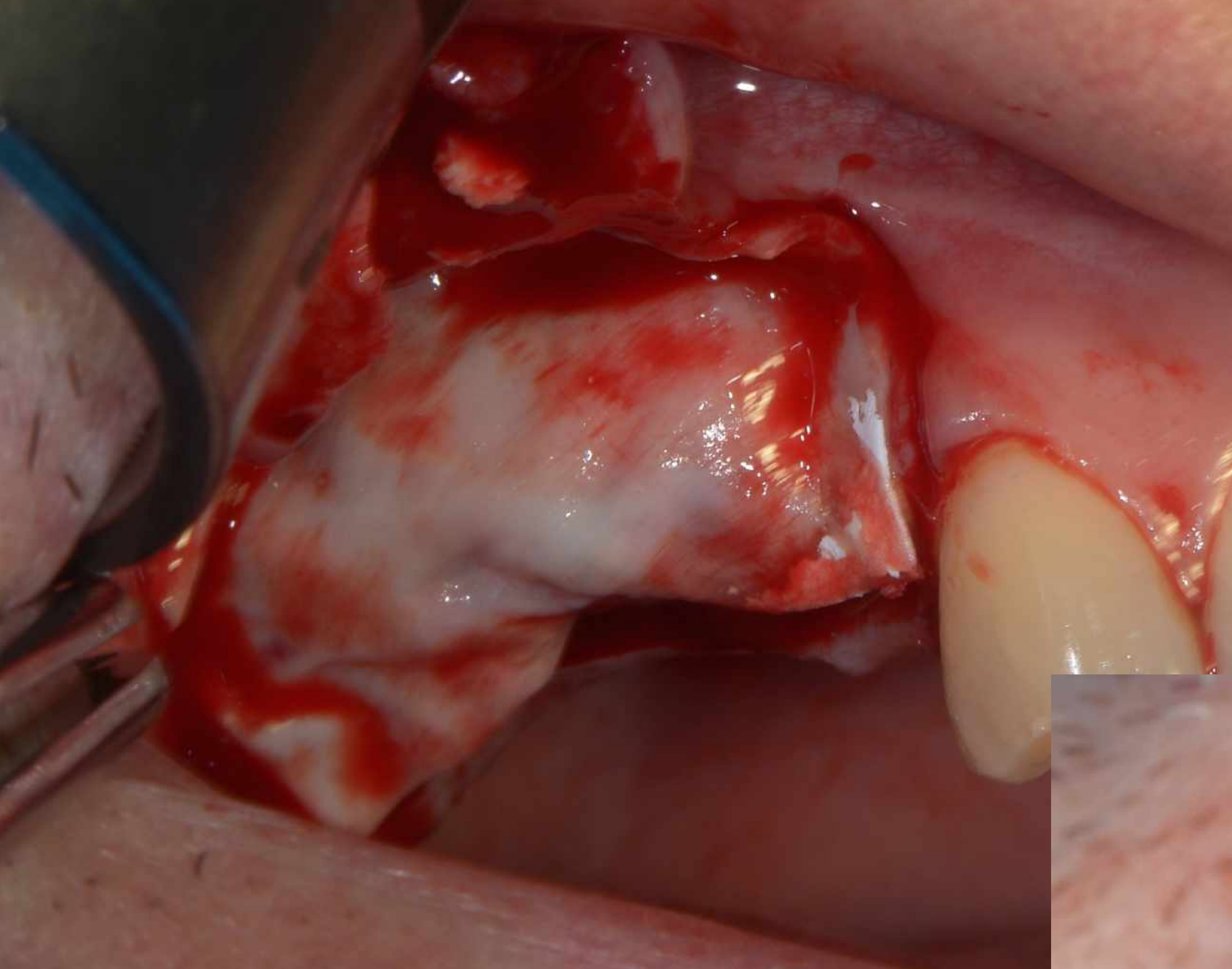


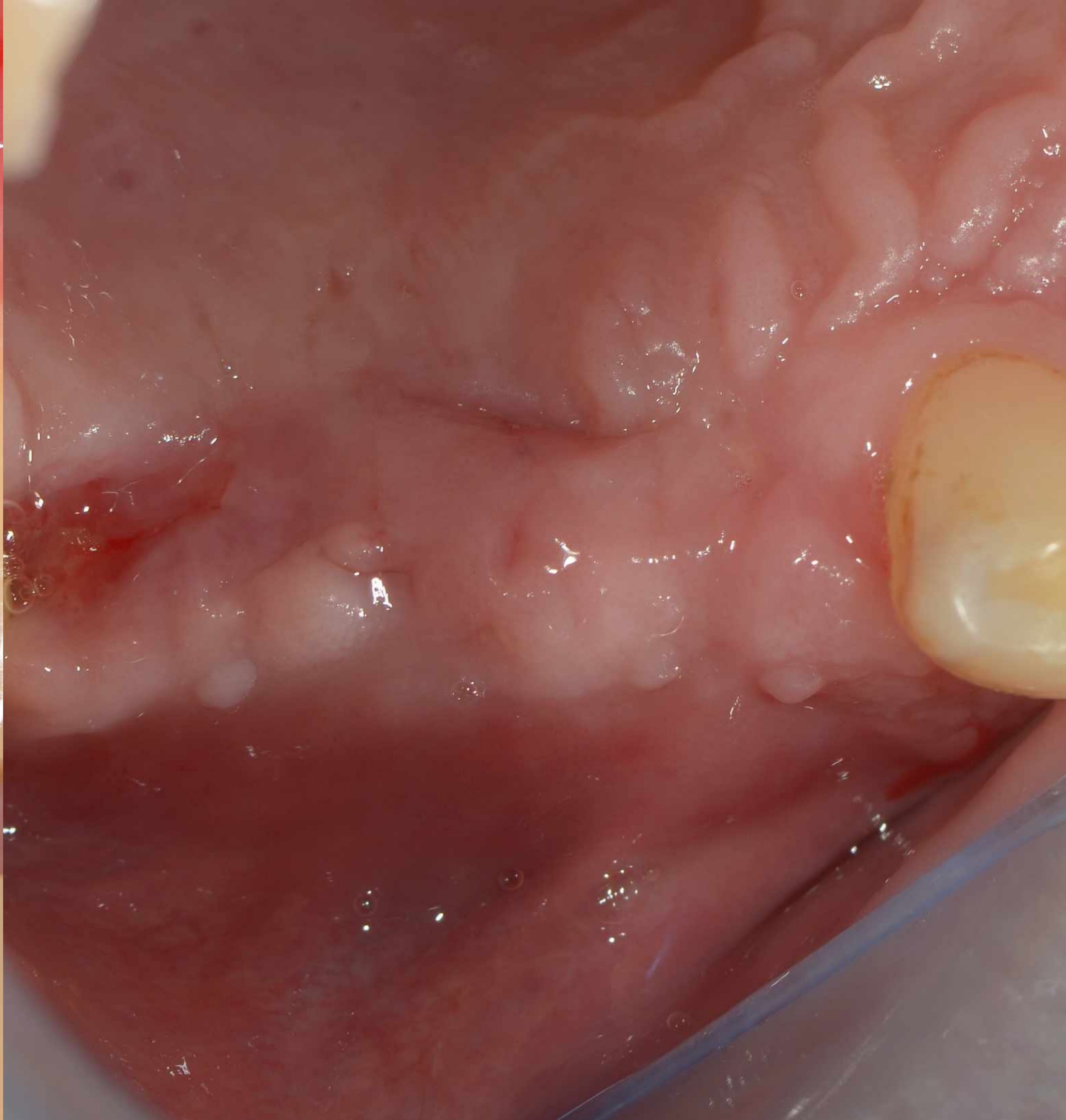
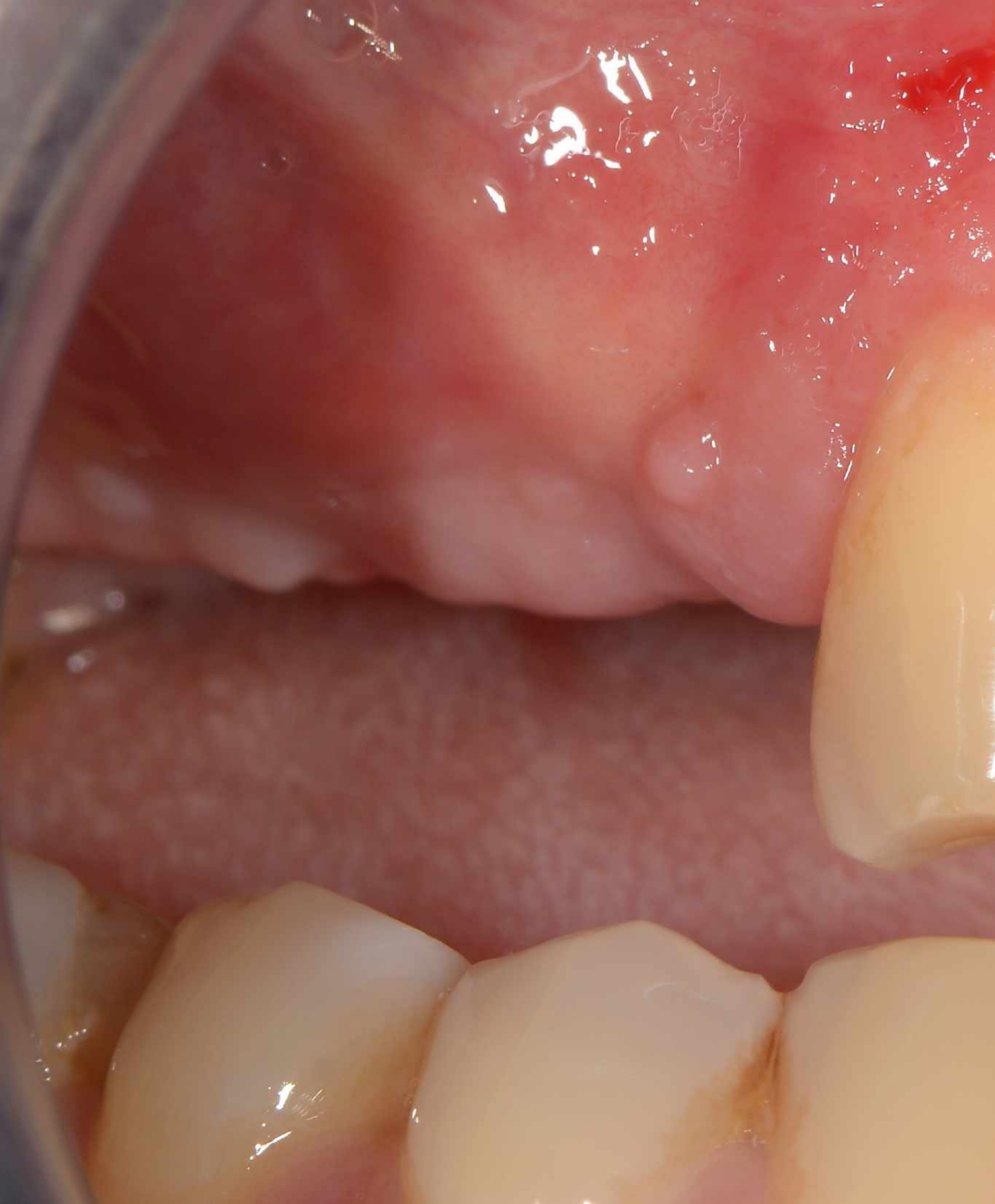Désépaissir le volet

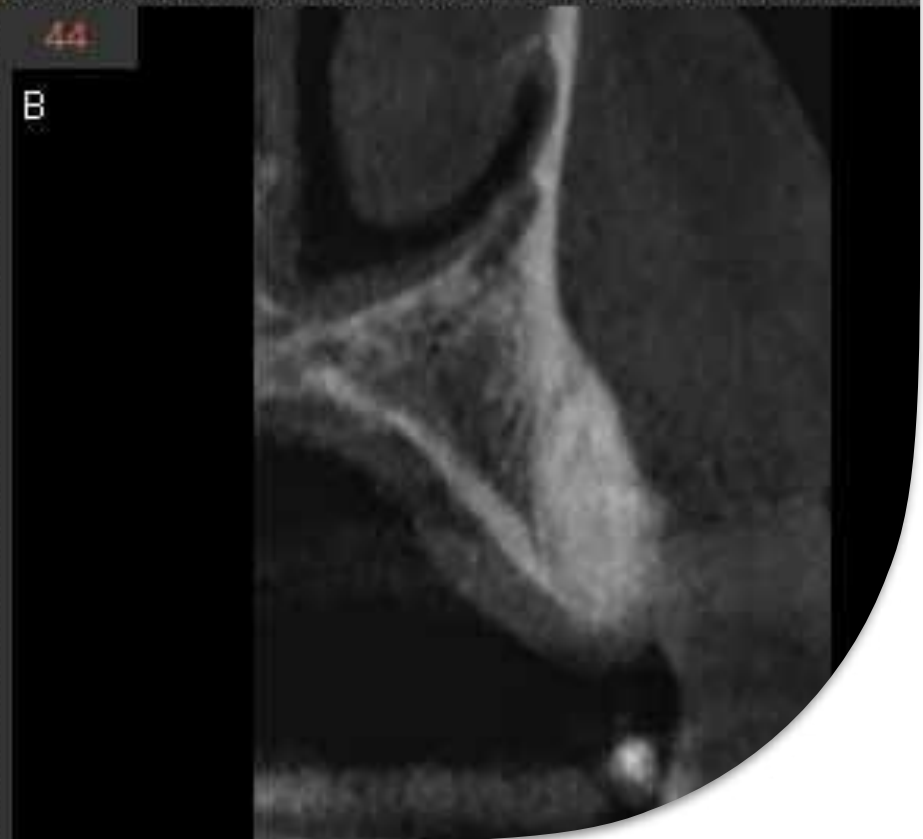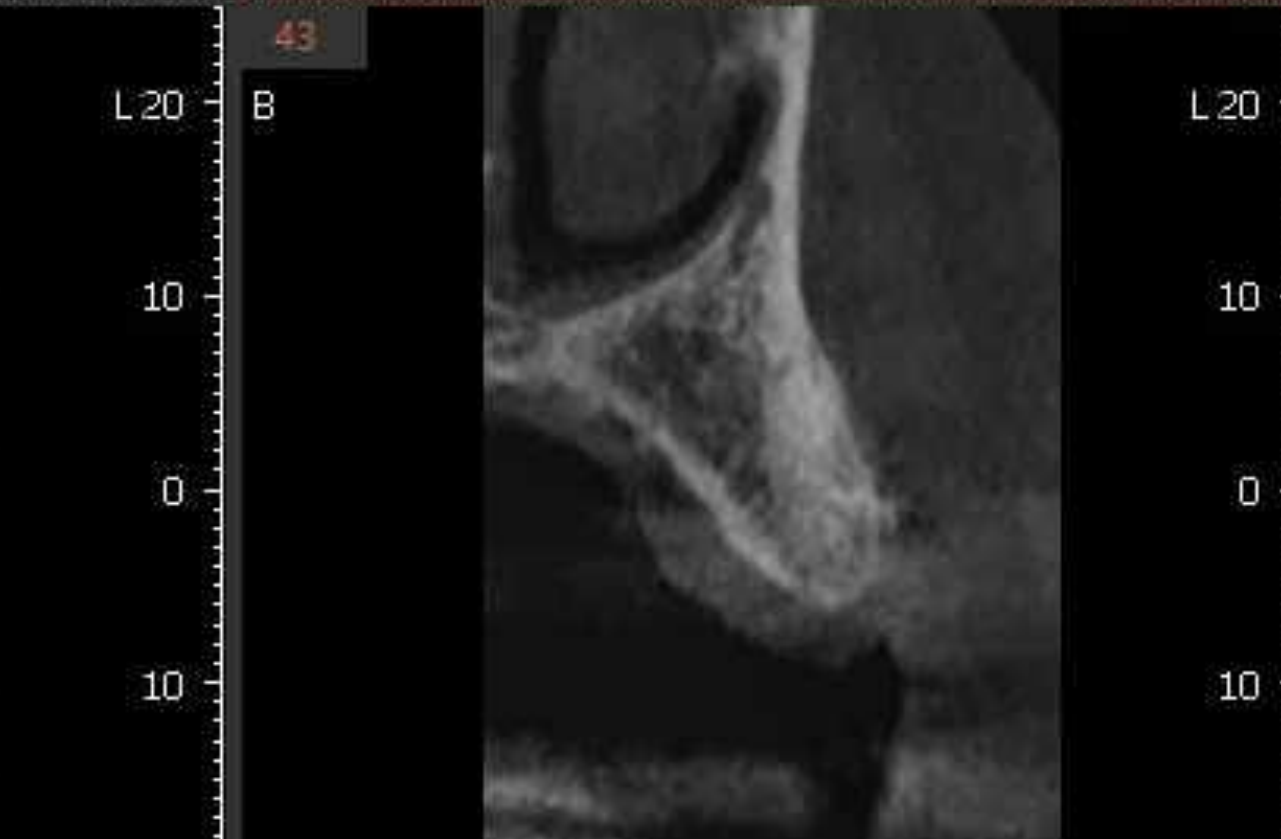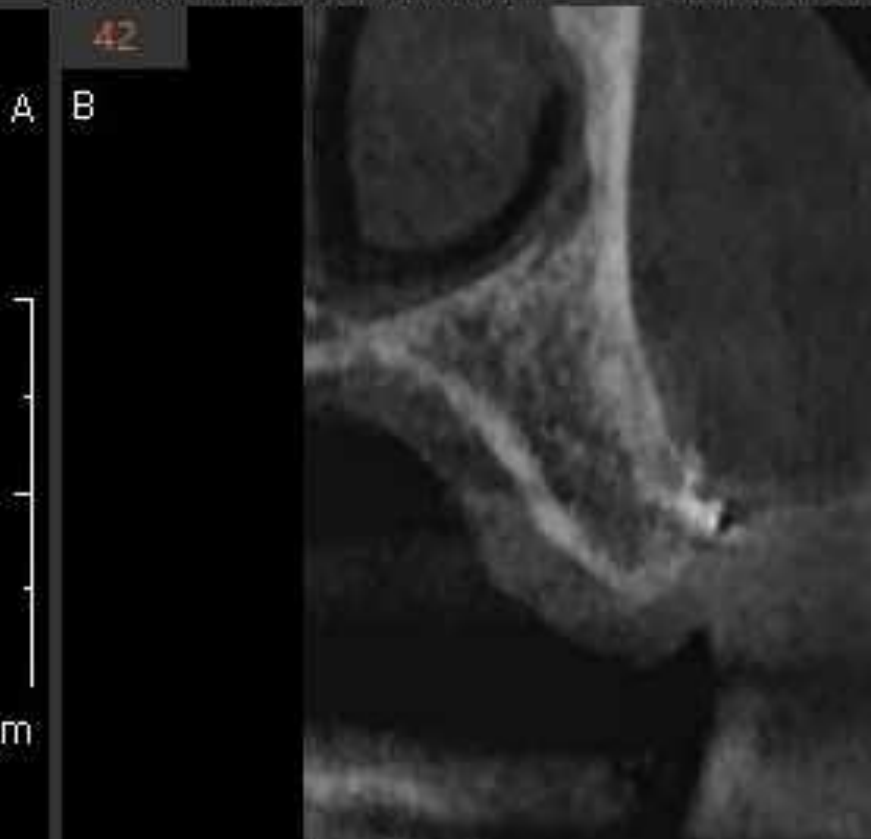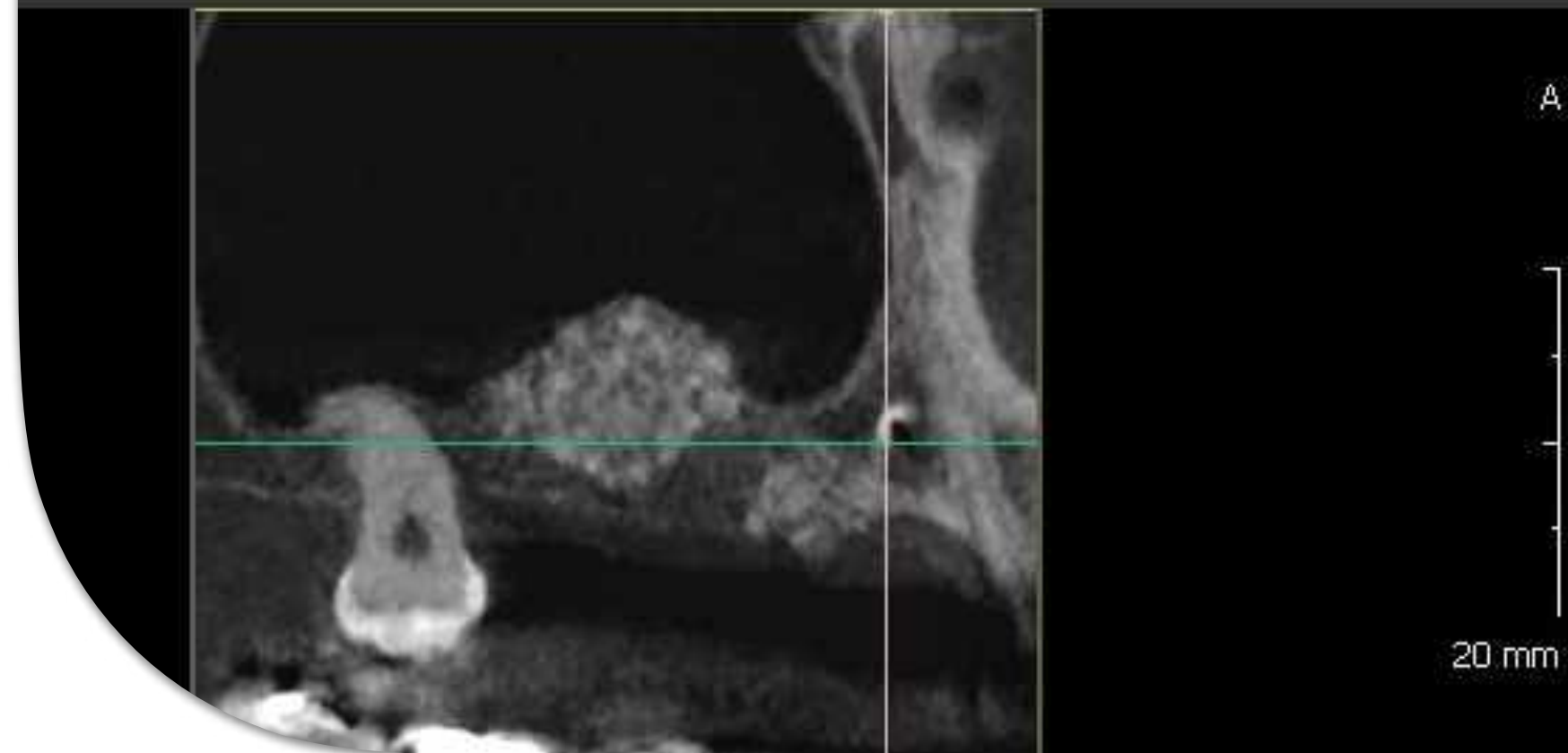
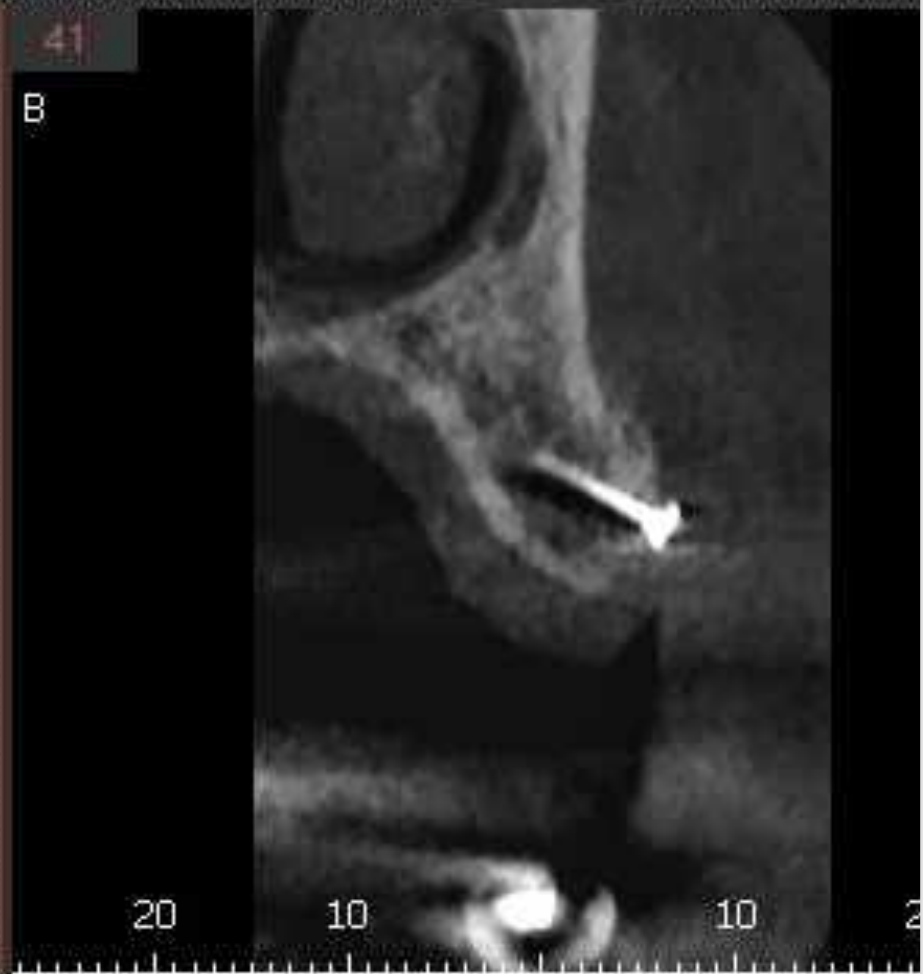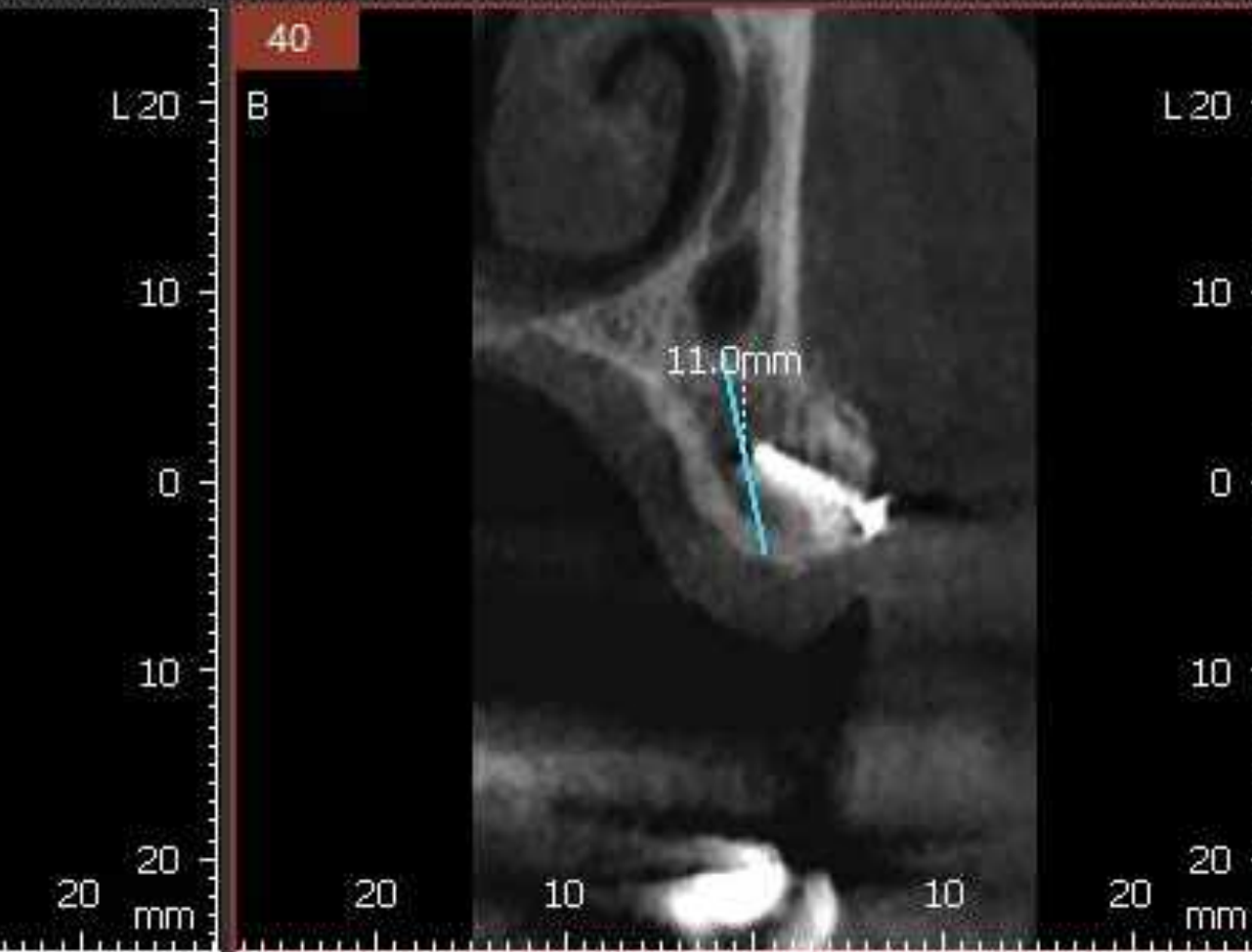
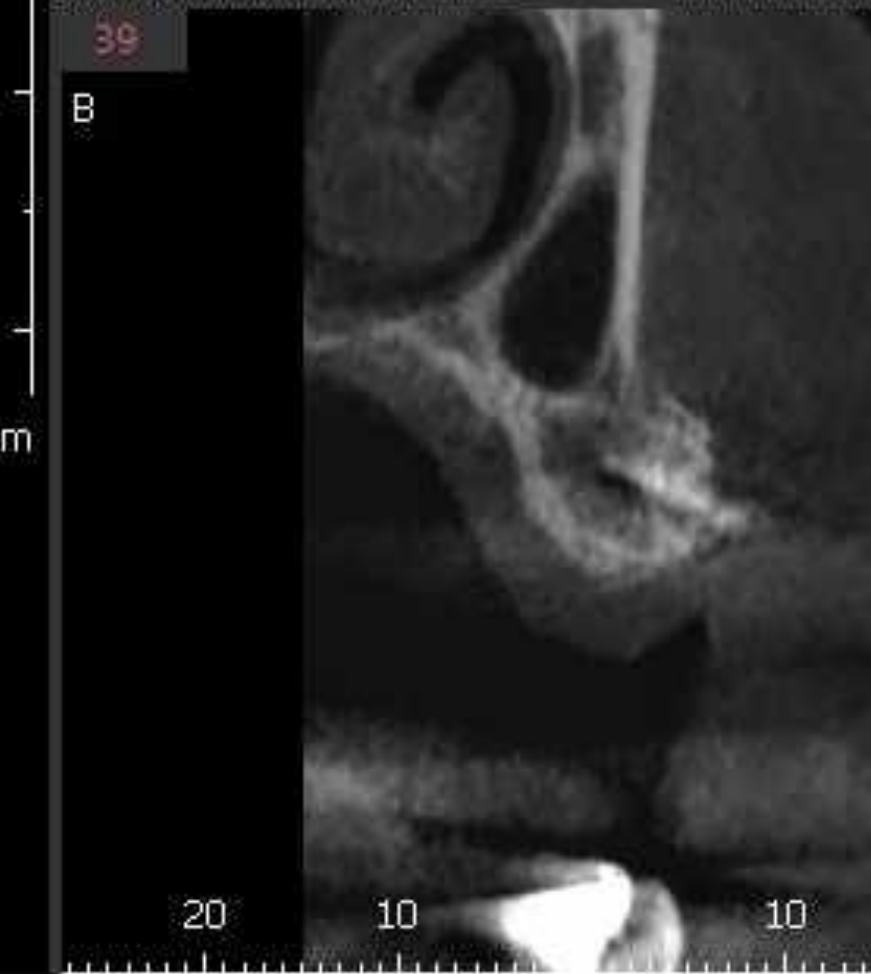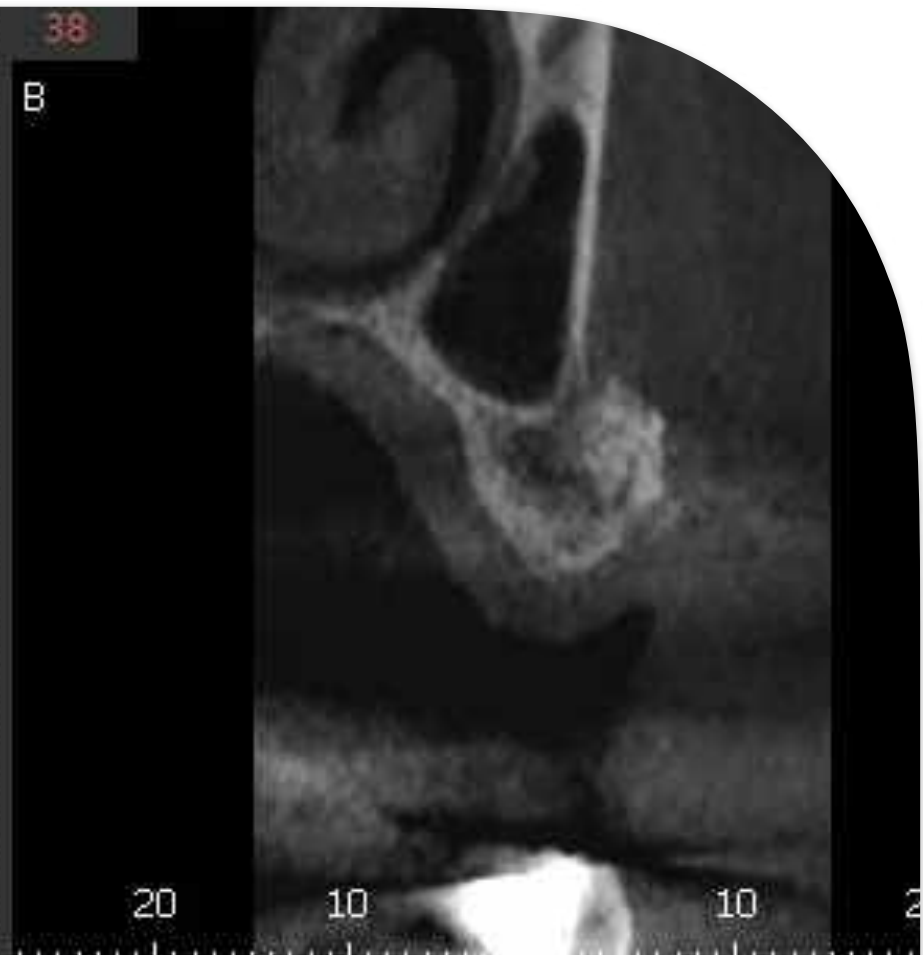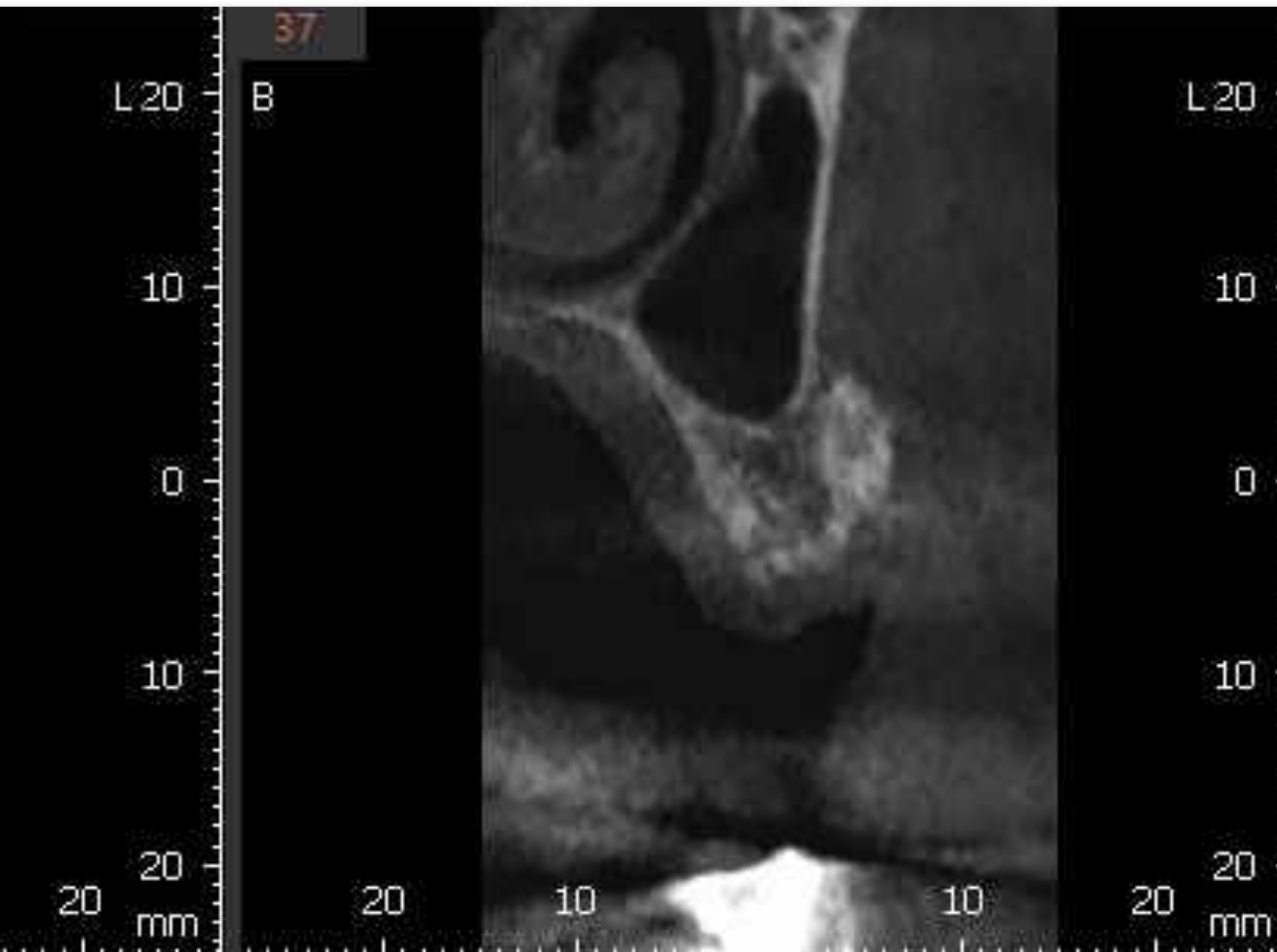
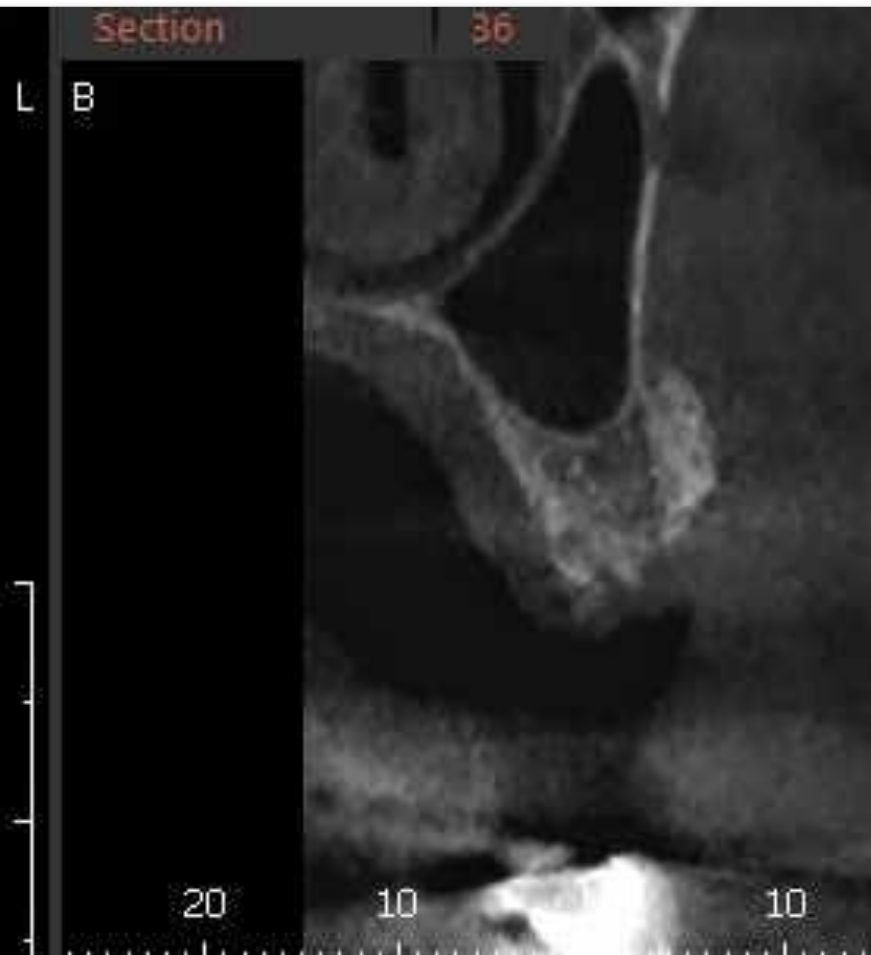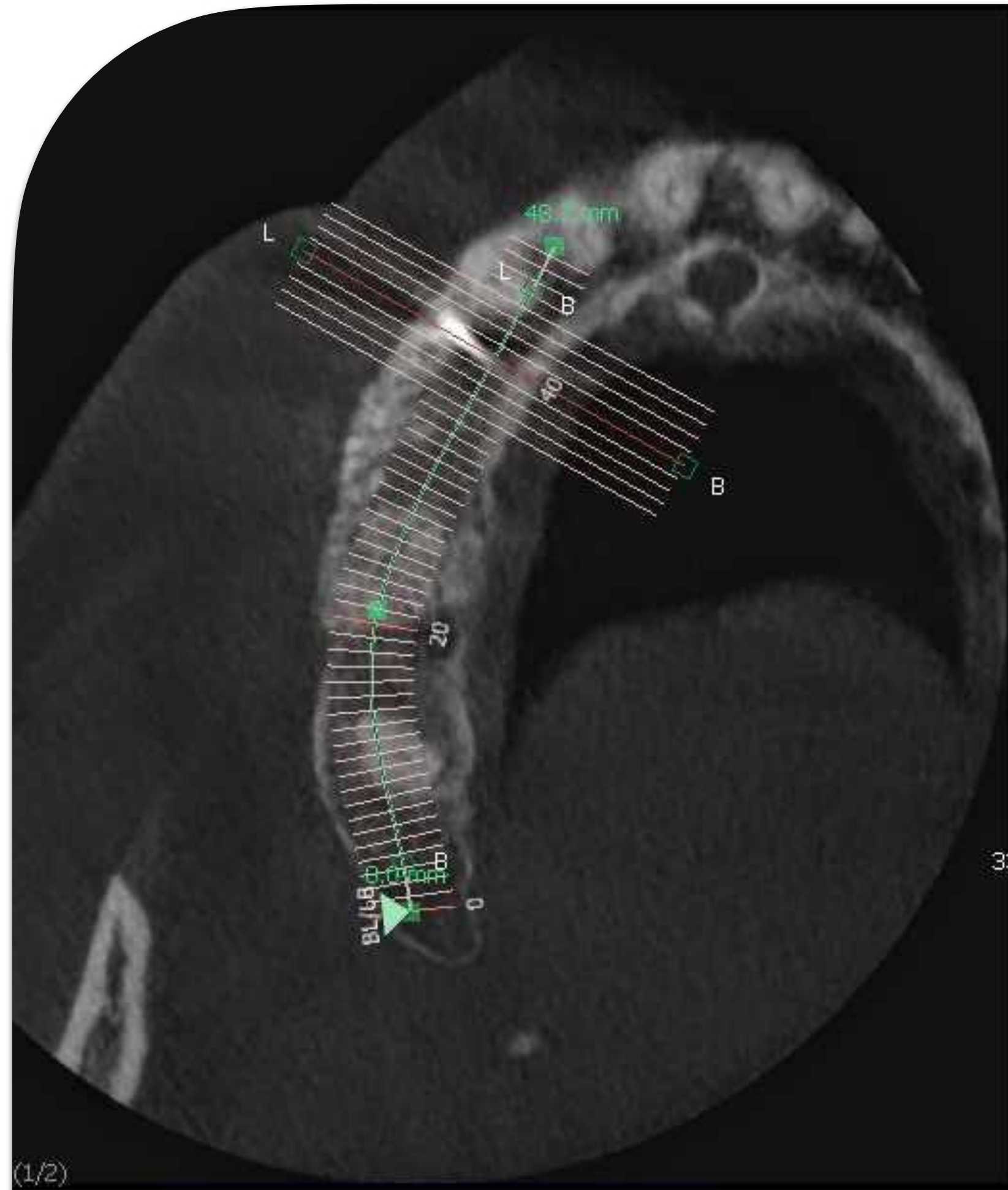


Augmentation Horizontale associée

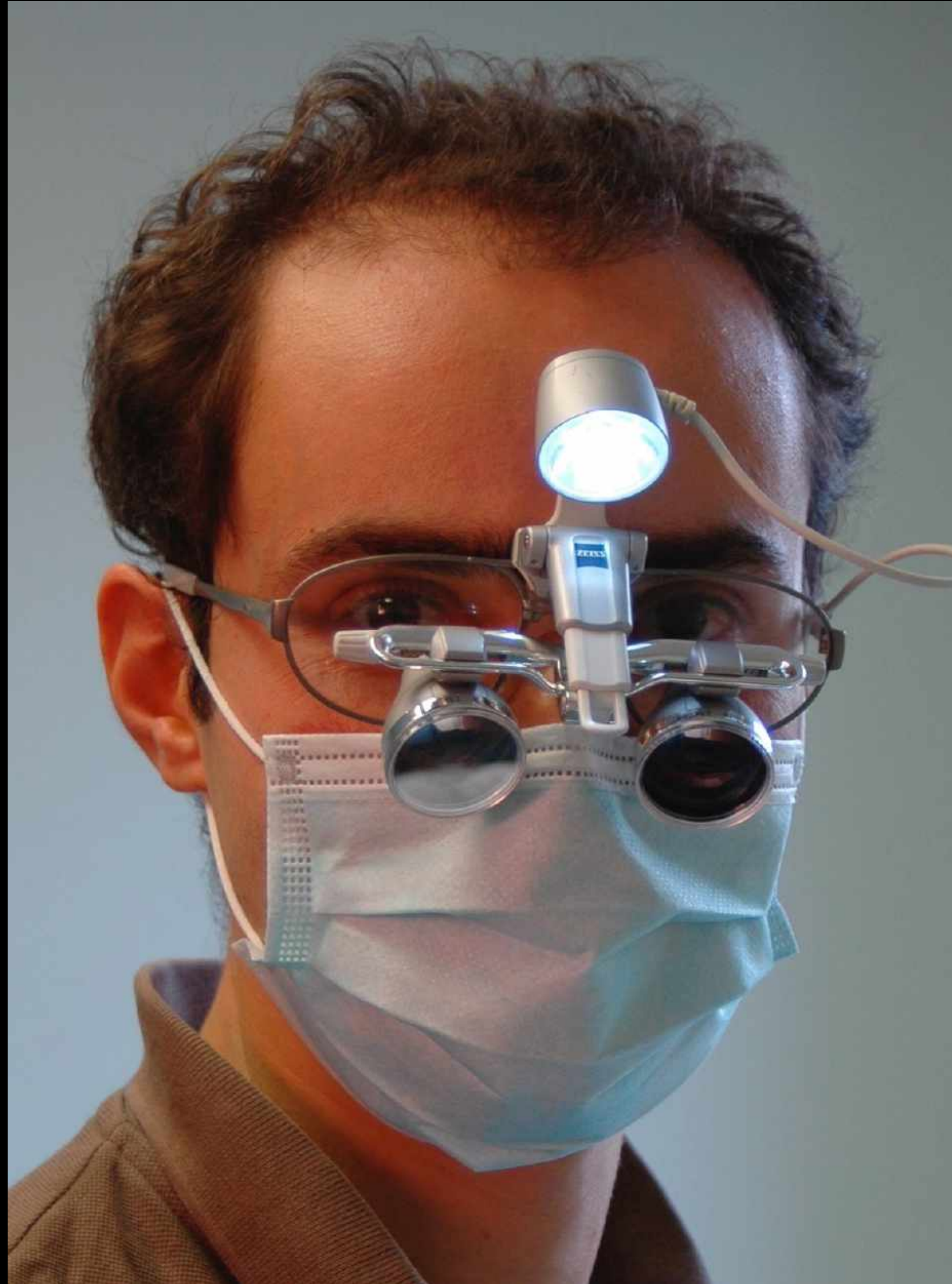







Aides optiques




Avantages :

Meilleure vision : grossissement + lumière
Meilleur sens tactile
Appréciation de l'incision osseuse (profondeur)

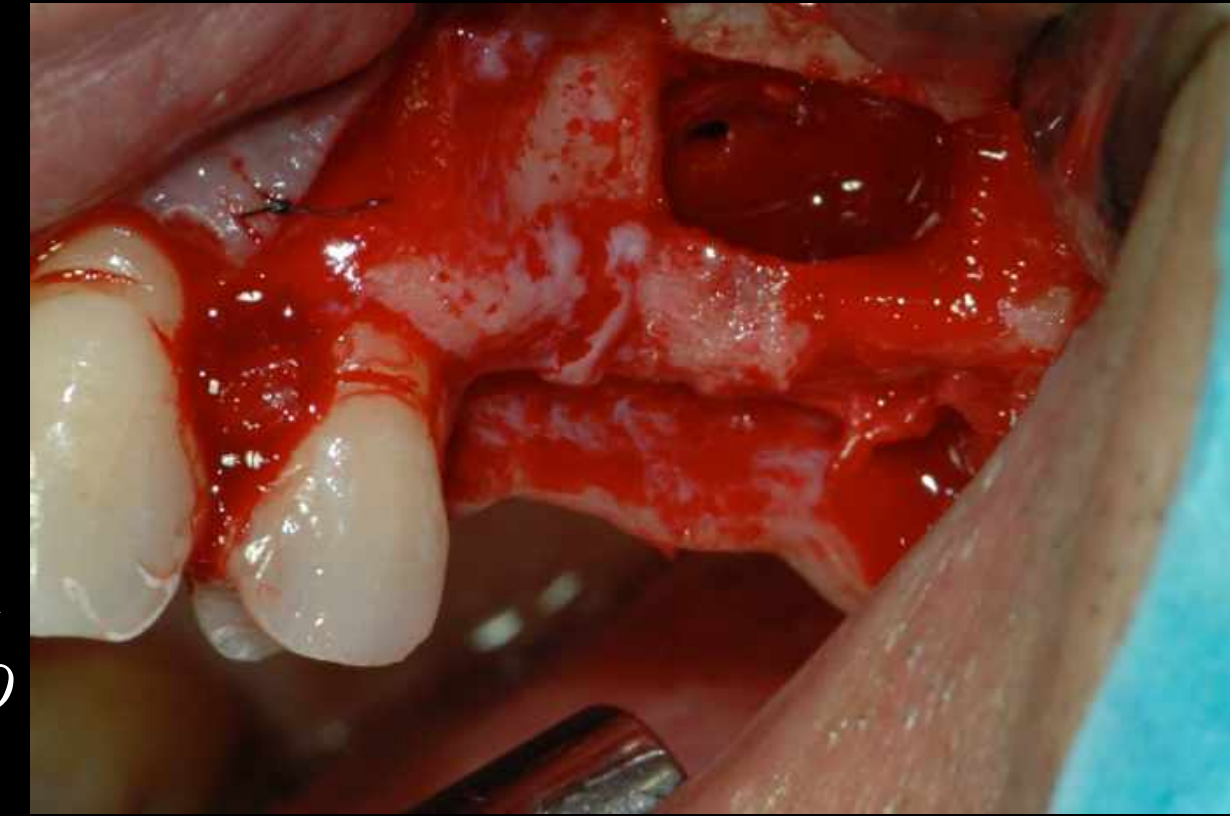
Inconvénients :

Positionnement du patient
Vitesse d'exécution : geste lent
Suture : profondeur de champ
Nécessite instruments micro-chir



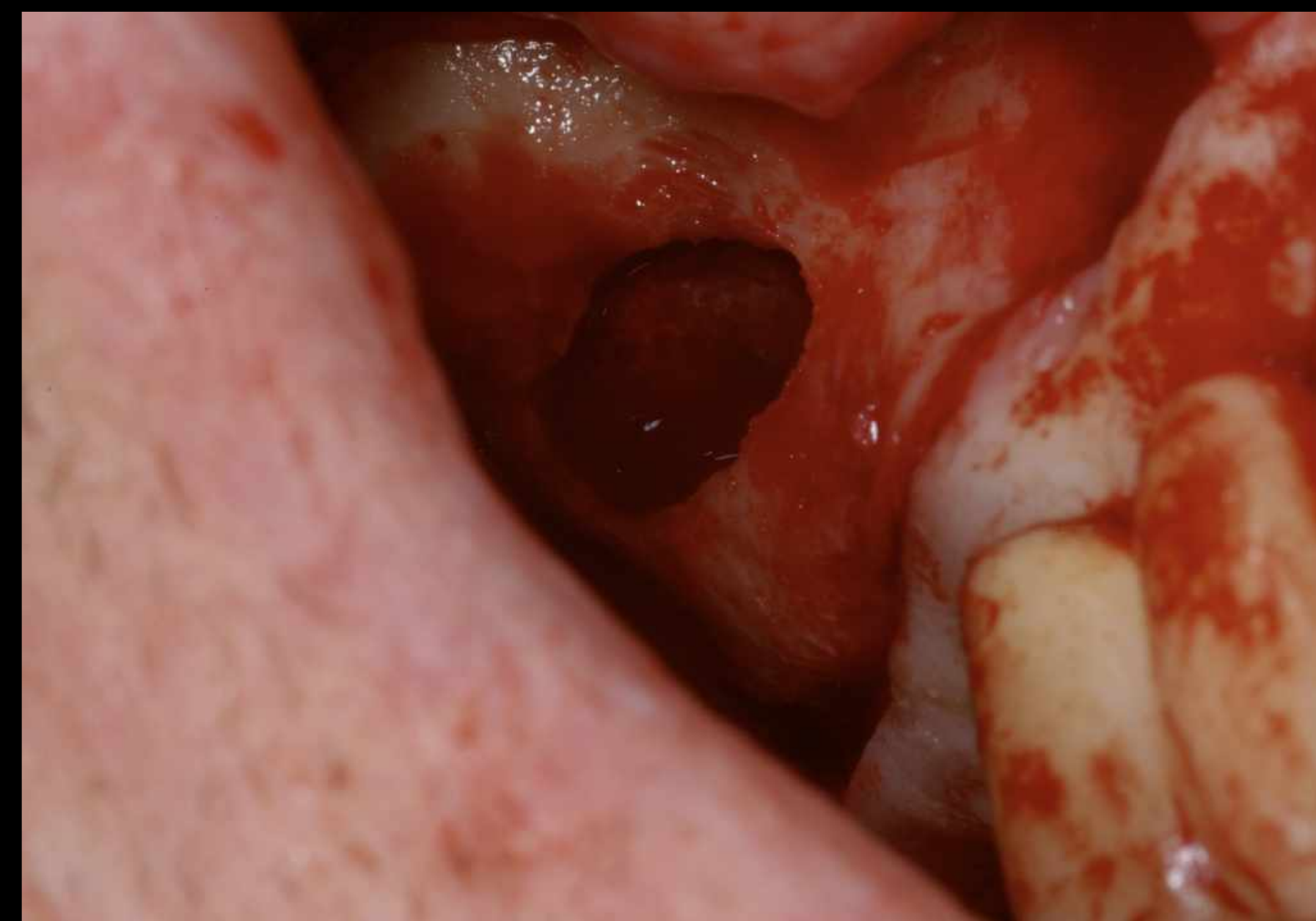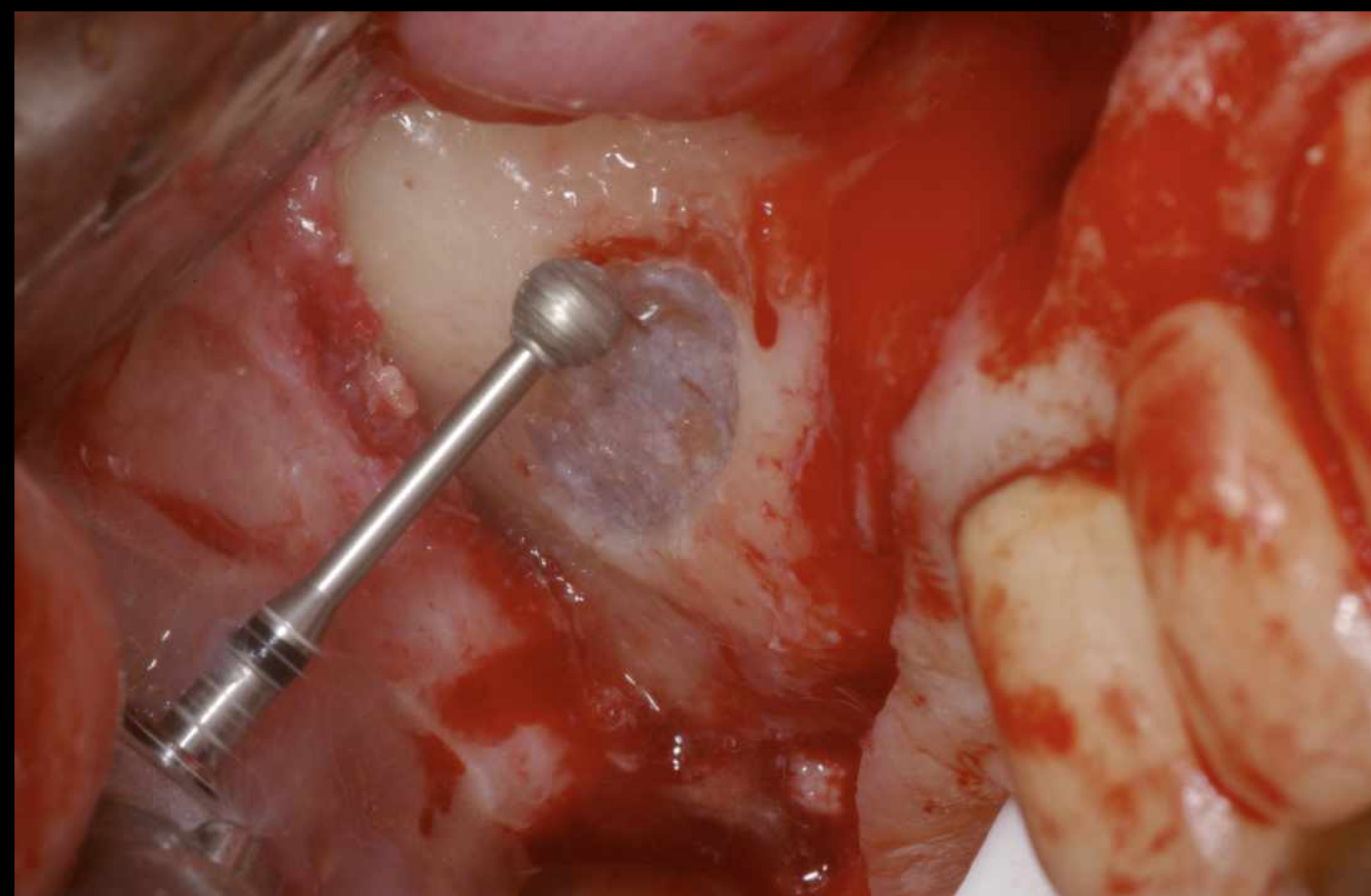
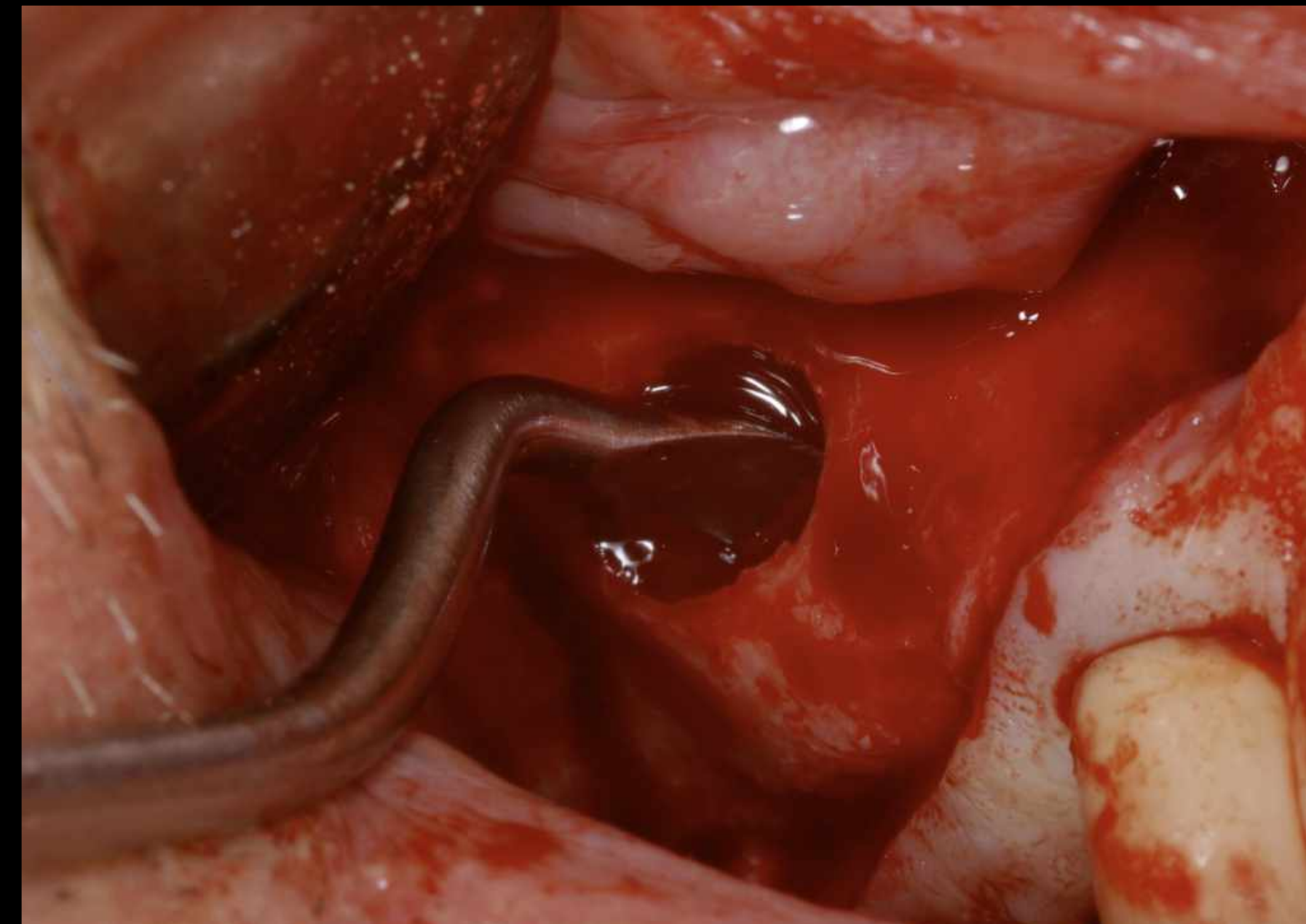
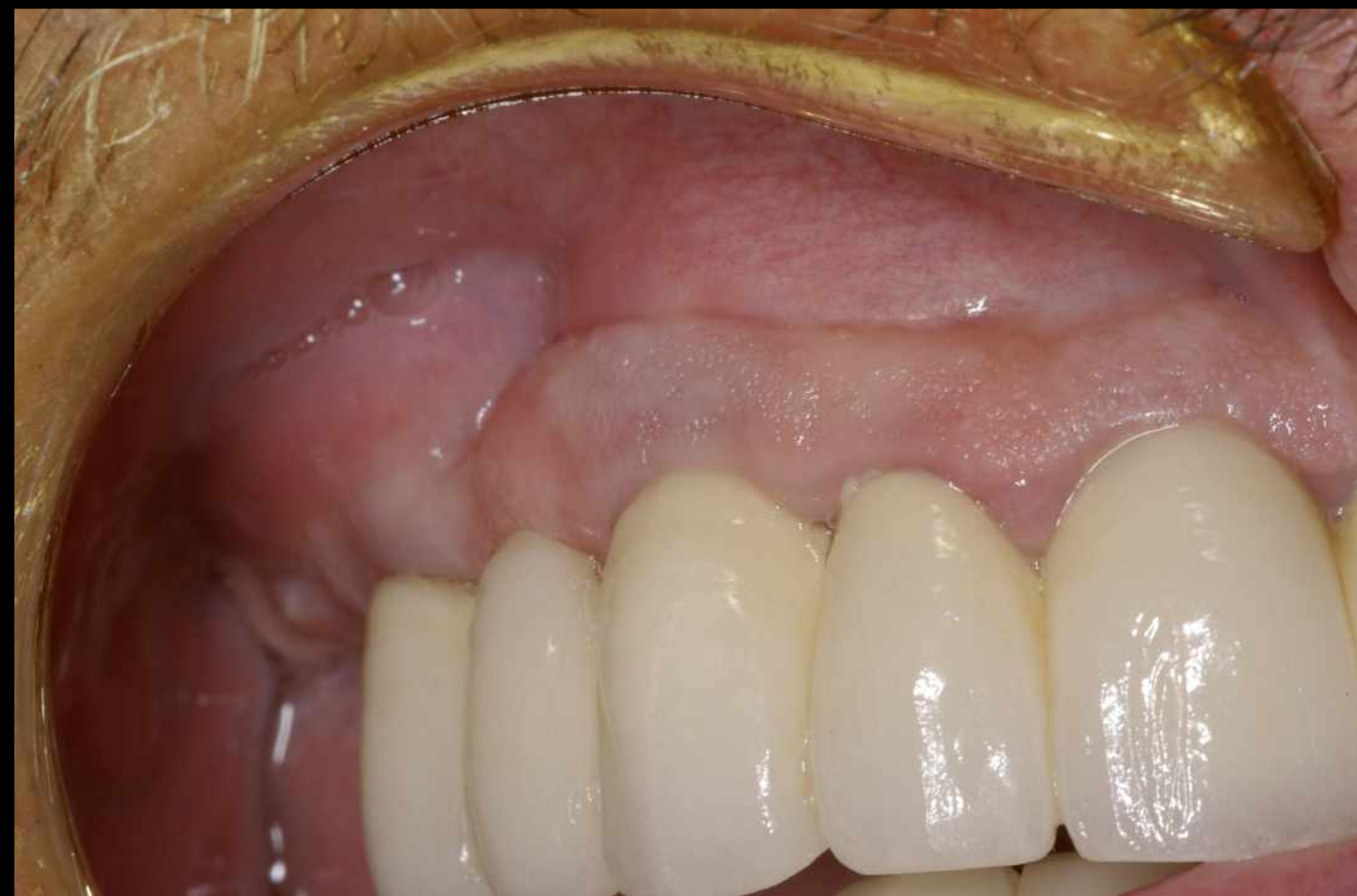Complications

- Déchirures de la membrane : 7 à 44 %
 - < 2 mm pas de traitement
 - 2 à 10 mm : membrane collagène, prf
 - > 10 mm différer la greffe (granules)
 - Taux de succès similaire / *Ardekian et coll*
 - Facteur à risques : ancienne chirurgie sinus, hauteur de l'os résiduel
- Sinusite
- Infection
- Fumeurs **NECROSE DU LAMBEAU**
- Insuffisance de comblement



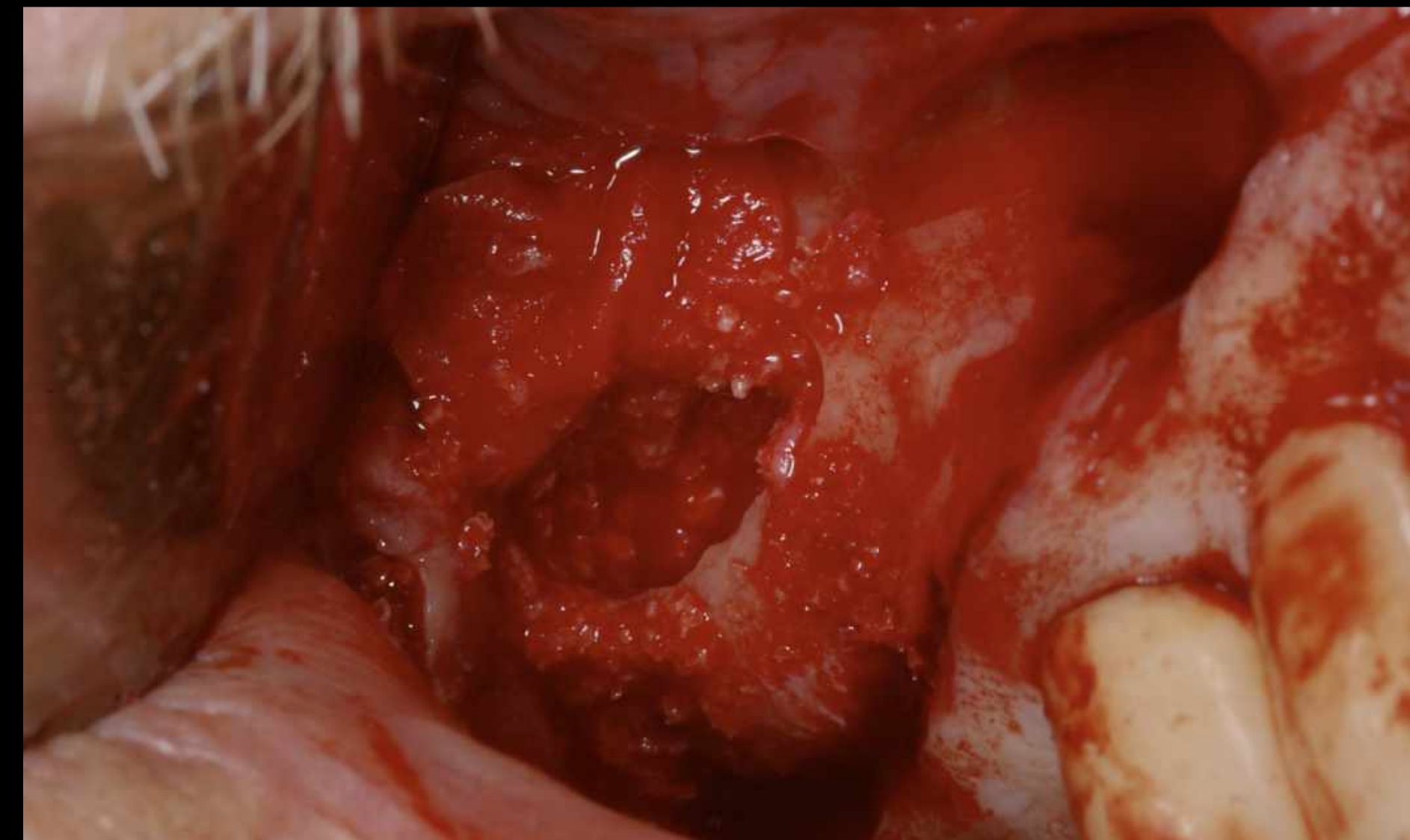
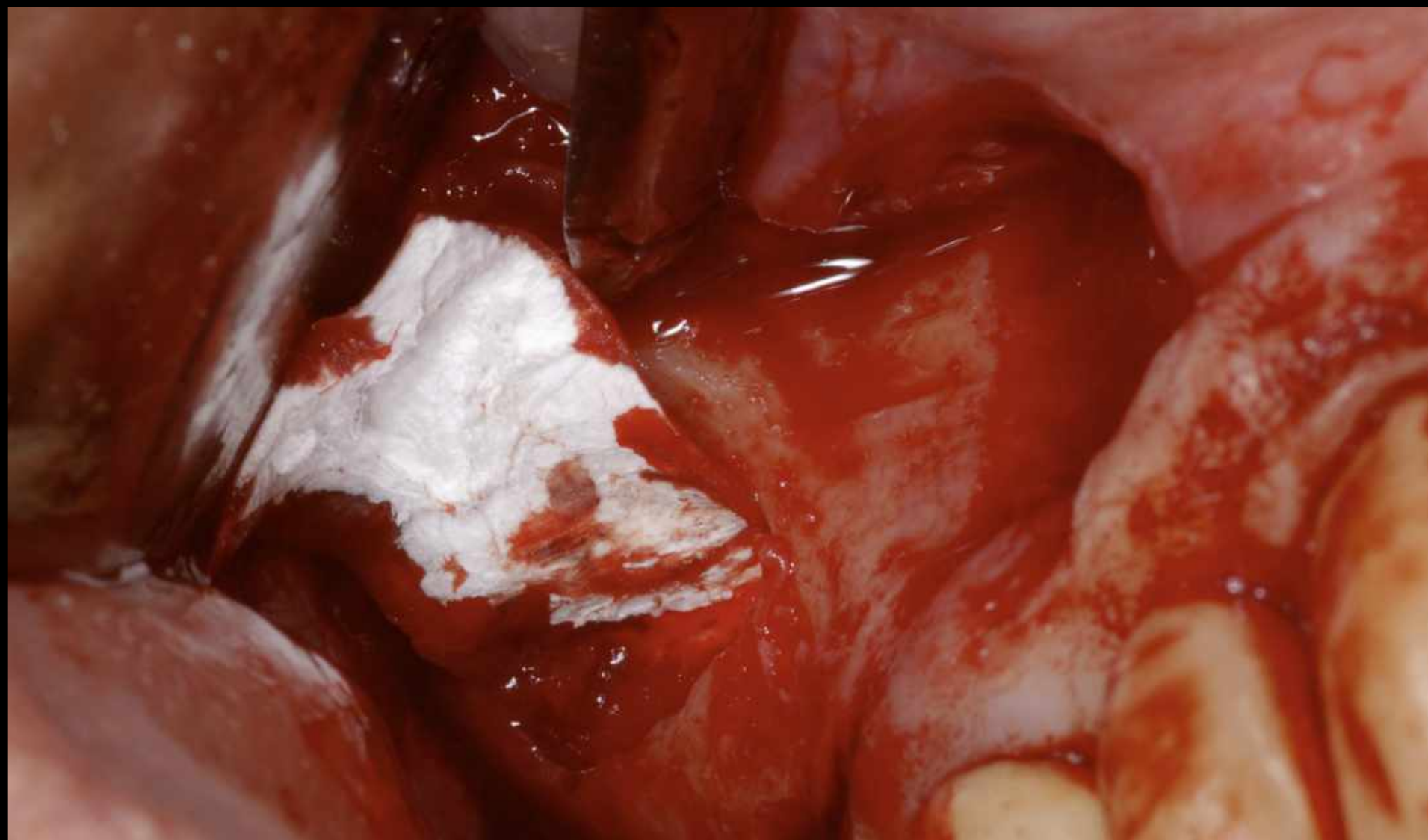
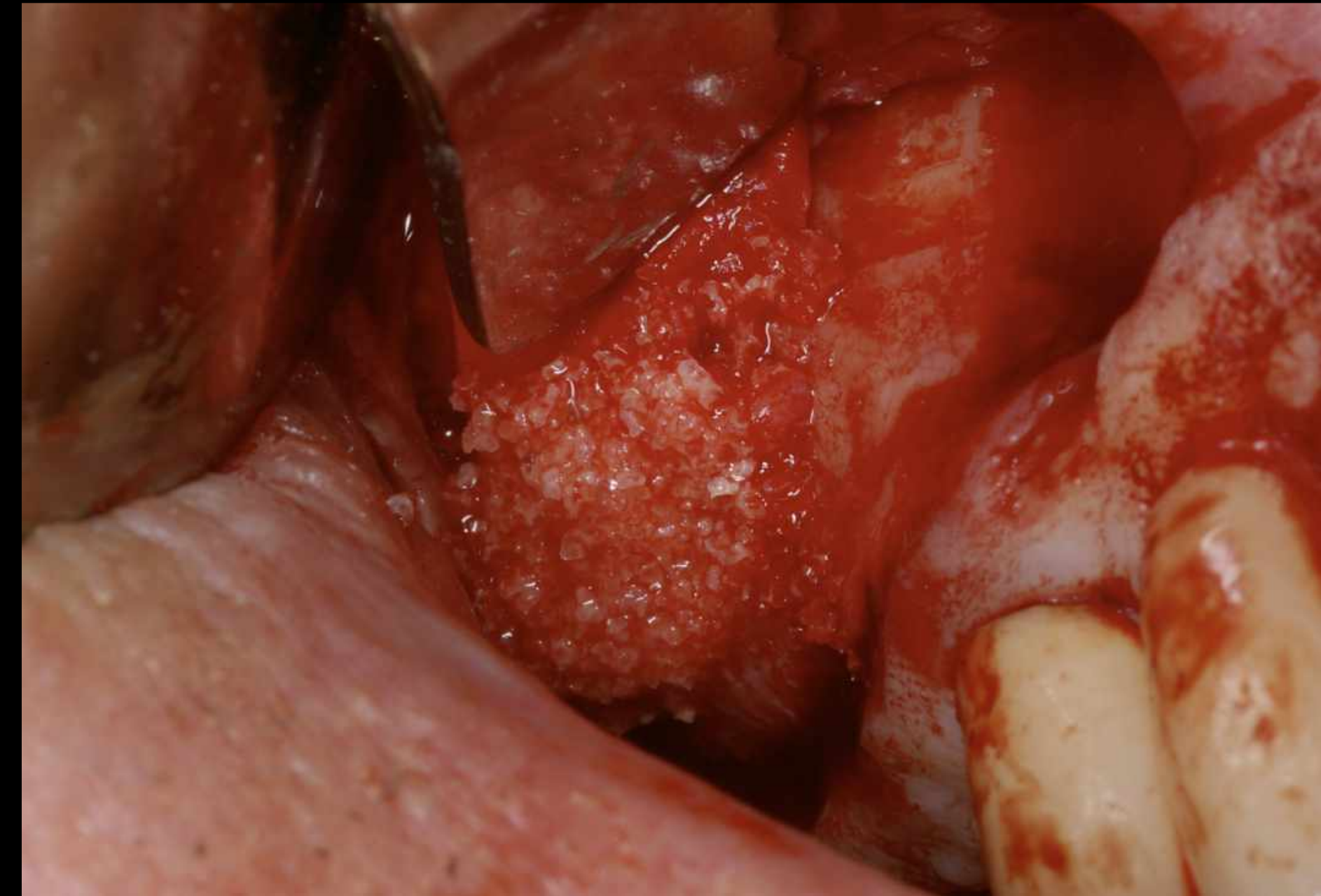Volet Latéral

Complications



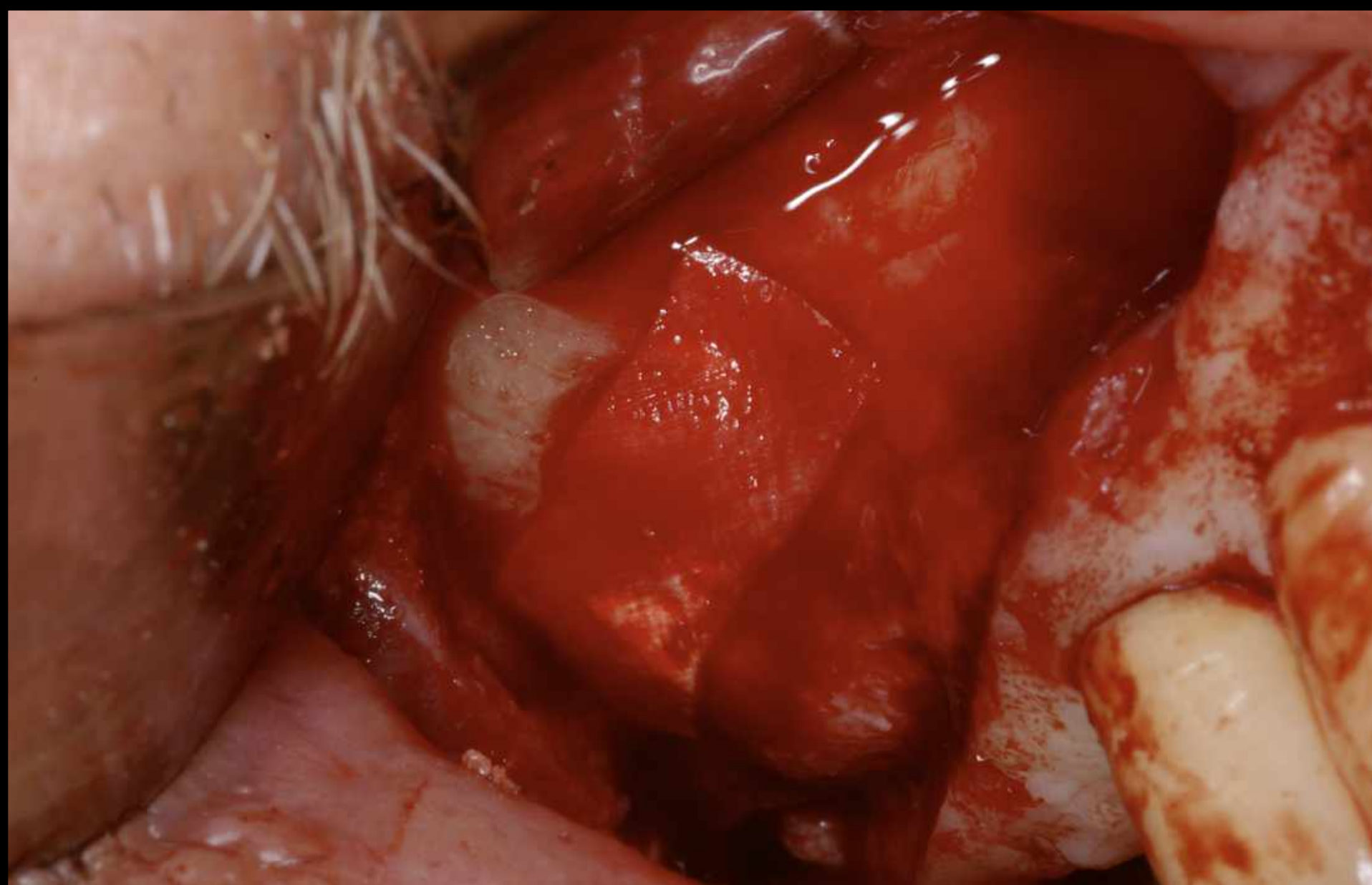
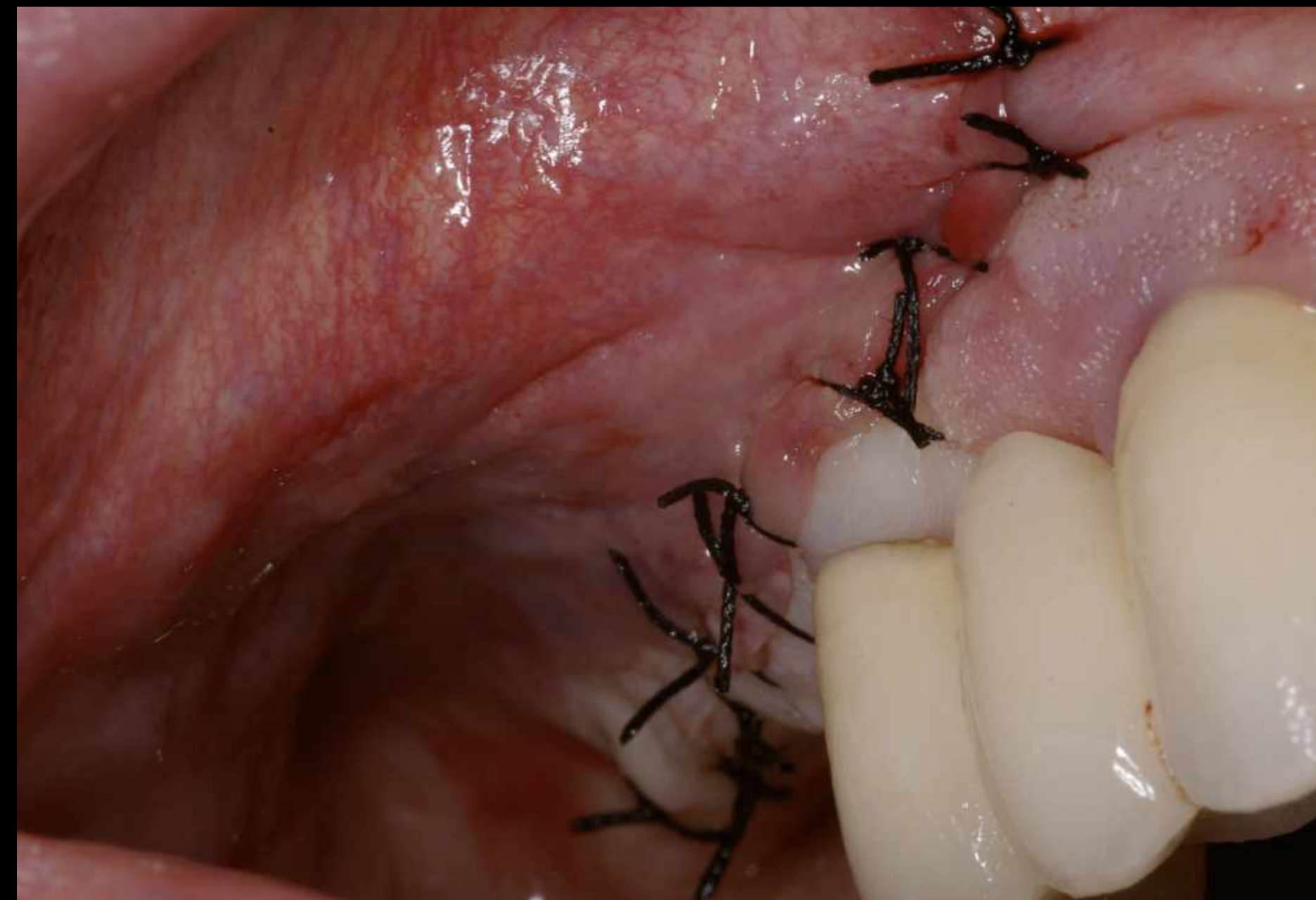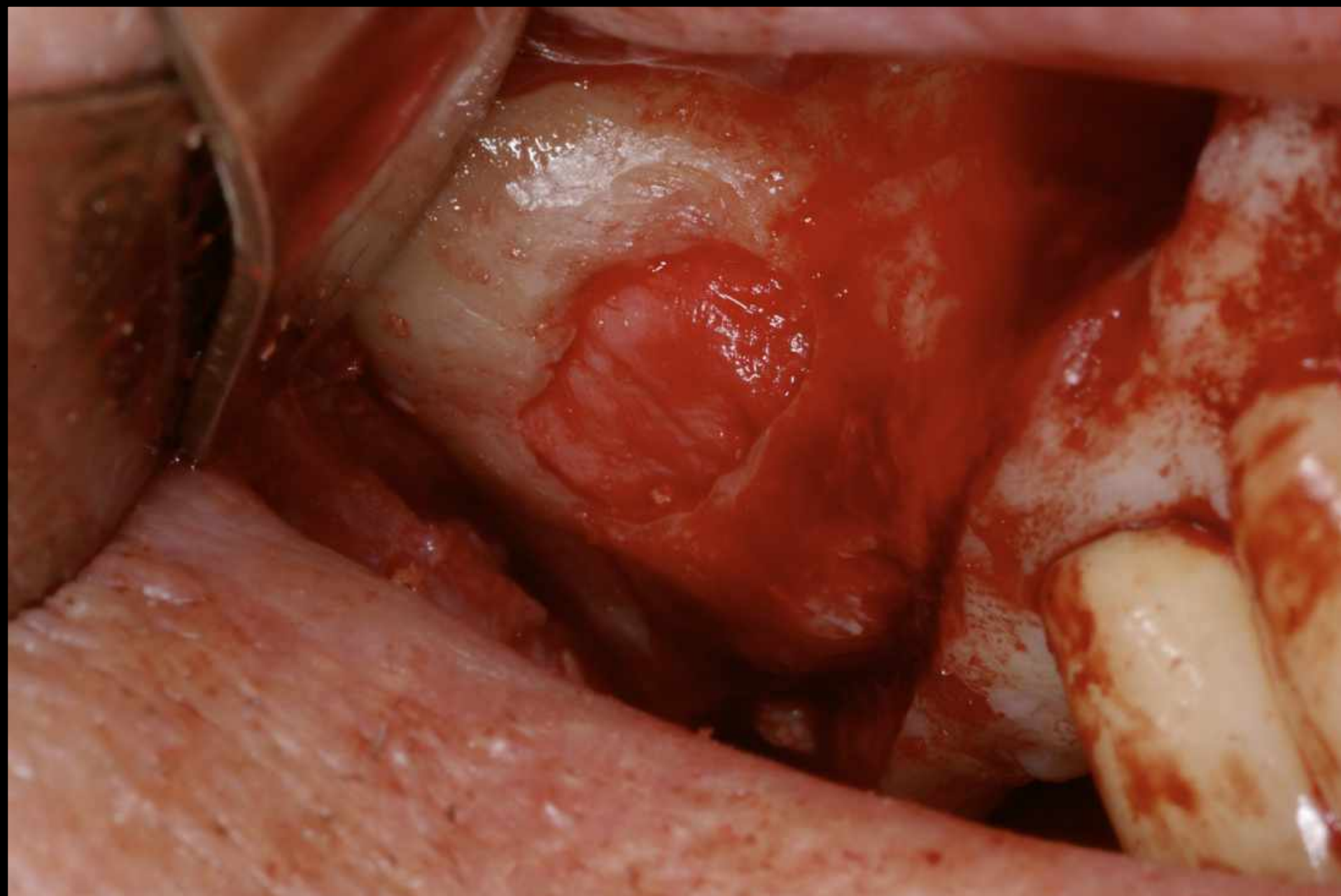
volet latéral

Complications



volet Latéral

Complications



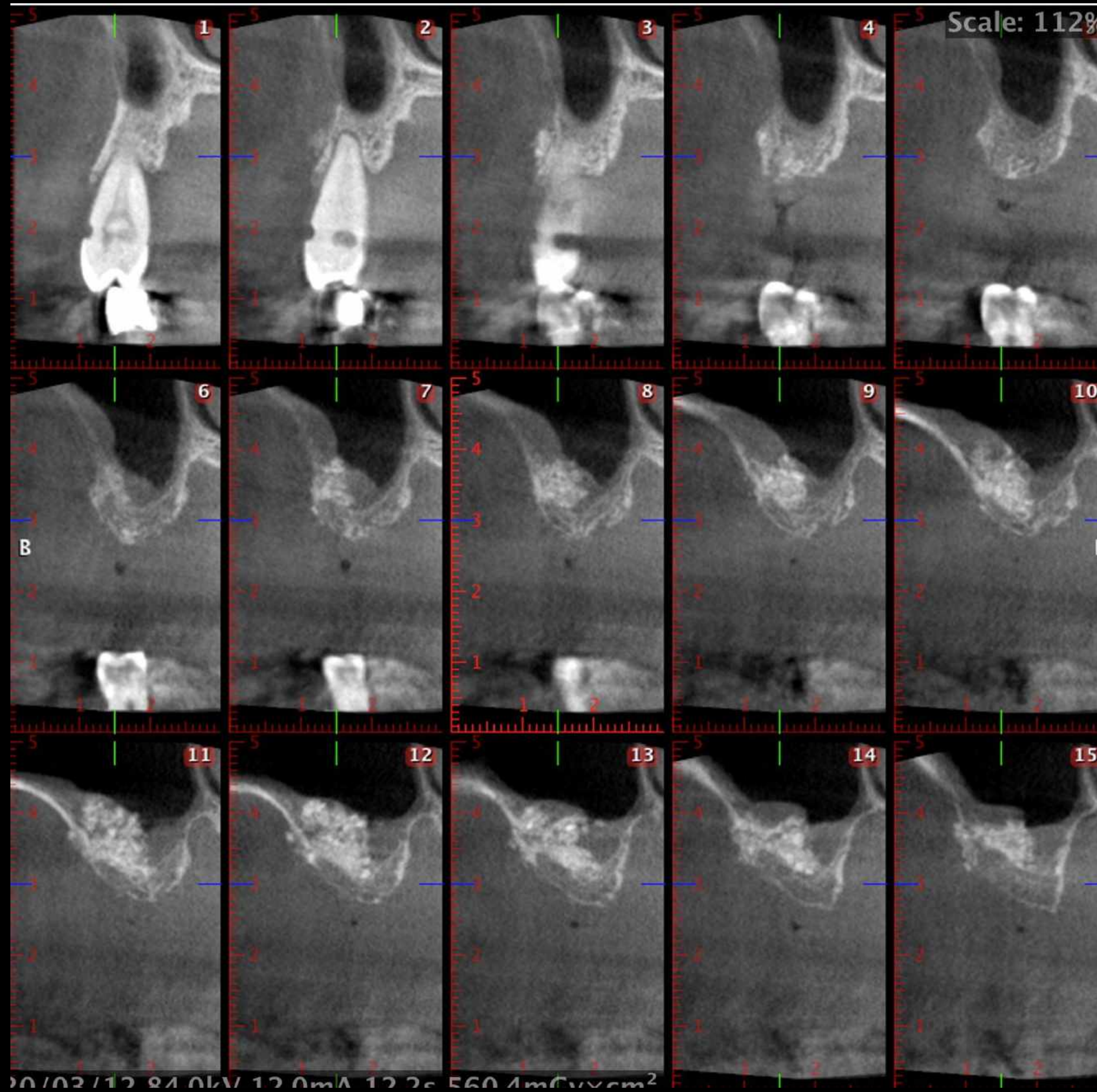
Volet Latéral

Complications

L'erreur de débutant :

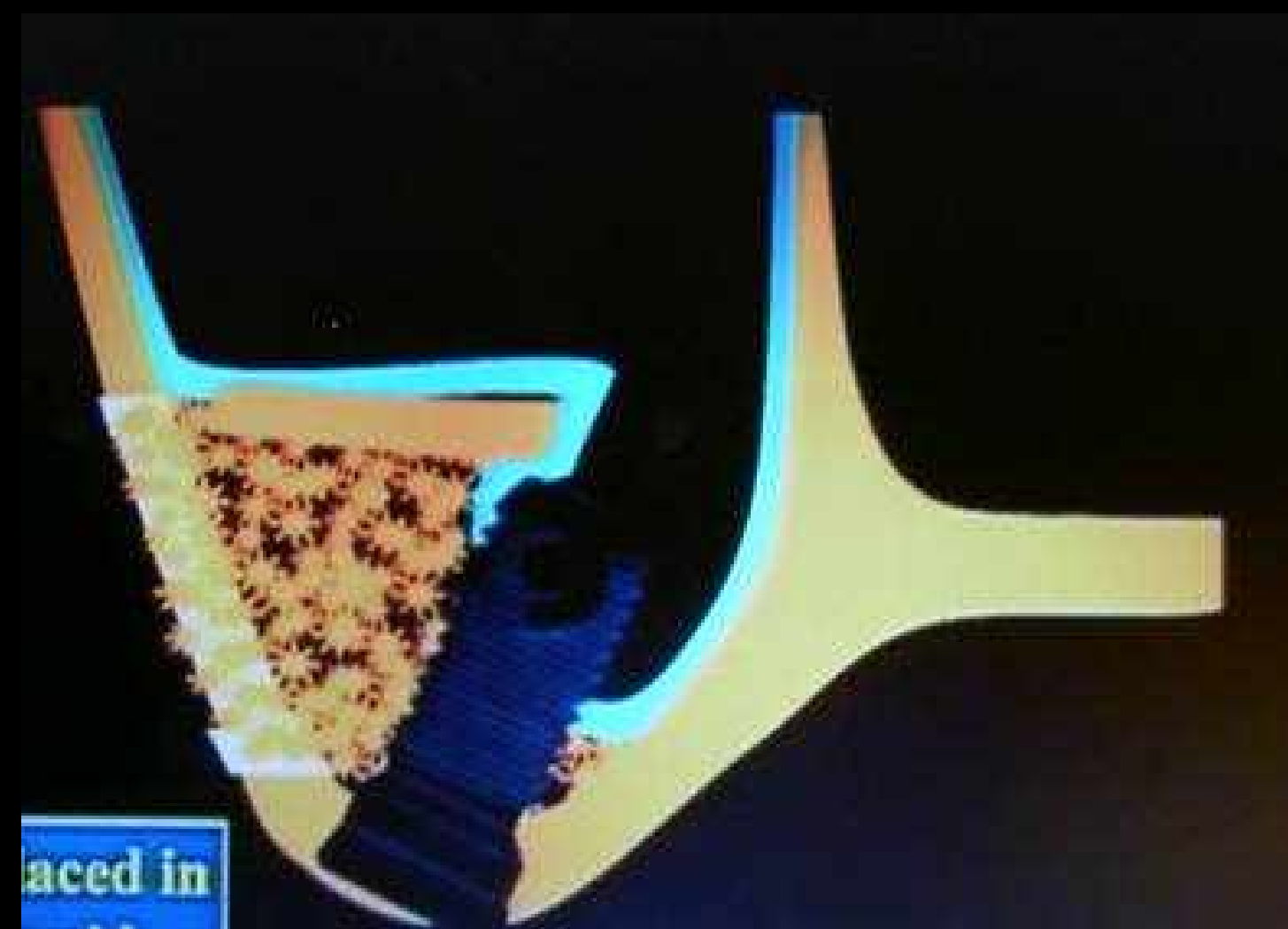
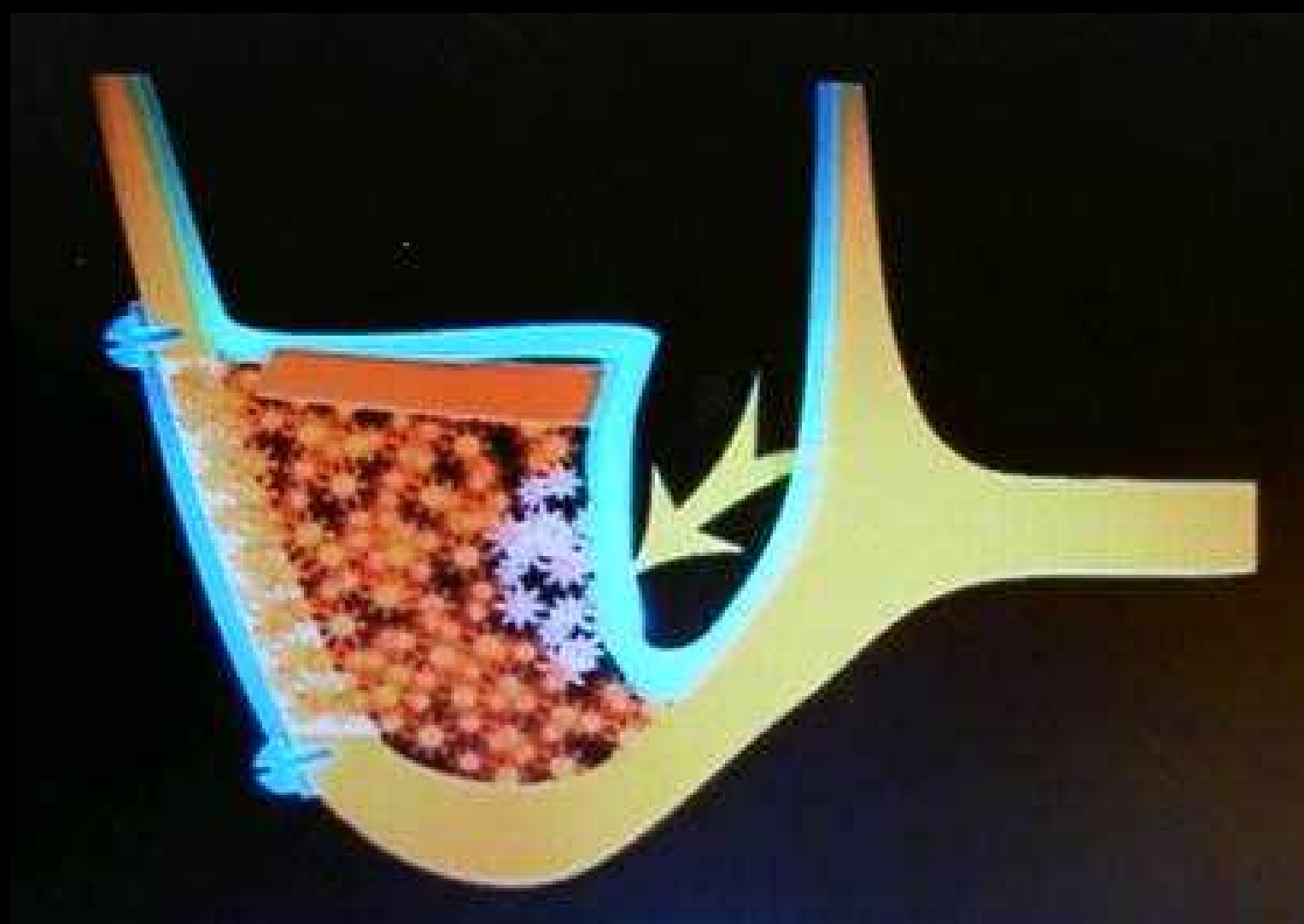
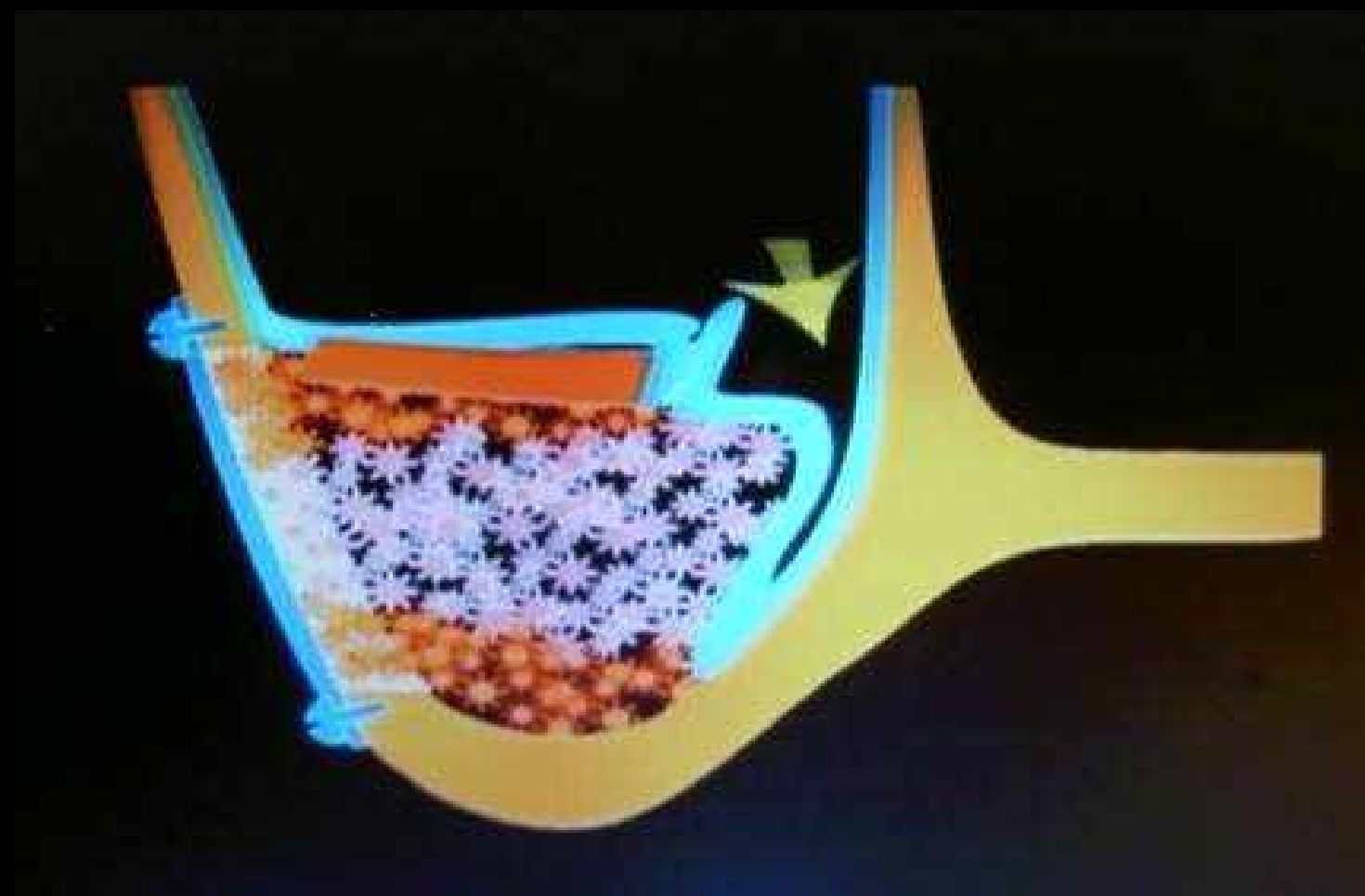
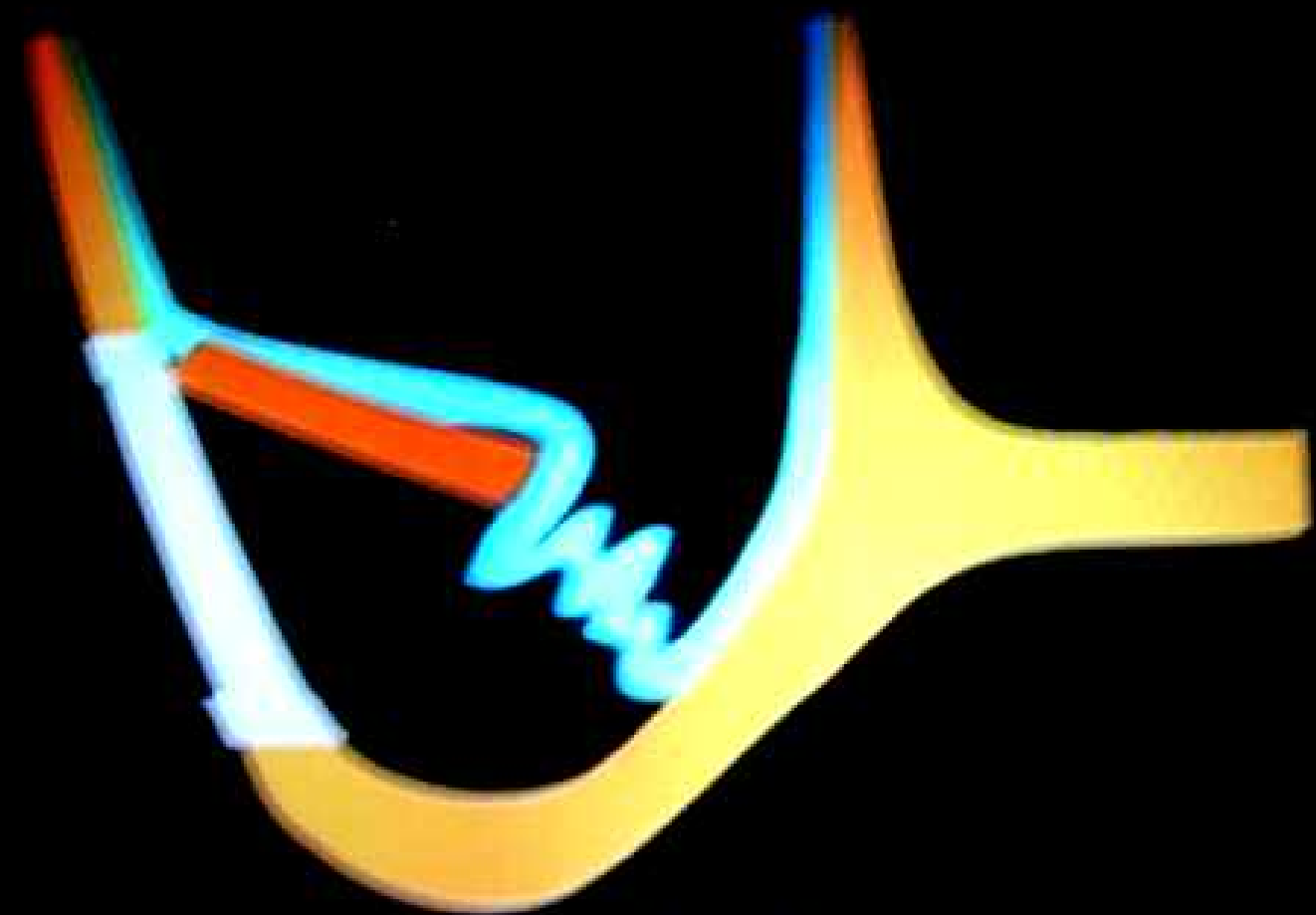
....

Ne pas aller chercher
la paroi médiale
du sinus



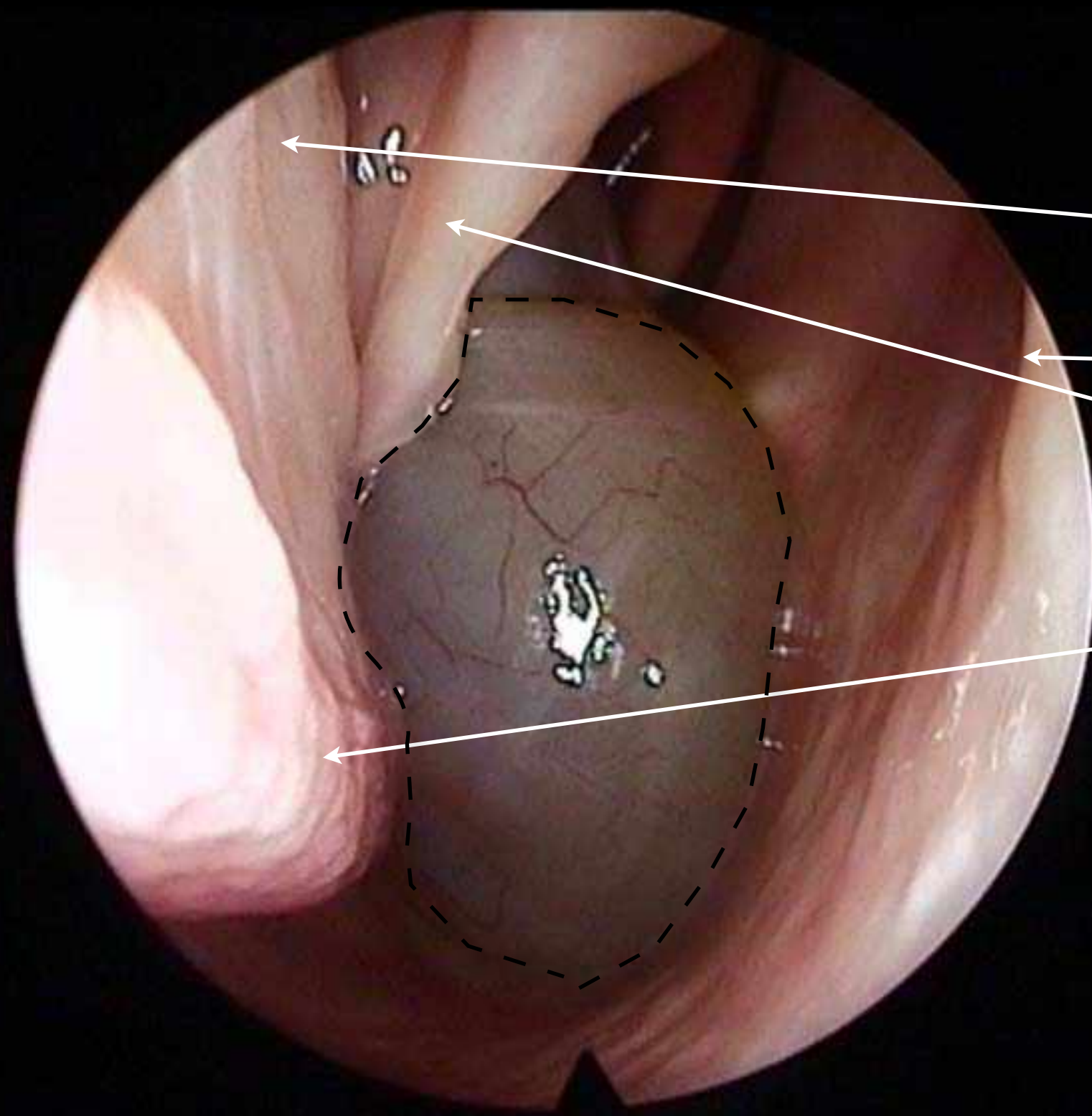
volet Latéral

Complications



GREFFE DU SINUS

Fosse nasale droite



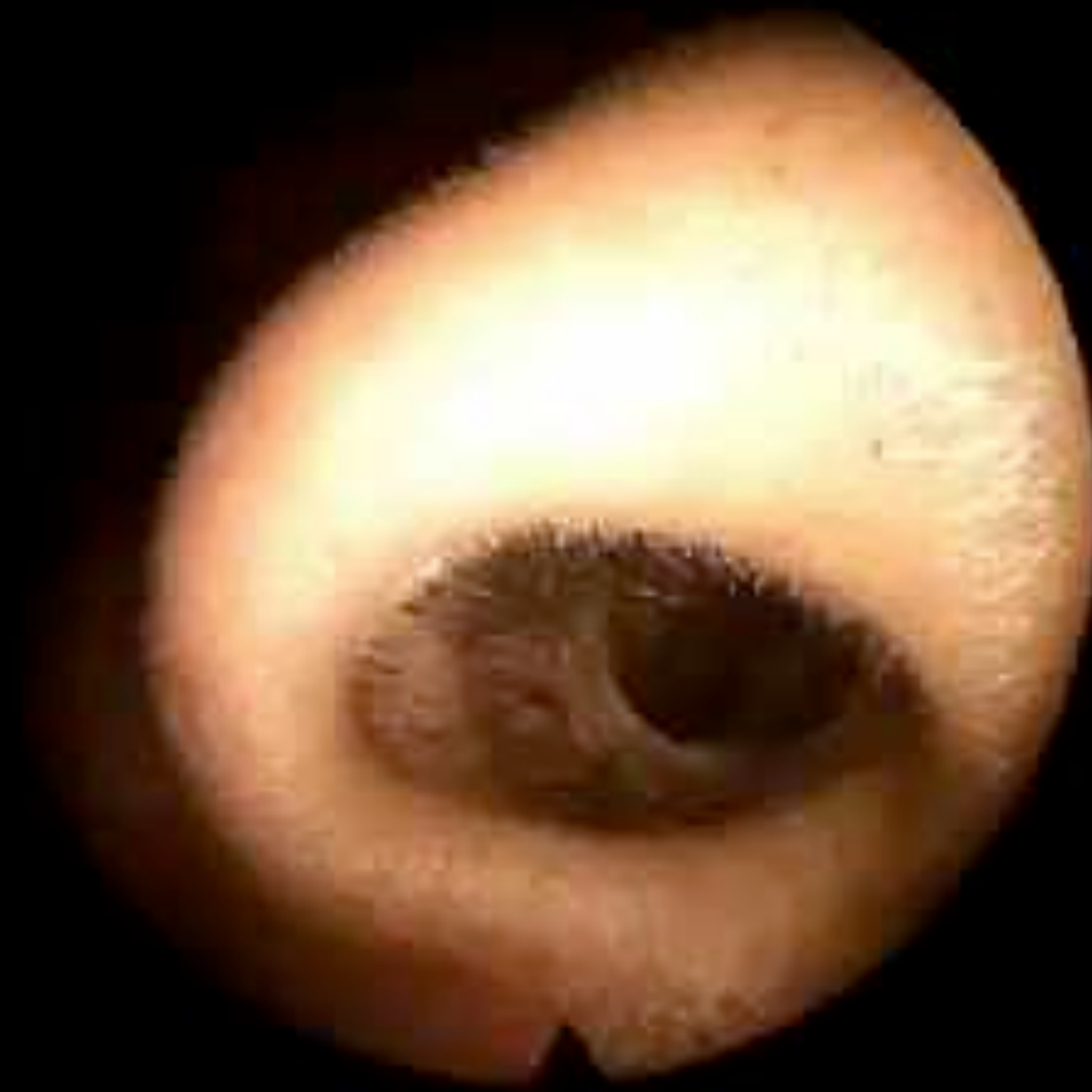- Apophyse unciforme
- Cloison
- Cornet moyen
- Cornet inférieur

Polypose solitaire antrochoanal (Kilian)

Volet Latéral

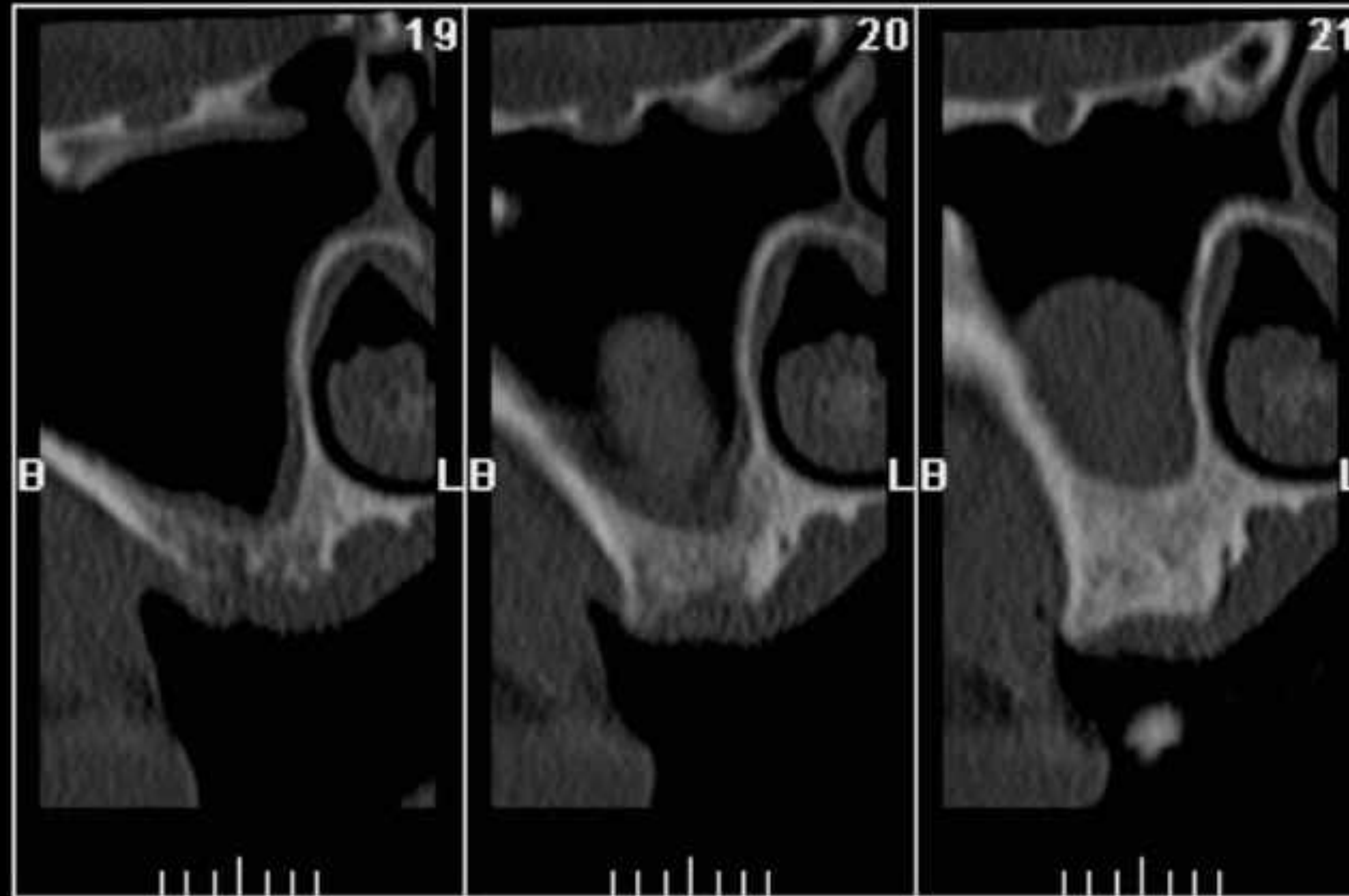
Examens cliniques

GREFFE DU SINUS



Polypose naso-sinusienne

Complications

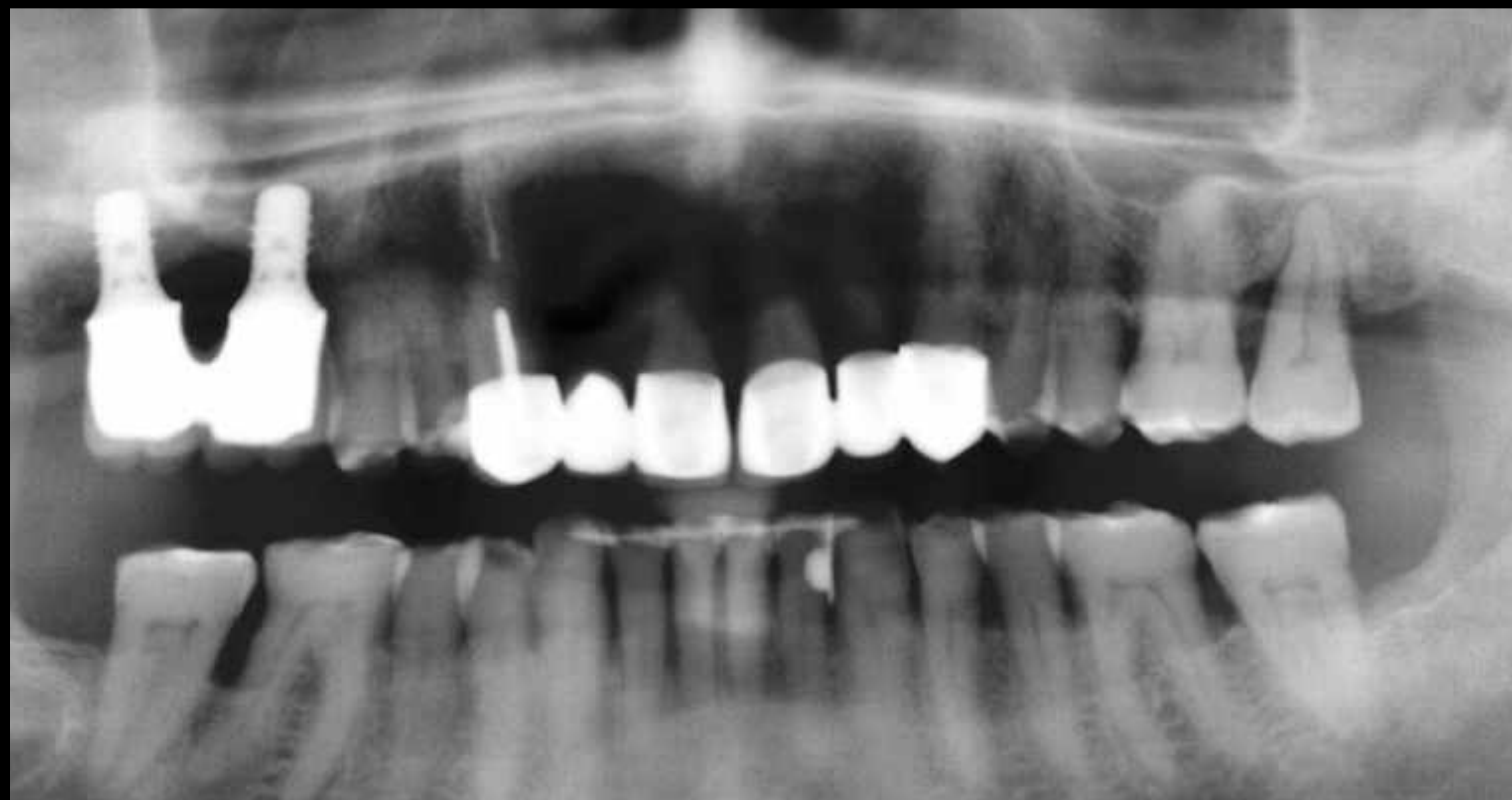

Je fais ou je ne fais pas ?

Complications

On fait !

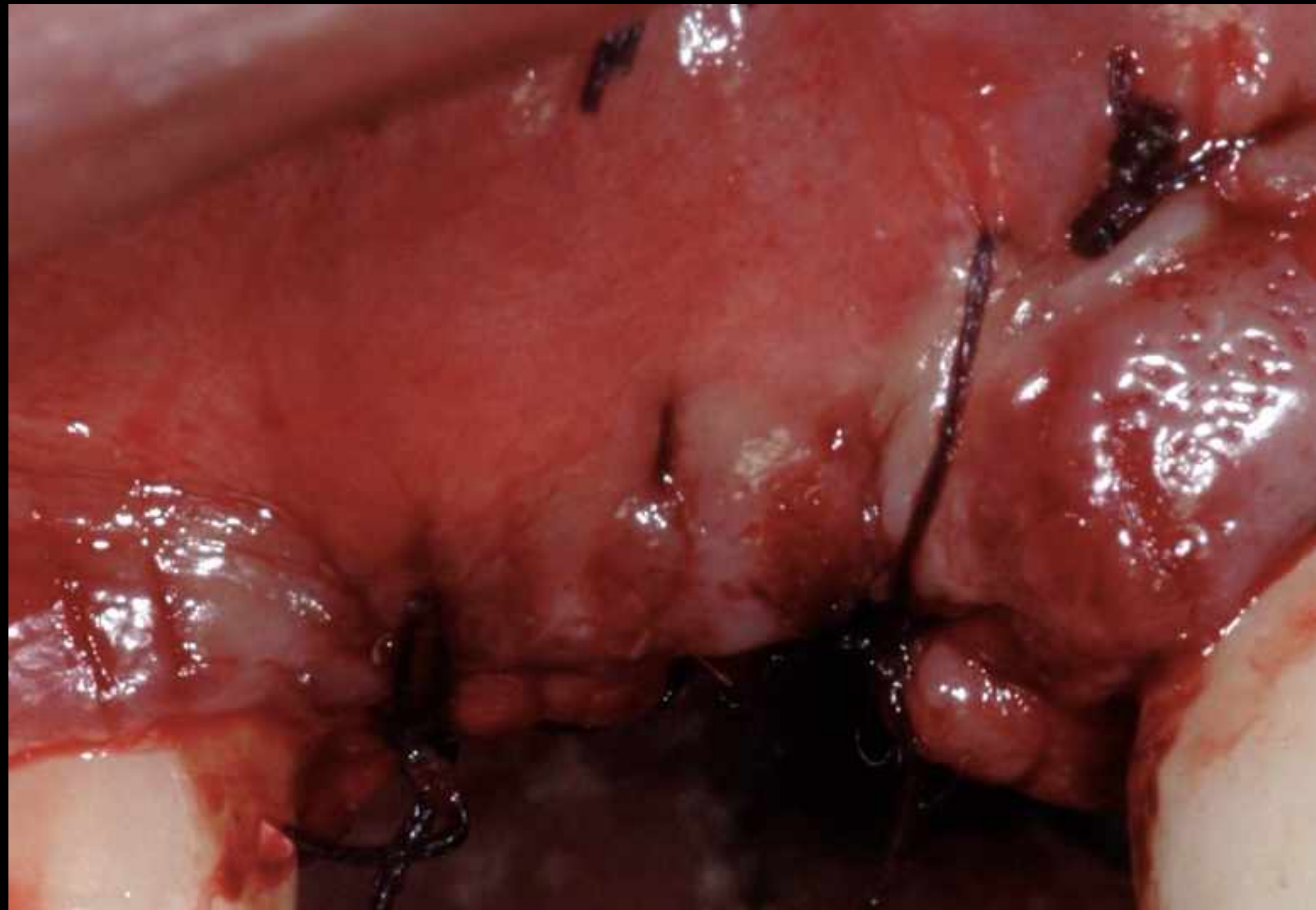Pas de difficulté opératoire particulière



Polype inférieur à 1/3 du volume du sinus

Volet Latéral

Complications



Complications:

inflammation du lambeau vestibulaire
pas de suppuration

Palpation douloureuse +
sinusite associée



Analyse :

Accord de l'ORL

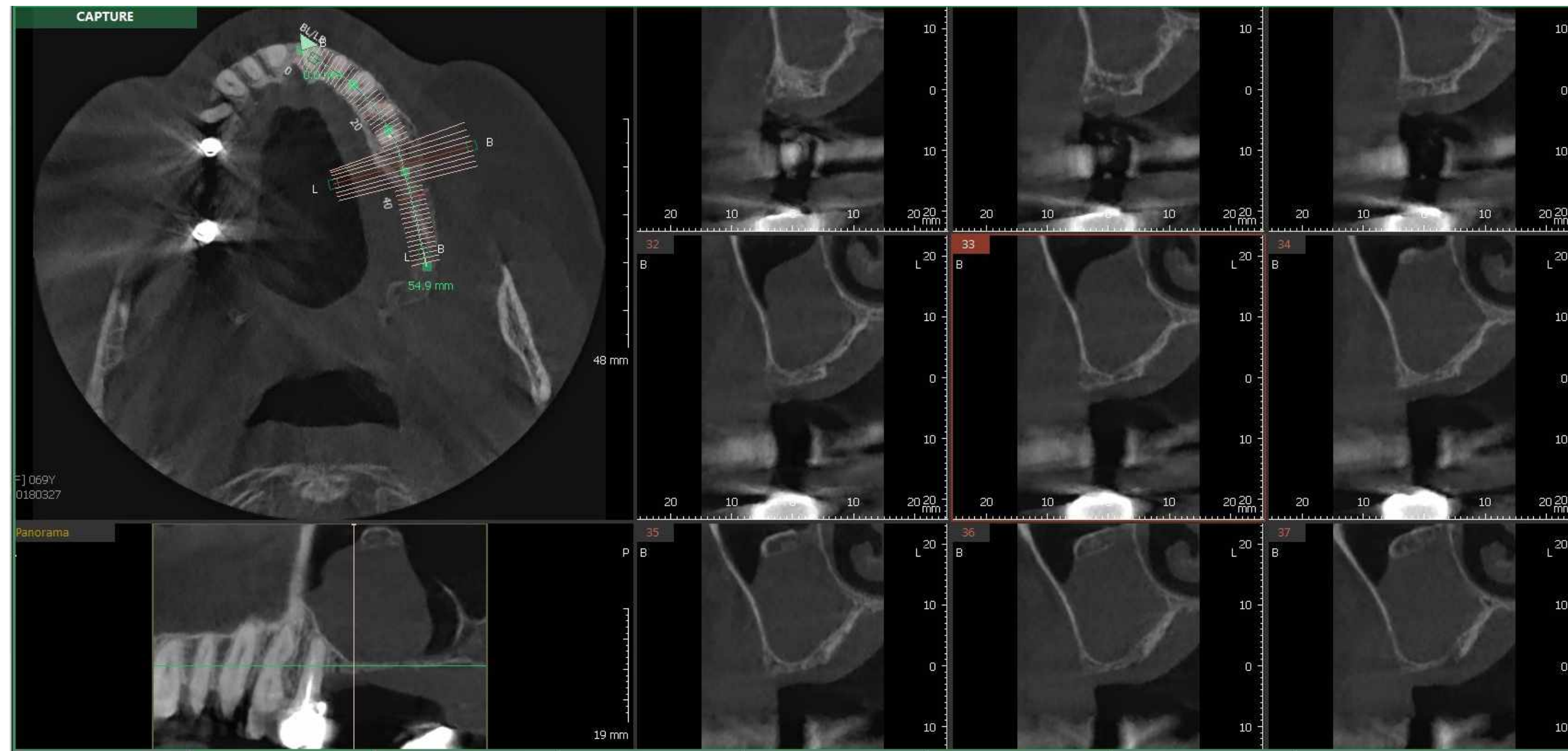
mais

ATCD pathologie sinusienne

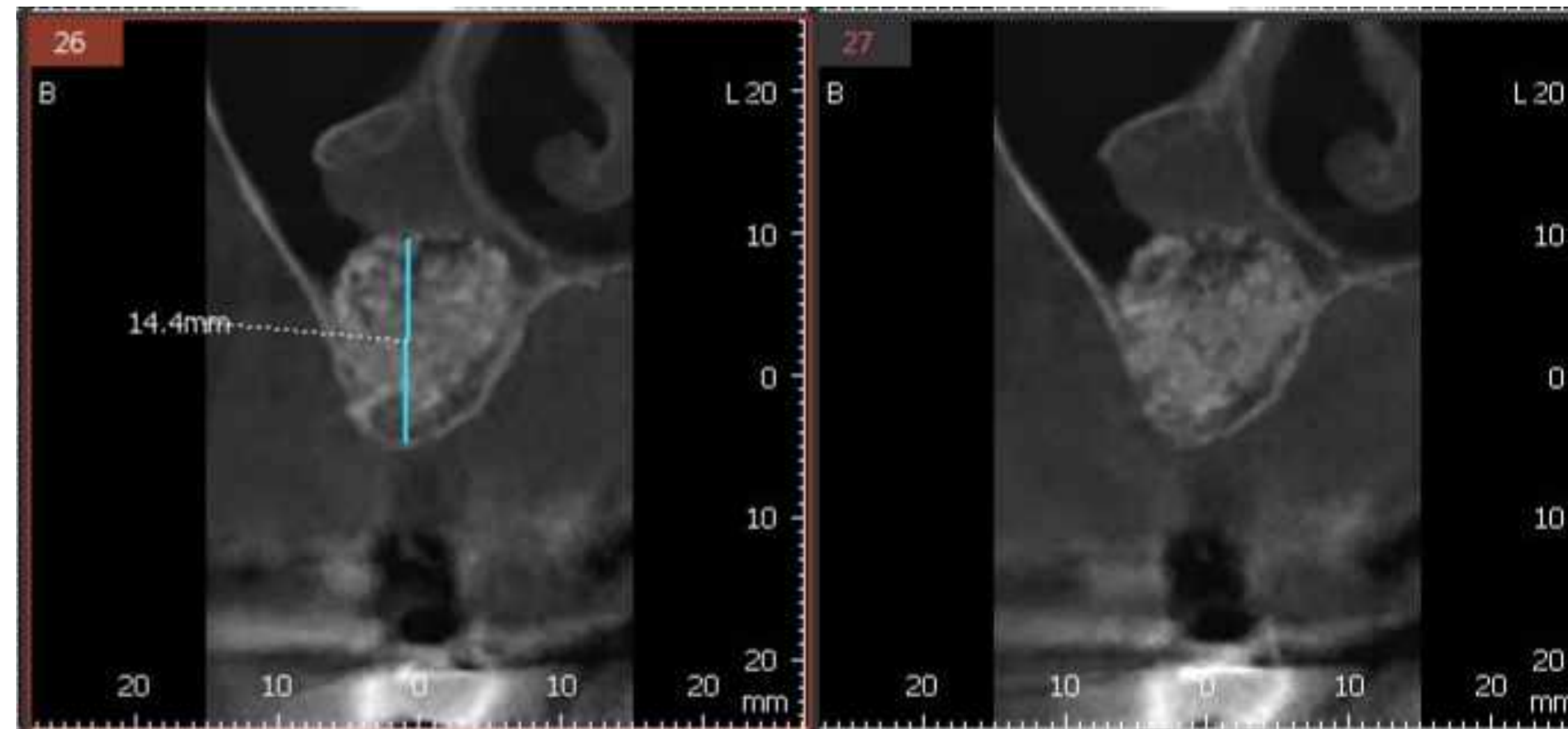
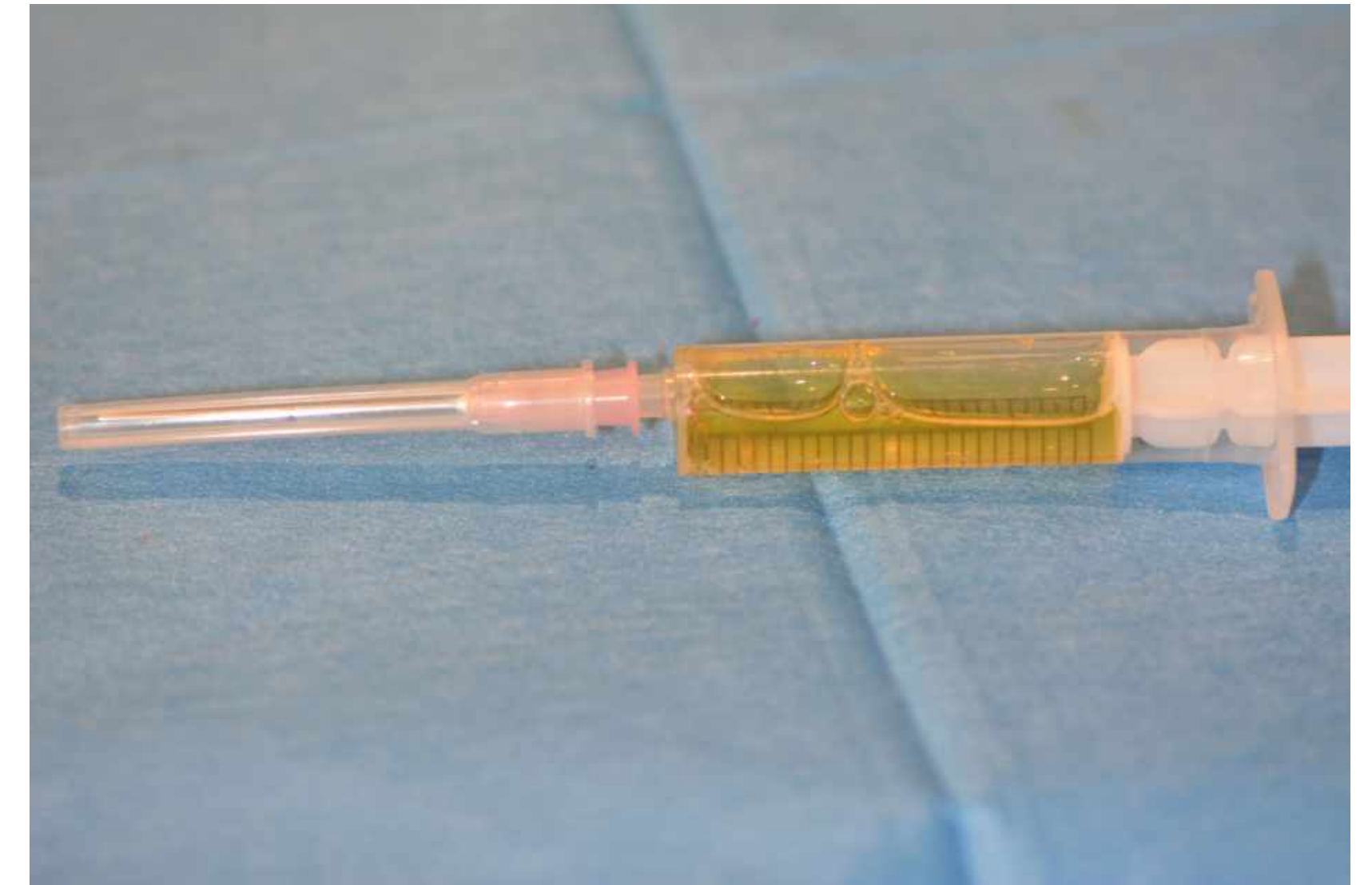Sinusite chronique

Polype

Inflammation membrane sinusienne : obturation méat moyen



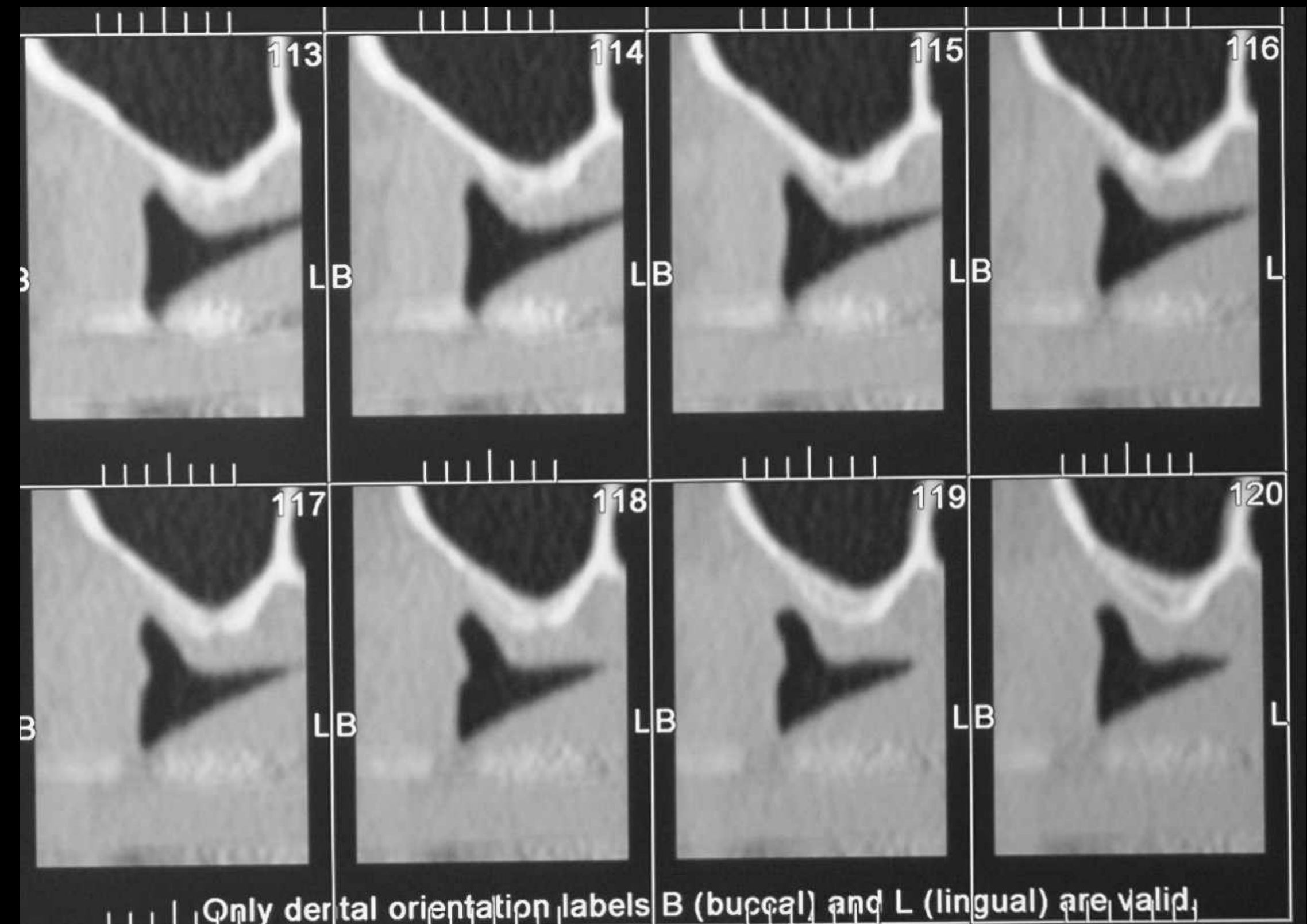
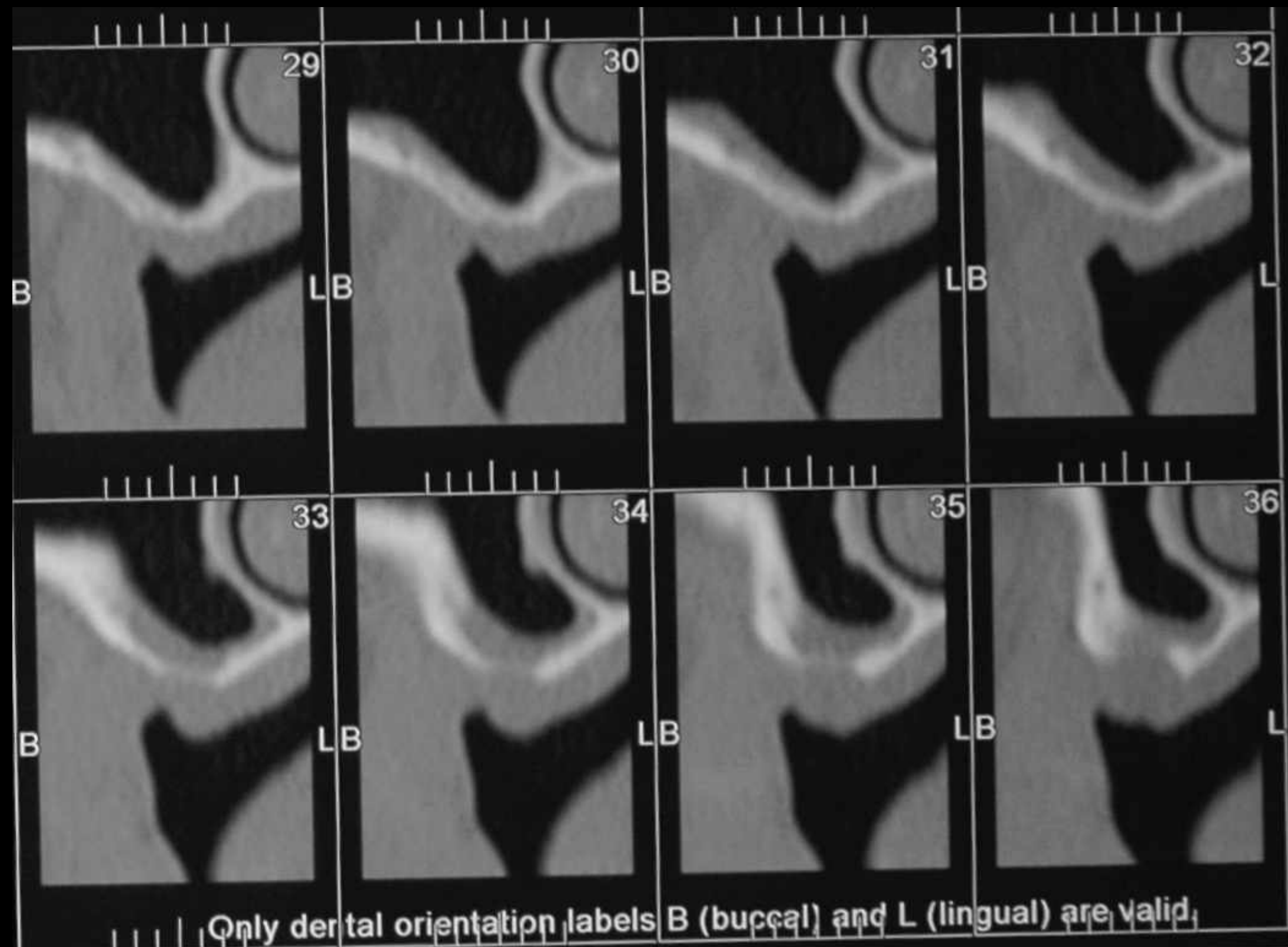
Aspiration d'un polype sinusien



Prévention
Complications

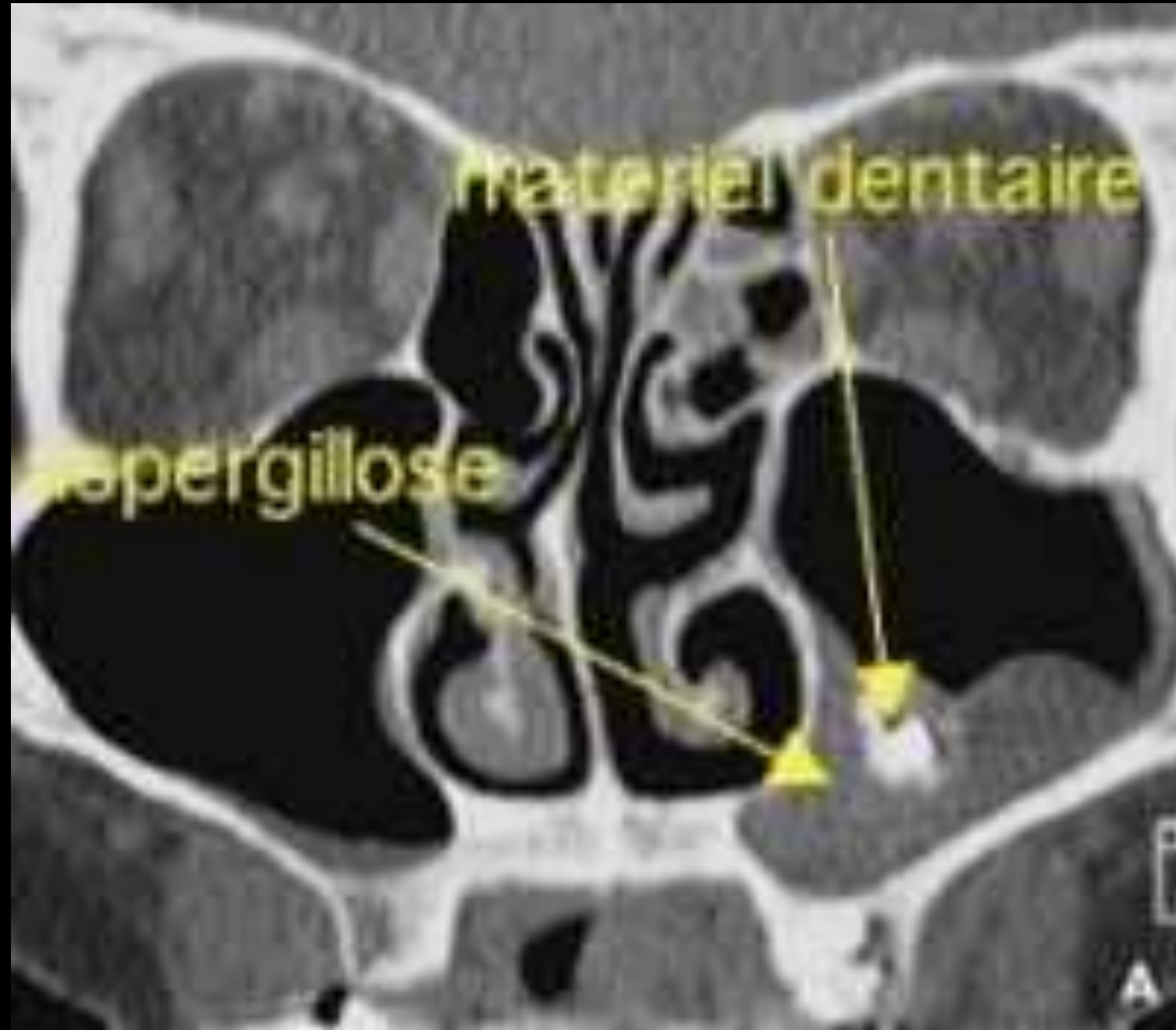
6 Mois
Post Op

Complications




Pas de pathologie mais sinus difficile :
Faible épaisseur de muqueuse
Sinus très pneumatisé
forme en S

GREFFE DU SINUS



Aspergillose
Balle fongique

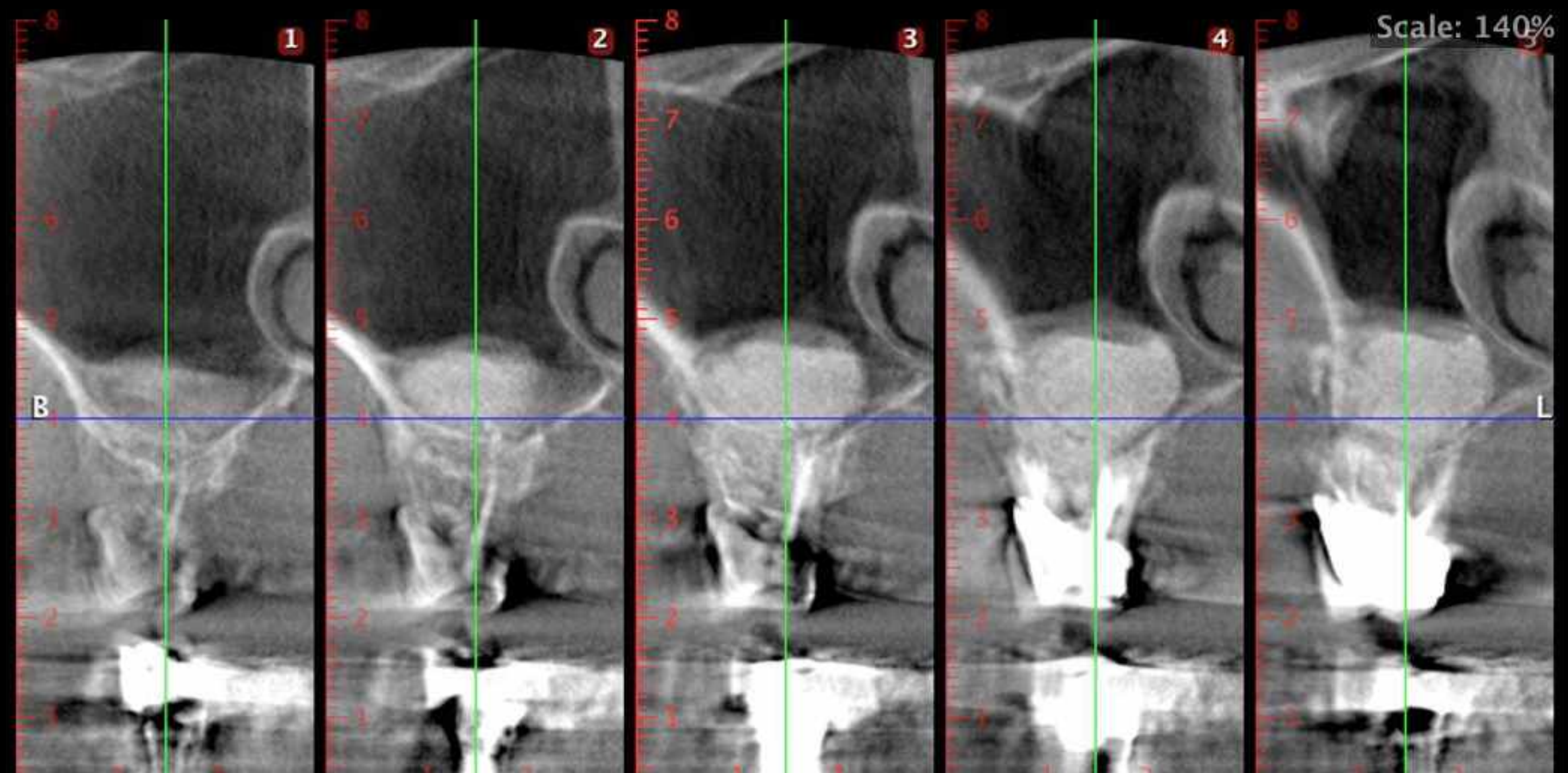

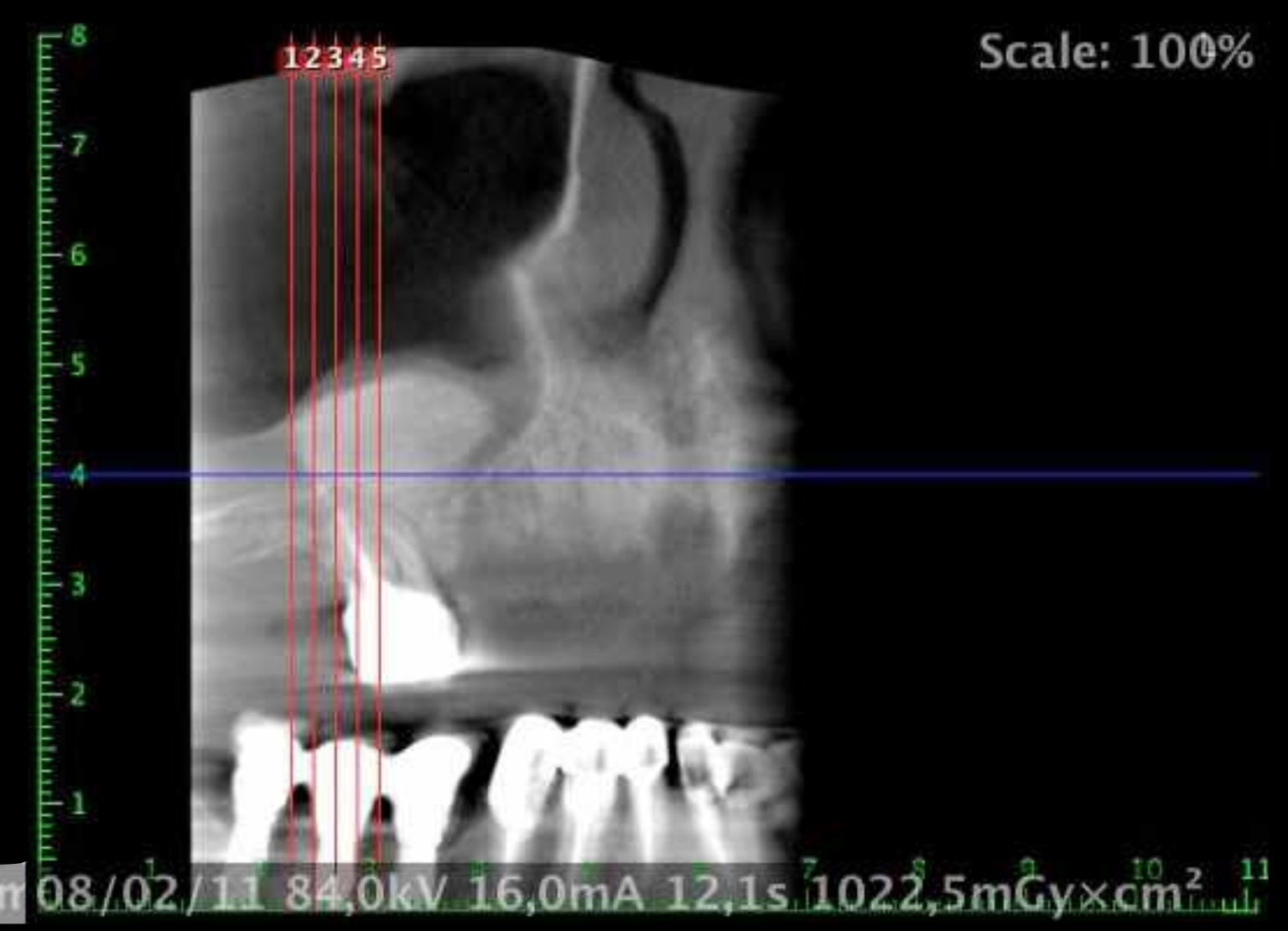
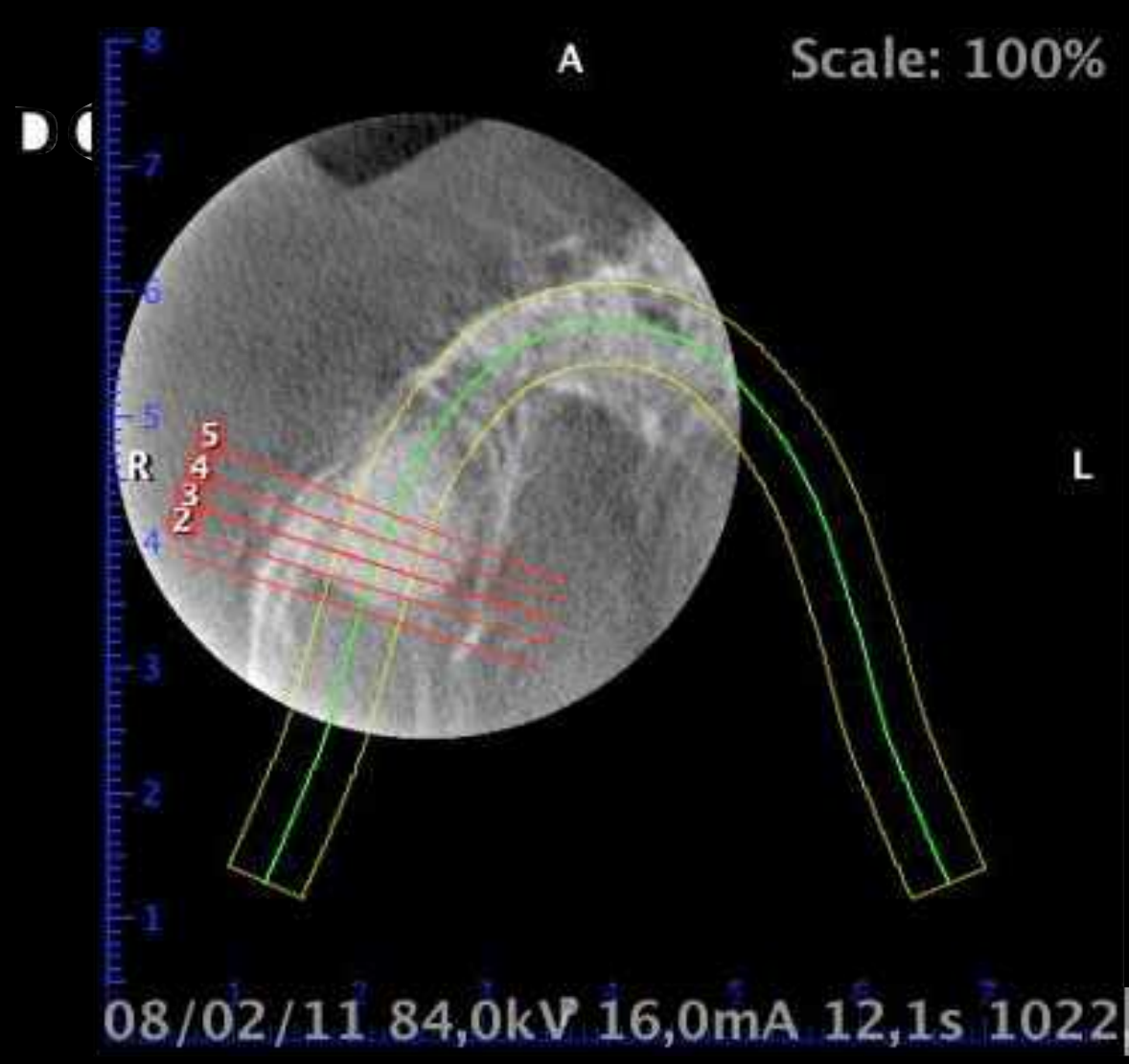
Se développe au dépend
des structures osseuses
indication chirurgicale



Intervention de l'ORL !

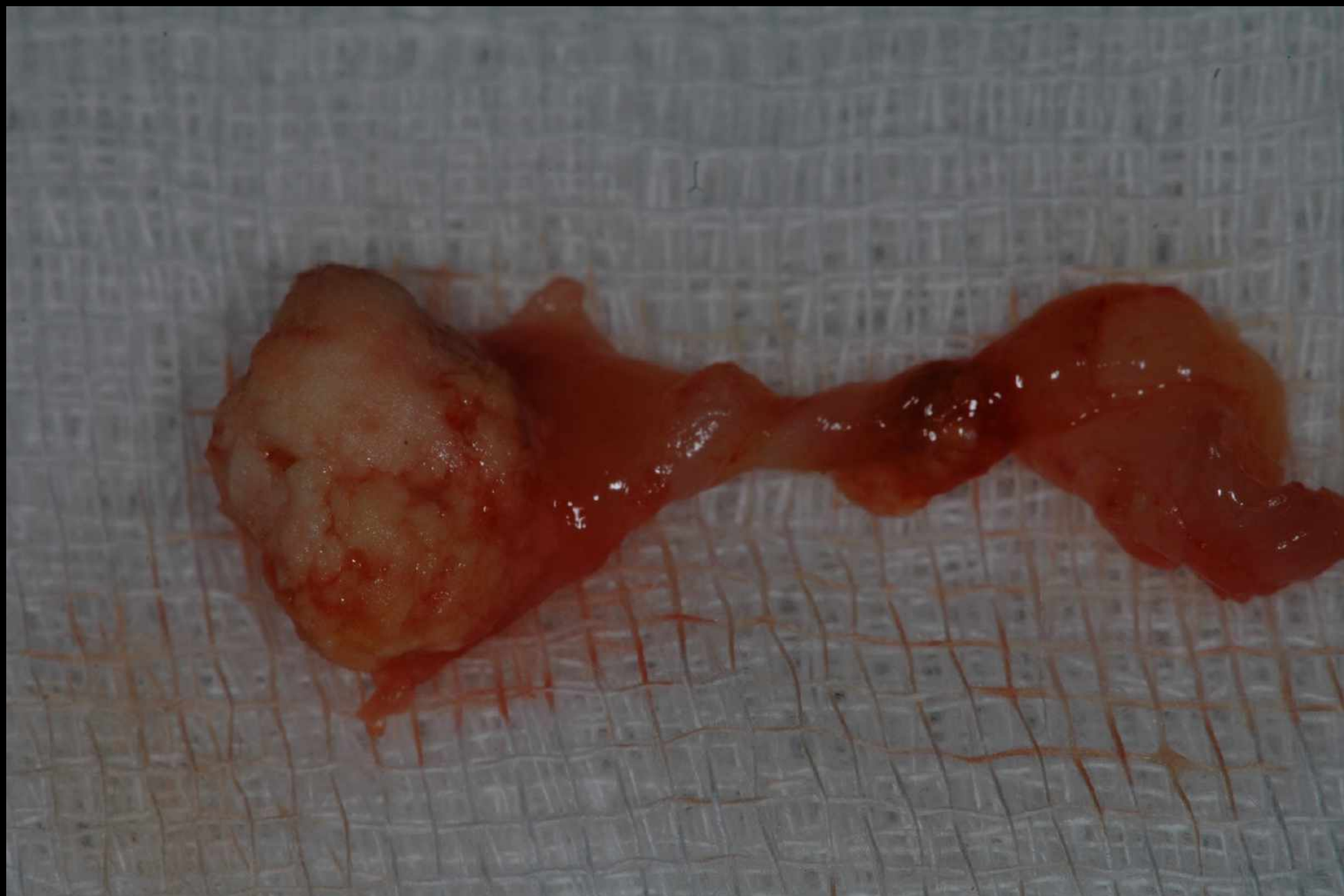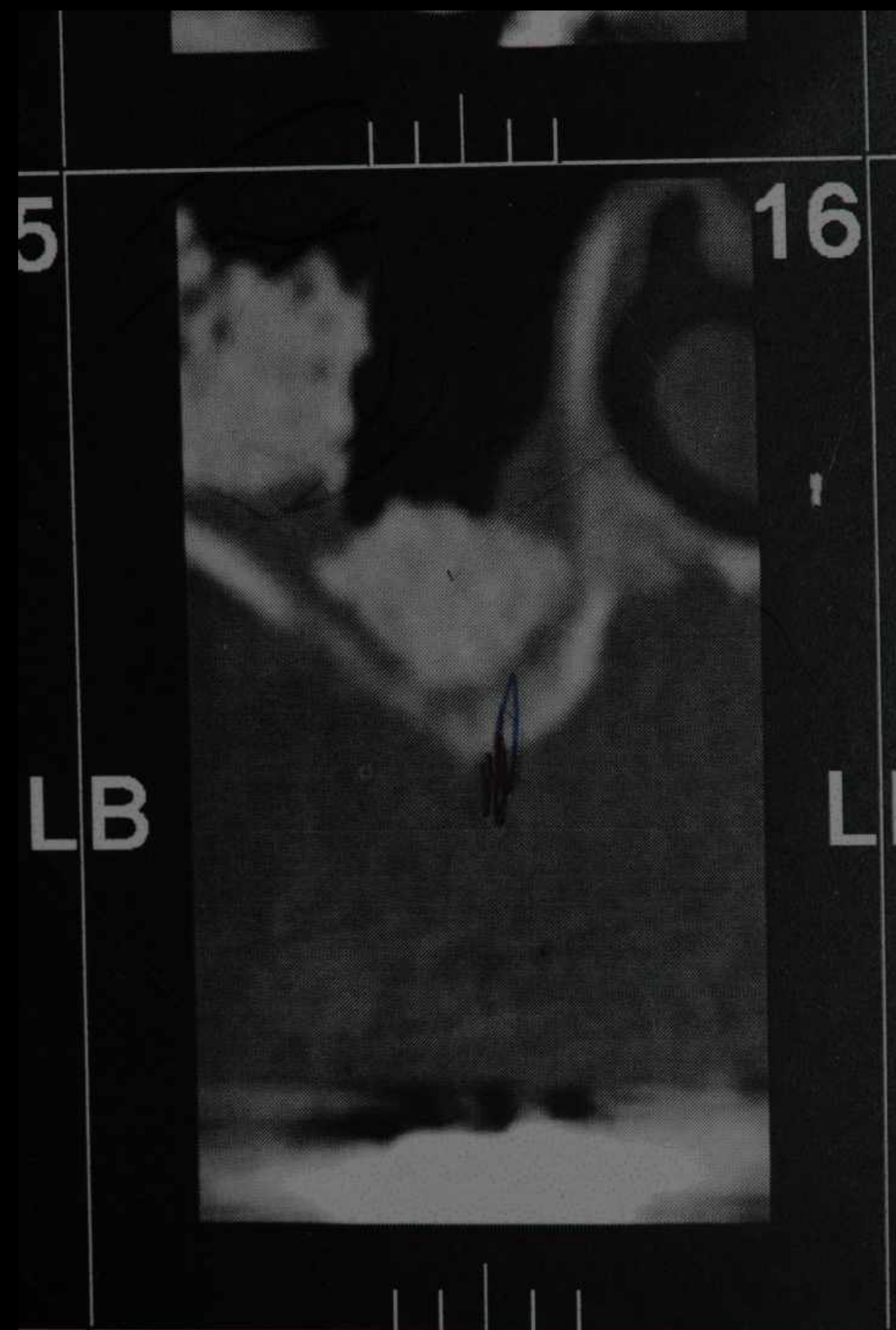
Volet Latéral

Complications

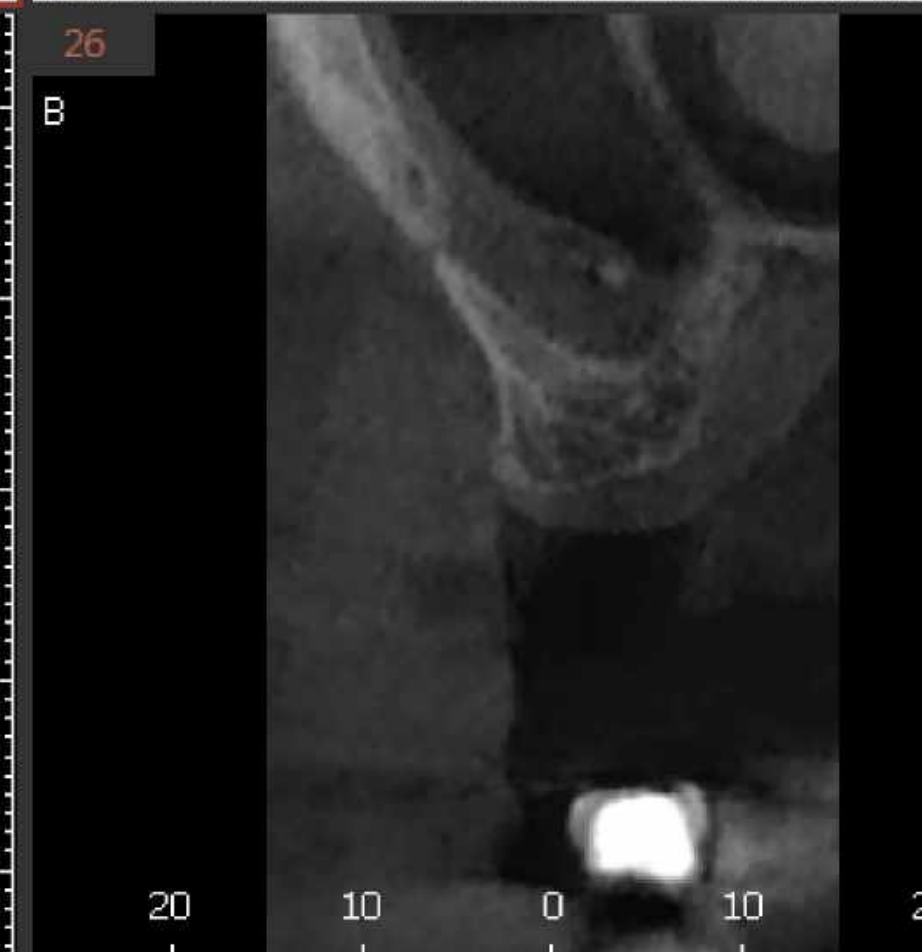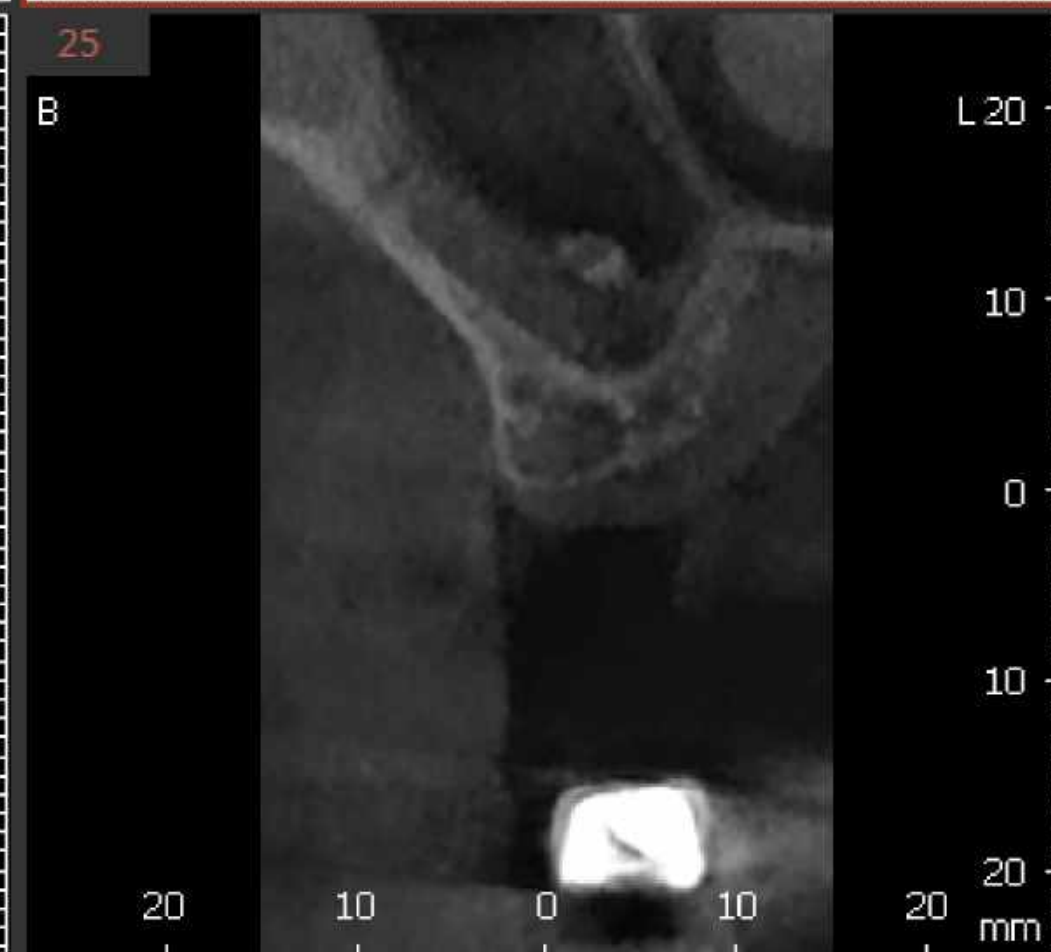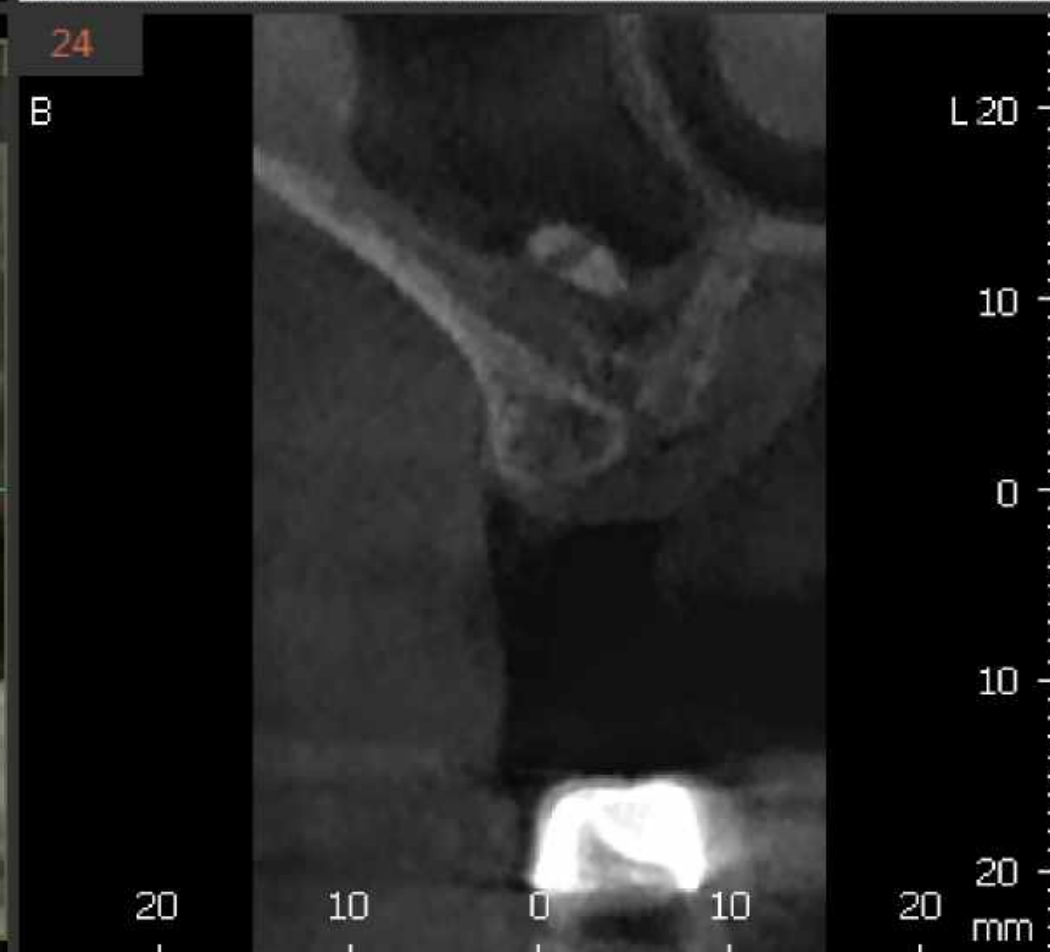
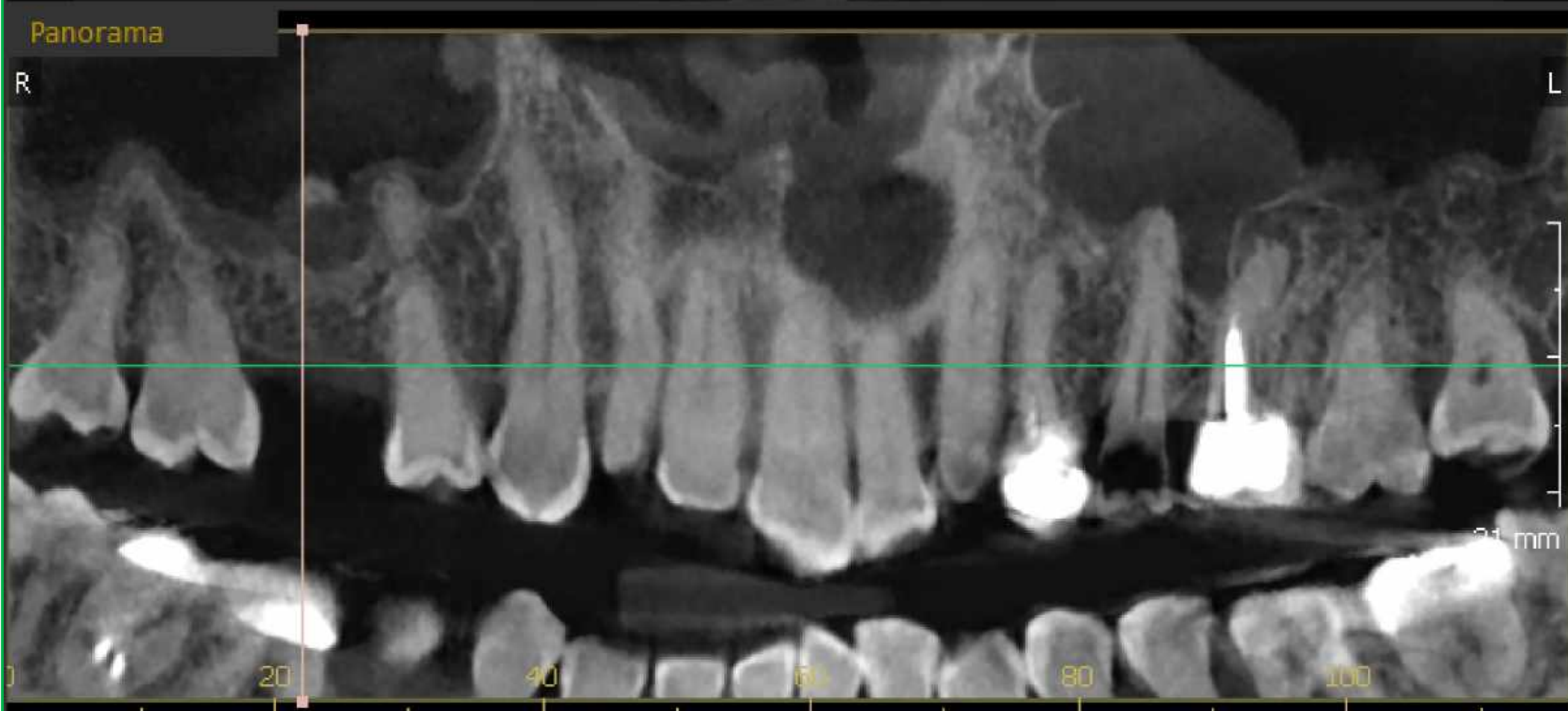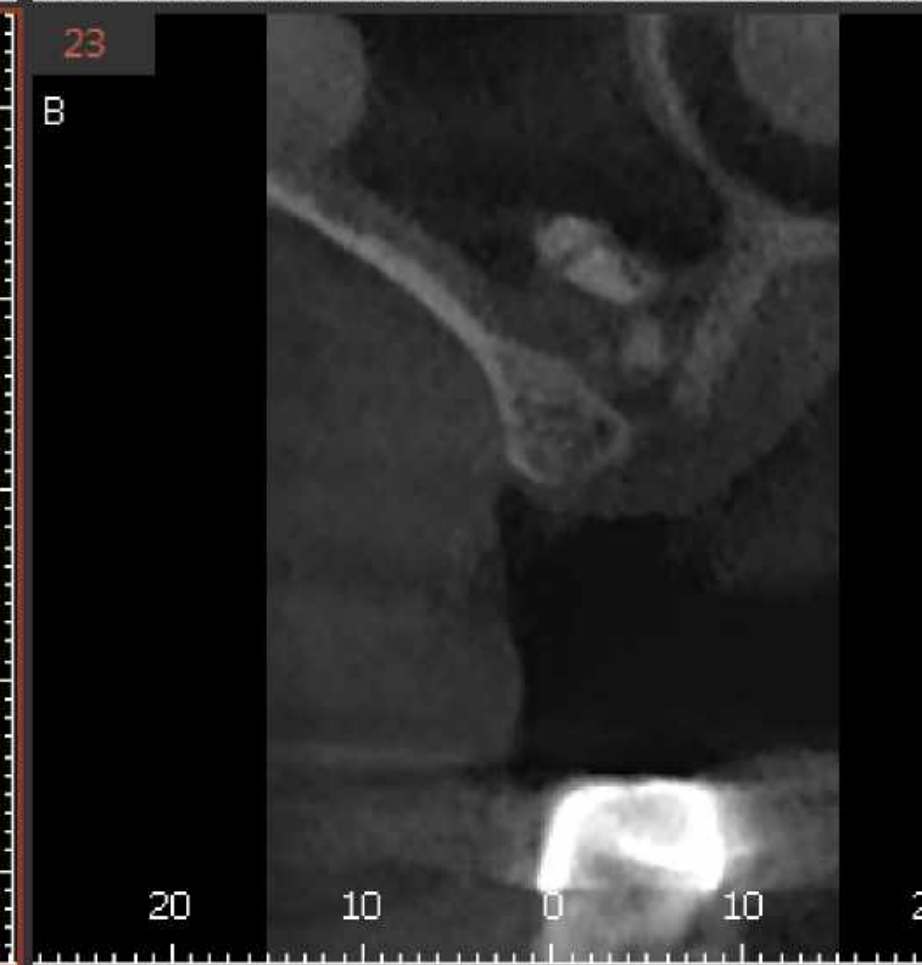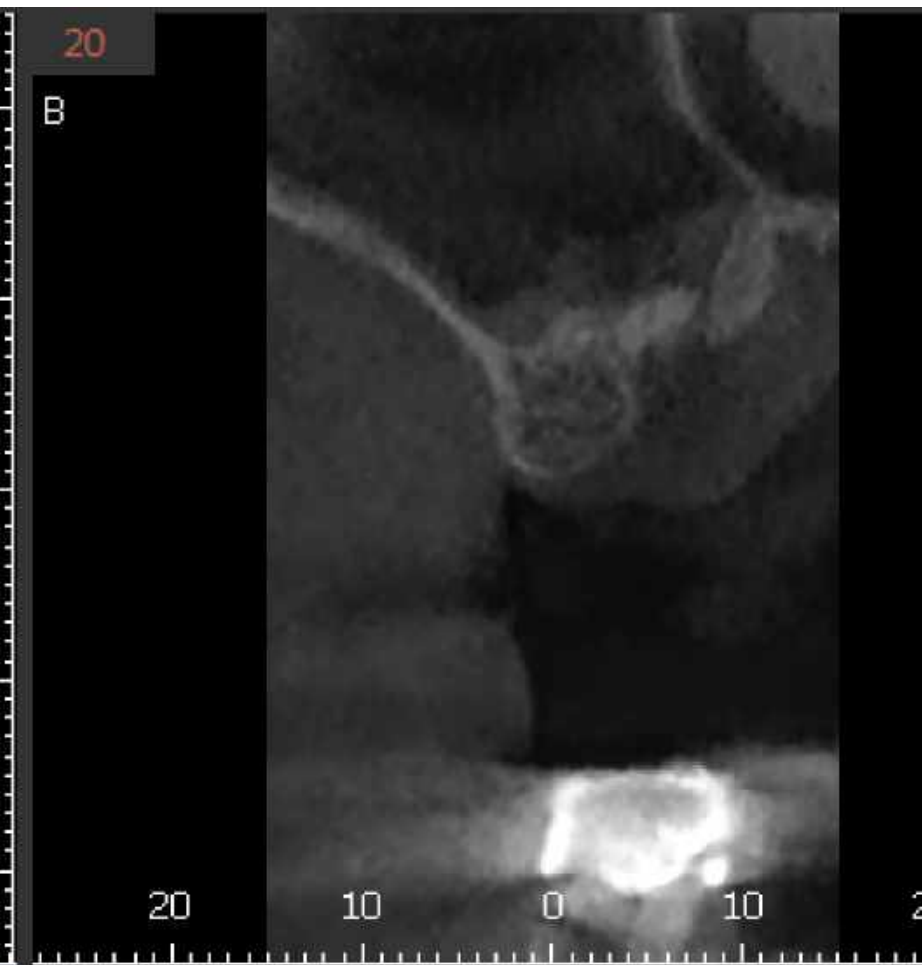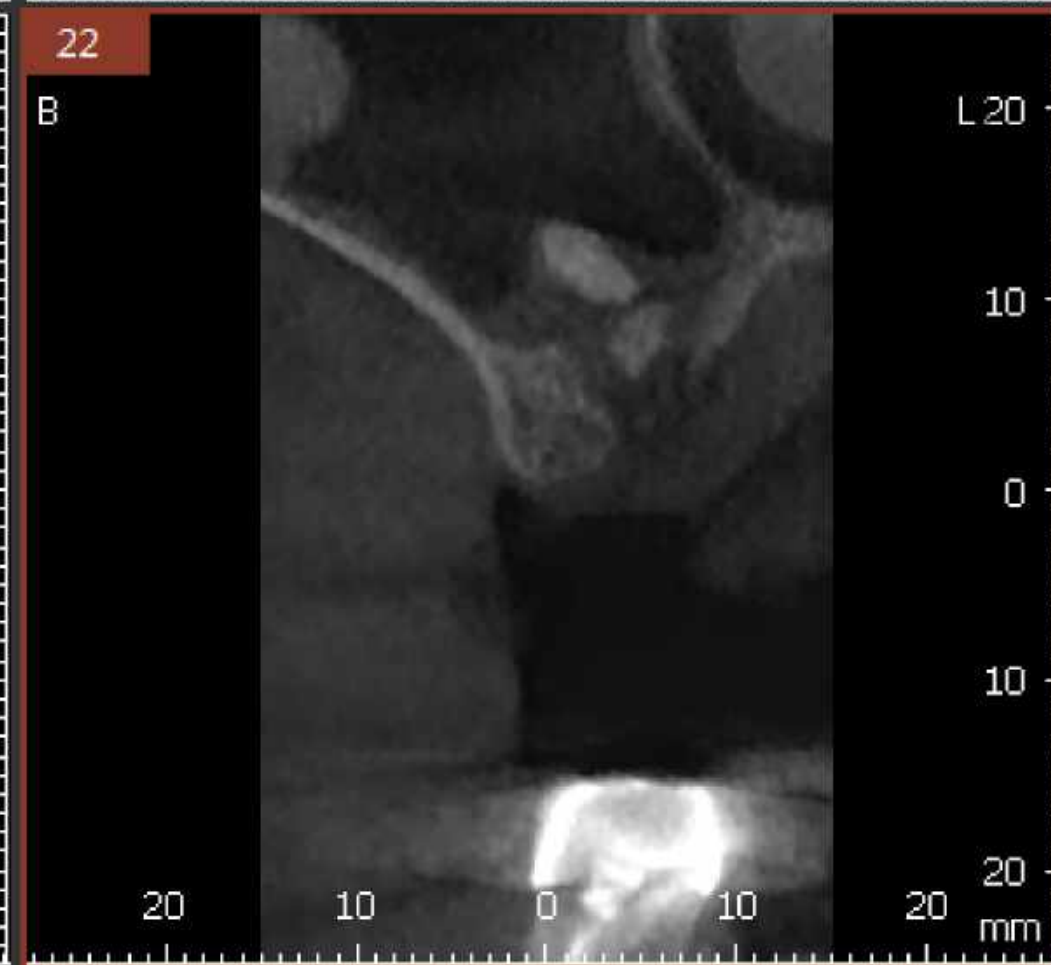
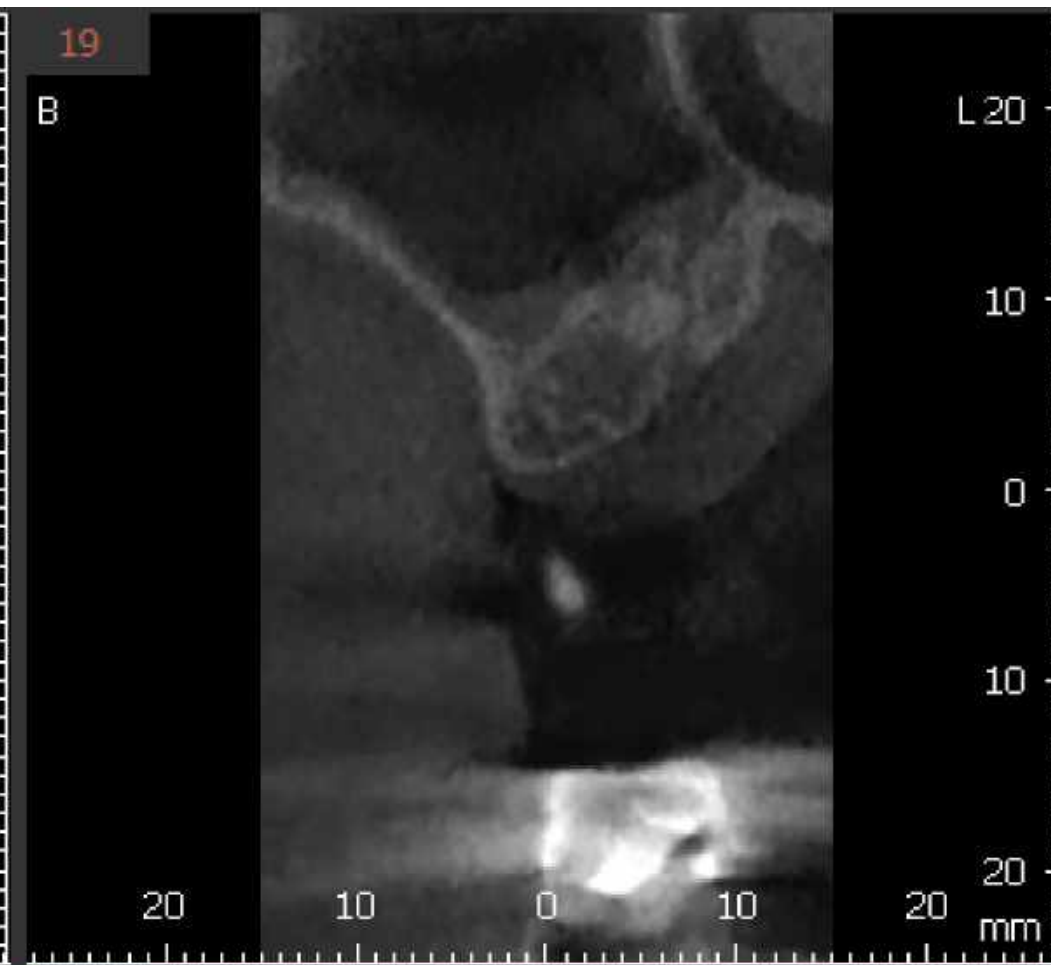
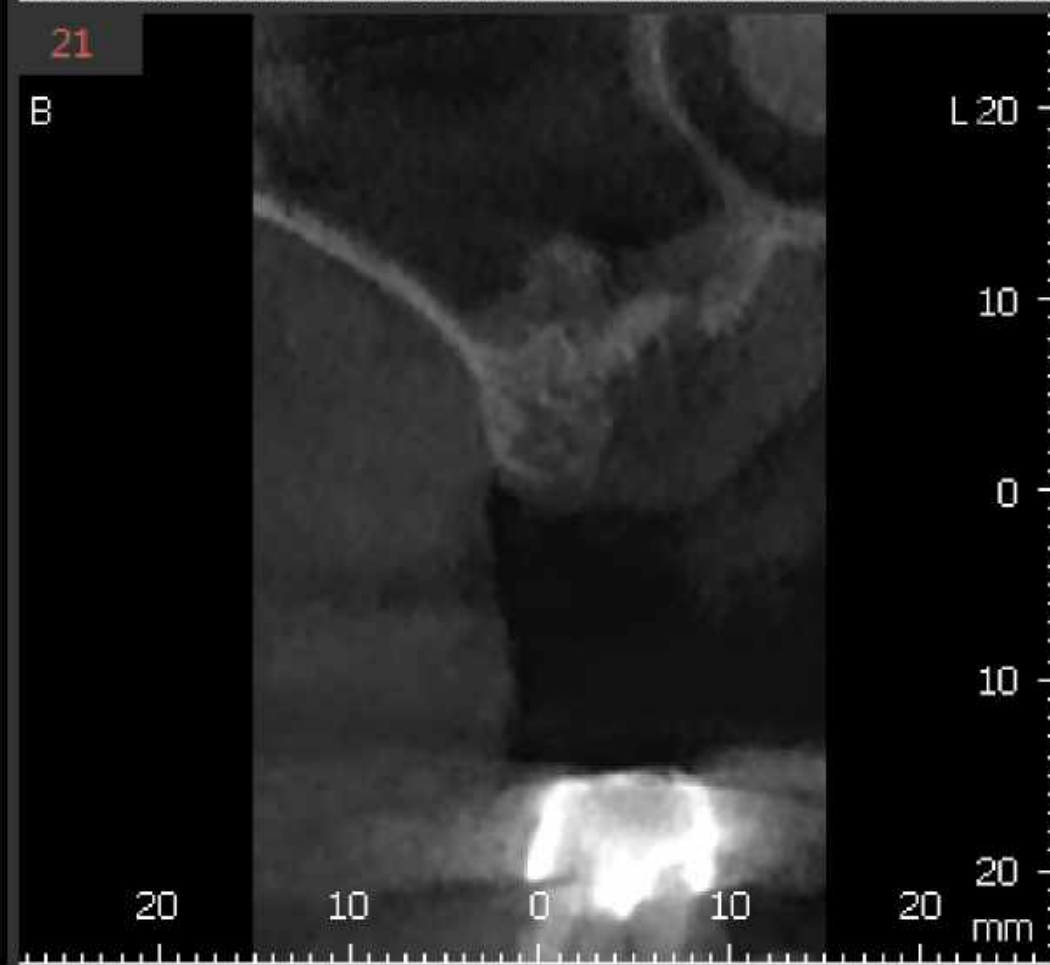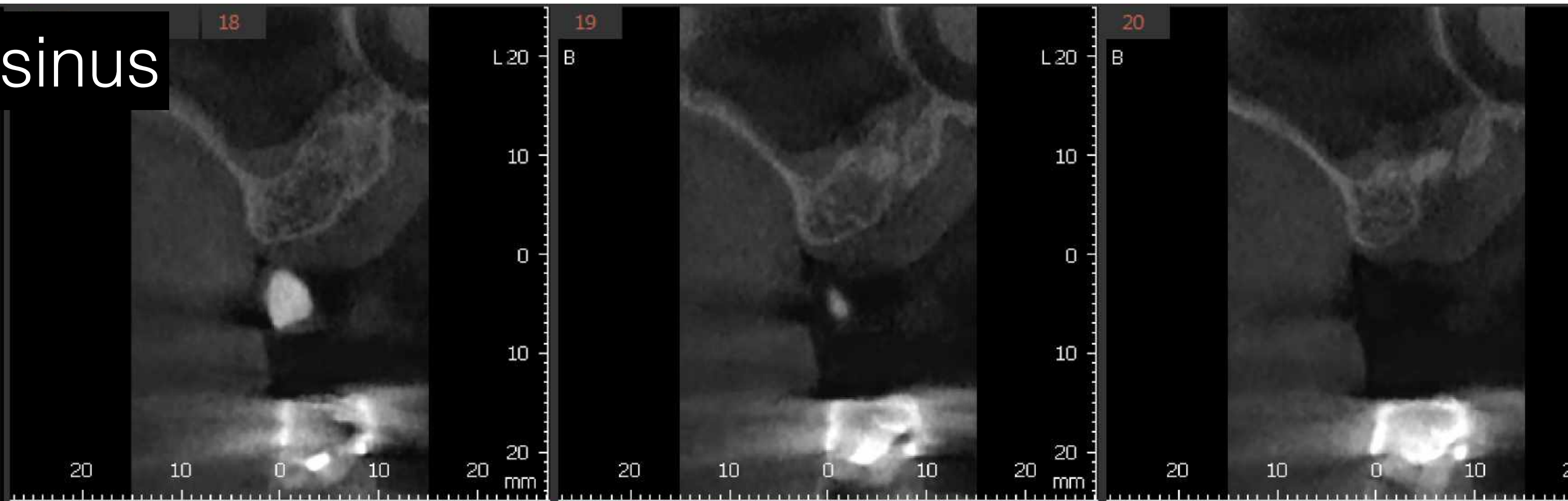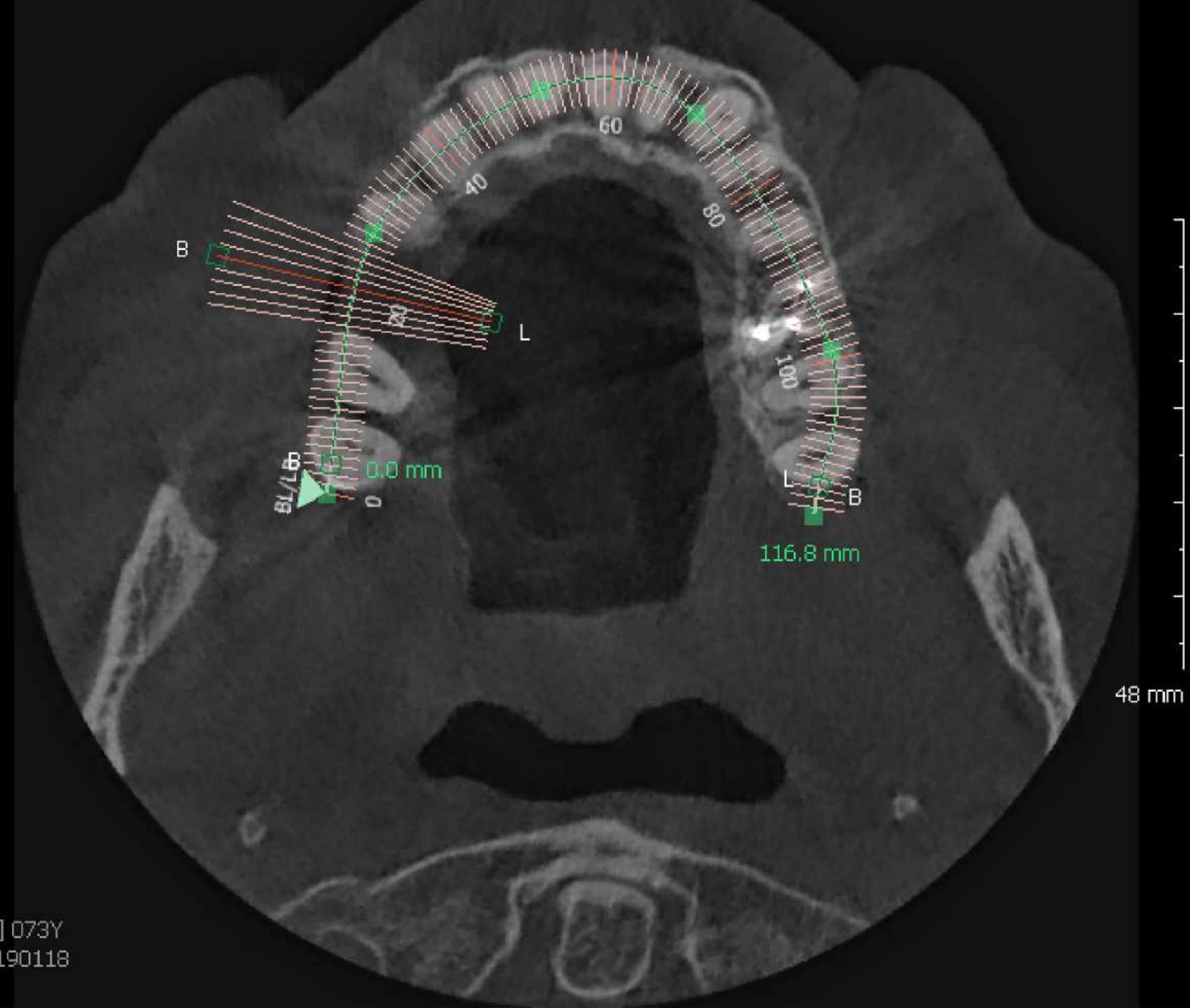


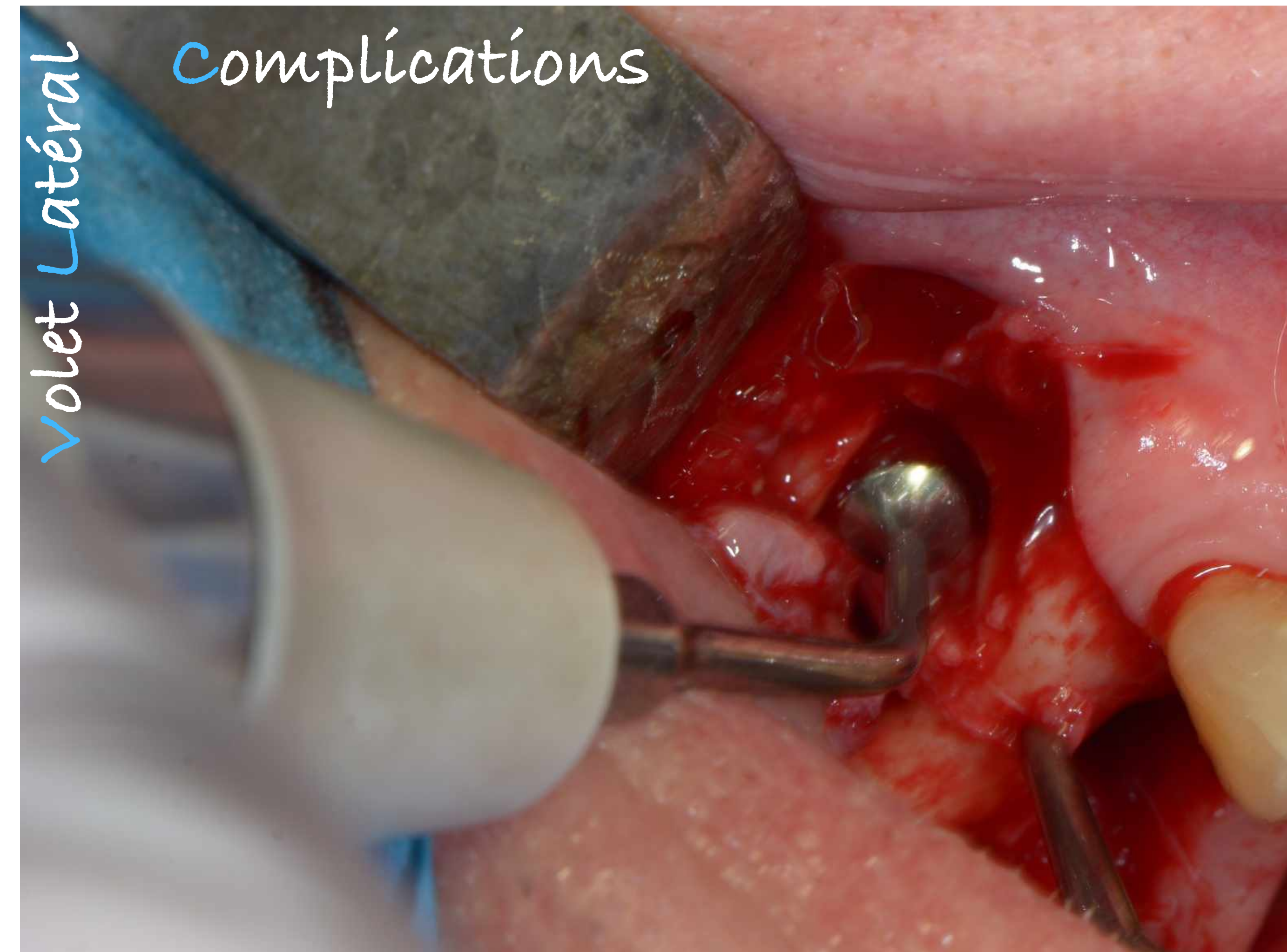
volet latéral

Complications

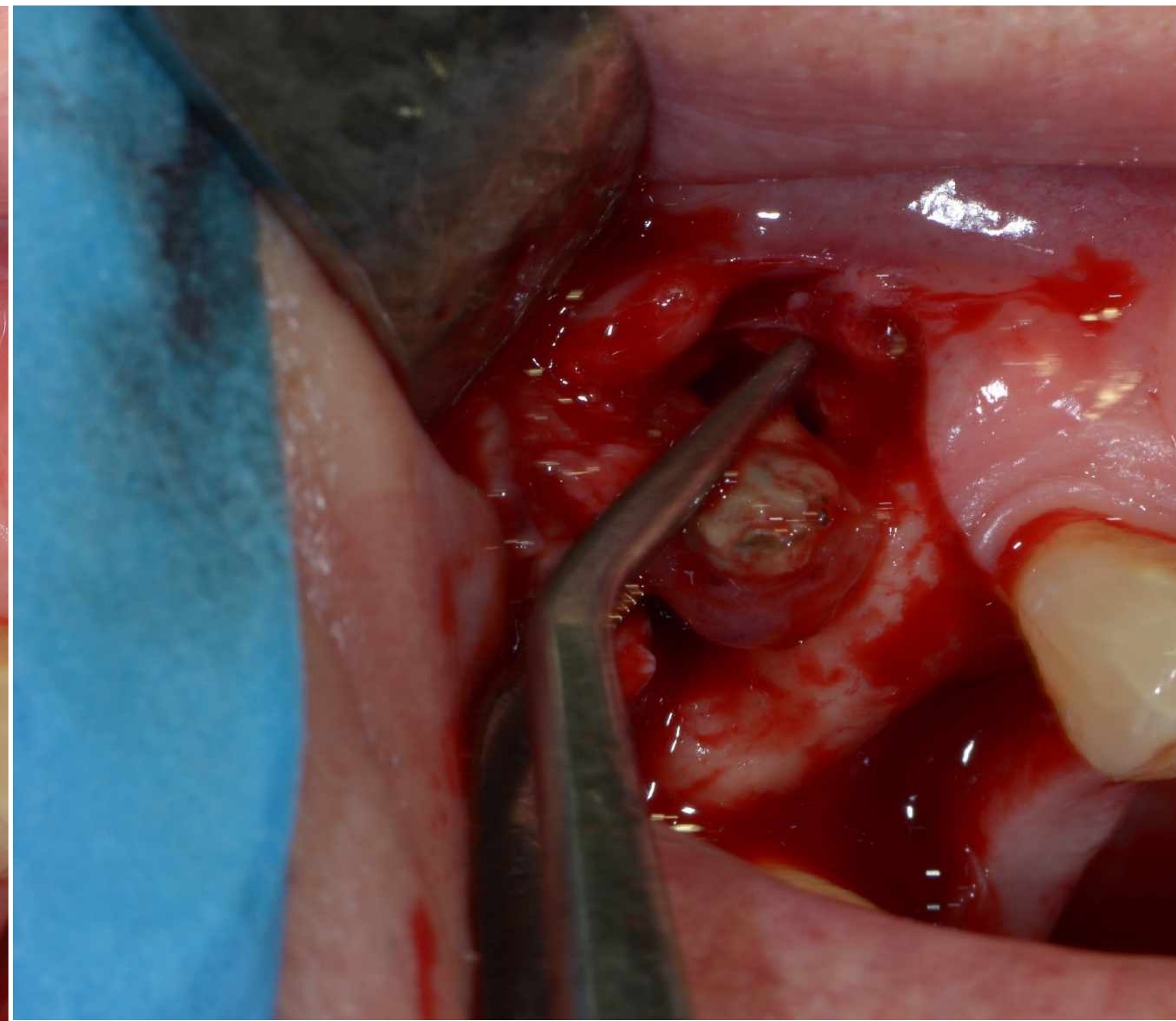


Racine résiduelle projetée dans le sinus



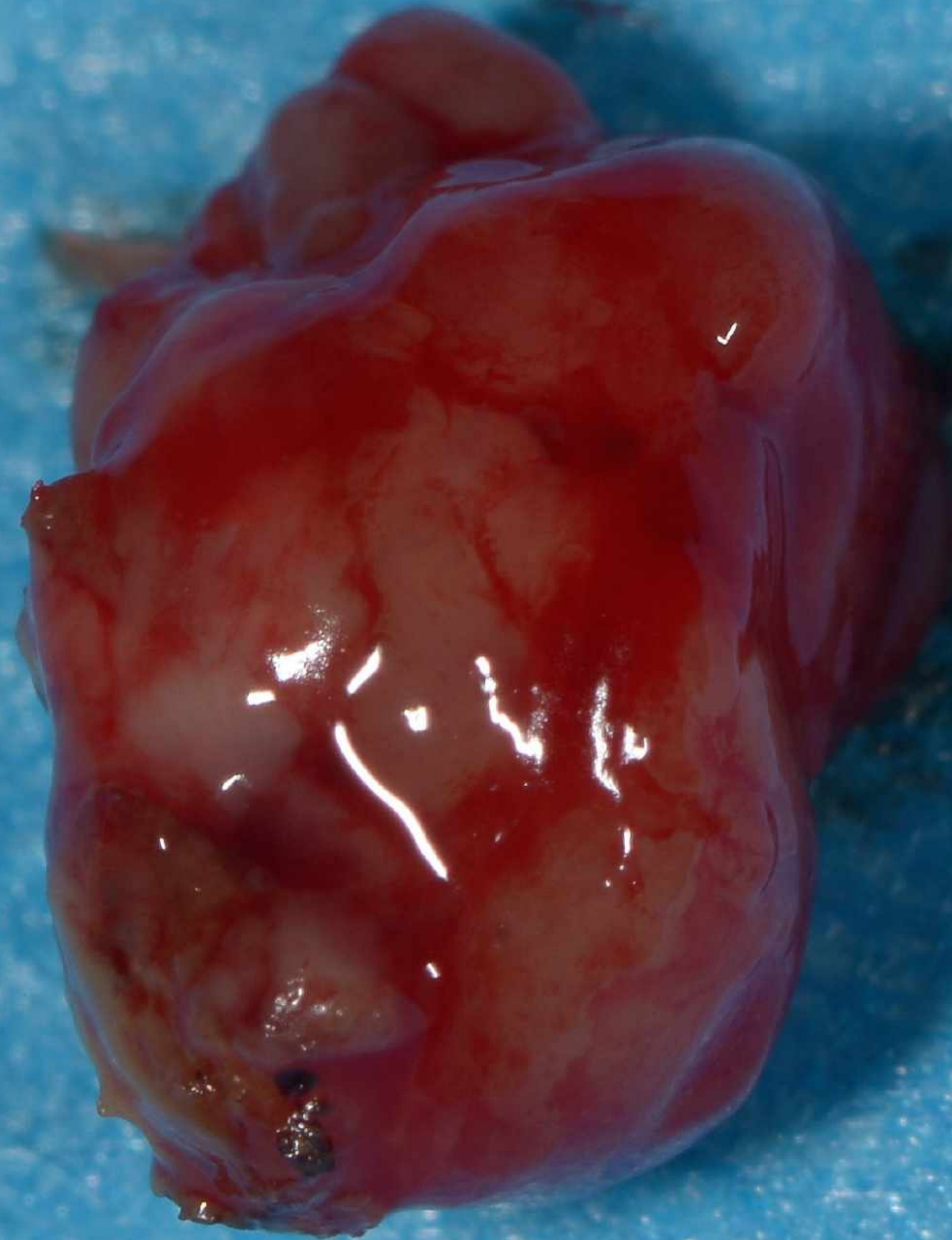

Elevation de la membrane



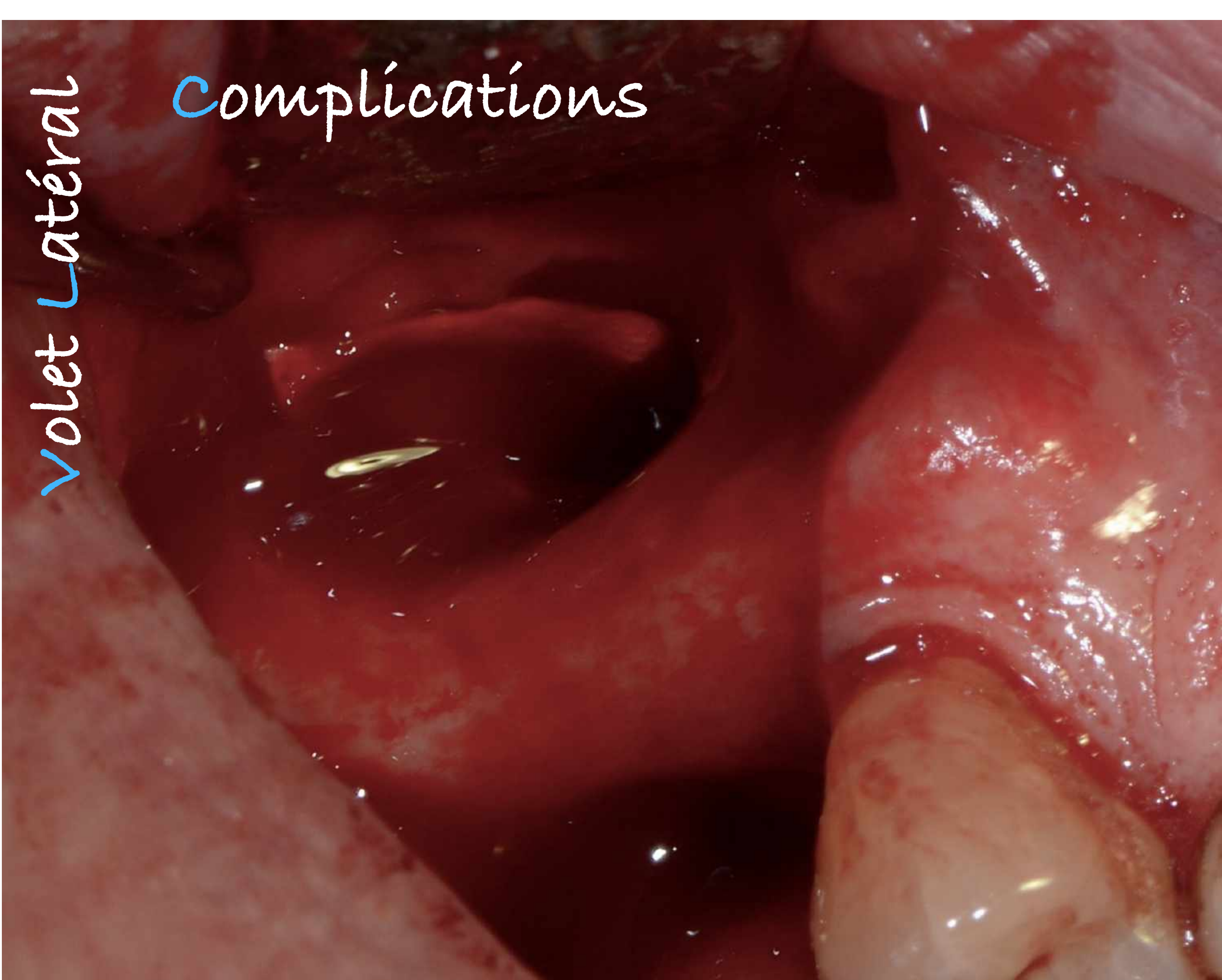
Libération du débris radiculaire
encapsulé

Complications

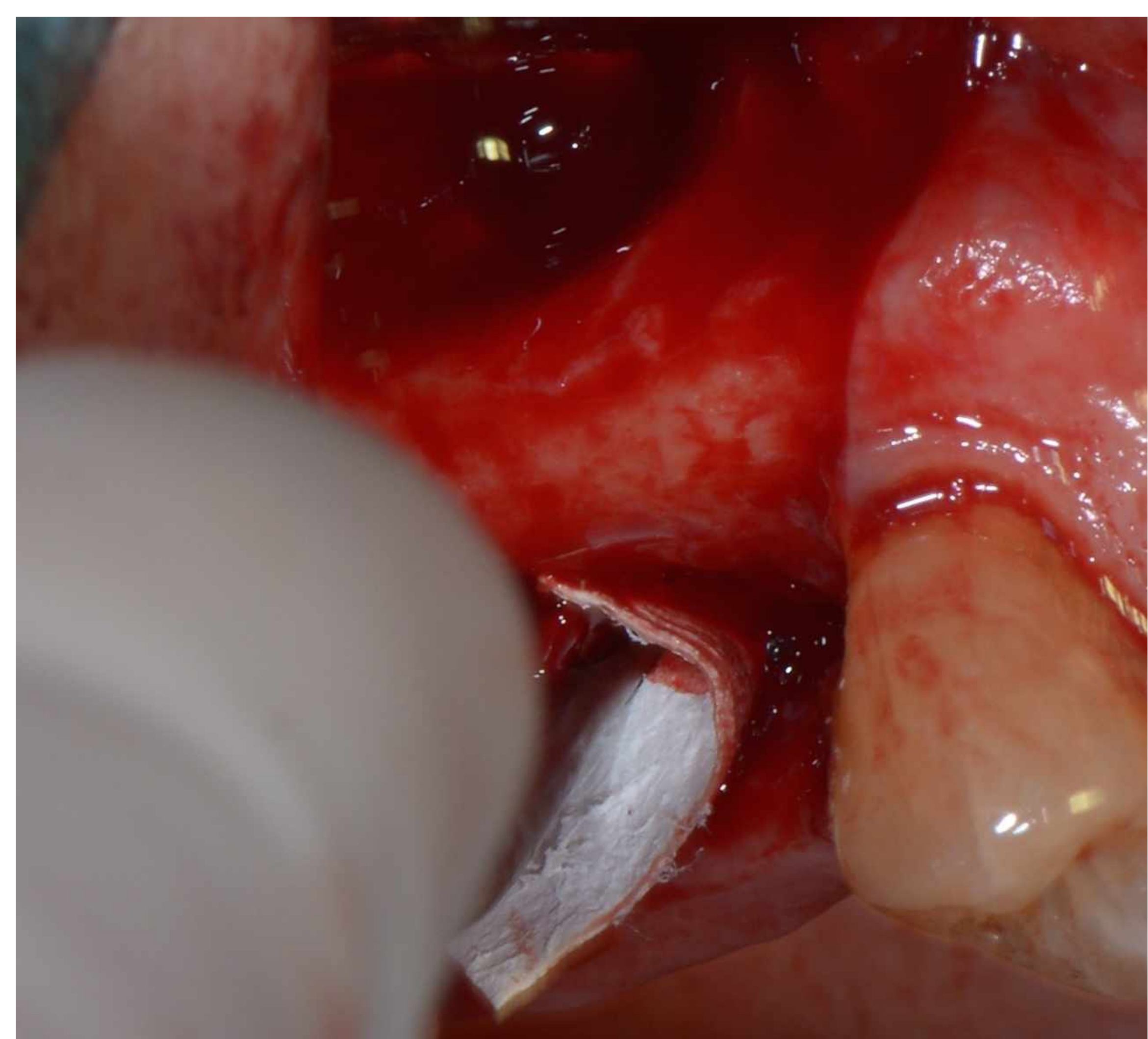


Pièce opératoire

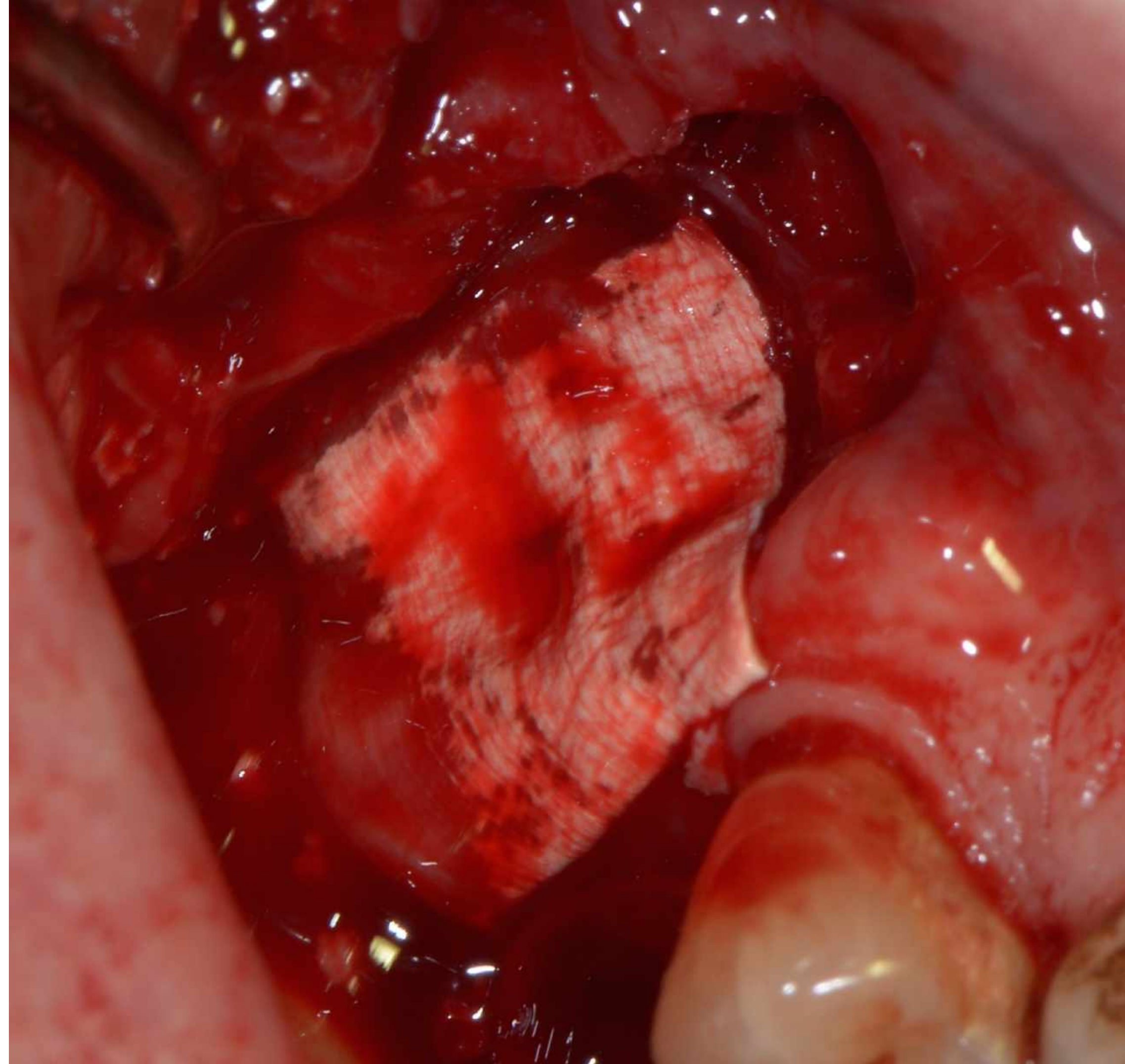
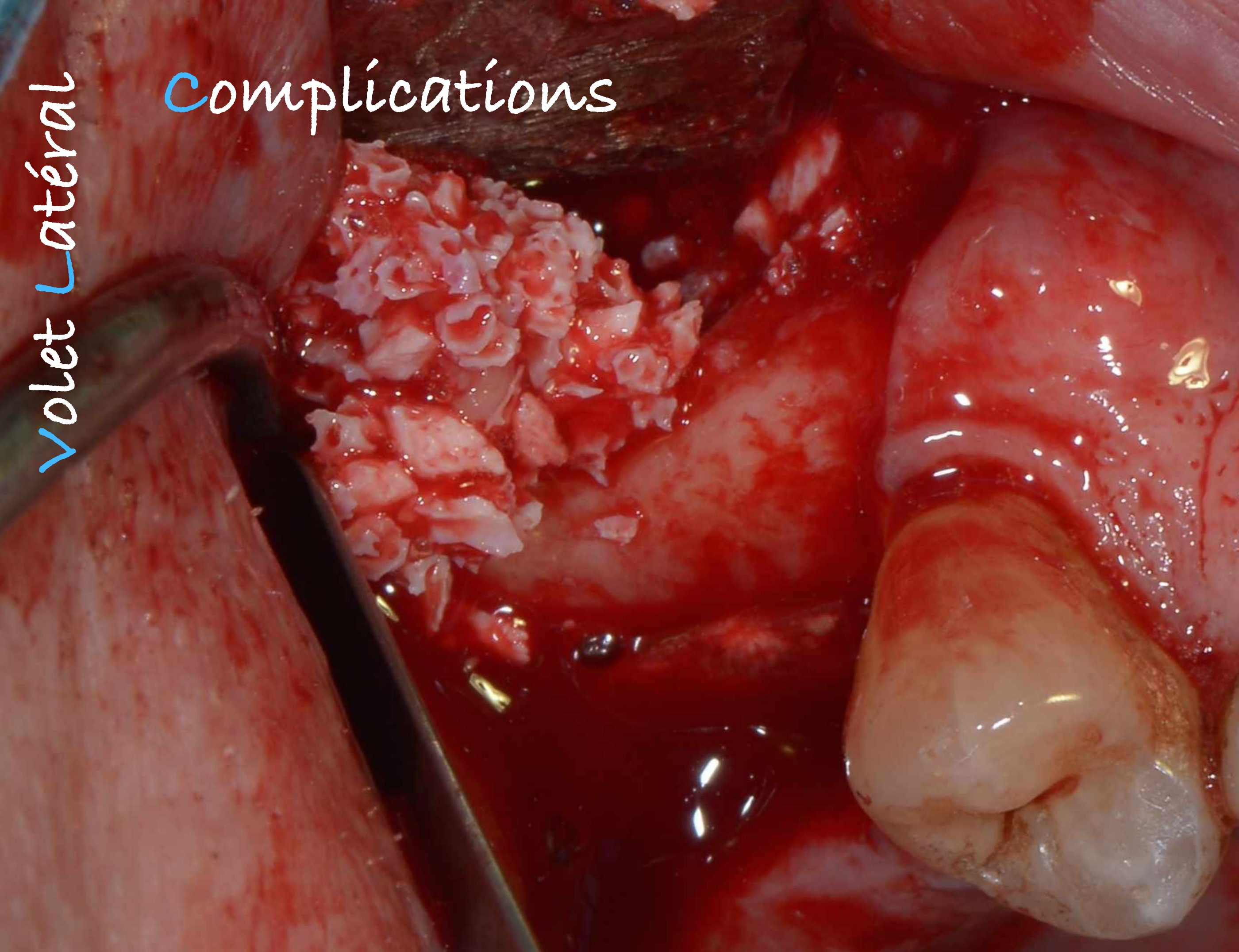
Racine résiduelle
encapsulée



Membrane collagène
contre membrane sinusienne



Membrane collagène
en palatin
(Fenestration osseuse)



Les complications post-opératoires

Perte des implants : 1 à 10%

Sinusites post-opératoires traitées par ATB : 5%

Sinusites post-opératoires traitées endoscopie et drainage : 1,6%

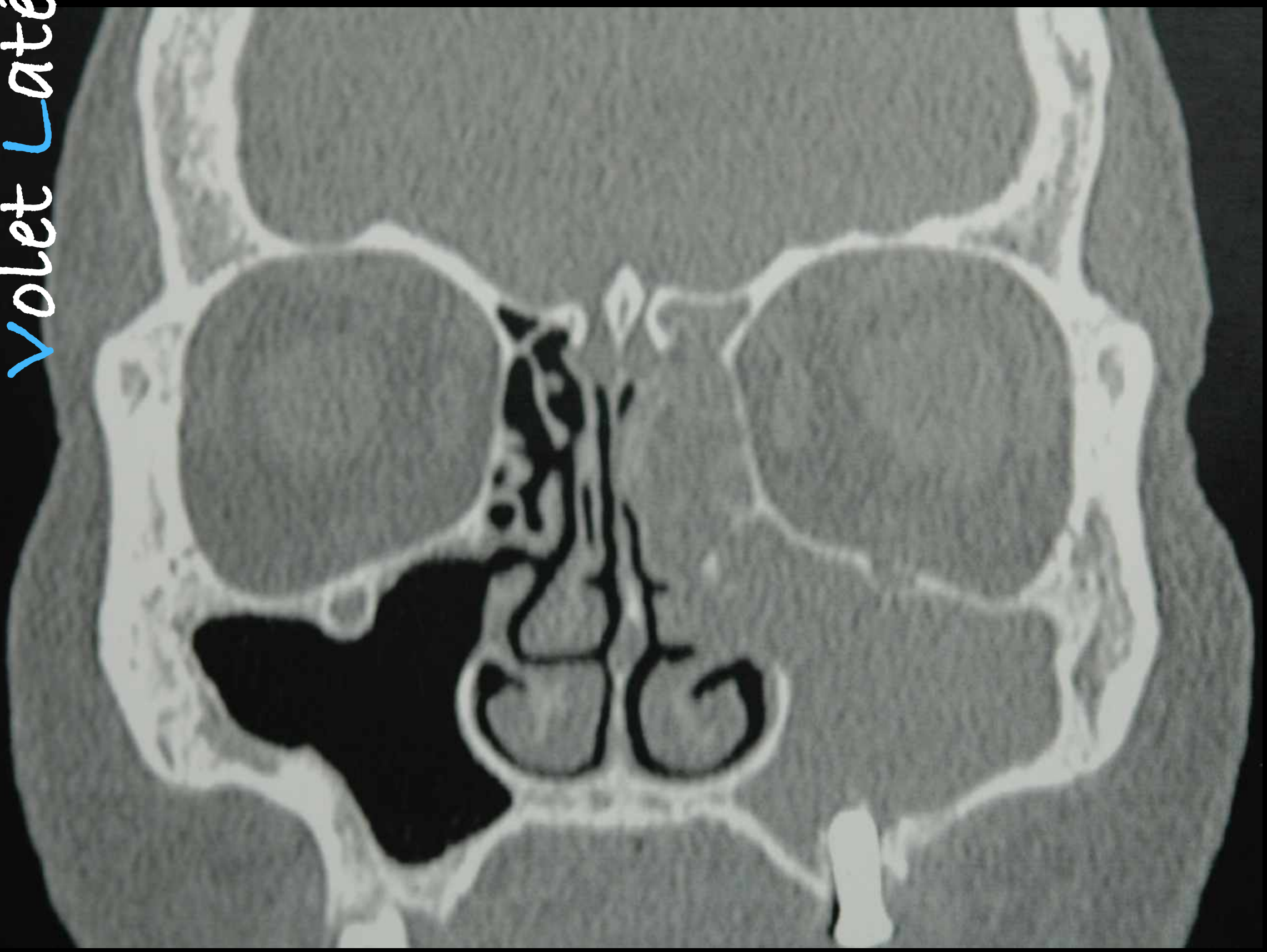
Augmentation significative quand
greffe Autogène et Fumeur !

Strietzel FP. Sinus floor elevation and augmentation. Evidence-based analysis of prognosis and risk factors. Mund Kiefer Gesichtschir. 2004 Mar;8(2):93-105. Epub 2004 Feb 6.

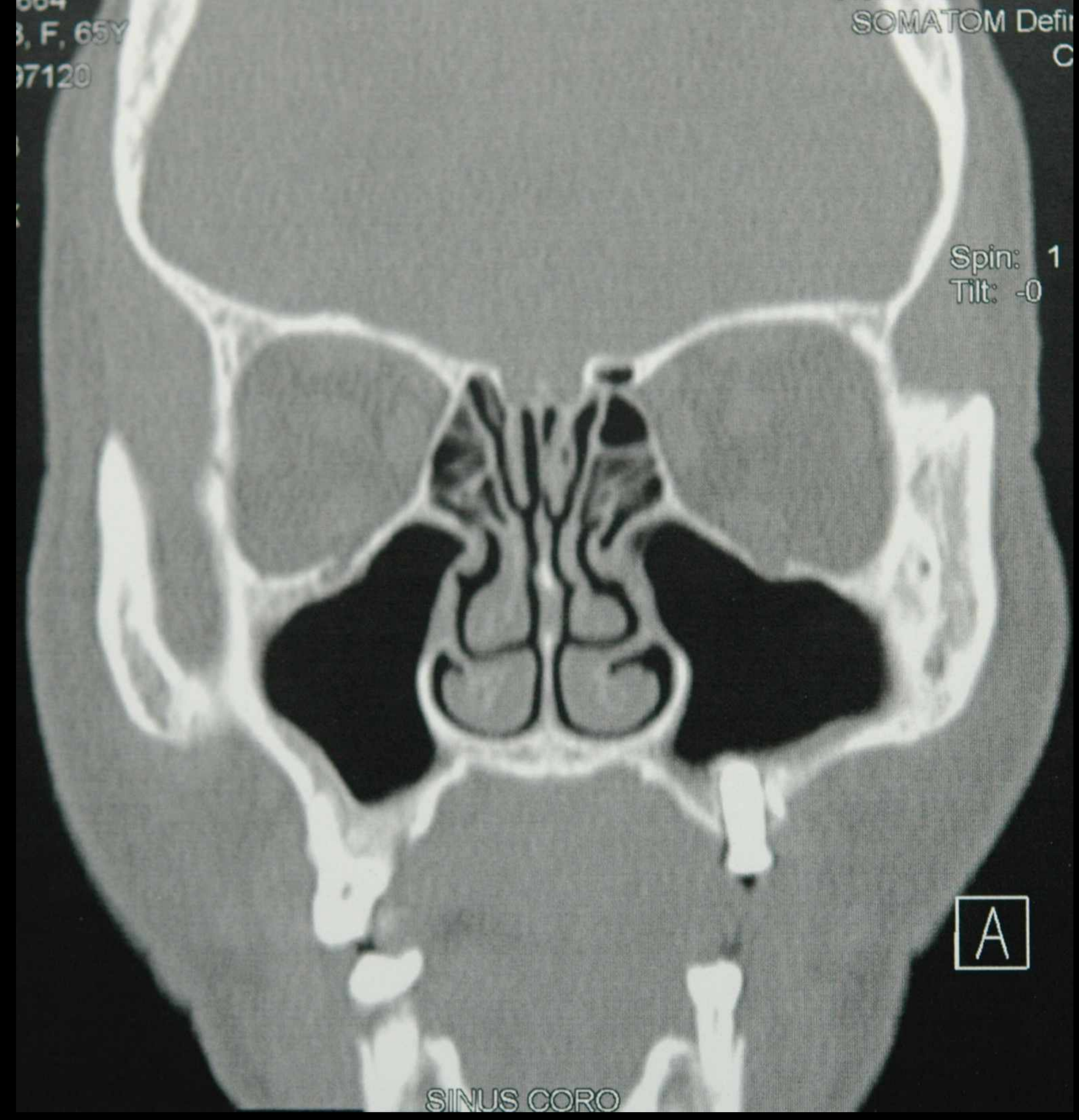
Barone A et al. A clinical study of the outcomes and complications associated with maxillary sinus augmentation. Int J Oral Maxillofac Implants. 2006 jan-feb;21(1):81-5

Volet Latéral

Complications

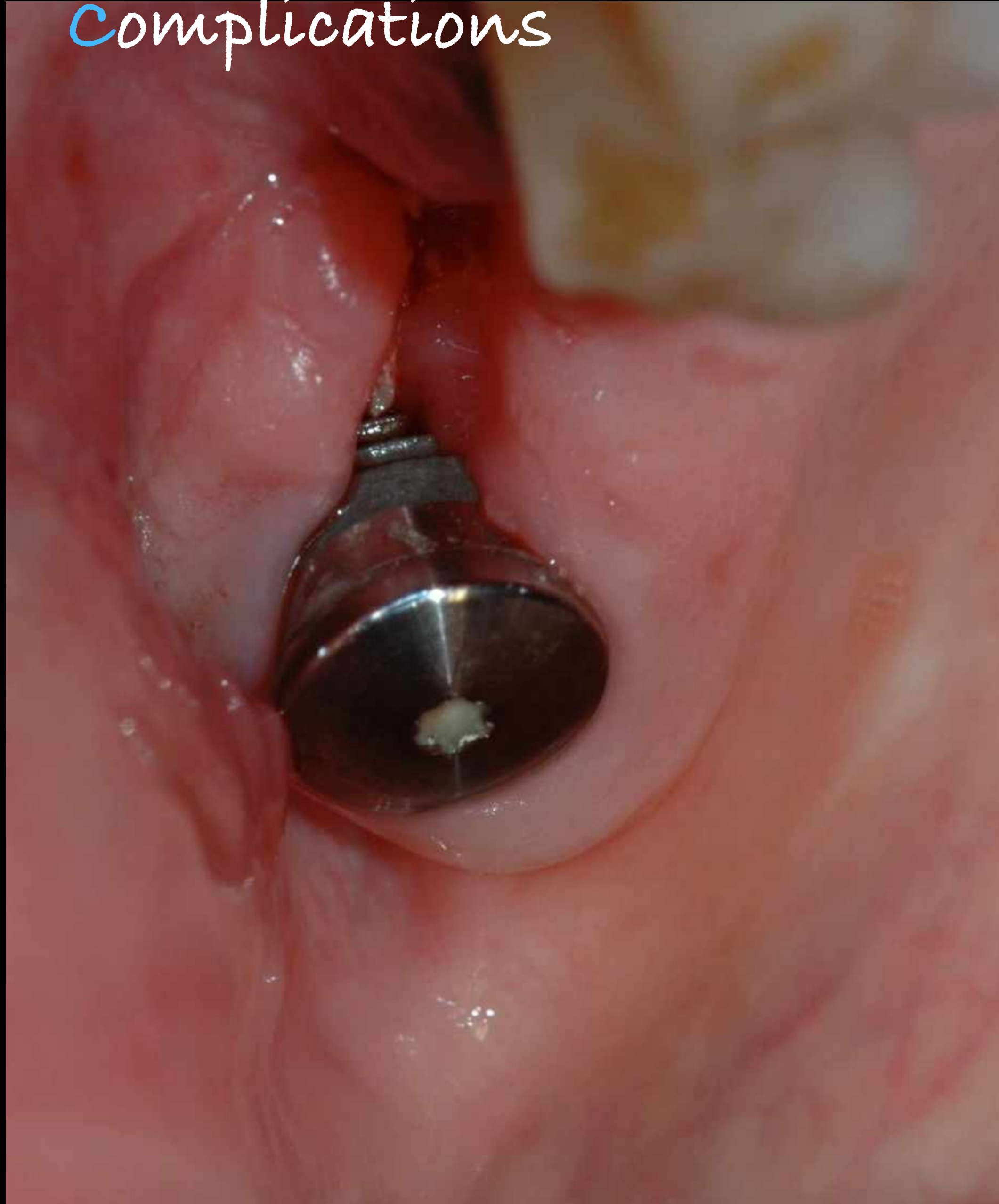

sinusite aigüe



Volet Latéral

Complications

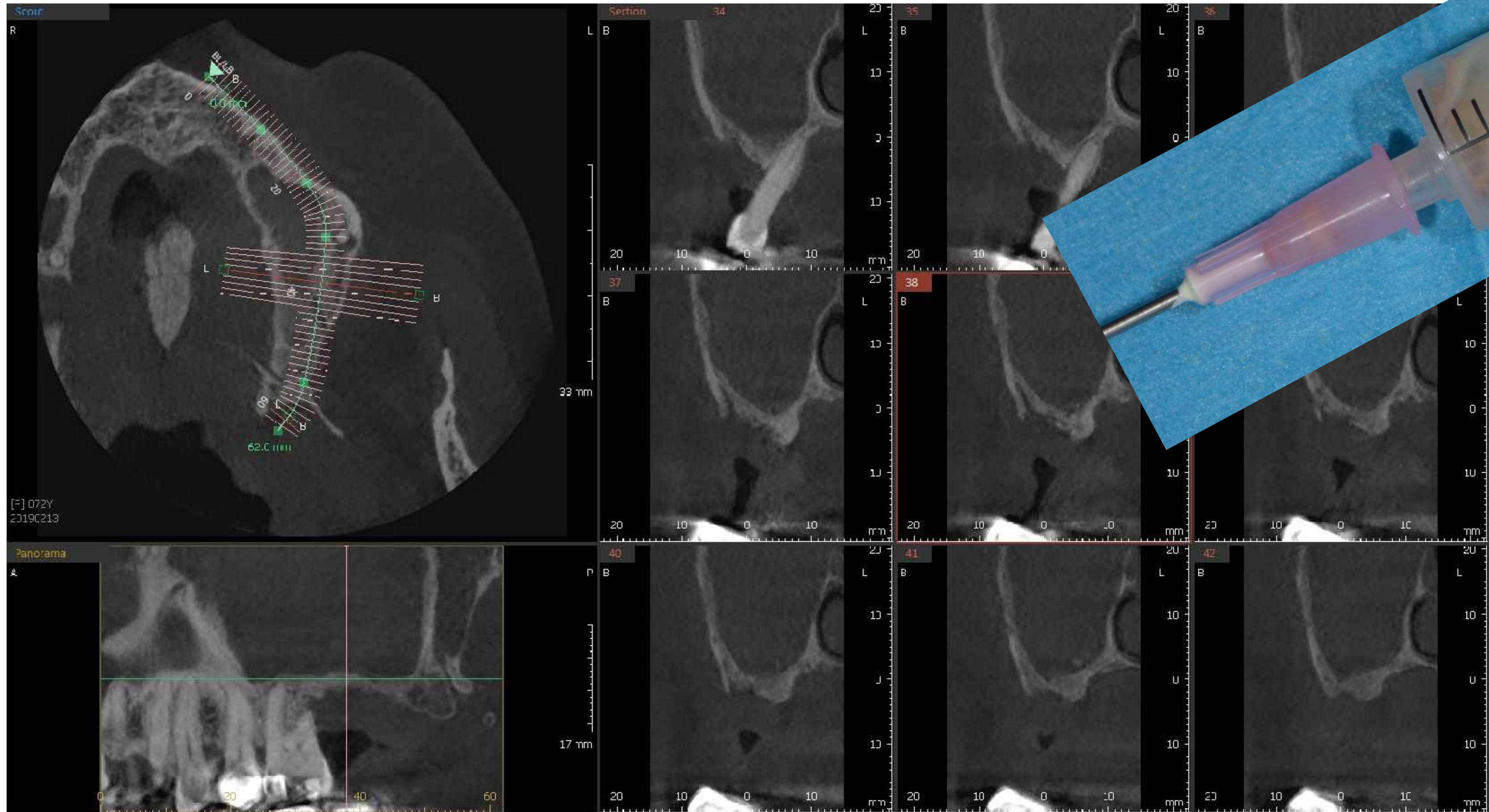


Complications:

infection du lambeau
sinusite aigüe

Suppurations le long de l'implant

Un doute pendant la chirurgie ?



Augmentin 15j
Solupred 3j

Aturgyl 4/J
Prorhinel

Resolution de la complication :

Allergie Augmentin

izilox 400mg/j 12 jours

Prorhinel 5 fois/ jour

Pivalone 4 pulverisations / jour

AVOIR UN BON ORL dans vos relations !

Resolution de la complication entre 15j et 1 mois:

Protocole Valentini

ATBio 15 jours Amox + Aclav ou Ciflox

Anesthésie locale

Dépose suture et réouverture

Dépose membrane

Curetage Biomatériau couleur vert (infecté)

Nouveau comblement Biomatériau + membrane

Grefe par volet latéral = technique fiable
Recul scientifique +++

Est-il plus rassurant de **ne rien voir** ?

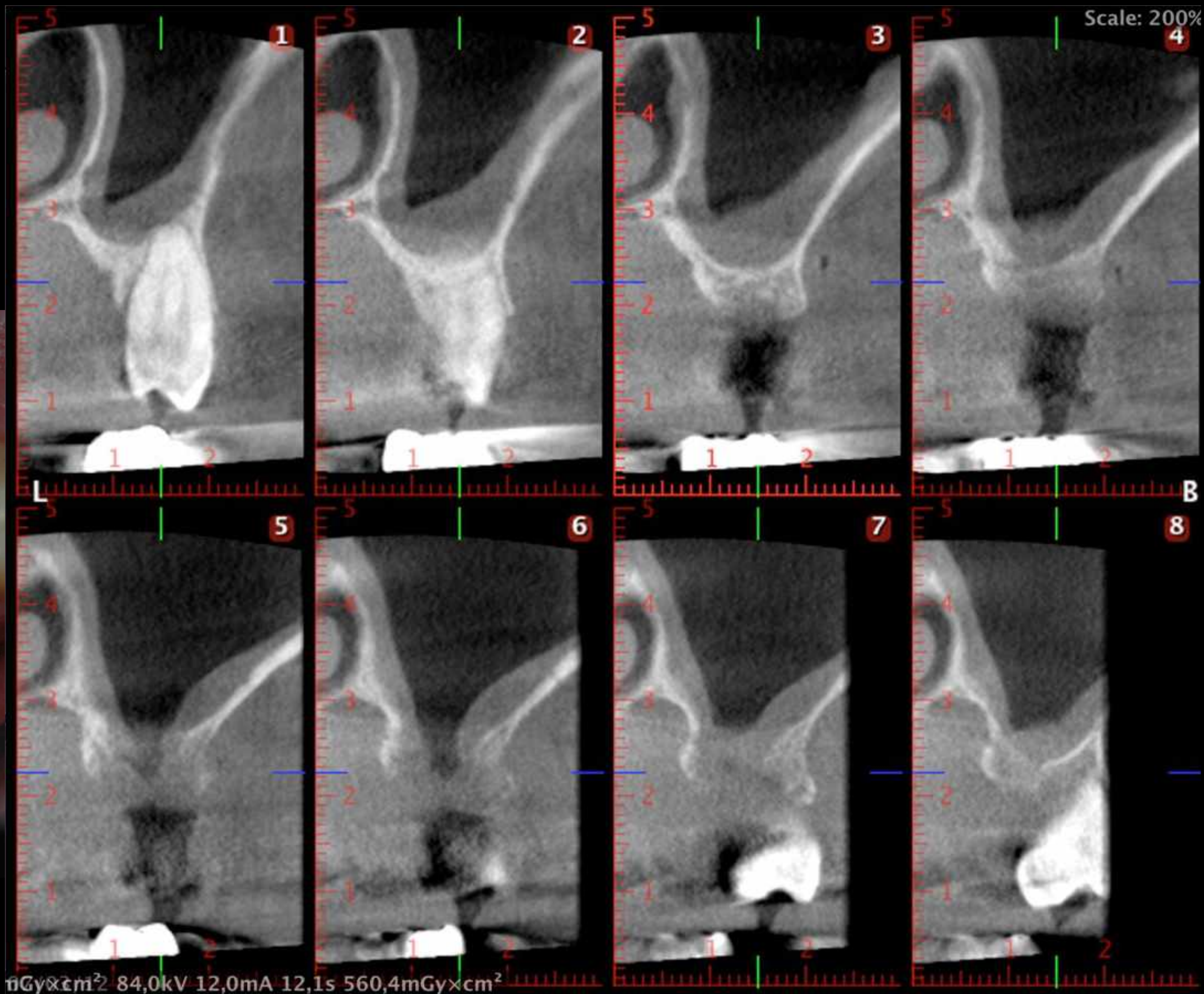
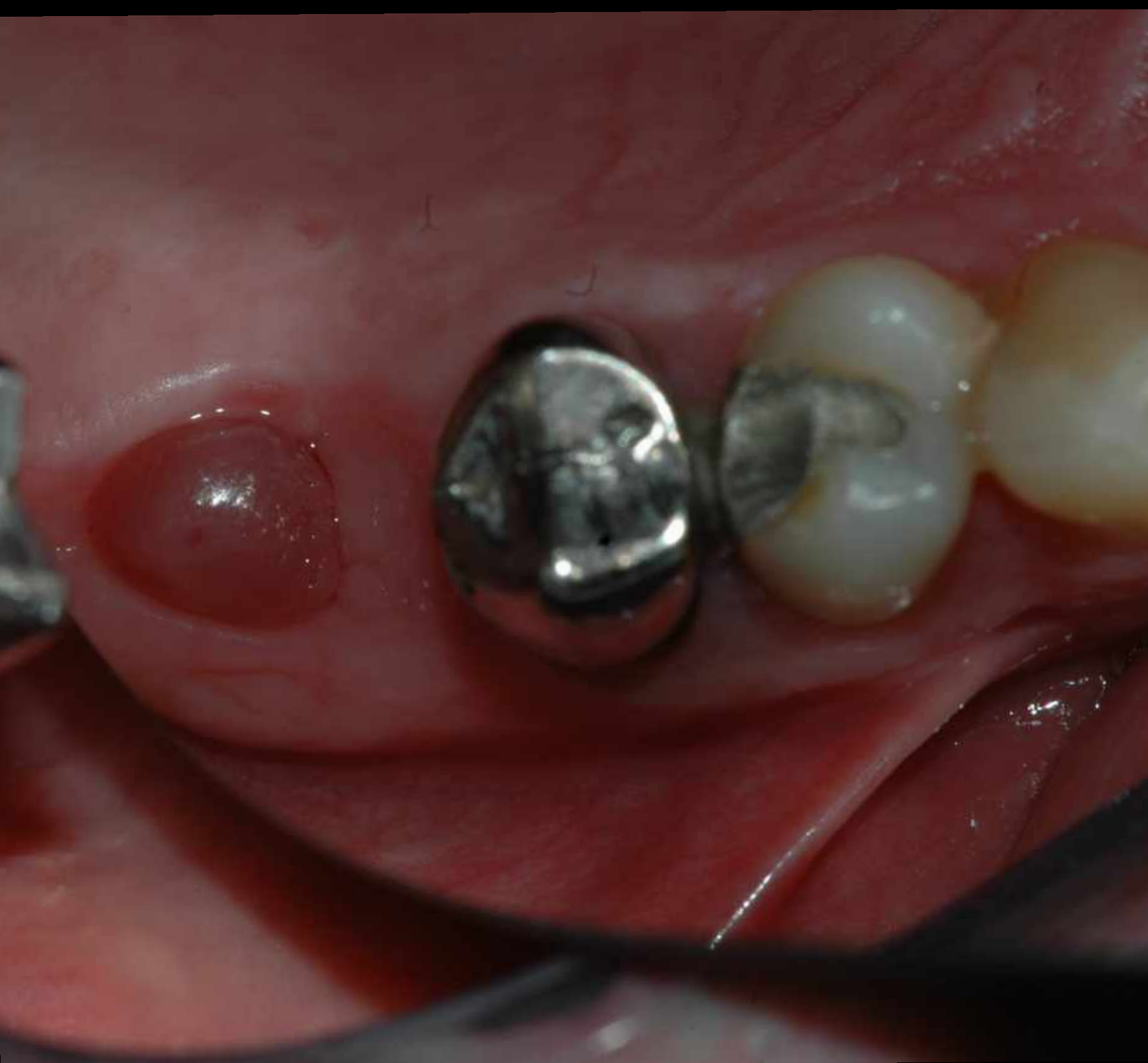Complications du volet latéral identiques à celles
d'une technique de Summers modifiée !

Qualité de l'os et taux de succès implantaire
Technique praticien dépendant

Savoir passer la main si complication (2% des cas)

Décision thérapeutique raisonnée : réfléchir aux alternatives

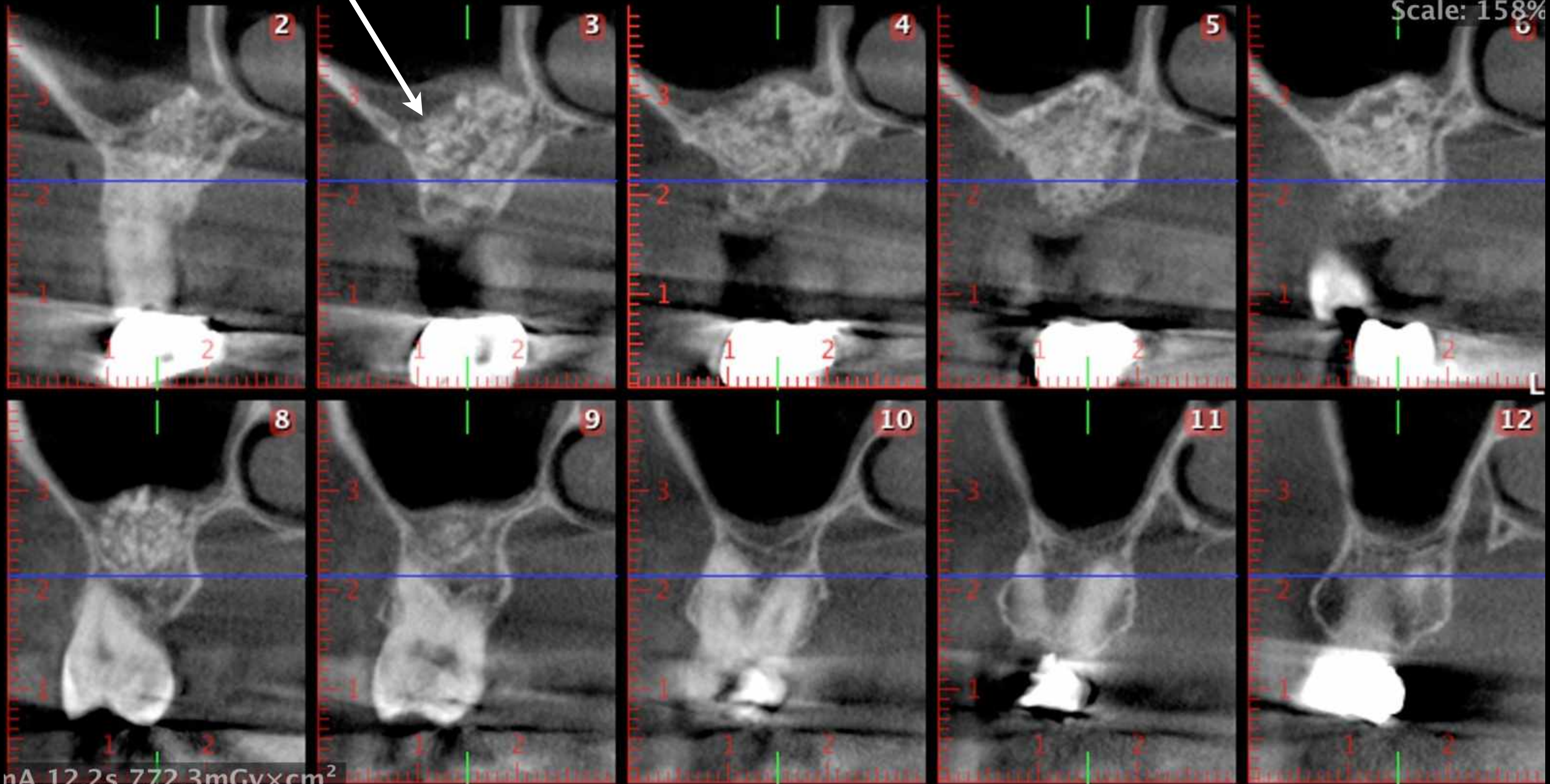
Traitement d'une CBS



Volet basculé

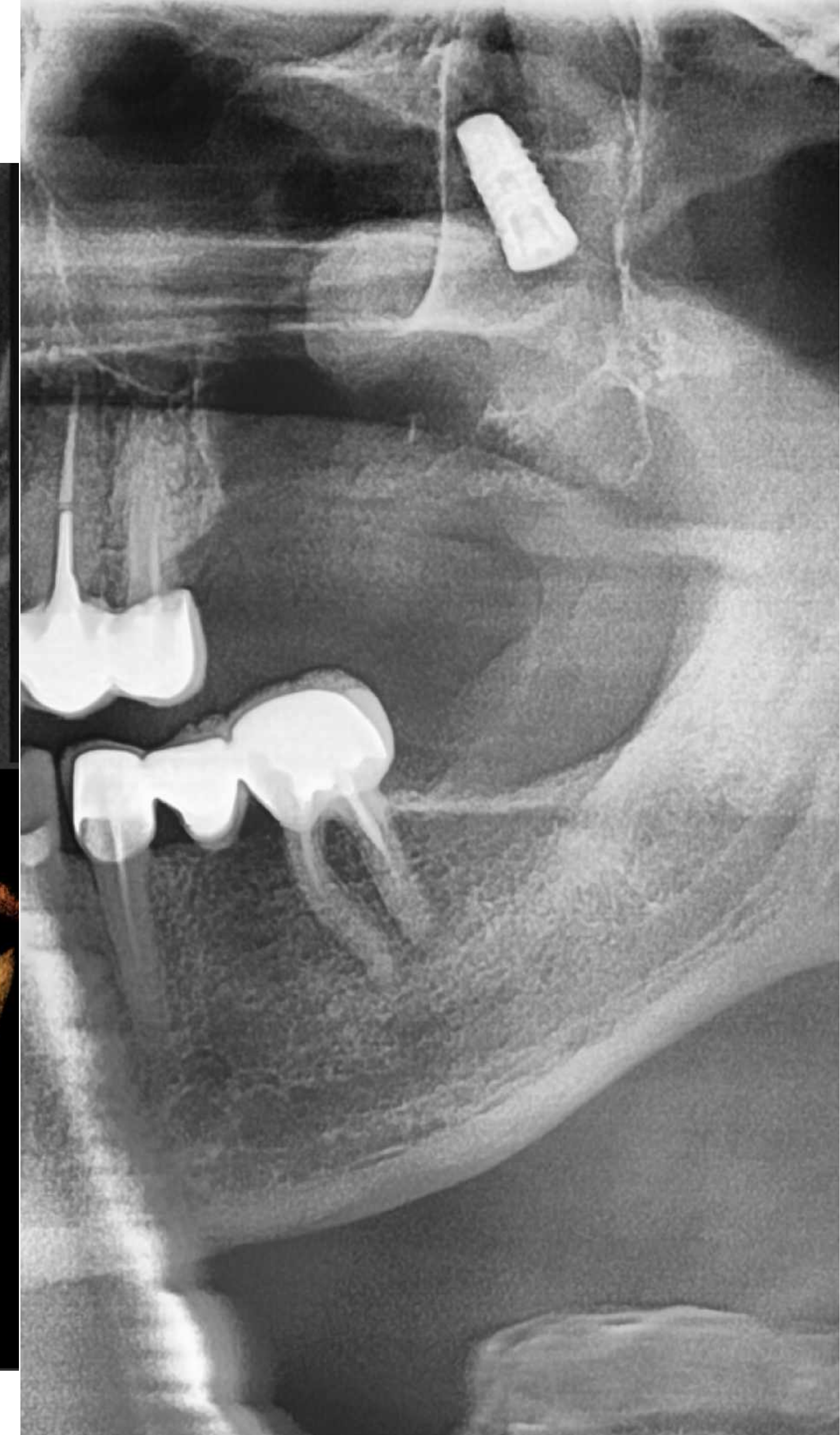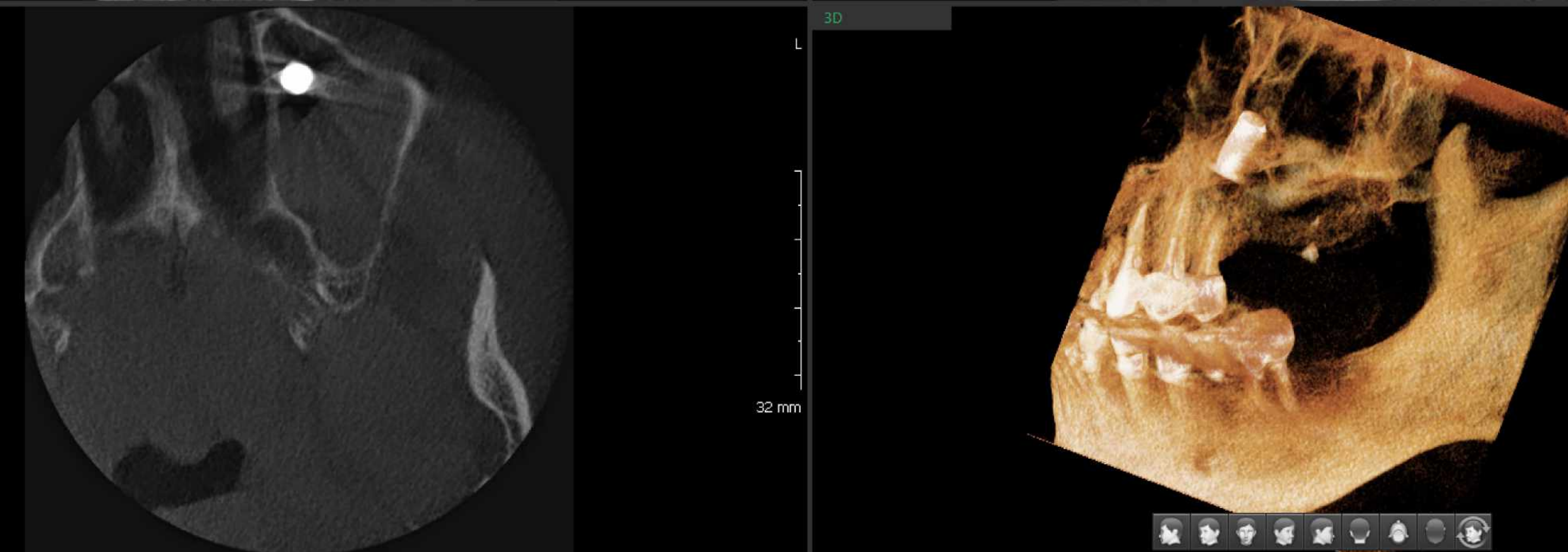
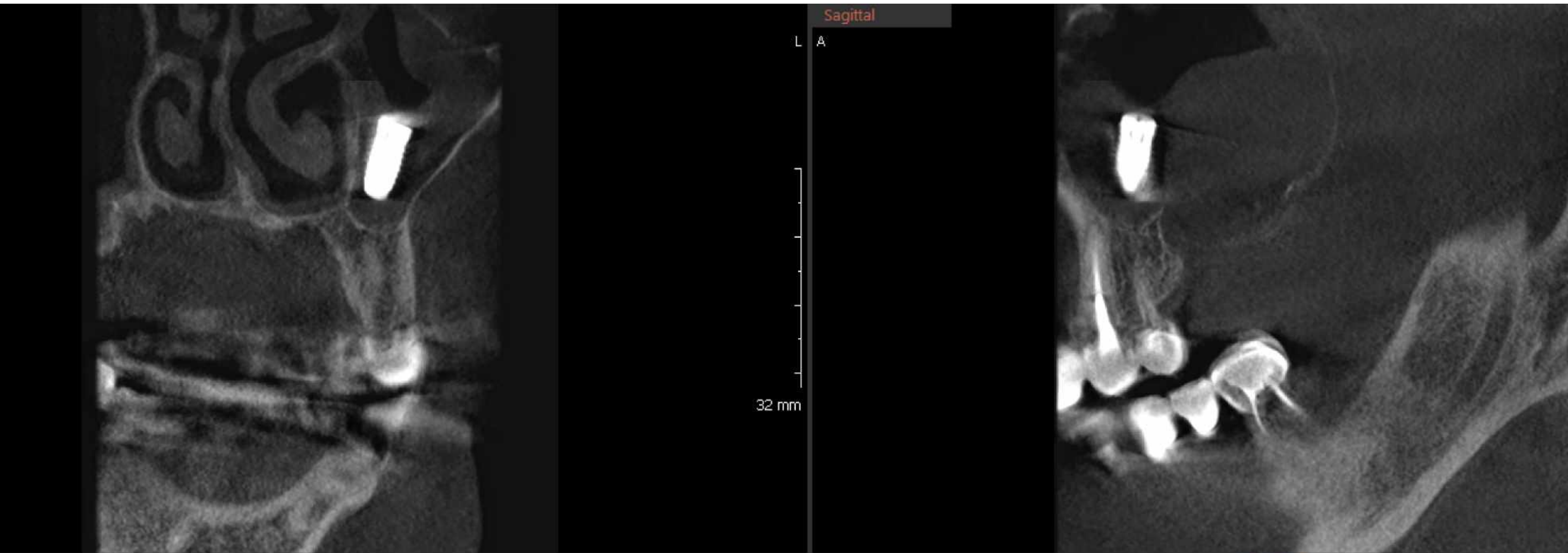


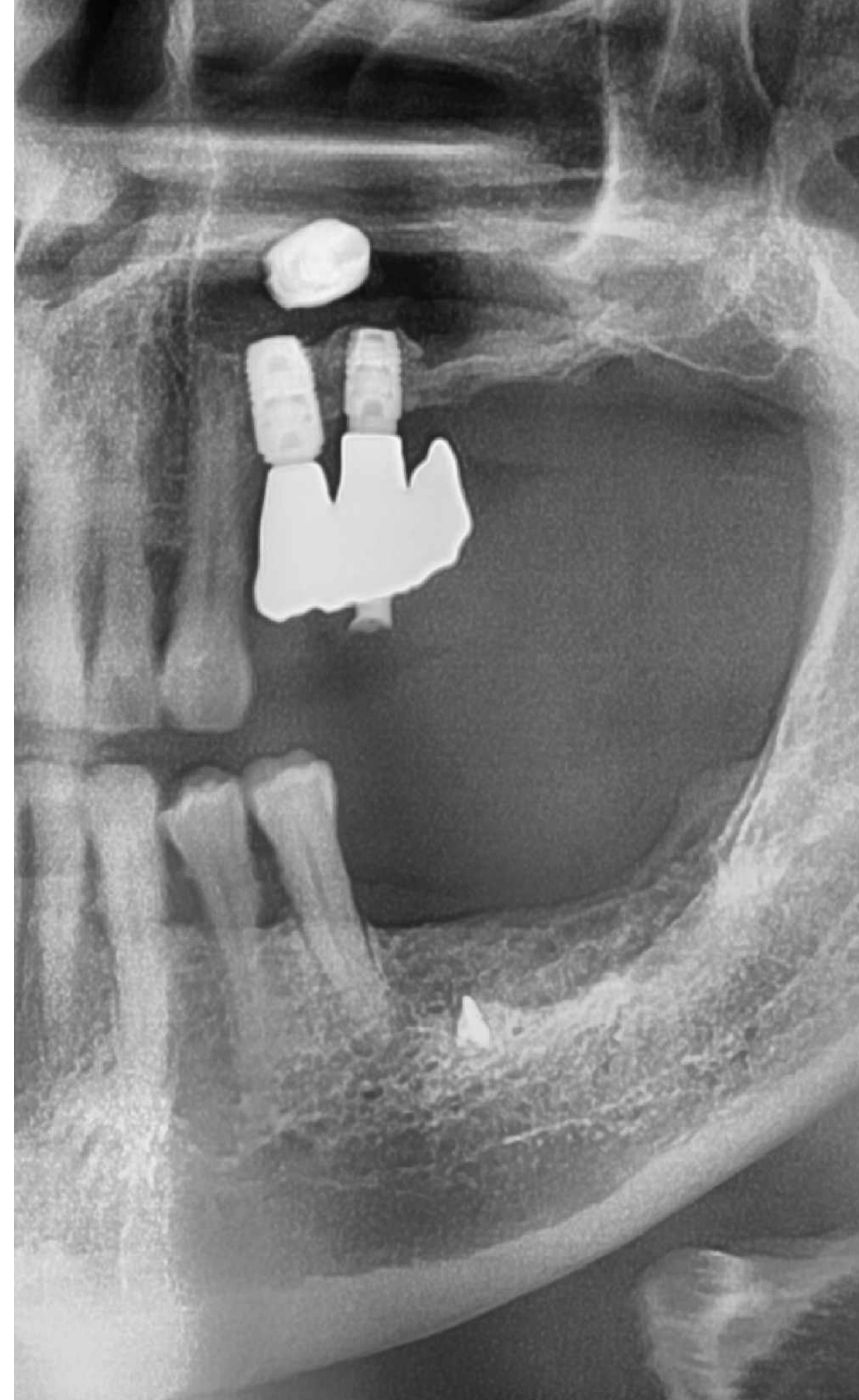
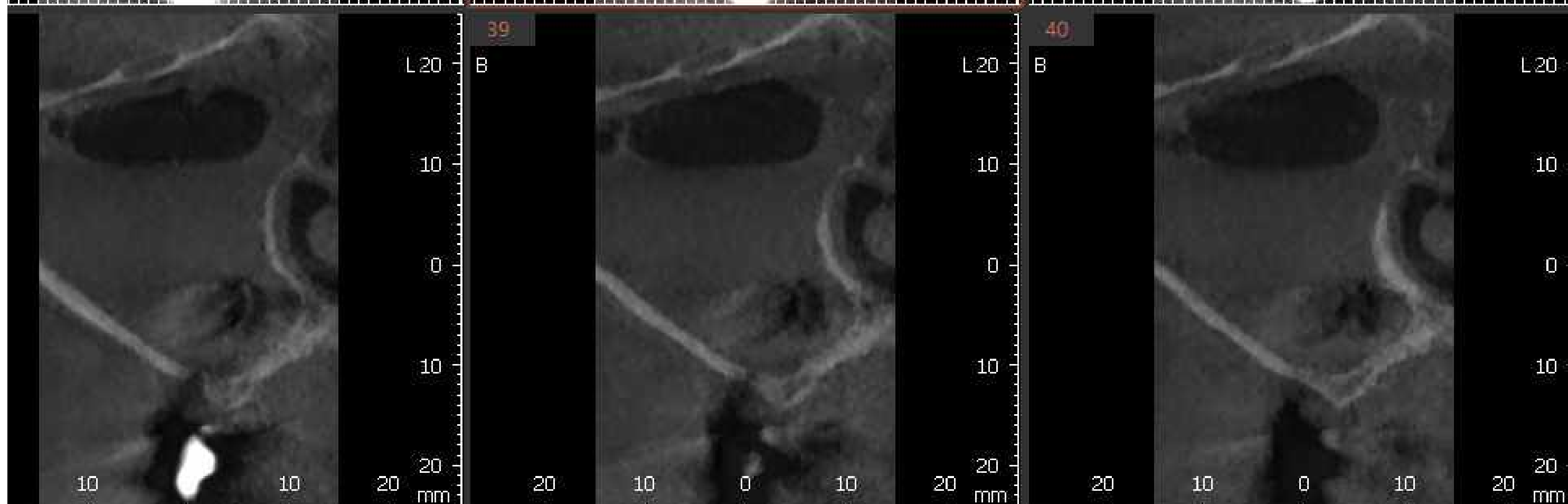
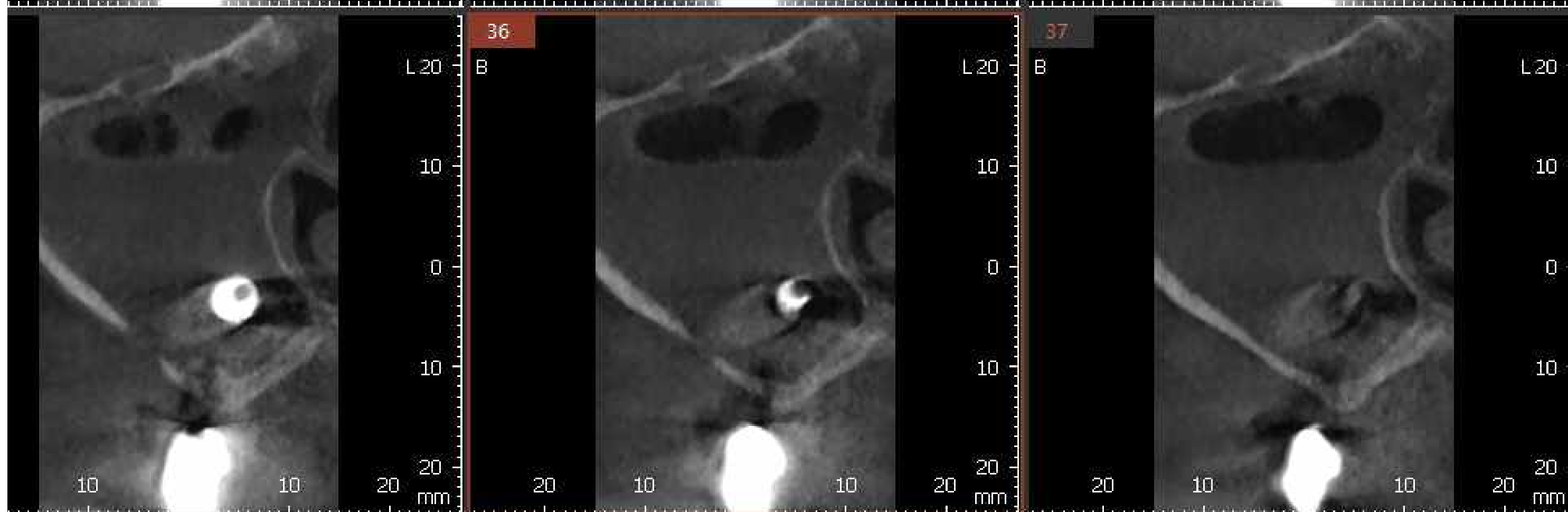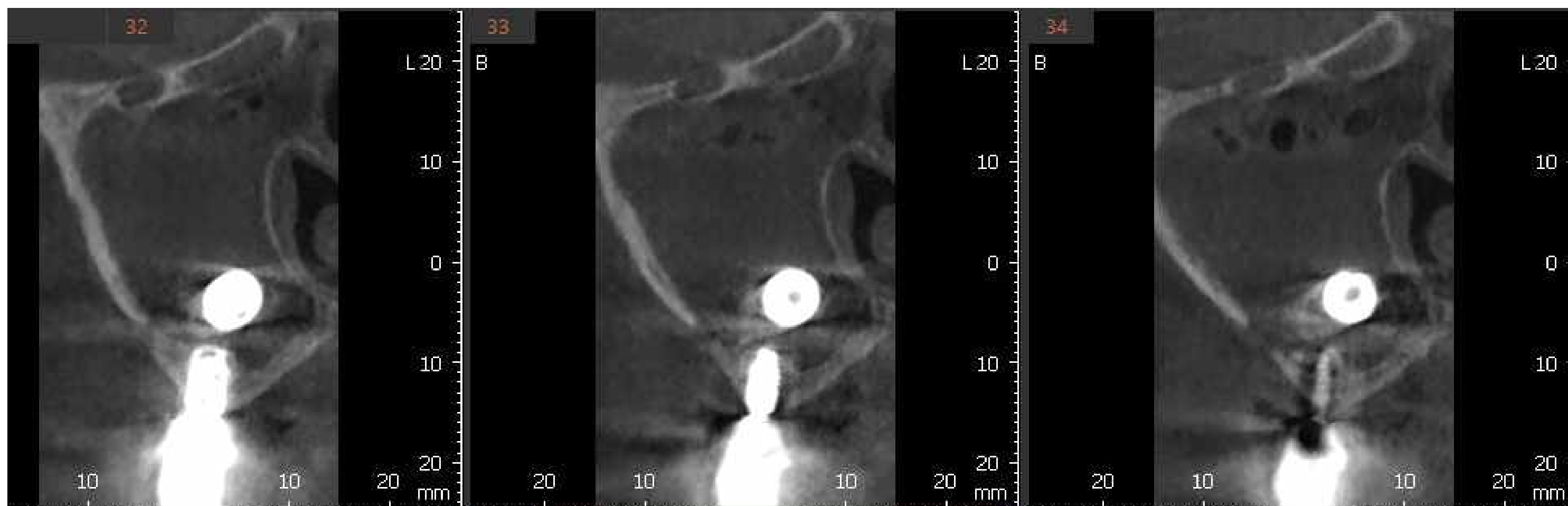Scale: 158%



nA 12,2s 772,3mGy×cm²

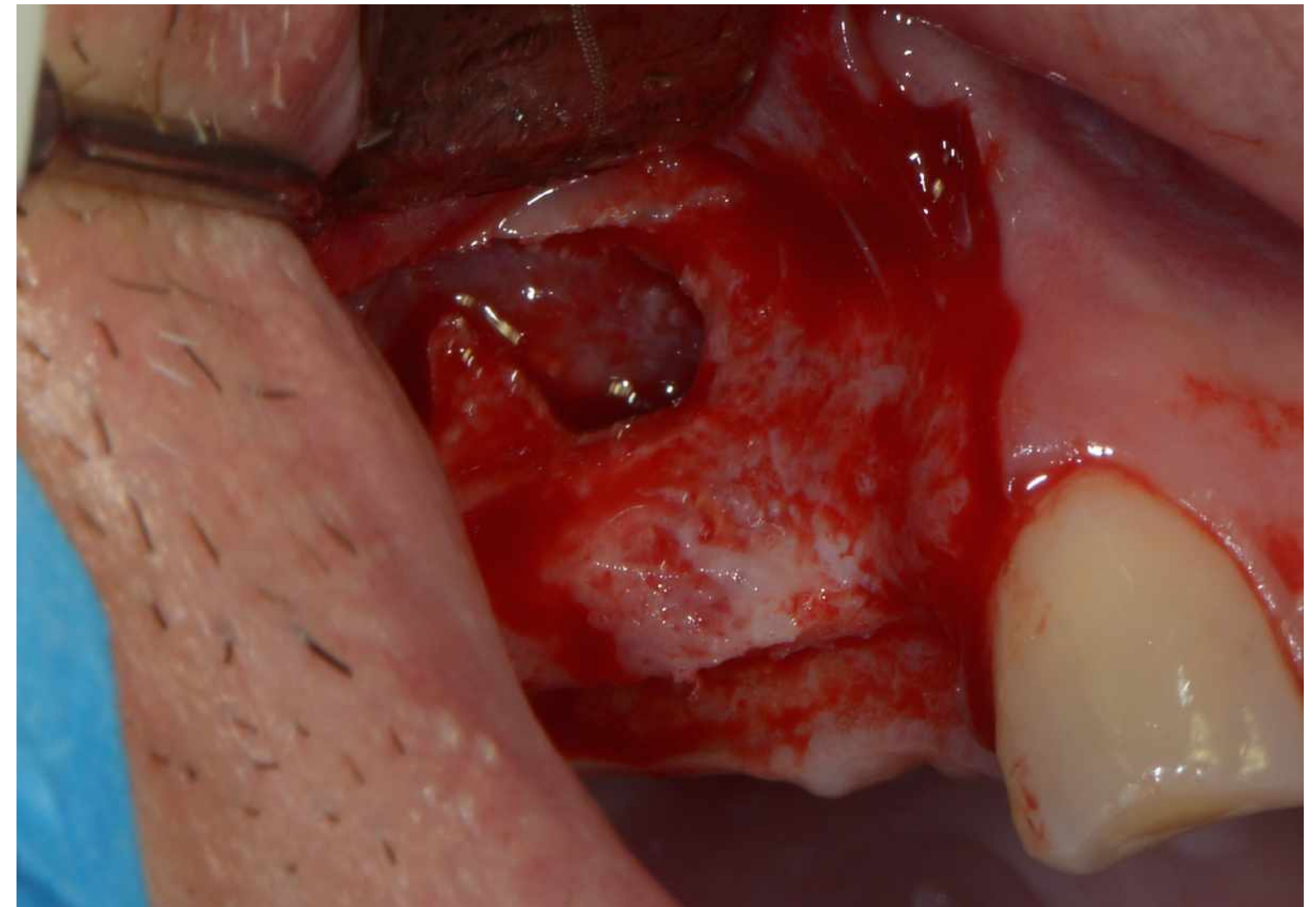
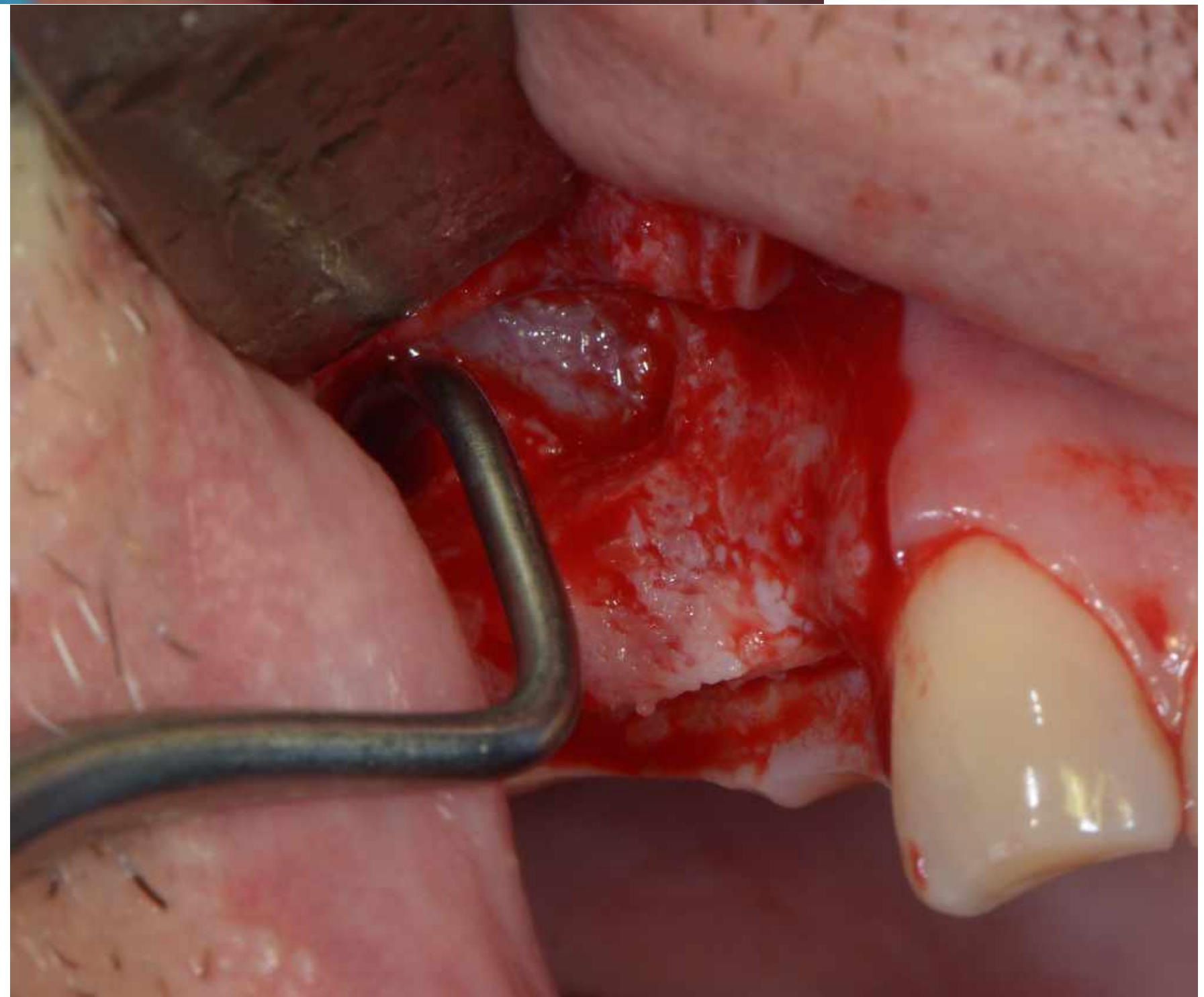
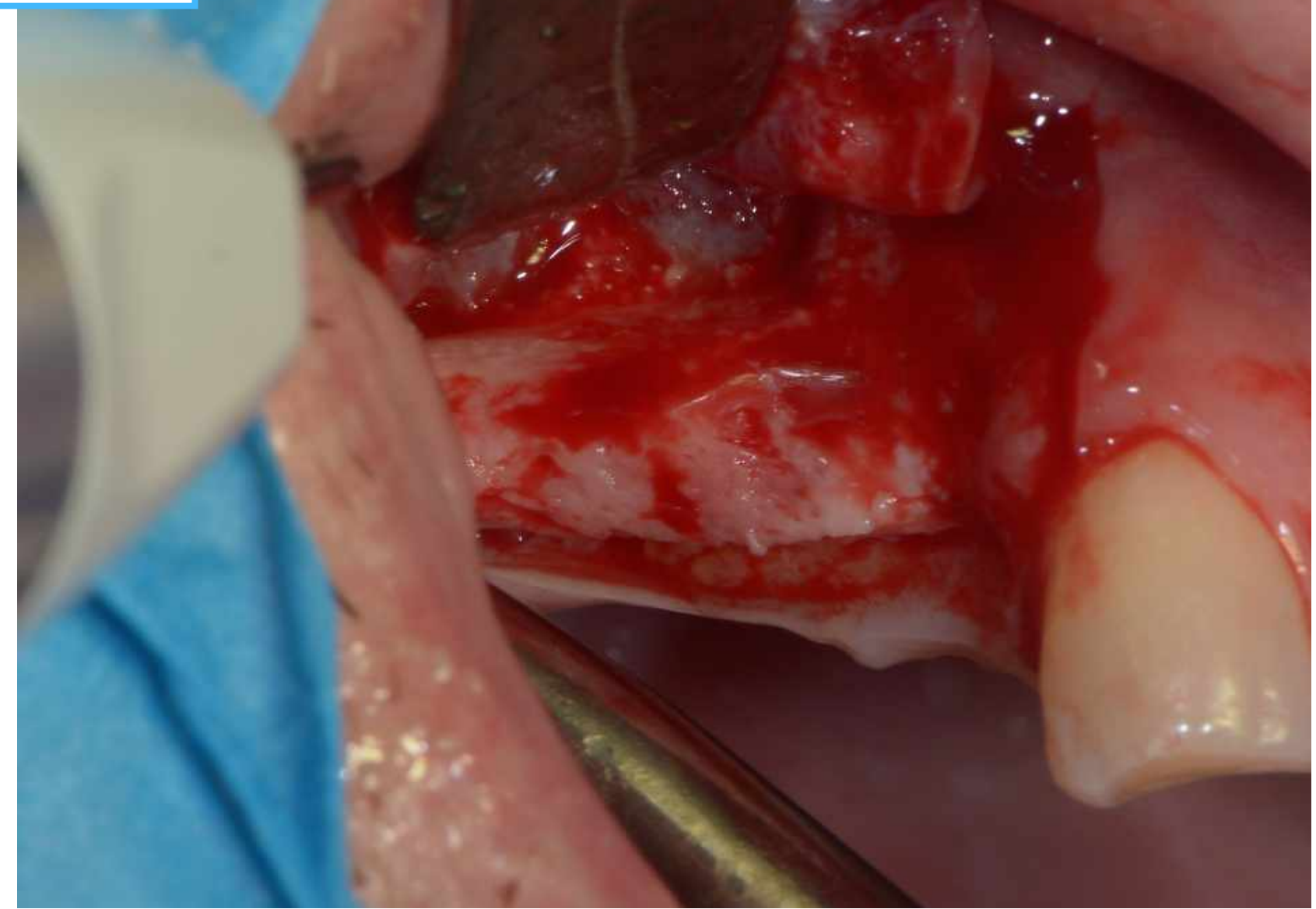
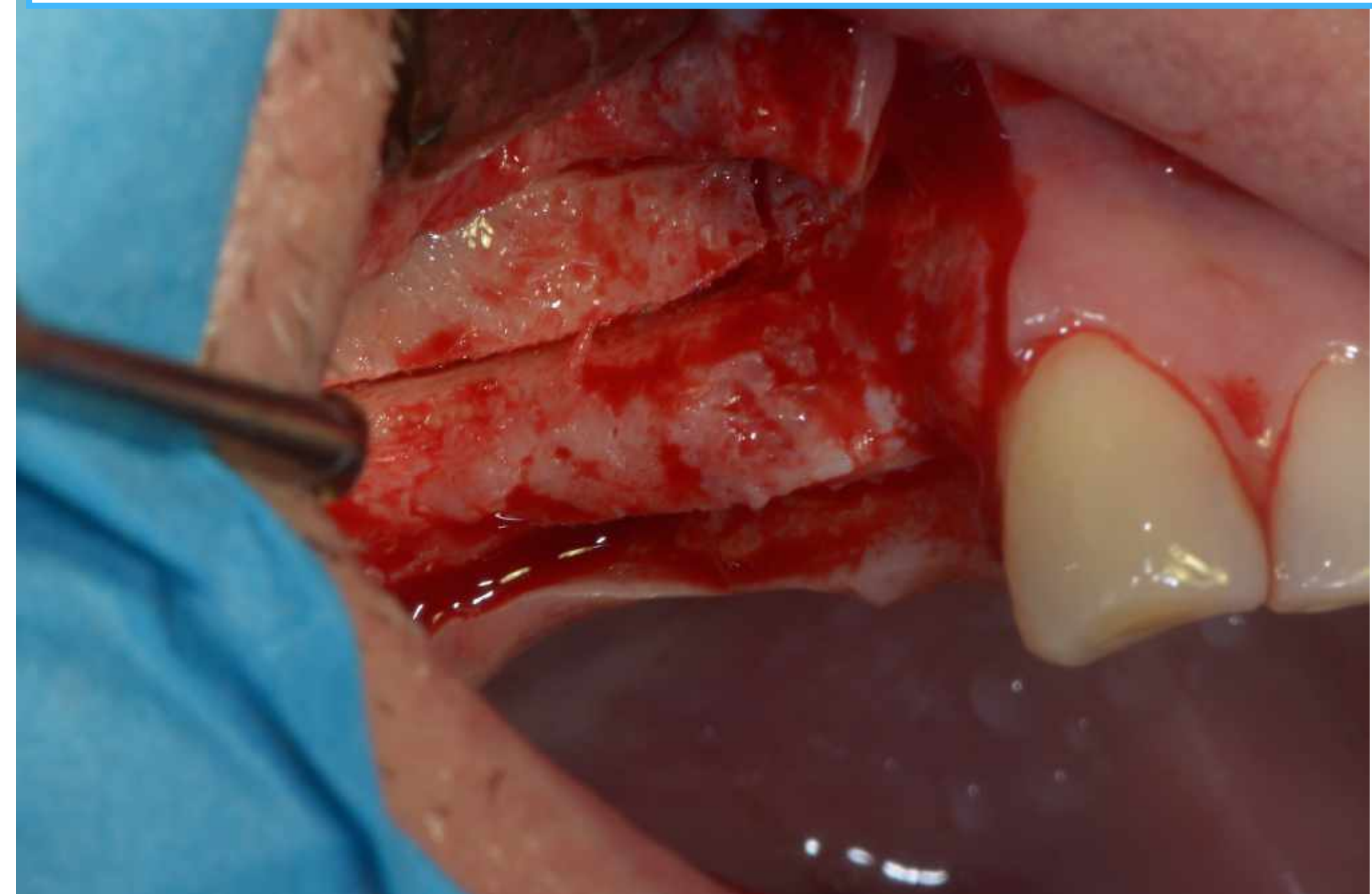
Projection dans le sinus

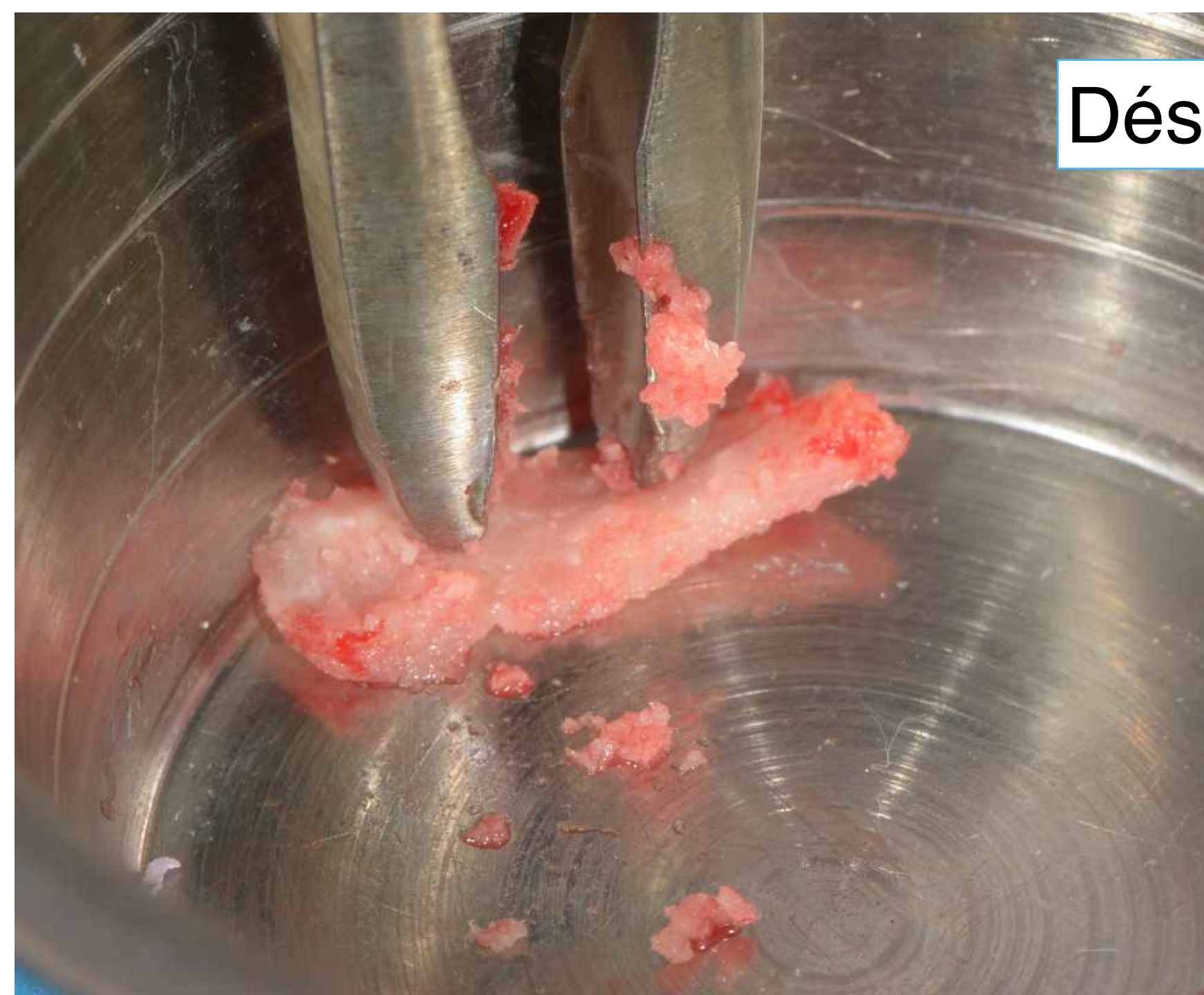




Sinus Lift + cloison + Augmentation horizontale

Technique du volet remplacé

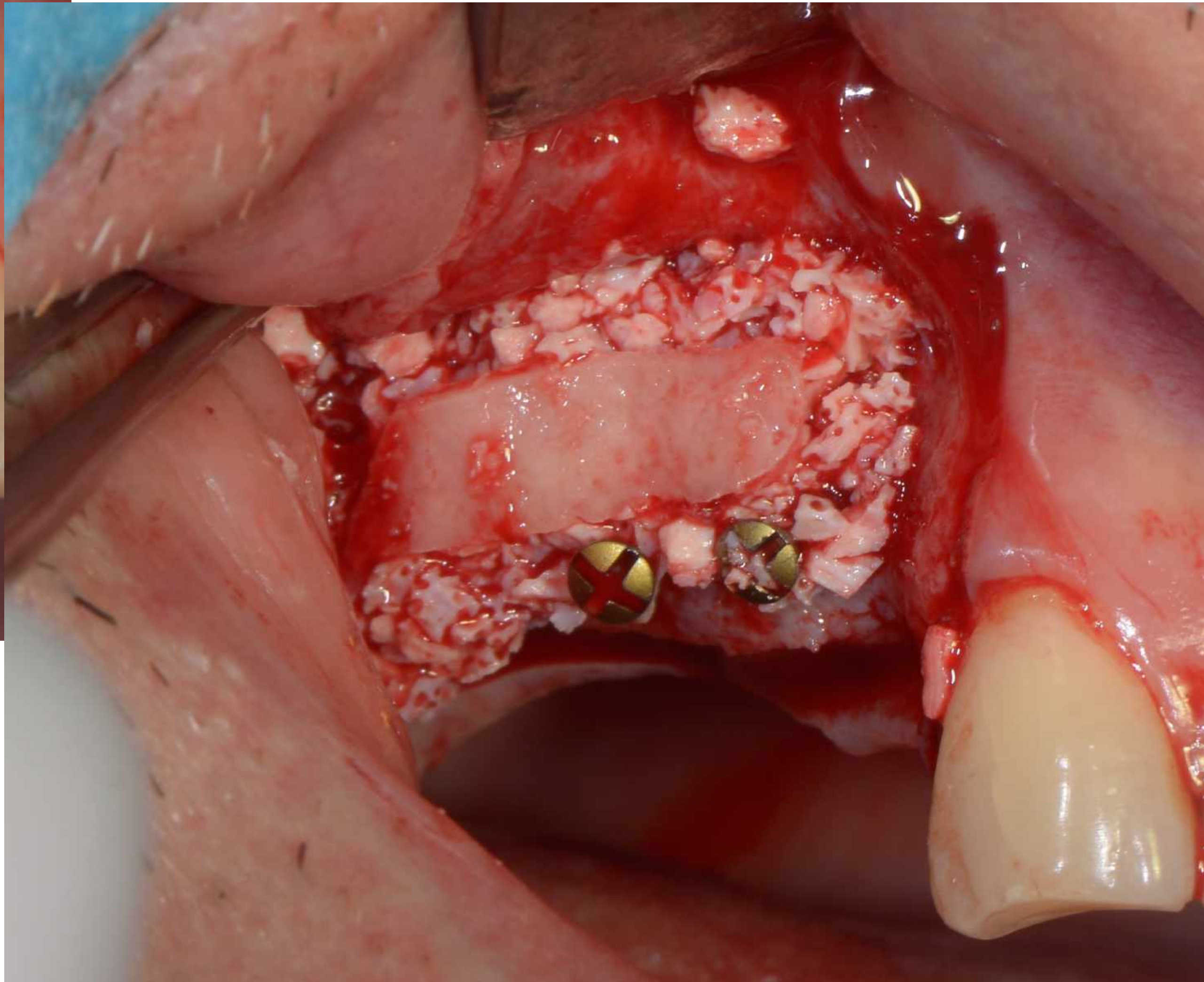
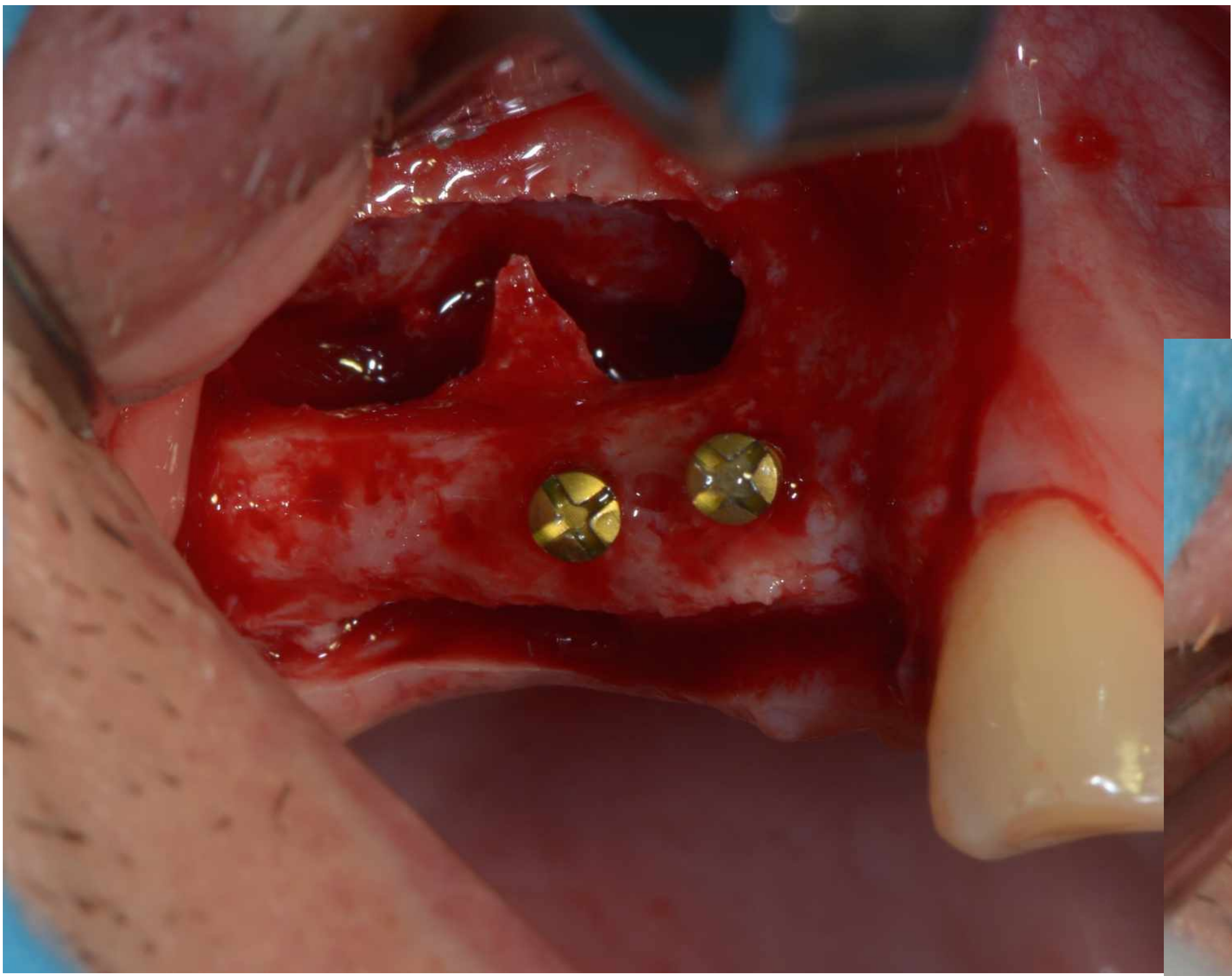


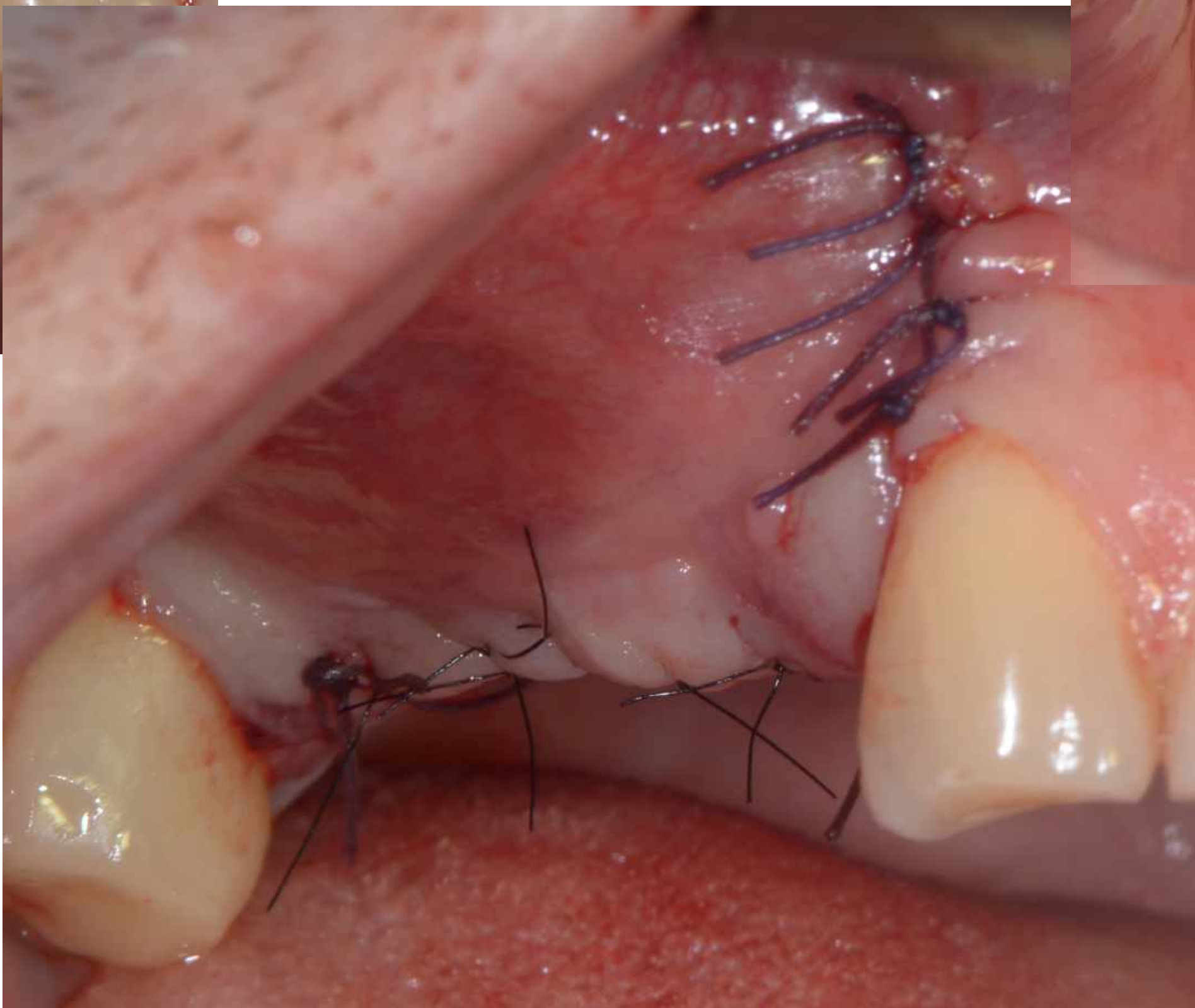
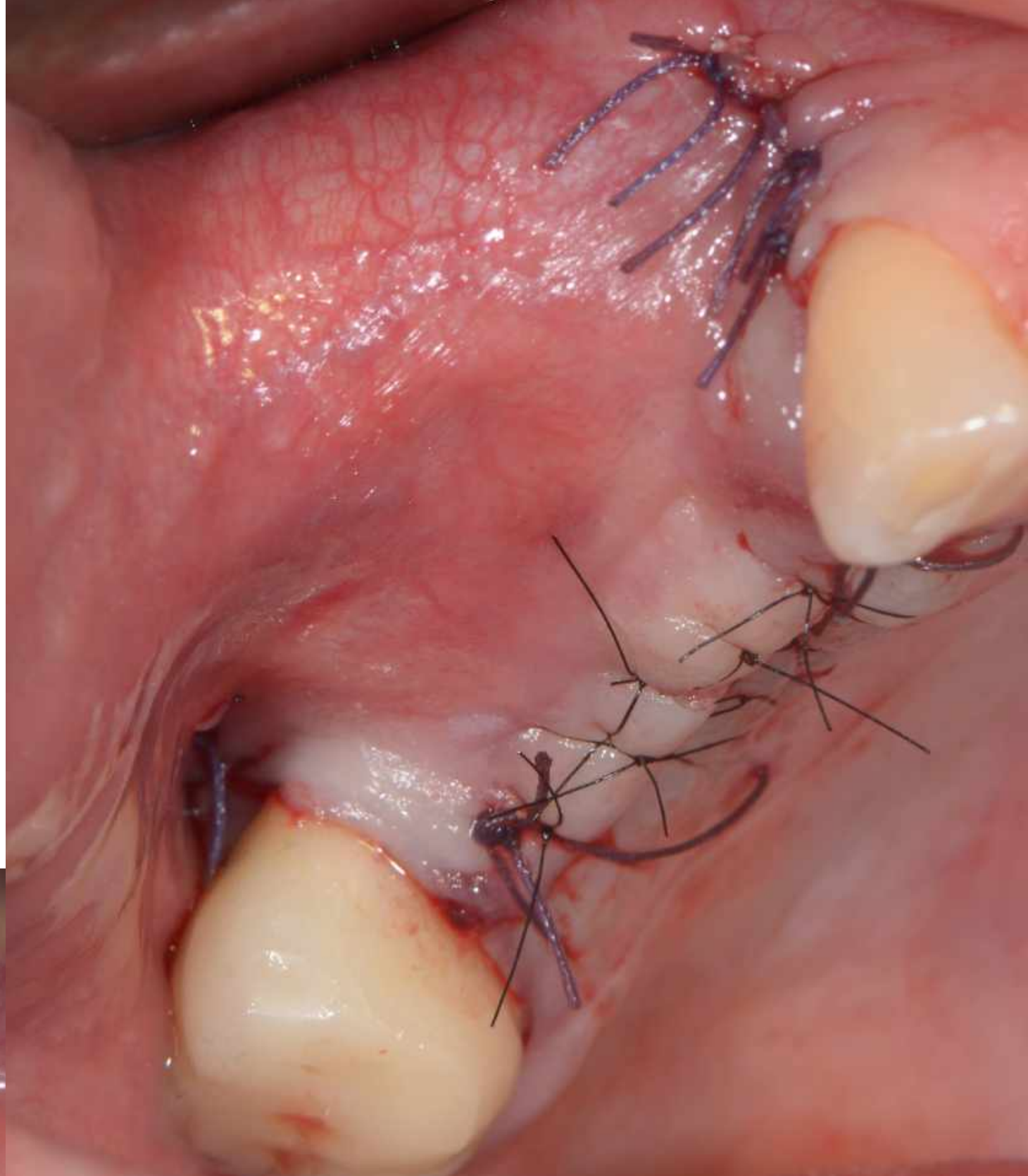
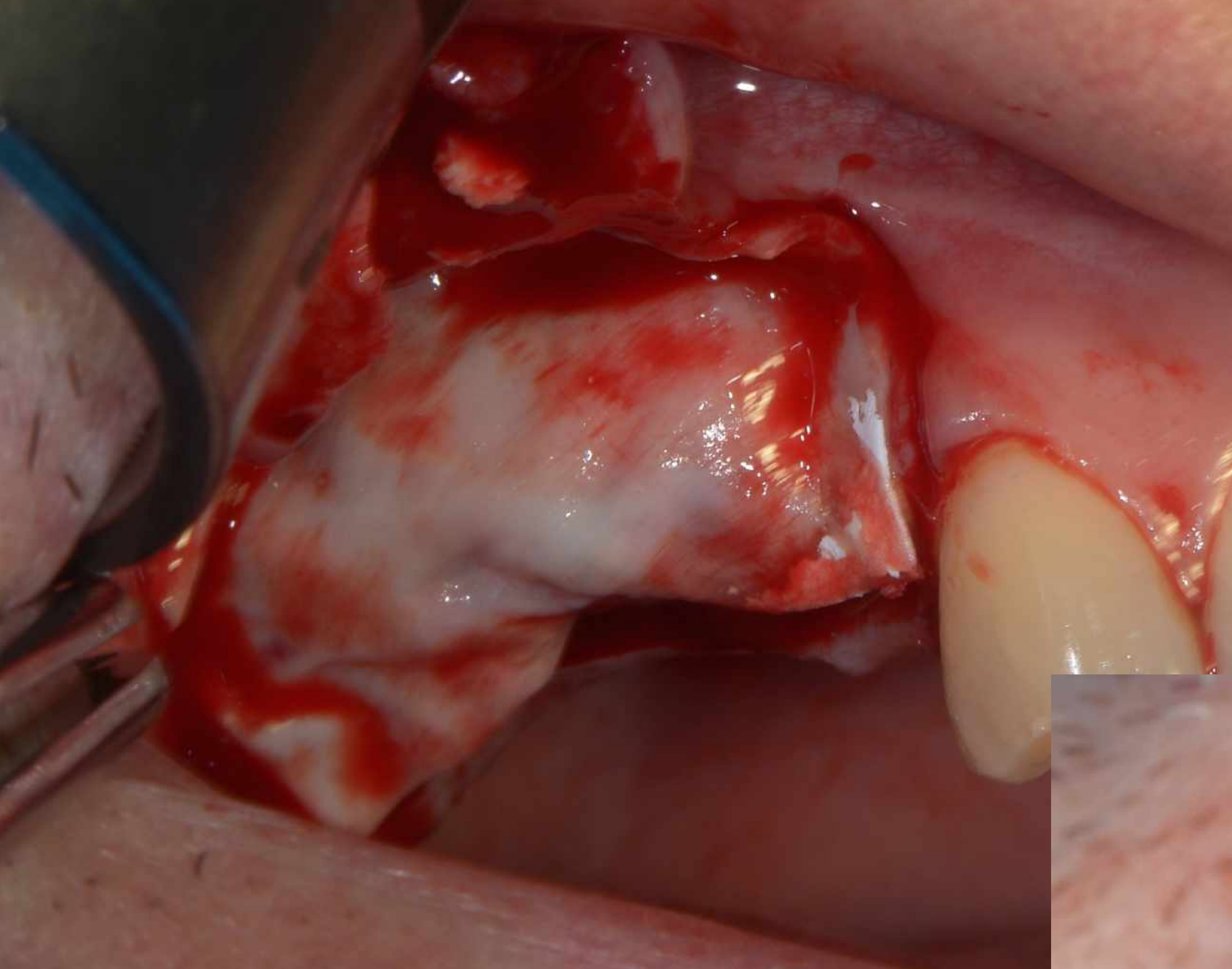


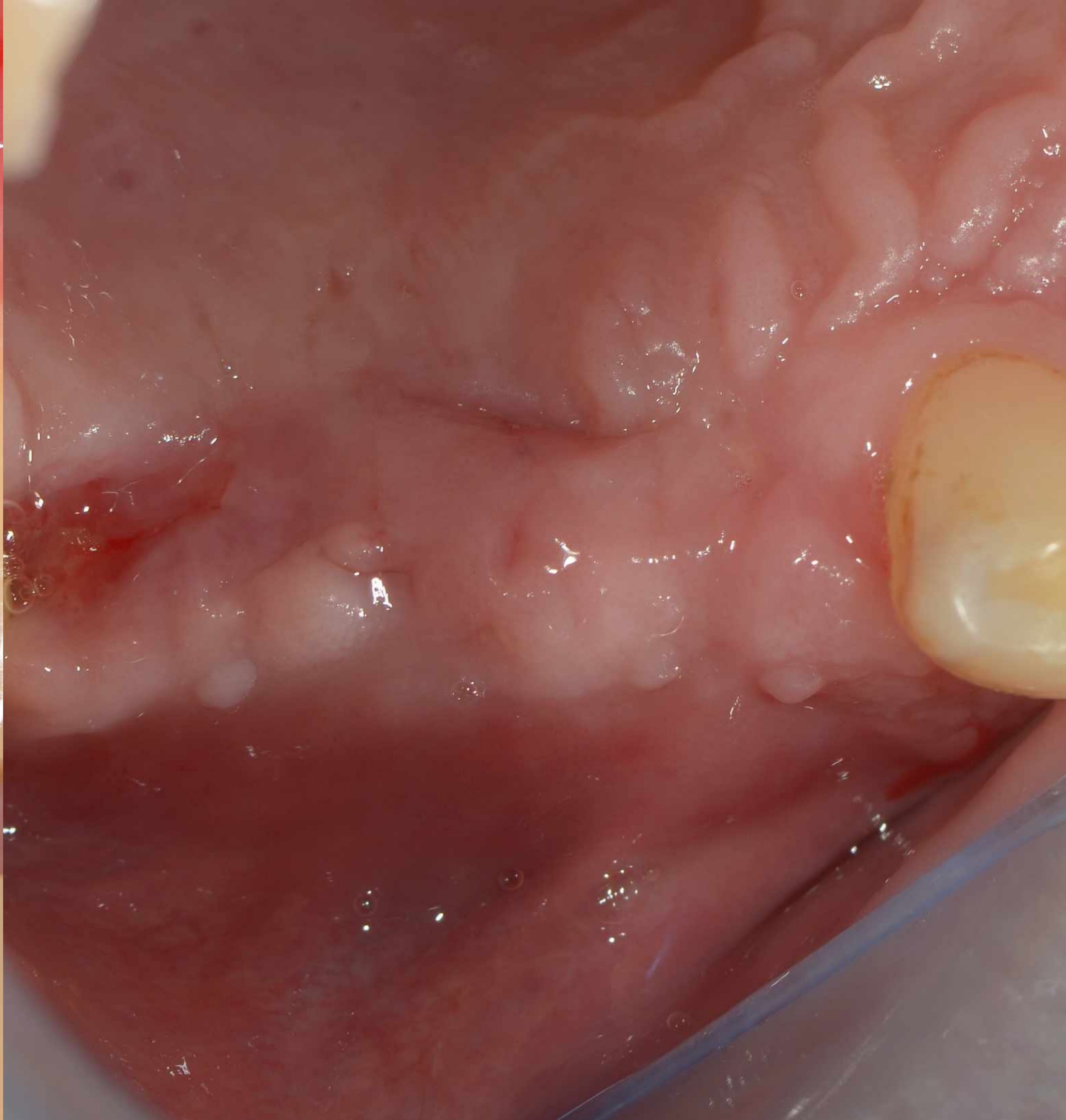
Désépaissir le volet

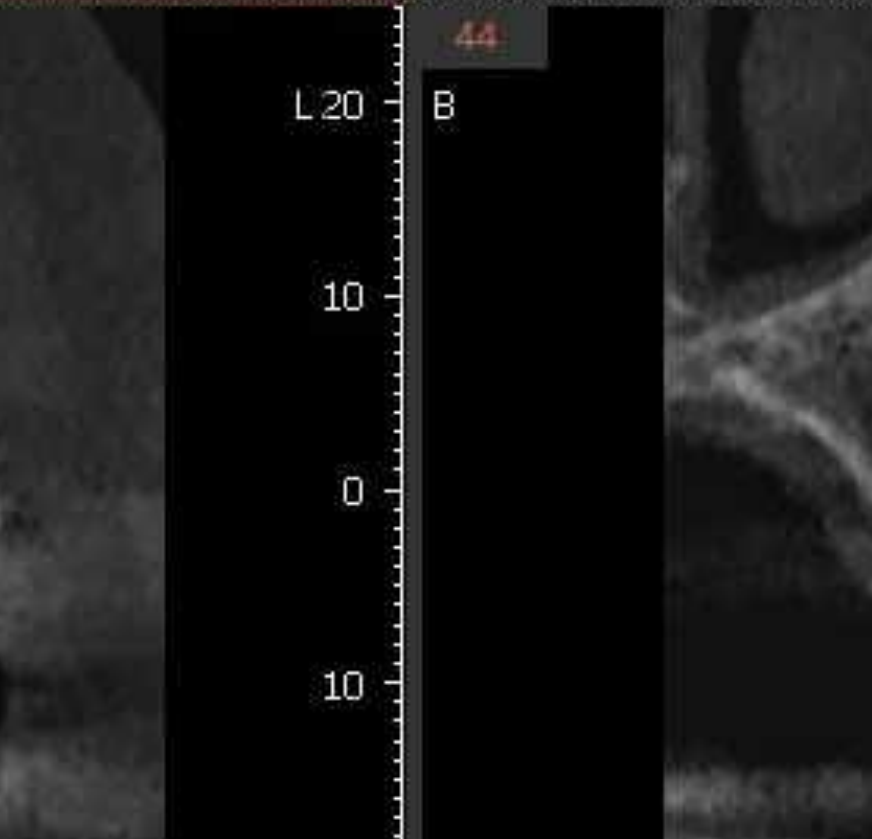
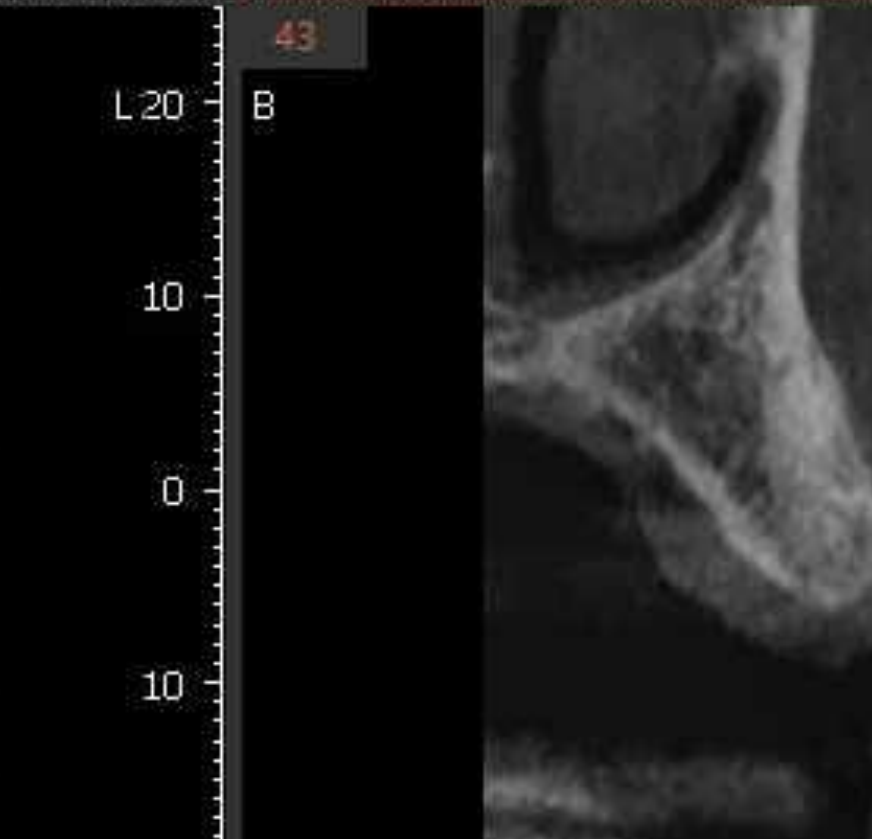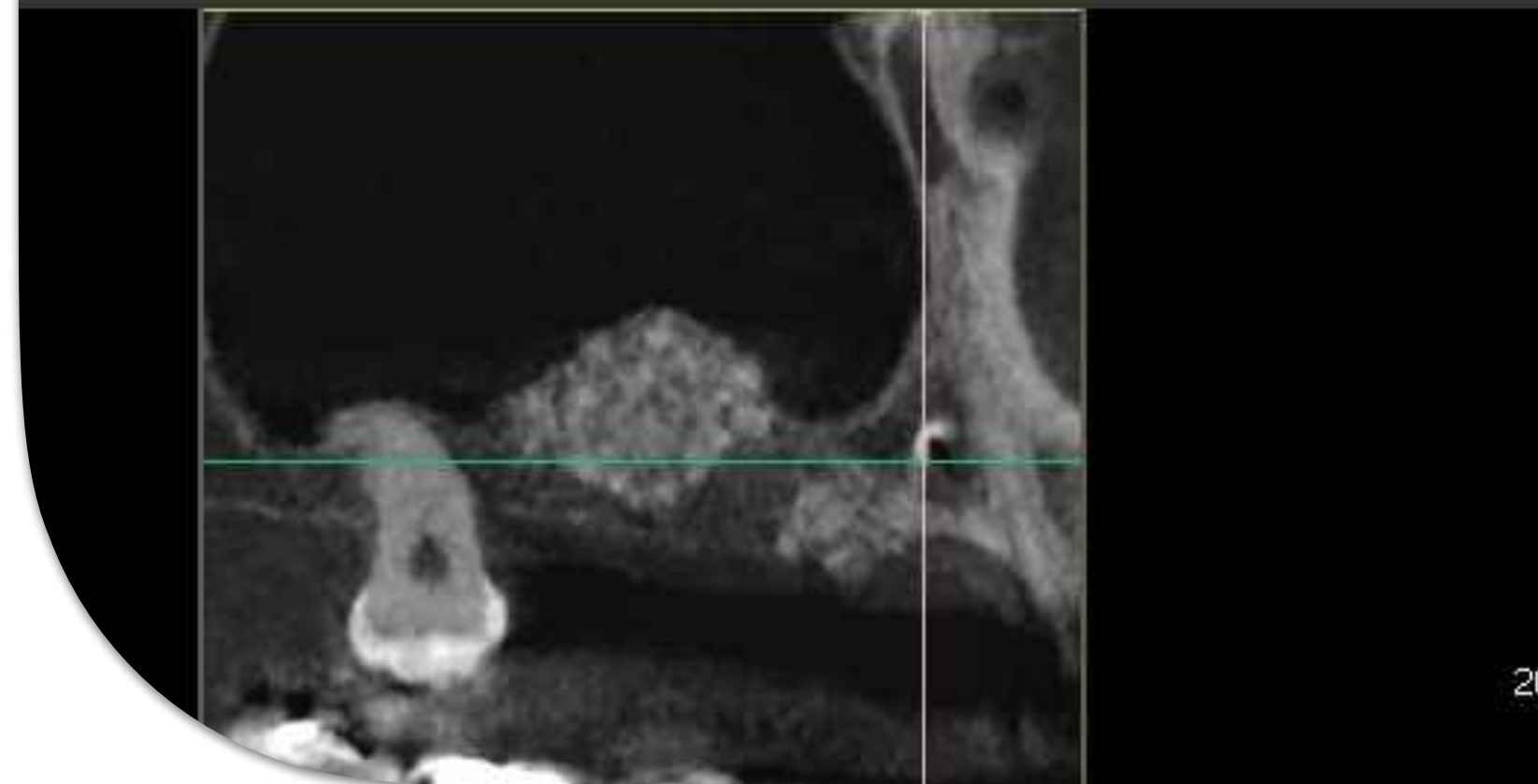
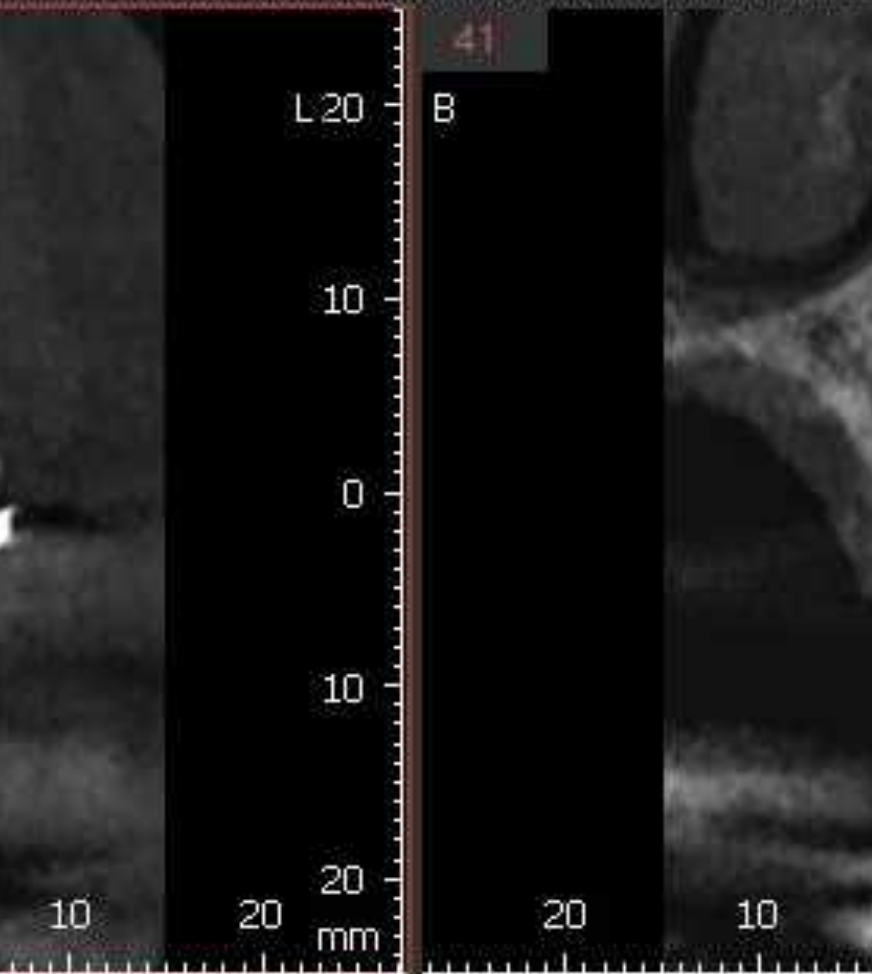
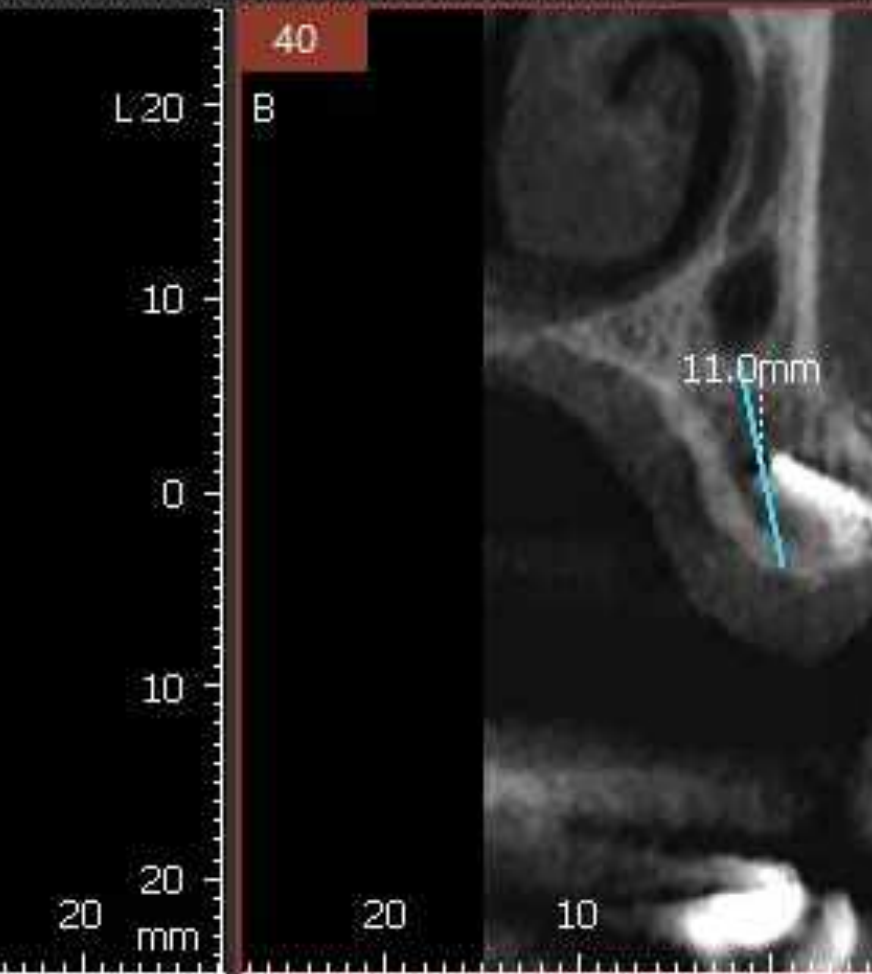
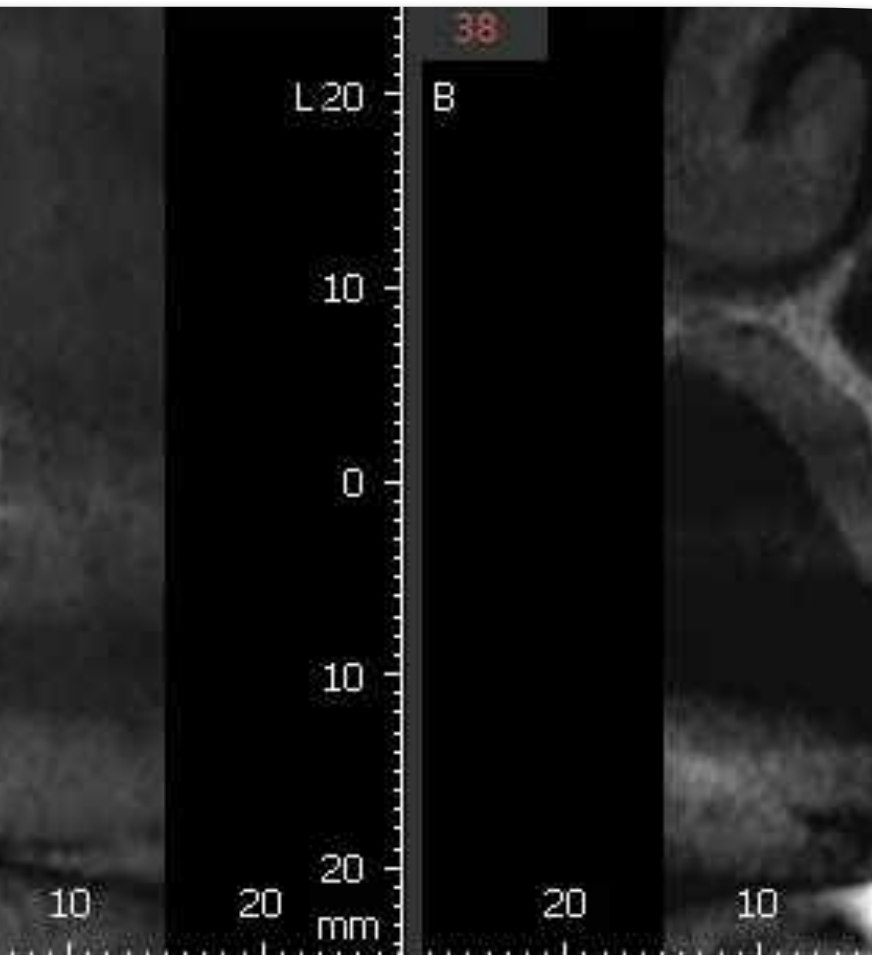
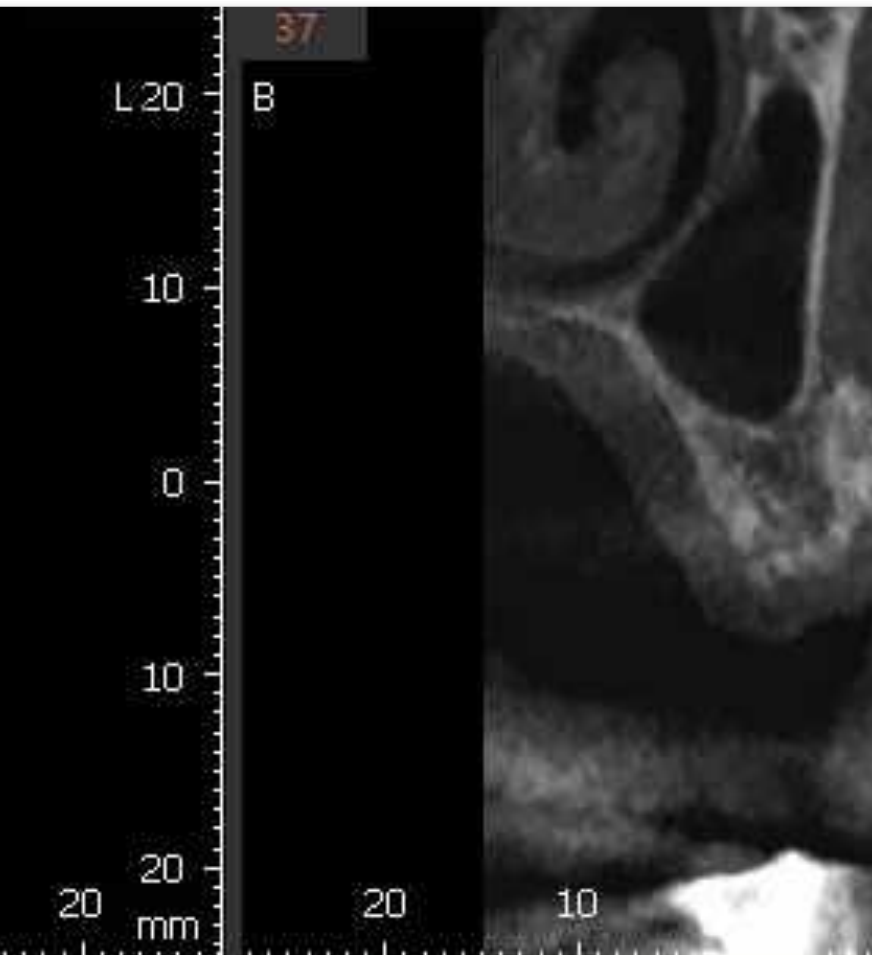
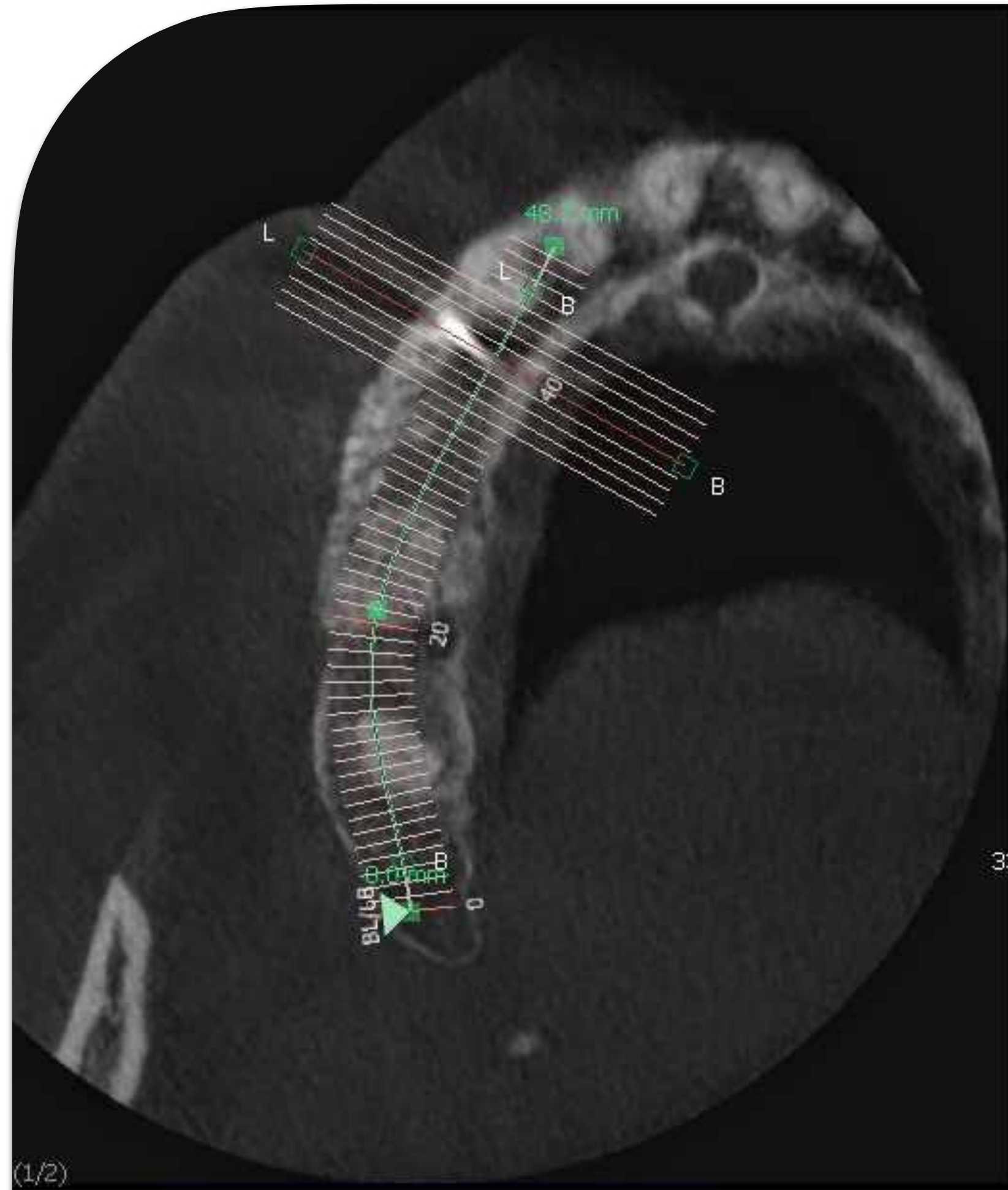


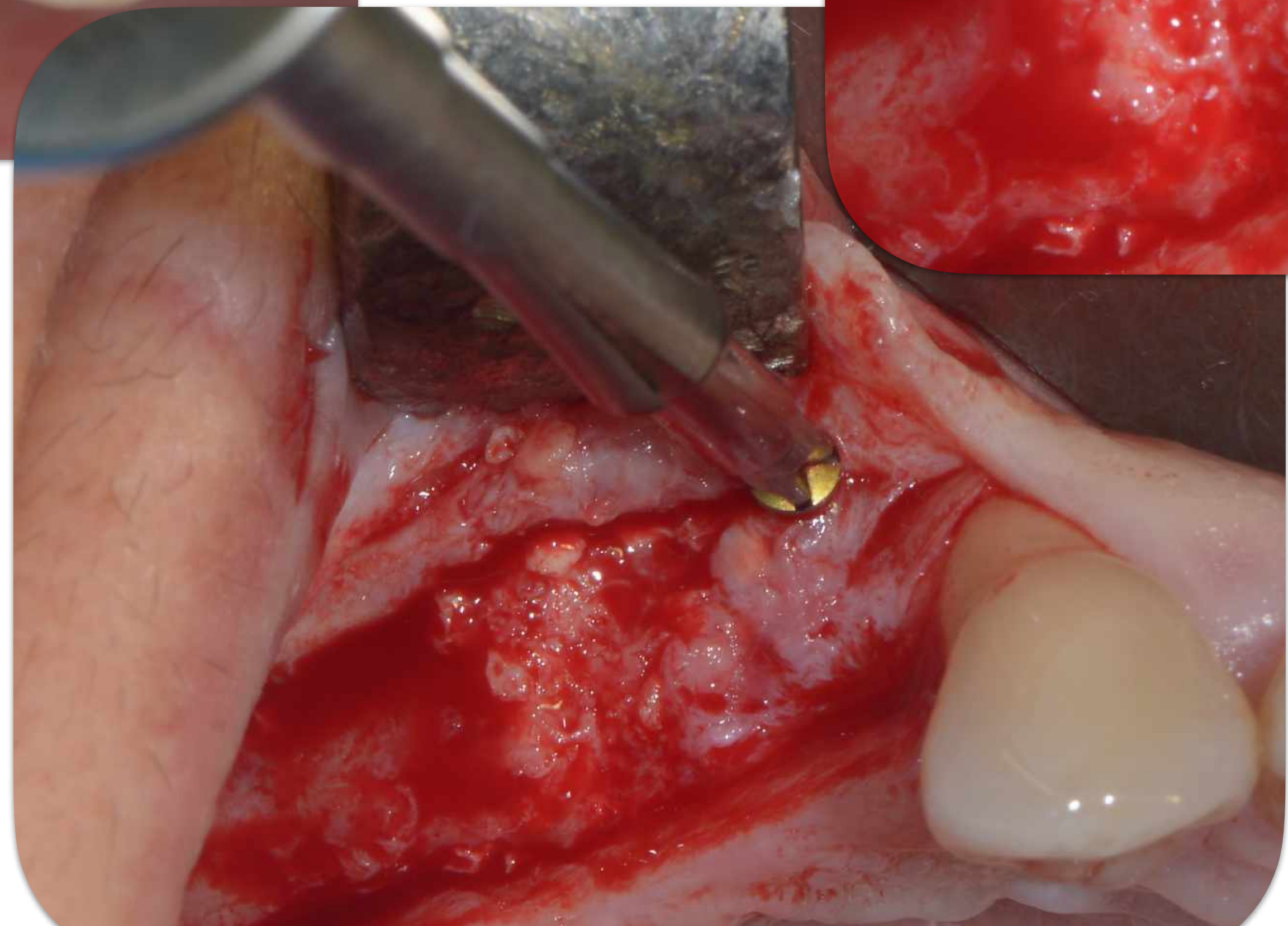
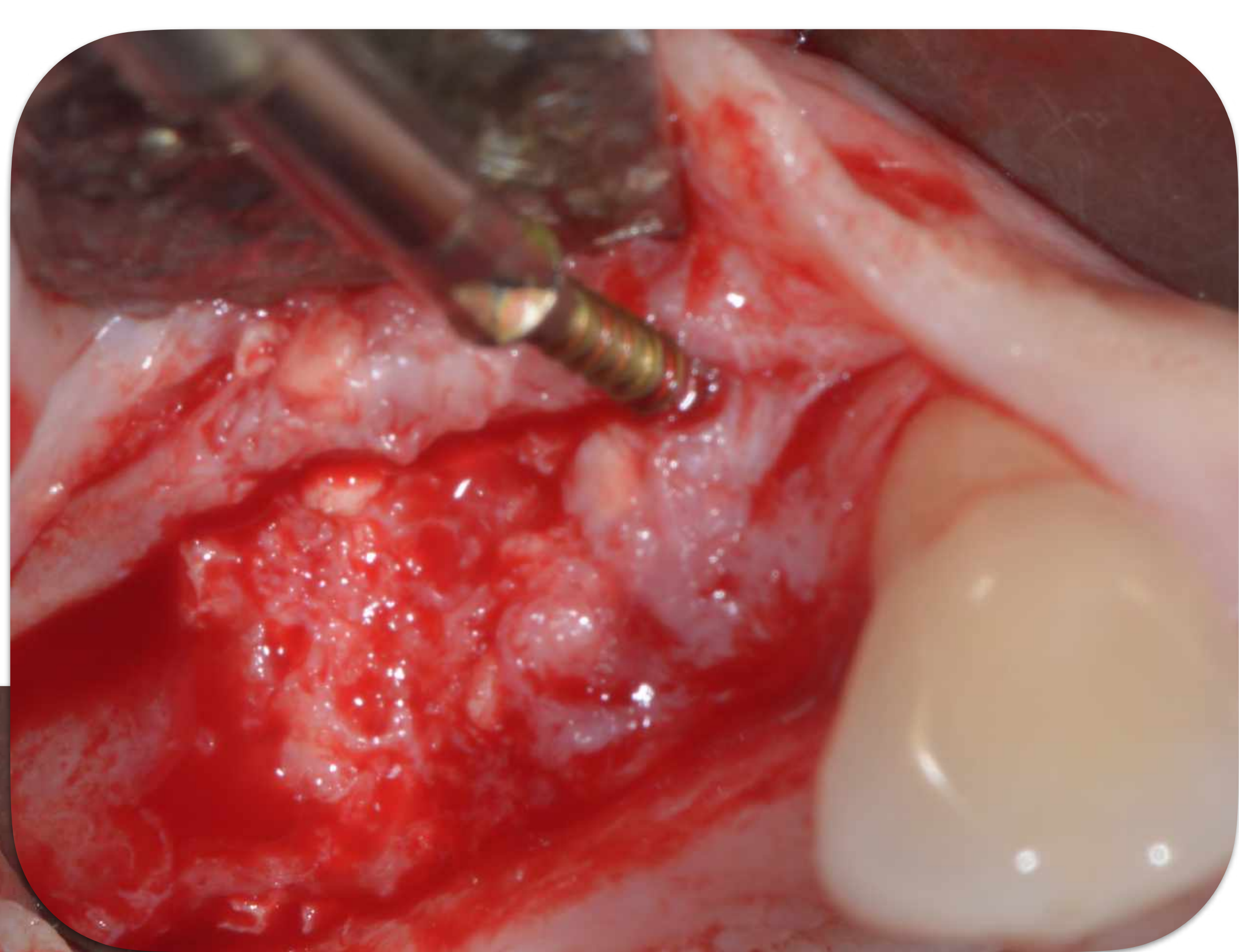
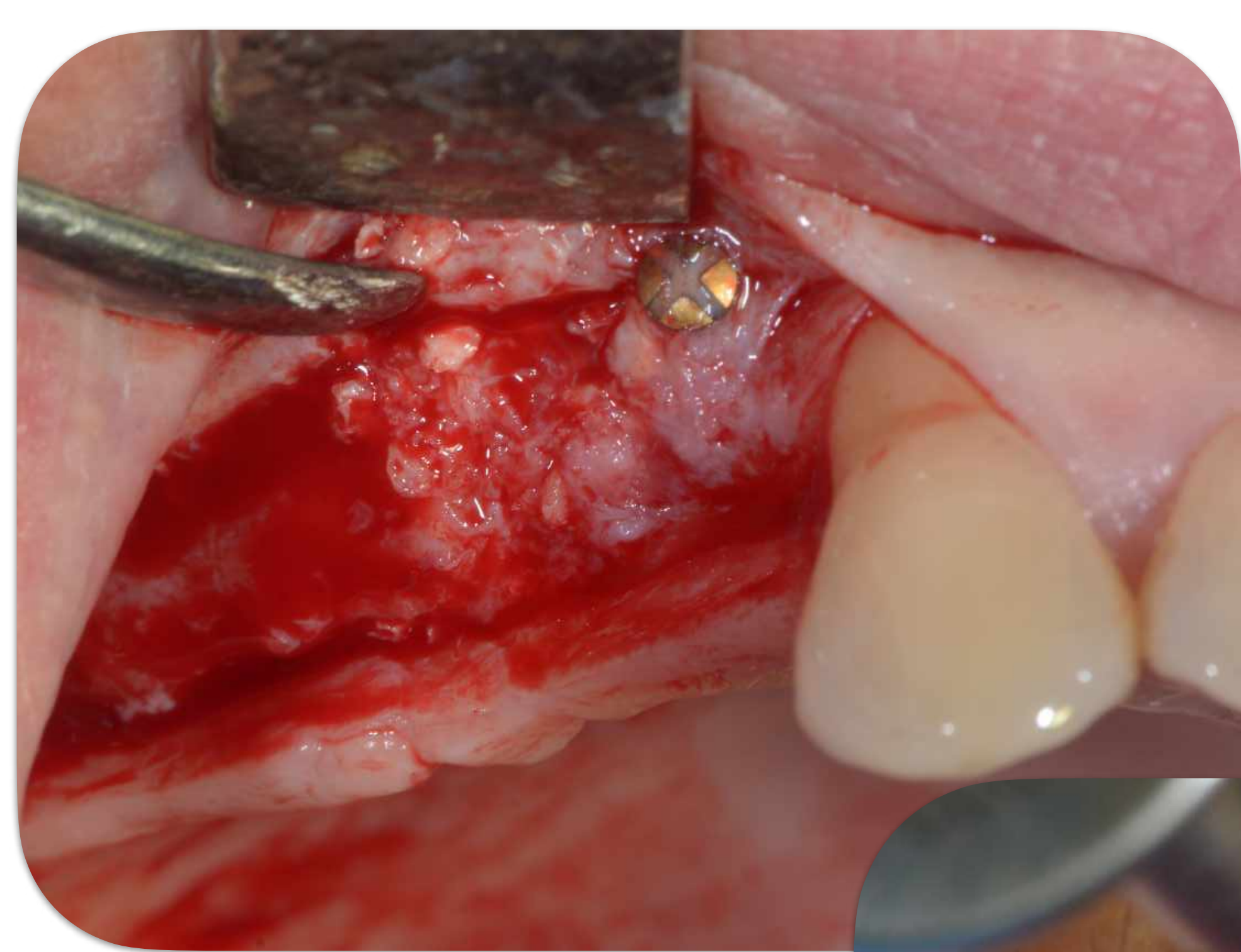
Augmentation Horizontale associée











Quels sont les limites de la pratique du volet latéral ?

Pathologie sinusienne

Condition de bloc opératoire

Matériel chirurgical spécifique

Maîtrise de la technique

Gestion des complications per-opératoires

Oedème post-op

Délais d'implantation : 6-8 mois

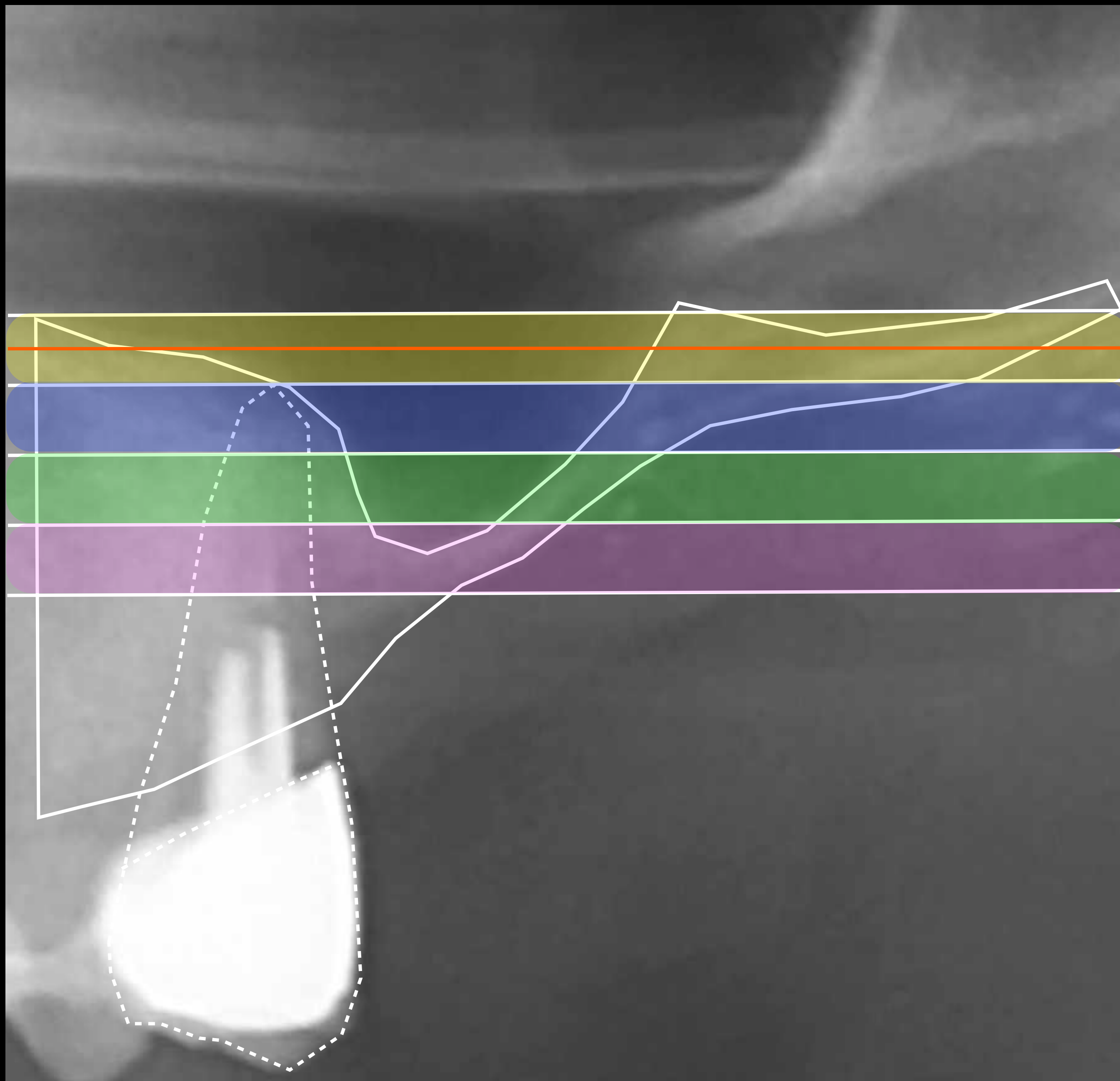
Conseils post-opératoires

Ne pas se moucher

Ne pas bloquer les éternuements

Éviter les pressions intrasinusiennes :

Plongée ou Avion



8
6
4
2
0

Summers — 7 Imp Court
Summers modifié
Sinus Lift + Implant
Sinus Lift